

## CASE REPORT

# Persistent Tight Hamstrings Following Conservative Treatment for Apophyseal Ring Fracture in Adolescent Athletes : Critical Appraisal

Ryo Miyagi<sup>1</sup>, Koichi Sairyo<sup>1,2</sup>, Toshinori Sakai<sup>1</sup>, Fumitake Tezuka<sup>1</sup>,  
Yasuhiro Kitagawa<sup>2</sup>, and Akira Dezawa<sup>2</sup>

<sup>1</sup>Department of Orthopedics, Institute of Health Biosciences, the University of Tokushima Graduate School, Tokushima, Japan, <sup>2</sup>Department of Orthopedics, Teikyo University Mizonokuchi Hospital, Tokyo, Japan

**Abstract :** Apophyseal ring fracture is a unique disease in children and adolescents. Its clinical features include low back pain, sciatica, paravertebral muscle spasm and tenderness, restricted back motion, neurological symptoms, and tight hamstrings. For all athletes, body flexibility is one of the most important factors for better performance. Therefore, persistent tight hamstrings has a negative influence on athletic performance. In this report, we present two adolescent athletes with apophyseal ring fracture treated successfully by conservative treatment for severe low back pain (LBP) and leg pain, despite having persistent tight hamstrings for more than one year. Unlike herniated nucleus pulposus, bony fragments in the spinal canal never disappear. Although conservative treatment can alleviate LBP and leg pain, surgical removal of fragments is considered when symptoms such as tight hamstrings and restricted lumbar motion due to canal stenosis are found, particularly in athletes. *J. Med. Invest.* 61 : 446-451, August, 2014

**Keywords :** Immature spine, Apophyseal ring fracture, Tight hamstrings, Conservative treatment

## INTRODUCTION

Posterior apophyseal ring fracture is an avulsion fracture characterized by separation of an osseous fragment at the posterior edge of the vertebral body, where fusion between ring apophysis and the adjacent vertebral body does not complete fully until the age of approximately 18 years (1). Thus, posterior apophyseal ring fracture usually occurs in children and adolescents with immature spines. Although its etiology is unclear, chronic stress and

repetitive trauma are thought to be causative factors. Clinical features of posterior apophyseal ring fracture are similar to those of lumbar disc herniation (LDH), for which conservative treatment should initially be given. However, unlike patients with LDH, conservative treatment is not always effective because the bony fragments never resolve spontaneously. Some authors have suggested that the indication for surgical treatment depends on the size of the bony fragment (2-5). However, resection of the fractured endplate can lead to instability of the spinal segment. Therefore, conservative treatment is favorable.

Tight hamstrings are typical symptoms of LDH, especially in children, and are related to traction of the cauda equina or nerve roots that innervate the hamstrings. Limitation of forward flexion and poor

Received for publication May 26, 2014 ; accepted July 1, 2014.

Address correspondence and reprint requests to Koichi Sairyo, MD and PhD, Professor, Department of Orthopedics, Institute of Health Biosciences, the University of Tokushima Graduate School, 3-18-15 Kuramoto-cho, Tokushima, 770-8503, Japan and Fax : +81-88-633-0178.

scores in the restricted straight leg raising test (SLRT) are the main symptoms of tight hamstrings. For all athletes, body flexibility is one of the most important factors for better performance. Therefore, persistent tight hamstrings has a negative influence on athletic performance.

In this paper, we present two adolescent athletes with persistent tight hamstrings following conservative treatment for posterior apophyseal ring fracture for critical appraisal.

## CASE REPORTS

### Case 1

A 12-year-old boy who belongs to a tennis club of his junior high school noticed low back pain (LBP) and bilateral leg pain after rope jumping. He was diagnosed as having lumbar apophyseal ring fracture and referred to our hospital for surgical treatment. On physical examination, neurological findings such as muscle weakness or sensory disturbance were not observed, but the SLRT was positive at 20 degrees on the right and positive at 10 degrees on the left.

Plain radiography revealed a small bony fragment posterior to the upper L4 endplate (Fig. 1). As vertebral bodies were immature in the cartilaginous stage, no ossification was identified at the corner of the vertebral bodies. Magnetic resonance imaging (MRI) showed central protrusion of the L4/5 disc, but the corresponding bony fragment was not clearly

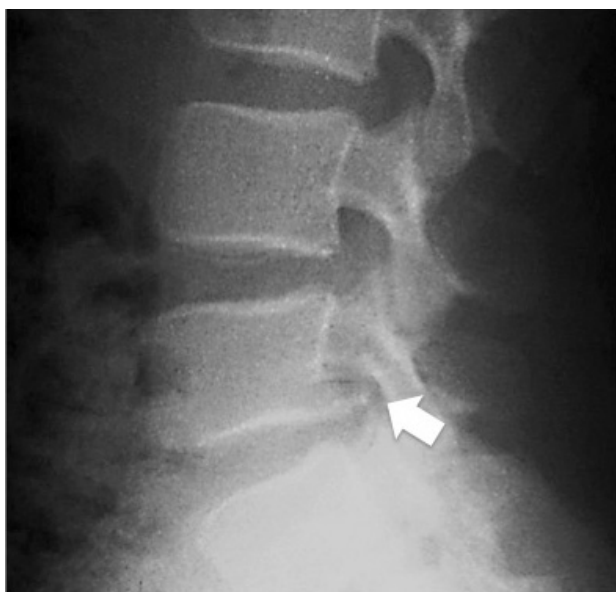

Figure 1 Lateral plain radiograph showing a bony fragment (arrowed) posterior to the upper L4 endplate

seen (Fig. 2A, B and C). Computed tomography (CT) revealed an apophyseal ring fracture in the lower L4 endplate (Fig. 3).

The patient was successfully managed by conservative treatment, and his LBP and leg pain resolved

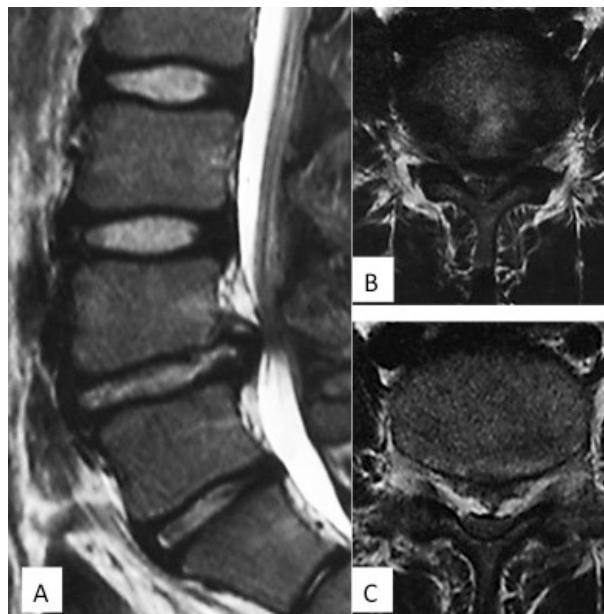

Figure 2 Sagittal (A) and axial T1 (B) and T2 (C)-weighted magnetic resonance image showing degenerative change and protrusion of the L4/5 disc, but no corresponding bony fragment was clearly seen

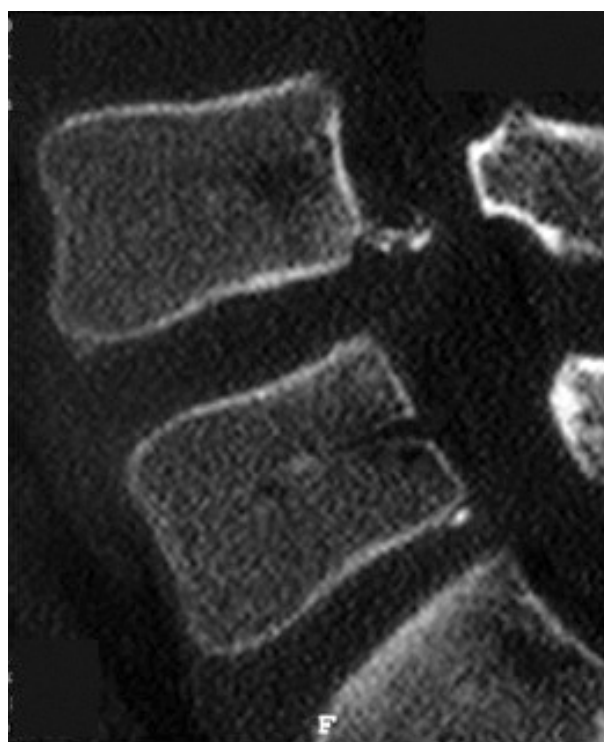


Figure 3 Sagittal reconstructed computed tomography scan showing the fractured apophyseal ring of the lower endplate of L4

completely. Although he experienced no difficulties in daily life, a limitation of forward lumbar flexion remained at the four-month follow up. His finger to floor distance (FFD) was still about 60 cm, and the SLRT was negative (painless), but limited to 40 degrees on the right and 10 degrees on the left due to tight hamstrings. He still has difficulty in forward lumbar flexion as a tennis player.

#### Case 2

A 12-year-old girl who was a high-level figure skater experienced severe LBP during practice. She was the high-ranking junior figure skater. Despite refraining from sports activities for two weeks, her LBP increased and right leg pain developed. Physical examination revealed no neurological findings. Range of lumbar motion during flexion was severely restricted due to LBP. FFD was limited to 36 cm, and the SLRT was positive at 40 degrees bilaterally due to leg pain.

On plain radiography, no fracture fragment was clearly seen (Fig. 4), and vertebral bodies were in the cartilaginous stage. MRI revealed severe central L5/S1 disc protrusions (Fig. 5A and B), and CT showed a central curvilinear bony fragment arising from the S1 superior endplate (Fig. 6A and B). The bony fragment's relationship to the disc protrusion and S1 corner truncation was particularly well demonstrated on reconstructed sagittal images (Fig. 6A and B).

The patient was treated conservatively, and her LBP subsided gradually over six months. At the

nine-month follow up, her tight hamstrings had improved. The FFD was 0 cm and SLRT was negative, but limited to 70 degrees on the right. However, she was unable to achieve sufficient flexibility for figure skating so finally retired from the sport.

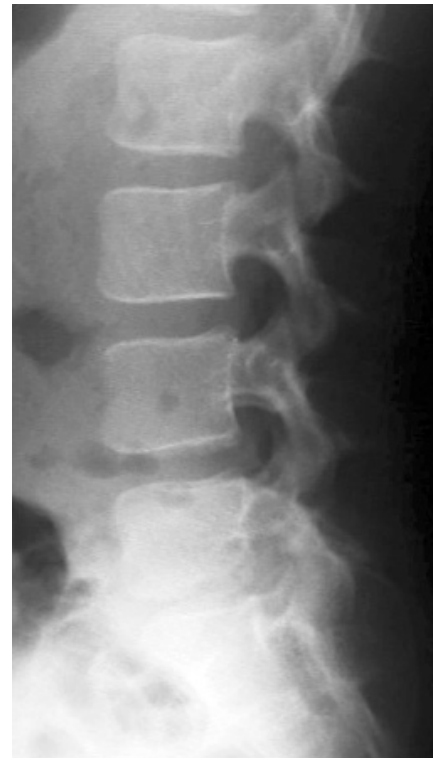

Figure 4 Plain radiograph showing no clear fracture fragment  
Vertebral bodies are in the cartilaginous stage

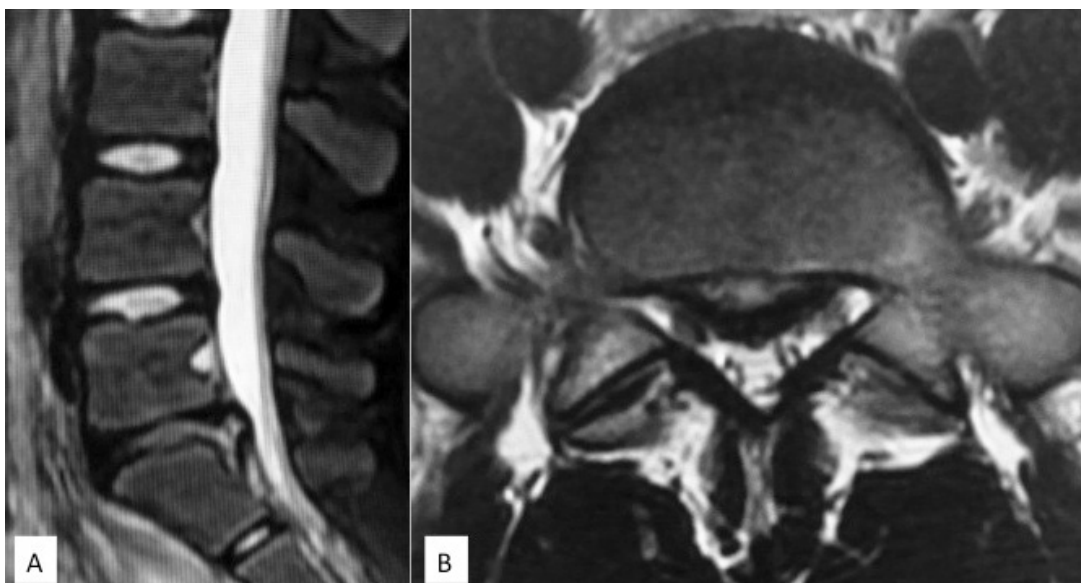


Figure 5 Magnetic resonance image showing severe central L5/S1 disc protrusions

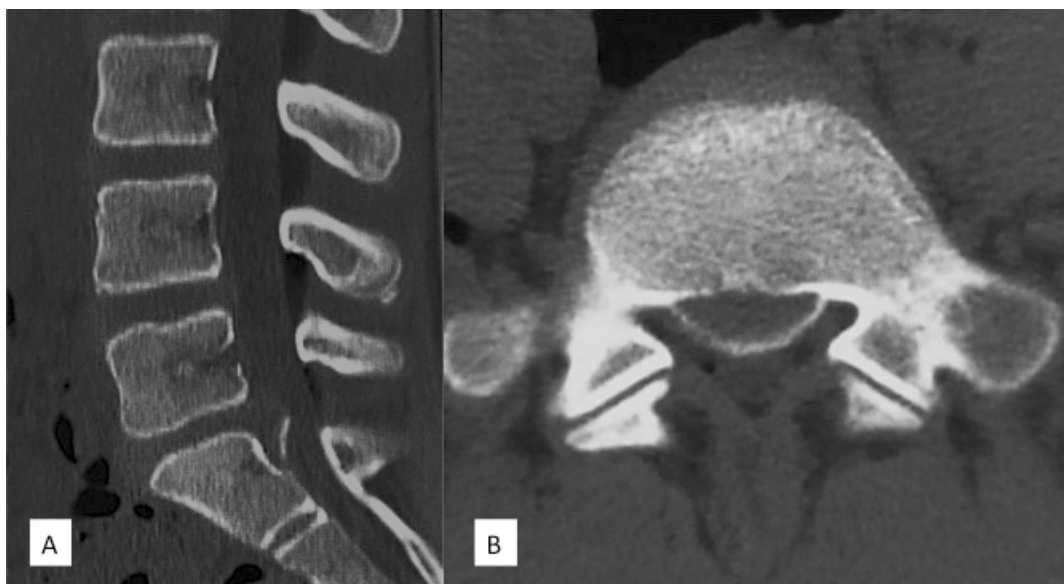

Figure 6 Sagittal (A) and axial (B) reconstructed CT scans showing the fractured apophyseal ring of the superior endplate of S1

## DISCUSSION

The vertebral ring apophysis in the immature spine develops as a cartilaginous rim at the margins of the superior and inferior lumbar endplates (1). Ossification of these cartilaginous processes starts around the age of 5 years, and apophyses are fused to the vertebral bodies by the age of approximately 18 years (1). The vertebral body is firmly attached to the annulus fibrosis by Sharpey fibers (6). Until this fusion is complete, this osteocartilaginous junction is relatively weak against biomechanical stress (7, 8).

Apophyseal ring fractures occur frequently at the posterior endplate of L5 and the sacrum (3). Chronic stress and repetitive trauma may cause apophyseal ring fracture, and it can develop insidiously. Acute trauma is also thought to be an important etiologic factor mediating the onset of symptoms (9, 10). In a biomechanical study, Sairyó *et al.* used three-dimensional finite element pediatric lumbar models to investigate the effect of ring ossification in the lumbar spine (11). They found that increased stress under repetitive extension might damage and weaken the posterior ring apophysis during the early stage of bone formation, resulting in avulsion of the weakened posterior corner in response to traction stress during flexion (11). In the present cases, there were no acute significant traumatic episodes; repetitive hyperextension and hyperflexion of the lumbar spine during athletic activities might have caused this fatigue phenomenon.

The most common symptoms and physical findings of apophyseal ring fracture include low back pain, sciatica, paravertebral muscle spasms and tenderness, tight hamstrings, restricted back motion, and neurological dysfunction caused by a compressed nerve root (12). Typical features of this disease are a limitation of forward flexion, restricted SLR, and tight hamstrings due to compression of the dura mater. The hamstrings are innervated by the L4-S3 spinal nerves, and their motor fibers are very sensitive to traction (7). It has been thought that tight hamstrings are related to traction of the cauda equina or the nerve roots that supply the hamstrings (13). Anatomically, nerve roots in the immature spines are too short in relation to the spinal canal, which may render the nerve roots sensitive to traction, even with minor encroachments compared with adults (14).

Conservative treatment should be prescribed initially (15-17). The principle of conservative treatment is similar to that for an avulsion fracture of the extremities and consists of bed rest, analgesic and nonsteroidal anti-inflammatory drugs, physical therapy, and limited physical activity with lumbar braces. Jack-knife stretching, which can promote flexibility of tight hamstrings, was not prescribed in either case because of the severe pain during forward flexion (18). Surgical treatment is performed in cases of failed conservative treatment, with persistent back pain adversely affecting the patient's ability with or without neurological deficits (19, 20).

Most adolescents and adults who are treated

surgically for apophyseal ring fractures show good to excellent results, and their symptoms are satisfactorily relieved (2-5). In some studies, the clinical results of simultaneous excision of apophyseal fragments with discectomy are satisfactory (3, 4, 21), while the results of other studies have suggested that only discectomy and decompression have been sufficient (15, 22). Chang *et al.* reported patients with small apophyseal fragments that had no clinical significance, but the large apophyseal fragments had more chance of producing chronic back pain and limitations in daily activities (21).

Compared with disc herniation, osseous material may trigger more severe symptoms because the bony fragment never disappears and may lead to bony spinal stenosis (21). The bony fragments in the present cases were large and therefore occupied a large space in the spinal canal. Although LBP and leg pain were resolved, tight hamstrings, which were thought to be due to canal stenosis, persisted. On the basis of this clinical experience, surgical removal of fragments should be considered when symptoms such as tight hamstrings or restricted lumbar motion due to canal stenosis are found. High flexibility is required by almost all sports. We think that restricted lumbar flexion caused by tight hamstrings is fatal on playing sports. For athletes in particular, surgical removal should be considered.

In this case series we can report only two cases. We should collect same cases and state the treatment algorithm for apophyseal ring fracture. In any case, we should consider the treatment based on various factors such as age, neurological findings, size of bone fragment or the kind of sport.

## CONFLICT OF INTEREST

No funds were received in support of this study.

## REFERENCES

1. Bick EM, Copel JW : The ring apophysis of the human vertebra. *J Bone Joint Surg Am* 33 : 783-7, 1951
2. Albeck MJ, Madsen FF, Wagner A, Gjerris F : Fracture of the lumbar vertebral ring apophysis imitating disc herniation. *Acta Neurochir (Wien)* 113 : 52-56, 1991
3. Epstein NE : Lumbar surgery for 56 limbus fractures emphasizing noncalcified type III lesions. *Spine (Phila Pa 1976)* 17 : 1489-1496, 1992
4. Farrokhi MR, Masoudi MS : Slipped vertebral epiphysis (report of 2 cases). *J Res Med Sci* 14 : 63-66, 2009
5. Ishihara H, Matsui H, Hirano N, Tsuji H : Lumbar intervertebral disc herniation in children less than 16 years of age. Long-term follow-up study of surgically managed cases. *Spine* 22 : 2044-2049, 1997
6. Keller RH : Traumatic displacement of the cartilaginous vertebral rim : a sign of intervertebral disc prolapse. *Radiology* 110 : 21-24, 1974
7. Dake MD, Jacobs RP, Margolin FR : Computed tomography of lumbar apophyseal ring fractures. *J Comput Assist Tomogr* 9 : 730-732, 1985
8. Yagan R : CT diagnosis of limbus vertebra. Case report. *J Comput Assist Tomogr* 8 : 149-15, 1984
9. Lowrey JJ : Dislocated lumbar vertebral epiphysis in adolescent children. Report of three cases. *J Neurosurg* 38 : 232-234, 1973
10. Epstein NE, Epstein JA, Mauri T : Treatment of fractures of the vertebral limbus and spinal stenosis in five adolescents and five adults. *Neurosurgery* 24 : 595-604, 1989
11. Sairyo K, Goel VK, Masuda A, Vishnubhotla S, Faizan A, Biyani A, Ebraheim N, Yonekura D, Murakami R, Terai T : Three-dimensional finite element analysis of the pediatric lumbar spine. Part I : pathomechanism of apophyseal bony ring fracture. *Eur Spine J* 15 : 923-929, 2006
12. Atalay A, Akbay A, Atalay B, Akalan N : Lumbar disc herniation and tight hamstrings syndrome in adolescence. *Childs Nerv Syst* 19 : 82-85, 2003
13. Barash HL, Galante JO, Lambert CN, Ray RD : Spondylolisthesis and tight hamstrings. *J Bone Joint Surg Am* 52 : 1319-1328, 1970
14. Kramer J : Intervertebral disc diseases causes, diagnosis, treatment and prophylaxis, 2nd edn. Thieme, Stuttgart, 1990
15. Laredo JD, Bard M, Chretien J, Kahn MF : Lumbar posterior marginal intra-osseous cartilaginous node. *Skeletal Radiol* 15 : 201-208, 1986
16. Takata K, Inoue S, Takahashi K, Ohtsuka Y : Fracture of the posterior margin of a lumbar vertebral body. *J Bone Joint Surg Am* 70 : 589-594, 1988

17. Higashino K, Sairyō K, Katoh S, Takao S, Kosaka H, Yasui N : Long-term outcomes of lumbar posterior apophyseal end-plate lesions in children and adolescents. *J Bone Joint Surg Am* 94(11) : e74, 2012
18. Sairyō K, Kawamura T, Mase Y, Hada Y, Sakai T, Hasebe K, Dezawa A : Jack-knife stretching promotes flexibility of tight hamstrings after 4 weeks : a pilot study. *Eur J Orthop Surg Traumatol* [Epub ahead of print], 2012
19. Fujita K, Shinmei M, Hashimoto K, Shimomura Y : Posterior dislocation of the sacral apophyseal ring. A case report. *Am J Sports Med* 14 : 243-245, 1986
20. Savini R, Di Silvestre M, Gargiulo G, Picci P : Posterior lumbar apophyseal fractures. *Spine (Phila Pa 1976)* 16(9) : 1118-1123, 1991
21. Chang CH, Lee ZL, Chen WJ, Tan CF, Chen LH : Clinical significance of ring apophysis fracture in adolescent lumbar disc herniation. *Spine (Phila Pa 1976)* 33 : 1750-1754, 2008
22. Shirado O, Yamazaki Y, Takeda N, Minami A : Lumbar disc herniation associated with separation of the ring apophysis : is removal of the detached apophyses mandatory to achieve satisfactory results? *Clin Orthop Relat Res* 431 : 120-128, 2005