

CASE REPORT

Trends in electrocardiographic R-wave amplitude during intraoperative pneumothorax

Yoshinobu Tomiyama¹, Sachiyo Higashijima², Takako Kadota³, Katsuyoshi Kume², Tomiya Kawahara², and Naohiro Ohshita²

¹Division of Surgical Center, Tokushima University Hospital, the University of Tokushima, Tokushima, Japan, ²Department of Anesthesiology, Tokushima University Hospital, the University of Tokushima, Tokushima, Japan, ³Department of Anesthesia, Takamatsu Red Cross Hospital, Kagawa, Japan

Abstract : Tension pneumothorax is a rare but potentially life-threatening complication of laparoscopic fundoplication. Electrocardiogram (ECG) changes may be used in the diagnosis of intraoperative tension pneumothorax. This case study examines a pediatric patient who underwent laparoscopic fundoplication. Sudden decreases in oxygen saturation were observed during dissection, although the patient's decrease in blood pressure was less marked. Manual ventilation with high inspiratory pressure and inspiratory pause improved oxygenation. The amplitude of the R-wave decreased from 0.8 mV to 0.3 mV in 5 seconds. Twenty minutes later, oxygen saturation decreased again, the R-wave amplitude decreased from 0.3 mV to 0.1 mV in 1 second, and the decrease in blood pressure was marked. Manual ventilation with high inspiratory pressure improved oxygenation, blood pressure, and R-wave amplitude within two minutes. After conversion to open surgery, the cardiorespiratory condition gradually improved, but the R-wave amplitude did not fully recover, even at the end of surgery. Right-side pneumothorax was subsequently confirmed by postoperative chest X-ray. Chest drains were inserted after surgery. This case suggests that trends in R-wave amplitude are potential indicators of intraoperative tension pneumothorax. *J. Med. Invest.* 61 : 442-445, August, 2014

Keywords : electrocardiogram, pneumothorax, R-wave amplitude

INTRODUCTION

Intraoperative tension pneumothorax is a rare (1) but potentially life-threatening complication of laparoscopic fundoplication. Singhal *et al.* reported that the incidence of tension pneumothorax during endoscopic fundoplication is 0.66% (2). Rapid and precise diagnosis and therapy are needed to ensure patients' safety ; however, diagnosis and treatment

of intra-operative pneumothorax can be difficult (3-5), especially in small children. Changes on ECG can provide clues to the diagnosis of tension pneumothorax (3, 4), although there is controversy regarding the usefulness of this indicator (6). Trends in R-wave amplitude have not been described with an exception of animal study (3). We recorded a rapid and remarkable change in R-wave amplitude that was coincident with a decrease in arterial saturation and blood pressure.

Received for publication May 28, 2014 ; accepted July 1, 2014.

Address correspondence and reprint requests to Dr Yoshinobu Tomiyama, Division of Surgical Center, Tokushima University Hospital, 2-50-1 Kuramoto, Tokushima 770-8503, Japan and Fax : +81-88-633-9191.

CASE HISTORY

A seven-month-old female patient weighing 6.1

kg had previously undergone radical surgery for esophageal atresia at seven days old. Nissen's fundoplication has been scheduled for the postoperative esophageal hiatal hernia. Anesthesia was induced with thiamylal, nitrous oxide and sevoflurane. Muscle relaxation was achieved with rocuronium. Anesthesia was maintained with sevoflurane, remifentanil and rocuronium. No nitrous oxide was used for maintenance. The patient was ventilated using pressure-controlled ventilation. Peak airway pressure was controlled under 20 cm H₂O with the patient in the supine position. The three-electrode system was used, and lead II was continuously monitored. The procedure was performed under pneumoperitonium. Carbon dioxide (CO₂) was insufflated into the intra-abdominal cavity at a pressure of 8 cm H₂O. The surgery proceeded uneventfully for approximately 2 hours and 45 minutes. At that point, oxygen saturation suddenly decreased from 100% to 90% with decreases in tidal volume. Manual ventilation with

high inspiratory pressure and inspiratory pause in a moment recovered saturation. The minimum peak airway pressure to improve of oxygen saturation was changed to prevent lung injury. No remarkable change was observed at the site of surgery. Blood pressure gradually decreased and then increased, possibly as a result of changes in remifentanil concentration and pneumothorax. Indirect blood pressure (74/30 mmHg) was higher than direct blood pressure (59/34 mmHg). A change in R-wave amplitude was noted in ECG lead II (Figure 1 A, B). R-wave amplitude decreased from 0.8 mV to 0.3 mV in 5 seconds in ex-post assessment (Figure 1 A, B). P-wave amplitude decreased from 0.13 mV to 0.1 mV, and the change was smaller than the change in R-wave amplitude. Twenty minutes later, decreases in arterial saturation and blood pressure were observed again. R-wave amplitude decreased from 0.3 mV to 0.1 mV in 1 second (Figure 1 C, D). Inspiratory oxygen concentration was increased from 50%

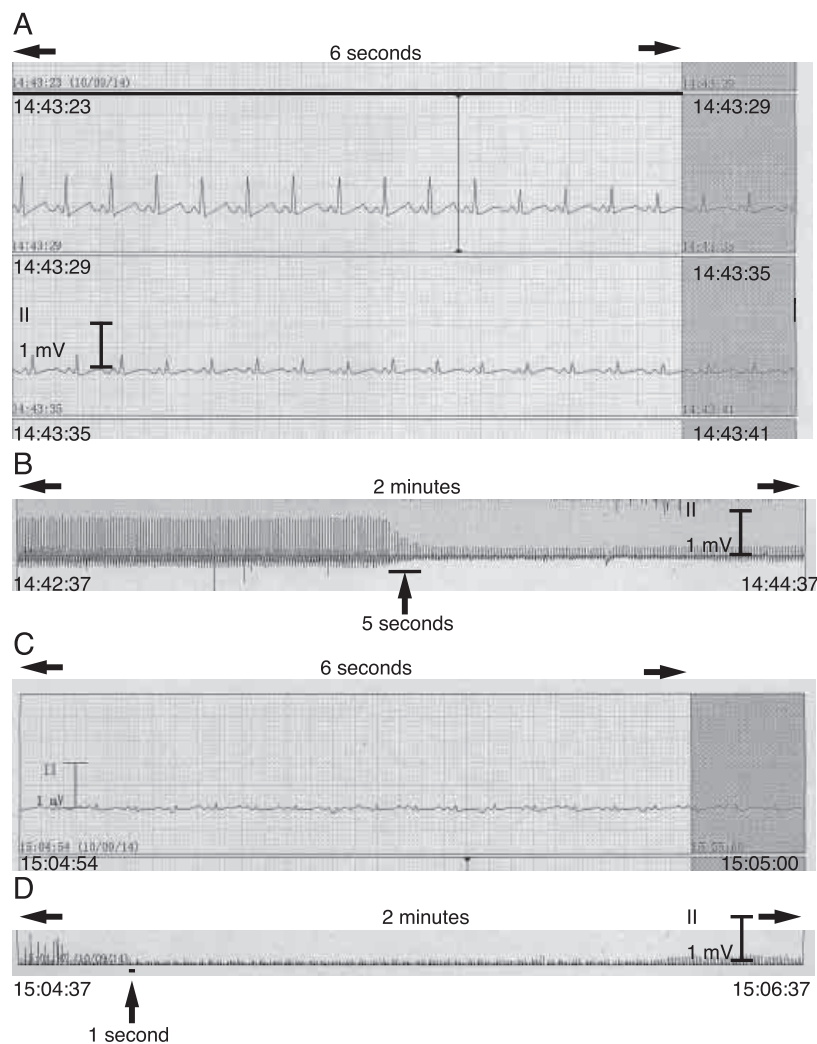


Figure 1. Changes in the ECG during pneumothorax. A : the first event ; 25 mm/sec trace, B : the first event ; 1.5 mm/sec trace, C : the second event ; 25 mm/sec trace, D : the second event ; 1.5 mm/sec trace.

to 100%. Manual ventilation with high inspiratory pressure and plateau pressure recovered oxygen saturation from 66% to 100%, direct blood pressure from 43/23 to 55/35 mmHg, and R-wave amplitude from 0.1 mV to 0.3 mV within 1-2 minutes (Figure 1 D). Then, the endoscopic surgery was changed to open surgery because of the difficulty of the dissection of the back of the stomach and possible pneumothorax. Hemodynamic stability was attained gradually. R-wave amplitude then recovered but did not reach the preoperative value at the end of the surgery. After the surgery was completed at 8 hours 7 minutes, a portable chest X-ray revealed a pneumothorax on the right side (Figure 2). The pneumothorax recovered after catheters were inserted into the affected area. Eventual postoperative ECG was almost same as the preoperative ECG.

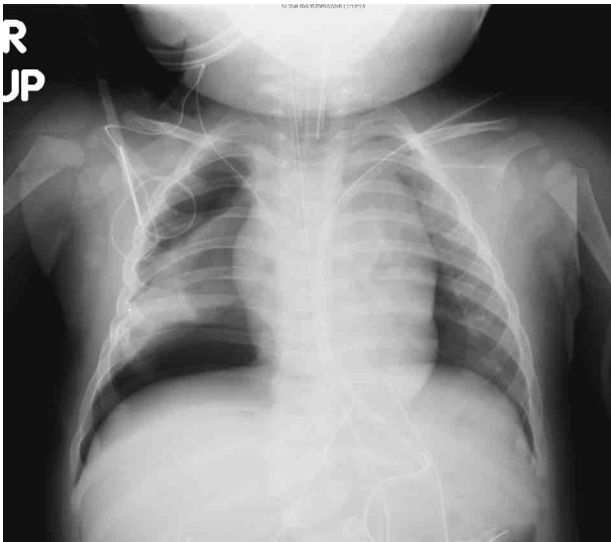

Figure 2. Chest radiograph showing a right pneumothorax.

DISCUSSION

Diagnosis of intra-operative pneumothorax is important (4, 5). The diagnosis is one of exclusion, as initial changes in vital signs such as cardiorespiratory decompensation and difficulty with ventilation are non-specific, and other causes of such changes are more common (5). One of the signs of intraoperative pneumothorax may be paradoxical ballooning of the hemidiaphragm on the affected side (3); however, no such change was observed at the site of surgery in this case. ECG manifestations of a tension pneumothorax have been well described (7). For a left tension pneumothorax, these manifestations include a rightward shift of the mean frontal

QRS axis, reduced precordial R-wave amplitude, decreased and/or alternating R-wave amplitude (electrical alternans), and precordial T-wave inversions (7). The combination of retrosternal air and rotation around the longitudinal axis of the heart may cause these ECG changes (3, 7). In a sheep model, R-wave amplitude was evaluated as a potential indicator of intraoperative pneumothorax (3); however, one report questioned its usefulness for rapid detection of pneumothorax in pediatric patients receiving controlled ventilation because artificial pneumothorax did not induce ECG changes (6). Our case clearly demonstrated decreases in R-wave amplitude induced by a pneumothorax confirmed by post-operative chest X-ray.

Diagnosis of the etiology of intra-operative pneumothorax is also important because treatment for pneumothorax should be specific to the etiology (8). Possible etiologies of intra-operative pneumothorax include passage of peritoneal CO₂ into the intrapleural space during laparoscopic surgery (3, 8) and rupture of the alveolus (5, 8). Positive-end expiratory pressure (PEEP) is effective for the influx of CO₂ gas (3, 8) but may aggravate pneumothorax caused by leakage of gas from the alveolus (5, 8). Thoracocentesis is mandatory in these cases.

Etiology of pneumothorax may alter the trend in R-wave amplitude. Previous case reports suggest that R-wave amplitude changes early and may be the only sign of an impending intra-operative pneumothorax in anaesthetized patients (4, 9). In this case, a decrease in the R-wave amplitude and oxygen saturation occurred almost simultaneously, possibly because of the rate of increase in gas volume in the intrapleural cavity. The ECG record suggests that the tension pneumothorax was completed in 5 seconds in the first event and 1 second in the second event in this case. The cardiopulmonary changes induced by pneumothorax during laparoscopic surgery may occur faster than changes associated with spontaneous pneumothorax, and rupture of an alveolus may induce a continuous decrease in the R-wave amplitude. Other causes of the low R-wave amplitude, such as pericardial effusion, may not induce ECG changes as rapid and remarkable as those observed in this study.

The addition of PEEP and changes in intraperitoneal insufflation pressures can overcome many of the pathophysiologic changes that occur secondary to CO₂ pneumothorax (3). The R-wave amplitude also suggests that manual ventilation with high inspiratory pressure recovered oxygenation in the first

event without a change in intrapleural CO₂ volume and that same procedure may decrease intrapleural CO₂ volume in the second event. R-wave amplitude did not recover to the preoperative value at the end of surgery, and a portable chest X-ray after surgery revealed a right pneumothorax. Generally, intraoperative CO₂ pneumothorax is well tolerated in the clinical setting and no invasive therapeutic measures are usually necessary (3). CO₂ is absorbed very quickly from the pleural cavity (2, 3). Singhal *et al.* reported tension pneumothorax in patients during trans-hiatal dissection for revisional surgery (2). In this case, adhesions after previous radical surgery for esophageal atresia might have caused the right-side tension pneumothorax by the check-valve mechanism (Figure 2), although previous reports describe left side pneumothorax (4, 9). Botz *et al.* reported that right pneumothoraxes may not reduce R-wave amplitude as dramatically as left pneumothoraxes (4). This discrepancy is possibly because of the massive CO₂ inflow or the position of the electrode in the three-electrode system. Thus, the trend in R-wave amplitude clearly reflected the massive and intermittent CO₂ inflow and retention of air in the pleural cavity, although the relationship between intrapleural gas volume and changes in ECG voltage is not always linear.

In conclusion, R-wave amplitude may provide a clue to the diagnosis of intraoperative tension pneumothorax. The rate of change in the R-wave amplitude, as confirmed by trends in R-wave amplitude, may have diagnostic significance.

CONFLICT OF INTEREST

None of the authors have any conflicts of interest to declare.

REFERENCE LIST

1. Sato Y, Miwa T, Hiroki K : Tension pneumothorax during laparoscopic Nissen fundoplication in a child. *Journal of clinical anesthesia* 19 : 162-3, 2007
2. Singhal T, Balakrishnan S, Hussain A, Grandy-Smith S, Paix A, El-Hasani S : Management of complications after laparoscopic Nissen's fundoplication : a surgeon's perspective. *Annals of surgical innovation and research* 3 : 1-9, 2009
3. Ludemann R, Krysztopik R, Jamieson GG, Watson DI : Pneumothorax during laparoscopy. *Surgical endoscopy* 17 : 1985-9, 2003
4. Botz G, Brock-Utne JG : Are electrocardiogram changes the first sign of impending peri-operative pneumothorax? *Anaesthesia* 47 : 1057-9, 1992
5. Bacon AK, Paix AD, Williamson JA, Webb RK, Chapman MJ : Crisis management during anaesthesia : pneumothorax. *Quality & safety in health care* 14 : e18, 2005
6. MacMahon M, McCormack J : Electrocardiographic changes associated with intra-operative pneumothorax in children. *Anaesthesia* 68 : 980-1, 2013
7. Strizik B, Forman R : New ECG changes associated with a tension pneumothorax : a case report. *Chest* 115 : 1742-4, 1999
8. Joris JL, Chiche JD, Lamy ML : Pneumothorax during laparoscopic fundoplication : diagnosis and treatment with positive end-expiratory pressure. *Anesthesia and analgesia* 81 : 993-1000, 1995
9. Ruo W, Rupani G : Left tension pneumothorax mimicking myocardial ischemia after percutaneous central venous cannulation. *Anesthesiology* 76 : 306-8, 1992