

CASE REPORT

Iliopsoas Abscess in an Infant

Hiroki Ishibashi^{1,2)}, Takehito Oshio²⁾, Tomoko Sogami²⁾, Akira Nii²⁾, Hiroki Mori¹⁾, Keigo Yada¹⁾, and Mitsuo Shimada¹⁾

¹⁾Department of Pediatric Surgery and Pediatric Endoscopic Surgery, Tokushima University Hospital, Tokushima, Japan, ²⁾Department of Pediatric Surgery, National Kagawa Children's Hospital, Zentsuji, Japan

Abstract : Iliopsoas abscess (IPA) is uncommon in childhood and very rare in the neonate and infant. We present a case of IPA after an umbilical granuloma in an infant. A baby girl with a birth weight of 2,970 g was born at thirty-seven weeks and two days gestation by Caesarean Section. On the fourteenth day after birth, her umbilicus was wet and developed the granulomatous formation. At two months of age, she presented with right leg and groin swelling with mild bluish discoloration and without fever. She had poor movement of her right leg and showed apparent discomfort. Her umbilicus was dry and there was no granulomatous material. Ultrasonography and computed tomography demonstrated an iliopsoas abscess in the right position. Therefore, an extraperitoneal surgical drainage was performed, aspirating yellowish pus. Culture of the purulent material revealed *Staphylococcus aureus*. Systemic antibiotic therapy was continued for ten days. After three days of drainage, full-range motion of the right leg was gained, and then after eleven days, CT findings confirmed the disappearance of the iliopsoas abscess. IPA is extremely rare and it is difficult to diagnose. However, it should be included in the differential diagnosis of an infant with poor leg movement and swelling of the groin to the femur. *J. Med. Invest.* 61 : 213-216, February, 2014

Keywords : iliopsoas abscess, infant, surgical drainage

INTRODUCTION

Iliopsoas abscess (IPA) is uncommon in childhood and very rare in the neonate and infant. The triad presentation of IPA in the neonate is leg or groin swelling ; limitation of leg motion ; and pain. However, the diagnosis of this disease is sometimes very difficult in childhood. Ultrasonography (US) and computed tomography (CT) are useful in the diagnosis of this condition. The etiology of many

cases of this disease is idiopathic. We report here on a case of IPA after an umbilical granuloma in an infant.

CASE

A baby girl with a birth weight of 2,970 g was born at thirty-seven weeks and two days gestation by Caesarean Section. She was showing normal growth. On the fourteenth day after birth, her umbilicus was wet and developed a granulomatous formation. At two months of age, she presented with right leg and groin swelling with mild bluish discoloration and without fever. She was admitted to our hospital with poor movement of her right leg

Received for publication December 3, 2013 ; accepted January 24, 2014.

Address correspondence and reprint requests to Hiroki Ishibashi, M.D., Department of Pediatric Surgery and Pediatric Endoscopic Surgery, Tokushima University Hospital, Kuramotocho, Tokushima, 770-8503, Japan and Fax : +81-88-631-9698.

and showing apparent discomfort (Figure 1). Her umbilicus was dry and there was no granulomatous material.

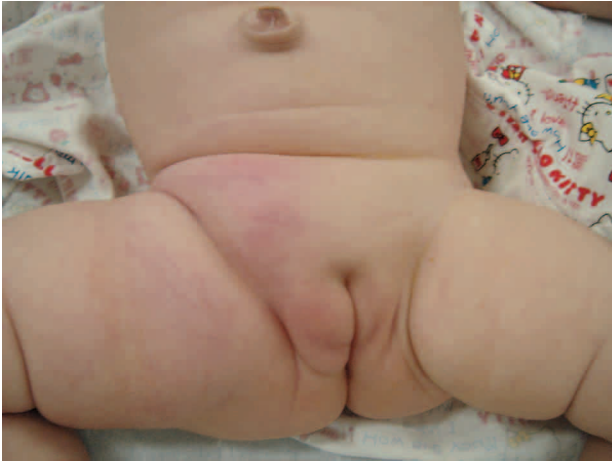

Figure 1 : The leg and groin appearance
The leg and groin appearance reveals swelling with mild bluish discoloration.

Laboratory examination revealed a peripheral white blood cell count (WBC) of $13,990 /\text{mm}^3$ and C-reactive protein concentration (CRP) of 6.72 mg/dl . US, CT and magnetic resonance imaging (MRI) demonstrated a retroperitoneal inflammatory mass extending to the right femoral region (Figure 2). Even though we began the treatment with systemic intravenous infusion of antibiotics (Flomoxef and Amikacin), the WBC was $19,420 /\text{mm}^3$ and the CRP was 10.11 mg/dl on third day of hospitalization. We confirmed the abscess formation in the right iliopsoas muscle by CT examination with contrast medium (Figure 3). Consequently an extraperitoneal surgical drainage was performed, aspirating yellowish pus and a penrose drain was inserted into the abscess cavity through an inguinal incision. Culture of the purulent material revealed methicillin-sensitive *Staphylococcus aureus* (MSSA). Systemic antibiotic therapy was continued for ten days. After three days of drainage, there was full-range motion of the right leg, and after eleven days the WBC and CRP were normal and the penrose drain was removed. At that time the CT findings showed the disappearance of the iliopsoas abscess. After five years, the child was symptom-free.

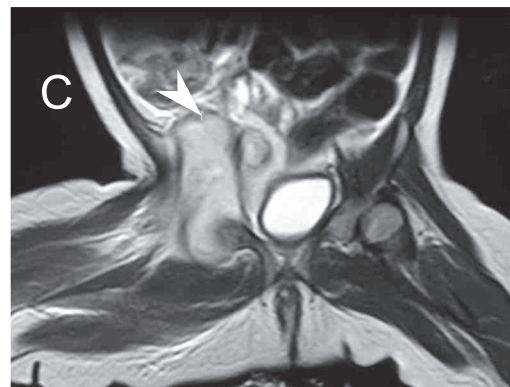
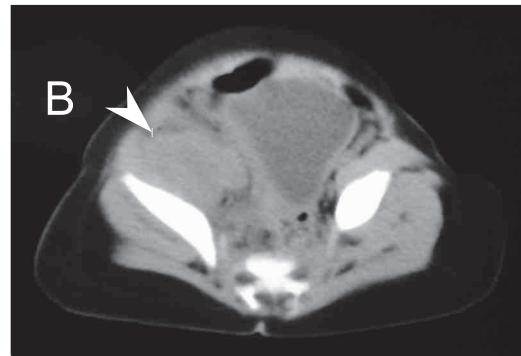
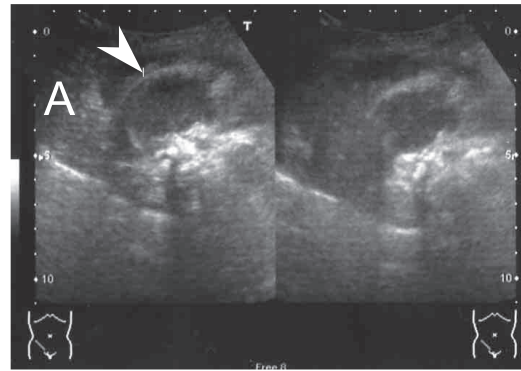


Figure 2 : (A)US finding, (B)CT finding, (C)MRI T2-weighted finding.

US, CT and MRI shows a retroperitoneal mass extending to the right femoral region (arrowheads).

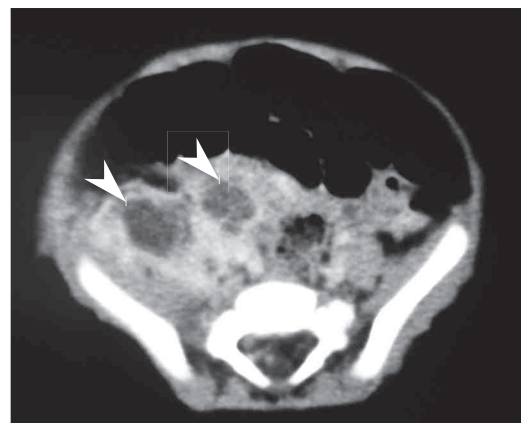


Figure 3 : Enhanced CT finding

Enhanced CT shows the abscess formation in the right iliopsoas muscle (arrowheads).

DISCUSSION

IPA can be classified as idiopathic (primary) or secondary. Primary IPA occurs due to the haematogenous or lymphatic spread of a causative organism from a distant site. Secondary IPA occurs as a result of the direct extension of inflammatory processes from adjacent structures, such as intestinal, renal, or bone disease including appendicitis, inflammatory bowel disease, pyelonephritis, osteomyelitis, tuberculosis, and others (1). In our case, the umbilical granuloma have already existed in the neonatal period. It is possible to assume that pathogenic bacteria invaded the iliopsoas muscle via the cord of umbilical artery from the umbilicus.

The etiology of iliopsoas abscess was linked to a geographical area with over 90% of cases in Asia and Africa being primary in origin while in Europe only 18.7% of reported cases were primary (2). Primary IPA makes up approximately 30% of all cases seen. Although the age distribution has not been established for IPA, in a review of IPA in children, the largest clustering of patients was in the ten to seventeen year age group, with a range of eleven days to seventeen years (3). IPA is extremely uncommon in neonates. Only seventeen cases of IPA in neonates have been reported in the English literature (4-18). The onset time has ranged from day eleven to day thirty-one after birth. In most cases, the cause of neonatal IPA has not been detected. Intramuscular hemorrhage due to the trauma of delivery has been proposed as one possible etiology of IPA (14). Among the cases we reviewed, only five showed precedent infection, namely bacteremia (11), umbilical venous catheter infection (8), pustular lesion (17), urethral infection (10) and arthritis of the hip (18). There has been no case reported where the spread of a causative organism has been from umbilical infection as in our case. The causative organisms of IPA isolated in all neonates were described. *Staphylococcus aureus* was the most frequently isolated organism (thirteen in seventeen neonatal cases). *Streptococcus pneumoniae*, *Klebsiella pneumoniae* and methicillin-resistant *Staphylococcus aureus* (MRSA) were also reported as pathogens in four neonates.

The major presenting symptoms were leg or groin swelling ; limitation of leg motion ; pain ; and fever. In the neonate and infant, it is difficult to identify clinical symptoms during the early stage. Diagnosis can usually be made, or at least be suspected, by US, but CT provides more precise information

about the abscess cavity and its extension. There are some reports that MRI is useful for diagnosis, but infants sometimes need heavy sedation while MRI is being performed.

Appropriate antibiotic administration with open or percutaneous surgical drainage is the recommended method of the treatment. There have been numerous case reports of successful ultrasonography-guided percutaneous drainage of IPA (15). Antibiotics alone may be successful in treating small abscesses. In two cases, the abscess was diminished with antibiotic therapy alone, but most of the neonatal reviews showed that antibiotic therapy alone was often insufficient and additional abscess drainage was required. In most cases, antibiotic therapy with surgical drainage reduced the abscess.

In conclusion, an awareness of this exceptional infection in infants presenting with poor leg movement and swelling of the groin to the femur along with the timely use of imaging studies will help in the prompt diagnosis and treatment of IPA, preventing complications caused by a delay.

CONFLICT OF INTEREST

The author and co-authors disclose that there are no conflicts of interest associated with the present study.

REFERENCES

1. Shields D, Robinson P, Crowley TP : Iliopsoas abscess--a review and update on the literature. *Int J Surg* 10 : 466-9, 2012
2. Ricci MA, Rose FB, Meyer KK : Pyogenic psoas abscess : worldwide variations in etiology. *World J Surg* 10 : 834-43, 1986
3. Firor HV : Acute psoas abscess in children. *Clin Pediatr* 11 : 228-231, 1972
4. Sedaghatian MR, Barkhordar J, Gerami S : Retroperitoneal abscess presenting as an abdominal mass in neonate. *J Pediatr Surg* 13 : 544-5, 1978
5. Zych GA, McCollough NC : Acute psoas abscess in a newborn infant. *J Pediatr Orthop* 5 : 89-91, 1985
6. Schut JM, Meradji M, Oranje AP, Bergmeijer JH, Schuller JL : Double-sided psoas abscess in a young infant : sonographic and radiographic findings. *Pediatr Radiol* 18 : 176-7, 1988

7. Singer J : Neonatal psoas pyomyositis simulating pyarthrosis of the hip. *Pediatr Emerg Care* 9 : 87-9, 1993
8. Edgar EA, Schlesinger AE, Royster RM, Deeney VFX : Ilio-psoas abscess in neonates. *Pediatr Radiol* 23 : 51-2, 1993
9. Lucas AP, Carneiro R, Viegas M, Pascoal J, Sousa-Santos A : Eur. Ilio-psoas abscess in the neonate. *J Pediatr Surg* 7 : 186-7, 1997
10. Natsume H, Nakanishi T, Nakagawa Y, Igarashi Y : A case of an iliopsoas abscess in a neonate. *Acta Paediatr Jpn* 39 : 459-61, 1997
11. Andreou A, Karasavvidou A, Papadopoulou F, Koukoulidis A : Ilio-psoas abscess in a neonate. *Am J Perinatol* 14 : 519-21, 1997
12. Prassopoulos PK, Giannakopoulou CA, Apostolaki EG, Charoulakis NZ, Gourtsoyiannis NC : Primary ilio-psoas abscess extending to the thigh in a neonate : US, CT and MR findings. *Pediatr Radiol* 28 : 605-7, 1998
13. Dib M, Bedu A, Garel C, Mazda K, Philippe-Chomette P, Rajguru M, Hassan M, Aujard Y : Ilio-psoas abscess in neonates : treatment by ultrasound-guided percutaneous drainage. *Pediatr Radiol* 30 : 677-80, 2000
14. Yano T, Takamatsu H, Noguchi H, Tahara H, Kaji T, Saruwatari Y, Sakai I : Iliopsoas abscess in the neonate. *J Pediatr Surg* 39 : E23, 2004
15. Okada Y, Yamataka A, Ogasawara Y, Matsubara K, Watanabe T, Lane GJ, Miyano T : Ilio-psoas abscess caused by methicillin-resistant *Staphylococcus aureus* (MRSA) : a rare but potentially dangerous. *Pediatr Surg Int* 20 : 73-4, 2004
16. Vastyan AM, MacKinnon EA : Primary psoas abscess in a neonate. *Am. J Perinatol* 23 : 253-4, 2006
17. Okan F, İnce Z, Çoban A, Can G : Neonatal psoas abscess simulating septic arthritis of the hip : a case report and review of the literature. *Turk. J Pediatr* 51 : 389-91, 2009
18. Horiuchi A, Kameoka K, Kuwabara J, Watanabe Y, Kawakami S, Tauchi H, Ishii E : Neonatal iliopsoas abscess. *Pediatr Int* 54 : 712-4, 2012