

CASE REPORT

Delayed-onset severe heparin-induced thrombocytopenia after total arch replacement under cardiopulmonary bypass

Taisuke Nakayama MD¹, Hajime Kinoshita MD¹, Mikio Sugano MD¹, Hirotsugu Kurobe MD, PhD¹, Tamotsu Kanbara MD¹, Eiki Fujimoto MD¹, Takashi Kitaichi MD PhD¹, Hiroshi Fujita MD², Hitoshi Sogabe MD, PhD², and Tetsuya Kitagawa MD, PhD¹

¹Department of Cardiovascular Surgery, Institute for Health Biosciences, the University of Tokushima Graduate School, Tokushima, Japan, ²Imabari Daiichi Hospital, Ehime, Japan

Abstract : An extremely rare case with delayed-onset heparin-induced thrombocytopenia (HIT) is described. A 46-year-old man underwent arch replacement for aortic dissection under cardiopulmonary bypass and initial exposure of unfractionated heparin. In post operative 7 days, persistent atrial fibrillation was occurred, so a continuous infusion of heparin (10000 IU/day) and Vitamine K antagonist (Warfarin) taking was started for preventing thrombosis. By 32 days after the operation, his platelet count had fallen ($3 \times 10^3 / \mu\text{L}$) and oral hematoma and ecchymoma of bilateral lower legs were occurred. The value of HIT antibodies and the IgG antibody was 2.485 and 1.586 on 32-postoperative day, respectively. Heparin was immediately discontinued, and argatroban administrated. Platelet exceeded above $100 \times 10^3 / \mu\text{L}$ on 12 days of the therapy. To our knowledge, few cases of delayed-onset severe HIT associated with CPB surgery have been reported in Japan. *J. Med. Invest.* 60 : 154-158, February, 2013

Keywords : heparin-induced thrombocytopenia, aortic surgery, unfractionated heparin, heparin-platelet factor 4 complex, argatroban

INTRODUCTION

A frequency of 1% to 3% in patients exposed to unfractionated heparin (UFH) for more than four days may develop a heparin-platelet factor 4 antibodies mediated thrombocytopenia (1), known as heparin-induced thrombocytopenia (HIT) (2). Usual HIT exhibits platelet count typically $> 20 \times 10^3 / \mu\text{L}$,

and spontaneous bleeding is unusual in contrast to idiopathic thrombocytopenic purpura with platelet count $< 10 \times 10^3 / \mu\text{L}$ and clinical bleeding (3). The major clinical problem associated with HIT is thrombosis, known as the heparin paradox. Delayed-onset HIT was quite rare and seemed to account for about 3 to 5% of all HIT cases (4). HIT with thrombotic complications after cardiac surgery under cardiopulmonary bypass (CPB) seemed to be associated with high mortality (5). In this report, an extremely rare case with delayed-onset severe HIT with bleeding symptoms, without thrombosis, after total arch replacement is described with ultimate recovery.

Received for publication October 29, 2012 ; accepted December 18, 2012.

Address correspondence and reprint requests to Taisuke Nakayama MD, 3-18-15 Kuramoto town, Tokushima city, Tokushima, Japan 770-8503 and Fax : +81-88-633-7408.

CASE

46-year-old man with chest pain was referred to our hospital for acute type A aortic dissection. He underwent emergent total arch replacement under CPB. 110×10^3 IU of UFH was given intravenously during CPB, which was initial exposure of heparin to him. When symptomatic atrial fibrillation (Af) was developed on postoperative day (POD) 7, a continuous intravenous administration of UFH (10×10^3 IU/day) was added and warfarin was started. Sinus rhythm resumed by cardioversion on POD 9. For preventing cardiogenic thromboembolism due to recurrent Af, UFH administration had been continued for the warfarin control achievement of PT-INR of 1.5-2.5. Finally, total UFH administration was kept for POD16.

Platelet count decreased to $56 \times 10^3 / \mu\text{L}$ on POD 3 after cardiac surgery under CPB and increased gradually as usual to $420 \times 10^3 / \mu\text{L}$ on POD 17. But it promptly decreased again to $3 \times 10^3 / \mu\text{L}$ on POD 32, 16 days after re-exposure of UFH (Fig. 1). Spontaneous oral submucosal hematoma and ecchymoma of bilateral lower legs requiring special attention were found at the same time. But thrombosis such as deep vein thrombosis and pulmonary

embolism, venous limb gangrene, cerebral sinus thrombosis, stroke and acute myocardial infarction, was not found clinically and by contrast CT and echography.

As he had not taken medicines that caused thrombocytopenia and was not combined with severe infection and/or disseminated intravascular coagulation (DIC) associated disease, the presence of HIT syndrome was suspected. Warfarin was immediately discontinued, and argatroban, direct thrombin inhibitor, was immediately administrated at a dose of 0.5-2.5 $\mu\text{g}/\text{kg}/\text{min}$ because of slight hepatic impairment. Target APTT of its treatment was 1.5-2.0 times normal APTT score. Serologic tests confirming antibodies against heparin-platelet factor 4 complexes, commonly known as HIT antibody, were performed. The optical density (OD) values of HIT antibody were 2.485, 2.314 and 2.116 on POD 32, 33 and 34, respectively (Table 1). The results greater than 2.00 OD value were assessed as a very strongly positive immunoassay result, which showed the probability of detecting platelet-activating antibodies was approximately 90%. In particular, clinically important heparin- platelet factor 4-IgG antibodies detected by peculiar enzyme immunoassay were 1.586, 1.640 and 1.479 OD values on POD 32,

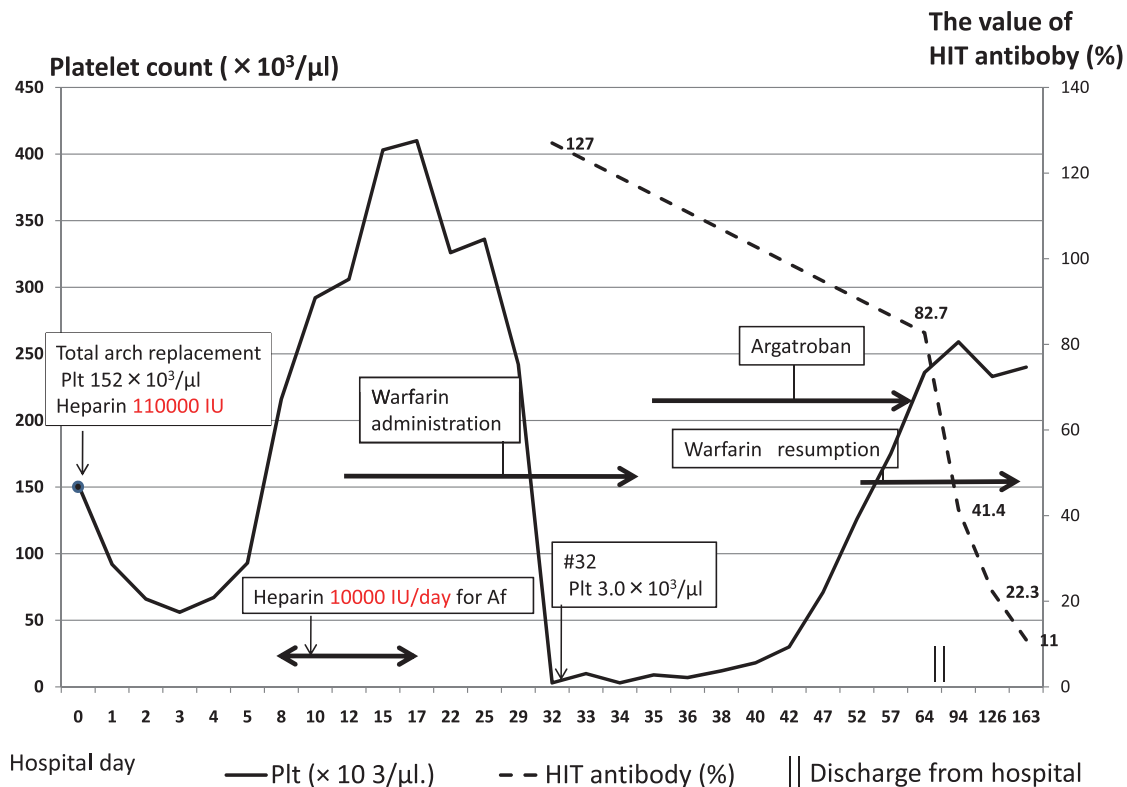


Fig 1. The course of platelet count, the level of heparin-induced thrombocytopenia (HIT) antibody and anticoagulant therapies after total arch replacement. (Plt ; platelet, Af ; Atrial fibrillation)

Table 1. (the upper row) Results of serologic tests confirming antibodies against heparin-platelet factor 4 complexes, the IgG antibodies detected by peculiar enzyme immunoassay on postoperative day (POD) 0, 32, 33, and 34. OD=optical density (the lower row) The hemostatic data in POD 32.

sampling day	The level of HIT antibody (%)	OD value		IgG of HIT antibody (OD value)	Plt count ($\times 10^3 / \mu\text{l}$)
Cut off	26.5	0.5		0.4	
POD #0	5.2	0.112		0.083	152
POD #32	127.0	2.485		1.586	3.0
POD #33	118.3	2.314		1.640	4.0
POD #34	108.2	2.116		1.479	3.5

	POD #32 value of this case	normal value
D-dimer	22.5 $\mu\text{g}/\text{dl}$	0.9 $\mu\text{g}/\text{dl}$ >
fibrinogen degradation products(FDP)	24 $\mu\text{g}/\text{dl}$	10 $\mu\text{g}/\text{dl}$ >
thrombin-antithrombin complex (TAT)	10.4 ng/dl	1.8 ng/dl >

33 and 34, respectively. The values of HIT antibodies and the IgG antibody of the preoperative stock blood serum were negative. Furthermore, the value of D-dimer, fibrinogen degradation products (FDP) and thrombin-antithrombin complex (TAT) increased on POD 32, respectively. It resembled the results of DIC. These results did not contradict the HIT theory.

Platelet count exceeded above $100 \times 10^3 / \mu\text{L}$ on 12 days of the therapy, and warfarin was reintroduced for a PT-INR of 1.5-2.5 and argatroban was discontinued. Hemorrhagic events had not been exacerbated, and no thrombosis had been appeared. Warfarin was reduced and discontinued with HIT antibody under the cut off level on POD 126.

DISCUSSION

Critical assessment of HIT suggests a frequency of 0.2 to 5.0 percentage in patients exposed to heparin for more than four days. Particularly, the incidence of HIT in patients who underwent cardiac surgery under CPB has been estimated to be 1.9% (6). Without prompt diagnosis and proper treatment, patients with HIT complicated with venous and/or arterial thrombosis often result in dismal outcomes, with limb amputation in approximately 10%, and death in about 20%-30% (7).

Typical-onset HIT usually occurs at 5-14 days after initial exposure to a prophylactic or therapeutic dose of heparin (4). Furthermore, the peak onset is 5 to 8 days after starting heparin therapy (8). Meanwhile, delayed-onset HIT begins with objectively proven venous and/or arterial thrombosis,

with prompt thrombocytopenia developing after re-exposure of heparin following withdrawn of previous heparin. It seems to develop after re-exposure at a median time of 14 days (range : 9 to 40 days) (9). In this case, the thrombocytopenia of the nadir platelet count of $3 \times 10^3 / \mu\text{L}$ occurred promptly at 32 days from the initial exposure to heparin for CPB, and 16 days from the re-exposure to heparin for Af.

HIT is usually caused by IgG antibodies that are reactive against complexes of platelet factor 4 and heparin. The key factor of delayed-onset HIT seems to be antibodies that activate platelets in both a heparin-dependent and -independent manner, mimicking an autoimmune disease (10). Theodore *et al.* reported that patients with delayed-onset HIT have high-titer platelet-activating antibodies that exhibit increased heparin-dependent and independent platelet activation compared with typical-onset type (9). It has been established that heparin-dependent antibodies recognize one or more sites on platelet factor 4 (11, 12) that are conformationally modified by pharmacologic heparin or endogenous glycosaminoglycans, such as endothelial-bound heparin sulfate (13, 14). Therefore, delayed-onset HIT could be caused by high titers of heparin-dependent antibodies that recognize platelet factor 4 bound to the platelet surface in the absence of residual pharmacologic heparin, platelet factor 4 bound to endothelial glycosaminoglycans, or both. We believe it may be relevant to delayed-onset HIT etiology.

The first-step in establishing a diagnosis of HIT is suspecting the presence of this syndrome. However, one major difficulty in establishing the diagnosis of HIT was that medical and surgical patients

might have multiple causes for thrombocytopenia other than the use of heparin, therefore, a pretest clinical score (called “the 4 T’s”) have been developed and prospectively validated to be useful (15). The “4 T’s” score of this patient was 2 points because of platelet nadir $< 10 \times 10^3 / \mu\text{L}$ and no thrombosis, and was interpreted as low probability for HIT. Generally, patients with a low pretest probability of HIT do not have clinically significant HIT antibodies. Although it was difficult to determine whether or not HIT was present in this particular case, the presence of a secondary fall in the platelet count below 50 percent following arch replacement under CPB and absence of possible drug-induced thrombocytopenia appeared to be highly predictive of HIT. Moreover, severe thrombocytopenia unusual in HIT was associated with spontaneous bleeding, reported in past literature (16). He showed a very strongly positive HIT antibody immunoassay result, which provided a definitive diagnosis of HIT.

Treatment of HIT consists of immediate cessation of all exposure to heparin and alternative anticoagulants that inhibit directly either coagulation factor Xa (fondaparinux) or thrombin (argatroban) in spite of different onset of HIT (9). He underwent an alternative anticoagulant therapy with argatroban during the time remaining risk of thrombosis of other sequelae. Argatroban was administered from low dose because of his hepatic impairment, and was continued until the thrombocytopenia has resolved (17).

CONCLUSION

In conclusion, if a patient manifests unexplained severe thrombocytopenia with spontaneous bleeding symptoms and heparin exposure within past 40 days, delayed-onset HIT should be kept in mind. Heparin should be discontinued immediately and alternative anticoagulant agents to heparin be started for preventing thrombosis of other sequelae, and the value of antibodies against the heparin-platelet factor 4 complex and the specific IgG antibody be measured simultaneously.

DECLARATION OF INTERESTS

The authors report no conflicts of interest. The authors alone are responsible for the content and writing of the paper.

REFERENCES

1. Murphy GS, Marymont JH : Alternative Anticoagulation Management Strategies for the Patient With Heparin-Induced Thrombocytopenia Undergoing Cardiac Surgery. *J Cardiothorac Vasc Anesth* 21(1) : 113-126, 2007
2. Menajovsky BL : Heparin-induced thrombocytopenia : clinical manifestations and management strategies. *Am J Med* 118 : 21-30, 2005
3. Greinacher A : Heparin-induced thrombocytopenia. *J Thromb Haemost* 7(1) : 9-12, 2009
4. Arepally GM, Ortel TL : Clinical practice : heparin-induced thrombocytopenia. *N Engl J Med* 355 : 809-817, 2006
5. Wan C, Warner M, DeVarenes B, Ergina P, Cecere R, Lachapelle K : Clinical presentation, temporal relationship, and outcome in thirty-three patients with type 2 heparin-induced thrombocytopenia after cardiectomy. *Ann Thorac Surg* 82 : 21-27, 2006
6. Follis F, Schmidt CA : Cardiopulmonary bypass in patients with heparin-induced thrombocytopenia and thrombosis. *Ann Thorac Surg* 70 : 2173-2181, 2000
7. Warkentin TE, Kelton JG : A 14-year study of heparin-induced thrombocytopenia. *Am J Med* 101 : 502-507, 1996
8. Warkentin TE : Clinical picture of heparin-induced thrombocytopenia. In : Warkentin TE, Greinacher A, eds. *Heparin-Induced Thrombocytopenia*. 2nd ed. Marcel Dekker Inc, New York, 2001, pp.43-81
9. Warkentin TE, Kelton JG : Delayed-Onset Heparin-Induced Thrombocytopenia and Thrombosis *Ann Intern Med*. 135 : 502-506, 2001
10. Warkentin TE, Makris M, Jay RM, Kelton JG : A spontaneous prothrombotic disorder resembling heparin-induced thrombocytopenia. *Am J Med* 121 : 632-636, 2008
11. Horsewood P, Warkentin TE, Hayward CP, Kelton JG : The epitope specificity of heparin-induced thrombocytopenia. *Br J Haematol* 95 : 161-167, 1996
12. Ziporen L, Li ZQ, Park KS, Sabnekar P, Liu WY, Arepally G, Shoenfeld Y, Kieber-Emmons T, Cines DB, Poncz M : Defining an antigenic epitope on platelet factor 4 associated with heparin-induced thrombocytopenia. *Blood* 92 : 3250-3259, 1998
13. Visentin GP, Ford SE, Scott JP, Aster RH : Antibodies from patients with heparin-induced

thrombocytopenia/thrombosis are specific for platelet factor 4 complexed with heparin or bound to endothelial cells. *J Clin Invest* 93 : 81-88, 1994

14. Greinacher A, Pötzsch B, Amiral J, Dummel V, Eichner A, Mueller-Eckhardt C : Heparin-associated thrombocytopenia : isolation of the antibody and characterization of a multimolecular PF4-heparin complex as the major antigen. *Thromb Haemost* 71 : 247-251, 1994
15. Lo GK, Juhl D, Warkentin TE, Sigouin CS, Eichler P, Greinacher A : Evaluation of pretest clinical score (4 T's) for the diagnosis of heparin-induced thrombocytopenia in two clinical settings. *J Thromb Haemost* 4 : 759-765, 2006
16. Theodore EW, Andreas G : Heparin-Induced Thrombocytopenia and Cardiac Surgery. *Ann Thorac Surg* 76 : 2121-2131, 2003
17. Lewis BE, Wallis DE, Leya F, Hursting MJ, Kelton JG : Argatroban anticoagulation in patients with heparin-induced thrombocytopenia. *Arch Intern Med* 163 : 1849-1856, 2003