

ORIGINAL

Visual and semi-quantitative assessment of brain tumors using ^{201}Tl -SPECT

Ayumi Nose¹, Hideki Otsuka^{1,2}, Hayato Nose¹, Yoichi Otomi¹, Kaori Terazawa¹, and Masafumi Harada¹

¹Department of Radiology, Tokushima University Hospital, Tokushima, Japan, ²Department of Medical Imaging, the University of Tokushima Graduate School, Tokushima, Japan

Abstract : Objective : To evaluate the usefulness of ^{201}Tl -SPECT in differentiating benign from malignant brain tumors. **Methods and Materials :** Eighty-eight patients (44 males and 44 females) with 58 high-grade (WHO grade III-IV) and 30 low-grade (WHO grade I-II) tumors were evaluated with ^{201}Tl -SPECT. (1) Visual assessment was performed by board-certificated radiologists using ^{201}Tl -SPECT. Tumors were classified in two groups (Tl-positive and Tl-negative) and scored using the five grade evaluation system. Receiver operating characteristic (ROC) analysis was performed in the Tl-positive group. (2) Semi-quantitative assessment involved measurement of early and delayed ^{201}Tl uptake, and the retention index (RI) was applied as follows : $\text{RI} = \text{delayed uptake ratio} / \text{early uptake ratio}$. Three combinations of RI using mean and maximum values of the region of interest were calculated. **Results :** (1) Seventy-four Tl-positive and 14 Tl-negative tumors. The area under the ROC curve (AUC) estimated by three radiologists exceeded a value of 0.7. The value was greater when estimated by the more experienced radiologist. (2) In all RIs, the difference of RI between high-grade tumors and low-grade tumors was statistically significant. **Conclusion :** A visual and semi-quantitative assessment using ^{201}Tl -SPECT was found to be useful for differentiating benign from malignant brain tumors. *J. Med. Invest.* 60 : 121-126, February, 2013

Keywords : ^{201}Tl -SPECT, brain tumors, retention index, differential diagnosis

INTRODUCTION

Differential diagnosis of brain tumors mainly involves the use of computed tomography (CT) and magnetic resonance imaging (MRI). These modalities provide morphological information, and it is sometimes difficult to predict the pathological grade based on morphological information alone. Single photon emission computed tomography (SPECT) can provide important functional/metabolic

information, such as details regarding tumor activity, cell proliferation and blood flow. Thallium-201 (^{201}Tl) SPECT has been widely used in tumor imaging in the brain, soft tissue (1), thyroid gland, lung and bone. With brain tumors, ^{201}Tl has been used for tumor localization (2, 3), the grading of tumor malignancy and differentiation of tumor recurrence from radiation necrosis (4-6). Semi-quantitative assessment using the retention index (RI) has been reported for the grading of brain tumor malignancy (7, 8).

The aim of our study was to evaluate the usefulness of visual and semi-quantitative assessment using ^{201}Tl -SPECT to differentiate benign from malignant brain tumors.

Received for publication October 31, 2012 ; accepted January 23, 2013.

Address correspondence and reprint requests to Hideki Otsuka, MD, PhD, Department of Medical Imaging, the University of Tokushima Graduate School, Kuramoto-cho 3-18-15, Tokushima city, Tokushima, Japan 770-8503 and Fax : +81-88-633-7174.

MATERIALS AND METHODS

This retrospective study was approved by the institutional review board of Tokushima University Hospital.

Patients

Patient data are shown in Table 1. ²⁰¹Tl-SPECT studies were performed on 88 patients with brain tumors (44 males and 44 females, aged between 3 and 80 years old, with a mean age of 55 years) between September 2005 and February 2011. Fifty-eight of the 88 lesions were high-grade (WHO grade III-IV) tumors and 30 were low-grade (WHO grade I-II) tumors. Eighty-five tumors were histologically confirmed in accordance with WHO directives (9) and three lesions were clinically diagnosed as meningiomas. The most common high-grade tumor was a glioblastoma, while most low-grade tumors were meningiomas.

²⁰¹Tl-SPECT

SPECT images were obtained during the early (15 min) and delayed (3 h) phases after the intravenous injection of 60-111 MBq of ²⁰¹Tl-Cl by means of a two-head gamma camera (E.CAM, Toshiba Medical Systems, Japan). The system was equipped with fanbeam collimators. We used a 15 and 20% symmetrical window at 166 and 70 keV, respectively. A 64 x 64 matrix with a Butterworth filter was used for correction, and images were reconstructed in the transverse plane using a Ramp filter.

Visual assessment

First, the tumors were classified in two groups

(Tl-positive and Tl-negative) by two board-certificated radiologists. Second, three board-certificated radiologists (two double-board certified [diagnostic radiology and nuclear medicine]) scored the SPECT images in the Tl-positive group using a five grade evaluation system (1 : benign ; 2 : possibly benign ; 3 : unknown whether benign or malignant, 4 ; possibly malignant, and 5 ; malignant). The radiologists did not use MRI and CT images and evaluated only the early and delayed phase of ²⁰¹Tl-SPECT. A receiver operating characteristic (ROC) analysis was performed.

The radiologists noticed the following facts regarding ²⁰¹Tl-SPECT of brain tumors : there was high Tl-uptake in malignant tumors during both the early and delayed phase, and wash-out in the delayed phase was low ; Tl-uptake was low to moderate in benign tumors other than meningioma ; and meningioma can show high early Tl-uptake and wash-out in the delayed phase. The radiologists were blinded to the final diagnosis (pathological and clinical) and the characteristics of the patient population including the number of lesions in each group.

Semi-quantitative assessment

Mean and maximum count of the region of interest (ROI) in both the early and delayed image were measured (Figure 1). ROIs of the tumors were manually placed over the area showing the greatest activity on MRI for reference. ROIs of normal brain parenchyma were placed over the contralateral regions. The ROIs of normal brain parenchyma were set in the anterior-posterior region in the same slice of the midline lesions. The

Table 1 Patient data.

| Low-grade tumors (WHO grade I-II) | | High-grade tumors (WHO grade III-IV) | |
|-----------------------------------------------------------|-------------------------------------------------------------|-----------------------------------------|----------|
| | 30 cases (3 cases was diagnosed meningiomas clinically.) | | 58 cases |
| Meningioma (angiomatous, meningothelial) | 11 | Glioblastoma | 39 |
| Astrocytoma (Diffuse, Pilocytic, Subependymal giant cell) | 9 | Anaplastic astrocytoma | 15 |
| Oligodendroglioma | 3 | Medulloblastoma | 1 |
| Hemangioblastom | 2 | Anaplastic oligodendroglioma | 1 |
| Ependymoma | 1 | Anaplastic oligoastrocytoma | 1 |
| Ganglioglioma | 1 | High grade astroblastoma | 1 |
| Central neurocytoma | 1 | | |
| Glioma (grade II) | 1 | | |
| Schwannoma | 1 | | |

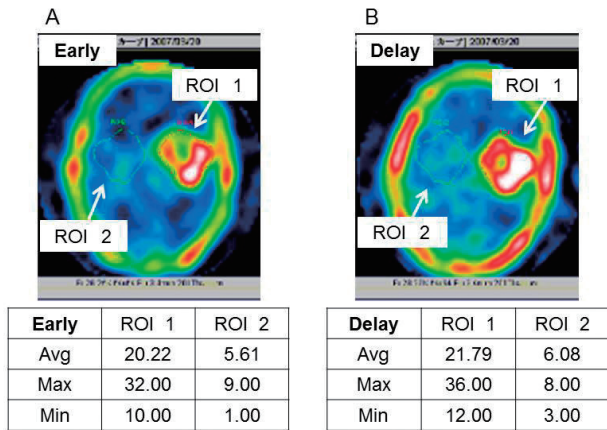


Figure 1. Calculation of TI retention index. A 71-year-old female with glioblastoma. Early (A) and delayed (B) ²⁰¹Tl-SPECT shows high uptake in the tumor. Regions of interest (ROIs) of the tumors were manually placed over the area showing the greatest activity on MRI for reference. ROIs of normal brain parenchyma were placed over the contralateral regions. The early and delayed ²⁰¹Tl uptake ratios were calculated, and the RI was calculated as : RI=delayed uptake ratio (DR)/early uptake ratio (ER). RI is usually calculated by using the mean value of the lesions (L) and background (BG) in the ROI. ER=20.22/5.61=3.60, DR=21.79/6.08=3.58, RI=3.58/3.60=0.99.

early and delayed ²⁰¹Tl uptake ratios were calculated, and the RI was applied as : RI=delayed uptake ratio (DR)/early uptake ratio (ER). RI is usually calculated by using the mean value of the lesions (L) and background (BG) in the ROI. This method indicates that RI=Lmean/BGmean. In the present study three combinations of RI were calculated using the mean and maximum values of the ROI : RI_{mean}=L_{mean}/BG_{mean}, RI_{max}=L_{max}/BG_{max} and RI_{maxmean}=L_{max}/BG_{mean}.

RESULTS

Visual assessment

Representative images are illustrated in Figure 2. Seventy-four tumors were classified as TI-positive and 14 as TI-negative. The TI-negative tumors are shown in Table 2. Ten of the 14 TI-negative tumors (71%) were low-grade tumors (grade I-II), and four were high-grade tumors (grade III). The ROC analysis for the visual assessment obtained using scoring data are shown in Figure 3. The area under the curve (AUC) estimated by the three board-certificated radiologists exceeded 0.7. Reader B and C were double-board-certificated (diagnostic radiology and nuclear medicine) radiologists. The years of experience of radiologist B were greater

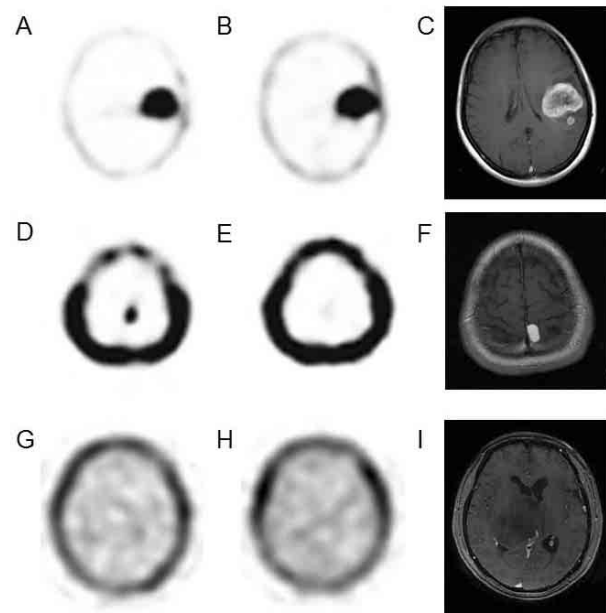


Figure 2. Representative early (15 min ; A, D, G) and delayed (3 h ; B, E, H) ²⁰¹Tl-SPECT images, MRI (Gd-DTPA T1-weighted image ; C, F, I). A 43-year-old female with glioblastoma (WHO grade IV) (A, B, C). The Gd-DTPA T1-weighted image (C) shows a peripheral-dominant enhanced tumor. Early (A) and delayed (B) ²⁰¹Tl-SPECT shows high uptake in the tumor. The retention index is 1.29. A 58-year-old male with angiomatous meningioma (WHO grade I) (D, E, F). The Gd-DTPA T1-weighted image (F) shows a strongly enhanced tumor. Early ²⁰¹Tl-SPECT (D) shows high uptake in the tumor. Delayed ²⁰¹Tl-SPECT (E) shows a rapid washout from the tumor. The retention index is 0.24. A 67-year-old female with diffuse astrocytoma (WHO grade I) (G, H, I). Gd-DTPA T1-weighted image (I) shows no enhancement in the tumor. Early (G) and delayed (H) ²⁰¹Tl-SPECT shows no uptake in the tumor.

Table 2 TI-negative tumors.

Ten of the 14 TI-negative tumors were low-grade tumors (grade I-II), and four were high-grade tumors (grade III).

| WHO grade | Cases | Tumor Type | Count |
|---------------|---------|-----------------------------|-------|
| WHO grade I | 3 cases | Astrocytoma | 1 |
| | | Pilocytic astrocytoma | 1 |
| | | Ganglioglioma | 1 |
| WHO grade II | 7 cases | Diffuse astrocytoma | 3 |
| | | Oligodendroglioma | 2 |
| | | Astrocytoma | 1 |
| | | Glioma | 1 |
| WHO grade III | 4 cases | Anaplastic astrocytoma | 3 |
| | | Anaplastic oligoastrocytoma | 1 |
| WHO grade IV | 0 case | - | - |

than those of radiologist C. The score values estimated by the more experienced radiologist was greater than those of the less experienced radiologist.

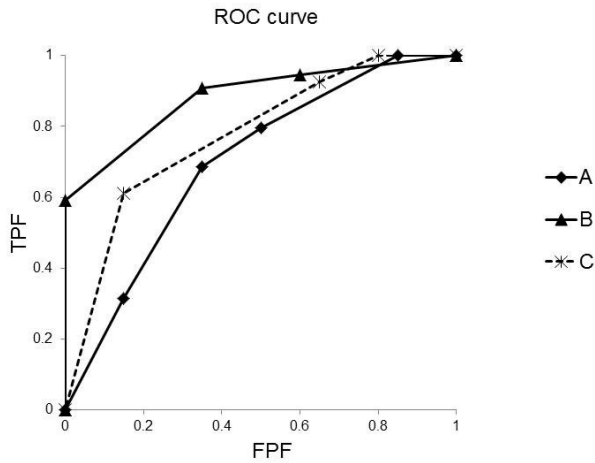


Figure 3. The ROC curve for the visual assessment of scoring. The area under the curve (AUC) estimated by reader A is 0.70, reader B is 0.88, reader C is 0.78. The AUC estimated by the three readers exceeds a value of 0.7. Reader B and C were double-board-certified (diagnostic radiology and nuclear medicine) radiologists. The years of experience of radiologist B were greater than those of radiologist C. This value was greater when estimated by the more experienced radiologist.

Semi-quantitative assessment

The distribution of the retention index (RI) according to the WHO grade classification was shown in Figure 4. RI showed a significant difference between grade I tumors and other grade tumors (grade II, III, IV). The difference between grade II tumors and high grade tumors (grade III, IV) was not statistically significant.

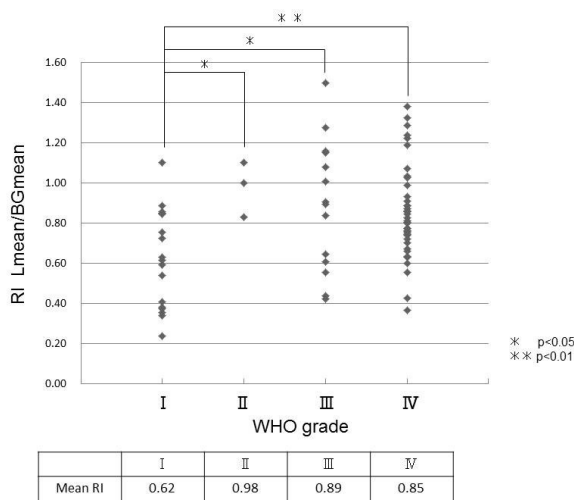


Figure 4. The distribution of the retention index (RI) according to the WHO grade classification. RI showed a significant difference between grade I tumors and other grade tumors (gradeII,III,IV). The difference between grade II tumors and high grade tumors (grade III,IV) was not statistically significant.

There was a statistically significant difference in the RI of high-grade tumors and low-grade tumors (Figure 5).

The difference of the RI between high-grade tumors and low-grade tumors was statistically significant with all three types of RI (Figure 6). A more accurate result was obtained when the background (BG) used the mean value of the ROI.

Receiver operating characteristic (ROC) analysis was performed in the three types of RI (Figure 7). The ROC curves for the three types of RI were similar. The area under the curve (AUC) estimated by RI Lmean/BGmean was 0.69, RI Lmax/BGmax was 0.65, RI Lmax/BGmean was 0.68. A cut-off value of

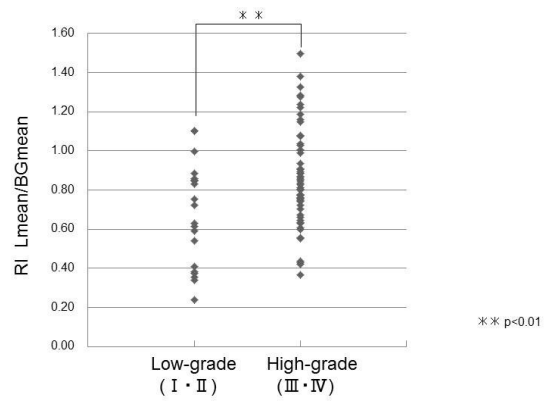


Figure 5. The retention index (RI) shows a significant difference between high-grade tumors and low-grade tumors. There was a statistically significant difference between the RI of high-grade tumors and low-grade tumors ($p < 0.01$).

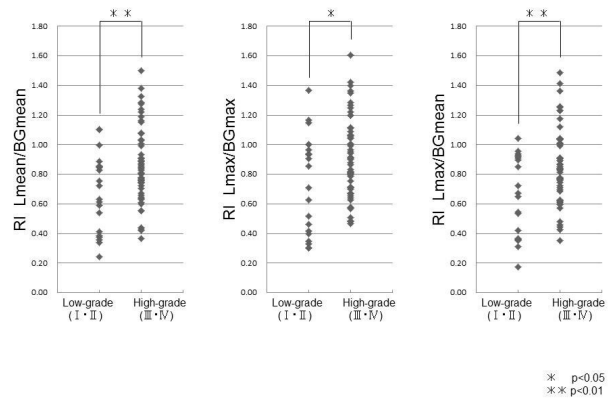


Figure 6. Comparison between the three types of retention index (RI). The difference of the RI between high-grade tumors and low-grade tumors was statistically significant with all three types of RI. A more accurate result was obtained when the background (BG) used the mean value of the ROI.

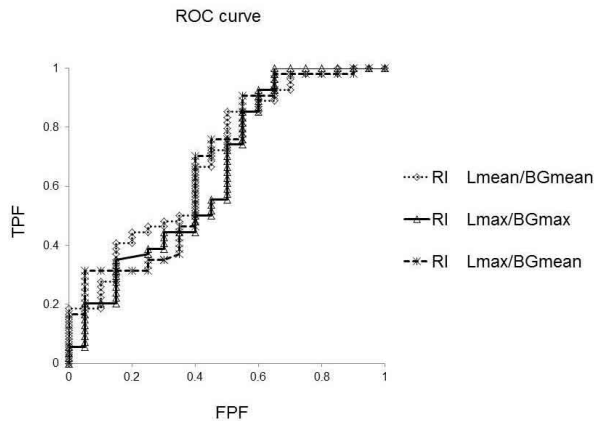


Figure 7. The ROC curve for the three types of RI. The ROC curves for the three types of RI were similar. The area under the curve (AUC) estimated by RI Lmean/BGmean was 0.69, RI Lmax/BGmax was 0.65, RI Lmax/BGmean was 0.68. A cut-off value of 0.63 in the RI Lmean/BGmean yielded a sensitivity of 85.2% and specificity of 50%. A cut-off value of 0.57 in the RI Lmax/BGmax yielded a sensitivity of 92.6% and specificity of 40%. A cut-off value of 0.57 in the RI Lmax/BGmean yielded a sensitivity of 90.7% and a specificity of 45%.

0.63 in the RI Lmean/BGmean yielded a sensitivity of 85.2% and specificity of 50%. A cut-off value of 0.57 in the RI Lmax/BGmax yielded a sensitivity of 92.6% and specificity of 40%. A cut-off value of 0.57 in the RI Lmax/BGmean yielded a sensitivity of 90.7% and a specificity of 45%.

DISCUSSION

The distribution of ^{201}Tl is related to blood-brain barrier (BBB) permeability, regional blood flow, cell proliferation and Na-K ATPase (10, 11). ^{201}Tl uptake in the tumors in early images depends on BBB dysfunction and increased regional blood flow. This occurs via a mechanism similar to Gd-DTPA enhancement of MRI. The accumulation of ^{201}Tl in malignant tumors was usually high in the early phase. However, four high-grade tumors (grade III) demonstrated no accumulation of ^{201}Tl . Three of the four high-grade tumors with no accumulation of ^{201}Tl showed no Gd-DTPA enhancement of MRI. A very small malignant lesion close to the calvarium was underestimated as Tl-negative because of the space resolution of SPECT and normal physiological uptake in the skull.

The ROC analysis of the visual assessment by scoring showed that the accuracy for differentiating benign from malignant tumors using only ^{201}Tl -SPECT was more than 70% by all radiologists, and

was higher in the case of the more experienced radiologist. All radiologists overestimated the four low-grade tumors as being high-grade (3 meningiomas and 1 central neurocytoma). All of these tumors exhibited a strong accumulation of ^{201}Tl in the early and delayed phase. Takeda *et al.* reported that clinically an atypical meningioma (WHO grade II) behaved like a malignant tumor (12). MIB1 and vascular endothelial growth factor (VEGF) expression correlated with the aggressive nature of tumors. The delayed Tl index of atypical meningioma was significantly higher than that of the other pathological types. There was a significant correlation between the Tl uptake index in the delayed image and the MIB1 labeling index. Meningiomas that were strongly positive for VEGF demonstrated a significantly higher Tl uptake in both the early image and the delayed image, in comparison to meningiomas that were weakly positive for VEGF. MRI was helpful in differentiating meningioma from other tumors, when the tumor showed high Tl uptake in both the early and delayed phase, using the typical MRI findings of a meningioma.

The results of the semi-quantitative assessment showed that the difference in RI between high-grade tumors and low-grade tumors was statistically significant for all RIs. A more accurate result was obtained when the background (BG) used the mean value of the ROI. The Tl uptake value was underestimated by the mean value of ROI when the lesion included an area of necrosis and a cystic lesion inside the tumor. Some studies have set the cut-off value at 0.7 to differentiate malignant from benign brain tumors (13). The sensitivity was 85.2% and the specificity was 50% when the cut-off value was set at 0.6 for the RI in the current study.

CONCLUSION

A visual and semi-quantitative assessment using ^{201}Tl -SPECT was found to be useful for differentiating benign from malignant brain tumors. Most Tl-negative tumors are benign. Tl-negative malignant tumors often show no contrast enhancement on MRI. Thallium accumulation and contrast enhancement on MRI may have a close correlation. The retention index (RI) is useful to differentiate malignant Tl-positive tumors from benign lesions. However, there is RI overlap between malignant and benign tumors, thus it is necessary to combine the analysis with other imaging modalities, such as MRI.

FINANCIAL SUPPORT

No potential conflict of interest relevant to this article was reported.

REFERENCES

- Otsuka H, Terazawa K, Morita N, Otomi Y, Takao S, Iwamoto S, Osaki K, Harada M, Nishitani H : Thallium-201 chloride scintigraphy in soft tissue tumors. *J Med Invest* 56(3-4) : 136-141, 2009
- Ancrì D, Basset JY, Lonchamp MF, Etavard C : Diagnosis of cerebral lesions by thallium 201. *Radiology* 128(2) : 417-422, 1978
- Kaplan WD, Takvorian T, Morris JH, Rumbaugh CL, Connolly BT, Atkins HL : Thallium-201 brain tumor imaging : a comparative study with pathologic correlation. *J Nucl Med* 28(1) : 47-52, 1987
- Kosuda S, Fujii H, Aoki S, Suzuki K, Tanaka Y, Nakamura O, Shidara N : Reassessment of quantitative thallium-201 brain SPECT for miscellaneous brain tumors. *Ann Nucl Med* 7(4) : 257-263, 1993
- Yoshii Y, Moritake T, Suzuki K, Fujita K, Nose T, Satou M : Cerebral radiation necrosis with accumulation of thallium-201 on single-photon emission CT. *AJNR Am J Neuroradiol* 17(9) : 1773-1776, 1996
- Serizawa T, Saeki N, Higuchi Y, Ono J, Matsuda S, Sato M, Yanagisawa M, Iuchi T, Nagano O, Yamaura A : Diagnostic value of thallium-201 chloride single-photon emission computerized tomography in differentiating tumor recurrence from radiation injury after gamma knife surgery for metastatic brain tumors. *J Neurosurg* 102 (Suppl) : 266-271, 2005
- Sun D, Liu Q, Liu W, Hu W : Clinical application of ²⁰¹Tl SPECT imaging of brain tumors. *J Nucl Med* 41(1) : 5-10, 2000
- Otsuka H, Shinbata H, Hieda M, Yamashita K, Kitamura H, Senba T, Kashihara K, Tagashira H : The retention indices of ²⁰¹Tl-SPECT in brain tumors. *Ann Nucl Med* 16(7) : 455-459, 2002
- Kleihues P, Burger PC, Scheithauer BW : The new WHO classification of brain tumors. *Brain Pathol* 3(3) : 255-268, 1993
- Ancrì D, Basset JY, Lonchamp MF, Etavard C : Diagnosis of cerebral lesions by thallium 201. *Radiology* 128(2) : 417-422, 1978
- Atkins HL, Budinger TF, Lebowitz E, Ansari AN, Greene MW, Fairchild RG, Ellis KJ : Thallium-201 for medical use. Part 3 : Human distribution and physical imaging properties. *J Nucl Med* 18(2) : 133-140, 1977
- Takeda T, Nakano T, Asano K, Shimamura N, Ohkuma H : Usefulness of thallium-201 SPECT in the evaluation of tumor natures in intracranial meningiomas. *Neuroradiology* 53(11) : 867-873, 2011
- Taki S, Kakuda K, Kakuma K, Kobayashi K, Ohashi M, Ito S, Yokoyama M, Tonami N : ²⁰¹Tl SPECT in the differential diagnosis of brain tumors. *Nucl Med Commun* 20(7) : 637-645, 1999