

ORIGINAL

Mineralocorticoid receptor expression in human penile corpus cavernosum

Tomoteru Kishimoto, Tomoya Fukawa, Kunihisa Yamaguchi, Yasuyo Yamamoto, Hiroyoshi Nakatsuji, Hirofumi Izaki, Masayuki Takahashi, Tomoharu Fukumori, and Hiro-omi Kanayama

Department of Urology, Institute of Health Biosciences, the University of Tokushima Graduate School, Tokushima, Japan

Abstract : Objectives : Mineralocorticoid receptor (MR) is known to play physiological and pathophysiological roles in the cardiovascular system, and MR activation directly damages these organs. The aim of this study was to evaluate the expression of MR and 11 β -hydroxysteroid dehydrogenase type 2 (11 β -HSD2) in the human penile corpus cavernosum. **Methods :** MR and 11 β -HSD2 expression was assayed in human penile tissues, and also in human renal tissues as a positive control. Expressions of MR mRNA and 11 β -HSD2 mRNA were evaluated using reverse transcription polymerase chain reaction (RT-PCR). MR and 11 β -HSD2 were visually identified using immunofluorescence analysis. **Results :** MR mRNA expression in human penis was confirmed by RT-PCR. On quantitative RT-PCR analysis, 11 β -HSD2 mRNA expression was detected at minimal levels in penile tissue. Immunofluorescence analysis revealed positive staining for MR and negative staining for 11 β -HSD2 in smooth muscle cells of the corpus cavernosum. **Conclusions :** This study demonstrated the presence of MR and the absence of 11 β -HSD2 in human penile corpus cavernosum. Considering that MR activation causes various organ damages, MR blockade in human penile corpus cavernosum may have therapeutic benefits. Investigations for the penile effects of MR activation have the potential to provide new treatment approaches for erectile dysfunction. *J. Med. Invest.* 60 : 21-26, February, 2013

Keywords : 11-beta-hydroxysteroid dehydrogenase type 2, aldosterone, erectile dysfunction, mineralocorticoid receptor, penis

INTRODUCTION

Mineralocorticoid receptor (MR) was originally thought to be activated by aldosterone and to act primarily by promoting sodium retention and potassium excretion in the kidney, thereby elevating

blood pressure. MR is located in the cytosol of target cells and the aldosterone-MR complex is then translocated to the cell nucleus, to modulate gene expression and translation of specific aldosterone-induced proteins that regulate electrolyte and fluid balance. Arriza *et al.* successfully cloned MR in 1987, identifying the receptor for aldosterone (1). MR is also known to be distributed not only in the kidney, but also in the cardiovascular and central nervous systems (2).

During the last 15 years, the direct role of the MR in contributing to cardiovascular diseases has

Received for publication July 9, 2012 ; accepted August 21, 2012.

Address correspondence and reprint requests to Tomoteru Kishimoto, 3-18-15 Kuramoto-cho, Tokushima 770-8503, Japan and Fax : +81-88-633-7160.

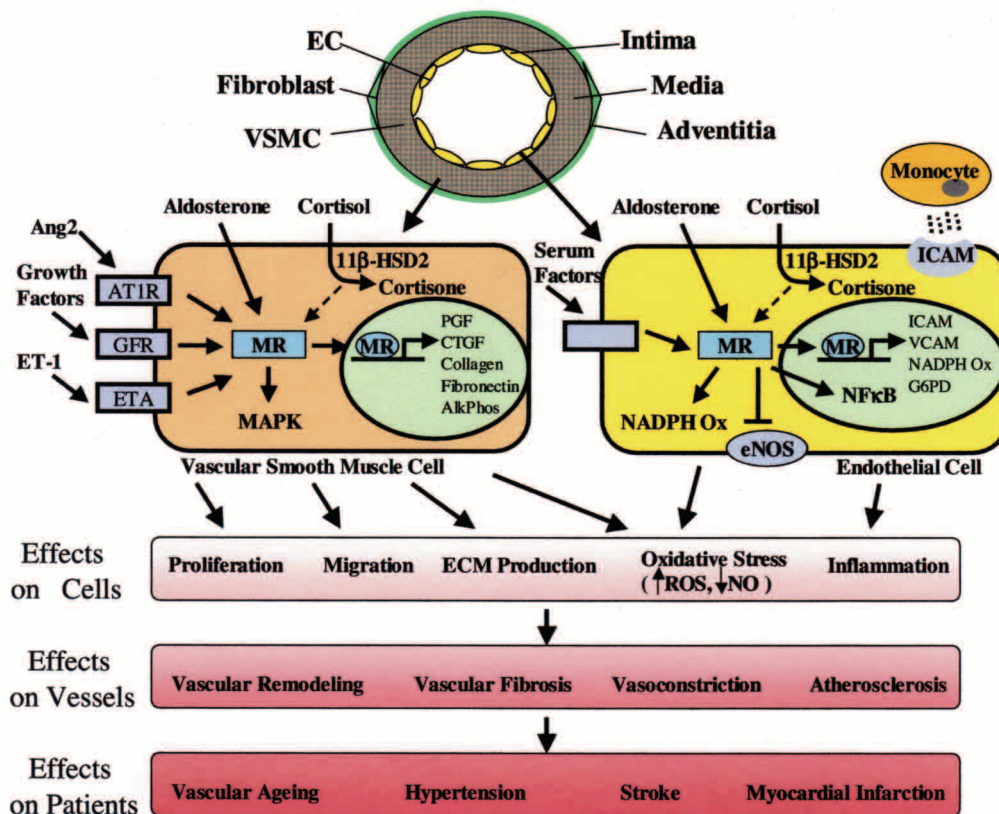
become clear. Two clinical studies, Randomized Aldactone Evaluation Study (RALES) (3) and Eplerenone Post-Acute Myocardial Infarction Heart Failure Efficacy and Survival Study (EPHESUS) (4), in which MR antagonists were used for heart failure patients, have identified major therapeutic benefits of MR antagonism in cardiac failure, emphasizing the importance of MR activation in causing adverse cardiovascular pathophysiological effects. In RALES, administration of the MR antagonist spironolactone to patients with heart failure who were already receiving treatment with an ACE inhibitor, diuretics and digoxin reduced mortality by 30% (3). Furthermore, EPHESUS studied the effects of the selective MR antagonist eplerenone in patients with left ventricular dysfunction following recent myocardial infarction (4). The addition of eplerenone significantly reduced all-cause and cardiovascular mortality. MR inactivation is thought to inhibit myocardial fibrosis and preserve cardiac function. Organ damage following MR activation has been reported in various organs other than the heart, and these effects have been attributed to the direct role of aldosterone through MR-mediated mechanisms (5). Inhibition of MR activation by an MR antagonist is

thus performed to prevent organ damage (6, 7).

MR binds mineralocorticoids and physiologic glucocorticoids with equal affinity. In epithelial tissues such as the kidney, MR is coexpressed with the enzyme 11β -hydroxysteroid dehydrogenase type 2 (11β -HSD2), which catalyzes the conversion of active glucocorticoids into inactive metabolites. MR selectivity for aldosterone is thus protected by 11β -HSD2 in epithelial tissues. In contrast, expression of 11β -HSD2 is very low or absent in non-epithelial tissues such as the heart, suggesting that the majority of MR are likely to be occupied by glucocorticoids with very few accessible by aldosterone in these tissues (5).

McCurley *et al.* summarized the role of vascular MR in regulating normal vascular function and in promoting vascular disease (8). They support that MR activation promotes vascular cell oxidative stress, inflammation, proliferation, migration and extracellular matrix production, thereby promoting vasoconstriction, atherosclerosis, vascular remodeling and fibrosis (Scheme. 1).

The present study examined the presence of MR and 11β -HSD2 in the human penile corpus cavernosum. If MR is also present in the human penile



Scheme 1. Mineralocorticoid receptor in vascular function and disease. (Adapted from McCurley's review.) McCurley *et al.* reveal the mechanism that MR activation promotes vascular dysfunction and disease (8).

corpus cavernosum, human penis appears to be an aldosterone-responsive tissue. Therefore, MR antagonism may be therapeutically beneficial in the human penile corpus cavernosum, as MR blockade prevents organ damage in the cardiovascular system.

MATERIALS AND METHODS

This study was performed with the approval of an institutional review board at the University of Tokushima Graduate School and complied with the tenets of the Declaration of Helsinki.

Subjects

Normal tissues from human penile corpus cavernosum and human renal parenchyma were obtained surgically. Renal tubules, which are known to possess both MR and 11 β -HSD2, were used as positive controls. Penile tissue samples were obtained from 2 patients with penile cancer and 3 patients with bladder cancer. Median age of these patients was 62 years (range 55 to 77). Meanwhile renal tissue samples were obtained from 5 patients with renal tumor. Median age of these patients was 46 years (range 35 to 54). After harvesting, tissue samples for RNA extraction were immediately immersed in RNA stabilization solution (RNAlater; Applied Biosystems, Foster City, CA, USA) to inhibit the destruction of RNA, and were then stored at 4°C. At the same time, tissue samples for immunofluorescence assay were fixed in embedding medium (Tissue-Tek OCT compound; Sakura Finetechnical, Tokyo, Japan) and frozen for preservation at -80°C.

Quantitative real-time reverse transcription polymerase chain reaction (RT-PCR) assay

Total RNA was isolated from human penile tissues using commercial RNeasy kits (Qiagen, Valencia, CA, USA). Complementary DNA was synthesized from 1 μ g of total RNA using a QuantiTect Reverse Transcription kit (Qiagen). QuantiTect Primer Assay QT00028490 (Qiagen) was used as the PCR primer for MR. The PCR primer for 11 β -HSD2 was designed according to Slight *et al.* (9); the sense primer was 5'-GACCAAACCAGGAGACATTAGC-3' (525-546); and the antisense primer was 5'-ATCTAGTCCTTGCCGTAGGC-3' (987-1007). The real-time PCR procedure was performed using a QuantiTect SYBR Green PCR kit (Qiagen), with human renal parenchyma as a positive control for

MR and 11 β -HSD2. For relative quantification, we used glyceraldehyde-3-phosphate dehydrogenase (GAPDH) with the primer from QuantiTect Primer Assay QT00079247 (Qiagen). PCR was performed using the LightCycler version 3.5 Real-Time PCR System (Roche, Basel, Switzerland).

Immunofluorescence analysis

Frozen samples were cut into 5- μ m sections, fixed in 4% paraformaldehyde for 10 min, then washed 3 times with phosphate-buffered saline for 5 min each and incubated with 10% normal goat serum for 30 min at room temperature. Expression of MR and 11 β -HSD2 was analyzed using a mouse monoclonal antibody H10E4C9F (ab2774; Abcam, Cambridge, UK) and an affinity-purified goat polyclonal antibody 11 β -HSD2(T-12) (sc-19262; Santa Cruz Biotechnology, Santa Cruz, CA, USA), respectively. Sections were incubated with anti-MR antibody at a dilution of 1:200. Rabbit polyclonal antibody against smooth muscle actin (RB-9010-R7; Thermo Fisher Scientific, Fremont, CA, USA) was used for detecting smooth muscle cells. This antibody was ready-to-use for immunohistochemical staining. For immunofluorescence assays, anti-MR antibody and anti-actin antibody complexes were visualized with goat anti-mouse immunoglobulin (Ig)G (AlexaFluor568; Invitrogen, Carlsbad, CA, USA) and goat anti-rabbit IgG (AlexaFluor488; Invitrogen), respectively. We performed counterstaining using 4'-6-diamidino-2-phenylindole (DAPI). AlexaFluor568 staining, AlexaFluor488 staining and counterstaining with DAPI appeared as red, green and blue, respectively. On other sections, the 11 β -HSD2-antibody complex was visualized using donkey anti-goat IgG (AlexaFluor568; Invitrogen). Staining for actin and cell nuclei was performed in the same way. Sections were examined under a fluorescence microscope. Renal parenchyma was used as a positive control, while samples incubated with secondary antibody alone were used as negative controls.

RESULTS

MR mRNA expression was confirmed by RT-PCR analysis of human penile corpus cavernosum and human renal parenchyma. Relative quantification of MR was performed in penile tissues (Table 1) and in renal tissues (Table 2), normalizing against GAPDH expression. Mean MR/GAPDH ratios of

Table 1. Quantitative real-time RT-PCR results for human penile tissue

Sample	MR/GAPDH	11 β -HSD2/GAPDH
P-1	4.15	0.0341
P-2	4.21	0.0197
P-3	2.62	0.00284
P-4	3.95	0.00134
P-5	5.30	0.00604
Mean \pm SD	4.05 \pm 0.96	0.0128 \pm 0.0139

SD, standard deviation

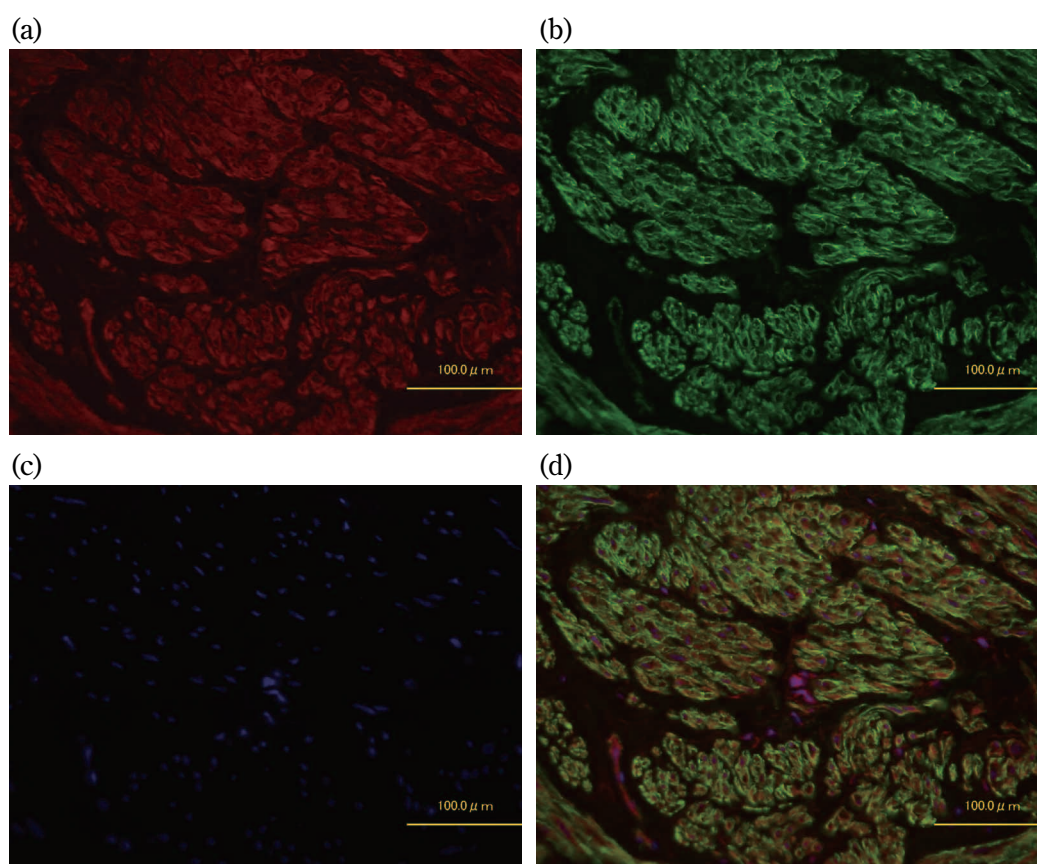
Table 2. Quantitative real-time RT-PCR results for human renal tissue.

Sample	MR/GAPDH	11 β -HSD2/GAPDH
R-1	19.0	48.1
R-2	28.7	23.3
R-3	9.07	9.70
R-4	19.4	48.5
R-5	26.8	11.7
Mean \pm SD	20.6 \pm 7.76	28.3 \pm 19.0

SD, standard deviation

human penile corpus cavernosum and renal parenchyma were 4.05 and 20.6, respectively. On quantitative RT-PCR analysis, 11 β -HSD2 mRNA expression was minimal in penile tissue (Table 1) when compared to renal tissues (Table 2); mean 11 β -HSD2/GAPDH ratios in human penile corpus cavernosum and renal parenchyma were 0.0128 and 28.3, respectively.

Immunofluorescence analyses revealed positive staining for MR in penile tissues (Fig. 1a). MR was also expressed on renal tubular and renal small arteries. In penile tissues, MR-positive regions overlapped corpus cavernosum smooth muscle cells (Fig. 1a-1d). On the other hand, although positive staining for 11 β -HSD2 was confirmed in renal tissues, negative staining for 11 β -HSD2 was confirmed in penile tissues.

**Figure 1.** Immunofluorescence staining of human penile corpus cavernosum.

a) MR is stained red by AlexaFluor568 secondary antibody.

b) Smooth muscle cells are stained green by AlexaFluor488 secondary antibody.

c) Counterstaining with DAPI is seen in blue.

d) Triple staining: MR-positive areas overlap with corpus cavernosum smooth muscle cells.

DISCUSSION

We examined whether MR and 11 β -HSD2 are expressed in the human corpus cavernosum. MR mRNA expression was confirmed in corpus cavernosum tissue, although levels of expression were lower than those found in renal tissue. Immunostaining showed that MR exists in smooth muscle cells of the corpus cavernosum. Moreover, 11 β -HSD2 mRNA expression was extremely low in the corpus cavernosum tissue and the results of immunostaining were negative. Our study thus demonstrated that MR is relatively rich and 11 β -HSD2 is essentially absent in human penile corpus cavernosum. These results are similar to the patterns seen in non-epithelial tissues, such as the heart and brain.

An association has been observed between increased severity of erectile dysfunction (ED) and decreased smooth muscle content (10). MR activation may cause tissue damage in the corpus cavernosum because of MR expression in the human penile corpus cavernosum. If this is true, MR blockade to prevent damage to cavernosal tissues would thus contribute to the prevention and treatment of ED.

Fogari *et al.* presented evidence that angiotensin II receptor blockers have positive effects on male sexuality (11). In a randomized double-blind crossover study of untreated hypertensive men, they compared effects of the angiotensin II receptor blocker valsartan and the β -blocker carvedilol on sexual activity. That study showed that valsartan led to a significant increase in sexual activity when compared with carvedilol. Düsing also suggested that valsartan improved sexual function in hypertensive males (12). Toblli *et al.* reported that male spontaneous hypertensive rats being given the angiotensin receptor blocker candesartan or the β -blocker Atenolol showed similar control in blood pressure, but candesartan provided a significant protective role against cavernosum tissue compared with atenolol (13). They suggested that candesartan prevented cavernosum tissue fibrosis, but the mechanism has not been clarified. MR inactivation associated with suppression of the renin-angiotensin-aldosterone system by angiotensin receptor blocker may be involved in the positive effects on sexual function and protection of corpus cavernosum tissues.

In humans, 11 β -HSD2 catalyzes the conversion of cortisol, which is capable of binding to MR with high affinity, into cortisone, which is incapable of binding MR. The action of 11 β -HSD2 thus effectively

protects MR from occupation by cortisol. In the heart, expression of 11 β -HSD2 is very low and cardiomyocyte MR are normally occupied (but not activated) by cortisol. As little 11 β -HSD2 is present in the human penile corpus cavernosum, most MR are likely to be occupied by cortisol. Qin *et al.* reported that transgenic mice overexpressing 11 β -HSD2 in cardiomyocytes developed cardiac hypertrophy, fibrosis and heart failure in the absence of hypertension, and that eplerenone treatment reversed these effects (14). These studies suggested a protective role for glucocorticoids in preventing the harmful actions of aldosterone. However, Mihailidou *et al.* have shown that cardiac damage is aggravated by MR activation induced by cortisol below myocardial ischemia-reperfusion (15). They mentioned that changes in redox state during oxidative stress may drive cardiomyocyte and vascular smooth muscle cell MR activation by glucocorticoids. We suppose that MR-mediated effects of cortisol in the corpus cavernosum smooth muscle cells are similar to those in the cardiomyocytes.

The rapid effects of aldosterone on human penile corpus cavernosum were investigated by Muguruma *et al.* (16). They demonstrated that aldosterone exerts no direct contractile or relaxation activity on human penile cavernosum tissue, but acts to significantly enhance noradrenaline-induced contraction. This effect was suppressed by the addition of spironolactone, supporting the presence of MR in human penile corpus cavernosum.

Caprio *et al.* recently suggested the potential benefits of selective MR antagonism in the treatment of ED (17). In their opinion, endothelial damage caused by an excess of MR activation may induce ED. Additionally, we consider that MR activation has direct negative impacts on the corpus cavernosum similar to the effects on cardiomyocytes and vascular smooth muscle cells. Further exploration is required to confirm this hypothesis.

This study demonstrated the presence of MR and the absence of 11 β -HSD2 in human penile corpus cavernosum. Considering that MR antagonism prevents various organ damages, we may hope for similar outcomes in the human penile corpus cavernosum. Therefore, investigations for the penile effects of MR activation have the potential to provide new treatment approaches for erectile dysfunction.

CONFLICTS OF INTEREST

We declare that the presenting authors have no conflicts of interest.

REFERENCES

1. Arriza JL, Weinberger C, Cerelli G, Glaser TM, Handelin BL, Housman DE, Evans RM : Cloning of human mineralocorticoid receptor complementary DNA : structural and functional kinship with the glucocorticoid receptor. *Science* 237 : 268-275, 1987
2. Viengchareun S, Le Menuet D, Martinerie L, Munier M, Pascual-Le Tallec L, Lombès M : The mineralocorticoid receptor : insights into its molecular and (patho)physiological biology. *Nucl Recept Signal* 5 : e012, 2007
3. Pitt B, Zannad F, Remme WJ, Cody R, Castaigne A, Perez A, Palensky J, Wittes J : The effect of spironolactone on morbidity and mortality in patients with severe heart failure. Randomized Aldactone Evaluation Study Investigators. *N Engl J Med* 341 : 709-717, 1999
4. Pitt B, Remme W, Zannad F, Neaton J, Martinez F, Roniker B, Bittman R, Hurley S, Kleiman J, Gatlin M : Eplerenone, a selective aldosterone blocker, in patients with left ventricular dysfunction after myocardial infarction. *N Engl J Med* 348 : 1309-1321, 2003
5. Marney AM, Brown NJ : Aldosterone and end-organ damage. *Clin Sci* 113 : 267-278, 2007
6. Remme WJ, Swedberg K : Comprehensive guideline for the diagnosis and treatment of chronic heart failure. *Eur J Heart Fail* 4 : 11-22, 2002
7. Sato A, Hayashi K, Naruse M, Saruta T : Effectiveness of aldosterone blockade in patients with diabetic nephropathy. *Hypertension* 41 : 64-68, 2003
8. McCurley A, Jaffe IZ : Mineralocorticoid receptors in vascular function and disease. *Mol Cell Endocrinol* 350 : 256-265, 2012
9. Slight SH, Ganjam VK, Gómez-Sánchez CE, Zhou MY, Weber KT : High affinity NAD⁺-dependent 11 β -hydroxysteroid dehydrogenase in the human heart. *J Mol Cell Cardiol* 28 : 781-787, 1996
10. Wespes E, Sattar AA, Goltzarian J, Wery D, Daoud N, Schulman CC : Corporeal veno-occlusive dysfunction predominantly intracavernous muscular pathology. *J Urol* 157 : 1678-1680, 1997
11. Fogari R, Zoppi A, Poletti L, Marasi G, Mugellini A, Corradi L : Sexual activity in hypertensive men treated with valsartan or carvedilol : a crossover study. *Am J Hypertens* 14 : 27-31, 2001
12. Düsing R : Effect of the angiotensin II antagonist valsartan on sexual function in hypertensive men. *Blood Pressure Suppl* 2 : 29-34, 2003
13. Toblli JE, Stella I, Mazza ON, Ferder L, Inserra F : Protection of cavernous tissue in male spontaneously hypertensive rats : beyond blood pressure control. *Am J Hypertens* 17 : 516-522, 2004
14. Qin W, Rudolph AE, Bond BR, Rocha R, Blomme EA, Goellner JJ, Funder JW, McMahon EG : Transgenic model of aldosterone-driven cardiac hypertrophy and heart failure. *Circ Res* 93 : 69-76, 2003
15. Mihailidou AS, Loan Le TY, Mardini M, Funder JW : Glucocorticoids activate cardiac mineralocorticoid receptors during experimental myocardial infarction. *Hypertension* 54 : 1306-1312, 2009
16. Muguruma H, Kawanishi Y, Sugiyama H, Kagawa J, Tanimoto S, Yamanaka M, Kojima K, Anzai H, Numata A, Kishimoto T, Kanayama HO : Effect of aldosterone on isolated human penile corpus cavernosum tissue. *BJU Int* 102 : 500-503, 2008
17. Caprio M, Mammi C, Jaffe IZ, Zennaro MC, Aversa A, Mendelsohn ME, Fabbri A, Rosano GM : The mineralocorticoid receptor in endothelial physiology and disease : novel concepts in the understanding of erectile dysfunction. *Curr Pharm Des* 14 : 3749-3757, 2008