

CASE REPORT

Usefulness of transcatheter arterial embolization prior to excision of hypervascular musculoskeletal tumors

Seiji Iwamoto¹, Shoichiro Takao², Hayato Nose¹, Yoichi Otomi¹,
Mitsuhiro Takahashi³, Toshihiko Nishisho³, Junji Ueno², Natsuo Yasui³, and
Masafumi Harada¹

¹Department of Radiology ; ²Department of Radiologic Science and Technology ; and ³Department of Orthopedics, the University of Tokushima, Tokushima, Japan

Abstract : The objective of this study was to evaluate the usefulness of transcatheter arterial embolization prior to surgical excision of musculoskeletal tumors. We reviewed the records of nine patients (3 females and 6 males) who received arterial embolization prior to excision of musculoskeletal tumors in our hospital from December 2009 to April 2010. We evaluated tumor region, size, histopathology, feeding artery, embolic material, and blood loss during surgery. We compared the actual amount of intraoperative bleeding with arterial embolization to estimated amounts of bleeding without embolization predicted by three orthopedic surgeons. Arterial embolization was performed on the same day or within 5 days before surgery. Operations were performed as planned in all patients without serious complications. The amount of intraoperative bleeding was 35-4200 mL and there was significantly less bleeding with arterial embolization compared with the estimated amounts ($p < 0.01$). Our results show that arterial embolization prior to resection of hypervascular musculoskeletal tumors reduces the amount of bleeding during surgery and contributes to patient safety. *J. Med. Invest.* 59 : 284-288, August, 2012

Keywords : *musculoskeletal diseases, therapeutic embolization, interventional radiology*

INTRODUCTION

Tumor embolization therapy was first used with renal cell carcinomas (1) and has since been widely employed in medicine and interventional radiology. Recently, this method has been used for controlling pain due to bone metastasis and management of tumors which do not respond to traditional treatment. To reduce hemorrhage during surgery, arterial embolization is performed preoperatively. We evaluated

the usefulness of transcatheter arterial embolization prior to surgical excision of musculoskeletal tumors.

MATERIALS AND METHODS

We reviewed the records of 9 patients (3 females and 6 males) who received arterial embolization prior to excision of musculoskeletal tumors in our hospital from April 2009 to December 2010 (Table 1). Arterial embolization was performed selectively using different types of microcoils (pushable coils and detachable coils) and gelatin sponge (GS) particles with a coaxial technique against the feeding vessels. The endpoint of embolization was disappearance or sufficient reduction of tumor stain. We

Received for publication April 2, 2012 ; accepted July 11, 2012.

Address correspondence and reprint requests to Seiji Iwamoto, MD, Department of Radiology, Institute of Health Biosciences, the University of Tokushima Graduate School, 3-18-15 Kuramoto-Cho, Tokushima 770-8503, Japan and Fax : +81-88-633-7174.

evaluated tumor location, size, histopathology, feeding artery, embolic material, and blood loss during surgery.

We statistically compared the actual amount of intraoperative bleeding with the estimated amounts

of bleeding if arterial embolization was not performed by t-test. Estimates were made after excision individually by three orthopedic surgeons with a specialty in musculoskeletal tumors, based on pre-operative CT, MR and angiography images (Table 2).

Table 1 : Patient features, tumor location and size

| Case No. | Age | Sex | Location | Tumor size(cm) |
|----------|-----|-----|---------------------------|----------------|
| 1 | 70 | F | Thoracic vertebra | 3×2×2 |
| 2 | 80 | M | L. gluteal region | 14×8×10 |
| 3 | 68 | M | L. femoral region | 5×4×7.5 |
| 4 | 46 | M | Thoracic vertebra | 3×4×3 |
| 5 | 47 | F | L. shoulder | 13×10×10 |
| 6 | 80 | M | R. ilium | 5×4×6 |
| 7 | 36 | M | R. retroperitoneal region | 6×6×8 |
| 8 | 10 | F | L. humerus | 15×13×13 |
| 9 | 78 | M | R. femoral region | 8×6×15 |

RESULTS

Arterial embolization was performed on the same day or within 5 days before surgery and surgery was performed as planned (total tumor extraction) in all patients without serious complications. Intraoperative bleeding was 35-4200 mL (average : 1236 mL) (Table 3, Fig. 1-4).

The actual amount of bleeding with arterial embolization was significantly (p<0.01) lower than the estimated amounts (average : 2430 mL).

Table 2 : Estimated blood loss (mL)

| | Case No. | | | | | | | | | |
|-----------------------|----------|------|------|-----|------|------|-------|------|-------|------|
| | 1 | 2 | 3 | 4 | 5 | 6 | 7 | 8 | 9 | |
| 3 Orthopedic Surgeons | Dr. A | 2000 | 1500 | 450 | 5000 | 650 | 6000 | 800 | 5000 | 800 |
| | Dr. B | 3000 | 600 | 300 | 1500 | 1000 | 2000 | 800 | 500 | 2000 |
| | Dr. C | 1200 | 2000 | 500 | 2500 | 2000 | 10000 | 2000 | 10000 | 1500 |
| | Average | 2067 | 1367 | 417 | 3000 | 1217 | 6000 | 1200 | 5167 | 1433 |

Table 3 : Interventions and outcomes

| Case No. | Embolic materials | Interval from embolization to operation | Actual bleeding (mL) | Average of estimated bleeding (mL) | Pathological diagnosis |
|----------|-------------------------------|---|----------------------|------------------------------------|---|
| 1 | Gelatin sponge (GS) particles | 5 days | 920 | 2067 | Metastatic adenocarcinoma |
| 2 | GS particles, Microcoils | 2 days | 765 | 1367 | Foreign body granuloma and hematoma with amyloid deposition |
| 3 | GS particles Microcoils | 1 day | 35 | 417 | MFH |
| 4 | GS particles Microcoils | 1 day | 1400 | 3000 | Metastatic adenocarcinoma |
| 5 | GS particles Microcoils | The same day | 350 | 1217 | Metastatic sarcoma |
| 6 | GS particles Microcoils | The same day | 4200 | 6000 | Metastatic renal cell carcinoma |
| 7 | GS particles Microcoils | 1 day | 460 | 1200 | MPNST |
| 8 | GS particles Microcoils | The same day | 2650 | 5167 | Chondroblastoma |
| 9 | GS particles Microcoils | The same day | 340 | 1433 | Liposarcoma |

MFH : malignant fibrous histiocytoma

MPNST : malignant peripheral nerve sheath tumor

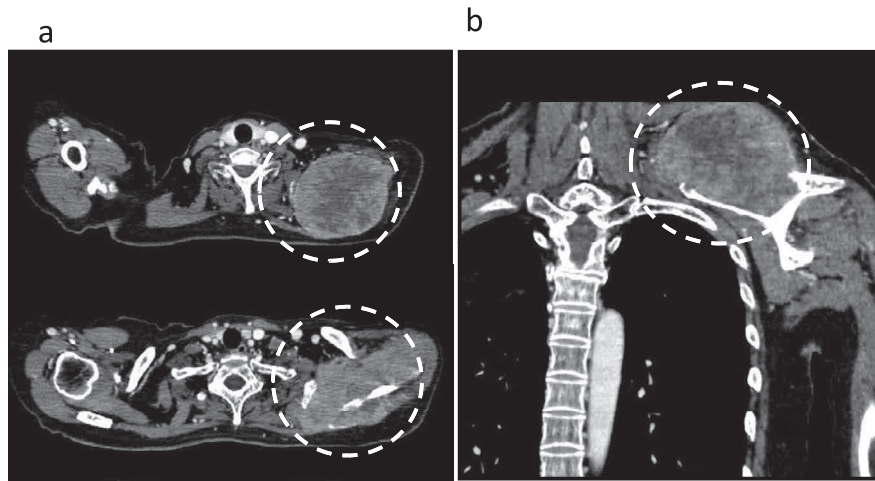


Figure 1 : Case 5. A 47-year-old woman with a metastatic tumor of the left shoulder (uterine leiomyosarcoma). Tumor size was $13 \times 10 \times 10$ cm ; a : enhanced CT, b : MPR coronal view.

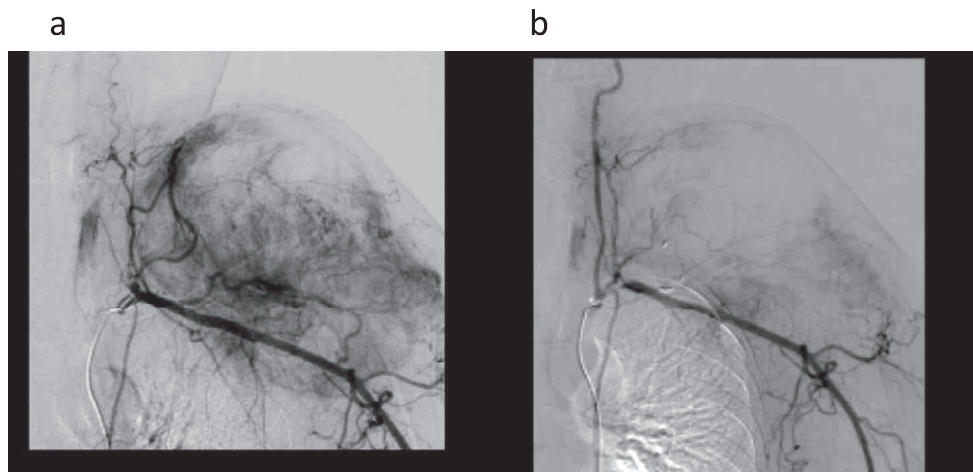


Figure 2 : Case 5. DSA of right external iliac artery ; a : pre-embolization, b : postembolization. GS particles and microcoils were used. The actual amount of intraoperative bleeding was 350 mL and the average estimated amount of bleeding was 1217 mL.

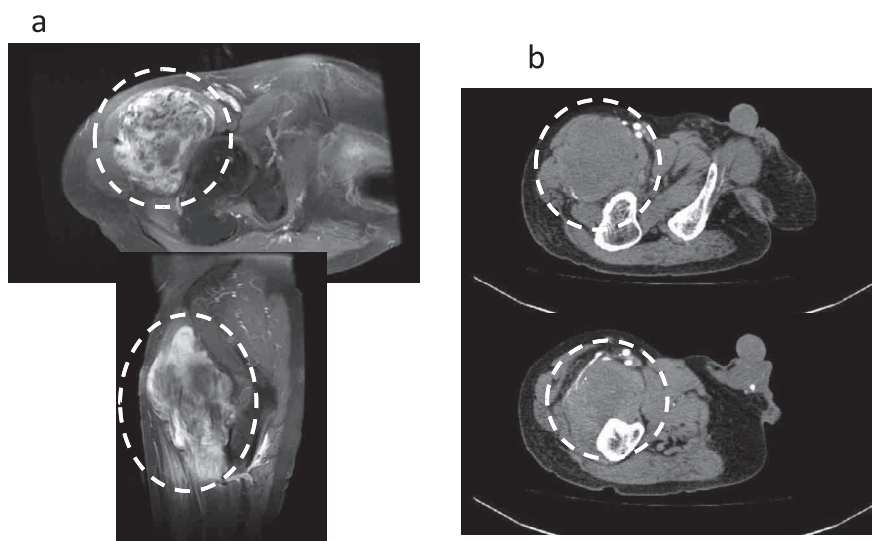


Figure 3 : Case 9. A 78-year-old man with a liposarcoma of the right femoral region. Tumor size was $8 \times 6 \times 15$ cm ; a : MRI CE Fat Sat T1WI axial & sagittal view, b : enhanced CT.

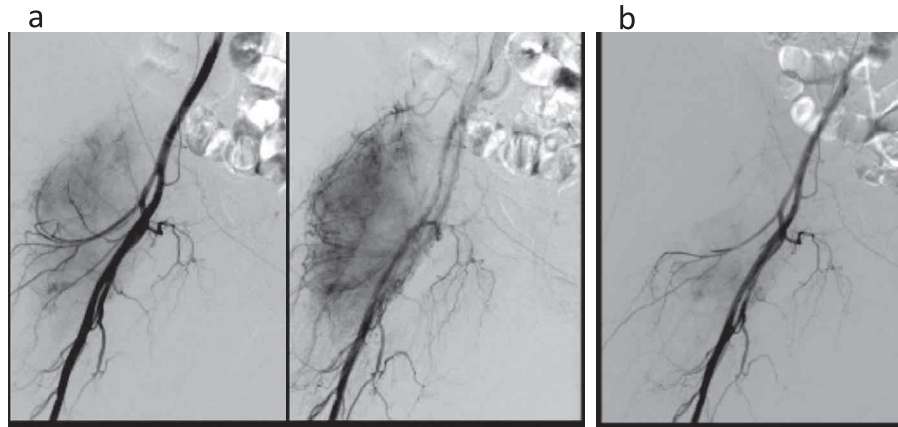


Figure 4 : Case 9. DSA of the right external iliac artery ; a : pre-embolization, b : postembolization. GS particles and microcoils were used. The actual amount of intraoperative bleeding was 340 mL and the average estimated amount of bleeding was 1433 mL.

DISCUSSION

Usefulness of embolization

One of the earliest reports of selective transcatheter arterial embolization for musculoskeletal bone tumors was in 1975 when the technique was employed to reduce perioperative blood loss. Reports of transcatheter arterial embolization prior to excision of musculoskeletal tumors are rare but usefulness is reported in every case (2-7). Location, size, and vascularity of the tumors vary widely. Operative time and blood loss during surgery also vary widely according to the degree of surgical intervention. In our study, arterial embolization significantly decreased the amount of intraoperative blood loss compared with the estimated amount of bleeding.

The interval from embolization to operation was 5 days on account of the schedule of embolization and excision in the first case, only. Metallic embolic coils are permanent and GS particles are temporary, with the embolic effect lasting at least 1 week with the latter. Generally speaking, the appropriate interval would be at least one day because collateral pathways readily develop, we believe the usefulness is the same if risks, such as infection, pain, and fever, are not considered.

Advantages and indications

The advantages of transcatheter arterial embolization include minimal invasion and that hemostasis is often possible even with difficult surgical ligation. We consider the ideal indications for arterial embolization prior to excision of musculoskeletal tumors are : 1. When large amounts of intraoperative bleeding are expected and where bleeding would be difficult to stop. 2. Cases with a lower risk of serious

complications following embolization. 3. Cases with hypervascular tumors of the trunk, pelvis and proximal limbs excluding the peripheral spinal region.

Embolization of bone tumors, especially vertebral tumors

Gellad, *et al.* reported that in patients who underwent adequate embolization, an average of 1,850 mL of estimated blood loss was reported. In those who underwent inadequate or no embolization, greater than 3,500 mL of estimated blood loss occurred (8).

We performed embolization in 2 cases with metastasis to the thoracic vertebrae. Angio-CT imaging and xylocaine infusion testing was used before embolization to identify the Adamkiewicz artery and confirm that it was not involved with the tumor, thus avoiding complications. We also used embolization in the intercostal and lumbar arteries without complications. Careful consideration of blood supply enabled us to perform embolization of vertebral tumors safely and we feel this intervention should be considered in the treatment of primary or secondary bone tumors (9).

Embolic materials

The main purpose of embolization is to achieve thrombus formation and occlusion by administering embolizing materials through a selective catheter placed in an artery or vein (10). Our interventional radiologists determined the appropriate artery and the release site of the metallic coils after discussion with the orthopedic surgeons.

The advantages of using metallic coils include a stronger embolus effect than with the single use of GS particles. Also, the position of the coils can be

easily confirmed by the surgeon using intraoperative fluoroscopy and palpation. The disadvantages include the high expense and the possibility of coil migration intraoperatively. Permanently placed coils may also cause CT and MR imaging artifacts.

In conclusion, arterial embolization prior to resection of hypervascular musculoskeletal tumors decreases the amount of bleeding during the operation and contributes to patient safety.

CONFLICT OF INTEREST

For all authors : No conflicts of interest are present.

REFERENCES

1. Almgard LE, Fernström I, Haverling M, Ljungqvist A : Treatment of renal adenocarcinoma by embolic occlusion of the renal circulation. *Br J Urol* 45 : 475-479, 1973
2. Fenoy AJ, Greenlee JD, Menezes AH, Donovan KA, Sato Y, Hitchon PW, Chaloupka JC : Primary bone tumors of the spine in children. *J Neurosurg* 105 Suppl : 252-260, 2006
3. Reuter M, Heller M, Heise U, Beese M : Transcatheter embolization of tumors of the muscular and skeletal systems. *Rofo* 156 : 182-188, 1992
4. Bowers TA, Murray JA, Charnsangavej C, Soo CS, Chuang VP, Wallace S : Bone metastasis from renal carcinoma. The preoperative use of transcatheter arterial occlusion. *J Bone Joint Surg* 64-A : 749-754, 1982
5. Feldman F, Casarella WJ, Dick HM, Hollander BA : Selective intra-arterial embolization of bone tumors. *AJR Am J Roentgenol* 123 : 130-139, 1975
6. Dick HM, Bigliani LU, Michelsen WJ, Johnston AD, Stinchfield FE : Adjuvant arterial embolization in the treatment of benign primary bone tumors in children. *Clin Orthop* 139 : 133-141, 1979
7. Carpenter PR, Ewing JW, Cook AJ, Kuster AH : Angiographic assessment and control of potential operative hemorrhage with pathologic fractures secondary to metastasis. *Clin Orthop* 123 : 6-8, 1977
8. Gellad FE, Sadato N, Numaguchi Y, Levine AM : Vascular metastatic lesions of the spine : preoperative embolization. *Radiology* 176 : 683-6, 1990
9. Owen RJ : Embolization of Musculoskeletal Bone Tumors. *Semin Intervent Radiol* 27 : 111-23, 2010
10. Börüban S, Sancak T, Yildiz Y, Sağlık Y : Embolization of benign and malignant bone and soft tissue tumors of the extremities. *Diagn Interv Radiol* 13 : 164-71, 2007