

## ORIGINAL

# Epidermal growth factor receptor-tyrosine kinase inhibitor (gefitinib) augments pneumonitis, but attenuates lung fibrosis in response to radiation injury in rats

Keiko Miyake<sup>1</sup>, Kenji Tani<sup>2</sup>, Soji Kakiuchi<sup>1</sup>, Chiyuki Suzuka<sup>1</sup>, Yuko Toyoda<sup>1</sup>, Jun Kishi<sup>1</sup>, Toshifumi Tezuka<sup>1</sup>, Shino Yuasa<sup>2</sup>, Masaki Hanibuchi<sup>1</sup>, Yoshinori Aono<sup>1</sup>, Yasuhiko Nishioka<sup>1</sup>, and Saburo Sone<sup>1</sup>

<sup>1</sup>Department of Respiratory Medicine and Rheumatology and <sup>2</sup>Department of General Medicine, Institute of Health Biosciences, the University of Tokushima Graduate School, Tokushima, Japan

**Abstract : Background :** Gefitinib, an inhibitor of epidermal growth factor receptor (EGFR) tyrosine kinase, has been reported to be associated with interstitial lung disorders, and their high incidence and mortality have become a matter of great concern, especially in Japan. In this study, we investigated the effect of gefitinib on different phases of radiation-induced lung disorders in an experimental model. **Methods :** The thoraxes of Wistar rats were irradiated on day 1 with a single X-ray dose of 20 Gy, and gefitinib (50 mg/kg/day) was orally administered from day 1 to 14. The rat lungs were harvested on days 15 and 57 and the bronchoalveolar lavage (BAL) was performed. **Results :** Gefitinib treatment increased the infiltration of inflammatory cells, which produced more pro-inflammatory cytokines (IL-6, IL-1 $\beta$ ), in the lungs of the irradiated rats on days 15 and 57, while gefitinib treatment reduced collagen content of the lungs in irradiated rats and decreased proliferation and EGFR expression in the lung fibroblasts from irradiated rats on day 57. **Conclusions :** In irradiated rats, gefitinib treatment augmented lung inflammation, including inflammatory cell infiltration and pro-inflammatory cytokine expression, while gefitinib treatment attenuated fibrotic lung remodeling due to the inhibition of lung fibroblast proliferation. *J. Med. Invest.* 59 : 174-185, February, 2012

**Keywords :** gefitinib, radiation pneumonitis, epidermal growth factor receptor

## INTRODUCTION

Non-small cell lung cancer (NSCLC) remains the leading cause of cancer-related mortality worldwide (1). Although the standard treatment for patients with metastatic NSCLC is the platinum-based

chemotherapy, it produced only a modest survival benefit (2, 3). On the other hand, newly developed tyrosine kinase inhibitors targeting the epidermal growth factor receptor (EGFR), such as gefitinib and erlotinib, have shown remarkable activity in a portion of patients with NSCLC (4). However,

Abbreviation used : NSCLC, non-small cell lung cancer ; EGFR, epidermal growth factor receptor ; ILD, interstitial lung disease ; TRT, thoracic radiation therapy ; BAL, bronchoalveolar lavage ; FCS, fetal calf serum ; IL, interleukin ; ELISA, enzyme-linked immunosorbent assay ; DMEM, Dulbecco's modified Eagle's medium ; MTT, 3-(4,5-dimethylthiazol-2-yl)-2, 5-diphenyl tetrazolium ; RT-PCR, reverse transcription polymerase chain reaction ; TGF- $\alpha$ , Transforming growth factor- $\alpha$ .

Received for publication November 10, 2011 ; accepted January 4, 2012.

Address correspondence and reprint requests to Saburo Sone, Department of Respiratory Medicine and Rheumatology, Institute of Health Biosciences, the University of Tokushima Graduate School, 3-18-15 Kuramoto-cho, Tokushima 770-8503, Japan and Fax : +81-88-633-2134.

life-threatening interstitial lung disease (ILD) related to gefitinib has previously been identified as the most problematic toxicity of this drug, with an incidence of ILD caused by gefitinib thought to be around 4% and with about one-third of the cases being fatal in Japan (5-7). Risk factors for ILD, such as male sex, smoking, and the existence of idiopathic pulmonary fibrosis, have been identified in a number of retrospective and prospective studies of Japanese gefitinib-treated NSCLC patients (5-7). One of these studies suggested that history of prior radiotherapy also seem to be a predictive risk factor for ILD development (8).

Meanwhile, definitive thoracic radiation therapy (TRT) in combination with chemotherapy is the current standard of care for patients with unresectable locally advanced NSCLC, corresponding to around one-third of individuals with newly diagnosed NSCLC. However, TRT also induces injury to normal lung tissue, causing radiation pneumonitis (inflammation of the lungs due to radiation) (9). The injury of capillary endothelial cells and epithelial cells, which have the highest mitotic rate and are the most susceptible cells in the lung to radiation, is believed to initiate alveolar edema, exudation, and vascular congestion (10, 11). Radiation fibrosis is a sequel of radiation pneumonitis, as an excessive and detrimental over-healing (12, 13).

Although the concurrent chemo-radiotherapy is the gold standard of the treatment for unresectable locally advanced NSCLC, most treated individuals experience disease recurrence, with the 5-year survival rate being only around 20% (14, 15). Further improvement in treatment outcome for patients with locally advanced NSCLC will require the development of more effective combined-modality therapies. Although the preclinical models have shown that EGFR inhibition enhances the antitumor activity of radiation (16, 17), a feasibility study, conducted by the West Japan Thoracic Oncology Group, to examine the safety and toxicity profile of gefitinib with concurrent TRT in patients with unresectable NSCLC was closed early because of pulmonary toxicity (18).

These lines of evidence suggest that gefitinib enhances radiation-induced pulmonary toxicity, however, the mechanism how gefitinib affects radiation pneumonitis and fibrosis has not been clarified. In this study, we developed an experimental model of radiation-induced lung injury and subsequent pulmonary fibrosis and investigated the effect of gefitinib on different phases of this disorder.

## MATERIALS AND METHODS

### *Animals*

Specific-pathogen-free male Wistar rats were obtained from the Tokushima Experimental Animal Laboratory (Tokushima, Japan) and they were housed in a laminar flow facility and allowed sterilized food and water. The rats suffered no pathogenic infection during the study. Experimental protocol was reviewed and approved by animal care and use committee of the University of Tokushima, and all animal experiments were performed according to its guidelines.

### *Designs for animal experiment, thoracic irradiation and gefitinib treatment*

The rats were randomly assigned to 1 of 4 experimental groups : 1) the unirradiated rats treated with oral administration of vehicle (0.1% Tween 80) once daily ; 2) the unirradiated rats treated with oral administration of gefitinib (50 mg/kg/day) once daily ; 3) the irradiated rats treated with oral administration of vehicle once daily ; and 4) the irradiated rats treated with oral administration of gefitinib once daily. Each experimental group comprised 5-6 rats and all treatments were delivered for 14 days. Thoracic irradiation was administered as described previously (19, 20). Briefly, the rats weighing 180-200 g were lightly anesthetized with an intraperitoneal injection of sodium pentobarbital and confined to a plastic molded frame so that both lungs were in the field defined by lead collimators. Simulation X rays determined the accuracy of positioning. The thoraxes were irradiated on day 1 with a single dose of 20 Gy using X-ray equipment (MBR-1520R3, Hitachi Medico Technology, Tokyo, Japan). The radiation parameters were as follows : a dose-rate of 3.8 Gy per minute at 150 kV and 20 mA (0.5 mmCu+0.5 mmAl). The unirradiated rats were anesthetized and exposed to the same room for the same period as the animals undergoing irradiation. Gefitinib (50 mg/kg/day ; Astra Zeneca, Macclesfield, UK) was suspended in 0.1% Tween 80 solution and given once daily by oral gavage from day 1 to day 14 after irradiation in the rats with gefitinib treatment groups. Similarly, vehicle (0.1% Tween 80) alone was administered in the rats without gefitinib treatment groups.

### *Bronchoalveolar lavage and bronchoalveolar cell analysis*

The lungs were harvested together with other

thoracic organs from the rats in each experimental group on days 15 and 57 after irradiation. The trachea was cannulated with plastic catheter attached to a 6-ml syringe, and bronchoalveolar lavage (BAL) fluid was collected in a total volume of 30 ml of sterile saline across five 6-ml samples with gentle massaging of the lungs. The BAL fluid was combined, passed through a sterile gauze, and centrifuged at 1200 rpm for 10 mins at 4°C to precipitate the cells it contained. The precipitated cells obtained from the BAL fluid were suspended in an appropriate volume of RPMI-1640 (Nissui Pharmaceutical Co., Tokyo, Japan) and counted in a hemocytometer. Differential counts of 500 cells were carried out on smears of sedimented cells stained with Diff-Quik solution (International Reagents Co., Kobe, Japan), and the percentages of alveolar macrophages, lymphocytes, neutrophils, and eosinophils were calculated.

#### *Assay for cytokines*

The BAL cells dissolved in RPMI-1640 containing fetal calf serum (FCS; GIBCO, Grand Island, NY) at a concentration of  $5.5 \times 10^5$  /ml were incubated for 48 hrs in 24-well tissue culture dishes (Falcon Plastics, Oxnard, CA) at 37°C in a humidified atmosphere of 5% CO<sub>2</sub> in air. Then, the supernatants were collected and the concentrations of interleukin (IL)-6 and IL-1 $\beta$  were determined by enzyme-linked immunosorbent assay (ELISA; R&D Systems, Minneapolis, MN). The assays were set up in duplicate and performed according to the manufacturer's recommendations. The lower limits of detection were 21.0 pg/mL and 5.0 pg/mL for IL-6 and IL-1 $\beta$ , respectively.

#### *Histological examination*

Whole non-lavaged lungs were harvested from irradiated rats on day 0, 15 and 57 after irradiation, fixed in 10% phosphate-buffered formalin, and embedded in paraffin. Sections of 3- $\mu$ m thickness were cut and stained with hematoxylin-eosin (H&E) or Azan for histological analysis. The sections were then systematically scanned in a microscope at  $\times 400$  magnification. Cell identification was performed using the classic definitions of cell shape, nuclear shape, heterochromatin, nuclear-to-cytoplasmic ratio, cytoplasmic volume, and staining characteristics.

#### *Collagen assay*

The right lungs harvested on day 57 were used for collagen assay. Total lung collagen was determined

using the Sircol Collagen Assay kit (Biocolor Ltd., Belfast, Northern Ireland) according to the manufacturer's

#### *The isolation of the rat lung fibroblasts*

The rat lung fibroblasts were prepared as described previously (21). Briefly, the lungs were harvested using sterile instruments, minced into 2-4 mm pieces, suspended in sterile PBS containing 0.5% trypsin, and incubated with gentle stirring for 30 mins at 37°C. The dispersed cells were then collected and separated from undigested tissue and debris by filtration through sterile gauze. Next, the cells were washed with Dulbecco's modified Eagle's medium (DMEM; Nissui Pharmaceutical Co., Tokyo, Japan) containing 10% FCS and then resuspended in DMEM, before being incubated at 37°C in a humidified atmosphere of 5% CO<sub>2</sub> in air. After 24-48 hrs, unattached cells were removed by washing, and fresh media was added. When the tissue culture plates had reached confluence, the cells were passaged by splitting them 1:3. The cells were then maintained in DMEM containing 10% FCS and passaged repeatedly. By the fourth passage, the cells had formed homogenous monolayers that were morphologically consistent with fibroblast-like cells. Cell identity was confirmed by positive vimentin staining and by negative staining of cytokeratin or CD68. All experiments were undertaken using cells from the 4th to 10th passage. Fibroblasts from irradiated and unirradiated rat lungs were each prepared as five separate lines on days 15 and 57 after irradiation.

#### *Cell proliferation assay*

Cell proliferation was determined using the MTT [3-(4,5-dimethylthiazol-2-yl)-2, 5-diphenyl tetrazolium] dye reduction method. The fibroblasts were seeded onto 6-well plates ( $5 \times 10^4$  cells/well) and maintained in DMEM containing 10% FCS for 24, 48, 72, 96, 120, or 144 hrs. At each time point, cell proliferation was evaluated by the MTT assay using Cell Counting Kits (WAKO, Osaka, Japan). Briefly, 10  $\mu$ l of stock MTT solution (5 mg/ml) was added to all wells of an assay, and the plates were incubated for 4 hrs at 37°C in a humidified atmosphere of 5% CO<sub>2</sub> in air. Acid-isopropanol (100  $\mu$ l of 0.04 N HCl in isopropanol) was added to all wells and mixed thoroughly to dissolve the dark blue crystals. After being left for a few minutes at room temperature to ensure that all crystals had dissolved, the plates were measured with an MTP-32 Microplate

Photometer (Corona Electric Co., Ibaragi, Japan) using a test wavelength of 550 nm and a reference wavelength of 630 nm.

*Quantitative reverse transcription-polymerase chain reaction (RT-PCR)*

Total RNAs of the samples extracted from each fibroblast line were isolated using the RNeasy Mini and RNase-free DNase kits (Qiagen, Valencia, CA) in accordance with the manufacturer’s recommendations. Total RNAs were reverse transcribed using the Omniscript RT kit (Qiagen, Valencia, CA), and the expression of EGFR, COL1A2, and GAPDH was measured by quantitative RT-PCR analysis on an ABI 7700 Sequence Detection system (Applied Biosystems, Foster City, CA) with the following commercially available sets of primers and fluorogenic probes (TaqMan® Gene Expression Assays products) : EGFR, Rn01434460\_m1 ; COL1A2, Rn00670322\_g1 ; GAPDH, Rn01775763\_g1. The quantitative RT-PCR experiments were performed in triplicate, and the relative expression levels were calculated based on the comparative Ct method.

*Statistical Analysis*

All results are expressed as the mean ± SEM. Statistical analysis was performed using the Student’s

two-tailed unpaired t test for comparisons between two groups. Differences were considered significant when the corresponding *p* value was 0.05 or less. Data were analyzed using the Statview software package.

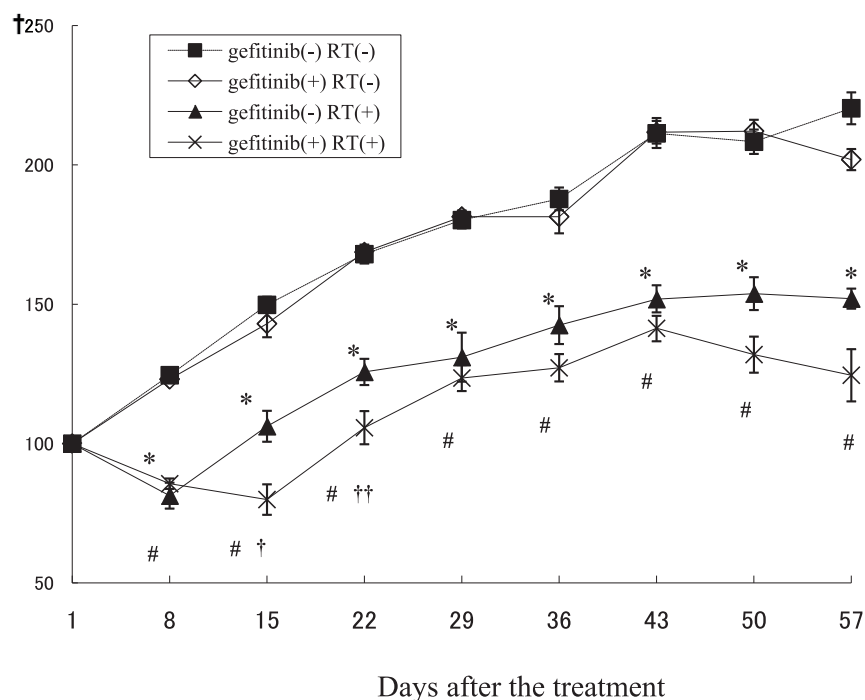
**RESULTS**

*Body weight changes of the rats*

To elucidate the influence of radiation and gefitinib, we first examined the body weights of the rats in each experimental group. Figure 1 shows the time course of body weight change after irradiation. A significant decrease in body weight was seen in the irradiated rats during entire experimental period compared with the unirradiated rats. The body weight of the irradiated rats treated with gefitinib tended to be decreased compared to those treated with vehicle during entire experimental period and a significantly decreased body weight was seen on day 15 after irradiation. Gefitinib treatment itself did not affect the body weight in unirradiated rats.

*Cellular analysis of the BAL fluids*

We previously demonstrated histological changes in the lungs after a single dose of radiation, which



**Figure 1.** Rats were irradiated on day 1 with a single dose of 20 Gy using X-ray equipment. Time course of the changes in body weight in each experimental group. Vehicle plus no radiation (RT) (■), gefitinib plus no RT (◇), vehicle plus RT (▲), and gefitinib plus RT (×). Data are presented as mean ± SEM. \**p* < 0.001 vs. vehicle plus no RT, #*p* < 0.001 vs. gefitinib plus no RT, and †*p* < 0.01 vs. vehicle plus RT, ††*p* < 0.05 vs. vehicle plus RT.

showed that interstitial pneumonitis occurs 2 weeks after irradiation, followed by an increase in interstitial lung collagen 8 weeks and later (22). Therefore, in this study, we examined the BAL fluid on days 15 and 57 after irradiation to test whether gefitinib treatment affects inflammation in the irradiated lungs.

Regarding cell differentiation, the numbers of neutrophils in the BAL fluids were significantly increased in the irradiated rats on days 15 and 57 compared with the unirradiated rats. Gefitinib treatment significantly increased the numbers of neutrophils in BAL fluids in irradiated rats on day 15, but significantly decreased those on day 57 (Figure 2A, B). Similarly, a significantly increased numbers of lymphocytes in the BAL fluids were observed in the irradiated rats with gefitinib compared to those without gefitinib on days 15 and 57 (Figure 2C, D). Gefitinib treatment itself did not affect the total number of BAL cells (data not shown) or the cellularity of the BAL cells in unirradiated rats.

#### Proinflammatory Cytokines production from the BAL cells

Several pro-inflammatory cytokines have been reported to contribute to the development of radiation-induced lung disorders (23, 24) and increases in IL-6 and IL-1 $\beta$  have been found during the development of alveolitis (24, 25). Therefore, we next measured the concentrations of IL-6 and IL-1 $\beta$  in the culture medium of BAL cells from the rats in each experimental group by ELISA. The BAL cells from the irradiated rats produced significantly more IL-6 and IL-1 $\beta$  than those from the unirradiated rats on day 15 after irradiation. Moreover, Gefitinib treatment for rats significantly increased the expressions of IL-6 and IL-1 $\beta$  from the BAL cells from the irradiated rats on day 15 after irradiation. The increased expression of IL-6 and IL-1 $\beta$  from the BAL cells from the irradiated rats with gefitinib continued until day 57 (Figure 3A-D).

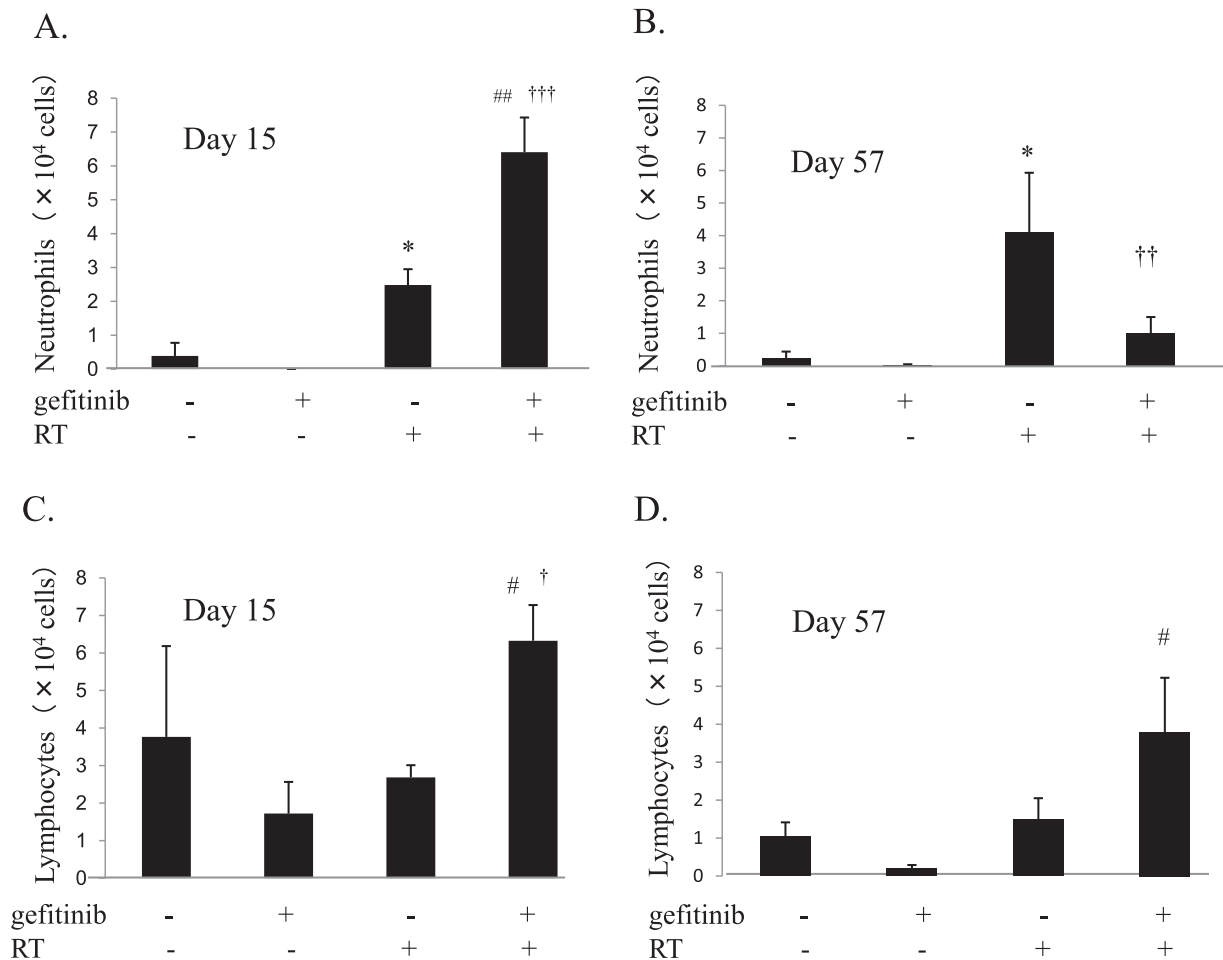


Figure 2. The number of neutrophils (A; day 15, B; day 57) and lymphocytes (C; day 15, D; day 57) in the BAL fluids from each experimental group. Data are presented as mean  $\pm$  SEM (n=3-5 per group). \* $p$ <0.005 vs. vehicle plus no RT, # $p$ <0.05 and ## $p$ <0.0001 vs. gefitinib plus no RT, and † $p$ <0.05, †† $p$ <0.01 and ††† $p$ <0.0005 vs. vehicle plus RT.

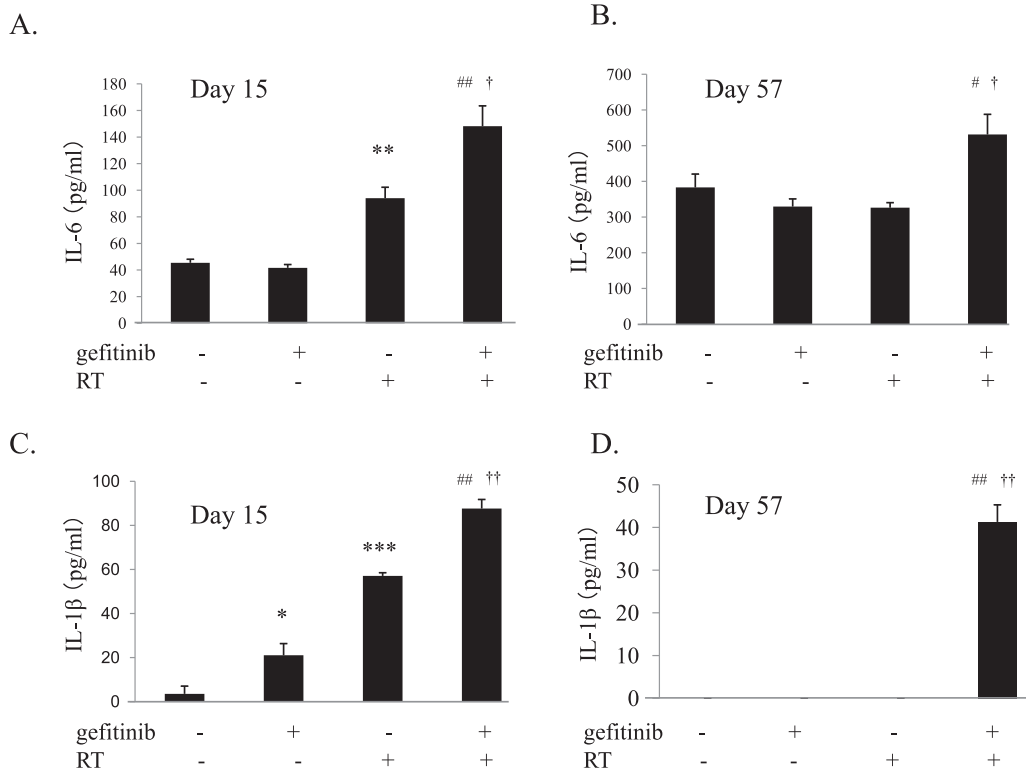


Figure 3. IL-6 (A; day 15, B; day 57) and IL-1β (C; day 15, D; day 57) expression from the BAL cells. Data are presented as mean ± SEM. \**p* < 0.01, \*\**p* < 0.005 and \*\*\**p* < 0.0001 vs. vehicle plus no RT, #*p* < 0.005 and ##*p* < 0.0001 vs. gefitinib plus no RT, and †*p* < 0.005 and ††*p* < 0.0001 vs. vehicle plus RT.

*Histological examination*

Lung histology showed increased inflammatory cell infiltration in the lungs on day 15, and severe lung fibrosis including collagen deposition on day 57 in the irradiated rats without gefitinib treatment (Figure 4A). The collagen content of the lung was significantly lower in irradiated rats with gefitinib

treatment compared to the rats without gefitinib treatment (Figure 4B).

*The proliferation of the lung fibroblasts*

The lung fibroblasts are well known to have the most central role in the process of pulmonary fibrosis due to their ability to produce collagen. Thus, we harvested the lung fibroblasts from the rats in

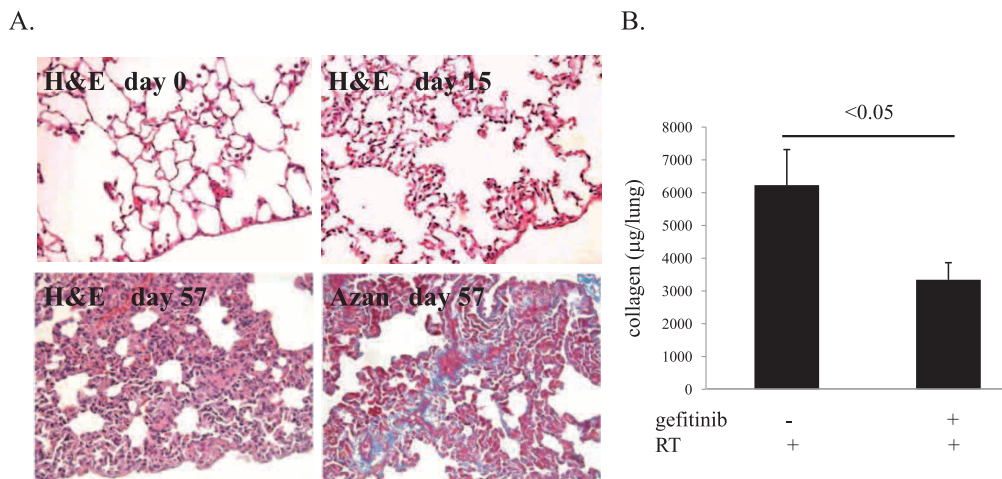


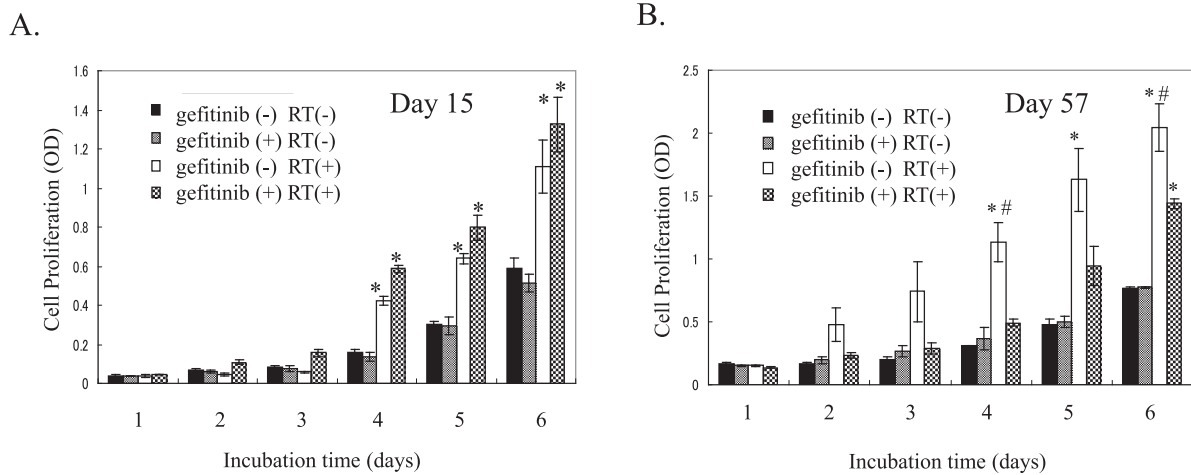
Figure 4. (A) Typical photomicrographs of H&E and Azan staining of the lungs from irradiated rats without gefitinib treatment on day 15 or 57 after irradiation. Magnification × 400. (B) Collagen content of the lungs from irradiated rats with or without gefitinib treatment on day 57 by Sircol collagen assay. Data are presented as mean ± SEM. n=5-6.

each experimental group and compared their proliferation by MTT assay. The proliferation of lung fibroblasts from the irradiated rats was significantly increased to a greater extent than those from the unirradiated rats on days 15 and 57 expectedly. Gefitinib treatment for rats did not change the proliferation of lung fibroblasts from either irradiated and unirradiated rats on day 15, while gefitinib treatment for rats significantly decreased the proliferation of lung fibroblasts from irradiated rats on day 57 (Figure 5A, B).

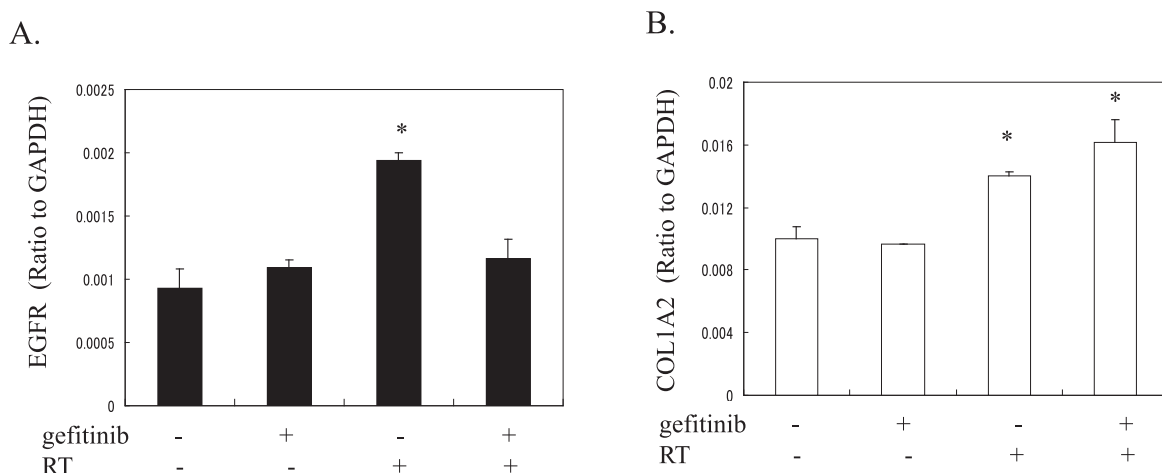
*The expression of EGFR and collagen in the lung fibroblasts*

To test whether gefitinib treatment for rats affects EGFR expression in the lung fibroblasts, we examined EGFR mRNA expression in the lung fibroblasts from the rats in each experimental group

on day 57 by quantitative RT-PCR. EGFR mRNA expressions were detectable in the lung fibroblasts derived from the rats in either experimental group. Although EGFR mRNA expression was enhanced by the irradiation, gefitinib treatment for rats significantly decreased EGFR mRNA expression in the lung fibroblasts from the irradiated rats (Figure 6A). To test whether gefitinib treatment for rats affects collagen production from the lung fibroblasts, we also examined COL1A2 mRNA expression in the lung fibroblasts from the rats in each experimental group by quantitative RT-PCR. Although COL1A2 mRNA expression in the lung fibroblasts from the irradiated rats was significantly greater than in those from the unirradiated rats, gefitinib treatment for rats did not decrease COL1A2 mRNA expression in the lung fibroblasts in either irradiated and unirradiated rats (Figure 6B).



**Figure 5.** The proliferation of the lung fibroblasts from each experimental group obtained on days 15 (A) and 57 (B). Data are presented as mean ± SEM. \**p* < 0.01 vs. vehicle plus no RT, and #*p* < 0.01 vs. gefitinib plus RT.



**Figure 6.** The expression of EGFR mRNA (A) and COL1A2 (B) mRNA in the lung fibroblasts from each experimental group on day 57. Data are presented as mean ± SEM. \**p* < 0.01 vs. vehicle plus no RT.

DISCUSSION

The expression and activity of EGFR are important determinants of radiation sensitivity in several cancers including NSCLC (26, 27). Irradiation of tumor cells has been shown to activate EGFR via ligand-dependent and ligand-independent mechanisms, possibly accounting for the radiation-induced acceleration of tumor cell repopulation and the development of radioresistance (27, 28). Such radiation-induced activation of EGFR-dependent processes provides a rationale for combined treatment with radiation and EGFR inhibitors. Although a series of recently published studies showed promising preclinical evidence regarding the capacity of EGFR inhibition to enhance the antitumor activity of ionizing radiation (16, 17), a feasibility to investigate the tolerability and safety of gefitinib combined with definitive TRT in patients with locally advanced NSCLC was closed early due to pulmonary toxicity (18). Moreover, the history of prior radiotherapy is known to be a predictive risk factor for ILD related to gefitinib (8). These findings suggest that gefitinib may enhance radiation-induced pulmonary toxicity, however, the mechanism how gefitinib affects radiation-induced pneumonitis and fibrosis has not been clarified. In this study, we sought to investigate the effect of gefitinib on different phases of radiation-induced lung disorders in an experimental model, and demonstrated that gefitinib augmented inflammation in the lungs, but attenuated the fibrotic lung remodeling in response to irradiation injury.

Radiation-induced lung disorder is characterized by interstitial edema, interstitial and alveolar inflammatory cell infiltration (11, 12), and subsequent fibrotic reaction characterized by the proliferation of fibroblasts and deposition of extracellular matrix (13). The recruitment and activation of inflammatory cells, such as neutrophils and lymphocytes, are central elements in the development of radiation-induced interstitial pneumonitis (22, 23, 29). Neutrophils are the first responding cells in lung tissues injured by irradiation (23). Lymphocytic alveolitis is a well-recognized component that occurs in response to tissue injury caused by irradiation, and a prominent feature of post-radiation lung injury is the development of lymphocytic alveolitis (19, 30). We have also shown the characteristic histological changes of lymphocytic alveolitis after irradiation (19, 22). In this study, the irradiated rats treated with gefitinib showed significantly lower body

weights than those treated without gefitinib on day 15. Moreover, gefitinib treatment increased the numbers of neutrophils and lymphocytes on day 15. These findings suggested that gefitinib augmented the extent of lung injury and interstitial pneumonitis caused by irradiation (Figure 7). On the other hand, gefitinib treatment decreased the number of neutrophils, but not that of lymphocytes on day 57. Gefitinib may have direct effects on the neutrophil population that are different from the early phase, or activated fibroblasts may affect the recruitment or proliferation of neutrophils in the late stage of fibrosis. The finding is a target of future experiment.

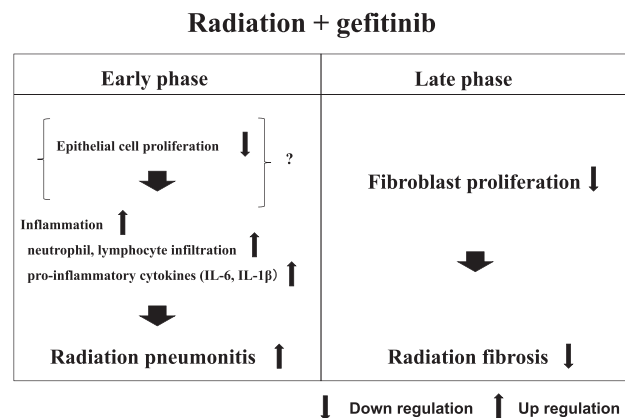


Figure 7. The effect of gefitinib on radiation injury of the lung.

Several lines of evidence have indicated the contribution of pro-inflammatory cytokines to the development of radiation-induced lung disorders (23, 24). Increases in IL-6 and IL-1β have been found during the course of the development of alveolitis in both patients and animal models (24, 25). In the present study, gefitinib treatment significantly increased the production of IL-6 and IL-1β from the BAL cells from the irradiated rats in both the early (day 15) and late phases (day 57) of radiation-induced lung disorders, indicating that gefitinib increased the production of pro-inflammatory cytokines, which might be responsible, at least in part, for the increased lung injury and inflammation induced by irradiation.

The mechanism responsible for the increased inflammation induced by gefitinib in radiation-induced lung disorders is uncertain. Gefitinib has been shown to inhibit the proliferation of EGFR-expressing cells such as alveolar epithelial cells, resulting in the inhibition of the anti-inflammatory response by these



cells following lung injury (31). Therefore, our results suggest that EGFR inhibition for epithelial cells by gefitinib might suppress normal repair from tissue injuries caused by irradiation, leading to prolonged inflammation.

Although severe alveolar injury induced by a variety of agents has been shown to disturb normal epithelial-fibroblast interactions, resulting in excessive collagen production and the development of pulmonary fibrosis (32, 33), the present study showed collagen content of the lung was decreased in spite of the increased inflammation in the lung of irradiated rats with gefitinib, which indicates that gefitinib attenuates radiation-induced lung fibrosis. The EGFR and its ligands are known to have an important role in the pathogenesis of pulmonary fibrosis. The EGFR expression was reported to be increased in the lung by bleomycin-induced lung injury in rats (34). Transforming growth factor- $\alpha$  (TGF- $\alpha$ ) was also increased in the lung of idiopathic pulmonary fibrosis (35), and TGF- $\alpha$  knockout mice displayed significantly reduced lung collagen accumulation following bleomycin-induced injury (36). In the present study, increased EGFR expression and faster proliferation were found in fibroblasts from the irradiated rats than in those from the unirradiated rats. However, gefitinib treatment decreased the EGFR expression and the proliferation in fibroblasts from the irradiated rats, suggesting that the decreased response to growth factors due to the down-regulation of EGFR by gefitinib treatment resulted in decreasing the proliferative ability of lung fibroblasts. The decreased proliferative ability in lung fibroblasts from the irradiated rats with gefitinib treatment may explain the finding that gefitinib treatment attenuated radiation-induced lung fibrosis. Our result is supported by a previous study reported by Wang *et al*, in which a high dose (200 mg/kg/day) of gefitinib administered during the late phase (days 14 to 19) reduced fibrosis score and collagen levels in the lungs of irradiated mice, but the administration during acute phase (days 0 to 5) and the low dose administration during late phase did not (37).

A study by Suzuki *et al* reported that gefitinib treatment augment lung fibrosis in BLM-treated mice and that gefitinib did not inhibit the proliferation of lung fibroblasts *in vitro* experiments (31), which are not consistent with the results reported by Wang *et al* and our findings that gefitinib treatment attenuated lung fibrosis in irradiated rats and that gefitinib treatment for rats decreased the proliferative ability of lung fibroblasts from the irradiated

rats. These results suggest that EGFR inhibitor may have conflict functions in lung fibrosis development, which may depend on which cell type is regulated by gefitinib. Inhibition of fibroblast proliferation may attenuate lung fibrosis, while inhibition of epithelial cell proliferation may augment lung fibrosis. The discrepancy between these studies may depend on the difference in the experimental systems, including the use of the BLM model in the Suzuki *et al* study and the RT model in Wang's and our studies. Lung injury induced by a single dose of irradiation might be mild for a drug intervention experiment. In addition, in this experimental model, chronic lung injury and fibrosis were longer lasting than in BLM model, in which lung fibrosis development may depend on fibroblast activation dominantly rather than decreased epithelial integrity. However, further studies are necessary to clarify the mechanism of the different effect of gefitinib treatment in lung fibrosis development in each experimental model.

Gefitinib treatment changed the proliferative ability of lung fibroblasts, while the treatment did not change the collagen production ability of lung fibroblasts, which suggests that gefitinib treatment does not affect fibroblast differentiation into myofibroblast. Therefore, the decreased collagen content in the lungs of irradiated rats with gefitinib treatment may depend on the decreased number of lung fibroblasts due to the decreased proliferative ability.

A phase I study designed to assess the safety of concomitant cetuximab, a monoclonal antibody that binds EGFR and radical RT in patients with inoperable Stage III NSCLC showed that the early and late toxicities of concomitant cetuximab and radical RT were acceptable (38). An ongoing radiation therapy oncology group (RTOG) trial, RTOG 0324, is evaluating the combination of cetuximab with RT in unresectable stage III NSCLC patients (38). The interim analysis showed improvement in overall survival (OS) compared to historical controls (response rate 62% (n=54), median survival 22.7 months and 2-year OS of 49.3%). In our study, gefitinib treatment has augmented interstitial pneumonitis and inflammation in the lungs especially on early phase in rats. Administration of gefitinib concurrent with thoracic irradiation might be harmful by increasing the risk of pneumonitis. Gefitinib treatment combined with definitive TRT for patients with locally advanced NSCLC had better be avoided due to its greater risk of pulmonary toxicity. Sequential gefitinib treatment after thoracic irradiation should be also considered carefully, but might be acceptable and useful for

patients with locally advanced NSCLC, when considering the safety of cetuximab combined with RT and our finding of anti-fibrotic effect of gefitinib in RT model on late phase. When we try sequential gefitinib treatment after thoracic irradiation, the interval until gefitinib treatment after irradiation may be essential, and a clinical trial should be planned. In addition, it is a future experiment in animal model whether sequential gefitinib treatment after irradiation is acceptable and useful.

In summary, the present study demonstrated that gefitinib treatment augmented interstitial pneumonitis, but attenuated fibrotic lung remodeling in response to irradiation injury. Gefitinib treatment concurrent with thoracic irradiation had better be avoided due to its greater risk of pulmonary toxicity, while sequential gefitinib treatment after thoracic irradiation might be acceptable and useful for patients with locally advanced NSCLC.

## CONFLICT OF INTEREST

None of the authors have any conflicts of interest to declare.

## ACKNOWLEDGMENTS

This work was supported in part by a Grant-in-Aid for Scientific Research (B) from the Ministry of Education, Culture, Sports, Science and Technology (MEXT), Japan (Y.N.), and a grant to the Diffuse Lung Diseases Research Group from the Ministry of Health, Labour and Welfare, Japan (Y.N.).

## REFERENCES

1. Jemal A, Siegel R, Ward E, Hao Y, Xu J, Thun MJ. Cancer statistics, 2009. *CA Cancer J Clin* 59(4) : 225-49, 2009
2. Kelly K, Crowley J, Bunn PA, Jr., Presant CA, Grevstad PK, Moinpour CM, Ramsey SD, Wozniak AJ, Weiss GR, Moore DF, Israel VK, Livingston RB, Gandara DR. Randomized phase III trial of paclitaxel plus carboplatin versus vinorelbine plus cisplatin in the treatment of patients with advanced non--small-cell lung cancer : a Southwest Oncology Group trial. *J Clin Oncol* 19(13) : 3210-8, 2001
3. Schiller JH, Harrington D, Belani CP, Langer C, Sandler A, Krook J, Zhu J, Johnson DH. Comparison of four chemotherapy regimens for advanced non-small-cell lung cancer. *N Engl J Med* 346(2) : 92-8, 2002
4. Mok TS, Wu YL, Thongprasert S, Yang CH, Chu DT, Saijo N, Sunpaweravong P, Han B, Margono B, Ichinose Y, Nishiwaki Y, Ohe Y, Yang JJ, Chewaskulyong B, Jiang H, Duffield EL, Watkins CL, Armour AA, Fukuoka M. Gefitinib or carboplatin-paclitaxel in pulmonary adenocarcinoma. *N Engl J Med* 361(10) : 947-57, 2009
5. Camus P, Kudoh S, Ebina M. Interstitial lung disease associated with drug therapy. *Br J Cancer* 91 Suppl 2 : S18-23, 2004
6. Inoue A, Saijo Y, Maemondo M, Gomi K, Tokue Y, Kimura Y, Ebina M, Kikuchi T, Moriya T, Nukiwa T. Severe acute interstitial pneumonia and gefitinib. *Lancet* 361(9352) : 137-9, 2003
7. Takano T, Ohe Y, Kusumoto M, Tateishi U, Yamamoto S, Nokihara H, Yamamoto N, Sekine I, Kunitoh H, Tamura T, Kodama T, Saijo N. Risk factors for interstitial lung disease and predictive factors for tumor response in patients with advanced non-small cell lung cancer treated with gefitinib. *Lung Cancer* 45(1) : 93-104, 2004
8. Hotta K, Kiura K, Tabata M, Harita S, Gemba K, Yonei T, Bessho A, Maeda T, Moritaka T, Shibayama T, Matsuo K, Kato K, Kanehiro A, Tanimoto Y, Ueoka H, Tanimoto M. Interstitial lung disease in Japanese patients with non-small cell lung cancer receiving gefitinib : an analysis of risk factors and treatment outcomes in Okayama Lung Cancer Study Group. *Cancer J* 11(5) : 417-24, 2005
9. Mehta V. Radiation pneumonitis and pulmonary fibrosis in non-small-cell lung cancer : pulmonary function, prediction, and prevention. *Int J Radiat Oncol Biol Phys* 63(1) : 5-24, 2005
10. Gross NJ. Pulmonary effects of radiation therapy. *Ann Intern Med* 86(1) : 81-92, 1977
11. Guerry-Force ML, Perkett EA, Brigham KL, Meyrick B. Early structural changes in sheep lung following thoracic irradiation. *Radiat Res* 114(1) : 138-53, 1988
12. Gross NJ, Narine KR, Colletti-Squinto L. Replicative activity of lung type 2 cells following lung X irradiation. *Radiat Res* 111(1) : 143-50, 1987
13. Vergara JA, Raymond U, Thet LA. Changes in

- lung morphology and cell number in radiation pneumonitis and fibrosis : a quantitative ultrastructural study. *Int J Radiat Oncol Biol Phys* 13(5) : 723-32, 1987
14. Furuse K, Fukuoka M, Kawahara M, Nishikawa H, Takada Y, Kudoh S, Katagami N, Ariyoshi Y. Phase III study of concurrent versus sequential thoracic radiotherapy in combination with mitomycin, vindesine, and cisplatin in unresectable stage III non-small-cell lung cancer. *J Clin Oncol* 17(9) : 2692-9, 1999
  15. Pfister DG, Johnson DH, Azzoli CG, Sause W, Smith TJ, Baker S, Jr., Olak J, Stover D, Strawn JR, Turrisi AT, Somerfield MR. American Society of Clinical Oncology treatment of unresectable non-small-cell lung cancer guideline : update 2003. *J Clin Oncol* 22(2) : 330-53, 2004
  16. Chinnaiyan P, Huang S, Vallabhaneni G, Armstrong E, Varambally S, Tomlins SA, Chinnaiyan AM, Harari PM. Mechanisms of enhanced radiation response following epidermal growth factor receptor signaling inhibition by erlotinib (Tarceva). *Cancer Res* 65(8) : 3328-35, 2005
  17. Huang SM, Li J, Armstrong EA, Harari PM. Modulation of radiation response and tumor-induced angiogenesis after epidermal growth factor receptor inhibition by ZD1839 (Iressa). *Cancer Res* 62(15) : 4300-6, 2002
  18. Okamoto I, Takahashi T, Okamoto H, Nakagawa K, Watanabe K, Nakamatsu K, Nishimura Y, Fukuoka M, Yamamoto N. Single-agent gefitinib with concurrent radiotherapy for locally advanced non-small cell lung cancer harboring mutations of the epidermal growth factor receptor. *Lung Cancer* 72(2) : 199-204, 2010
  19. Huang L, Tani K, Ogushi F, Ogawa H, Shimizu T, Motoki Y, Moriguchi H, Sone S. Role of CD13/aminopeptidase N in rat lymphocytic alveolitis caused by thoracic irradiation. *Radiat Res* 157(2) : 191-8, 2002
  20. Tada H, Ogushi F, Tani K, Nishioka Y, Miyata JY, Sato K, Asano T, Sone S. Increased binding and chemotactic capacities of PDGF-BB on fibroblasts in radiation pneumonitis. *Radiat Res* 159(6) : 805-11, 2003
  21. Tani K, Yasuoka S, Ogushi F, Asada K, Fujisawa K, Ozaki T, Sano N, Ogura T. Thrombin enhances lung fibroblast proliferation in bleomycin-induced pulmonary fibrosis. *Am J Respir Cell Mol Biol* 5(1) : 34-40, 1991
  22. Huang L, Ogushi F, Tani K, Ogawa H, Kawano T, Endo T, Izumi K, Sono N, Ueno J, Nishitani H, Sone S. Thrombin promotes fibroblast proliferation during the early stages of experimental radiation pneumonitis. *Radiat Res* 156(1) : 45-52, 2001
  23. Chiang CS, Liu WC, Jung SM, Chen FH, Wu CR, McBride WH, Lee CC, Hong JH. Compartmental responses after thoracic irradiation of mice : strain differences. *Int J Radiat Oncol Biol Phys* 62(3) : 862-71, 2005
  24. Johnston CJ, Piedboeuf B, Rubin P, Williams JP, Baggs R, Finkelstein JN. Early and persistent alterations in the expression of interleukin-1 alpha, interleukin-1 beta and tumor necrosis factor alpha mRNA levels in fibrosis-resistant and sensitive mice after thoracic irradiation. *Radiat Res* 145(6) : 762-7, 1996
  25. Rube CE, Uthe D, Wilfert F, Ludwig D, Yang K, Konig J, Palm J, Schuck A, Willich N, Remberger K, Rube C. The bronchiolar epithelium as a prominent source of pro-inflammatory cytokines after lung irradiation. *Int J Radiat Oncol Biol Phys* 61(5) : 1482-92, 2005
  26. Harari PM, Huang SM. Epidermal growth factor receptor modulation of radiation response : preclinical and clinical development. *Semin Radiat Oncol* 12(3 Suppl 2) : 21-6, 2002
  27. Schmidt-Ullrich RK, Mikkelsen RB, Dent P, Todd DG, Valerie K, Kavanagh BD, Contessa JN, Rorrer WK, Chen PB. Radiation-induced proliferation of the human A431 squamous carcinoma cells is dependent on EGFR tyrosine phosphorylation. *Oncogene* 15(10) : 1191-7, 1997
  28. Lammering G, Hewit TH, Hawkins WT, Contessa JN, Reardon DB, Lin PS, Valerie K, Dent P, Mikkelsen RB, Schmidt-Ullrich RK. Epidermal growth factor receptor as a genetic therapy target for carcinoma cell radiosensitization. *J Natl Cancer Inst* 93(12) : 921-9, 2001
  29. Johnston CJ, Williams JP, Elder A, Hernady E, Finkelstein JN. Inflammatory cell recruitment following thoracic irradiation. *Exp Lung Res* 30(5) : 369-82, 2004
  30. Morgan GW, Breit SN. Radiation and the lung : a reevaluation of the mechanisms mediating pulmonary injury. *Int J Radiat Oncol Biol Phys* 31(2) : 361-9, 1995
  31. Suzuki H, Aoshiba K, Yokohori N, Nagai A. Epidermal growth factor receptor tyrosine kinase inhibition augments a murine model of

- pulmonary fibrosis. *Cancer Res* 63(16) : 5054-9, 2003
32. Adamson IY, Young L, Bowden DH. Relationship of alveolar epithelial injury and repair to the induction of pulmonary fibrosis. *Am J Pathol* 130(2) : 377-83, 1988
  33. Madtes DK, Rubenfeld G, Klima LD, Milberg JA, Steinberg KP, Martin TR, Raghu G, Hudson LD, Clark JG. Elevated transforming growth factor-alpha levels in bronchoalveolar lavage fluid of patients with acute respiratory distress syndrome. *Am J Respir Crit Care Med* 158(2) : 424-30, 1998
  34. Madtes DK, Busby HK, Strandjord TP, Clark JG. Expression of transforming growth factor-alpha and epidermal growth factor receptor is increased following bleomycin-induced lung injury in rats. *Am J Respir Cell Mol Biol* 11(5) : 540-51, 1994
  35. Baughman RP, Lower EE, Miller MA, Bejarano PA, Heffelfinger SC. Overexpression of transforming growth factor-alpha and epidermal growth factor-receptor in idiopathic pulmonary fibrosis. *Sarcoidosis Vasc Diffuse Lung Dis* 16(1) : 57-61, 1999
  36. Madtes DK, Elston AL, Hackman RC, Dunn AR, Clark JG. Transforming growth factor-alpha deficiency reduces pulmonary fibrosis in transgenic mice. *Am J Respir Cell Mol Biol* 20(5) : 924-34, 1999
  37. Wang C, Abe S, Matsuda K, Yu C, Li Y, Usuki J, Azuma A, Kudoh S. Effects of gefitinib on radiation-induced lung injury in mice. *J Nippon Med Sch* 75(2) : 96-105, 2008
  38. Aggarwal C, Borghaei H. Rational use of cetuximab in the treatment of advanced non-small cell lung cancer. *Onco Targets Ther* 2 : 251-60, 2009