

CASE REPORT

Anterior thoracolumbar reconstruction surgery for late collapse following vertebroplasty : report of three cases

Ryo Miyagi^{1,2}, Toshinori Sakai^{3,4}, Nitin N. Bhatia⁴, Koichi Sairyo³, Shinsuke Katoh³, and Takashi Chikawa¹

¹Department of Orthopedic Surgery, Tokushima Municipal Hospital, Tokushima, Japan ; ²Department of Orthopedic Surgery, Kaminaka Hospital, Tokushima, Japan ; ³Department of Orthopedics, Institute of Health Biosciences, the University of Tokushima Graduate School, Tokushima, Japan ; and ⁴Department of Orthopedic Surgery, University of California, Irvine, California, USA

Abstract : Although vertebroplasty (VP) using polymethylmethacrylate (PMMA) is thought to be an effective procedure for osteoporotic vertebral compression fractures, several complications have been reported. In this paper, we present three patients who developed local kyphotic deformity as a result of late collapse of the cemented vertebrae. In all patients we safely removed the PMMA block through an anterior approach and anterior reconstruction was performed successfully. In only one patient who had a three column unstable injury with fractured posterior elements was additional posterior spinal fixation needed. In conclusion, VP is thought to be an effective and minimal invasive technique to treat osteoporotic compression fractures in older patients. Once collapse or nonunion of the treated vertebral body occurs, however, removal of the cement and anterior reconstruction may be required to realign of the affected segments and reconstruct the spine. *J. Med. Invest.* 58 : 148-153, February, 2011

Keywords : *compression fracture, vertebroplasty, salvage procedure, polymethylmethacrylate (PMMA)*

INTRODUCTION

Vertebroplasty (VP) with polymethylmethacrylate (PMMA) bone cement was introduced by Galibert *et al.* (1) and has been used extensively in the treatment of osteoporotic spine fracture. Although VP is thought to be a safe and effective procedure for symptomatic osteoporotic vertebral compression fractures, several complications have been reported. Complications that can occur during the acute time

period include leakage of cement into the spinal canal, adjacent discs, paravertebral soft tissues, or perivertebral venous system, and pulmonary embolism (2-7). As delayed complications, adjacent vertebral fracture, nerve root injury, cement dislodgement, and subsequent pyogenic spondylitis have been described (7-14). As a result of these complications, salvage procedures such as on urgent spinal cord decompression may need to be performed (2-7), and these procedures have been described in the literature. Procedures for salvage of late collapse of the cemented vertebra, however, are controversial (10-15).

In this paper, we present three patients who developed local kyphotic deformity with severe back pain and paralysis as the result of late collapse of

Received for publication October 18, 2010 ; accepted November 11, 2010.

Address correspondence and reprint requests to Takashi Chikawa, MD, PhD, Department of Orthopedic Surgery, Tokushima Municipal Hospital, 2-34 Kitajosanjima-cho, Tokushima 770-0812, Japan and Fax : +81-88-622-5313.

the cemented vertebrae, and we discuss their treatment with anterior thoracolumbar reconstruction surgery for this late collapse following VP.

CASE REPORT

CASE 1

History

An 81-year-old woman with a symptomatic L1 osteoporotic compression fracture underwent VP using PMMA in another hospital. Her back pain was relieved immediately after the VP. Twenty months later, however, her back pain recurred suddenly with no traumatic episode. She was unable to walk due to the pain and associated muscle weakness with bilateral lower extremity paresthesias.

Radiological findings

Radiographs on admission revealed an L1 compression fracture that had been treated with VP with PMMA placement. A local kyphotic deformity (Cobb angle : 29°) was identified (Figure 1). Computed tomography (CT) scans demonstrated a vacuum cleft around the PMMA (Figure 2).

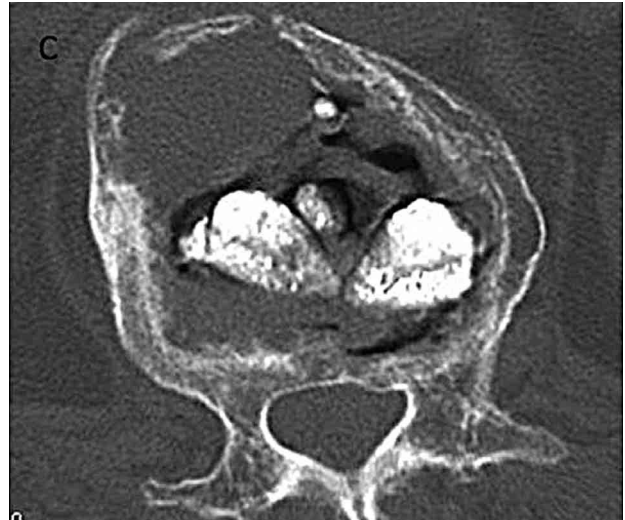

Figure 2 CT scan demonstrating vacuum clefts around the PMMA in the L1 vertebral body.

Surgery

Removal of the PMMA and anterior spinal reconstruction was performed using retroperitoneal approach. The PMMA was found to be covered with fibrous tissue and was easily removed without retraction of the dura mater. After removal of

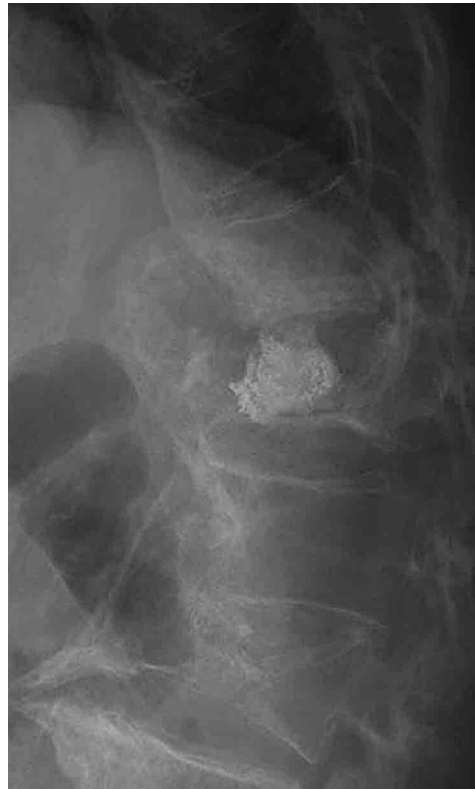
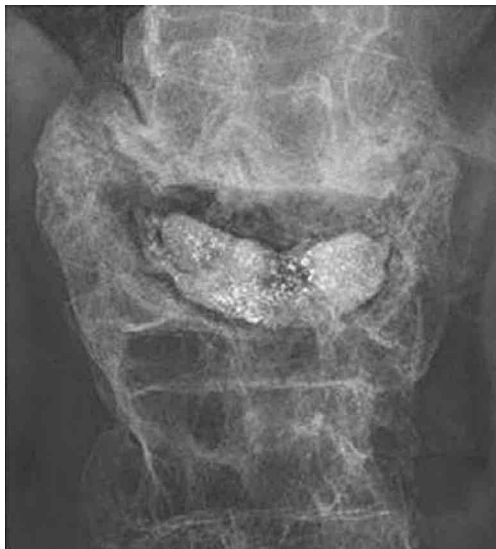
Figure 1 Plain radiographs showing a compression fracture of L1 treated by VP with PMMA implantation. Note the radiolucent area around the PMMA and the local kyphotic deformity (Cobb angle : 29°).

the PMMA and curettage of the fibrous tissue, correction of the kyphotic deformity was achieved using a metal cage filled with autologous bone graft, and an anterior thoracolumbar plate was placed (Figure 3). The local kyphosis improved from 29° to 17°.

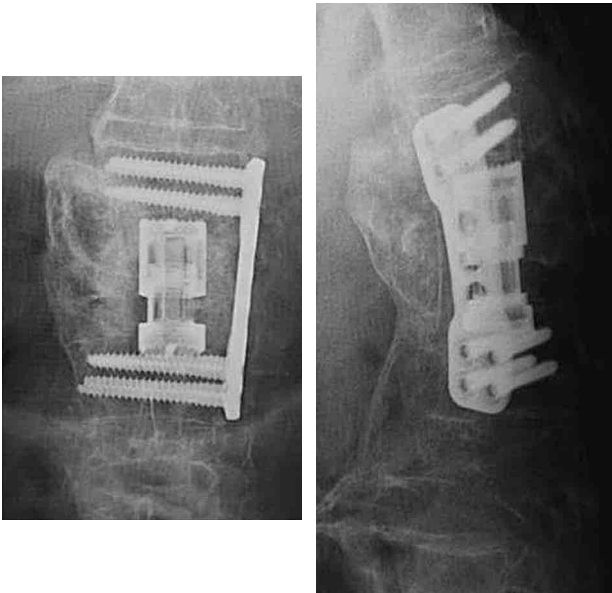


Figure 3 Postoperative plain radiographs showing improved local kyphosis (Cobb angle : 17°).

Postoperative Course

After the salvage operation, the patient's symptoms were immediately relieved. Four months postoperatively, bony union was achieved with a slight loss of the sagittal correction (5°).

CASE 2

History

A 73-year-old woman with severe back pain from a T12 osteoporotic compression fracture underwent VP using PMMA in another hospital. Three months after the VP, she developed recurrent severe back pain without a traumatic episode and was not able to walk due to pain and muscle weakness in both legs.

Radiological findings

Radiographs revealed compression fracture of T12 with retention of the VP PMMA. A local kyphotic deformity of the thoracolumbar junction (Cobb angle : 33°) was identified (Figure 4). On the CT scans, extravasation of PMMA cement into the vertebral canal was found (Figure 5).

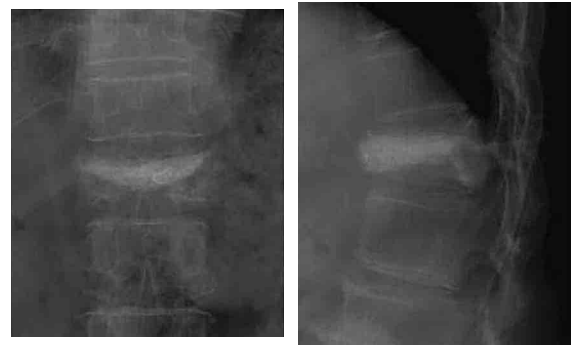


Figure 4 Plain radiographs showing compression fracture of T12 with implantation of PMMA and local kyphotic deformity of the thoracolumbar junction (Cobb angle : 33°).

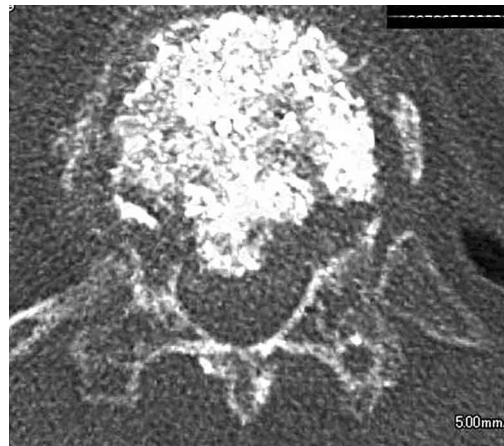

Figure 5 CT scans showing extravasation of PMMA cement into the vertebral canal.

Surgery

Removal of the PMMA and anterior spinal reconstruction was performed using a retroperitoneal approach. The PMMA was covered with fibrous tissue and was removed easily without retraction of the dura mater. After removal of the PMMA and curettage of the fibrous tissue, correction of the kyphotic deformity using a metal cage filled with autologous bone graft, and anterior plate was placed (Figure 6).

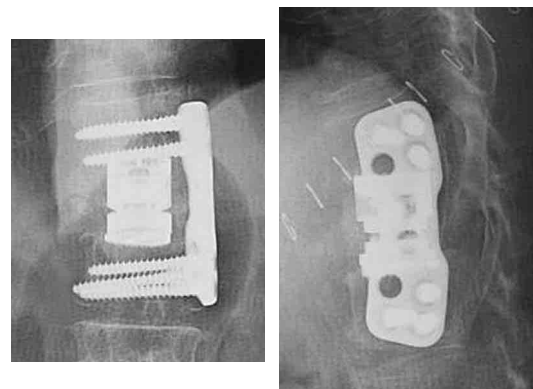


Figure 6 Postoperative plain radiographs showing improved local kyphosis (Cobb angle : 22°).

The local kyphotic deformity was improved from 33° to 22°.

Postoperative Course

After the revision surgery, the patient’s symptoms improved, and she had full resolution of her pre-operative symptoms. Six months post-operatively, radiographs revealed solid bony union of the surgical site with a mild loss of correction (3°).

CASE 3

History

A 73-year-old woman with an osteoporotic burst fracture-dislocation of L3 underwent VP using PMMA at an outside institution. One week later, she developed recurrent severe back pain and leg pain without a traumatic episode. She could not ambulate due to her lower extremity weakness, and she was referred to our facility for evaluation and treatment.

Admission radiographs revealed a split fracture of the L3 vertebral body and lamina, with associated bilateral pedicle fractures (Figure 7, 8).

Surgery

A three stage, posterior-anterior-posterior, surgery was performed. During the first stage, a total laminectomy of L3 was performed followed by insertion of pedicle screws. Because of the patient’s poor bone quality and significant instability, it was felt that the patient would require anterior column reconstruction and fixation. We removed the PMMA mass during an anterior L3 corpectomy as part of the second stage. Also during this second stage, the dislocation was reduced, a metal cage filled with autologous iliac bone was inserted, and an anterior plate and screws were placed. The final stage consisted of another posterior approach during which rods were placed, and the pedicle screws were locked into position (Figure 9).

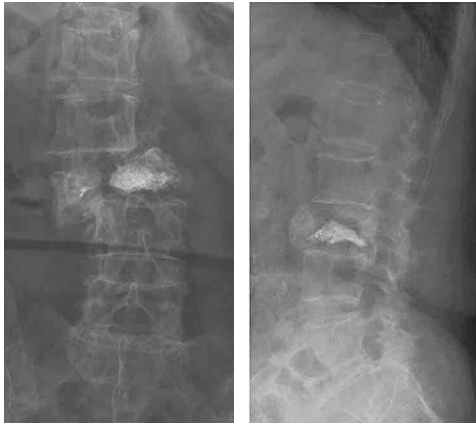


Figure 7 Plain radiographs revealing a fracture-dislocation of L3 and PMMA cement in the vertebral body.

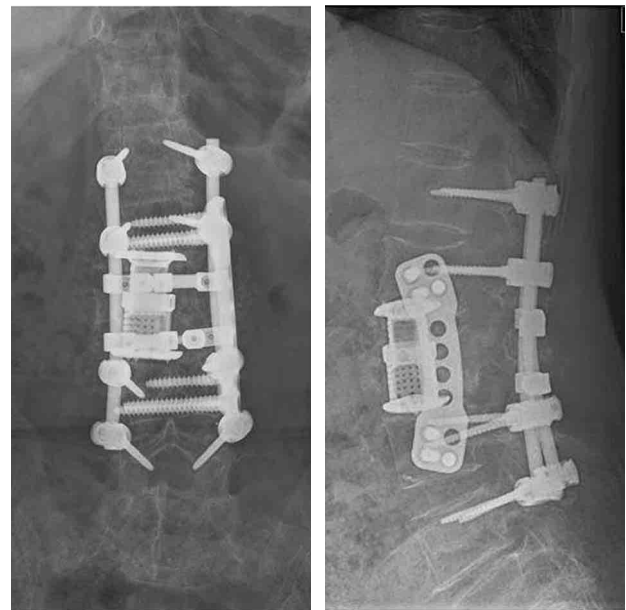


Figure 9 Postoperative plain radiographs showing the reconstructed lumbar spine.

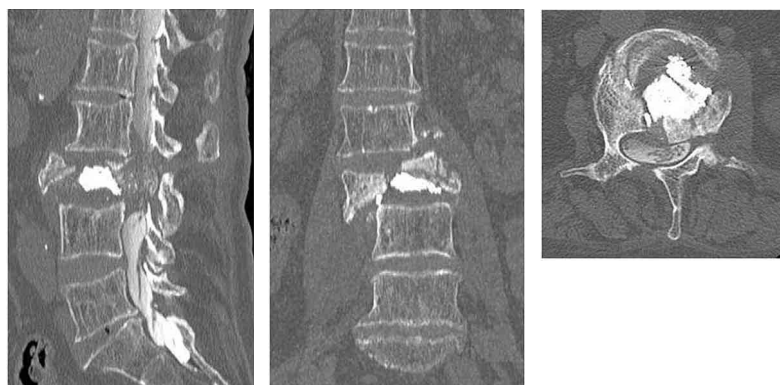


Figure 8 Reconstructed CT scans revealing the fractures of the vertebral body, bilateral pedicles, and lamina.

Postoperative Course

After the operation, the patient's weakness in both legs improved and her pain was relieved. One year post-operatively, radiographs revealed bony union with stable fixation and reduction of the fracture-dislocation.

DISCUSSION

Vertebroplasty (VP), and the similar procedure kyphoplasty, is considered as a minimally invasive procedure, and it is generally performed for older patients who have sustained an osteoporotic compression fracture. Perioperative complications of these procedures such as leakage of cement into the spinal canal, dislocation of the cement, osteonecrosis, and thermal nerve root injury due to the exothermic reaction involved in PMMA cement polymerization, and pulmonary embolism have been reported (2-7). Delayed complications may include adjacent vertebral body fracture, cement dislodgement or fragmentation, and late collapse of the cemented vertebrae due to nonunion of the fracture site (7-14). Once the postoperative complication has occurred, patients may require a more invasive additional surgery to correct the initial and subsequent pathology.

Several salvage procedures for VP have been described. These revision surgeries include repeat VP, anterior surgery, posterior surgery, and combined anterior and posterior spinal reconstructions (11-14). Yang *et al.* recommended repeat VP as the first choice surgery, especially for patients in whom a unipedicular approach was initially used (11). In their study, however, not all of the failed VP patients could be successfully treated with another VP. For example, a repeat VP is difficult in patients in whom the bipedicular approach was initially used, and some patients require revision surgeries through anterior, posterior, or combined approaches due to more significant instability or collapse. In all of our cases, the bipedicular approach was used during the index procedure.

Removal of the implanted cement may be required if there is significant failure of the vertebral body segment following VP. Shapiro *et al.* described use of the posterior approach to the lumbar spine for removal of the extravasated PMMA cement while retracting the thecal sac and nerve roots (14). Wu *et al.* suggested removing the cement using

subtraction osteotomy of the pedicles which were already perforated during the VP (15). In cases with abundant cement, however, it may be difficult to remove the cement safely through only the posterior approach, especially at or above the level of the conus medullaris. Furthermore, to obtain good bony union and to correct any kyphotic deformity, complete removal of the bone cement is mandatory. In our opinion, therefore, an anterior approach may be required for these cases. In the presented cases, we removed the PMMA block safely through an anterior approach. Only in one case, which involved a three-column unstable injury, was anterior and posterior fixation required.

Late collapse of the vertebral body treated by VP could be caused by osteonecrosis or delayed spondylodiscitis (16). Thermal necrosis due to the high temperature that occurs during the polymerization of PMMA or the development of fibrous tissue on the surface of the fractured cancellous bone could cause nonunion of the fracture site with subsequent collapse of the vertebral body (3, 15). Kim *et al.* also suggested that avascular necrosis of the vertebral body is closely related to the re-collapse of the vertebral body (17). All patients in our study suffered from re-collapse after the VP with an intervertebral vacuum cleft without a causative traumatic episode. This constellation of findings suggests that the patients in our study may have suffered from avascular necrosis of the vertebral body (18, 19), but our study is limited because no microscopic pathology specimens were obtained.

CONCLUSIONS

Vertebroplasty is thought to be an effective and minimally invasive technique to treat osteoporotic compression fractures in older patients. Once collapse or nonunion of the treated vertebral body occurs, however, removal of the cement and anterior reconstruction of the spinal column may be required to stabilize the fractured segment, correct malalignment of the spine, and prevent further neurologic deterioration.

REFERENCES

1. Galibert P, Deramond H, Rosat P, Le Gars D : Preliminary note on the treatment of vertebral angioma by percutaneous acrylic vertebroplasty.

- Neurochirurgie 33 : 166-168, 1987
2. Kim YJ, Lee JW, Park KW, Yeom JS, Jeong HS, Park JM, Kang HS : Pulmonary cement embolism after percutaneous vertebroplasty in osteoporotic vertebral compression fractures : incidence, characteristics, and risk factors. *Radiology* 251 : 250-259, 2009
 3. Schmidt R, Cakir B, Mattes T, Wegener M, Puhl W, Richter M : Cement leakage during vertebroplasty : an underestimated problem? *Eur Spine J* 14 : 466-473, 2005
 4. Layton KF, Thielen KR, Koch CA, Luetmer PH, Lane JI, Wald JT, Kallmes DF : Vertebroplasty, first 1000 levels of a single center : evaluation of the outcomes and complications. *AJNR Am J Neuroradiol* 28 : 683-689, 2007
 5. Laredo JD, Hamze B : Complications of percutaneous vertebroplasty and their prevention. *Skeletal Radiol* 33 : 493-505, 2004
 6. Mirovsky Y, Anekstein Y, Shalmon E, Blankstein A, Peer A : Intradiscal cement leak following percutaneous vertebroplasty. *Spine* 31 : 1120-1124, 2006
 7. Voormolen MH, Lohle PN, Juttman JR, van der Graaf Y, Fransen H, Lampmann LE : The risk of new osteoporotic vertebral compression fractures in the year after percutaneous vertebroplasty. *J Vasc Interv Radiol* 17 : 71-76, 2006
 8. Harrington KD : Major neurological complications following percutaneous vertebroplasty with polymethylmethacrylate : a case report. *J Bone Joint Surg Am* 83 : 1070-1073, 2001
 9. Yu SW, Chen WJ, Lin WC, Chen YJ, Tu YK : Serious pyogenic spondylitis following vertebroplasty--a case report. *Spine* 29 : 209-211, 2004
 10. Shin JH, Ha KY, Kim KW, Lee JS, Joo MW : Surgical treatment for delayed pyogenic spondylitis after percutaneous vertebroplasty and kyphoplasty. Report of 4 cases. *J Neurosurg Spine* 9 : 265-272, 2008
 11. Yang SC, Chen WJ, Yu SW, Tu YK, Kao YH, Chung KC : Revision strategies for complication and failure of vertebroplasties. *Eur Spine J* 17 : 982-988, 2008
 12. Tsai TT, Chen WJ, Lai PL, Chen LH, Niu CC, Fu TS, Wong CB : Polymethylmethacrylate cement dislodgment following percutaneous vertebroplasty : a case report. *Spine* 28 : 457-460, 2003
 13. Chen JK, Lee HM, Shih JT, Hung ST : Combined extraforaminal and intradiscal cement leakage following percutaneous vertebroplasty. *Spine* 32 : 358-362, 2007
 14. Shapiro S, Abel T, Purvines S : Surgical removal of epidural and intradural polymethylmethacrylate extravasation complicating percutaneous vertebroplasty for an osteoporotic lumbar compression fracture. Case report. *J Neurosurg* 98 : 90-92, 2003
 15. Wu CC, Lin MH, Yang SH, Chen PQ, Shih TT : Surgical removal of extravasated epidural neuroforaminal polymethylmethacrylate after percutaneous vertebroplasty in the thoracic spine. *Eur Spine J* 16 : 326-331, 2007
 16. Heo DH, Chin DK, Yoon YS, Kuh SU : Recollapse of previous vertebral compression fracture after percutaneous vertebroplasty. *Osteoporos Int* 20 : 473-480, 2009
 17. Kim HW, Kwon A, Lee MC, Song JW, Kim SK, Kim IH : The retrieval of percutaneous vertebroplasty for the treatment of vertebral compression fracture. *J Korean Neurosurg Soc* 47 : 278-281, 2010
 18. Mirovsky Y, Anekstein Y, Shalmon E, Peer A : Vacuum clefts of the vertebral bodies. *AJNR Am J Neuroradiol* 26 : 1634-1640, 2005
 19. Lane JI, Maus TP, Wald JT, Thielen KR, Bobra S, Luetmer PH : Intravertebral clefts opacified during vertebroplasty : pathogenesis, technical implications, and prognostic significance. *AJNR Am J Neuroradiol* 23 : 1642-1646, 2002