

CASE REPORT

General anesthesia for electroconvulsive therapy with Brugada electrocardiograph pattern

Yasuo M. Tsutsumi¹, Yoshinobu Tomiyama², Yousuke T. Horikawa¹, Yoko Sakai³, Naohiro Ohshita³, Katsuya Tanaka¹, and Shuzo Oshita¹

¹Department of Anesthesiology, Institute of Health Bioscience, the University of Tokushima Graduate School, ²Division of Surgical Center, Tokushima University Hospital, and ³Department of Anesthesiology, Tokushima University Hospital, Tokushima, Japan

Abstract : Brugada syndrome is characterized by an electrocardiograph pattern of right bundle-branch block and has an increased risk for cardiac arrest due to malignant arrhythmia. We describe the successful anesthetic management for electroconvulsive therapy in a patient with Brugada electrocardiograph pattern. Patients with Brugada ECG pattern are not recommended to use neostigmine which augments ST elevation. Sugammadex was administered as a neuromuscular reversal agent in this case. Sugammadex provides rapid reversal of profound rocuronium-induced neuromuscular blockade under propofol anesthesia. J. Med. Invest. 58 : 273-276, August, 2011

Keywords : *electroconvulsive therapy, ECT, Brugada electrocardiograph pattern*

INTRODUCTION

Brugada syndrome is an inherited cardiac disorder initially described in 1992 by Pedro and Josep Brugada (1). It is traditionally identified by electrocardiograph (ECG) and is defined by right bundle-branch block and ST segment elevation in the right precordial leads (V1-V3), without evidence of any underlying structural heart disease. Other symptoms can include : ventricular arrhythmias, syncope, and sudden death (1, 2). The genetic abnormalities that cause Brugada syndrome have been linked to mutation in the ion channel genes which encodes the α -subunit of the cardiac sodium channel (3). General anesthetic management with Brugada syndrome is limited, however, careful anesthetic management is important to avoid inducing malignant

arrhythmias (4-7).

Electroconvulsive therapy (ECT) has an important role in the treatment of severe and medication-resistant major depression, mania, schizophrenia and related psychotic disorders (8). When an electrical current is applied to the brain via transcutaneous electrodes, the resultant electroencephalographic (EEG) spike and wave activity is accompanied by a generalized tonic-clonic motor seizure and acute cardiovascular response (8). The typical cardiovascular response to ECT consists of transient tachycardia and hypertension lasting approximately 5 minutes. The cardiovascular response is associated with the release of catecholamine and occasional cardiac arrhythmias (9). This case report presents the general anesthetic management used for a patient with Brugada ECG pattern for a series of ECT.

Received for publication June 6, 2011 ; accepted August 5, 2011.

Address correspondence and reprint requests to Yasuo M. Tsutsumi, MD, PhD, Department of Anesthesiology, Institute of Health Bioscience, the University of Tokushima Graduate School, 3-18-15 Kuramoto, Tokushima 770-8503, Japan and Fax : +81-88-633-7182.

CASE DESCRIPTION

A 61 year old male patient, 176 cm, 48 kg was

scheduled for a series of ECT for severe major depression. The patient was disoriented to place, apathetic, poriomania, consciousness disorder, and needed intravenous alimentation for lack of oral intake. Several adequate medical treatments had been tried, however, were ineffective. The most recent pharmacologic regimen for the treatment of his mental disorder was 0.25 mg brotizoram, 5 mg levomepromazine, 10 mg paroxetine, and 0.4 mg alprazolam. Due to the patient's current neurological state, written consent was obtained from the patient's family.

On preoperative investigation, he had a 12-lead ECG showing an incomplete right bundle block and ST segment elevation in the precordial leads (Figure 1). The patient had no history of cardiac symptoms like arrhythmias or syncope, however, his sister died suddenly due to unknown cardiac events. Pre-operative echocardiography was normal and the patient was diagnosed with Brugada ECG pattern (type 2) by a licensed cardiologist.

His medical history included diabetes mellitus with diet therapy, and hemorrhoidectomy which had been performed under local anesthesia 19 years before. Preoperative blood analysis and serum electrolytes were all within normal limits.

The patient was anesthetized for each ECT, totaling ten events within 20 days. Electrocardiography, blood pressure, pulse oximetry, body temperature and neuromuscular transmission at the adductor pollicis muscle using acceleromyography or train

of four (TOF) were monitored. The number of responses to the TOF stimuli indicates the degree of neuromuscular blockade (10). Four twitches (T4) of the TOF response mean to be able to move, three twitches (T3) indicate intermediate acting muscle relaxant, two twitches (T2) are suitable for short term relaxation with approximate 80% of receptors blocked, and one twitch (T1) and twitches absent (T0) of the TOF are conditions for intubation or long term mechanical ventilation. Each time, body temperature was maintained and general anesthesia was induced with intravenous propofol (50 mg), followed by rocuronium (50 mg) after loss of consciousness and the ventilation was assisted using a face mask and 100% oxygen. An arterial tourniquet was applied to the left leg of the patient to isolate the left leg for motor seizure duration. An electrical stimulus was delivered via bitemporal electrodes. The duration of motor seizure was recorded as the time from the electrical stimulus to cessation of tonic-clonic motor activity in the isolated leg. Sugammadex (4 mg/kg) was administered to reverse neuromuscular block while monitoring TOF at the appearance of T2. Spontaneous breathing returned immediately and T4 of the TOF were appeared. The patient was hemodynamically stable and ECT was performed safely and effectively in all treatments.

DISCUSSION

Anesthetic management of a patient with Brugada ECG pattern deserves careful preoperative evaluation and is essential to avoid inducing malignant arrhythmia. Sodium channel blockers such as procainamide and flecainide are contraindicated in the patients with Brugada ECG pattern (2). Additionally, neostigmine and α -agonists augment ST elevation without coronary spasm (11). Therefore, class IA anti-arrhythmic drugs should be avoided and special caution should be exercised when neostigmine and α -agonists are used (4-7).

There is one case report on a patient without previously known cardiac abnormalities, who developed asystole during ECT and was later diagnosed with Brugada syndrome. In that case, it is uncertain whether Brugada syndrome was the causative factor of asystole under ECT although the investigators did feel that Brugada was a risk factor when determining whether ECT was the most appropriate therapy (12). As a result, ECT in this patient was

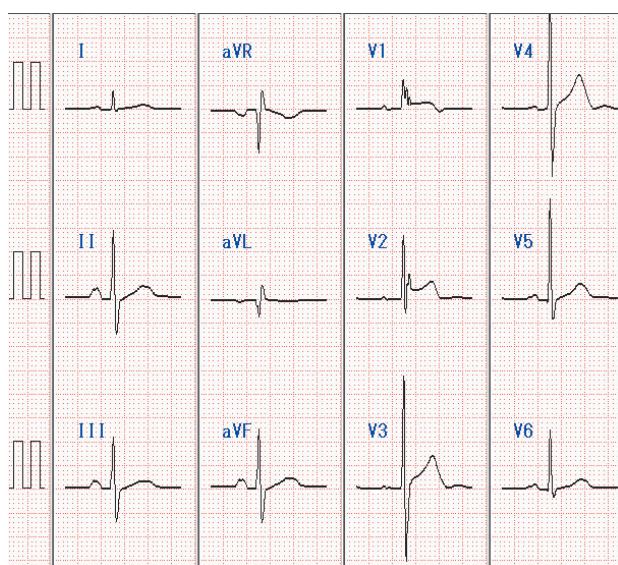


Figure 1 : A 12-lead ECG with an incomplete right bundle block and ST segment elevation in the precordial leads (V1 to V2).

decided carefully as adequate intensity and length of seizure is required for effective ECT (13), which likely would result in transient tachycardia and hypertension and possibly provoke malignant arrhythmia and asystole.

In this case, propofol was used for induction of anesthesia. Propofol has more anti-convulsant effects than other inductional agents, although measurements of seizure quality after propofol anesthesia were not significantly different (14, 15). Propofol also has characteristics such as rapid emergence from anesthesia, lower incidence of hypertension or tachycardia. Due to these effects, propofol is preferable for patients with Brugada ECG pattern.

Succinylcholine is the most commonly used muscle relaxant to reduce the muscle contractions and minimize injury and pain associated with ECT. However, even small doses of succinylcholine can produce side effects such as myalgia, hyperthermia, and hyperkalemia (8). In this case, rocuronium was administered to the patient. This short-acting, amino-steroidal neuromuscular blocking agent has a specific reversal agent, sugammadex. Sugammadex is the γ -cyclodextrin that encapsulates rocuronium. Cholinesterase inhibitor, neostigmine, is ineffective if used in profound block and may not completely reverse moderate block after 20 minutes (16). However, sugammadex can easily and rapidly reverse profound neuromuscular block at doses greater than 2 mg/kg (17).

Brugada syndrome is an increasingly recognized disorder with fatal consequences if not correctly identified and addressed. Many drugs and treatments can precipitate malignant arrhythmia or cardiac effects. In this case we show that a combination of propofol, rocuronium and sugammadex can effectively and safely be used for patients with Brugada ECG pattern undergoing numerous cycles of ECT.

REFERENCES

1. Brugada P, Brugada J : Right bundle branch block, persistent ST segment elevation and sudden cardiac death : a distinct clinical and electrocardiographic syndrome. A multicenter report. *J Am Coll Cardiol* 20 : 1391-1396, 1992
2. Yap YG, Behr ER, Camm AJ : Drug-induced Brugada syndrome. *Europace* 11 : 989-994, 2009
3. Naccarelli GV, Antzelevitch C, Wolbrette DL, Luck JC : The Brugada syndrome. *Curr Opin Cardiol* 17 : 19-23, 2002
4. Canbay O, Erden IA, Celebi N, Aycan IO, Karagoz AH, Aypar U : Anesthetic management of a patient with Brugada syndrome. *Paediatr Anaesth* 17 : 1225-1227, 2007
5. Hayashida H, Miyauchi Y : Anaesthetic management in patients with high-risk Brugada syndrome. *Br J Anaesth* 97 : 118-119, 2006
6. Edge CJ, Blackman DJ, Gupta K, Sainsbury M : General anaesthesia in a patient with Brugada syndrome. *Br J Anaesth* 89 : 788-791, 2002
7. Candiotti KA, Mehta V : Perioperative approach to a patient with Brugada syndrome. *J Clin Anesth* 16 : 529-532, 2004
8. Ding Z, White PF : Anesthesia for electroconvulsive therapy. *Anesth Analg* 94 : 1351-1364, 2002
9. Weinger MB, Partridge BL, Hauger R, Mirow A : Prevention of the cardiovascular and neuroendocrine response to electroconvulsive therapy : I. Effectiveness of pretreatment regimens on hemodynamics. *Anesth Analg* 73 : 556-562, 1991
10. Ali HH, Savarese JJ, Lebowitz PW, Ramsey FM : Twitch, tetanus and train-of-four as indices of recovery from nondepolarizing neuromuscular blockade. *Anesthesiology* 54 : 294-297, 1981
11. Miyazaki T, Mitamura H, Miyoshi S, Soejima K, Aizawa Y, Ogawa S : Autonomic and antiarrhythmic drug modulation of ST segment elevation in patients with Brugada syndrome. *J Am Coll Cardiol* 27 : 1061-1070, 1996
12. Luckhaus C, Hennersdorf M, Bell M, Agelink MW, Zielasek J, Cordes J : Brugada syndrome as a potential cardiac risk factor during electroconvulsive therapy (ECT). *World J Biol Psychiatry* 9 : 150-153, 2008
13. Sackeim HA, Devanand DP, Prudic J : Stimulus intensity, seizure threshold, and seizure duration : impact on the efficacy and safety of electroconvulsive therapy. *Psychiatr Clin North Am* 14 : 803-843, 1991
14. Geretsegger C, Nickel M, Judendorfer B, Rochowanski E, Novak E, Aichhorn W : Propofol and methohexital as anesthetic agents for electroconvulsive therapy : a randomized, double-blind comparison of electroconvulsive therapy seizure quality, therapeutic efficacy, and cognitive performance. *J ECT* 23 : 239-243, 2007

15. Rampton AJ, Griffin RM, Stuart CS, Durcan JJ, Huddy NC, Abbott MA : Comparison of methohexital and propofol for electroconvulsive therapy : effects on hemodynamic responses and seizure duration. *Anesthesiology* 70 : 412-417, 1989
16. Bevan JC, Collins L, Fowler C, Kahwaji R, Rosen HD, Smith MF, deV Scheepers L, Stephenson CA, Bevan DR : Early and late reversal of rocuronium and vecuronium with neostigmine in adults and children. *Anesth Analg* 89 : 333-339, 1999
17. Groudine SB, Soto R, Lien C, Drover D, Roberts K : A randomized, dose-finding, phase II study of the selective relaxant binding drug, sugammadex, capable of safely reversing profound rocuronium-induced neuromuscular block. *Anesth Analg* 104 : 555-562, 2007