

## ORIGINAL

# Using the MDCT thick slab MinIP method for the follow-up of pulmonary emphysema

Hai Lan<sup>1,2</sup>, Hiromu Nishitani<sup>1</sup>, Sadamitsu Nishihara<sup>3</sup>, Junji Ueno<sup>3</sup>, Shoichiro Takao<sup>3</sup>, Seiji Iwamoto<sup>1</sup>, Takashi Kawanaka<sup>1</sup>, Mawlan Mahmut<sup>1</sup>, and Si Qingge<sup>2</sup>

<sup>1</sup>Department of Radiology, Institute of Health Biosciences, the University of Tokushima Graduate School, Tokushima, Japan, <sup>2</sup>Department of Radiology, Inner Mongolia International Mongolian Hospital, China ; and <sup>3</sup>Department of Biomedical Information Sciences, Institute of Health Biosciences, the University of Tokushima Graduate School, Tokushima, Japan

**Abstract : Purpose :** The purpose of this study was to evaluate the usefulness of thick slab minimum intensity projection (MinIP) as a follow-up method in patients with pulmonary emphysema. This method was used to determine the presence or absence of changes over time in the lung field based on multi-detector-row CT (MDCT) data. **Methods :** Among patients diagnosed with pulmonary emphysema who underwent 16-MDCT (slice thickness, 1 mm) twice at an interval of 6 months or more, 12 patients without changes in the lung field and 14 with clear changes in the lung field were selected as subjects. An image interpretation experiment was performed by five image interpreters. Pulmonary emphysema was followed up using two types of thick slab MinIP (thick slab MinIP 1 and 2) and multi-planar reformation (MPR), and the results of image interpretation were evaluated by receiver operating characteristic (ROC) analysis. In addition, the time required for image interpretation was compared among the three follow-up methods. **Results :** The area under the ROC curve (Az) was 0.794 for thick slab MinIP 1, 0.778 for the thick slab MinIP 2, and 0.759 for MPR, showing no significant differences among the three methods. Individual differences in each item were significantly more marked for MPR than for thick slab MinIP. The time required for image interpretation was around 18 seconds for thick slab MinIP 1, 11 seconds for thick slab MinIP 2, and approximately 127 seconds for MPR, showing significant differences among the three methods. **Conclusion :** There were no significant differences in the results of image interpretation regarding the presence or absence of changes in the lung fields between thick slab MinIP and MPR. However, thick slab MinIP showed a shorter image interpretation time and smaller individual differences in the results among image interpreters than MPR, suggesting the usefulness of this method for determining the presence or absence of changes with time in the lung fields of patients with pulmonary emphysema. *J. Med. Invest.* 58 : 175-179, August, 2011

**Keywords :** *pulmonary emphysema, MDCT, MinIP*

Received for publication February 24, 2011 ; accepted March 30, 2011.

Address correspondence and reprint requests to Hiromu Nishitani, MD, Ph.D, Department of Radiology, Institute of Health Biosciences, the University of Tokushima Graduate School, 3-18-15 Kuramoto-Cho, Tokushima 770-8503, Japan and Fax : +81-88-633-7174.

## INTRODUCTION

Pulmonary emphysema is defined as a pathological condition characterized by the abnormal enlargement of airspaces peripheral to terminal bronchioles

accompanied by alveolar wall destruction without clear fibrosis (1). The prognosis of patients with this disease is poor. With disease progression, respiratory failure, cor pulmonale, and right heart failure develop, leading to death. The incidence of pulmonary emphysema is expected to increase due to recent advanced aging and high smoking rates amongst the population. Since the repair of damaged alveoli is difficult, the prevention of emphysema and inhibition of its progression are major therapeutic goals. To achieve these aims, the accurate evaluation of the degree of progression, i.e., follow-up, of pulmonary emphysema, is important (2, 3).

In recent years, marked advances have been made in medical imaging equipment, including multi-detector-row CT (MDCT). Information obtained from one scan using this method has markedly increased, which has consequently increased the image interpretation time and the burden on radiologists. Therefore, efficient image interpretation methods are urgently needed.

Since many lung lesions show higher CT values than the normal lung, attention tends to be paid to high CT values when abnormalities are detected. Therefore, less attention tends to be directed to pulmonary emphysema showing lower CT values than the normal lung at the time of diagnosis. In addition, comparison among a large number of images is time-consuming and burdensome. Therefore, if a method is developed allowing accurate and rapid evaluation of the course of pulmonary emphysema, image interpretation time will decrease, and the diagnostic efficiency will improve.

Three-dimensional images based on 1-mm isotropic voxel data can be obtained using 16-MDCT. The lung can be observed from any direction using multi-planar reformation (MPR). Minimum intensity projection (MinIP) is the reverse of maximum intensity projection (MIP), displaying minimum signal values along the projection line of volume data. MinIP is used to display low-attenuation structures (such as the bronchi, pulmonary emphysema, bile ducts, and pancreatic ducts) with respect to surrounding tissues. MinIP allows the evaluation of pulmonary emphysematous changes using CT (4, 5), and findings obtained using this are consistent with pathological findings (6). In addition, sliding thin slab MinIP (thickness, 3-8 mm) is more sensitive than MPR for the early detection of mild pulmonary emphysema and the diagnosis of pulmonary emphysema (7).

In this study, we produced coronary images (thickness, 8-13 cm) covering extensive areas of the lung using MinIP, and evaluated the usefulness of this method for observing changes over time in the lung field of patients with pulmonary emphysema.

## METHODS AND SUBJECTS

CT examination was performed using a 16-MDCT system (Aquilion 16, Toshiba Medical Systems Corporation, Tokyo, Japan) under the following conditions: slice thickness, 1 mm; rotation, 0.5 seconds; beam pitch, 0.9375; voltage, 120 KV; electric current, 10-400 mA, and automatic exposure control, 8.5 (SD).

Low attenuation areas (LAA) are considered to reflect pathological pulmonary emphysema in chest CT images. In patients diagnosed with pulmonary emphysema, LAA on chest CT images have been increasing. In this study, in patients diagnosed with pulmonary emphysema who underwent 16-MDCT twice at an interval of 6 months or more, the presence or absence of changes during the follow up period was determined by consultation between two radiologists using MPR and MinIP with a slab thickness of 5 or 10 mm. Twelve patients without changes and 14 showing clear changes were selected as the subjects of this study. All subjects were males aged 49-84 years (mean, about 67 years). Images obtained using follow-up MDCT performed twice were interpreted by five image interpreters (years of experience, 7-31 years; mean, 13.2 years). The course of pulmonary emphysema was observed under the following three conditions:

- 1) Thick slab MinIP 1: Coronal images with a thickness covering an extensive area of the lung (8-13 cm) under conditions providing the clearest image of the pulmonary parenchyma (WW, 300, WL, -1,000)
- 2) Thick slab MinIP 2: Coronal images with a thickness covering an extensive area of the lung (8-13 cm) under conditions showing relatively conspicuous emphysematous changes (WW, 2; WL, -930). The WW of 2 used in thick slab MinIP 2 was the minimum value of the 16-MDCT system used in this study. The WL of -930 was selected based on the literature (8).
- 3) MPR: MPR images were moved through axial, coronal, and sagittal sections and observed. Display conditions (WW, 1,600; WL, -600).

The three methods were performed at intervals

of 2 weeks or more with changes in the examination order of patients. The presence or absence of changes in the lung fields during the period from the first to second MDCT examination was determined.

The results of image interpretation were evaluated by receiver operating characteristic (ROC) analysis, and a t-test was performed using DBM MRMC software (9). Concerning the results of image interpretation, the image interpreters applied a vertical line to the site corresponding to their interpretation on a 10-cm line, with the ends indicating the presence or absence of changes.

The detection accuracy of changes with time in the lung fields using each method was evaluated using ROC analysis. In addition, the time required for image interpretation using each observation method was measured with a stopwatch and compared among the three methods. Non-parametric data was analyzed using the Friedman test.

**RESULTS**

1) The area under the ROC curve (Az) was 0.794 for thick slab MinIP 1, 0.778 for thick slab MinIP 2, and 0.759 for MPR. Comparison among the three methods showed no significant differences despite the highest Az value being for thick slab MinIP 1 (Fig. 1).

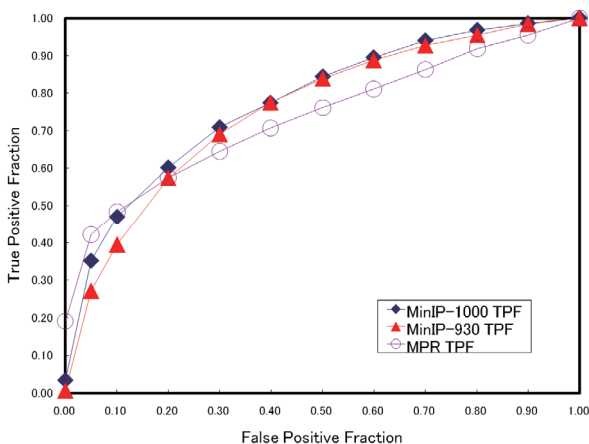


Fig. 1 The mean area under the ROC curve (Az) for the five image interpreters was 0.794 for thick slab MinIP 1, 0.778 for thick slab MinIP 2, and 0.759 for MPR, with no significant differences among the three methods.

2) Individual differences in each item were more marked for MPR than thick slab MinIP (Fig. 2-1, 2-2, 2-3).

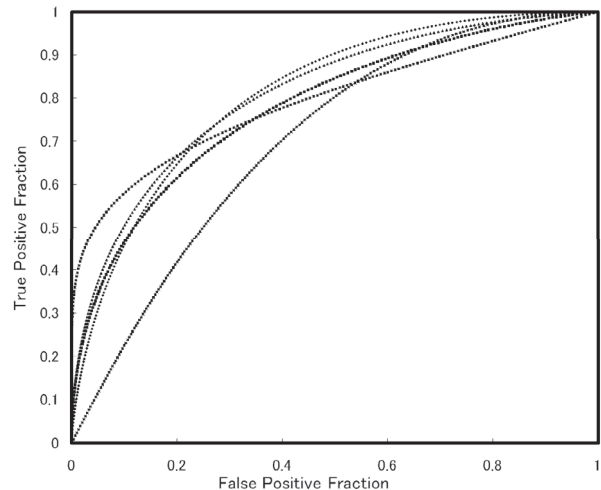


Fig. 2-1 Thick slab MinIP 1 : Az values for the five image interpreters.

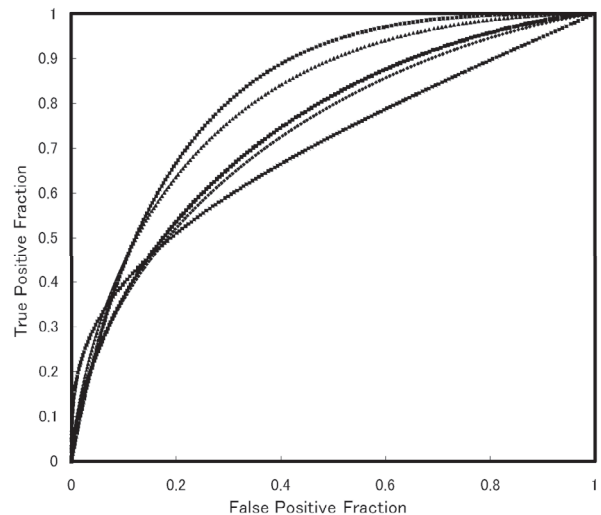


Fig. 2-2 Thick slab MinIP 2 : Az values for the five image interpreters.

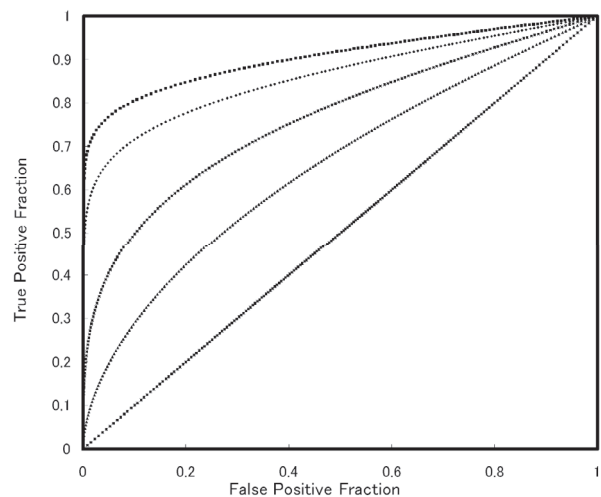


Fig. 2-3 MPR : Az values for the five image interpreters.

3) The time required for image interpretation was around 18 seconds (10.5-40.1 seconds) for thick slab MinIP 1, 11 seconds (8.5-11.9 seconds) for thick slab MinIP 2, and 127 seconds for MPR. The time required for image interpretation significantly differed among the three observation methods.

## DISCUSSION

The usefulness of CT for the accurate diagnosis of pulmonary emphysema has been frequently reported and established (10). In particular, since the acquisition of volume data during one breath-holding became possible due to recent advances in MDCT, studies have shown progression toward quantitative automatic diagnosis using CT values (11).

Pulmonary emphysema is classified into centrilobular, panacinar, and paraseptal types. Centrilobular emphysema is characterized by lesions predominantly located in the upper lobe, and is closely associated with smoking. Panacinar emphysema is characterized by diffuse lesions throughout the entire lung fields and observed in diseases represented by  $\alpha 1$  antitrypsin deficiency. Paraseptal emphysema is characterized by emphysematous changes predominantly in the subpleural areas of the peripheral lung fields. Given these differences in the distribution of lesions, it is important to not only perform purely quantitative evaluation of CT values, but also interpret images showing the lesion distribution.

This study was performed because we experienced difficulty in interpreting images for lesions associated with pulmonary emphysema, showing diffuse low attenuation areas, although we could sensitively interpret images for lesions seen with pneumonia, showing high attenuation in the lung field.

The usefulness of MinIP, which highlights low attenuation areas, has already been shown, and a strong correlation between the results of image interpretation using MinIP and those of pulmonary function tests has also been reported (4-7).

The addition of MinIP to follow-up observations using diagnostic imaging in daily practice may allow not only the diagnosis of diseases, such as pneumonia showing high attenuation, but also the diagnosis and follow-up of changes in diseases such as pulmonary emphysema which show low attenuation. Sliding MinIP has been conventionally used as an application of MinIP to pulmonary emphysema. However, in terms of pulmonary emphysema follow-up,

we consider thick slab MinIP to be useful, and evaluated this method. As a result, image interpretation could be performed in a short time with accuracy similar to that using MPR with thin slice sliding. The addition of thick slab MinIP to routine follow-up using CT may allow straightforward follow-up of pulmonary emphysema.

## CONCLUSION

Compared with MPR, thick slab MinIP reduces follow-up examination time, and causes only small individual differences among image interpreters. In addition, results regarding the presence or absence of changes in the lung fields were similar between the two methods. Therefore, thick slab MinIP may be appropriate for the follow-up of pulmonary emphysema to determine the presence or absence of changes in the lung fields.

## REFERENCES

1. Snider GL, Kleinerman JL, Thurlbeck WM, Bengali ZH : The definition of emphysema : report of a National Heart, Lung, and Blood Institute, Division of Lung Disease Workshop. *Am Rev Respir Dis* 132 : 182-185, 1985
2. Newell JD, Hogg JC, Snider GL : Report of a workshop : quantitative computed tomography scanning in longitudinal studies of emphysema. *Eur Respir J* 23 : 769-775, 2004
3. Bankier AA, Madani A, Gevenois PA : CT quantification of pulmonary emphysema : assessment of lung structure and function. *Crit Rev Comput Tomogr* 43 : 399-417, 2002
4. Yamaguchi K, Matsubara H : Computed tomographic diagnosis of chronic obstructive pulmonary disease. *Curr Opin Pulm Med* 6 : 92-98, 2000
5. Satoh S, Ohdama S, Shibuya H : Sliding thin slab, minimum intensity projection imaging for objective analysis of emphysema. *Radiat Med* 24 : 415-421, 2006
6. Satoh S, Kitazume Y, Taura S, Kimula Y, Shirai T, Ohdama S : Pulmonary Emphysema : Histopathologic Correlation With Minimum Intensity Projection Imaging, High-Resolution Computed Tomography, and Pulmonary Function Test Results. *J Comput Assist Tomogr* 32 : 576-582, 2008

7. Remy-Jardin M, Remy J, Gosselin B, Copin MC, Wurtz A, Duhamel A : Sliding Thin Slab, Minimum Intensity Projection Technique in the Diagnosis of Emphysema : Histopathologic-CT Correlation. *Radiology* 200 : 665-671, 1996
8. Aizawa H, Inoue H, Takata S, Matsumoto K, Shigyo M, Hara N, Murakami J, Murayama S, Hashiguchi N : Clinical usefulness of helical computed tomography in evaluating chronic obstructive pulmonary diseases. *Nihon Kyobu Shikkan Gakkai Zasshi* 34(Suppl) : 63-68, 1996
9. Shimosegawa M : Fundamental theory of ROC analysis and practice using DBM MRMC. *Nippon Hoshasen Gijutsu Gakkai Zasshi* 66 : 1508-1514, 2010
10. Litmanovich D, Boiselle PM, Bankier AA : CT of pulmonary emphysema-current status, challenges, and future directions. *Eur Radiol* 19 : 537-551, 2009
11. Matsuoka S, Yamashiro T, Washko GR, Kurihara Y, Nakajima Y, Hatabu H : Quantitative CT Assessment of Chronic Obstructive Pulmonary Diseases. *Radiographics* 30 : 55-60, 2010