

CASE REPORT

Long-term recurrence-free survivor after laparoscopic removal of solitary adrenal metastasis from endometrial adenocarcinoma

Hirofumi Izaki¹, Masayuki Takahashi¹, Avirmed Shiirevnyamba¹, Ryuichi Taue¹, Hiroyuki Furumoto², Yoshimi Bando³, Yoshihide Murakami⁴, Tomoya Fukawa¹, Takahiro Koizumi¹, Yasuyo Yamamoto¹, Kunihisa Yamaguchi¹, Hiroyoshi Nakatsuji¹, Tomoteru Kishimoto¹, Tomoharu Fukumori¹, and Hiro-omi Kanayama¹

¹Department of Urology and ²Department of Gynecology, Institute of Health Biosciences, the University of Tokushima Graduate School, ³Division of Pathology, Tokushima University Hospital, Tokushima, Japan ; and ⁴Department of Urology, Tokushima Municipal Hospital, Tokushima, Japan

Abstract : Solitary adrenal metastasis from endometrial adenocarcinoma is extremely rare. We report herein the case of a laparoscopically resected solitary adrenal metastasis originating from endometrial adenocarcinoma. The patient was a 55-year-old woman who had undergone total abdominal hysterectomy for stage IIIc endometrial carcinoma, followed by 7 courses of adjuvant chemotherapy comprising carboplatin and paclitaxel. However, the patient developed an isolated right adrenal metastasis 15 months postoperatively. The solitary adrenal metastasis (diameter, 5.7 cm) was removed laparoscopically. The patient has now been in good health without recurrence for 5 years and 7 months after laparoscopic surgery. To the best of our knowledge, this is the first case of solitary adrenal metastasis originating from endometrial adenocarcinoma that is controlled for the long term by successful laparoscopic resection. *J. Med. Invest.* 57 : 174-177, February, 2010

Keywords : laparoscopic adrenalectomy, solitary adrenal metastasis, endometrial adenocarcinoma

INTRODUCTION

The tumors that most commonly metastasize to the adrenal gland are lung cancer, breast cancer, gastric cancer, renal cell carcinoma, malignant melanoma, followed by liver cancer (1, 2). Patients may rarely present with solitary adrenal metastasis (2). In general, the presence of adrenal metastasis in endometrial adenocarcinoma indicates widespread disease (3). Solitary adrenal metastasis

from endometrial adenocarcinoma is thus extremely rare. To the best of our knowledge, only two cases of isolated adrenal metastasis from endometrial adenocarcinoma have been reported (3), and this represents the first description of a laparoscopically resected solitary adrenal metastasis originating from endometrial adenocarcinoma.

CASE REPORT

A 55-year-old woman presented in June 2004 with abnormal genital bleeding. She was referred to our hospital with endometrial adenocarcinoma in July 2004. Her serum carcinoembryonic antigen, CA19-9 and CA125 were within normal limits. The

Received for publication November 2, 2009 ; accepted December 1, 2009.

Address correspondence and reprint requests to Hiro-omi Kanayama, M.D., Ph.D., Department of Urology, Institute of Health Biosciences, the University of Tokushima Graduate School, 3-18-15, Kuramoto-cho, Tokushima 770-8503, Japan and Fax : +81-88-633-7160.

patient underwent total abdominal hysterectomy with bilateral salpingo-oophorectomy and pelvic lymph node dissection. Histopathological examination revealed well-differentiated endometrial carcinoma with depth of myometrial invasion in the inner one-half, with no invasion of the cervix or adnexa. The cytological diagnosis of ascitis in the pelvic cavity was negative, but she had pelvic node involvement. We diagnosed stage IIIc. The patient then received 7 courses of adjuvant chemotherapy with carboplatin and paclitaxel. However, surveillance computed tomography (CT) performed 14 months postoperatively revealed a suspicious right adrenal tumor, 30 mm in diameter (Fig. 1), which

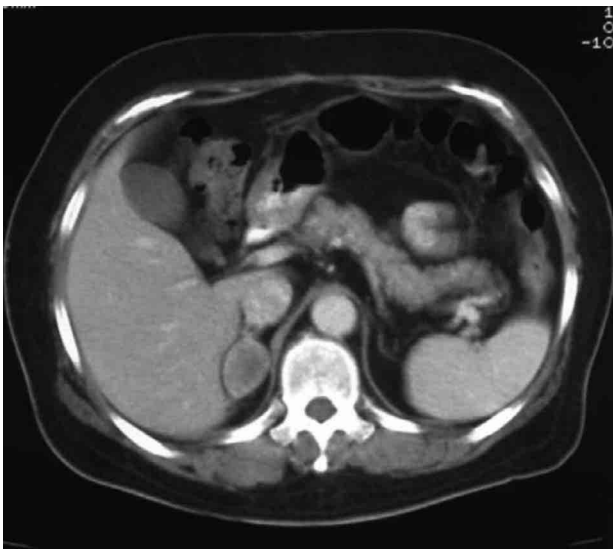


Fig. 1 : Surveillance computed tomography performed 14 months postoperatively, revealing a right adrenal tumor, 30 mm in diameter

had not been present in previous scans. No other sites of metastatic disease were identified. CT performed 1 month later showed a rapidly enlarging adrenal tumor, 57 mm in diameter, indicating metastasis (Fig. 2). Laparoscopic adrenalectomy was performed. Mild adhesions existed between the tumor and liver or inferior vena cava, but the tumor could be successfully removed. Operative time was 3 h 50 min. Pathological examination was consistent with metastasis from the endometrial adenocarcinoma (Fig. 3). The patient was treated with 3 courses of adjuvant chemotherapy using carboplatin and paclitaxel after laparoscopic adrenalectomy. She has now been in good health without recurrence for 5 years and 7 months after laparoscopic surgery.

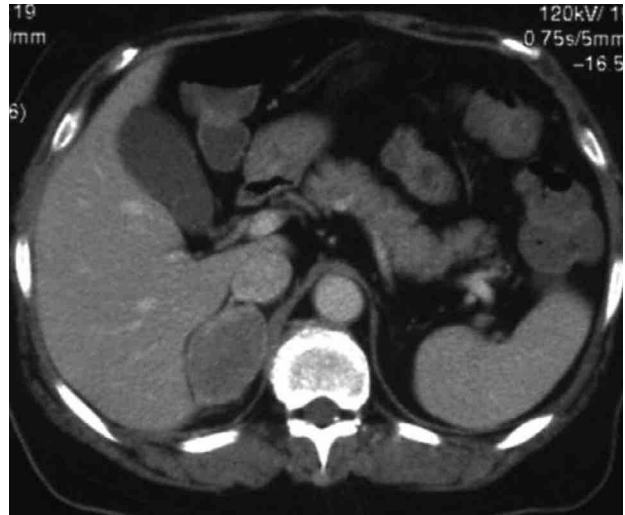

Fig. 2 : CT showing rapid enlargement of the metastatic adrenal tumor, reaching 57 mm in diameter 15 months postoperatively.

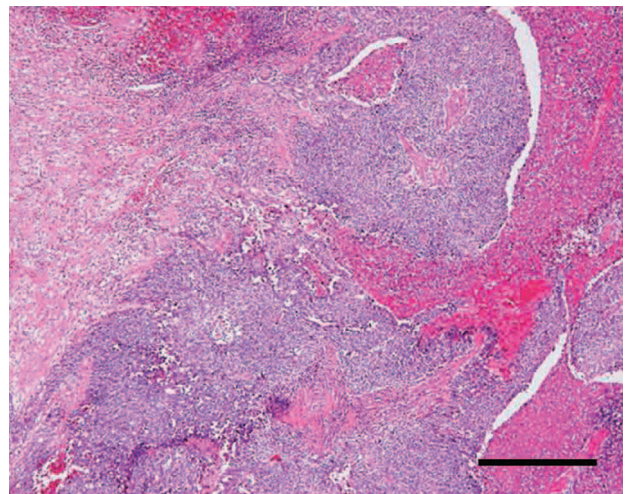


Fig. 3 : Histological appearance of metastatic adenocarcinoma (right) with compressed adrenal gland (left). The tumor displayed glandular and solid patterns with necrosis, compatible with endometrial adenocarcinoma. Bar, 40 μ m.

DISCUSSION

Since the first report by Gagner et al. in 1991 (4), laparoscopic adrenalectomy has been adopted as the gold standard for surgical management of most adrenal tumors. Current indications for laparoscopic adrenalectomy include biochemically and clinically functional adrenal tumors and potentially malignant tumors of the adrenal gland (5). This indication applies to the open adrenalectomy. Potentially malignant tumors of the adrenal gland are generally considered to be non-functional tumors exceeding 5-6 cm in maximum diameter, including

adrenal metastasis or primary adrenocortical carcinoma. However, the role of laparoscopy in the treatment of adrenal malignancies remain controversial. In general, malignant tumor has the presence of dense adhesions, fixation of the tumor, and unusually numerous retroperitoneal feeding vessels. In this sense, the laparoscopic adrenalectomy for adrenal metastasis should be performed by expert laparoscopists (6). Laparoscopic adrenalectomy has been contraindicated in cases of proven or suspected primary adrenal cancer. The locoregional recurrence rate after laparoscopic adrenalectomy of primary adrenal cancer is 60%, occurring 1-2.5 years after resection. This recurrence rate resembles that for patients who have undergone open adrenalectomy for adrenocortical carcinoma (7). As for metastatic cancer, the presence of adrenal metastasis signals widespread disease. In general, the prognosis of patients with metastatic disease is poor, with few survivors at 5 years. In regard to non-small cell lung cancer, Luketich and Burt reported on 14 patients with isolated adrenal metastasis from lung cancer. Median survival was greater in the open surgical resection plus chemotherapy group of 6 patients (31 months) than in the chemotherapy alone group of 6 patients (8.5 months, $p=0.03$) (8). The treatment of isolated adrenal metastases mainly from primary lung cancer is advantageous to the patient if complete removal of the gland can be achieved (9, 10), whereas chemotherapy alone thus seems to have been largely ineffective against adrenal metastasis from non-small cell lung cancer. The same may apply to adrenal metastasis of endometrial adenocarcinoma. In general, the presence of adrenal metastasis from endometrial adenocarcinoma signals widespread or end-stage disease (3). Only 6% of patients with recurrent uterus cancer survived 3 or more years (11). A solitary adrenal metastasis from endometrial adenocarcinoma is extremely rare (Table 1). Combination therapy with carboplatin and paclitaxel reportedly covers the major effective drug

classes in the treatment of advanced and recurrent endometrial cancer (12-14). Overall response rates for patients with evaluable disease range from 62.0 to 82.1% (12-14). Our case was treated with 7 courses of adjuvant chemotherapy using carboplatin and paclitaxel after the initial operation, but surveillance CT performed 14 months postoperatively revealed the right adrenal tumor, 30 mm in diameter. CT 1 month later showed the adrenal tumor had grown to 57 mm in diameter. The volume-doubling time as calculated using the method originally described by Schwartz (15) was 13 days. We diagnosed this rapidly enlarging adrenal tumor as adrenal metastasis from endometrial adenocarcinoma. Chemotherapy thus seems to have been largely ineffective against adrenal metastasis from the endometrial adenocarcinoma. We therefore strongly recommend performing additional surveillance CT soon after detecting small adrenal tumor if the primary lesion was endometrial adenocarcinoma. In addition, surgery should be performed as soon as possible if the adrenal tumor is diagnosed as solitary metastasis of endometrial adenocarcinoma.

Diagnosis of the adrenal tumor as a solitary adrenal metastasis is very important. Several reports have described long-term survival after adrenalectomy for isolated adrenal metastases. The development of ^{18}F -fluorodeoxyglucose (FDG) positron emission tomography (PET) as an imaging technique utilizing the fact that malignant cells contain increased levels of hexokinase (the enzyme responsible for glucose phosphorylation) appears promising for characterizing metastatic adrenal masses. The sensitivity, specificity, accuracy, positive predictive value, and negative predictive value of PET and/or PET/CT in detecting recurrences in patients with endometrial adenocarcinoma have been reported as 100, 83.3, 96, 95, and 100%, respectively (16). As we treated this patient before our hospital started running PET/CT, this modality was unavailable. Currently, all patients with confirmed or

Table 1 : Solitary adrenal metastasis cases from endometrial adenocarcinoma

No	Age	Tumor size (mm)	Management of primary tumor	Management of adrenal tumor	status	Survival (months)
1	76	50	Laparotomy Radiation	Laparotomy chemotherapy	died	15
2	61	50	Laparotomy Radiation	Laparotomy chemotherapy	died	12
3	55	57	Laparotomy chemotherapy	Laparotomy chemotherapy	alive	67

suspected solitary adrenal metastasis at our institution undergo PET with the aim of confirming the lesion as a solitary metastasis.

REFERENCES

1. Kim SH, Brennan MF, Russo P, Burt ME, Coit DG. : The role of surgery in the treatment of clinically isolated adrenal metastasis. *Cancer* 82 : 389-394, 1998
2. Paul CA, Virgo KS, Wade TP, Audisio RA, Johnson FE. : Adrenalectomy for isolated adrenal metastases from non-adrenal cancer. *Int J Oncol* 17 : 181-187, 2000
3. Baron M, Hamou L, Laberge S, Callonnec F, Tielmans A, Dessogne P : Metastatic spread of gynaecological neoplasms to the adrenal gland : case reports with a review of the literature. *Eur J Gynaec Oncol* 17 : 523-526, 2008
4. Gagner M, Lacroix A, Bolte E : Laparoscopic adrenalectomy in Cushing's syndrome and pheochromocytoma. *N Engl J Med* 327 : 1033, 1992
5. Saunders BD, Wainess RM, Dimick JB, Upchurch GR, Doherty GM, Gauger PG. : Trends in Utilization of Adrenalectomy in the United States : Have Indications Changed? *World J Surg* 14 : 14, 2004
6. Castillo OA, Vitagliano G, Kerkebe M, Parma P, Pinto I, Diaz M. : Laparoscopic adrenalectomy for suspected metastasis of adrenal glands : our experience. *Urology* 69 : 637-641, 2007
7. Vassilopoulou-Sellin R, Schultz PN. : Adrenocortical carcinoma : clinical outcome at the end of the 20th century. *Cancer* 92 : 1113-1121, 2001
8. Luketich, J. D. and Burt, M. E. : Does resection of adrenal metastases from non-small cell lung cancer improve survival? *Ann Thorac Surg* 62 : 1614-1616, 1996
9. Porte H, Siat J, Guibert B, Lepimpec-Barthes F, Jancovici R, Bernard A, Foucart A, Wurtz A. : Resection of adrenal metastases from non-small cell lung cancer : A Multicenter study. *Ann Thorac Surg* 71 : 981-985, 2001.
10. Sebag F, Calzolari F, Harding J, Sierra M, Palazzo FF, Henry JF : Isolated adrenal metastasis : The role of laparoscopic surgery. *World J Surg* 30 : 888-892, 2006
11. Van Nagell JR Jr, Rayburn W, Donaldson ES, Hanson M, Gay EC, Yoneda J, Marayuma Y, Powell DF. : Therapeutic implications of patterns of recurrence in cancer of the uterine cervix *Cancer* 44 : 2351-2361, 1979
12. Pectasides D, Pectasides E, Papaxoinis G, Xiros N, Sykiotis C, Papachristodoulou A, Tountas N, Panayiotides J, Economopoulos T. : Combination chemotherapy with carboplatin, paclitaxel and pegylated liposomal doxorubicin for advanced or recurrent carcinosarcoma of the uterus : clinical experience of a single institution. *Gynecol Oncol* 110 : 299-303, 2008
13. Pectasides D, Xiros N, Papaxoinis G, Pectasides E, Sykiotis C, Koumariou A, Psyrris A, Gaglia A, Kassanos D, Gouveris P, Panayiotidis J, Fountzilias G, Economopoulos T. : Carboplatin and paclitaxel in advanced or metastatic endometrial cancer. *Gynecol Oncol* 109 : 250-254, 2008
14. Ang JE, Shah RN, Everard M, Keyzor C, Coombes I, Jenkins A, Thomas K, A'Hern R, Jones RL, Blake P, Gabra H, Hall G, Gore ME, Kaye SB. : A feasibility study of sequential doublet chemotherapy comprising carboplatin-doxorubicin and carboplatin-paclitaxel for advanced endometrial adenocarcinoma and carcinosarcoma. *Ann Oncol* 20. : 109 : 250-4, 2009
15. Schwartz M. A biomathematical approach to clinical tumor growth. *Cancer* 14 : 1272-1294, 1961
16. Park JY, Kim EN, Kim DY, Kim JH, Kim YM, Kim YT, Nam JH. : Clinical impact of positron emission tomography or positron emission tomography/computed tomography in the post-therapy surveillance of endometrial carcinoma : evaluation of 88 patients. *Int J Gynecol cancer* 18 : 1332-8, 2008