

CASE REPORT

A huge ovarian smooth muscle tumor : a case report

Masahiro Murakami¹⁾, Hisanori Uehara²⁾, Masato Nishimura³⁾, Takeshi Iwasa³⁾, and Hiroshi Ikawa¹⁾

¹⁾Department of Obstetrics and Gynecology, Oe Kyodo Hospital ; ²⁾Department of Molecular and Environmental Pathology, and ³⁾Department of Obstetrics and Gynecology, Institute of Health Biosciences, the University of Tokushima Graduate School, Tokushima, Japan

Abstract : Ovarian smooth muscle tumors are a very rare type of ovarian tumor. In this paper, we report the case of a 62-year-old woman who had a huge smooth muscle tumor of the right ovary. The values of all the serum tumor markers were within normal limit. The tumor measured 25 cm in diameter and weighed 6,200 g. Histological examination revealed that coagulative cellular atypia was moderate to severe, necrosis was not present and mitotic index was low. According to the criteria for the evaluation of the uterine smooth muscle tumors, this huge tumor was diagnosed as atypical leiomyoma. However, we finally made a diagnosis of this tumor as a smooth muscle tumor of uncertain malignant potential (STUMP) because of its huge size. Further information is required regarding the characteristics of ovarian smooth muscle tumor and the propriety to introduce uterine tumor histological criteria to ovarian tumors. *J. Med. Invest.* 57 : 158-162, February, 2010

Keywords : leiomyosarcoma, histological diagnosis, smooth muscle tumor

INTRODUCTION

Primary ovarian smooth muscle tumors account for less than 1% of all ovarian tumors (1, 2). However, there are no histological criteria for evaluating them. Currently, the histological criteria used to evaluate the smooth muscle tumors of uterus are applied to ovary (2-4). Those tumors are uncommon tumors that exhibit varied histological patterns, and there is discordance between their morphologic features (mitotic index, coagulative tumor cell necrosis, and atypia) and clinical outcomes. For example, sometimes we encounter a benign tumor with aberrant cytological features with high mitotic counts. Among those smooth muscle tumors, uterine smooth

muscle tumors of uncertain malignant potential (STUMP) are difficult tumors for the diagnosis because they cannot be classified as benign nor malignant by histological criteria (3). Despite this uncertain histological evidence, histological diagnosis is still regarded as the important information in its clinical management and treatment.

In this paper, we present a case of an ovarian smooth muscle tumor whose diagnosis was difficult to distinguish their malignant potential.

CASE REPORT

A 62-year-old woman (gravida 2, para 2) who had been in menopause for 12 years visited the outpatient clinic of internal medicine in our hospital on September 25, 2008. She had complained of 5 kg weight loss, a slight fever, loss of appetite for a month. Gastroduodenoscopy did not reveal any abnormalities in her upper gastrointestinal tract. However, a

Received for publication April 27, 2009 ; accepted August 29, 2009.

Address correspondence and reprint requests to Masahiro Murakami, MD, PhD., Department of Obstetrics and Gynecology, Oe Kyodo Hospital, 252 Kamojima, Kamojima-cho, Yoshinogawa, Tokushima 776-8511, Japan and Fax : +81-883-24-4167.

huge mass was palpated from pelvis extended to the xiphisternum, and a computed tomography (CT) scan of her abdomen and pelvis revealed the presence of a huge solid tumor which arose out of the pelvis and extended to the xiphisternum. This huge tumor seemed to be originated from the one side ovary. She was introduced to our outpatient clinic to have a gynecologic examination.

The pelvic examination and transvaginal ultrasound (US) revealed the presence of a huge solid tumor with a hypoechoic irregular area. The tumor was hard and easily palpated through the abdominal wall, of which movability was limited. These findings suggested the possible malignant potential of this tumor. However, US revealed that this tumor did not accompanied with large amount of ascites and laboratory tests showed that the levels of serum tumor markers (CA125, CA72-4, CA19-9, and CEA) or LDH were all within the normal range. The CT scan revealed that the tumor had an irregular shape with a smooth border and consisted of both solid and cystic part. It occupied almost whole the pelvis and grew out to the extrapelvic space. Additionally, no signs of distant metastasis or pelvic lymphadenopathy were observed on the scan. Pelvic magnetic resonance image (MRI) was also performed. On T1-weighted images, the tumor showed low signal intensity, while on T2-weighted images, the signal intensity remained high. One area of a small part of the tumor showed cystic changes that were often associated with a hemorrhage or necrosis (Fig. 1).

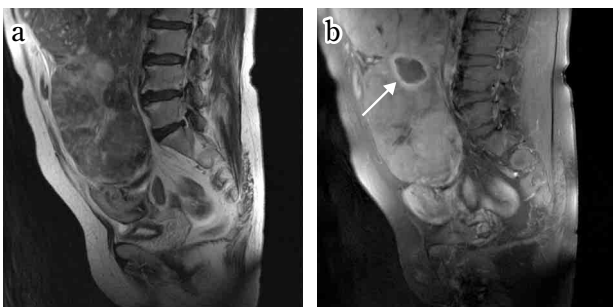


Fig. 1 T2-weighted MR images showing a huge pelvic heterogeneous mass (a) and T1-weighted fat-suppressed gadolinium-enhanced MR images showing cystic changes (arrow) associated with hemorrhage or necrosis (b).

The differential diagnosis of this huge tumor included leiomyoma, leiomyosarcoma, ovarian solid tumor, ovarian cancer, and gastrointestinal smooth muscle tumor (GIST). On October 27 in 2008, a laparotomy was performed.

SURGICAL SPECIMENS

The huge tumor occupied almost the entire abdomen (Fig. 2). However, only small amount of

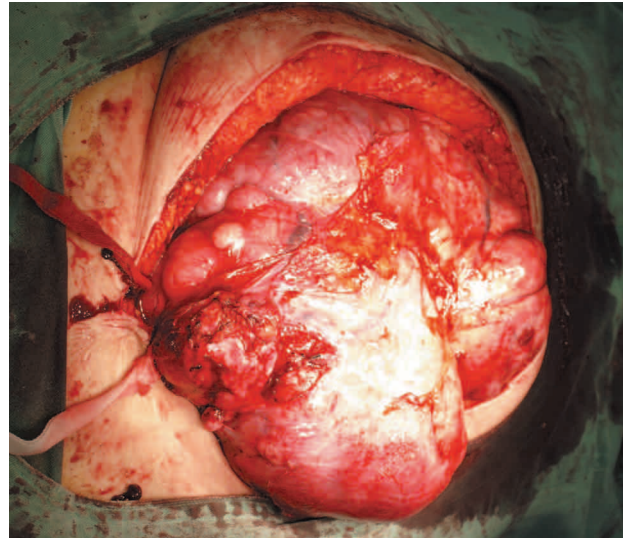


Fig. 2 Surgical specimen. The huge tumor extended from the pelvic to the xiphisternal area.

ascites was observed. The tumor was found to adhere to the omentum and mesentery. It was originated from the right ovary, extending to the retroperitoneal space under the broad ligament. She underwent a right salpingo-oophorectomy (RSO). The rapid histology revealed that it was a low grade malignancy of right ovarian tumor. We did not perform the extirpation of the uterus, left adnexae, omentum, upper abdomen, and retroperitoneal lymph nodes. Before the operation, deep vein thrombosis (DVT) at the renal vein was detected. Additionally, broad adhesion of this tumor to the vessels in the retroperitoneal space and mesentery caused the increased blood loss and prolongation of the operation. Thus further operation besides RSO should not be performed. We thought that it would be better to perform further operation later after obtaining the final precise histological diagnosis of this ovarian tumor.

GROSS FINDINGS

The tumor measured 25 cm in diameter and weighed 6,200 g. Its surface was irregular, and the cut surface was firm and white. Focal irregular cystic and necrotic areas were present, while hemorrhagic areas were absent (Fig. 3).

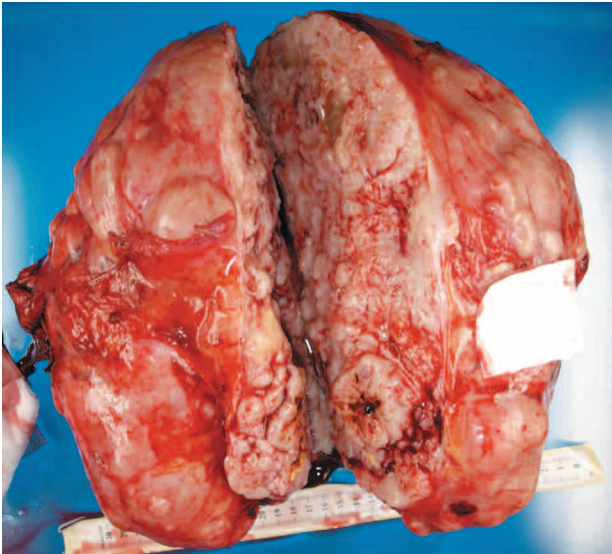


Fig. 3 Macroscopic findings for the extirpated tumor. The external surface was irregular and nodular. The arrow shows cystic areas.

HISTOPATHOLOGICAL AND IMMUNOHISTOCHEMICAL FINDINGS

Histological examination of the tumor showed that it was composed of fascicles of spindle-shaped cells with moderate to severe cellular atypia and increased cellularity, but no coagulative necrosis or excessive number of mitotic figures (2 to 3/10 HPF). Immunohistochemical examination of the tumor cells showed that they were positive for α -smooth muscle actin and desmin. The MIB-1 labeling index was approximately 10%. Although coagulative necrosis was not present, and mitotic activity was moderate, a final diagnosis of STUMP was made on the basis of cellular atypia, increased cellularity, and tumor size (Figs. 4, 5).

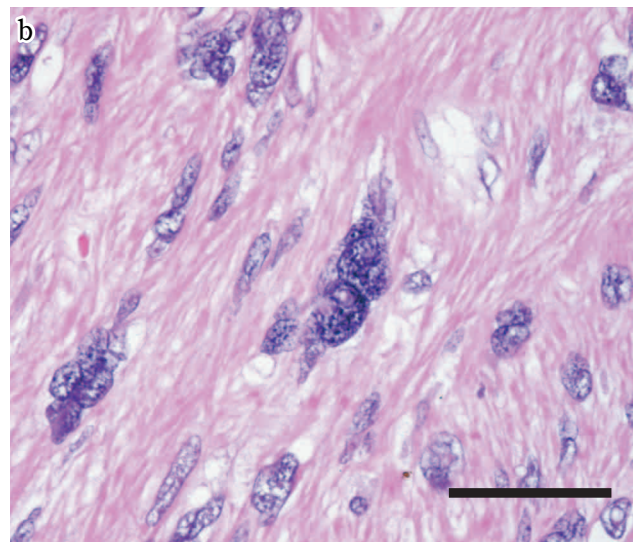
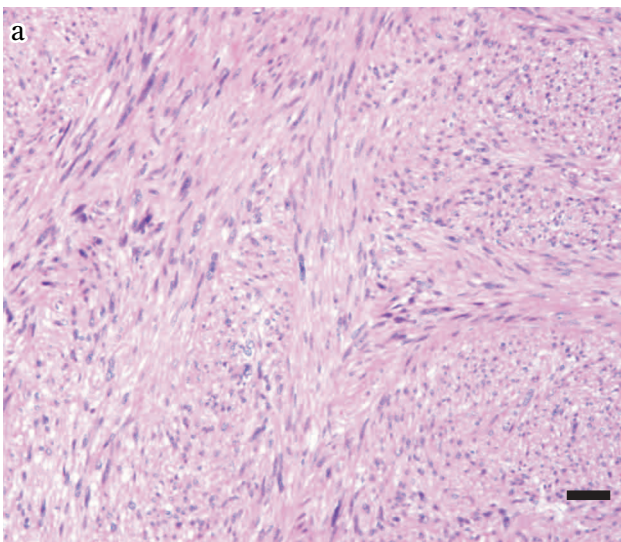


Fig. 4 (a) The tumor is composed of fascicles of spindle-shaped cells (HE). (b) Multinucleated tumor cells with hyperchromatic nuclei. Cellular atypia is graded as moderate to severe (HE). Scale bars, 50 μ m.

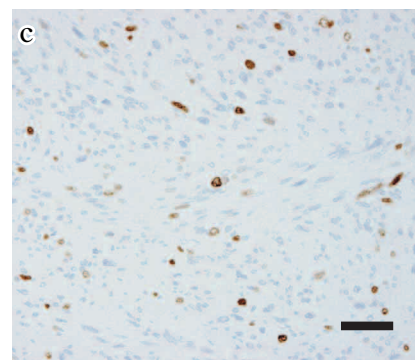
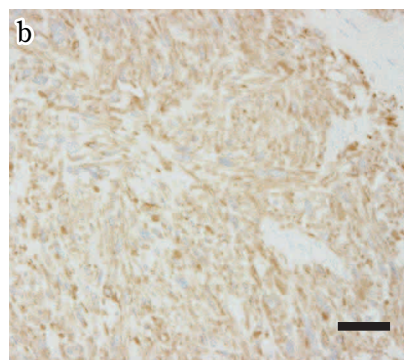
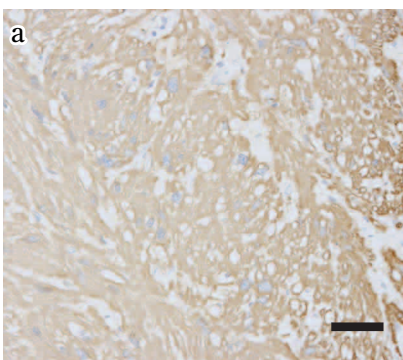


Fig. 5 The tumor cells were positive for (a) α -smooth muscle actin and (b) desmin. (c) The MIB-1 labeling index was approximately 10%. Scale bars, 50 μ m.

POSTOPERATIVE CLINICAL COURSE

The patient and her family were informed of the fact that the effect of additional surgery on survival in patients of STUMP had not been shown because the tumor of low-grade malignancy generally did not metastasize. They were also informed that the effectiveness of chemotherapy or radiation for STUMP was not known even in case any metastasis existed. After the careful consideration, they finally did not agree with an additional surgery, adjuvant chemotherapy, or radiation therapy.

She has been observed in our outpatient clinic and for the time being, relapse has not been detected 5 months after the operation.

DISCUSSION

Primary ovarian smooth muscle tumors are very rare tumors in comparison with the uterine smooth muscle tumors (1). There is little information on their origin, etiology, histological features, clinical behavior, and treatment (5). Furthermore, there are no determinant histological criteria for evaluation. Thus, there are some reports that they can be identified on the basis of criteria similar to those used for uterine smooth muscle tumors (2-5).

Uterine smooth muscle tumors are classified into the following groups : leiomyoma, mitotically active leiomyoma, atypical leiomyoma, leiomyosarcoma, and STUMP. If tumor cell atypia is absent or most mild without necrosis, the tumor is leiomyoma. There is no need to use mitotic index (MI) if atypia and coagulative necrosis are clearly absent. In case that MI of the leiomyoma is more than 10, the tumor is specially called as the mitotic active leiomyoma. If tumor cell atypia is moderate or severe without necrosis, the tumor is classified according to the MI. If the MI is less than 10, it is classified as atypical leiomyoma. If MI is more than 10, it is classified as leiomyosarcoma. When both significant atypia and coagulative necrosis are present, the tumor is leiomyosarcoma regardless of the MI. (2). If the tumor shows the problematic clinical and histological features that can not led the clear classification into benign nor malignant category, it is classified as smooth muscle tumor of uncertain malignant potential (STUMP). According to these criteria of uterine smooth muscle tumors, this case should be classified as atypical leiomyoma because the cellular atypia is moderate to severe without necrosis,

and the MI is 2 to 3. Generally, malignant potential behavior of smooth muscle tumors is almost always associated with any two of the following features : coagulative necrosis, cellular atypia, and $MI > 10$ (3). The tumor size is not considered. However, in this case, we made the diagnosis as STUMP, not atypical leiomyoma. Because the size of this tumor was, to our knowledge, the hugest in the reported cases, we were reluctant to apply the criteria of uterine smooth muscle tumors to this ovarian tumor.

The International Federation of Gynecology and Obstetrics (FIGO) staging and treatment of ovarian leiomyosarcoma have been the same as those for ovarian carcinoma (6). There is no established treatment for them other than surgery (7). About the treatment of uterine leiomyosarcoma, adjuvant chemotherapy or radiation therapy after the primary surgery is often performed. Those therapies of uterine disease should be applied to the ovarian leiomyosarcoma, however, the effects of these adjuvant therapies could not be proved because of the rareness of this disease (5, 8). The prognosis of ovarian leiomyosarcoma is extremely poor, and it depends on the tumor stage, tumor size, and MI (2, 5, 9, 10). Taskin, *et al.* reported that 63.3% of stage-1 patients survived with no evidence of the disease after a mean follow-up period of 41.7 months, while 81.25% of patients at a higher stage died after a mean follow-up period of only 14.7 months (5).

Unfortunately, fewer cases were reported on STUMP of the ovary compared with leiomyosarcoma of the ovary which is a still very rare disease. Lerwill, *et al.* reported that total abdominal hysterectomy and bilateral salpingo-oophorectomy were performed in one case, unilateral salpingo-oophorectomy in one, and unilateral oophorectomy in two cases. Only three patients could be followed up after the operation : the follow-up report for one was not available because it was recent, while the disease recurred in the other two patients (at 16 months for one and at 58 months for the other patient) (2).

We encountered a huge ovarian tumor which features are intermediate between leiomyoma and leiomyosarcoma. We presumed that the patient had a stage-1 tumor, and the minimum surgery of RSO was performed.

This patient and her family did not wish for further therapy. There is no established treatment protocol other than surgery, which is the mainstay of treatment. Various adjuvant therapies have been proposed, including radiotherapy and chemotherapy, with no additional benefit (5, 8). However, careful

observations should be required in this case because the huge tumor size might indicate a high malignancy potential.

Because ovarian smooth muscle tumors are very rare, it was difficult to assess the histological findings in our patient. In light of this case report, we think that it is important to establish criteria for the differential diagnosis of ovarian smooth muscle tumors.

Further information is required regarding the characteristics of ovarian smooth muscle tumors and the propriety to introduce uterine tumor histological criteria to ovarian tumors.

REFERENCES

1. Anderson B, Turner DA, Benda J : Ovarian sarcoma. *Gynecol Oncol* 26 : 183-192, 1987
2. Lerwill MF, Sung R, Oliva E, Prat J, Young RH : Smooth muscle tumors of the ovary : a clinicopathologic study of 54 cases emphasizing prognostic criteria, histologic variants, and differential diagnosis. *Am J Surg Pathol* 28 : 1436-1451, 2004
3. Kempson RL, Hendrickson MR : Smooth muscle, endometrial stromal, and mixed Müllerian tumors of the uterus. *Mod Pathol* 13 : 328-342, 2000
4. Clement PB : Selected miscellaneous ovarian lesions : small cell carcinomas, mesothelial lesions, mesenchymal and mixed neoplasms, and non-neoplastic lesions. *Mod Pathol* 18 : 113-129, 2005
5. Taskin S, Taskin EA, Uzüm N, Ataoglu O, Ortaç F : Primary ovarian leiomyosarcoma : a review of the clinical and immunohistochemical features of the rare tumor. *Obstet Gynecol Surv* 62 : 480-486, 2007
6. Greene FL, Page DL, Fleming ID, A Fritz, CM Balch, DG Haller, M Morrow : *AJCC Cancer Staging Manual* 6 th ed. Springer, New York, 2002
7. Bouie SM, Cracchiolo B, Heller D : Epithelioid leiomyosarcoma of the ovary in a perimenarchal female. *Gynecol Oncol* 48 : 389-393, 1993
8. Monk BJ, Nieberg R, Berek JS : Primary leiomyosarcoma of the ovary in a perimenarchal female. *Gynecol Oncol* 48 : 389-393, 1993
9. Seracchioli R, Colombo FM, Bagnoli A, Trengia V, Venturoli S : Primary ovarian leiomyosarcoma as a new component in the nevoid basal cell carcinoma syndrome : a case report. *Am J Obstet Gynecol* 188 : 1093-1095, 2003
10. Shakfeh SM, Woodruff JD : Primary ovarian sarcoma : report of 46 cases and review of literature. *Obstet Gynecol Surv* 42 : 331-349, 1987