

An incident involving blood sucking by a tick in a suburb in Japan

Ichiro Shimizu^{*}, Hiroaki Mitani^{**}, Masayuki Shono⁺, Toshihiro Omoya^{*}, Yoko Musashi^{*}, Katsutaka Sannomiya^{*}, Masaharu Suzuki^{*}, Takahiro Horie^{*}, Hirohito Honda^{*}, and Susumu Ito^{*}

^{*}Second Department of Internal Medicine, The University of Tokushima School of Medicine, Tokushima, Japan; ^{**}Mitani Physical Clinic, Anan, Japan; and ⁺Institute for Enzyme Research, Tokushima University, Tokushima, Japan

Abstract : We encountered a patient whose blood was sucked by *Haemaphysalis longicornis* in the suburb of a business city in Tokushima prefecture in Japan. The tick, which had been attached to the lower limb of the patient for one week, measured 10 mm in length. There were no notable objective or subjective findings after the complete extirpation of the tick. The area had not been known in recent history to be a habitat of ticks, and, thus, this case is of importance in terms of predicting future trends of tick-borne diseases in Japan. *J. Med. Invest.* 47 : 145-147, 2000

Key words : tick-borne disease, suburb, *Haemaphysalis longicornis*

INTRODUCTION

Infections with pathogenic microorganisms transmitted via the tick are referred to as tick-borne diseases. Regarding such diseases in Japan, Lyme 's disease, caused by *Borrelia* infection (1), Rickettsial spotted fever, caused by *Rickettsia* infection (2), and Tularemia caused by bacterial infection (3) have all been reported. Ticks have not been observed in city areas, excluding some rural districts. However, because of the increase in outdoor activities and leisure activities of the population in recent years, areas of human activity have expanded to the surrounding areas where ticks can be found, and it is not unusual that humans encounter ticks that are then accidentally transported back to urban areas. In addition, ticks can be transported by wild animals that were expelled from their habitat due to forest destruction by urban development (4).

In the present study, we encountered an incident

involving blood-sucking by a tick in an urban residential area of a business city in the Tokushima prefecture in Japan. A tick attached itself to the lower limb of an individual, began to suck blood and subsequently grew to a size of 10 mm. It remained attached to the skin even during bathing and, as a result, the patient mistook the tick for an ecchymoma. Since incidents involving blood sucking by ticks have been reported only rarely in Tokushima prefecture, this case was considered very important in terms of predicting future trends of tick-borne diseases in Japan.

CASE REPORT

The patient was a 72-year-old Japanese female, who found a small light red erythema with a dark brown' protrusion-like accretion 'measuring a few mm in the center in the skin of the upper medial malleolar region of the right lower limb around August 12, 1999, but she did not have subjective symptoms and, as a result, left it untreated. The ' protrusion 'gradually enlarged, reaching 10 mm in diameter one week later, but did not move or otherwise respond, even when the patient touched or poured running water on it. The patient bathed on

Received for publication January 24, 2000 ; accepted March 31, 2000.

Address correspondence and reprint requests to Ichiro Shimizu, M.D., Second Department of Internal Medicine, The University of Tokushima School of Medicine, Kuramoto-cho, Tokushima 770-8503, Japan and Fax : +81-88-633-9235.

a daily basis and wore socks over the tick as usual. The patient had mistaken it for a blood blister in her words (ecchymoma). On August 19, 1999, the patient visited our department for a course of observation of healing of a duodenal ulcer, and the blood-sucking tick was found when the protrusion-like accretion 'accidentally fell from her skin. Regarding the tick bite, no notable abnormalities including fever or enlargement of the lymph nodes were observed other than a light red semi-ringed erythema measuring 25×15 mm around the tick bite region in the upper region of the right medial malleolus (Fig. 1). The tick was a blood-sucking imago of *Haemaphysalis longicornis* measuring 10×9 mm (Fig. 2). The head of the tick, which partially re-

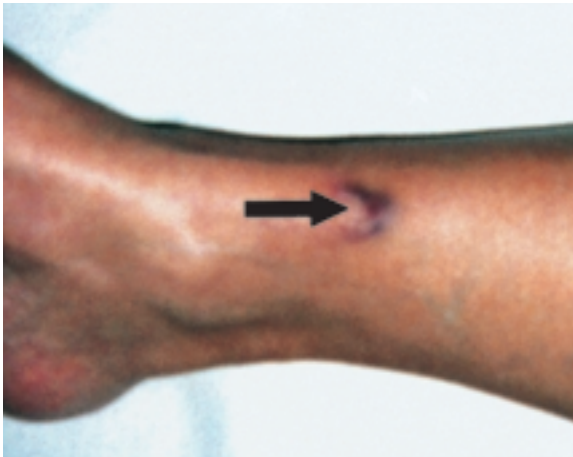

Fig. 1. An erythema around the tick bite region (arrow) in the upper medial malleolar region of right lower limb.

mained in the tick bite region in the skin was completely removed by incision. Amoxicillin was administered at a dose of 500 mg/day for one week. In a blood chemistry test, the peripheral blood was normal including leukocyte classification. An inflammatory response was not observed, nor were any notable abnormal findings shown in biochemical tests (Table 1).

Approximately 7 days later, the rash in the lower limb disappeared, and the skin incision was cicatrized and subsequently healed. There have been no notable objective or subjective findings as of five months later.

DISCUSSION

A tick imago measures about 3 - 4 mm, and when it sucks blood, it becomes enlarged to about 10 mm.

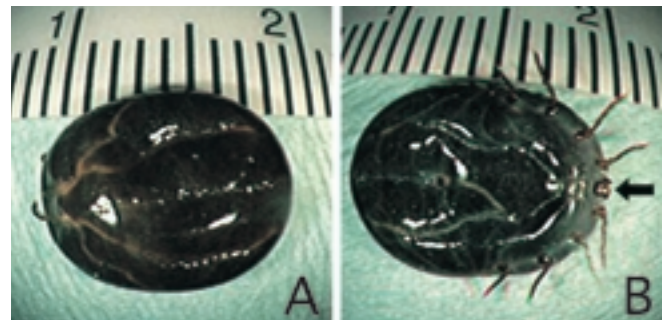


Fig. 2. An imago of the *Haemaphysalis longicornis* (body measuring 10×9 mm) that sucked blood.

(A) Dorsal side.

(B) Ventral side. A portion of the head is missing (arrow).

Table 1. Laboratory data on medical examination

RBC	450 (400 - 450×10 ⁴ /mm ³)	TP	7.4 (6.5 - 8.2 g/dl)
Hb	12.3 (12.0 - 16.0 g/dl)	Alb	4.8 (3.7 - 5.1 g/dl)
Ht	39.5 (37.7 - 47.0 %)	AST	27 (5 - 38 IU/l)
Plt	22.4 (15.0 - 40.0×10 ⁴ /mm ³)	ALT	17 (5 - 40 IU/l)
WBC	4300 (4000 - 9000/mm ³)	LDH	390 (200 - 450 IU/l)
Stab	7.0 (3 - 12 %)	ALP	229 (66 - 250 IU/l)
Seg	44.7 (35 - 55 %)	γ-GTP	11 (< 35 U/l)
Eos	3.5 (0 - 6 %)	T-bil	0.5 (< 1.0 mg/dl)
Bas	1.2 (0 - 2 %)	BUN	18 (8 - 20 mg/dl)
Mon	5.6 (2 - 8 %)	Cre	0.6 (0.5 - 0.9 mg/dl)
Lym	38.0 (18 - 48 %)	CK	90 (30 - 200 IU/l)
CRP	< 0.3 (< 0.3 mg/dl)	IgE	15 (< 160 IU/ml)

Normal values are shown in parentheses.

The tick found in this patient was a blood-sucking imago of *Haemaphysalis longicornis*. After hatching, ticks grow by two ecdyses from nymphs through young ticks to adult ticks, and they suck blood once in each generation in different hosts (5). Nymphs parasitize and suck blood in small mammals, birds and reptiles, and young and adult ticks parasitize and suck blood in large mammals, birds and humans (6). It is thought that ticks suck human blood in the spring and summer, and this case occurred in August.

Ticks inhabit hills and fields, and tick-borne diseases form transmission cycles that consist of ticks and wild animals. However, because of the expansion in human outdoor activities in recent years, many pet owners bring their animals to fields. Therefore, opportunities for ticks to directly parasitize humans as well as pets, and transporting ticks into human living areas may have been increased. Moreover, changes in the natural environment, especially the destruction of forests, have driven wild animals into surrounding areas, and ticks, which are common parasites on wild animals, are carried with the animals, which may expand the endemic area. Residential development of hills and fields may further increase contact with ticks. Alternatively, forest restoration and wild animal preservation are considered to facilitate growth of transmitter ticks (4), indicating a risk that the probability of contact between humans and ticks will increase in the future (6).

The area around the district where the patient lives is not a habitat of ticks. The patient manages her household all day, but does not go to fields or have a pet, although she sometimes works in the household vegetable garden. However, a stray cat

sometimes came into her kitchen, suggesting that the tick could have arrived via this cat. Fortunately, the area is not associated with endemic regions of tick-borne diseases, and an infection transmitted by ticks did not occur. However, tick-borne diseases, which used to be endemic only to limited regions, are becoming serious social problems, and possible increases in exposure of humans to ticks should be noted in conjunction with these problems. Therefore, it is important in any area of Japan to actively collect available information on blood-sucking ticks.

REFERENCES

1. Burgdorfer W, Barbour AG, Hayes SF, Benach JL, Grunwaldt E, Davis JP: Lyme disease—a tick-borne spirochetosis? *Science* 216 : 1317-1319, 1982
2. Woodward TE: Rickettsial diseases. In: Isselbacher KJ, Braunwald E, Wilson JD, Martin JB, Fauci AS, Kasper DL, eds. *Harrison's Principles of Internal Medicine*. 13th ed. McGraw-Hill, New York, 1994, pp. 747-757
3. Guerrant RL, Humphries MK Jr, Butler JE, Jackson RS: Tickborne oculoglandular tularemia: case report and review of seasonal and vectorial associations in 106 cases. *Arch Intern Med* 136 : 811-813, 1976
4. Steere AC: Lyme disease: a growing threat to urban populations. *Proc Natl Acad Sci USA* 91 : 2378-2383, 1994
5. Anderson JF: Epizootiology of *Borrelia* in ixodid tick vector and reservoir hosts. *Rev Infect Dis* 11 : 1451-1459, 1989
6. Kawabata M: Lyme disease. *Jpn J Clin Pathol* 46 : 645-650, 1998