

Reduced-intensity allogeneic stem cell transplantation for renal cell carcinoma: In vivo evidence of a graft-versus-tumor effect

著者	Takami Akiyoshi, Asakura Hidesaku, Koshida Kiyoshi, Namiki Mikio, Nakao Shinji
著者別表示	高見 昭良, 朝倉 英策, 越田 潔, 並木 幹夫, 中尾 眞二
journal or publication title	Haematologica
volume	89
number	3
page range	375-376
year	2004
URL	http://doi.org/10.24517/00053664

Correspondence: Hiroyasu Ogawa, M.D., Department of Molecular Medicine, Osaka University Graduate School of Medicine 2-2, Yamada-Oka, Suita City, Osaka, Japan 565-0871. Phone: international +81.6.68793831. Fax: international +81.6.68793839. E-mail: ogawah@imed3.med.osaka-u.ac.jp

References

- Ogawa H, Soma T, Hosen N, Tatekawa T, Tsuboi A, Oji Y, et al. Combination of tacrolimus, methotrexate, and methylprednisolone prevents acute but not chronic graft-versus-host disease in unrelated bone marrow transplantation. *Transplantation*, 2002;74:236-43.
- Szydlo R, Goldman JM, Klein JP, Gale RP, Ash RC, Bach FH, et al. Results of allogeneic bone marrow transplants for leukemia using donors other than HLA-identical siblings. *J Clin Oncol* 1997;15:1767-77.
- Anasetti C, Beatty PG, Storb R, Martin PJ, Mori M, Sanders JE, et al. Effect of HLA incompatibility on graft-versus-host disease, relapse, and survival after marrow transplantation for patients with leukemia or lymphoma. *Hum Immunol* 1990;29:79-91.
- Anasetti C, Hansen JA. Effect of HLA incompatibility in marrow transplantation from unrelated and HLA-mismatched related donors. *Transfus Sci* 1994;15:221-30.
- Ruggeri L, Capanni M, Urbani E, Perruccio K, Shlomchik WD, Tosti A, et al. Effectiveness of donor natural killer cell alloreactivity in mismatched hematopoietic transplants. *Science* 2002;295:2097-100.
- Giebel S, Locatelli F, Lamparelli T, Velardi A, Davies S, Frumento G, et al. Survival advantage with KIR ligand incompatibility in hematopoietic stem cell transplantation from unrelated donors. *Blood* 2003;102:814-9.

Stem Cell Transplantation

Reduced-intensity allogeneic stem cell transplantation for renal cell carcinoma: *in vivo* evidence of a graft-versus-tumor effect

We report the cases of 3 patients with advanced renal cell carcinoma who underwent reduced-intensity allogeneic stem cell transplantation. In 2 partial responders, histologic analyses of metastases revealed prominent accumulation of CD8⁺ T cells and degenerative changes of clear cell carcinoma, suggestive of induction of tumor-specific cytotoxic T lymphocytes.

haematologica 2004; 89:375-376
(<http://www.haematologica.org/2004/3/375>)

Recently, reduced-intensity allogeneic stem cell transplantation (RIST) has been introduced into the treatment of renal cell carcinoma (RCC).¹⁻⁵ We report the preliminary results of RIST in 3 patients (Table 1) with advanced RCC refractory to cytokine-based therapy, and show the histologic analyses before and after transplantation. The patients and donors gave written informed consent to participate in this institutionally approved investigational protocol. The preparative regimen, consisting of cyclophosphamide and

fludarabine, was entirely based on a previously reported study and included cyclosporine (CSP).¹ Patients received granulocyte colony-stimulating factor-mobilized peripheral blood stem cells from their HLA-identical siblings on day 0. Following transplantation, the degree of donor-recipient chimerism in both myeloid and T-cell lineages was assessed by polymerase-chain reaction assay according to a published method.¹

All three patients achieved sustained myeloid and platelet engraftment with the proportion of donor cells in the peripheral blood exceeding 80% for both T cells and granulocytes within 2 months. We observed 2 partial responses in patients #1 and #3 six months and eight months after transplantation respectively: one response occurred after the development of chronic graft-versus-host disease (GVHD) and the other after acute GVHD: both coincided with full donor T-cell chimerism. Thereafter, the disease in patient #1 remained stable while GVHD responded to treatment with low-dose CSP plus steroids. Unfortunately, this patient died of bacterial pneumonia on day 554. In patient #3, chronic GVHD of the skin, salivary glands, and lung required treatment with CSP and steroids. Twenty months after transplantation, metastases started to grow despite a lack of change in GVHD. Reducing CSP and steroids caused acute respiratory failure due to chronic lung GVHD, though some regression of RCC metastases was observed. This

Table 1. Characteristics of the patients and outcome of transplantation.

Patient no.	Age (yr)/sex	Histology	Sites of metastases	No. of previous systemic treatments	Nephrectomy	Age (yr)/sex of donor	CD34 ⁺ cells/kg infused ($\times 10^6$)	No. of CD3 ⁺ cells/kg infused ($\times 10^8$)	GVHD	Response	Outcome
1	64/M	Clear cell	Lung, pleura, bone, nodes	3	Yes	69/M	5.6	3.0	Extensive chronic skin, oral, salivary	PR	SD; died of pneumonia on day 554
2	58/F	Papillary	Pleura, liver, adrenal, nodes	2	No	59/M	9.7	4.3	Acute grade 3 skin, liver, GI	PD	Died of disease progression on day 68
3	56/M	Clear cell	Bone, lung, pleura, adrenal, nodes, disease	3	Yes	51/F	4.9	2.4	Acute grade 2 skin, GI, extensive chronic skin, salivary, lung	PR	Died of progressive and GVHD on day 709

M: male; F: female; GVHD: graft-versus-host disease; GI: gastrointestinal; PR: partial response; SD: stable disease; PD: progressive disease.

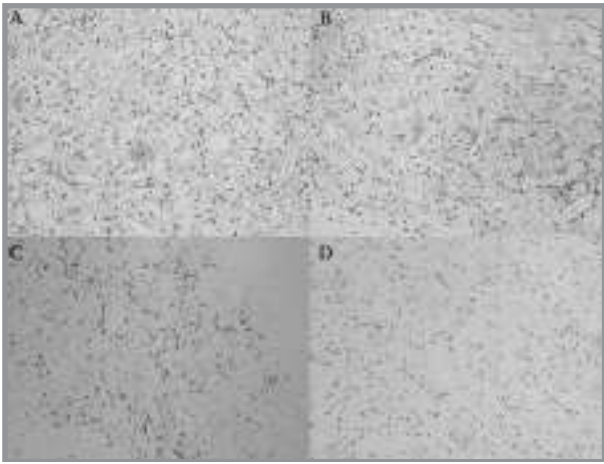


Figure 1. Photomicrographs of pleural metastases of RCC from patient #1. (A) Before transplantation, the clear cell architecture was intact in a pleural section obtained by open-lung biopsy. (B) In the pleural section taken post-mortem, tumor cell detritus and heavy mononuclear cell infiltration were seen. Immunohistochemical staining with monoclonal antibodies against CD8 (C) and CD4 (D) antigens showed that mononuclear cells in the post-mortem pleural section were primarily CD8⁺. Original magnification, $\times 200$.

patient died of respiratory failure from GVHD and disease progression on day 709. Since the median survival of patients with cytokine therapy-resistant metastatic RCC is less than 6 months,⁶ having stabilized disease progression for 12 months in patient #3 may be noteworthy. Patient #2 progressed soon after the transplantation and did not respond to withdrawal of CSP on day 18. To induce a graft-versus-tumor (GVT) effect, she received interleukin-2 plus donor-lymphocyte infusion with 3.0×10^8 CD3⁺ cells/kg on day 27. On day 45, grade III GVHD of the liver and intestine developed. Shortly thereafter lymphadenopathy in the neck and axilla regressed gradually, but there was no reduction in massive pleural effusions. Patient #2 died of disease progression on day 68.

Histologic analyses of the pleural metastasis in patient #1 revealed intact tumor cell architecture and the absence of lymphocyte infiltration before transplantation (Figure 1A). However, after transplantation we found an accumulation of mononuclear cells corresponding to a degenerative lesion of clear cell carcinoma (Figure 1B), which mainly consisted of CD3⁺CD8⁺ cells (Figure 1C), but not CD4⁺ cells (Figure 1D). The other metastases in lung, bone, and lymph nodes also showed considerable penetration by infiltrating CD8⁺ cells. These findings were also seen in patient #3. Post-mortem sections of bone, lung, pleura, adrenal, and lymph node metastases were found to contain abundant infiltrating CD8⁺ cells. In patient #2, conversely, lymphocyte infiltra-

tion and destruction of tumor were not present in metastatic sites examined post-mortem, except for a small number of lymphocytes seen in the supraclavicular lymph node and the primary lesion of the left kidney as well as minimal destruction of the primary tumor.

Our study showed that the GVT effect was closely associated with infiltration of CD8⁺ cells without infiltration of CD4⁺ cells, although there is a possibility that T cells seen after death may differ from those at the time of response.

These findings suggest that the GVT effect after RIST may be mediated by induction of tumor-specific cytotoxic T lymphocytes (CTL) rather than induction of lymphocytes which secrete cytokines locally, since cytokine secretion and cytotoxicity are mainly functions of CD4⁺ cells and CD8⁺ cells respectively. The future direction of this study will be to isolate tumor antigens exclusively or preferentially presented by tumor cells, and generation of CTL specific for these tumor antigens.

Akiyoshi Takami,* Hidesaku Asakura,* Kiyoshi Koshida,^o Mikio Namiki,^o Shinji Nakao,*

*Departments of Hematology and Oncology;
^oUrology, Kanazawa University Graduate School of Medicine, Japan

Key words: reduced-intensity stem cell transplantation, renal cell carcinoma, graft-versus-tumor effect, tumor-infiltrating lymphocytes.

Funding: this research was supported by a Grant-in-Aid for Scientific Research from the Ministry of Health, Labor and Welfare, Japan.

Correspondence: Akiyoshi Takami, M.D., Department of Hematology and Oncology, Kanazawa University Graduate School of Medicine, 13-1 Takaramachi, Kanazawa, 920-8641 Japan.

Phone: international +81.762.65 2273.

Fax: international +81.762.34 4252.

E-mail: takami@med3.m.kanazawa-u.ac.jp

References

- Childs R, Chernoff A, Contentin N, Bahceci E, Schrupp D, Leitman S, et al. Regression of metastatic renal-cell carcinoma after nonmyeloablative allogeneic peripheral-blood stem-cell transplantation. *N Engl J Med* 2000;343:750-8.
- Bregni M, Dodero A, Peccatori J, Pescarollo A, Bernardi M, Sassi I, et al. Nonmyeloablative conditioning followed by hematopoietic cell allografting and donor lymphocyte infusions for patients with metastatic renal and breast cancer. *Blood* 2002;99:4234-6.
- Hentschke P, Barkholt L, Uzunel M, Mattsson J, Wersall P, Pisa P, et al. Low-intensity conditioning and hematopoietic stem cell transplantation in patients with renal and colon carcinoma. *Bone Marrow Transplant* 2003;31:253-61.
- Predrazzoli P, Da Prada GA, Giorgiani G, Schiavo R, Zambelli A, Giraldo E, et al. Allogeneic blood stem cell transplantation after a reduced-intensity, preparative regimen. *Cancer* 2002;94:2409-15.
- Rini BI, Zimmerman T, Stadler WM, Gajewski TF, Vogelzang NJ. Allogeneic stem-cell transplantation of renal cell cancer after nonmyeloablative chemotherapy: feasibility, engraftment, and clinical results. *J Clin Oncol* 2002;20:2017-24.
- Motzer RJ, Russo P. Systemic therapy for renal cell carcinoma. *J Urol* 2000;163:408-17.

Come to our website to earn Continuing Medical Education credits!

Each month, four multiple-choice questions are presented both in the print journal and on the Internet. To participate in the monthly CME program, registered physicians are invited to go online to:

cme.haematologica.org