

Characterization of skin blister fluids from children with Epstein-Barr virus-associated lymphoproliferative disease

著者	Wada Taizo, Toma Tomoko, Miyazawa Hanae, Koizumi Eiko, Shirahashi Tetsujiro, Matsuda Yusuke, Yachie Akihiro
著者別表示	和田 泰三, 東馬 智子, 白橋 徹志郎, 谷内江 昭宏
journal or publication title	Journal of Dermatology
volume	45
number	4
page range	444-449
year	2018-04-02
URL	http://doi.org/10.24517/00050510

doi: 10.1111/1346-8138.14226

Type of paper: Original Article

Characterization of skin blister fluids from children with Epstein-Barr virus-associated lymphoproliferative disease

Taizo Wada, Tomoko Toma, Hanae Miyazawa, Eiko Koizumi, Tetsujiro Shirahashi, Yusuke Matsuda, and Akihiro Yachie

Institutional affiliations:

Department of Pediatrics, School of Medicine, Institute of Medical, Pharmaceutical and Health Sciences, Kanazawa University, Kanazawa, Japan.

Correspondence to: Taizo Wada, MD, PhD
Department of Pediatrics, School of Medicine,
Institute of Medical, Pharmaceutical and Health Sciences,
Kanazawa University
13-1 Takaramachi, Kanazawa 920-8641, Japan
Phone: +81-76-265-2313
Fax: +81-76-262-1866
E-mail: taizo@staff.kanazawa-u.ac.jp

Running title: Skin blister fluids in EBV-LPD

ABSTRACT

Epstein-Barr virus (EBV)-associated T- or natural killer (NK)-cell lymphoproliferative disease (LPD) is a heterogeneous group of disorders characterized by chronic proliferation of EBV-infected lymphocytes. Patients may present with severe skin manifestations, including hypersensitivity to mosquito bites (HMB) and hydroa vacciniforme (HV)-like eruption, which are characterized by blister formation and necrotic ulceration. Skin biopsy specimens show inflammatory reactions comprising EBV-infected lymphocytes. However, blister fluids have not been fully assessed in patients with this disease. Blister fluids were collected from three patients with EBV-associated LPD: two with HMB and one with HV. Immunophenotyping of blister lymphocytes and measurement of tumor necrosis factor (TNF)- α in blister fluids were performed. The patients with HMB and HV exhibited markedly increased percentages of NK and $\gamma\delta$ T cells, respectively, in both peripheral blood and blister fluids. These NK and $\gamma\delta$ T cells strongly expressed the activation marker HLA-DR and were considered to be cellular targets of EBV infections. TNF- α was highly elevated in all blister fluids. Severe local skin reactions of EBV-associated LPD might be associated with infiltrating EBV-infected lymphocytes and a high TNF- α concentration in blister fluids.

Key words: blister fluids; Epstein-Barr virus; hydroa vacciniforme; hypersensitivity to mosquito bites; lymphoproliferative diseases.

INTRODUCTION

Epstein-Barr virus (EBV) is a ubiquitous herpes virus that infects more than 90% of human and persists in B cells for the lifetime of the seropositive normal hosts.¹ Primary EBV infection is usually asymptomatic, but occasionally causes infectious mononucleosis, which resolves spontaneously after the emergence of EBV-specific immunity. EBV rarely infects T or natural killer (NK) cells in healthy individuals, and chronic proliferation of those EBV-infected cells causes EBV-associated T- or NK-cell lymphoproliferative diseases (LPD).² EBV-associated T- or NK-cell LPD shows diverse clinical manifestations ranging from localized forms, such as hypersensitivity to mosquito bites (HMB) and hydroa vacciniforme (HV) to systemic forms, such as chronic active EBV infection (CAEBV).³

CAEBV is characterized by persistent or recurrent infectious mononucleosis-like symptoms and extremely high viral loads in peripheral blood.^{4,5} Patients with CAEBV typically present with prolonged fever, lymphadenopathy and hepatosplenomegaly. Based on the cellular targets of EBV, CAEBV can be divided into T-cell type and NK-cell type infections, and T-cell type CAEBV is further subdivided into CD4⁺, CD8⁺, and $\gamma\delta$ T cell-type infections.⁶ Patients with CAEBV may show cutaneous manifestations, including HMB or HV-like eruptions.

HMB is characterized by large erythematous swellings, blister formation and necrotic ulcerations after exposure to mosquito bites.^{7,8} In patients with HMB, vaccinations may precipitate similar cutaneous lesions. HMB has also been associated with NK-cell type CAEBV, but rarely with T-cell type CAEBV.⁹ Patients with HV

present with characteristic skin lesions, including vesicle, crust and scar formation, which recurrently occur on sun-exposed areas with onset in childhood.¹⁰ Some of these patients may show systemic manifestations, including fever, lymphadenopathy and liver dysfunction, that are associated with T-cell type CAEBV.¹¹ The immunological mechanisms leading to local skin reactions such as HMB and HV are largely unknown. In this study, we examined skin blister fluids from three children with EBV-associated LPD to determine the association of cellular and humoral factors with severe local skin reactions.

METHODS

Patients

The subjects were three Japanese patients with EBV-associated T- or NK-cell LPD. Clinical and immunological data for the patients are shown in Table 1. Patients 1 and 2 have been described in previous case reports,^{12,13} in which these patients were referred to as patients 1 and 3, respectively.¹³ Patient 3 was an 11-year-old boy who developed vesicle, crust and scar formation on sun-exposed skin at age 10 years (Figure 1A). A diagnosis of HV was made at age 11, when skin biopsy specimens showed the presence of the EBV genome. There was no history of HMB in this patient. Approval for the study was obtained from the Human Research Committee of Kanazawa University Graduate School of Medical Science, and informed consent was obtained according to the Declaration of Helsinki.

Cell preparation and in situ hybridization for EBV-encoded small RNA1 (EBER1)

Peripheral blood mononuclear cells (PBMCs) were isolated by Ficoll-Hypaque gradient centrifugation from patients and controls. Peripheral blood lymphocytes (PBLs) were prepared from PBMCs by depletion of monocytes using anti-CD14 monoclonal antibody (mAb)-coated magnetic beads. CD4⁺ T, CD8⁺ T, CD19⁺ B, and CD56⁺ NK cells were then purified by positive selection from PBLs using mAb-coated magnetic beads.¹⁴ To obtain $\gamma\delta$ T cells, PBLs were stained with biotin-conjugated anti-T-cell receptor (TCR) $\gamma\delta$ mAb, followed by incubation with streptavidin-coated magnetic beads (all from Becton Dickinson, San Diego, CA). The purities of the isolated $\gamma\delta$ T, CD4⁺ T, CD8⁺ T,

CD19⁺ B, and CD56⁺ NK cells from patient 3 were 98.3, 94.4, 88.4, 80.1, and 86.2%, respectively, as determined by flow cytometric analysis. In situ hybridization for EBER-1 was performed as described previously.¹⁴

Flow cytometry

Blister fluids from the patients were collected into syringes. Flow cytometric analysis of blister lymphocytes was performed immediately after sample collection. All incubation and washing steps were carried out in ice-cold phosphate-buffered saline. After lysis of erythrocytes and washing, stained cells were analyzed with a FACSCalibur flow cytometer using CellQuest software (BD Bioscience, Tokyo, Japan).¹² HLA-DR was used as the activation marker on $\gamma\delta$ T or CD56⁺ NK cells. Blister fluids from three children with “simple” mosquito allergy who exhibited erythema and blister formations after mosquito bites were utilized as disease controls.¹⁵ Despite the presence of blister formation, there were no systemic symptoms and no evidence of lymphoproliferative diseases in the three controls.

Tumor necrosis factor (TNF)- α measurement

After centrifugation, blister samples were stored at -80°C until use. Concentrations of TNF- α were determined using an enzyme-linked immunosorbent assay kit (R&D Systems, Minneapolis, MN).¹⁶ Analysis of significant differences between groups was performed using a Student *t*-test for unpaired samples. A difference with $P < 0.05$ was considered significant.

RESULTS

Patient characteristics

Patients 1 and 2 showed typical clinical features of HMB, such as intense local skin reactions accompanied by general symptoms including fever and abnormal liver function, after mosquito bites (Figure 1A). Patient 3 showed characteristic skin findings of HV, but no systemic manifestations of fever, lymphadenopathy or liver dysfunction. Serological tests for EBV indicated past infection, and EBV DNA loads in peripheral blood were markedly increased in all patients (Table 1). The percentage of EBER-1-positive cells in the population of PBMCs from patients 1, 2 and 3 were 43.2%, 27.2%, and 14.4%, respectively. Ectopic EBV infection of CD56⁺ NK cells was found in patient 1 (81.6%),¹² whereas the dominant population of EBER-1-positive cells was $\gamma\delta$ T cells in patient 3 (58.6%), who showed negligible expression of EBER-1 in CD4⁺ T, CD8⁺ T, CD19⁺ B, and CD56⁺ NK cells (Figure 1B). We were unable to analyze the cellular target of EBV in patient 2 because no appropriate sample was available. Flow cytometric analysis of peripheral lymphocytes showed markedly increased percentages of NK cells from patients 1 and 2, and of $\gamma\delta$ T cells from patient 3 (Table 1). These NK and $\gamma\delta$ T cells strongly expressed the activation marker HLA-DR (Figure 2).

Patients 1 and 2 underwent successful stem cell transplantation at age 8 and 10 years, and are alive with no evidence of recurrence at age 16 and 14 years, respectively. Patient 3 is now 12 years old, and prophylactic care including the use of sunscreens effectively reduces the severity of skin reactions.

Characterization of skin blister fluids

Because blisters do not develop on skin in healthy individuals, there are no reference values for immunophenotyping of lymphocytes infiltrated into skin blister fluids. Therefore, we utilized blister fluids from children with “simple” mosquito allergy as controls. Most blister-infiltrated cells were found to be CD203c⁺ cells, which were assumed to be basophils and/or mast cells. Small populations of CD3⁺ T and CD56⁺ NK cells were also identified in these fluids (Table 2).¹² In contrast to the controls with mosquito allergy, there were significant increases in the percentages of CD56⁺ NK cells in patients 1 and 2, and of $\gamma\delta$ T cells in patient 3. Most of these NK and $\gamma\delta$ T cells expressed HLA-DR, similarly to circulating NK and $\gamma\delta$ T cells in the respective patients (Figure 2). An analysis of TNF- α in blister fluids (Figure 3) showed that TNF- α was markedly elevated in the patients, but was not elevated in the controls with mosquito allergy. However, this result failed to reach statistical significant because of the small sample size.

DISCUSSION

The clinical features of the three patients in this study were consistent with EBV-associated LPD. Patient 1 had a diagnosis of NK-cell type CAEBV,¹² which represents the major type of EBV-associated NK cell-LPD.⁶ In patient 2, the cellular target of EBV infection was not analyzed, but NK-cell type CAEBV was also likely in this case because of the presence of NK cell lymphocytosis, high serum IgE levels, and HMB.¹⁷ Patient 3 was diagnosed with HV. This disease is divided into classical and severe HV, both of which exhibit a high EBV viral load and increased percentages of $\gamma\delta$ T cells in peripheral blood.¹⁸ Patients with severe HV show systemic manifestations, including fever, lymphadenopathy and liver dysfunction, and may progress to malignant lymphoma.¹⁹ Because this condition is closely related to T-cell type CAEBV and it is difficult to predict which patients will develop overt lymphoma, the term HV-like lymphoma has been changed to HV-like LPD in the 2016 World Health Organization classification of lymphoid neoplasms.²⁰ In patient 3, the lack of general symptoms supports the diagnosis of classical HV; however, it should be noted that systemic inflammation may behave in an indolent fashion.²¹

HMB and HV are characterized by severe local skin reactions such as blister formation and necrotic ulcerations.³ Blister formation can be due to various causes, including inflammation, infection, injury, autoimmune and genetic defects.^{22, 23} Accumulation of fluids within the epidermis causes the epidermis to lift and results in blister formation in a setting of inflammation and infection. Skin biopsy specimens of HMB and HV show inflammatory reactions composed of EBV-infected lymphocytes and

reactive lymphocytes.^{8, 11} Therefore, characterization of blister fluids may allow an additional assessment of the local immunological conditions in skin lesions. In this study, we found that most blister-infiltrated cells were NK cells in patients 1 and 2, and $\gamma\delta$ T cells in patient 3, and all these cells were assumed to be infected with EBV. Similarly to circulating EBV-infected lymphocytes, these infiltrated cells markedly expressed activation marker HLA-DR, suggesting their involvement in severe local skin reactions. In addition, blister fluids from the patients had much higher levels of TNF- α compared with those from controls with simple mosquito allergy. We did not examine the cellular sources of TNF- α production in blister fluids, but the markedly high TNF- α level might also be associated with the severe local skin reactions in the patients. From a diagnostic point of view, these assessments of skin blister fluids may provide clues that lead to diagnosis of EBV-associated T- or NK-cell LPD.

Careful interpretation of the results of cellular compositions and inflammatory cytokines in blister fluids is needed because the time to sampling after blister formation may influence the findings. In addition, there is a possibility that peripheral blood can contaminate blister fluids. However, blister fluids from the patients had much lower percentages of cells that were not infected by EBV, compared to peripheral blood. Accordingly, the appearance of NK or $\gamma\delta$ T cells in the blister fluids was probably a consequence of infiltration of EBV-infected cells, rather than contamination with peripheral blood. Other limitations of the study include the small number of patients and the small amount of blister fluid, which did not allow performance of multiple cytokine analysis and serial flow cytometric analysis. Further studies will be necessary to understand the pathogenesis underlying severe local skin reactions in association with

EBV infection in patients with EBV-associated LPD. Because sampling of blister fluids is less invasive compared to skin biopsy, our approach may be clinically beneficial in diagnosis of children with suspected EBV-associated LPD.

In summary, this study demonstrated the usefulness of characterization of blister fluids and suggests that EBV-infected cells and a high TNF- α level in blister fluids are associated with the pathogenesis of severe local skin reactions in EBV-associated T- or NK-cell LPD.

ACKNOWLEDGMENTS

We thank Ms. Harumi Matsukawa and Ms. Kaori Ishihara for their excellent technical assistance.

CONFLICT OF INTEREST

None declared.

REFERENCES

1. Rickinson AB, Long HM, Palendira U, Munz C, Hislop AD. Cellular immune controls over Epstein-Barr virus infection: new lessons from the clinic and the laboratory. *Trends Immunol* 2014; **35**: 159-69.
2. Cai Q, Chen K, Young KH. Epstein-Barr virus-positive T/NK-cell lymphoproliferative disorders. *Exp Mol Med* 2015; **47**: e133.
3. Gru AA, Jaffe ES. Cutaneous EBV-related lymphoproliferative disorders. *Semin Diagn Pathol* 2017; **34**: 60-75.
4. Straus SE. The chronic mononucleosis syndrome. *J Infect Dis* 1988; **157**: 405-12.
5. Okano M, Kawa K, Kimura H *et al*. Proposed guidelines for diagnosing chronic active Epstein-Barr virus infection. *Am J Hematol* 2005; **80**: 64-9.
6. Kimura H, Ito Y, Kawabe S *et al*. EBV-associated T/NK-cell lymphoproliferative diseases in nonimmunocompromised hosts: prospective analysis of 108 cases. *Blood* 2012; **119**: 673-86.
7. Tokura Y, Ishihara S, Tagawa S *et al*. Hypersensitivity to mosquito bites as the primary clinical manifestation of a juvenile type of Epstein-Barr virus-associated natural killer cell leukemia/lymphoma. *J Am Acad Dermatol* 2001; **45**: 569-78.
8. Asada H. Hypersensitivity to mosquito bites: a unique pathogenic mechanism linking Epstein-Barr virus infection, allergy and oncogenesis. *J Dermatol Sci* 2007; **45**: 153-60.
9. Kimura H, Hoshino Y, Hara S *et al*. Differences between T cell-type and natural killer cell-type chronic active Epstein-Barr virus infection. *J Infect Dis* 2005; **191**: 531-9.

10. Iwatsuki K, Xu Z, Takata M *et al.* The association of latent Epstein-Barr virus infection with hydroa vacciniforme. *Br J Dermatol* 1999; **140**: 715-21.
11. Iwatsuki K, Satoh M, Yamamoto T *et al.* Pathogenic link between hydroa vacciniforme and Epstein-Barr virus-associated hematologic disorders. *Arch Dermatol* 2006; **142**: 587-95.
12. Wada T, Yokoyama T, Nakagawa H *et al.* Flow cytometric analysis of skin blister fluid induced by mosquito bites in a patient with chronic active Epstein-Barr virus infection. *Int J Hematol* 2009; **90**: 611-5.
13. Sakakibara Y, Wada T, Muraoka M *et al.* Basophil activation by mosquito extracts in patients with hypersensitivity to mosquito bites. *Cancer Sci* 2015; **106**: 965-71.
14. Toga A, Wada T, Sakakibara Y *et al.* Clinical significance of cloned expansion and CD5 down-regulation in Epstein-Barr Virus (EBV)-infected CD8⁺ T lymphocytes in EBV-associated hemophagocytic lymphohistiocytosis. *J Infect Dis* 2010; **201**: 1923-32.
15. Peng Z, Simons FE. Advances in mosquito allergy. *Curr Opin Allergy Clin Immunol* 2007; **7**: 350-4.
16. Wada T, Muraoka M, Yokoyama T *et al.* Cytokine profiles in children with primary Epstein-Barr virus infection. *Pediatr Blood Cancer* 2013; **60**: E46-8.
17. Kimura H, Hoshino Y, Kanegane H *et al.* Clinical and virologic characteristics of chronic active Epstein-Barr virus infection. *Blood* 2001; **98**: 280-6.
18. Hirai Y, Yamamoto T, Kimura H *et al.* Hydroa vacciniforme is associated with increased numbers of Epstein-Barr virus-infected gammadeltaT cells. *J Invest Dermatol* 2012; **132**: 1401-8.

19. Cohen JI, Kimura H, Nakamura S, Ko YH, Jaffe ES. Epstein-Barr virus-associated lymphoproliferative disease in non-immunocompromised hosts: a status report and summary of an international meeting, 8-9 September 2008. *Ann Oncol* 2009; **20**: 1472-82.
20. Swerdlow SH, Campo E, Pileri SA *et al.* The 2016 revision of the World Health Organization classification of lymphoid neoplasms. *Blood* 2016; **127**: 2375-90.
21. Ohshima K, Kimura H, Yoshino T *et al.* Proposed categorization of pathological states of EBV-associated T/natural killer-cell lymphoproliferative disorder (LPD) in children and young adults: overlap with chronic active EBV infection and infantile fulminant EBV T-LPD. *Pathol Int* 2008; **58**: 209-17.
22. Welsh B. Blistering skin conditions. *Aust Fam Physician* 2009; **38**: 484-90.
23. Turcan I, Jonkman MF. Blistering disease: insight from the hemidesmosome and other components of the dermal-epidermal junction. *Cell Tissue Res* 2015; **360**: 545-69.

Table 1. Patient characteristics

	P1	P2	P3	Normal range
Age at onset (y)	7	8	10	
Age at diagnosis (y)	7	9	11	
Sex	Male	Male	Male	
Symptoms	HMB, fever, liver damage	HMB, fever, liver damage	Hydroa vacciniforme	
WBC (/μL)	7,400	4,990	4,070	4,000-10,500
Lymphocytes (/μL)	2,310	1,370	2,210	1,500-3,000
sIL-2R (IU/mL)	2,053	1,929	451	145-519
Ferritin (μg/L)	152	376	32	25-280
IgE (IU/mL)	1,055	10,020	633	<696
EBV titer*				
VCA-IgG	40	40	80	<10
VCA-IgM	<10	NA	<10	<10
EBNA	40	80	20	<10
EBV DNA loads (copies/ 10 ⁶ WBC)	1.3x10 ⁶	2.8x10 ⁴	2.3x10 ⁵	<2.0x10 ¹
EBV terminal repeat	monoclonal	monoclonal	NA	
Lymphocyte subsets (%)				
γδ ⁺ T cells	1.4	1.0	24.8	4.4 ± 2.4
CD3 ⁺ T cells	36.3	41.9	81.9	69.5 ± 4.6
CD4 ⁺ T cells	23.1	34.3	30.3	43.1 ± 6.0
CD8 ⁺ T cells	9.5	15.0	24.4	22.0 ± 5.4
CD20 ⁺ B cells	3.5	8.5	8.2	11.2 ± 3.5
CD56 ⁺ NK cells	51.8	38.6	8.5	12.8± 5.3
HLA-DR ⁺ cells	60.1	51.7	44.3	NA

* EBV titers were measured by immunofluorescence assay and are expressed as reciprocal serum dilutions. EBNA, Epstein-Barr virus nuclear antigen; HMB, hypersensitivity to mosquito bites; NA, not available; NK, natural killer; sIL-2R, soluble interleukin-2 receptor; VCA, viral capsid antigen; WBC, white blood cell.

Table 2. Immunophenotype of lymphocytes in blister fluids

	P1	P2	P3	Mosquito allergy (n=3)
$\gamma\delta^+$ T cells	NA	NA	84.8	2.5 \pm 1.4
CD3 ⁺ T cells	11.5	30.6	89.1	15.6 \pm 5.5
CD4 ⁺ T cells	NA	29.8	2.3	11.5 \pm 5.5
CD8 ⁺ T cells	NA	2.0	5.2	7.4 \pm 7.2
CD56 ⁺ NK cells	66.8	52.9	1.2	7.2 \pm 2.8
CD203c ⁺ cells	5.5	5.6	4.5	62.9 \pm 17.8

Data are expressed as percentages. NA, not available.

Figure Legends

Figure 1. Skin lesions and characterization of EBV-infected cells. (a) Intense inflammatory skin lesions after mosquito bites (patients 1 and 2) and after sun exposure (patient 3). (b) Detection of EBER-1⁺ cells in $\gamma\delta$ T cells, but not in CD4⁺ T, CD8⁺ T, CD19⁺ B, and CD56⁺ NK cells, from patient 3.

Figure 2. Flow cytometric analysis of peripheral blood and skin blister fluids. Peripheral blood and blister samples were stained with monoclonal antibodies for anti-CD56 or anti-TCR Pan $\gamma\delta$ together with anti-HLA-DR.

Figure 3. Tumor necrosis factor (TNF)- α concentration in blister fluids. Data represent the mean \pm standard deviation. EBV, Epstein-Barr virus; LPD, lymphoproliferative disease.

Figure 1

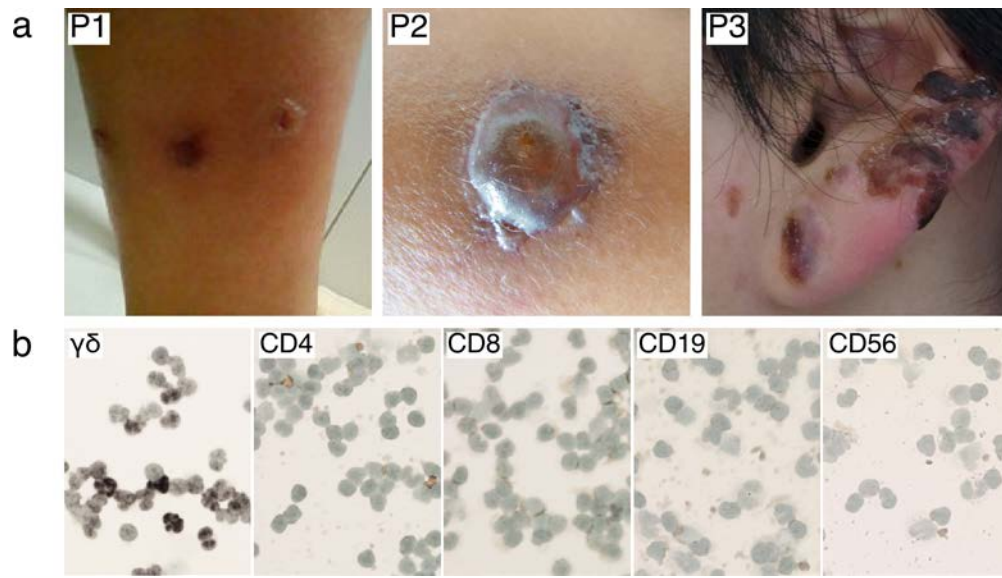


Figure 2

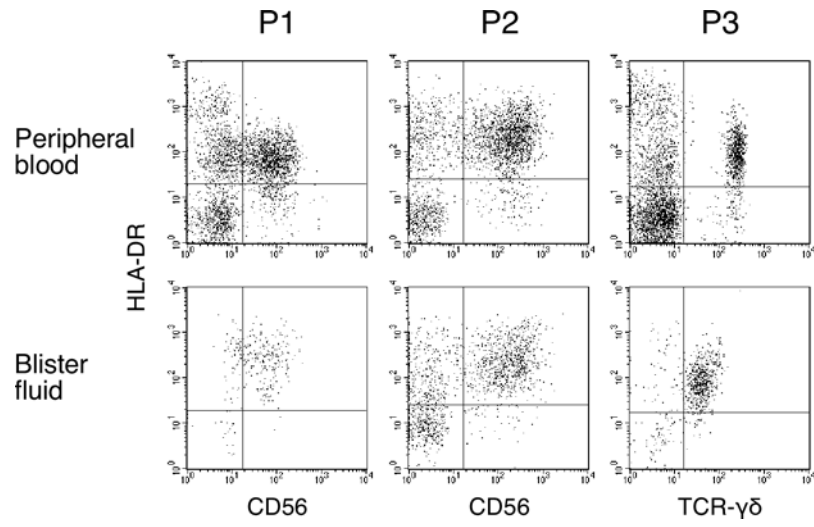


Figure 3

