

A prospective observational study using sea cucumber and honey as topical therapy for diabetic foot ulcers in Indonesia

Haryanto^{***}, Kazuhiro Ogai^{***}, Suriadi^{**}, Gojiro Nakagami^{****}, Makoto Oe^{*****}, Toshio Nakatani^{*****},
Mayumi Okuwa^{*****}, Hiromi Sanada^{****}, Junko Sugama^{*****}

Abstract

Background

In vitro and in vivo studies have indicated that the sea cucumber has biological and pharmacological activities, including antiinflammatory, antimicrobial, antibacterial, antibiofilm, and wound healing activities. However, there have been no studies to evaluate the effects of sea cucumber on wound healing in clinical settings.

Objective

This study was performed to evaluate wound healing of diabetic foot ulcers (DFUs) using sea cucumber and to evaluate the effects of sea cucumber on biofilm, tumor necrosis factor alpha (TNF- α), matrix metalloproteinase (MMP-2), and matrix metalloproteinase (MMP-9).

Subjects and Methods

This study had a prospective cohort design. The study population consisted of 42 DFU patients with new ulcers; 21 each were treated using sea cucumber and honey. This study was conducted at two sites: Kitamura Wound Care Clinic and the Outpatient Wound Care Clinic at Soedarso General Hospital, Pontianak, West Kalimantan, Indonesia, from March 2016 to February 2017. The participants were followed up for 12 weeks.

Results

There were significant differences in the TNF- α level between weeks 0 vs. 8, 0 vs. 10, and 0 vs. 12 in the sea cucumber group ($p = 0.005$, $p = 0.006$, and $p = 0.010$, respectively; Steel post hoc test). There was no significant difference in the change in pattern of biofilm-like staining from positive to negative between the groups ($p = 0.55$, Fisher's exact test). There was no significant difference in wound healing between the sea cucumber and honey groups ($p = 0.66$; Kaplan-Meier analysis, log rank test).

Conclusion

These results indicated that sea cucumber could be used as an alternative wound dressing for DFUs in a clinical setting.

KEY WORDS

sea cucumber, biofilm, matrix metalloproteinases, diabetic foot ulcer

* Graduate Course of Nursing Sciences, Division of Health Sciences, Kanazawa University, Japan

** The Institute of Nursing Muhammadiyah, Pontianak, Indonesia

*** Wellness Promotion Science Center, Institute of Medical, Pharmaceutical and Health Sciences, Kanazawa University, Japan

**** Department of Gerontological Nursing/Wound Care Management, Division of Health Sciences and Nursing, Graduate School of Medicine, The University of Tokyo, Japan

***** Division of Care Innovation Global Nursing Research Center Graduate School of Medicine, The University of Tokyo

***** Department of Clinical Nursing, Institute of Medical, Pharmaceutical and Health sciences, Kanazawa University, Japan

***** Advanced Health Care Science Research Unit Innovative Integrated Bio-Research Core Institute for Frontier Science Initiative, Kanazawa University, Japan

INTRODUCTION

The prevalence of diabetes mellitus (DM) is increasing in Indonesia. In 2015, Indonesia had 10.0 million DM patients, which was the seventh-highest globally; this number is expected to increase to 16.2 million by 2040¹⁾. A national survey showed that Ternate (19.6%) and West Kalimantan (11.1%) regions have the highest prevalence of DM²⁾.

One of the most common complications of DM is diabetic foot ulcers (DFUs). DFUs occur in 15%–25% of DM patients³⁻⁴⁾. DFUs often result in lower extremity amputation, and it is the most common reason (54%) for admission to hospitals in Indonesia⁵⁾. This condition affects people's quality of life and psychological and socioeconomic statuses⁶⁻⁸⁾. DFU cases are increasing with the prevalence of DM.

DFUs are a chronic or nonhealing wound. Unlike acute wounds, chronic wounds are characterized by increasing expression of tumor necrosis factor alpha (TNF- α) and interleukin one beta (IL-1 β), which have various effects on different cells. In acute inflammations, inflammatory cytokines such as TNF- α are produced by macrophages. Furthermore, TNF- α induces macrophages to produce IL-1 β , which is mitogenic to fibroblasts and upregulates metalloproteinase (MMP) expression. Consequently, TNF- α and IL-1 β cause persistent inflammation in chronic wounds; they also cause the deposition of collagen by fibroblasts and upregulate MMP expression⁹⁾. This causes an increase or imbalance in MMPs, especially MMP-2/MMP-9 and MMP-1¹⁰⁾. MMPs are a family of calcium-dependent zinc-containing enzymes that are involved in the degradation of the extracellular matrix¹¹⁾. MMPs play important roles in wound healing, including facilitating cell migration, removing the damaged matrix, and remodeling the new scar matrix⁹⁾. Two MMPs perform important functions in normal wound healing during both remodeling and reepithelialization: MMP-2 (gelatinase-A) and MMP-9 (gelatinase-B)¹²⁾. Another factor that influences the healing of DFUs is high blood sugar. High blood glucose stimulates macrophage to enhance the production of proinflammatory cytokines such as IL-1 β , IL-6, and TNF- α ¹³⁾. Therefore, TNF- α , MMP-2, MMP-9, and high blood glucose are internal factors that influence the healing of DFUs.

DFU healing is also influenced by external factors such as infection (biofilm). Infection are caused by bacterial

colonization or biofilms. Biofilms are composites of bacterial or fungal cells that are encased in an extracellular matrix comprising hydrated polymers and debris¹⁴⁾. Up to 60% of biofilms are microscopically identifiable in chronic wounds¹⁵⁾. Various bacteria and biofilms can cause elevated MMP levels in chronic wounds¹⁶⁾. As a result, the wound healing process may get delayed or may fail. Therefore, local wound management to treat infections and promote wound healing is important.

One aspect of local wound management is the dressing. In Indonesia, complementary dressings such as honey are used as wound dressings in both clinics and hospitals. Honey is the first choice for dressing wounds that are necrotic, sloughed, or infected. Studies have reported on the beneficial effects of honey on wound healing¹⁷⁾. Generally, honey comprises approximately 40% glucose, 40% fructose, 20% water, amino acids, vitamin and minerals¹⁸⁾ as well as enzymes and phytochemicals such as flavonoids and ferulic and caffeic acids¹⁹⁾. In addition, honey has antibacterial²⁰⁾, antibiofilm²¹⁻²³⁾, immunostimulatory²⁴⁻²⁵⁾, and antiinflammatory²⁶⁻²⁷⁾ effects. However, the availability of honey depends on the season. Therefore, an alternative is needed to substitute for the use of honey in clinical settings.

Another complementary therapy is sea cucumbers. Sea cucumber are found throughout the year; in fact, Indonesia is the world's largest producer of sea cucumbers²⁸⁾. A sea cucumber is a marine animal that contains various bioactive compounds, including triterpene glycosides (saponins)²⁹⁻³⁰⁾, sulfated polysaccharides³¹⁾, phenolics³²⁾, and fatty acids (FAs)³³⁻³⁴⁾. Several studies have reported that sea cucumbers have biological and pharmacological activities including antiinflammatory³⁵⁾, antimicrobial and antibacterial³⁶⁻³⁹⁾, antibiofilm⁴⁰⁾, and wound healing⁴¹⁾ activities. These studies were conducted in vivo and in vitro. However, no study has evaluated the effect of sea cucumbers on wound healing in clinical settings.

In this study, we hypothesize that sea cucumbers are effective for wound healing and that they eliminate biofilms and reduce MMPs (MMP-2 and MMP-9) and TNF- α levels in DFUs. The primary outcome in this study was to evaluate wound healing using sea cucumbers on DFUs. The secondary outcome was to evaluate the effect of sea cucumbers on biofilms, TNF- α , MMP-2 and MMP-9 levels.

MATERIALS AND METHODS

1. Study design

This study was a prospective observational design.

2. Subject

The study population were DFU patients with new ulcers. The inclusion criteria were patients who were ≥ 21 years of age, Wagner grading system 2–4, ankle brachial index (ABI) of 0.7–1.2, and willing and able to give informed consent to participate in the study. The exclusion criteria were subjects who have systemic signs of infection or gangrenous ulcers. Participant came to facilities and were selected by researcher according to inclusion criteria.

3. Setting

This study was conducted at two sites: Kitamura wound care clinic (30 DFU patients who visited in one day) and the outpatient wound care clinic at Soedarso General Hospital (12 DFU patients who visited in one day) in Pontianak, West Kalimantan, Indonesia, from March 2016 to February 2017. The specialist nurse decided one patient to be the honey group and another patient to be the sea cucumber group based on wound bed condition and clinical experience. All wound care procedures were performed by 15 and 5 specialist nurses at these respective sites. Wound care was based on standard management (cleansing and debridement) .

4. Materials

1) Sea cucumber

Sea cucumbers (*Sthicopus hermannii*) from Sukadana district were provided in gel form by the laboratory at the Pharmacy Academy in Pontianak, West Kalimantan.

Extraction of sea cucumber

Sea cucumbers were dried at room temperature for 2 weeks and then pulverized in laboratory at Academy of Pharmacy, Yarsi, Pontianak. The pulverized sea cucumbers were macerated in ethanol 96% for 48 hour. After 48 hour, the mixture was filtered and the extract concentrated using a rotary evaporator set at 40°C and were stored at 4-8°C for further use.

Preparation of gel base

The preparation of gels containing Carbopol 940 was dissolved in 100 mL, triethanolamine gradually were added while homogenized. Then methyl paraben was mixtured until until a clear consistent gel base was obtained.

Preparation of gel formulation

Gel formulation was prepared using ethanol sea

cucumber extract (2.5%) , the gel base of carbopol 940 (1.75 %) , methyl paraben (0.18%) , and triethanolamine (1.75%) .

2) Pure honey

Commercially available honey (*Apis dorsata*) was used. The honey was sterilized and stored in a sterile container.

5. Measurement outcomes

1) Primary outcome

The primary outcome in this study was healing. Healing was defined as complete epithelialization of the wound based on an observation using Diabetic Foot Ulcer Assessment Scale (DFUAS) (total score: 0) . DFUAS is a wound assessment tool that was developed in Indonesia to evaluate the severity of diabetic foot ulcer and monitor the wound healing process using 11 domains (depth, size, size score, inflammation/infection, proportion of slough, maceration, type of wound edge and tunneling) . The minimum and maximum scores on this scale are 0 and 98, respectively; higher scores indicate more severe wounds. This tool already was established validity by Arisandi D, et al.⁴²⁾ The DFU wounds were photographed after they were cleaned. Healing was validated every 2 weeks or until the end of the study. DFUAS was evaluated by one researcher (H).

2) Secondary outcomes

(1) Biofilm-like staining

For biofilm detection, wound blotting was performed on the wound surface after debridement and cleansing before sea cucumber and honey application. The biofilm-like staining procedure was based on the study by Nakagami et al.⁴³⁾ . The wound was cleaned, and then, the wound and surrounding skin were wiped dry. A nitrocellulose membrane was firmly pressed to the wound bed for 10 s. The blotted membranes were stored at 4°C until staining. For biofilm-like staining, the blotted membranes were hydrated with phosphate-buffered saline (PBS) and stained for total proteins using a reversible protein stain kit (Thermo Fisher Scientific, Waltham, MA) according to the manufacturer's instructions to confirm whether the blotting membrane was properly attached to the wound surface. The blot was then destained prior to staining for biofilm-like structures. Ruthenium red (5 mg/mL; Wako Pure Chemical Industries, Tokyo, Japan) was used to detect mucopolysaccharides in the bacterial biofilm. After staining for 1 min, the membrane was washed by soaking in a 40% methanol + 10% acetic acid solution for 30 min

three times to reduce the amount of nonspecifically bound staining solution, thereby facilitating clearer visualization. The stained membranes were then scanned and evaluated by the researcher to determine whether the biofilm-like staining was positive or negative. In this study, we considered biofilm-like staining positive when the stain color was red, orange, or brown. Then, we determined the reduction in biofilm-like staining according to the pattern from baseline to week 4 (positive to positive or positive to negative), and we compared it with the reduction in the DFUAS total score at weeks 0 and 4. We chose week 4 because this time predicts healing at 12 weeks⁴⁴. The sea cucumber or honey treatment was considered effective if the pattern changed from positive to negative and the DFUAS total score at week 4 was lower than that at week 0. However, the reduction in biofilm like-staining was considered ineffective if the pattern did not change or the DFUAS total score at week 4 was not lower. For a wound area larger than the membrane size, we placed the membrane at the wound center, which was determined based on the maximum length and width perpendicular to each other. Biofilms were obtained every 2 weeks or until the end of the study.

(2) Biomarkers (TNF- α , MMP-2, and MMP-9)

Biomarkers were detected by wound blotting by a procedure similar to that for biofilm-like staining. TNF- α , MMP-2, and MMP-9 were analyzed by immunostaining. For simultaneous visualization of TNF- α , MMP-2, and MMP-9 on the membrane, primary antibodies for TNF- α (sc-1350, goat polyclonal; Santa Cruz Biotechnology, Dallas, TX, USA), MMP-2 (sc-10736, rabbit polyclonal; Santa Cruz Biotechnology), and MMP-9 (sc-21733, mouse monoclonal; Santa Cruz Biotechnology) and secondary antibodies for TNF- α (Alexa Fluor 488-conjugated donkey anti-goat IgG antibody; ab150133; Abcam plc., Cambridge, UK), MMP-2 (Alexa Fluor 555-conjugated donkey anti-rabbit IgG antibody; ab150062; Abcam plc.), and MMP-9 (Alexa Fluor 647-conjugated donkey anti-mouse IgG antibody; ab150111; Abcam plc.) were used. The wound blotting membranes were hydrated with PBS and blocked with Blocking One solution (Nacalai Tesque Inc., Kyoto, Japan) for 20 min. The membranes were then incubated with the mixture of primary antibodies (TNF- α , 1:250; MMP-2, 1:250; MMP-9, 1:250) at room temperature for 1 h. After washing, the membranes were incubated with the mixture of secondary antibodies (488-anti-goat

IgG, 1:1500; 555-anti-rabbit IgG, 1:500; 647-anti-mouse IgG, 1:750) at room temperature for 1 h. After washing again, the stained membranes were then scanned using a Typhoon 9400 imager. The scanner setup was as follows: for TNF- α , 526 SP filter, laser blue 488, normal sensitivity, PMT: 550 V; for MMP-2, 580 BP 30 filter, laser green 532, normal sensitivity, PMT: 600 V; and for MMP-9, 670 BP 30 filter, laser red 633, normal sensitivity, PMT: 600 V. For distribution analysis, we used images of the total protein staining for edge determination⁴⁵ with two criteria: (1) when the wound edge could be determined clearly, protein signals were quantified within the wound edge (i.e., wound area); and (2) when the wound edge was ambiguous, the protein signals were quantified for the entire membrane region. The intensity of each protein was analyzed by using ImageJ software (National Institutes of Health, Bethesda, MD, USA)⁴⁶. Then, the integrated signal intensity was normalized by dividing by the wound area. Biomarker were obtained every 2 weeks or until the end of the study.

3) Compounding factors

Demographic data were obtained using a developed minimum data sheet. The questions were related to age, gender, occupation, medical history, body mass index, glycemic status, smoking status, type of DM therapy, year of onset of DM treatment, and ABI. The Wagner grading system, wound onset, triggers, location, and bacteria count were used to compare the patient groups. Wound blotting was used to obtain the biofilm and biomarkers (TNF- α , MMP-2, and MMP-9).

6. Statistical analysis

We used IBM SPSS software (version 22.0., IBM Corp., Armonk, NY, USA) to analyze patients and wound characteristics by the Chi-square and Fisher tests. Independent t-test and Mann-Whitney U-test were used for comparisons between groups, and the Kolmogorov-Smirnov test was used for the normal distribution of variables. Healing outcomes were compared between groups by the Kaplan-Meier Survival curve and log-rank test. The nonparametric Kruskal-Wallis test and Steel post-hoc test were used for comparisons within groups. The level of significance was set at $p < 0.05$.

7. Ethical considerations

This study was approved by the ethics committee of the Department of Medical Sciences at Kanazawa University (ref. no. 643-1), Kitamura Wound Care Clinic

(Number: 001/KTMR/1/16) , and Soedarso General Hospital, Pontianak (Number: 178/III.AU/F/I/2016) . This research was performed according to the principles of the Declaration of Helsinki. Informed consent was obtained from the patients and their family members.

RESULTS

1. Patient characteristics

Figure 1 shows the flow of participants through the study. Forty-two patients were enrolled from the two sites. Of these, 21 participants each used sea cucumbers and honey. The results shown in Table 1 indicate that there were no significant differences between them.

2. Wound characteristics

DFUAS was similar in both groups. The proportion of tissue granulation showed significant differences between

the groups ($p = 0.01$) . The sea cucumber group had 11 participants (52.4%) with peripheral arterial disease and the honey group had 12 participants (57.1%) with peripheral arterial disease. The Wagner scale, triggers, wound site, biofilm-like staining distribution, and median wound onset did not show statistically significant differences between the two groups (Table 2) .

3. Healing outcomes

The Kaplan-Meier curve showed no significant difference between the groups (log rank test: $p = 0.66$; sea cucumber group: $N = 7, 7/21$ (33%) ; honey group: $N = 8, 8/21$ (38%) (Figure 2) .

4. Change in pattern biofilm-like staining

As shown in Table 3, 10 participants from the sea cucumber group showed positive biofilm-like staining. At week 4, one participant showed positive biofilm-

Table 1. Patient characteristics of both groups

Variables	HG (N=21)	SCG (N=21)	p-value
Gender, no,			1.00 ^d
Female	12 (57.14%)	15 (71.40%)	
Male	9 (42.86%)	6 (28.60%)	
Age (years),	56.23±9.18	52.23±12.04	0.23 ^a
BMI (kg/m²),	22.00 (19-30)	22.00 (18-35)	0.63 ^b
Occupation, no,			0.65 ^c
Housewife	11 (52.30%)	11 (52.30%)	
Private worker	4(19.10%)	5 (23.80%)	
Civil servant	3 (14.30%)	2 (9.50%)	
Farmer	0 (0%)	1 (4.80%)	
Retired	3 (14.30%)	1 (4.80%)	
None	0 (0%%)	1 (4.80%)	
Duration of DM in years,	6.95±4.69	7.70±5.59	0.65 ^a
Treatment of DM, no,			
Oral	14 (66.67%)	17 (80.95%)	0.48 ^c
Insulin	7(33.33%)	4 (19.05%)	
Fasting Blood Sugar (mg/dl),	264.40±135.20	282.8±110.20	0.63 ^a
Body temperature (°C),	36.60±0.50)	36.5±0.70	0.88 ^a
Blood pressure (mmHg),			
Systole	126 (110-190)	130 (90-172)	0.80 ^b
Diastole	80 (69-100)	80 (65-108)	0.70 ^b
HbA1c (%),	12.5 (7.2-14)	13.5 (8.7-14)	0.33 ^b
Ankle Brachial Index(mmHg), no,			
0.40-0.90	9(42.86%)	10 (47.62%)	0.11 ^c
0.91-1.30	12(57.14%)	11 (52.38%)	
Neuropathy, no,	10 (47.61%)	10 (47.61%)	1.00 ^c
Smoking, no,			0.50 ^d
None	20 (95.24%)	19 (90.48%)	
Smoker	1(4.76%)	2(9.52%)	

HG, honey group, SCG, Sea cucumber group; BMI, body mass index; DM, diabetes mellitus; n, participants. Data are presented as mean± standard deviation, median (min-max) and percentage; a. t independent test, b. Mann-Whitney, c. chi-square, d. Fisher exact test (* $p < 0.05$)

Table 2. Wound Characteristics

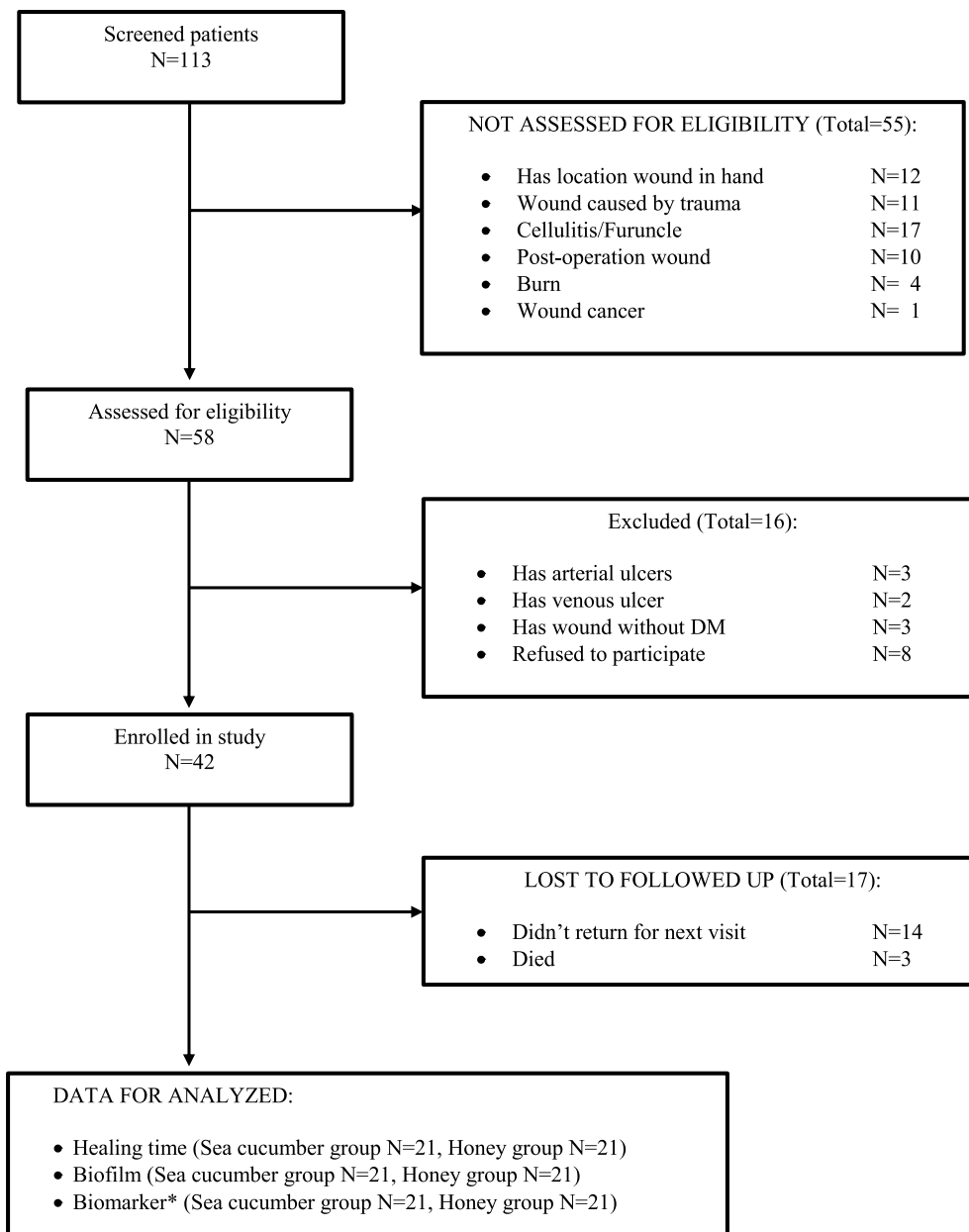
Variables	HG (N=21)	SCG (N=21)	p-Value
DFUAS			
Depth	2(2-4)	2(2-4)	0.56 ^a
Size	5(2-9)	5(2-9)	0.76 ^a
Size Score	5(1-5)	5(1-5)	0.67 ^a
Inflammation/infection	1(1-2)	1(1-2)	1.00 ^a
Proportional of granulation tissue	0(0-5)	3(0-5)	0.01 ^{a*}
Necrotic Tissue			
a) Type of necrotic tissue	1(0-2)	1(0-2)	0.98 ^a
b) Proportional of necrotic tissue	5(0-5)	4(0-5)	0.83 ^a
c) Proportional of slough	5(0-5)	4(0-5)	0.83 ^a
Maceration	0(0-1)	0(0-2)	0.60 ^a
Type of wound edge	4(4-5)	4(3-5)	0.78 ^a
Tunneling	0(0-0)	0(0-0)	1.00 ^a
Total score	30 (11-50)	27 (15-49)	0.60 ^a
Wound onset (days)	7.0 (2-60)	7.0 (2-365)	0.99 ^a
Trigger, no. (%),			
Unknown	11 (52.4)	10 (47.6)	0.94 ^c
Trauma	7 (33.3)	7 (33.3)	
Needle	1 (4.8)	2 (9.5)	
Footwear	2 (9.5)	2 (9.5)	
Wound site, no. (%),			
Toe	5 (23.8)	7 (33.3)	0.43 ^c
Forefoot	4 (19.0)	1 (4.8)	
Midfoot	1(4.8)	4 (19.0)	
Dorsal	4(19.1)	5 (23.8)	
Heel	5 (23.8)	3 (14.3)	
Malleolus	2 (9.5)	1 (4.8)	
Bacteria count (CFU/ml), (N=20), no. (%),			
<10⁶	7(35.0)	4(20.0)	0.32 ^c
10⁶-10⁷	13(65.0)	16(80.0)	
Wagner scale, no. (%),			
2	13 (61.9)	10 (47.6)	0.33 ^c
3	7 (33.3)	7 (33.3)	
4	1 (4.8)	4 (19.0)	
Biofilm-like staining, no. (%),			0.45 ^c
Positive	12 (57.1)	16 (76.2)	
Negative	9 (42.9)	5 (23.8)	

HG, honey group, SCG, Sea cucumber group, DFUAS, Diabetic foot ulcer assessment scale; Data are presented as median (min-max) and percentage; a. Mann-Whitney, b. Fisher exact, c. Chi-square test
* $p < 0.05$

Table 3. Comparing of changing pattern positive to negative between sea cucumber and honey group at week 4

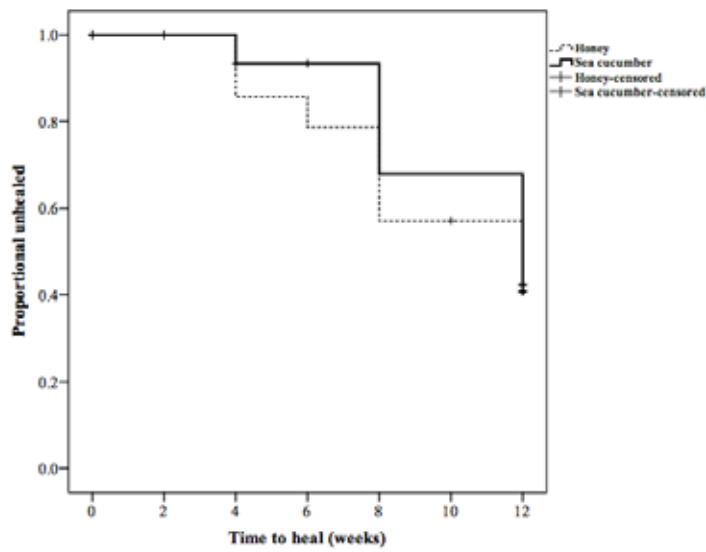
Group	Pattern of biofilm-like staining weeks	p- Value	Proportion of reduction of DFUAS total score
	0-4		
Sea cucumber	Positive to Positive (n=1)	0.55	1/1 (100%)
	Positive to Negative (n=9)		8/9 (88.9%)
Honey	Positive to Positive (n=3)		3/3 (100%)
	Positive to Negative (n=7)		5/7 (71.4%)

n, participant; Data are presented percentage, Fisher exact test



* MMP-2, MMP-9 and TNF-α

Figure 1. Flow chart of participants



Groups		0	2	4	6	8	10	12
Sea cucumber (N)		21	18	15	13	11	8	7
Honey (N)		21	15	14	12	11	8	8

Figure 2. Kaplan-Meier survival curve depicting healing outcome between groups. There were no significant between groups (log rank test $P=0.66$). Honey healed (N=8) and sea cucumber group (N=7)

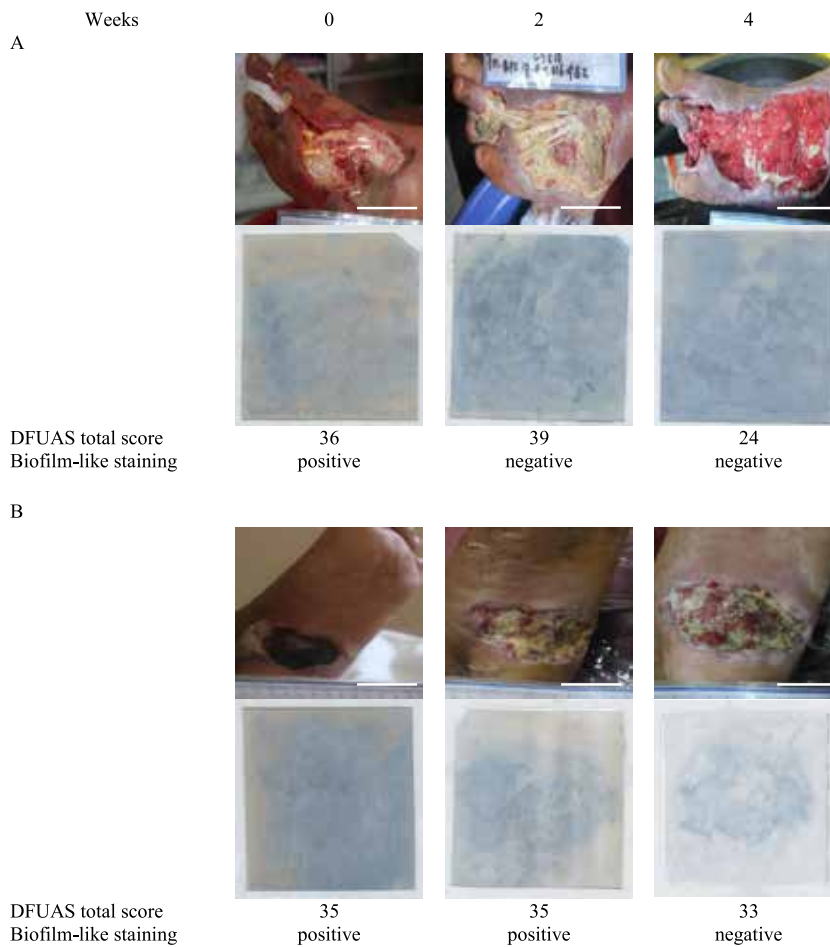


Figure 3. Representative for change in pattern biofilm-like staining and DFUAS total score from weeks 0 to 4. (A) Change in pattern biofilm-like staining and DFUAS total score sea cucumber group. (B) Change in pattern biofilm-like staining and DFUAS total score honey group. Scale bars=1cm

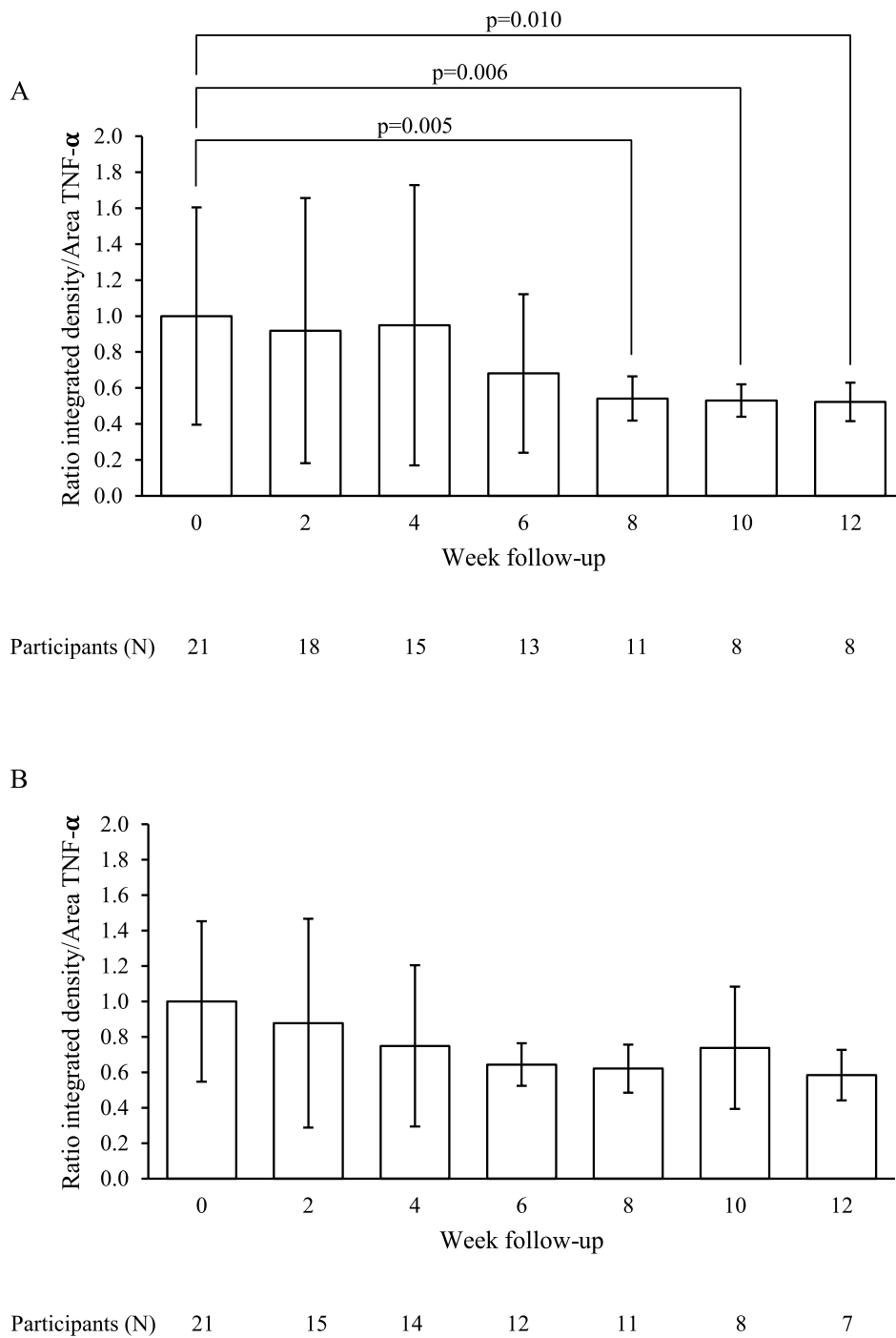
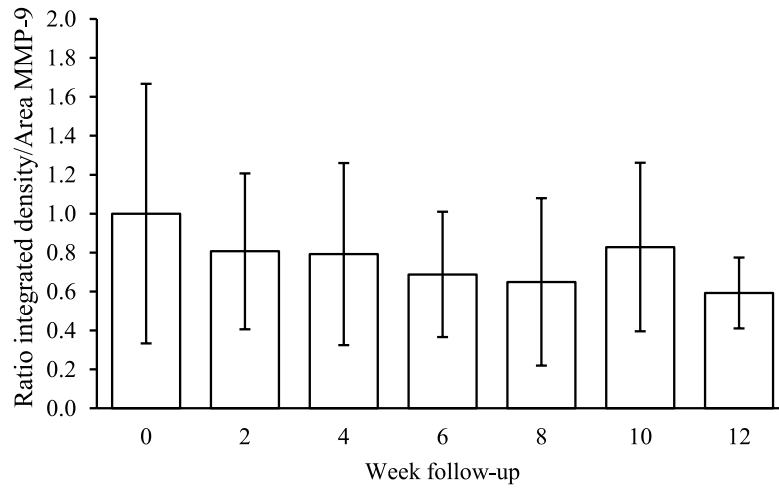


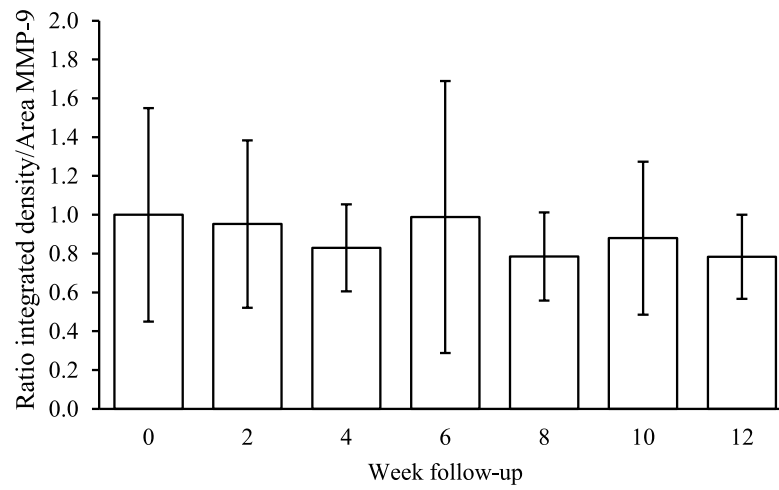
Figure 4. TNF- α level from weeks 0 to 12. (A) There were significant differences within sea cucumber group between week 0 vs 8 ($p=0.005$), 0 vs 10 ($p=0.006$), and 0 vs 12 ($p=0.010$). (Steel post hoc test, versus 0 week). (B) Changing of TNF- α level of honey group. There was no significant difference. Data are presented as mean \pm standard deviation.

A



Participants (N) 21 18 15 13 11 8 8

B



Participants (N) 21 15 14 12 11 8 7

Figure 5. MMP-9 level from weeks 0 to 12. (A) Changing of MMP-9 level of sea cucumber group. (B) Changing of MMP-9 level of honey group. There were no significant differences each group. Data are presented as mean \pm standard deviation.

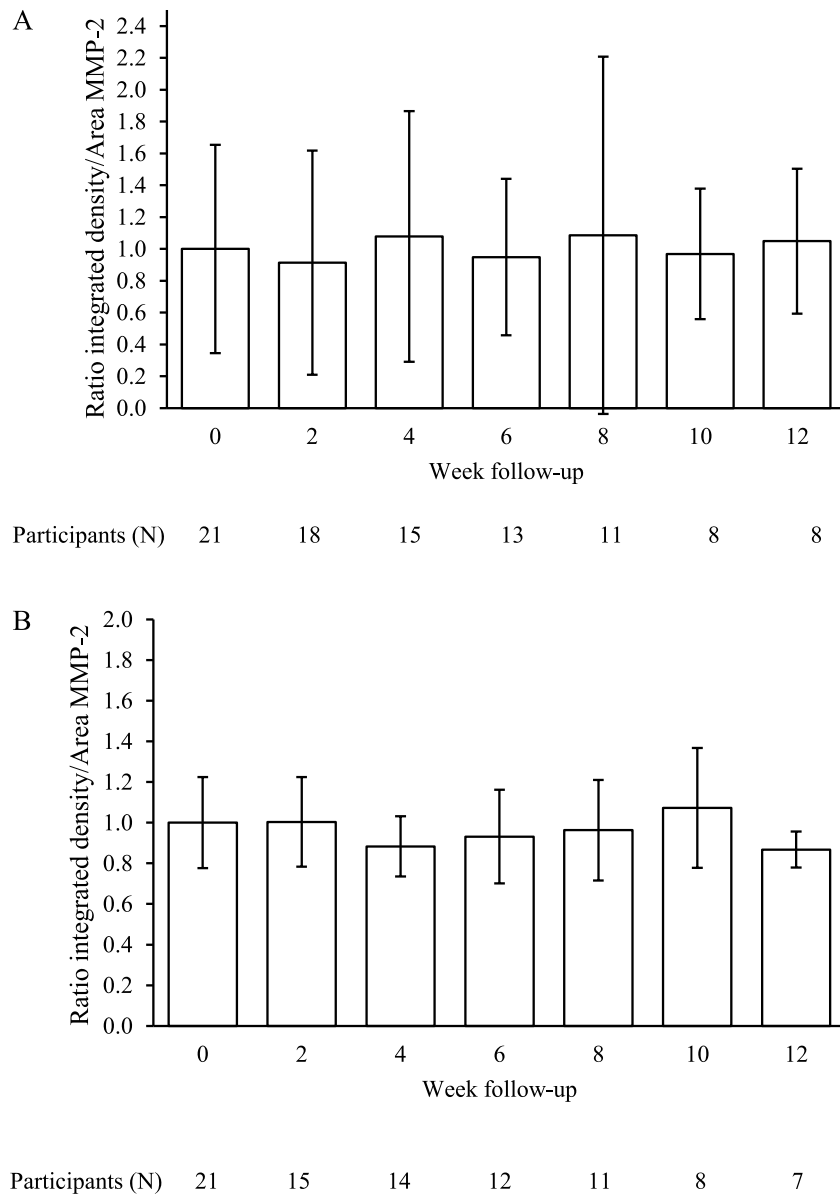


Figure 6. MMP-2 level from weeks 0 to 12. (A) Changing of MMP-2 level of sea cucumber group. (B) Changing of MMP-2 level of honey group. There were no significant differences each group. Data are presented mean \pm standard deviation.




Figure 7. Representative images of the stained membranes with anti-TNF- α (A) , anti-MMP-9 (B) , and anti-MMP-2 (C) antibodies from the wound same patient. The value was intensity that was analyzed by using Image J. Then, the integrated signal intensity was normalized by dividing by the wound area. The lines were wound area

like staining (unchanged) . Nine participants showed negative biofilm-like staining (changed) , and eight showed reduced DFUAS total score (88.9%) . In the honey group, 10 participants showed positive biofilm-like staining. At week 4, three participants showed positive biofilm-like staining (unchanged) . Seven participants showed negative biofilm-like staining (changed) , and five showed reduced DFUAS total score (71.4%) . There was no significant difference in the change in pattern from positive to negative ($p = 0.55$) . Representative for change in pattern biofilm-like staining and DFUAS total score from weeks 0 to 4 (Figure 3) .

5. Change in TNF- α , MMP-2, and MMP-9 levels

There were significant differences in the TNF- α level between weeks 0 versus 8, 0 versus 10, and 0 versus 12 in the sea cucumber group ($p = 0.005$, $p = 0.006$, and $p = 0.010$, respectively) (Figure 4A) . However, the honey group showed no significant differences ($p = 0.09$) (Figure 4B) . There was no significant difference in MMP-9 levels in both the sea cucumber group ($p=0.35$) (Figure 5A) and the honey group ($p=0.79$) (Figure 5B) . Similarly, there was no significant difference in MMP-2 levels in both the sea cucumber group ($p = 0.58$) (Figure 6A) and the honey group ($p = 0.47$) (Figure 6B) . The highest value was the darkest image. The images were shown in Figure 7.

6. Adverse events

Local skin redness was seen after treatment in both the sea cucumber group ($n = 1$ (4.76%)) and honey group ($n = 2$ (9.52%)) . This condition was referred to a doctor. The doctor recommended that the participants remain involved in this study. The skin redness disappeared by itself without treatment.

DISCUSSION

In the present studies, we found new finding including the effect of sea cucumbers on the TNF- α level, effect of sea cucumbers on biofilm, and wound healing on sea cucumbers. To the best of our knowledge, this is first study using sea cucumber compared honey on diabetic foot ulcer in clinical setting. We found that the TNF- α level in the sea cucumber group was significantly reduced at weeks 8, 10, and 12 compared with the honey group. This finding agreed with our hypothesis that sea cucumbers were effective in reducing the TNF- α level in patients with DFUs. The antiinflammatory effect of

sea cucumbers may be explained by the mechanism that the water fraction of sea cucumber inhibits the release of nitric oxide (NO) and proinflammatory cytokines such as TNF- α and IL-6⁴⁷⁾ . The major fatty acids (FAs) in sea cucumber were eicosapentaenoic acid (EPA) and docosahexaenoic acid (DHA) . EPA and DHA produce resolvins and protectins (antiinflammatory mediators) through the cyclooxygenase (COX-2) and lipoxygenase (5-LOX) pathways. Resolvins inhibit IL-1 β production, and protectin inhibits TNF and IL-1 β production⁴⁸⁾ . Sea cucumbers also contain saponin; it can prevent the lipopolysaccharide-induced production of TNF- α by blocking the transcription factor nuclear factor kappa-light-chain-enhancer of activated B cell (NF- κ B) that regulates the transcription of many genes associated with inflammation⁴⁹⁾ . Therefore, we believe that sea cucumber is effective as an antiinflammatory agent for DFU compared with honey because of the compounds it contains. Honey contains phenolic compounds, including flavonoids, that work as antiinflammatory agents. However, honey does not contain FAs and saponin, which also act as antiinflammatory agents⁵⁰⁾ . Therefore, sea cucumbers may have a stronger antiinflammatory effect than honey. However, we did not identify the contents of sea cucumber gel in this study. Therefore, its use needs to be validated through future research.

In our result, the pattern changed from positive to negative and DFUAS total score reduced in 88.9% of sea cucumbers. Sea cucumber contains bioactive compounds such as FAs. FAs are ubiquitous molecules that are typically found bound to other compounds such as glycerol, sugar, or phosphate headgroups to form lipids. FAs can be released from lipids, typically by enzymatic action, to form free fatty acids (FFAs) ; FFAs have diverse and potent biological activities, including antibacterial effects⁵¹⁾ . FFAs could inhibit and kill bacteria by creating unfavorable conditions for the growth of certain bacteria, such as acidic pH⁵²⁾ . Therefore, we believe that this mechanism can explain the effect of sea cucumbers on biofilm.

A comparison of wound healing between sea cucumbers and honey showed no significant differences. This finding did not agree with our hypothesis. We believe that two factors influence this result. Internal factors include high blood glucose, MMP-2, and MMP-9 levels. In our data, hemoglobin A1c (HbA1c) in both groups is high

(hyperglycemia) . HbA1c > 12 is associated with reduced neutrophil function, including leukocyte chemotaxis⁵³⁾ . Hyperglycemia affects wound healing through the formation of advanced glycation end product (AGEs) that induce the production of inflammatory molecules (TNF- α and IL-1) and interfere with induced collagen synthesis⁵⁴⁾ . In addition, high blood glucose is associated with changes in cellular morphology, decreased proliferation, and abnormal differentiation of keratinocytes⁵⁵⁾ . Another internal factor is MMP. MMP-2 is secreted by fibroblasts for the synthesis of collagen, and MMP-9 is secreted by leukocytes for keratinocyte migration during wound closure⁵⁶⁾ . In our data, the MMP-2 and MMP-9 levels remained stable, and there were no significant differences between both groups. Salo et al.⁵⁷⁾ evaluated acute experimental wounds in the oral mucosa and showed that the MMP-2 level remained stable during wound healing. In addition, Arumugam et al.⁵⁸⁾ reported that the MMP-2 and MMP-9 level persisted even after wound closure. External factors include neuropathy and ischemia. Our data showed that 52.4% and 57.1% of patients in the sea cucumber and honey groups had arterial problems (ischemia or hypoxia) . Prolonged hypoxia caused by inadequate perfusion and insufficient angiogenesis is highly detrimental to wound healing⁵⁸⁾ . Neuropathy also influences wound healing in DFUs (our data (Table 2) showed no significant differences between the groups) . Neuropathy refers to a communication problem of neurons, particularly peripheral nerves by neuropeptides. Neuropeptides such as nerve growth factor, substance P, and calcitonin-gene-related peptide are relevant to wound healing, because they promote cell chemotaxis, induce growth factor production, and stimulate cell proliferation⁵⁹⁾ . Thus, the factors in both groups were similar. As a result, in this study, wound healing did not show significant differences between the sea cucumber and the honey groups.

CLINICAL IMPLICATIONS

The use of sea cucumbers was preferable in the inflammatory phase and as an antibiofilm agent for chronic wounds, particularly those in DFUs. In addition, sea cucumber was safer than honey as wound dressing for DFUs. Therefore, sea cucumbers could be used as an alternative wound dressing in a clinical setting.

LIMITATIONS

The current study had several limitations. First, the study population included participants with new ulcers. New and recurrent ulcers show different healing depending on the wound bed condition. The recurrent ulcers had scar so that the wound healing will be different with the new ulcers. Second, the confounding control used was HbA1c. In our study, all participants had HbA1c above the normal value (6.5%) . If the A1c value is normal, wounds heal faster than our data. Third, we only used one type of sea cucumber and honey; however, different types may have different effects on wound healing. Fourth, the selection of participants in this study were chosen by the specialist nurse based on wound bed condition and clinical experience. To reducing bias, the selection of participants was better by randomly. Finally, the sample size was relatively small. Thus, the generalizability of these results may be limited.

CONCLUSION

The results of this study demonstrated that sea cucumber has an antiinflammatory effect. Sea cucumber reduced biofilms in DFU wounds. No significant differences were seen in DFU wound healing between sea cucumber and honey. Sea cucumbers were safer than honey dressing for DFUs in a clinical setting. These results indicated that sea cucumbers could be used as an alternative wound dressing in a clinical setting.

ACKNOWLEDGMENTS

We sincerely thank The Muhammadiyah Institute of Nursing and the staff and nurses of the Kitamura Wound Clinic and Soedarso General Hospital, Pontianak, Indonesia, for this cooperation during our research. This study was financially supported by a grant from The Muhammadiyah Institute, Pontianak, Indonesia, and a JSPS Kakenhi grant (no. 16H05852) . Japan.

REFERENCES

- 1) International Diabetes Federation: Diabetes Atlas. 7th ed. Available via [http:// www.idf.org/diabetesatlas](http://www.idf.org/diabetesatlas). Accessed 20 June 2017
- 2) Soewondo P, Ferrario A, Tahapary D: Challenges in diabetes management in Indonesia: a literature review. *Global Health* 9:1-17, 2013 doi:10.1186/1744-8603-9-63
- 3) Boulton AJ, Armstrong DG: Diabetic foot and ulceration: epidemiology and pathophysiology. London: Taylor & Francis, 2005
- 4) Boulton AJ: The diabetic foot. *Medicine* 38:644-648, 2010
- 5) Kementerian Kesehatan RI: InfoDATIN. Pusat data dan informasi 2014. <http://www.depkes.go.id>. Accessed 20 June 2017
- 6) Fejfarova V, Jirkovska A, Dragomirecka E, et al.: Does the diabetic foot have a significant impact on selected psychological or social characteristics of patients with diabetes mellitus? *J Diab Res* 3:1-7, 2014 doi:10.1155/2014/371938
- 7) Siersma V, Thorsen H, Holstein PE, et al.: Health-related quality of life predicts major amputation and death, but not healing, in people with diabetes presenting with foot ulcers: The Eurodiale study. *Diabetes Care* 37:694-700, 2014 doi:10.2337/dc13-1212
- 8) Nather A, Bee CS, Lin WK, et al.: Socioeconomic profile of diabetic patients with and without foot problems. *Diabet Foot Ankle* 1:1-6, 2010 doi:10.3402/dfa.v1i0.5523
- 9) Schultz GS, Mast BA: Molecular analysis of the environments of healing and chronic wounds: cytokines, protease and growth factors. *Wounds* 10 (suppl. F) :1F-9F, 1998
- 10) Lobmann R, Zemlin C, Motzkau M, et al.: Expression of matrix metalloproteinases and growth factors in diabetic foot wounds treated with a protease absorbent dressing. *J Diab Compli* 20:329-335, 2006 doi:10.1016/j.jdiacomp.2005.08.007
- 11) Caley MP, Martin, VLC, O'Toole, EA: Metalloproteinases and wound healing. *Adv Wound care* 4 (4) :225-235, 2015
- 12) Fray JM, Dickinson RP, Huggins JP et al.: A potent, selective inhibitor of matrix metalloproteinase-3 for the topical treatment of chronic dermal ulcers. *J Med Chem* 46: 3514-3525, 2003
- 13) Wen Y, Gu J, Li L, et al.: Elevated glucose and diabetes promote interleukin-12 cytokine gene expression in mouse macrophages. *Endocrinology* 147 (5) :2518-2525, 2006
- 14) Zhao G, Usui ML, Lippman SI, et al.: Biofilms and inflammation in chronic wounds. *Adv Wound Care* 2 (7) :389-399, 2013
- 15) McCarty SM, Percival SL: Proteases and delayed wound healing. *Adv Wound Care* 2 (8) :438-447, 2013
- 16) James GA, Swogger E, Wolcott R: Biofilms in chronic wounds. *Wound Rep Reg* 16:37-44, 2008
- 17) Molan P and Rhodes T: Honey: a biologic wound dressing. *Wounds* 27 (6) :141-151, 2015
- 18) Bergman A, Yanai J, Weiss J et al.: Acceleration of wound healing by topical application of honey. An animal model. *The American Journal of Surgery*, 9610 (Table III) :374-376, 2016 [http://doi.org/10.1016/0002-9610 \(83\) 90204-0](http://doi.org/10.1016/0002-9610(83)90204-0)
- 19) Wahdan H: Causes of the antimicrobial activity of honey. *Infection* 26:26-31,1997 doi:10.1007/BF02768748
- 20) Zainol MI, Mohd Yusoff K, Mohd Yusof MY: Antibacterial activity of selected Malaysian honey. *BMC Complement Altern Med* 13:1-10, 2013 doi:10.1186/1472-6882-13-129
- 21) Maddocks SE, Lopez MS, Rowlands RS et al.: Manuka honey inhibits the development of *Streptococcus pyogenes* biofilms and causes reduced expression of two fibronectin binding proteins. *Microbiology*. 158:781-790, 2012 doi:10.1099/mic.0.053959-0
- 22) Hammond EN, Donkor ES, Brown CA: Biofilm formation of *Clostridium difficile* and susceptibility to Manuka honey. *BMC Complement Altern Med* 14:1-6, 2014 doi:10.1186/1472-6882-14-329
- 23) Alandejani T, Marsan J, Ferris W et al.: Effectiveness of honey on *Staphylococcus aureus* and *Pseudomonas aeruginosa* biofilms. *Otolaryngol - Head Neck Surg* 141:114-118, 2009 doi:10.1016/j.otohns.2009.01.005
- 24) Tonks AJ, Cooper RA, Jones KP et al.: Honey stimulates inflammatory cytokine production from monocytes. *Cytokine* 21:242-247, 2003 doi:10.1016/S1043-4666 (03) 00092-9
- 25) Majtan J.: Honey: An immunomodulator in wound healing. *Wound Rep Regen* 22:187-192, 2014 doi:10.1111/wrr.12117
- 26) Kassim M, Achoui M, Mansor M et al.: The inhibitory effects of Gelam honey and its extracts on nitric oxide and prostaglandin E2 in inflammatory tissues. *Fitoterapia* 81:1196-1201, 2010 doi:10.1016/j.fitote.2010.07.024
- 27) Kassim M, Achoui M, Mustafa MR et al.: Ellagic acid, phenolic acids, and flavonoids in Malaysian honey extracts demonstrate in vitro anti-inflammatory activity. *Nutr Res* 30:650-659, 2010 doi:10.1016/j.nutres.2010.08.008
- 28) Choo P. Population status, fisheries and trade of sea cucumbers in Asia — The Philippines: A hotspot of sea cucumber fisheries in Asia. *FAO Fish Tech Pap*. 516:81-188, 2008
- 29) Kerr RG, Chen ZL: In vivo and in vitro biosynthesis of saponins in sea cucumbers. *J Nat Prod* 58:172-176,1995 doi:10.1021/np50116a002
- 30) Tian F, Zhang X, Tong Y, et al.: PE, a new sulfated saponin from sea cucumber, exhibits anti-angiogenic and anti-tumor activities in vitro and in vivo. *Cancer Biol Ther* 4:874-882, 2005 doi:10.4161/cbt.4.8.1917
- 31) Liu X, Sun Z, Zhang M, et al.: Antioxidant and antihyperlipidemic activities of polysaccharides from sea cucumber *Apostichopus japonicus*. *Carbohydrate Polymer* 90:1664-1670, 2012 doi:10.1016/

- j.carbpol.2012.07.047
- 32) Mamelona J, Pelletier É, Girard-Lalancette K, et al.: Quantification of phenolic contents and antioxidant capacity of Atlantic sea cucumber, *Cucumaria frondosa*. *Food Chem* 104:1040-1047,2007 doi:10.1016/j.foodchem.2007.01.016
 - 33) Fredalina BD, Ridzwan BH, Abidin AA, et al.: Fatty acid compositions in local sea cucumber, *Stichopus chloronotus*, for wound healing. *Genetic Pharmacol* 33:337-340, 1999 doi:10.1016/S0306-3623 (98) 00253-5
 - 34) Ridzwan BH, Hanita MH, Nurzafirah M et al.: Free fatty acids composition in lipid extracts of several sea cucumber species from Malaysia. *Int J Bioscien Biochem Bioinforma* 4:204-207, 2014 doi:10.7763/IJBBB.2014.V4.340
 - 35) Collin PD: Tissue fractions of sea cucumber for the treatment of inflammation 5,770,205. U.S. Patent. 1998
 - 36) Farouk AEA, Ghouse FAH, Ridzwan BH: New bacterial species isolated from Malaysian sea cucumbers with optimized secreted antibacterial activity. *Am J Biochem Biotechno* 3:64-69, 2007 doi:10.3844/ajbbsp.2007.60.65
 - 37) Mohammadizadeh F, Ehsanpor M, Afkhami M.: Evaluation of antibacterial, antifungal and cytotoxic effects of *Holothuria scabra* from the north coast of the Persian Gulf. *J Mycol Med* 23:225-229, 2013 doi:10.1016/j.mycmed.2013.08.002
 - 38) Ridzwan BH, Kaswandi MA, Azman Y et al.: Screening for antibacterial agents in three species of sea cucumbers from coastal areas of Sabah. *Gen Pharmacol* 26:1539-1543, 1995 doi:10.1016/0306-3623 (95) 00041-0
 - 39) Schillaci D, Cusimano MG, Schillaci D, et al.: Immune mediators of sea-cucumber *Holothuria tubulosa* (Echinodermata) as source of novel antimicrobial and anti-staphylococcal biofilm agents. *AMB Express* 3:1-10, 2013 doi:10.1186/2191-0855-3-35
 - 40) Vibrio B. Antibiofilm activity of an exopolysaccharide from marine. *6 (4) :1-11*, 2011 doi:10.1371/journal.pone.0018514
 - 41) Zohdi RM, Zakaria ZAB, Yusof N et al.: Sea cucumber (*Stichopus hermanii*) based hydrogel to treat burn wounds in rats. *J of Biomed Mat Res - Part B Applied Biomaterials* 98 B:30-37, 2001 <http://doi.org/10.1002/jbm.b.31828>
 - 42) Arisandi D, Oe M, Roselyne YR, et al.: Evaluation of validity of the new diabetic foot ulcer assessment scale in Indonesia. *Wound Repair Regen* 24:876-884, 2016 doi:10.1111/wrr.12464
 - 43) Nakagami G, Schultz G, Gibson DJ, et al.: Biofilm detection by wound blotting can predict slough development in pressure ulcers: A prospective observational study. *Wound Repair Regen* 25:131-138, 2017 doi:10.1111/wrr.12505
 - 44) Sheehan P, Jones P, Caselli A, et al.: Percent change in wound area of diabetic foot ulcer over a 4 week period is a robust predictor of complete healing in a 12 week prospective trial. *Diabetes Care* 26 (6) :1879-1882, 2003
 - 45) Minematsu T, Nakagami G, Yamamoto Y, et al.: Wound blotting: A convenient biochemical assessment tool for protein components in exudate of chronic wounds. *Wound Repair Regen* 21:329-334, 2013 doi:10.1111/wrr.12017
 - 46) Mayrovitz HN, Soontupe LB: Wound area by computerized planimetry of digital images: Accuracy and reliability. *Adv Skin Wound Care* 22:222-229, 2009
 - 47) Song M, Park Dong K, Cho M, et al.: Anti-inflammatory and anti-allergic activities of sea cucumber (*Stichopus japonicus*) extract. *Food Sci Biotechnol* 22 (6):1661-1666, 2013
 - 48) Calder PC: Omega-3 fatty acids and inflammatory process. *Nutrients* 2 (3) :355-374, 2010
 - 49) EL Barky AR, Ali EMM, Mohammed TM: Marine sea cucumber saponins and diabetes. *Austin Pancreatic Disorder* 1 (1) :1-4, 2017
 - 50) Alvarez MJ-Suarez, Gasparrini M, Tamara Y, et al: The composition and biological activity of honey: A focus on Manuka Honey. *Foods* 3 (7) 420-432, 2014. doi:10.3390/foods3030420
 - 51) Desbois, AP & Smith VJ: Antibacterial free fatty acids: Activities, mechanisms of action and biotechnological potential. *Applied Microbiology and Biotechnology*, 85:1629-1642, 2010. <http://doi.org/10.1007/s00253-009-2355-3>
 - 52) Takigawa H, Nakagawa H, Kuzukawa M, et al.: Deficient production of hexadecenoic acid in the skin is associated in part with the vulnerability of atopic dermatitis patients to colonization by *Staphylococcus aureus*. *Dermatology*, 211:240-248, 2005 <http://doi.org/10.1159/000087018>
 - 53) McMurry JF: Wound healing with diabetes mellitus. Better glucose control for better wound healing in diabetes. *Surg Clin North Am* 64:769-778, 1984
 - 54) Hennessey PJ, Ford EG, Black, CT et al.: Wound collagenase activity correlates directly with collagen glycosylation in diabetic rats. *J Pediatric Surgery*, 25 (1) :75-78, 1990.
 - 55) Spravchikov N, Sizyakov G, Gartsbein M, et al.: Glucose effects on skin keratinocytes: Implications for diabetes skin complications. *Diabetes* 50 (7) :1627-1635, 2001
 - 56) Caley MP, Martins Vera LC, O'Toole EA: Metalloproteinase and wound healing. *Adv Wound Care* 4 (4) :225-229, 2014
 - 57) Salo T, Makela M, Kylmaniemi M, et al.: Expression of matrix metalloproteinase-2 and -9 during early human wound healing. *Lab Invest* 70:176-182, 1994
 - 58) Arumugam S, Jang YC, Chen-Jensen C, et al.: Temporal activity of plasminogen activators and matrix metalloproteinases during cutaneous wound repair. *Surgery* 125:587-593, 1999
 - 59) Guo S, Dipetro LA: Factors affecting wound healing. *J Dent Res* 89 (3) :219-229, 2010

海鼠または蜂蜜局所管理法を受ける糖尿病足潰瘍の創傷治癒に関するインドネシアにおける前向き調査

ハリアント, 大貝 和裕, 仲上豪二郎, 大江 真琴,
中谷 壽男, 大桑麻由美, 真田 弘美, 須釜 淳子

要 旨

【背景】海鼠の抗炎症作用、抗菌作用、創傷治癒効果については生物学的、薬理的にあるいは実験動物にて報告されている。しかし臨床における創傷治癒効果については報告されていない。【目的】本研究の目的は海鼠の糖尿病足潰瘍（DFU）における創傷治癒効果をバイオフィーム、腫瘍壊死因子（TNF- α ）、マトリックス分解酵素（MMP）-2、9を指標として評価することである。【対象・方法】研究デザインは前向き観察研究である。42名の糖尿病患者に新規に発生したDFUに、海鼠あるいは蜂蜜が創部に使用された（各群21名）。調査場所は、インドネシア西カリマンタン・ポンティアナックにある創傷専門クリニックまたは創傷外来であった。調査期間は2016年3月から2017年2月であった。創傷は12週間観察された。【結果】海鼠使用群では、調査開始時と比べ8週、10週、12週のTNF- α が有意に低下した（ $p=0.005, 0.006, 0.010$ ）。両群のバイオフィーム陽性→陰性変化割合に有意差はなかった（ $p=0.55$, Fisher exact test）。さらに群間の創傷治癒に有意差はなかった（ $p=0.66$, Kaplan-Meier 解析, log rank test）。【結論】海鼠はDFUの創傷局所療法として使用可能であると示唆された。