

# Pathological studies on seabirds died of "Nakhodka" oil spill

著者	Yanai Tokuma, Sakai Hiroaki, Masegi Toshiaki
journal or publication title	"Heavy oil spilled from Russian tanker "Nakhodka" in 2008 : Towards eco-responsibility, earth sense"
page range	123-137
year	2003-10-01
URL	<a href="http://hdl.handle.net/2297/5528">http://hdl.handle.net/2297/5528</a>

# **Pathological Studies on Seabirds Died of "Nakhodka" Oil Spill**

**Tokuma YANAI, Hiroaki SAKAI and Toshiaki MASEGI**

*Department of Veterinary and Pathology, Gifu University, 1-1 Yanagido, Gifu,  
501-1193, JAPAN; e-mail: yanai@cc.gifu-u.ac.jp*

## **INTRODUCTION**

A shipwreck of oil tanker "Nakhodka" caused various disasters to animals, especially seabirds in January 2003. To assess influences of "Nakhodka" oil spill in seabird, dead seabirds collected in spilled area of the Japan Sea were examined histologically.

## **MATERIALS AND METHODS**

Totally 147 dead birds, which were collected via prefecture governmental offices in Nigata, Fukui, Yamagata, Ishikawa, Hyogo, Akita and Kyoto Prefecture, were sent to the Department of Veterinary Pathology, Gifu University, and were necropsied to determine their cause of death and affections of oil spill in various organs and tissues. Dead birds were stocked in deep-freezer till necropsy. The heart, lungs, trachea, liver, spleen, kidneys, ovaries, adrenals, thyroids, proventriculus, gizzard, small intestine, large intestine, cloacae, pancreas were collected and fixed in 10% buffered formalin. After fixation, the tissue blocks were dehydrated and embedded in paraffin wax in the usual manner, sectioned (5  $\mu$  m) and stained with hematoxylin and eosin (HE).

The species of birds, site of collection are as follows.

Of the birds necropsied at Gifu University (Total 147 birds), the largest number was Rhinoceros Auklet (61 birds; 41%), secondarily Ancient murrelet (53 birds; 36%). Other species of birds were no less than 10, a smaller number. This time, we examined dead birds when found, with exception of Ancient murrelets, which were found alive but died thereafter.

Prefectural Distribution of Collection

	Total	Nigata	Fukui	Yamagata	Ishikawa	Hyogo	Akita	Kyoto	Unknown
Rhinoceros Auklet	61	21	13	13	2		1		8
Ancient Murrelet	53	5		48					
Family Gaviidae	11								
Arctic Loon	9	4	3			1	1		
Red-throated Loon	2	2							
Family Phalacrocoracidae	9								
Temminck's Cormoran	7	2	2	2				1	
Pelagic Cormorant	2		2						
Family Podicipitidae	6								
Red-necked Grebe	4	2	2						
Great Crested Grebe	2					2			
Family Laridae	7								
Slaty-backed Gull	4	2	1			1			
Black-headed Gull	1		1						
Herring Gull	1		1						
Common Gull	1				1				
<b>Total</b>	<b>147</b>	<b>35</b>	<b>23</b>	<b>19</b>	<b>7</b>	<b>4</b>	<b>2</b>	<b>1</b>	<b>56</b>

**RESULTS****Ancient murrelets**

Fifty-three Ancient murrelets were necropsied in Gifu University, of which 47 birds were grossly intact without losses of organs and tissues, and were not able to weigh their body weights. The average body weights and sexes were as follows. Although there was no documents regarding collection sites, and found dead or alive, not a few birds seemed to receive external washing and treatments.

Sex

♂	♀	unknown	Total
22	25	6	53

Six birds, sex unknown, involved three ones with a heavy damage of visceral organs, and other three had difficulty to differentiate sex at necropsy.

Body weight

♂ (n=22)	♀ (n=23)	total (n=45)	indetermined (organs were lost, sex unknown)
202.0g	183.5g	192.6g	8

The body weight varied considerably. The average body weight was 145-295g in males, and 130-270 g in females. Although some factors were supposed to influence body weight changes, it was difficult to analyze the accurate reason of marked ranging in body weights because of lack in detailed information when collected.

### ***Oil stuck on the surface of body***

The degree of oil spill on the individual body surface was divided into four grades based on external square spoiled. The result was as follows.

#### **Grades of oil spill (external)**

-	+	++	+++
28.30%	30.20%	22.60%	18.9%
(15/53)	(16/53)	(12/53)	(10/53)

Grades, -:0% +:0~30% ++:30~80% +++:over 80%

### ***Presence of black oily contents in the alimentary tract***

Fifteen of 53 birds examined had various amounts of black oily contents in the alimentary tracts. Its occurrence sites in the alimentary tract were as follows;

	Oral	esophagus	Proventriculus	Gizzard	Small intestine	Large intestine
Birds No.7	-	-	+	+	+	-
13	-	-	+	+	+	+
24	-	-	-	-	+	+
25	-	-	+	+	+	+
26	-	-	+	+	+	+
27	-	-	-	+	+	+
28	-	-	+	+	+	+
29	-	-	-	+	+	-
31	-	+	-	+	+	+
32	+	+	+	+	+	+
35	-	-	-	-	-	+
37	-	+	-	+	+	+
40	-	-	-	+	-	+
42	-	+	+	+	+	+
43	-	-	+	+	+	+
44	-	-	+	+	+	+
48	-	-	+	+	+	+

-:negative +:positive

**Frequency of black oily contents**

	Oral	Esophagus	Proventriculus	Gizzard	Small intestine	Large intestine
Percent	2%	7.80%	20%	30%	30%	30%
Frequency	(1/50)	(4/51)	(10/50)	(15/51)	(15/50)	(15/50)

The discrepancy of the number among organs was due to exclusion of lost or damaged organs. Only four of 27 birds collected before January 14th, without detailed documents about life and death, had black contents in the gut (No. 1-24, 41, 43, 46), but after January 14th, 13 of 26 birds were positive for black contents in the gut (No. 25-40, 42, 44, 45, 47-53).

**Detection of Parasites**

Parasites found in gross and microscopic examination were as follows:

Renal trematoda	Esophageal nematode	Proventriculus nematode	Sarcocystis	Gizzard nematode
42.0%	7.8%	6.0%	4.1%	2.0%
(21/50)	(4/51)	(3/50)	(2/49)	(1/49)

Esophageal and proventricular nematodes were found at necropsy, and renal trematodes, sarcocystis, gizzard nematodes were found at microscopic examination with HE sections. Sarcocystis were observed in the skeletal muscle (thoracic muscle) in two birds, and no ones occurred in the cardio-muscle. Detailed classification of these parasites was done by Dr. Yokohata, Toyama University (1).

**Other macroscopic lesions**

Three birds showed loss of some organs, and 28 birds showed pulmonary edema in the lungs. In the liver, there were two cases of hepatomegaly, two cases of fatty liver, one focal necrosis, one liver abscess, and one blackened liver.

**Histopathological changes**

Histopathological changes were as follow;

Renal uric acid	Renal calculus	Proventriculus erosion	Renal trematode	Sarcocystis	Gizzard nematode
26%	14%	6.1%	42.0%	4.1%	2.0%
(13/50)	(7/50)	(3/49)	(21/50)	(2/49)	(1/49)

As mentioned in parasites, renal trematodas were frequently observed mainly in the beginning of the ureters, without apparent reactive inflammation.

In Family Alcidae, various degrees of depositions of uric acid (renal gout) were frequently observed in the medulla of the kidney, which lacked apparent inflammation and appeared to be fresh. Of 13 birds with renal gout, 11 affected birds were collected alive before January 14, and had received cleaning of feather while they were alive. Other two with renal gout were not sure if they received treatments when they were collected. Of 26 birds with oil spill on the feather without cleaning, only 2 birds had renal gout. This means that cleaned birds were collected alive and were not able to ingest foods and drink water due to heavy debility, dehydrated, and eventually might become hyper-uric acidemia.

As for renal stones, 7 birds had globoid or crystalline stones in the collecting tubules and the beginning of the ureter. These changes were not so heavy to induce obstruction and disturbance of renal function. In addition, all of 53 birds examined had edematous lesion in the lung but it was uncertain when the lesion occurred because of decorations by freezing or advanced autolysis. Fifteen of 50 birds showed macroscopic black contents in the gut, but it was not able to determine histologically how this contents gave damage to gastrointestinal mucosa because of advanced autolysis.

### **Rhinoceros auklet**

Total 61 Rhinoceros Auklets were examined at Gifu University, Department of Veterinary Pathology, all of which were collected as dead bodies. As bellow shown in the table, the number of males was larger 1.5 times than those of females, and total 14 birds were sex-unknown due to loss of sexual organs.

Sex in Rhinoceros auklet

♂	♀	sex-unknown	Total
30	17	14	61

The average body weights in males and females are shown in the following table. Thirteen birds with losses of organs and 11 birds with heavy oil spill on the body surface were excluded to achieve accurate weights.

The body weight varied considerably. The average body weight was 365-770g in

males, and 430-850 g in females. Although some factors were supposed to influence body weights, it was difficult to analyze the accurate reason for ranging because of shortage of information when they were collected.

Average body weights (g)

$\sigma$ (n=24)	$\text{♀}$ (n=9)
555.8	584.4

***Oil stuck on the surface of body***

The degree of oil spill was divided into four grades based on total squire spoiled. The result was as follows.

Grades of oil spill

-	+	++	+++
26.20%	31.10%	22.90%	19.70%
(16/61)	(19/61)	(14/61)	(12/61)
- : 0 %    + : 0~30%    ++ : 30~80%    +++ : over 80%			

***Frequency of black oily contents in the alimentary tracts***

	Oral	Esophagus	Proventriculus	Gizzard	Small intestine	Large intestine
Percent	6.90%	15.40%	54.20%	85.40%	91.10%	95.30%
Frequency	(4/58)	(8/53)	(26/48)	(41/48)	(41/45)	(41/43)

All birds except one had various amounts of black oily content in the alimentary tract; especially the gastrointestinal tracts from gizzard to the large intestine were highly affected.

***Other macroscopic lesions***

Other macroscopic changes were shown as below. Of 61 examined 13 birds showed loss of some organs due to tissue damages or advanced autolysis.

Other macroscopic changes

Liver	congestion	4/47
	white mottle	2/47
Lungs	congestion and pulmonary edem	22/49
Air sac	opacity	19/48

***Histopathological changes***

Gizzard erosion	Renal nematode	Renal calculus	renal uric acid
2/48	15/50	1/50	2/50
(4.2%)	(30%)	(2%)	(4%)

Fifteen birds, approximately 30%, had frequent renal nematodes, which occurred in the beginning of the ureter but induced no apparent inflammations. Only two of 50 birds had deposition of uric acid with radial fashions in the medulla of the kidneys, and were fresh without reactive inflammations. In cases of Rhinoceros Auklet most, most birds might die shortly after collection without having enough time to become hyper uric academia. Gizzard erosion and renal calculus were minimum changes, and not associated to cause of death Like Aalcidae family, although most cases had macroscopic black contents in the gastrointestinal tracts, we could not determine how this oily contents affected to gastrointestinal mucosa because of marked autolysis. Pulmonary edematous changes were found in 22 birds of 49 birds examined.

**Family Gaviidae**

Totally 11 birds of Family Gaviidae including 9 Arctic Loons and 2 Red-throated Loons were necropsied. Animal number, sexes, and body weights were shown as follow.

As most birds showed some damages in various organs, body weights were

Arctic Loon			Red-throated Loon		
Animal number	Sex	Body weight	Animal number	Sex	Body weight
1	♂	1900g	1	♂	1000g
2	♂	1500g	2	♀	1150g
3	♀	2000g			
4	♀	1500g			
5	♀	1110g			
6	Sex unknown	1650g			
7	Sex unknown	1600g			
8	Sex unknown	2650g			
9	♀	1140g			

considerably varied, from 1500-1900 g in males, and from 1110-2000 g in females.

***Oil spill on the surface of the body***

The degree of oil spill on the external surface is shown as follows;

Degree (spoiled area/Total area%)	Arctic Loon (n=9)	Red throated Loon(n=2)
0%	2	0
up to 30%	2	1
up to 80%	5	1
over 80%	0	0



***The presence of black oily contents in the alimentary tracts***

	Oral	Esophagus	Proventriculus	Gizzard	Small intestine	Large intestine	External
<b>Arctic Loon</b>							
1	—	+	+	+	+	+	+
2	—	+	+	+	+	+	+
3	+	—	+	+	+	+	+
4	+	—	+	+	+	+	+
5	—	—	—	+	—	—	+
6	+	+	+	+	+	+	+
7	—	—	—	+	+	+	+
8	—	—	—	+	—	—	+
9	—	—	—	—	ND	ND	+
<b>Red-throated Loon</b>							
1	+	—	+	+	—	+	+
2	—	—	+	+	—	—	+

— : negative    + : Present    ND: Not detected

In Arctic Loons and Red-throated Loons, 9 of 11 birds showed black oily contents in the alimentary tracts. These black oily contents were observed in the gastrointestinal tract after the gizzard. Birds with external oil spoil had a tendency to have more frequent black contents in the gastrointestinal tracts.

***Parasites***

Grossly following parasites were observed.

	Esophageal nematode	Proventricular nematode
Arctic Loon (9)	2	
Red-throated Loon (2)	1	1

***Other gross lesions***

	Arctic Loon (n=9)	Red-throated Loon (n=2)
Lungs congestive edema	6	2
Air sac opacity	5	
Intestinal hemorrhages	1	
Damages by scavengers	5	1
Loss of organs	1	

Most birds showed advanced degree of autolysis.

### ***Histopathology***

	Arctic Loon (n=9)	Red-throated Loon (n=2)
Renal calculus	3	1
Esophageal granuloma	1	

### ***Other birds***

Data from other birds than Family Gaviidae and Family Alcidae are shown as follows;

#### **Family Podicipitidae (n=6)**

Red-necked Grebe (n=4)			Great Crested Grebe (n=2)		
	Sex	Body weight		Sex	Body weight
①	♂	785g	①	♂	650g
②	♀	810g	②	♀	525g
③	♀	875g			
④	♀	680g			

#### **Family Phalacrocoracidae (n=9)**

Temminck's Cormorant (n=7)			Pelagic Cormorant (n=2)		
	Sex	Body weight		Sex	Body weight
①	♂	2100g	①	♂	1200g
②	♀	2250g	②	unknown	830g
③	♀	2500g			
④	♀	2500g			
⑤	♀	2280g			
⑥	unknown	2100g			
⑦	unknown	3100g			

## Family Laridae (n=7)

Slaty-backed Gull (n=4)			Herring Gull (n=1)		
	Sex	Body weight		Sex	Body weight
①	♂	1100g	①	♂	1080g
②	♂	815g			
③	♂	1440g			
④	♀	2000g			

Common Gull (n=1)			Black-headed Gull (n=1)		
	Sex	Body weight		Sex	Body weight
①	♀	570g	①	unknown	390g

	Oral	Esophagus	Proventriculus	Gizzard	Small intestine	Large intestine	External
<b>Arctic Loon</b>							
1	-	+	+	+	+	+	+
2	-	+	+	+	+	+	+
3	+	-	+	+	+	+	+
4	+	-	+	+	+	+	+
5	-	-	-	+	-	-	+
6	+	+	+	+	+	+	+
7	-	-	-	+	+	+	+
8	-	-	-	+	-	-	+
9	-	-	-	-	ND	ND	+
<b>Red-throated Loon</b>							
1	+	-	+	+	-	+	+
2	-	-	+	+	-	-	+

+ : Present - : negative ND: Not detected

***The presence of black oily contents in the alimentary tracts***

## Family Podicipitidae

	Oral	Esophagus	Proventriculus	Gizzard	Small intestine	Large intestine
<b>Red-necked grebe</b>						
① ♂	-	-	-	+	+	+
② ♀	+	-	-	-	-	-
③ ♀	-	-	-	-	+	+
④ ♀	-	-	-	-	-	-
<b>Great Crested grebe</b>						
① ♂	-	-	-	-	-	-
② ♀	-	-	-	-	-	+

- : negative + : Present ND: Not detected

## Family Phalacrocoracidae

		Oral	Esophagus	Proventriculus	Gizzard	Small intestine	Large intestine
<b>Temminck's Cormorant</b>							
①	♂	-	-	-	-	-	-
②	♀	-	-	-	-	-	+
③	♀	-	-	-	+	+	+
④	♀	-	-	-	-	+	+
⑤	♀	-	-	-	-	+	+
⑥	unknown	-	-	-	-	-	-
⑦	unknown	-	-	-	-	+	-
<b>Pelagic Cormorant</b>							
①	♂	-	-	-	+	+	+
②	unknown	+	-	ND	ND	ND	ND

- : negative + : Present ND: Not detected

## Family Laridae

		Oral	Esophagus	Proventriculus	Gizzard	Small intestine	Large intestine
<b>Slaty-backed Gull</b>							
①	♂	-	-	-	-	+	+
②	♀	-	-	-	+	+	+
③	♀	-	-	+	+	+	+
④	♀	-	-	-	-	-	-
<b>Herring Gull</b>							
①	♂	-	+	+	+	+	+
<b>Black-headed Gull</b>							
①	unknown	-	-	-	+	+	+
<b>Common Gull</b>							
①	♀	-	-	-	-	-	-

- : negative + : Present ND: Not detected

***Oil stuck on the surface of body***

The degree of oil spill was divided into four grades based on squire spoiled. The result was as follows;

**Grades of oil spill**

	-	+	++	+++
Family Podicipitidae	1/6	3/6	1/6	1/6
Family Phalacrocoracidae	4/9	2/9	0/9	3/9
Family Laridae	2/7	1/7	3/7	1/7

- : 0 % + : 0~30% ++: 30~80% +++: over 80%

***Parasites***

Parasites found in gross or microscopic examinations are as follows;

### Family Podicipitidae

In Red-necked grebes, all birds (No. 1-4) had singled to multiple nematodes in the lumen of the small intestine, some of which had tapeworms in the large intestine (No. 2 and 3). No. 2 had a long tapeworm, up to 50 cm, in the small intestine and large intestine. By light microscopy, there were nematodes in the esophagus. In Great crested grebes, No. 2 had an intestinal tapeworm and frequent renal trematodes, and another one (No.1) had only renal trematodes.

### Family Phalacrocoracidae

In Temminck' s cormorants, No. 1, 4, 6 and 7 had various nematodes in the proventriculus, and all except No.2 had a cluster of nematodes in the gizzard. In addition, No.4 showed histological parasitic granulomas in the intestinal mucosa. In Pelagic cormorants, only No.1 had parasites in the esophagus, proventriculus and gizzard.

### Family Laridae

Common gulls showed frequent parasites in only the small intestine. A Slaty-backed gull (No.4) had parasites in the large intestine. Herring Gull and Black headed gull showed macroscopic lesions but histologically two had parasite.

### ***Other macroscopic changes***

#### Family Podicipitidae

A Red-necked grebe had hemorrhagic foci in the spleen, small intestine and large intestine. A Great crested grebe showed only pulmonary edema.

#### Family Phalacrocoracidae

In Temminck' s cormorant, there were yellow and black mottles in the liver (No.1) and splenomagaly (No.4). Besides, No. 1, 2 and 3 had pulmonary edema. There were no significant changes in Pelagic cormorants with exception of external damages.

#### Family Laridae

There was no significant change related to oil spill.

### Microscopic lesion

All birds had various degrees of pulmonary edema, but this alteration was not concluded to associated with oil spill because all materials were damaged and decorated by freezing.

### Family Podicipitidae

In Red-necked grebes, there was no significant lesion in No. 1, 2 and 4, with an exception of esophageal nematodes in No.4. Great Crested Grebes also showed no significant changes with exception of frequent renal trematodes.

### Family Phalacrocoracidae

In Temminck's cormorants, there were multi-focal parasitic invasions and granulomas in the mucosa of the proventriculus and the large intestine, and pyogranuloma in the spleen and liver (No. 3). No. 5, 6 and 7 had no significant lesions. In Pelagic cormorants, No. 1 had fresh hemorrhages in the skeletal muscle but other organs showed no significant alterations. Another one (No.2) also showed no lesion except multiple losses of the organs.

### Family Laridae

There were frequent trematodes in the kidneys in black-headed gulls and Herring gulls, and other organs appeared normal. In slaty-backed gulls, No. 2 had slight renal calculus and uric acid deposition, and No.4 showed slight proventricular erosion.

## DISCUSSION AND CONCLUSION

### a) Pulmonary edema

All birds alive or dead when collected showed various degrees of pulmonary edema. However, it was rather difficult to determine if these alterations were caused by oil spill or not because all materials were stocked in freezers, and then defrosted just before necropsies.

## b) Parasites

Various kinds of parasites including frequent renal trematodes were observed, but almost all of them had no inflammatory reactions, with an exception of occasional parasitic granulomas. As a result, these parasites were spontaneous ones, and were thought never to be causes of death.

## c) The presence of black oily contents in the gut and renal uric acid deposition (gout)

	Black contents in the gut	Uric acid deposition in the kidney
Ancient Murrelet	15/50 (30%)	13/50 (26%)
Rhinoceros Auklet	41/48 (85%)	2/50 (4%)
Family Gaviidae	10/11 (91%)	0/11
Other birds	16/22 (73%)	1/22 (5%)

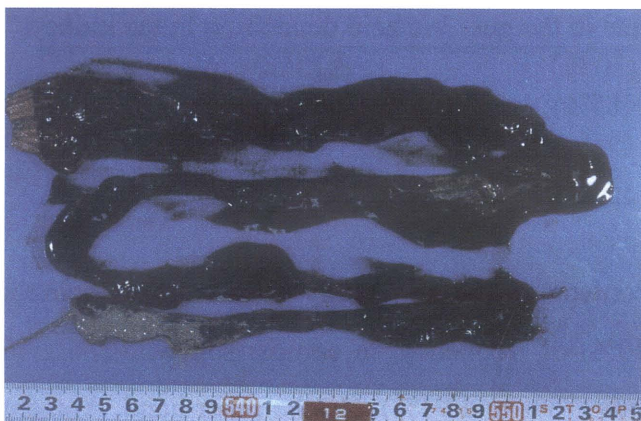
As for frequency of black oily contents in the alimentary tract, Ancient murrets showed relatively lower percentage (30%) of frequency, in comparison with those in Rhinoceros Auklet (85%) and other birds (73% and 91%). On the other hand, Ancient murrets had a higher frequency of renal uric acid depositions than those in other birds (0 to 4%). Of 13 Ancient murrets with renal uric acid depositions ten had no black oily contents in the alimentary tract. As mentioned above, there was no or scarce foreign body reactions to uric acid crystals, which meant that these lesions were quite recently formed and fresh just before death. Based on these findings, most of Ancient murrets might be rescued alive without ingestion of a lot of oil, but they seemed not to be able to take water due to sticky oil spill on external surface, consequently became hyper-uric acidemia. Further study was needed to clarify the relationship between drinking shortage and uric-acidemia.

## REFERENCES

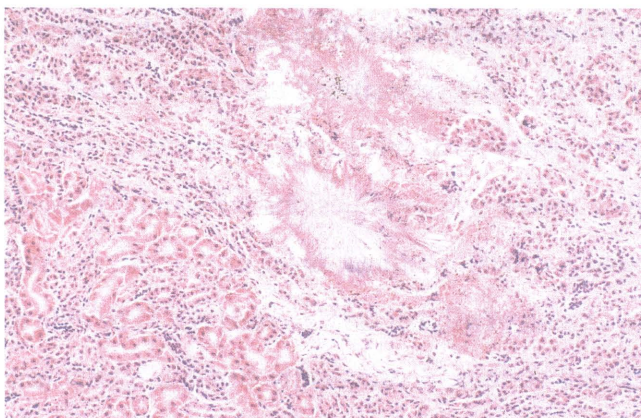
- Yokohata, Y. (2002). Preliminary report on the parasitic helminth fauna of seabirds killed in the "Nakhotka" oil spill. *Japanese Journal of Benthology*, **57**, 90-94.



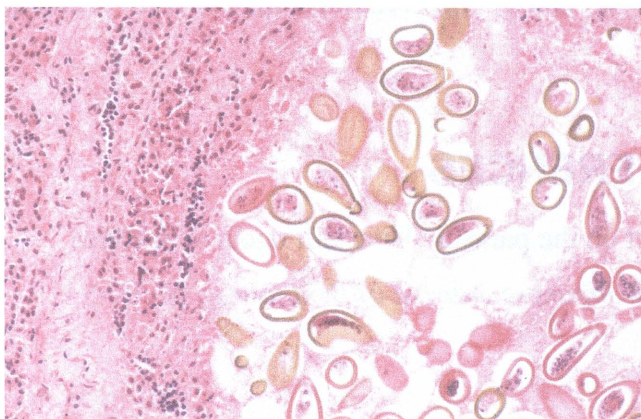
**Figure 1** An Ancient murrelet collected died in the "Nakhodka" oil spill.



**Figure 2** Black oily contents in the alimentary tract in a Rhinoceros Auklet collected after the "Nakhodka" oil spill.



**Figure 3** Deposition of uric acid in the kidney of an Ancient murrelet. Crystalline structures are in radial fashion. There are no apparent inflammatory reactions. HE stain. Original magnification, X20.



**Figure 4** A clumps of trematodes in the kidney of an Ancient murrelet. HE stain. Original magnification, X20.