

Midline dural filum of the sellar floor: Its relationship to the septum attachment to the sellar floor and the ossification in the sphenoid sinus

著者	Hayashi Yasuhiko, Kita Daisuke, Iwato Masayuki, Fukui Issei, Sasagawa Yasuo, Oishi Masahiro, Tachibana Osamu, Nakada Mitsutoshi
journal or publication title	Clinical Neurology and Neurosurgery
volume	147
page range	53-58
year	2016-08-01
URL	http://hdl.handle.net/2297/45947

doi: 10.1016/j.clineuro.2016.05.007

Clinical article

Midline dural filum of the sellar floor: its relationship to the septum attachment to the sellar floor and the ossification in the sphenoid sinus

Yasuhiko Hayashi¹, M.D.,Ph.D., Daisuke Kita¹, M.D.,Ph.D., Masayuki Iwato¹,
M.D.,Ph.D., Issei Fukui¹, M.D., Yasuo Sasagawa¹, M.D.,Ph.D., Masahiro Oishi¹, M.D.,
Osamu Tachibana², M.D.,Ph.D., Mitsutoshi Nakada¹, M.D.,Ph.D.,

1; Department of Neurosurgery, Graduate School of Medical Science, Kanazawa University, Kanazawa, Japan

2; Department of Neurosurgery, Kanazawa Medical University, Kanazawa, Japan

A running head; midline filum on the sellar floor

Key words; midline, filum, dura, septum, ossification

Corresponding author;

Yasuhiko Hayashi, M.D., Ph.D

13-1 Takara-machi, Kanazawa, Ishikawa, 920-8641, Japan

TEL; +81-076-265-2384, FAX; +81-076-234-4262

e-mail; yahayashi@med.kanazawa-u.ac.jp

Abstract

Objectives. It is important to identify and maintain a midline orientation during endoscopic transsphenoidal surgery (ETSS) for sellar lesions to prevent critical injury to the internal carotid artery. Therefore, the preoperative neuroradiological assessment of the bony structures in the sphenoid sinus, including the septum attachment to the sellar floor and its surrounding structures, is essential. It has been reported that the midline filum of the sellar dura can function as a useful intraoperative orientation guide during ETSS. However, the relationship between the midline dural filum and the intrasinus bony structures, such as the sellar floor, the intrasinus septation and the ossification, remains unclear and the mechanisms underlying development of the midline dural filum have also not yet been explored.

Methods. This retrospective study included 160 patients undergoing ETSS to assess both the midline dural filum and the intrasinus bony structures, using video recording reviews. The intrasinus septum and the ossification in the sphenoid sinus were evaluated on the computed tomography images of the bone window.

Results. A midline dural filum was identified in 66 (41.3%) of 160 patients. Attachment of the septum to the sellar midline was found in 61 (39.4%) of 155 patients,

after excluding 5 patients with the conchal type of sphenoid sinus, in 55 (90.2%) of 61 patients with a septum on the midline, and in only 6 (6.4%) of the remaining 94 patients without a septum on the midline. The relationship between a midline dural filum and a septum on midline was statistically significant ($p < 0.001$), regardless of the number of intrasphenoidal septa. In terms of the types of sphenoid sinus, the midline dural filum was predominantly detected in patients where ossification extended over the midline filum. In patients with the sellar type of sphenoid sinus, 49 (36.0%) of 136 had a midline dural filum, meanwhile, 16 (84.2%) of 19 patients with the pre-sellar type ($p=0.039$) and all 5 patients (100%) with the conchal type harbored a midline dural filum ($p<0.001$).

Conclusion. This study clearly verified the importance of the midline dural filum in a large series and evaluated the obvious relationship between the midline dural filum and the bony structures on the sellar floor. Our results strongly suggest that, during developing of the midline dural filum, the sellar dura becomes tethered to the bony elements attached to the sellar surface, such as the septum on the midline and the ossification in both the pre-sellar and the conchal type of sphenoid sinus.

Introduction

The transsphenoidal approach is the golden standard for a surgical intervention for sellar and parasellar lesions. Recently, endoscopic transsphenoidal surgery (ETSS) for sellar lesions has become globally accepted, and extended anterior cranial base surgery, for the suprasellar lesions, such as craniopharyngioma and tuberculum sellae meningioma, has also been performed using purely endoscopic procedures [1,2]. During the early stages of both standard and extended EETS, when in the sphenoid sinus, it is important to identify and maintain the orientation of the midline, to prevent the critical injury to the internal carotid arteries [3,4].

Several anatomic structures, such as the vomer bone and the sphenoid rostrum in the nasal cavity, and the carotid artery prominence and the optico-carotid recess in the sphenoid sinus, could be used as reliable midline landmarks in ETSS [5,6]. Moreover, the septum, which is attached at the midline in the sphenoid sinus, which can be detected on preoperative neuroradiological imaging, such as 3-dimensional computed tomography angiography (3D-CTA), can also be an important landmark, providing direct anatomical orientation during ETSS [4].

Zada et al. reported that a midline filum of the sellar dura was observed in 50% of cases operated for sellar lesions and could function as a useful intraoperative index, along with intraoperative neuronavigation and Doppler ultrasonography for the cavernous carotid arteries during ETSS [3]. However, the relationship of the midline dural filum and bony structures in the sphenoid sinus, and the mechanisms by which it develops is unknown. In this study, we aimed to clarify whether the midline dural filum has an anatomical relationship with septation and ossification over the sellar floor, and we discuss the possible mechanisms underlying the development of the midline dural filum.

Methods

This retrospective study involved 160 patients undergoing ETSS for various sellar and parasellar lesions in our institute between 2006 and 2014. Patients were enrolled with the approval of the Institutional Review Board of Kanazawa University. Patients' demographics, including sex, age, and histology of tumors, were garnered from their clinical charts. Preoperative 3D-CTA images were investigated for anatomical features of the sella and the sphenoid sinus, and their anatomical relationship to the internal carotid arteries. This study consisted of 69 males and 91 females, with an age at diagnosis ranging from 10 to 88 years (mean; 53.0 years). The diagnoses of tumor histology were pituitary adenoma in 116 patients (non-functioning in 76 and functioning in 40), Rathke's cleft cyst in 24, craniopharyngioma in 8, and the other diagnoses in 12 (Table 1).

Intraoperative video recording

Intraoperative video recordings of the patients were also reviewed to assess the presence and the location of a midline dural filum and a septum on the sellar floor. We routinely measure the length of the bone window on the sellar floor with a small ruler intraoperatively. The bone window was made to the boundary between the sellar floor

and the carotid prominence accurately, which was confirmed by the postoperative thin-slice bone CT scan. Therefore, all the dural filums on the sellar floor were confirmed to exist on the midline (Fig. 1).

The sellar floor was divided into two sections, viz., the anterior surface and the lower surface. The midline of the sellar floor was identified by the distance from the medial margin on both sides of the carotid prominence and the optico-carotid recess at the parasellar regions, both preoperatively and intraoperatively. This intraoperative identification of the presence of a midline filum and a septum was performed by at least three neurosurgeons on the pituitary team in our department. Patients who had previously undergone ETSS, whose tumors showed predominant infra-sellar extension, or whose tumors had significant dural invasion through the sellar dura, were excluded from the analysis. In those cases with the choncal type of sphenoid sinus, confirmation of the midline was performed in each patient using intraoperative neuronavigation (Stealth Station, Medtronic, Louisville, CO, USA).

Neuroradiological findings

Preoperative 3D-CTA bone images in the 160 patients undergoing ETSS described above were reviewed to evaluate septation and ossification in the sphenoid sinus. Intrasphenoidal septation was assessed by numbers of the septa and their attachments to the sellar floor (on-midline or off-midline), and its surrounding structures, such as the carotid prominence, optic prominence, and optico-carotid recesses. The thickness of the CT slice was 0.625 mm, and the attachment of the intrasphenoidal septum was evaluated on both axial and coronal sections of the CT scans. Our inclusion criteria for a septum on-midline on the sellar floor were that the septum is attached on the midline, even for a short section, or that it passes through the midline. Ossification in the sphenoid sinus was categorized as the sellar, pre-sellar, or conchal type, according to the extent of ossification assessed with the sagittal view on the bone images of the CT scans as follows: the sellar type was defined as the ossification stayed beneath the lower surface of the sellar floor (posterior border of the sphenoid sinus extended under the lower surface); the pre-sellar type was defined as the ossification extended over the anterior surface of the sellar floor (posterior border of the sphenoid sinus contact with the anterior wall only) and the conchal type was defined when the ossification in front of

the anterior wall of the sella exceeded 10 mm [7,8] (Fig.2). These radiological findings were evaluated by at least three neurosurgeons, as described above.

The chi-squared test was used to compare between the two groups and the post-hoc tests was used for comparison among the three groups. These statistical analyses were performed using Microsoft Statview (ver.5, SAS institute Inc.). A p-value of < 0.05 was considered as statistically significant.

Results

Patient characteristics

Among the 160 patients included in the analysis, a midline dural filum was noted in 66 (41.3%) during ETSS. In each of the patients harboring a dural filum, the filum was identified intraoperatively as single and located on the midline i.e., equidistant from both sides of the medial margins of the carotid prominence and the optico-carotid prominence, and all the dural filums were found on the midline of the sellar floor around the interface between the anterior surface and the lower surface (Fig.1). The association of the presence of a midline dural filum with sex and age (≤ 50 years or > 50 years) was evaluated. In the 66 patients (41.3%) with a midline dural filum, 37 (56.1%) were male and 29 (43.9%) female. Among the total cohort, a midline dural filum was predominantly present in males (37 of 69 patients, 53.6%), as compared with in females (29 of 91 patients, 31.9%; $p = 0.021$). However, there was no significant difference in the presence of a midline filum between patients ≤ 50 years (23 of 62 patients, 37.1%) and those > 50 years (43 of 98 patients, 43.9%; $p = 0.147$) (Table 2). In the patients included in this study, there was no association of the presence of a midline dural filum with any particular tumor histology ($p = 0.392$); in the 116 cases with pituitary adenoma, 47

(40.5%) had a midline dural filum; in the 24 cases with Rathke's cleft cyst, 8 (33.3%) had a midline filum, in the 8 cases with craniopharyngioma, 5 (62.5%) had a midline filum, and among the 12 cases with other diagnoses, 6 (50%) had a midline filum.

Correlation between a midline dural filum and septation in sphenoid sinus

There was a clear and statistically strong correlation between a midline dural filum and a septum on-midline was obviously presented ($P < 0.001$); 55 (90.2%) of the 61 patients with a septum on-midline also had a midline dural filum. No dural filum was observed off the midline at the sellar floor in this study. On the other hand, only 1 patient (2.9%) with a midline dural filum was found among 34 patients with a septum off-midline on the sellar floor. In addition, 5 patients (8.3%) with a midline dural filum were found among 60 patients in whom no septum was observed on the sellar floor (Table 2).

The numbers of the intrasphenoidal septa among the 155 patients who did not have the conchal type of sphenoid sinus (5 patients with the conchal type were excluded) were as follows; no septum in 10 patients (6.5%), 1 septum in 38 patients (24.5%), 2 septa in 64 patients (41.3%), and 3 septa in 43 patients (27.7%). A septum on-midline was observed in 61 (39.4%) of the 155 patients in this analysis, and the distribution

thereof according to the number of intrasphenoidal septa was as follows; 11 of 38 patients (28.9%) with 1 septum, 21 of 64 patients (32.8%) with 2 septa, 29 of 43 patients (67.4%) with 3 septa. The presence of a midline dural filum was divided almost equally among these 3 groups; 10 of 11 patients (90.9%) with 1 septum, 19 of 21 (90.5%) with 2 septa, and 26 of 29 (89.7%) with 3 septa also had a midline dural filum. No statistically significant difference was found in the ratios of the midline dural filum was among the groups of patients with different numbers of septa, including a septum on-midline (Table 3).

Correlation between a midline dural filum and ossification in sphenoid sinus

The presence of a midline dural filum was found in 49 (42.2%) of 116 patients with the sellar type, 16 (84.2%) of 19 patients with the pre-sellar type, and 5 (100%) of 5 patients with the conchal type of sphenoid sinus. The percentage of patients with a dural filum among the patients with the conchal type of sphenoid sinus was markedly higher than among patients with the sellar type ($p < 0.001$), but not markedly different from that among patients with the presellar type ($p = 0.342$) of sphenoid sinus. Moreover, a midline dural filum was significantly more common in patients with the pre-sellar type

than in those with the sellar type of sphenoid sinus ($p = 0.004$). Ossification extended over the anterior surface of the sellar floor including both in the pre-sellar and the conchal type of sphenoid sinus was clearly correlated with the presence of a midline dural filum (Table 2).

Discussion

It is important to identify the orientation of the midline in the sphenoid sinus during ETSS to prevent critical injuries to lateral structures, including the internal carotid arteries [3,4]. Zada et al. reported that a midline filum of the sellar dura could function as a useful intraoperative orientation guide during ETSS [3]. Intrasinus septation has been recognized as an excellent anatomic marker for the orientation of the sella, including the midline in order to perform ETSS safely and effectively [4,5]. If the intrasinus septum is found to be present on the midline on the sella turcica during preoperative evaluation, as detected in the 61 cases (39.4%) in this study, it can act as a direct landmark of the midline during surgery. Moreover, if the intrasinus septum is present off-midline on the sellar floor, as detected in the 34 cases (21.9%) of our series, it can also be an indirect landmark of the midline orientation, by measuring the distance from the septum to the midline on the preoperative radiological scan, including 3D-CTA images.

In our series, a midline dural filum could be identified in 66 of 160 patients (41.3%) undergoing ETSS by reviewing of intraoperative video recording. This proportion in our series seems to be comparable to that of series shown by Zada et al. [3]; our sample size was larger than their series, and compared to the 50% found in their study, more

than 40% of the patients who harbor pituitary tumors were identified as having a midline dural filum at the sellar floor in our study. We have recognized that the dural filum was identified as a useful adjunctive, intraoperative landmark, which let us to be re-oriented on the midline before dural incision at the sellar floor.

In our series, a midline dural filum was found in 55 (90.2%) of 61 patients with a septum on-midline; on the other hand, the dural filum was detected in only 6 (6.4%) of 94 patients without a septum on-midline. These results led us to consider the attractive anatomical relevance between a midline filum of the sellar dura and a septum on-midline on the sellar floor from the aspects of developmental biology. On the other hand, only 1 (2.9%) among 34 patients with a septum off-midline on the sella floor harbored a midline dural filum. In addition to this, only 5 (8.5%) among 59 patients with no septum on the sellar floor presented with a dural filum. There was no statistical correlation between a midline dural filum and a septum off-midline. Our results differed from the results reported by Zada et al., who showed that the midline dural filum was not statistically correlated with the presence of a midline sphenoid septation. Their data revealed a septum on-midline was identified in 56% of their patients with a midline filum

and in 39% of patients without a midline filum. Although the exact reasons for this difference remain unknown, our inclusion criteria for a septum on-midline may have differed from their study. However, our results strongly suggested that the process underlying development of the midline dural filum is associated with that of the intrasphenoid septum on-midline.

In our study, all of the dural filums identified intraoperatively on the midline, were located at the lower hemisphere of the exposed sellar dural surface, as described by Zada et al. [3]. Furthermore, our findings on ossification in the pre-sellar and conchal types of sphenoid sinus strongly suggested the importance of ossification extending over the interface between the anterior wall and the lower wall of the sella turcica in the development of a midline dural filum. In the 19 patients with the pre-sellar type of sphenoid sinus, 16 (84.2%) were found to harbor a midline dural filum, which was significantly higher than in those with the sellar type (42.2%, $p = 0.004$). Moreover, in all the patients with the conchal type of sphenoid sinus, a midline dural filum was present (100%, $p < 0.001$), which was markedly higher than that in patients with other types of sphenoid sinus. Thus, the “midline” dural filum was, surprisingly, found to be a valuable

landmark in cases with the conchal type of sphenoid sinus. In patients with the conchal type, not only the sella turcica, but also the surrounding structures, including the optico-carotid recess, optic prominence, and carotid prominence were completely masked behind the ossification in sphenoid sinus [9]. Therefore, the usefulness of this midline dural filum as the intraoperative midline orientation for avoiding critical vascular injury is more important in this type than in other types of sphenoid sinus. Together with the results from the pre-sellar type described above, ossification in sphenoid sinus that extends over the interface between the anterior surface and the lower surface of the sella turcica which is the most common location of the midline dural filum, might induce formation of the dural filum.

In patients with the conchal type of the sphenoid sinus, TSS should be performed very carefully in preventing inadvertent damages to parasellar structures, such as the internal carotid artery. The poorly pneumatized sphenoid sinus can be drilled safely using the neuronavigation system. In our series, neuronavigation was used in 5 patients with conchal type of the sphenoid sinus and no complication was encountered. In

addition, we could confirm the midline filum on the sellar floor indeed exist on the midline.

Our speculation is that an intrasinus septum on-midline might lead to the development of the midline dural filum at the sellar floor could be supported by two anatomical aspects. First, intraoperative observation revealed that the midline dural filum was found to be oriented in a vertical direction between the superior and the inferior intercavernous sinus at the sellar dura, and can be identified macroscopically as a strand-like dural extension at the sella. Subsequently, microscopic histological examination of the dural filum demonstrated that it comprises dense connective tissue, without ductal epithelium or vascular wall, as found in the dura mater [3]. Second, intraoperative observation also showed that bleeding occurred from the midline dural filum, which can easily be controlled by means of a bipolar coagulator. During bone removal from the sellar floor, this bleeding that emerges from the midline dural filum may be due to avulsion of the dural filum. McConnell's capsular artery, which branches from the intracavernous portion of the internal carotid artery (medial surface), is thought to be responsible for this bleeding, as it feeds into the sellar dura, and has extensive

anastomosis on the midline with the contralateral McConnell's capsular artery [10,11].

In terms of the development of the intrasinus septation, trabecular cartilage on both sides extend in front of the pituitary, thereby building the sella turcica, and fuse on the midline to form the trabecula communis, which may lead to formation of the intrasinus septum on the ventral extension [12,13]. If the trabecula communis grows on the midline in the sphenoid sinus, the dural extension may lead to tethering of the sellar dura to the bony surface of the sellar floor and subsequently to the intrasinus septum, along with the ingress of McConnell's capsular artery from the midline anastomosis. Therefore, we speculate that the midline dural filum develops from tethering of the sellar dura to the sellar floor with concomitant evolution of a vascular network (Fig. 3).

Rhoton et al. reported an anatomical study on the sella turcica and the sphenoid sinus from the point of view of transsphenoidal surgery, and reported that the most frequent attachment site of the intrasinus septum is around the interface between the anterior surface and the lower surface of the sella turcica, if the intrasinus septation runs along the midline [14]. In our study, the midline dural filum was found at the interface between the both surfaces on the sellar floor, where the septum on-midline was also

found in all cases where the dural filum and the septum were both found on midline.

This finding suggests that these structures may share a common developmental process (Fig. 3).

Conclusion

In our study, a midline filum of the sellar dura was demonstrated in 41.3% of the cases with pituitary tumors and could provide useful orientation during ETSS. In about 90% of cases with a midline dural filum, an intrasinus septum was also present on the midline at the sellar floor. In addition, ossification extended beyond the lower surface of the sellar floor, in the pre-sellar and conchal types of sphenoid sinus, which also emphasized the existence of a midline dural filum. This markedly higher rate of co-existence of the dural filum and the septum on the midline or ossification extending over the interface between the anterior surface and the lower surface of the sellar floor suggest that the sellar dura is tethered to the bony structures on the sellar floor during development.

Compliance with ethical standards

Conflict of Interest

All authors have no conflict of interests.

List of Abbreviations

CT; computed tomography

ETSS; endoscopic transsphenoidal surgery

3D-CTA; 3-dimensional computed tomography angiography

References

- [1] S. Aydin, L.M. Cavallo, A. Messina. The endoscopic endonasal trans-sphenoidal approach to the sellar and suprasellar area. Anatomic study. *J Neurosurg Sci* 51 (2007) 129-138.
- [2] LM Cavallo, A. Messina, P. Cappabianca. Endoscopic endonasal surgery of the midline skull base: anatomical study and clinical considerations. *Neurosurg Focus* 19 (2005) E2.
- [3] G. Zada, A.H. Kim, L.S. Governale, E.R. Laws ER. Midline filum of the sellar dura: a useful landmark during endoscopic transsphenoidal pituitary surgery. *Neurosurgery* 67(ONS Suppl 2) (2010) 391-394.
- [4] J.C. Fernandez-Miranda, D.M. Prevedello, R. Madhok, V. Morera, J. Barges-Coll, K. Reineman, C.H. Synderman, P. Gardner, R. Carrau, A.B. Kassam. Sphenoid septations and their relationship with internal carotid arteries: anatomical and radiological study. *Laryngoscope* 119 (2009) 1893-1896.
- [5] O. Hamid, L.E. Fiky, O. Hassan, A. Kotb, S.E. Fiky. Anatomic variations of the sphenoid sinus and their impact on trans-sphenoid pituitary surgery. *Skull Base* 18

(2008) 9-15.

[6] V.R. Ramakrishnan, J.D. Suh, J.Y. Lee, B.W. O'Mallet Jr, M.S. Grady, J.N. Palmer.

Sphenoid sinus anatomy and suprasellar extension of pituitary tumor. J Neurosurg 119

(2013) 669-674.

[7] J.B. Anon, R. Michael, S.J. Zonreich. Sphenoid sinus anatomy. Anatomy of the

paranasal sinuses. Thieme, New York, 1996, pp25-28.

[8] N. Štoković, V. Trkulja, I. Dumić-Čule, I. Čuković-Bagić, T. Lauc, S. Vukičević, L.

Grgurević. Sphenoid sinus types, dimensions and relationship with surrounding

structures. Ann Anat 203 (2016) 69-76.

[9] M. Banna, P.S. Olutola PS. Patterns of pneumatization and septation of the

sphenoidal sinus. J Can Assoc Radiol 34 (1983) 291-293.

[10] F.S. Harris, A.L. Rhoton. Anatomy of the cavernous sinus. A microsurgical study. J

Neurosurg 45 (1976) 169-180.

[11] E. Palacios, B. Azar-Kia, V. Williams. The significance of the dural supply from the

carotid siphon. Am J Roentgenol Radium, Ther Nucl Med 125 (1975) 816-822.

[12] W. Vorster. The development of the chondrocranium of *Gallus gallus*. *Adv Anat*

Embryol Cell Biol 113 (1989) 1-75.

[13] N. Wada, T. Nohno, S. Kuratani. Dural origins of the prechordal cranium in the

chicken embryo. *Developmental Biology* 356 (2011) 529-540.

[14] A.L. Rhoton Jr. The sellar region. *Neurosurgery* 51(ONS Suppl 4) (2002) 335-374.

Figure Legends

Figure 1. (A) Schematic representation of the sphenoid sinus and the sellar floor in the sagittal view, describing the anterior surface (a), the lower surface (b), and the interface (asterisk) between the anterior surface and the lower surface of the sellar floor.

Intraoperative photographs and schematic representations of (B) a septum on-midline and (C) a midline dural filum at the sellar floor in the sphenoid sinus. A septum on-midline (asterisk) in the sellar floor was always attached at the midline at the interface between the both surfaces, where all the midline filums were found in our study (arrow). (D) Intraoperative measurement of the length of the bone window on the sellar floor performed using a small ruler clearly showed that a dural filum located on the midline (arrow).

Figure 2. Schematic representation and computed tomography scans of the bone window in a sagittal view, showing ossification with varying extension into the sphenoid sinus. (A and D) conchal type, (B and E) pre-sellar type, in which the interface between the anterior surface and the lower surface of the sellar floor (asterisk) is covered with

ossification, (C and F) sellar type, the interface is covered with the intrasphenoidal pneumatization.

Figure 3. Schematic representation of the anatomical relationship between a midline dural filum and a septum on-midline (A) and between a midline dural filum and ossification extending over the interface between the anterior surface and the lower surface of the sellar floor.

Tables

Table 1. Demographic features of the patients in this study.

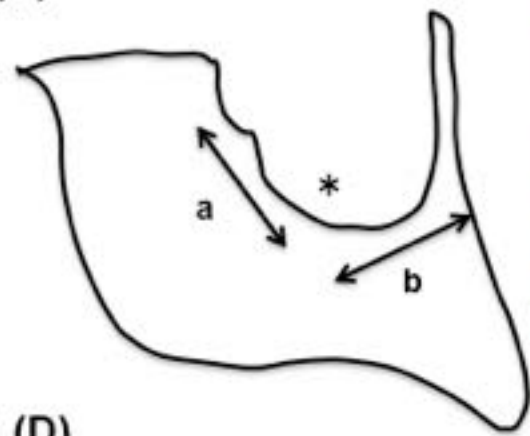
Table 2. Correlation of the presence of a midline dural filum with the factors described in

Table 1.

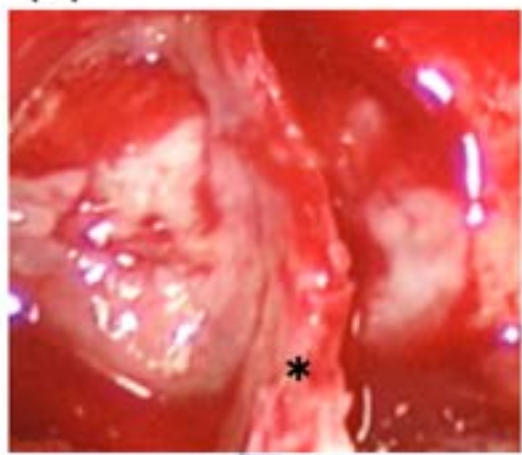
Table 3. Numbers of the intrasphenoidal septum, and the ratios of the septum on-midline and the midline dural filum.

Figure 1

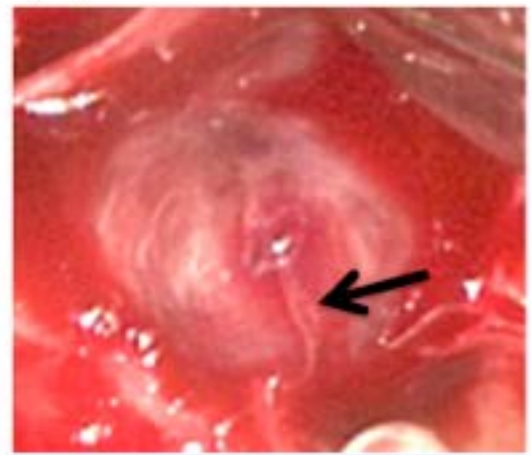
(A)



(B)



(C)



(D)

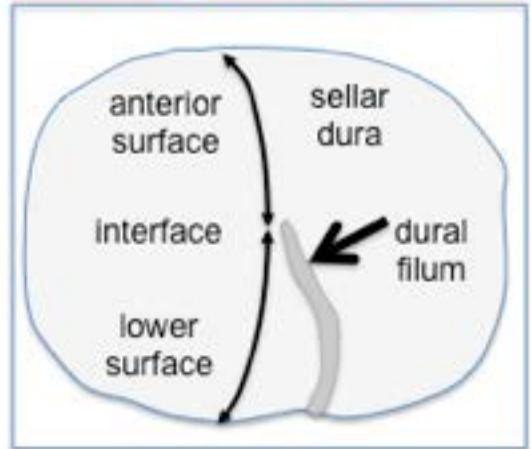
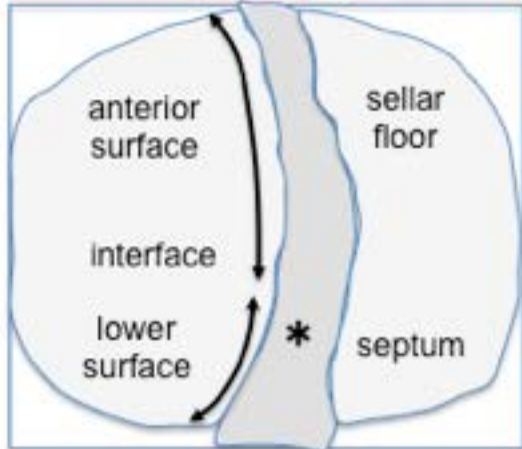
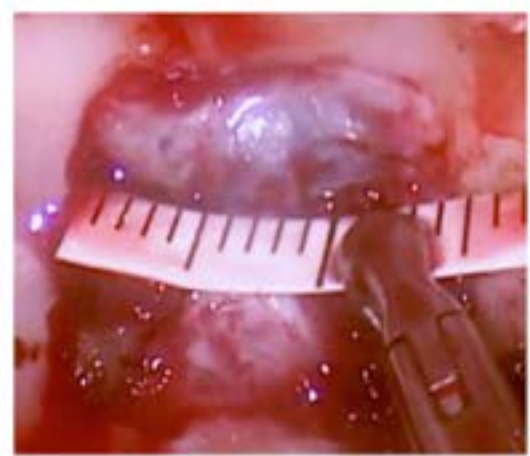


Figure 2

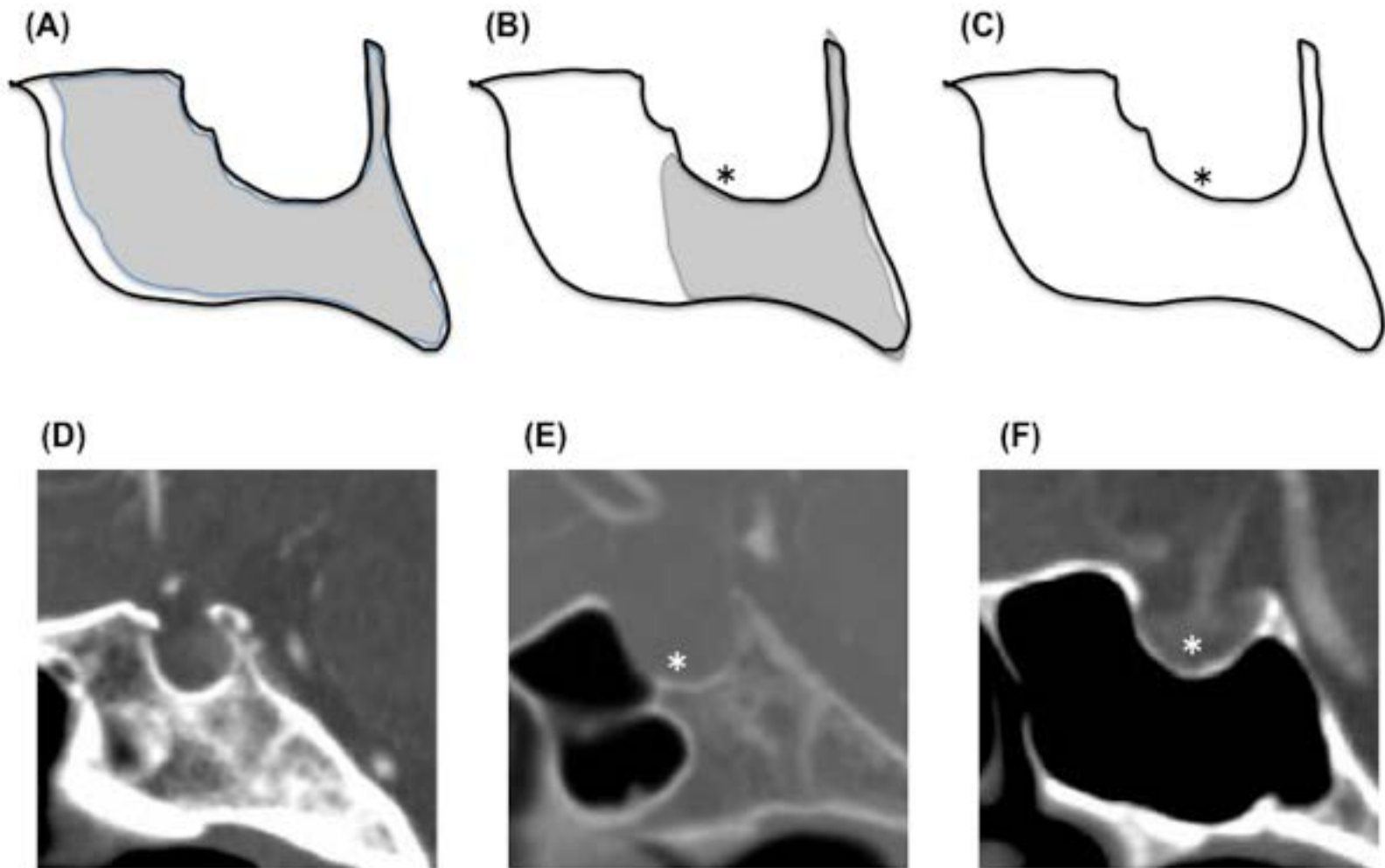


Figure 3

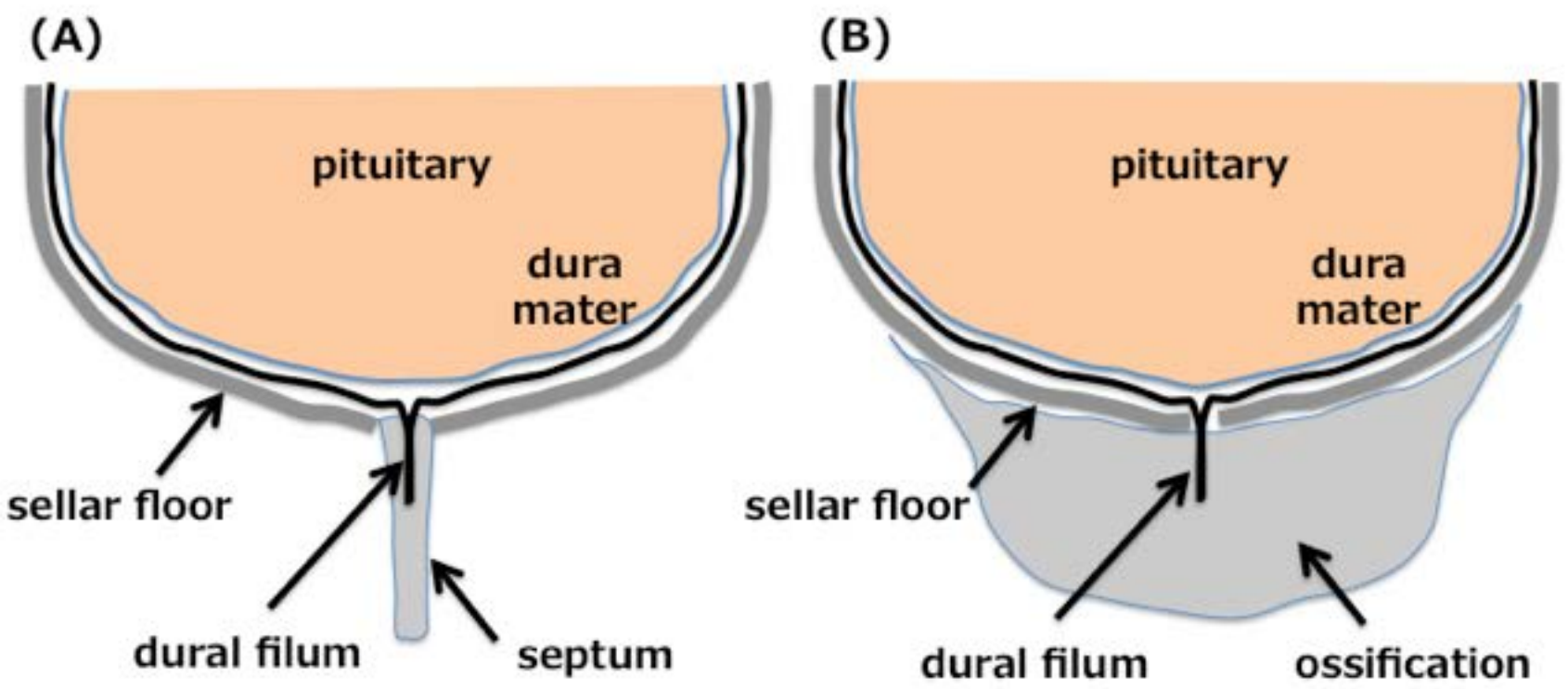


Table 1

Variables		Numbers
Gender	Male	69
	Female	91
Age	50 and less	62
	50 over	98
Tumor histology	Pituitary adenoma	116
	Rathke Cleft Cyst	24
	Craniopharyngioma	8
	Other tumors	12
Intrasphenoidal septum	septum on-midline	61
	septum off-midline	34
	no septum	60
Type of Sphenoid sinus	Sellar	136
	Presellar	19
	Conchal	5

Table 2

Variables		Midline filum		<i>P-value</i>	
		+	-	Chi-Square	Post-hoc
Gender	Male	37	32	0.0207	
	Female	29	62		
Age	50 and less	23	39	0.1466	
	50 over	43	55		
Tumor histology	Pituitary adenoma	47	69	0.3917	
	Rathke Cleft Cyst	8	16		
	Craniopharyngioma	5	3		
	Other tumors	6	6		
intrasphenoidal septum	(A) septum on-midline	55	6	< .0001	A vs. B < .0001
	(B) septum off-midline	1	33		A vs. C < .0001
	(C) no septum	5	55		B vs. C 0.3041
Types of Sphenoid sinus	(A) Sellar	49	87	< .0001	A vs. B 0.0039
	(B) Presellar	16	3		A vs. C < .0001
	(C) Conchal	5	0		B vs. C 0.3422

Table 3

	intrasphenoidal septation	septum on-midline	midline dural filum	Post hoc test P-value
0	10	*	1 (10.0)	1 septum vs. 2 septa
1	38	11	10 (90.9)	.9682
2	64	21	19 (90.5)	1 septum vs. 3 septa
3	43	29	26 (89.7)	.9052
	155	61	55 (90.2)	1 septum vs. 3 septa
			(%)	.9239

% was assessed as the ratio of the numbers of cases with midline dural filum out of those with septum on-midline