

Symptomatic foramen of Magendie arachnoid cyst in an elderly patient

| | |
|------------------------------|---|
| 著者 | Hayashi Yasuhiko, Kita Daisuke, Watanabe Takuya, Yoshikawa Akifumi, Hamada Jun-ichiro |
| journal or publication title | Surgical Neurology International |
| volume | 6 |
| number | 1 |
| page range | 7 |
| year | 2015-01-01 |
| URL | http://hdl.handle.net/2297/42219 |

doi: 10.4103/2152-7806.149611

Symptomatic foramen of Magendie arachnoid cyst in an elderly patient

Hayashi, Y. , Kita, D. , Watanabe, T. , Yoshikawa, A. , Hamada, J.-I.

Department of Neurosurgery, Kanazawa University, Kanazawa, Ishikawa, Japan

Abstract

Background: Arachnoid cysts (ACs) are congenital anomalies of the central nervous system and arise in virtually all locations where the arachnoid membrane exists. Posterior fossa ACs are considered to develop in the posterior aspect of the rhombencephalic roof plate and do not communicate freely with the fourth ventricle or perimedullary subarachnoid space. Although posterior fossa ACs have been reported a number of times, ACs arising from the foramen of Magendie are very rare.

Case description: We report here on a 76-year-old woman who presented with progressive gait disturbance. Magnetic resonance imaging of the head showed a large AC in the foramen of Magendie that was compressing the inferior vermis and medial aspects of the cerebellar hemisphere without causing hydrocephalus. Neurological examination revealed cerebellar

ataxia without Romberg's sign. A nearly total excision of the cyst was safely performed via a median suboccipital approach. The patient's postoperative course was excellent and her neurological recovery was remarkable.

Conclusion: Most cases of ACs located in the foramen of Magendie are reported in children, and it is extremely rare to observe such ACs in the elderly. In fact, to our knowledge, a symptomatic foramen Magendie AC has never been reported previously in an elderly person. Our results indicate that proper surgical intervention can yield highly positive outcomes in such cases.

Key Words; arachnoid cyst, posterior fossa, elderly, midline, foramen of Magendie

Introduction

Arachnoid cysts (ACs) are benign developmental anomalies located within the arachnoid membrane and account for approximately 1% of all intracranial lesions ^[5,14]. Posterior fossa ACs reportedly comprise 26-38% of all ACs; nevertheless, they are frequently difficult to distinguish from other arachnoid cavities, such as arachnoid pouches and mega cisterna magna ^[8,10,13]. ACs located in the foramen of Magendie are very rare, and most cases have been reported in children ^[11].

ACs in the elderly are rarely symptomatic. Because ACs in the elderly are almost always found in the same locations as in children, the developmental mechanisms leading to AC formation are believed to be similar between children and the elderly ^[9,15].

We present here the case of an elderly patient with a symptomatic AC located in the foramen of Magendie that was successfully treated with surgical intervention.

Case Report

A 76-year-old woman had experienced unstable gait for 3 months. Because her disability was gradually progressing, she consulted a local hospital. When she came to our hospital for further examination 1 week later, she could not move without a wheel chair. Neurological examination revealed cerebellar truncal ataxia without Romberg's sign. Magnetic resonance imaging (MRI) of the head showed a cystic lesion in the foramen of Magendie, which was compressing the inferior part of the vermis and the medial part of the cerebellar hemisphere without causing hydrocephalus [Figure 1].

She had previously consulted her local hospital with a complaint of headache 3 years ago. MRI performed at that time revealed the same cystic lesion to be present. The intensity of the cyst was similar to that of the cerebrospinal fluid (CSF), and the cyst was divided into two portions, suggesting the presence of a multilobular cyst. Because the patient's symptoms were believed to attribute to the presence of this cystic lesion, surgical decompression was planned.

Median suboccipital craniectomy was performed such that after the dural incision, the cyst

was exposed. The retromedullary cistern was open, but the cyst had not shrunk, and the cyst was found not to communicate with the surrounding cistern [Figure 2a]. Most of the cyst wall was successfully removed. A small part of the cyst that was still attached to the choroid plexus at the foramen of the Magendie was allowed to remain [Figure 2b], and the fourth ventricle was not opened via the obex.

Pathohistological examination demonstrated that the cyst wall was composed of a collagenous membrane lined by multiple layers of arachnoid cells [Figure 3]. Chronic inflammation and hemosiderin pigmentation were absent on the wall. This result confirmed the diagnosis of the cyst as an AC.

The patient's postoperative clinical course was excellent and her neurological recovery was remarkable. She regained her mobility and could walk without a cane. MRI performed 2 weeks after the operation revealed that the cyst had diminished and clearly demonstrated a flow artifact entering into the foramen of Magendie [Figure 4]. Recurrence of the cyst has not been detected on follow-up MRI for 4 years.

Discussion

ACs are congenital lesions that arise during development in virtually all locations where arachnoid membrane is present, and is caused by the splitting of the membrane. The symptoms and signs of an AC include elevated intracranial hypertension and focal signs due to the effects of compression^[5,14]. Many authors have indicated that ACs typically remain constant in size or grow very slowly, and that enlargement only occurs in patients under 5 years of age^[1,2].

The clinicopathological features of retrocerebellar ACs have been reported by several authors^[6,11,13]. These ACs are male-dominant, usually occur in children under 10 years of age, and are associated with obstructive hydrocephalus in many cases. They are usually located beneath the cerebellar convexity, although in our case, the cyst did not extend into the cerebellar convexity and was located only in the Foramen of Magendie. Craniocervical (craniospinal) ACs are similar to retrocerebellar AC; however, craniocervical ACs are mainly located at the base of the posterior fossa and extend into the cervical canal. The symptoms of craniocervical ACs are primarily attributed to the compression to the craniocervical junction and to obstructive

hydrocephalus^[7,12].

In our patient's case, the cyst did not extend into the spinal canal. Although the cyst wall was attached to the choroid plexus from the fourth ventricle, no part of the cyst extended into the fourth ventricle. Therefore, the cyst can be considered an AC in the foramen of Magendie. Because both of the foramina of Luschka were patent, the AC did not induce obstructive hydrocephalus. Pascal et al. reported 3 cases of AC in the foramen of Magendie in their review of 67 childhood cases, but did not discuss the clinicoradiological features of these cases^[11].

Among the cystic lesions that are located in the midline of the posterior fossa, persistent Blake's pouch cyst (PBPC) is most important in a differential diagnosis^[13]. The MRI findings of PBPC include tetraventricular hydrocephalus, wide communication between the fourth ventricle and the PBPC, inferior posterior fossa mass effect with or without hypoplasia of the cerebellar vermis and medial aspects of the cerebellar hemispheres, and an absence of communication

between the fourth ventricle and midline posterior basal subarachnoid space. PBPC can be caused by a failure of embryonic assimilation of the area membranacea anterior within the tela choroidea associated with the imperforation of the foramen of Magendie^[3,4]. Typically, this condition becomes symptomatic early in life. The laterally positioned foramina of Luschka most likely maintain some CSF flow between the intraventricular and subarachnoid spaces, allowing the establishment of a precarious equilibrium characterized by a compensatory enlargement of the whole ventricular system^[13]. We can confirm that our patient did not have PBPC, as hydrocephalus was not observed, moreover, histological verification demonstrated the cyst to be an AC.

Because ACs in the elderly are found in almost the same locations as are ACs in children, the developmental mechanisms leading to this condition are considered to be similar between the two aged groups^[9,15]. The mechanisms of cyst expansion have been described as follows; first, osmolarity in the cyst becomes elevated; second, fluid is secreted from the cyst wall; third, a ball-valve mechanism develops on the cyst wall. In our patient, the AC caused a local effect in

the form of ataxia due to cerebellar compression. However, the cyst had been detected 3 years previously and the cyst was observed to be unchanged in size and shape since that time. While the progressive growth of the skull and plasticity of the brain in children can buffer the mass effect caused by a cyst, the breakdown of compensatory mechanisms in elderly patients with or without cyst expansion can lead to relatively rapid progression of symptoms, once they appear. Therefore, we can speculate that our patient's symptoms developed because of the breakdown of compensatory mechanism in the brain surrounding the AC. Her neurological recovery after successful removal of the cyst supports this speculation. However, the factors which induce the breakdown of compensatory capacity remain unknown ^[9,15].

In conclusion, an AC in the foramen of Magendie has never previously been reported to be symptomatic in an elderly patient. The breakdown of compensatory mechanisms might have contributed to the appearance of motor symptoms despite the absence of cyst expansion over 3 years. We propose that once neurological impairment is confirmed to attribute to the AC, surgical intervention to decompress the surrounding structures can result in a highly successful

clinical outcome, even though the patient is high-aged.

Conflict of Interest Disclosure

All authors have no conflict of interest.

Lists of Abbreviations;

AC; arachnoid cyst

CSF; cerebrospinal fluid

FIESTA; fast imaging employing steady state acquisition

MRI; magnetic resonance imaging

PBPC; persistent Blake pouch cyst

WI; weighted image

Reference

1. Al-Holou WN, Terman S, Kilburg C, Carton HJ, Muraszko KM, Maher CO. Prevalence and natural history of arachnoid cysts in adults. *J Neurosurg* 2013; 118: 222-231.
2. Al-Holou WN, Yew AY, Boomsaad ZE, Garton HJ, Muraszko KM, Maher CO. Prevalence and natural history of arachnoid cysts in children. *J Neurosurg Pediatrics* 2010; 5: 578-585.
3. Calabrò F, Arcuri T, Jinkins JR. Blake's pouch cyst: an entity within the Dandy-Walker continuum. *Neuroradiology* 2000; 42: 290-295.
4. Cornips EM, Overvliet GM, Weber JW, Postma AA, Hoeberigs CM, Baldewijns MM, Vles JS. The clinical spectrum of Blake's pouch cyst: report of six illustrative cases. *Childs Nerv Syst* 2010; 26:1057-1064.
5. Dyck P, Gruskin P. Supratentorial arachnoid cysts in adult. *Arch Neurol* 34; 276-279, 1977.
6. Fujita K, Ishida K, Tamaki N, Matsumoto S. Mid-line arachnoid cyst of the brain. *Neurol Med Chir (Tokyo)* 1983; 23: 387-392.
7. Fukushima Y, Sato M, Taguchi J, Sasaki M, Kanai N, Hayakawa T. Craniospinal arachnoid cyst. *Neurol Surg (No Shinkei Geka)* 1996; 24: 75-79.

8. Fulkerson DH, Vogel TD, Baker AA, Patel NB, Ackerman LI, Smith JI, Boaz JC. Cyst-ventricle stent as primary or salvage treatment for posterior fossa arachnoid cysts. *J Neurosurg Pediatrics* 2011; 7: 49–56.
9. Hishikawa T, Chikama M, Tsuboi M, Yabuno N. Two cases of symptomatic arachnoid cyst in elderly patients. A comparison and analysis with child cases. *Neurol Surg (No Shinkei Geka)* 2002; 30: 959-965.
10. Önal H, Adal E, Ersen A, Isik O, Önal Z, Arslan G. Arachnoid cysts in childhood with endocrinological outcomes. *The Turkish Journal of Pediatrics* 2011; 53: 295-300.
11. Pascual-Castroviejo I, Roche MC, Martínez Bermejo A, Arcas J, García Blázquez M. Primary intracranial arachnoidal cysts. A study of 67 childhood cases. *Childs Nerv Syst* 1991; 7: 257-263.
12. Price SJ, David KM, O'Donovan DG. Arachnoid cyst of the craniocervical junction. *Neurosurgery* 2001; 49: 212-215.
13. Utsunomiya H, Yamashita S, Takano K, Ueda Y, Fujii A. Midline cystic malformations of the brain: imaging diagnosis and classification based on embryologic analysis. *Radiat Med* 2006; 24: 471–481.

14. Verghese J, Mahore A, Goel A. Arachnoid cyst associated with painful tic convulsive. J. Clinical Neuroscience 2012; 19: 763-764.

15. Watanabe M, Kameyama S, Takeda N, Tanaka R. Two cases of symptomatic interhemispheric arachnoid cyst in the elderly. Surg Neurol 1994; 42: 346-351.

Figure Legends

Figure 1: (a) Axial section of pre-operative magnetic resonance imaging (MRI) on T2-weighted image (WI) reveals a cyst with isointensity to cerebrospinal fluid (CSF) located behind the medulla oblongata along the midline. (b) Sagittal section of preoperative MRI on fast imaging with steady state acquisition (FIESTA) shows the cyst to be composed of two portions, attached to the choroid plexus, and compressing both cerebellar hemispheres.

Figure 2: Intraoperative microscopic view after the removal of the small cyst at the outer membrane reveals that the cyst is located between the two hemispheres (a), and the part of the cyst wall was attached to the choroid plexus (b).

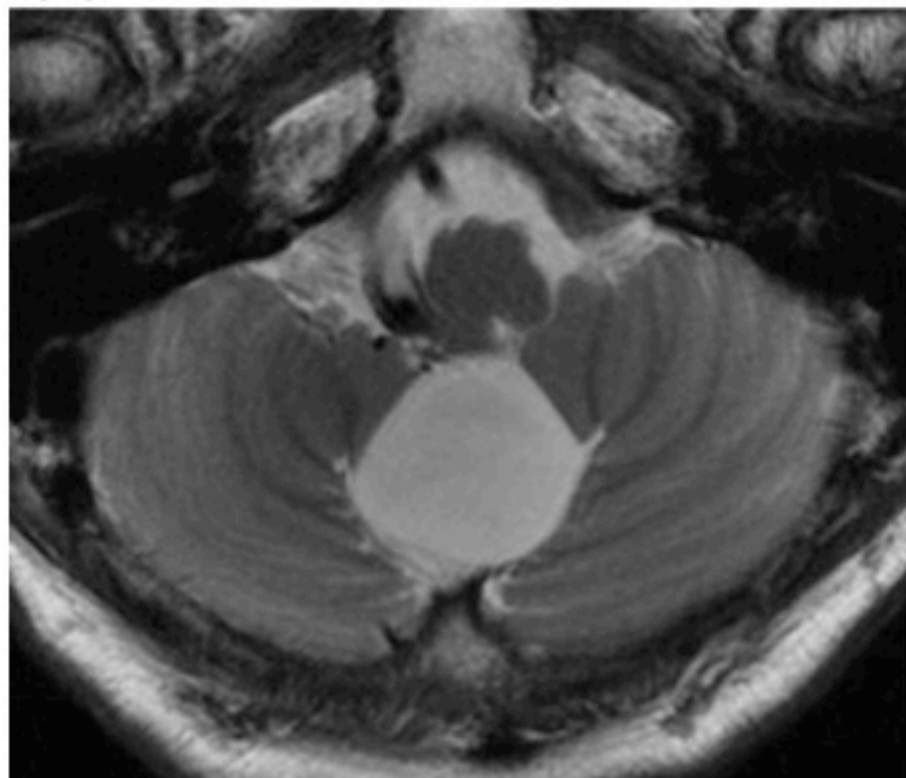
Figure 3: Photomicrograph demonstrating the cyst wall to be composed of a collagenous membrane lined by a single layer of arachnoid cells (hematoxylin and eosin; original magnification x 200).

Figure 4: (a) Axial section of postoperative MRI on T2-WI reveals that the cyst cavity has markedly reduced such that the CSF flow artifact can be seen clearly. (b) Sagittal section of postoperative MRI on FIESTA shows the residual CSF space in the foramen of Magendie.

Figure 1

Yasuhiko Hayashi

(a)



(b)

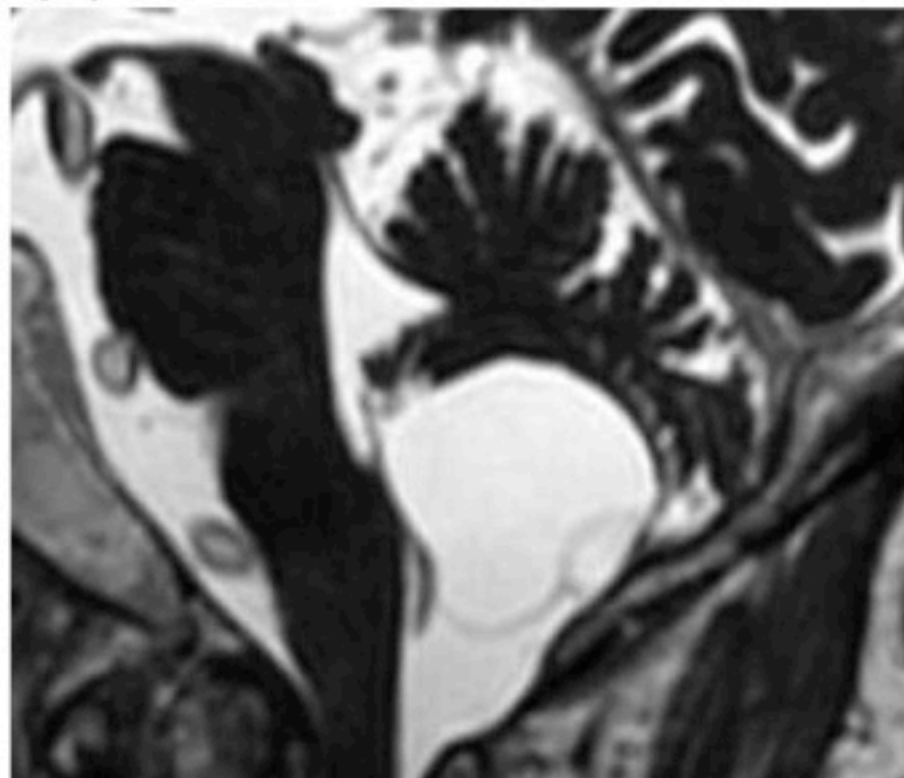
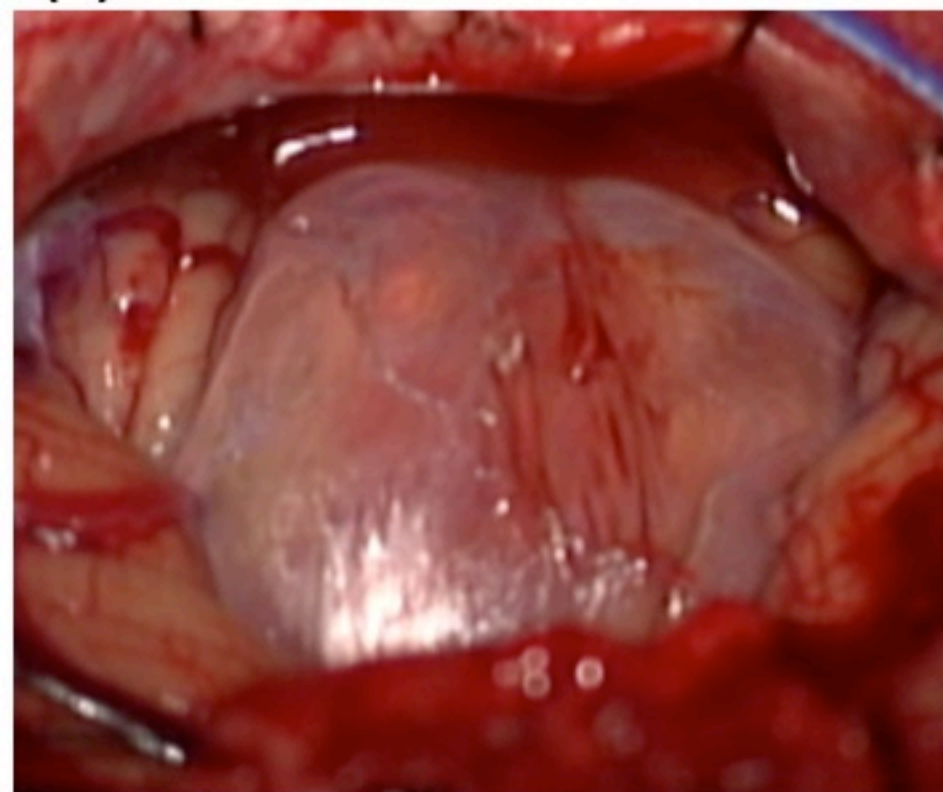


Figure 2

Yasuhiko Hayashi

(a)



(b)

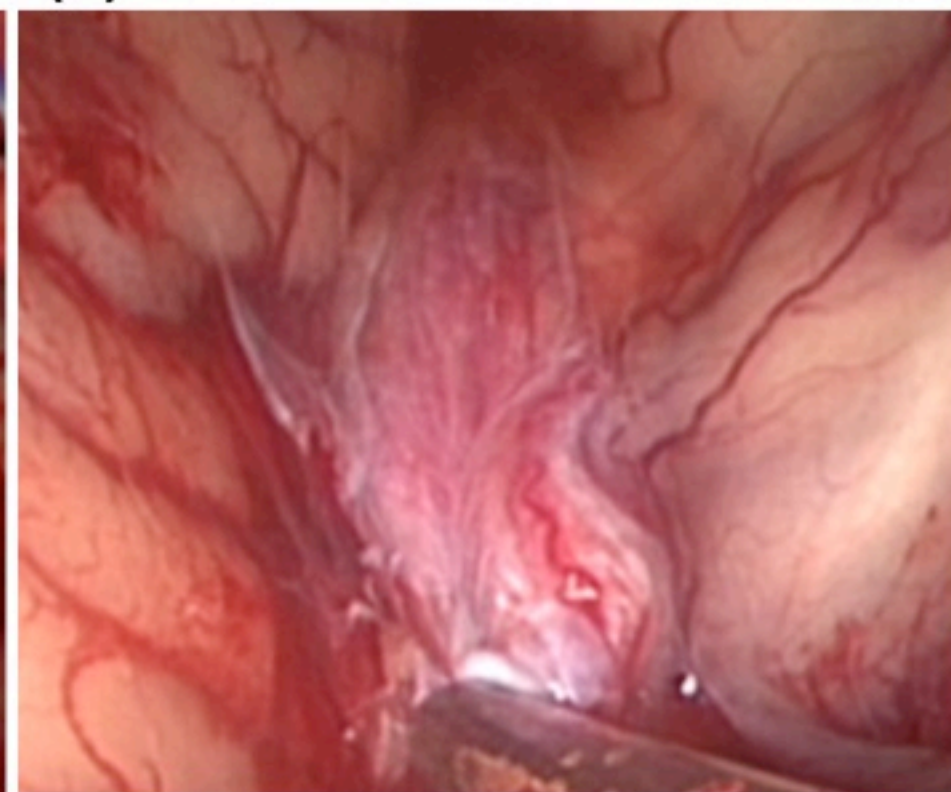


Figure 3

Yasuhiko Hayashi

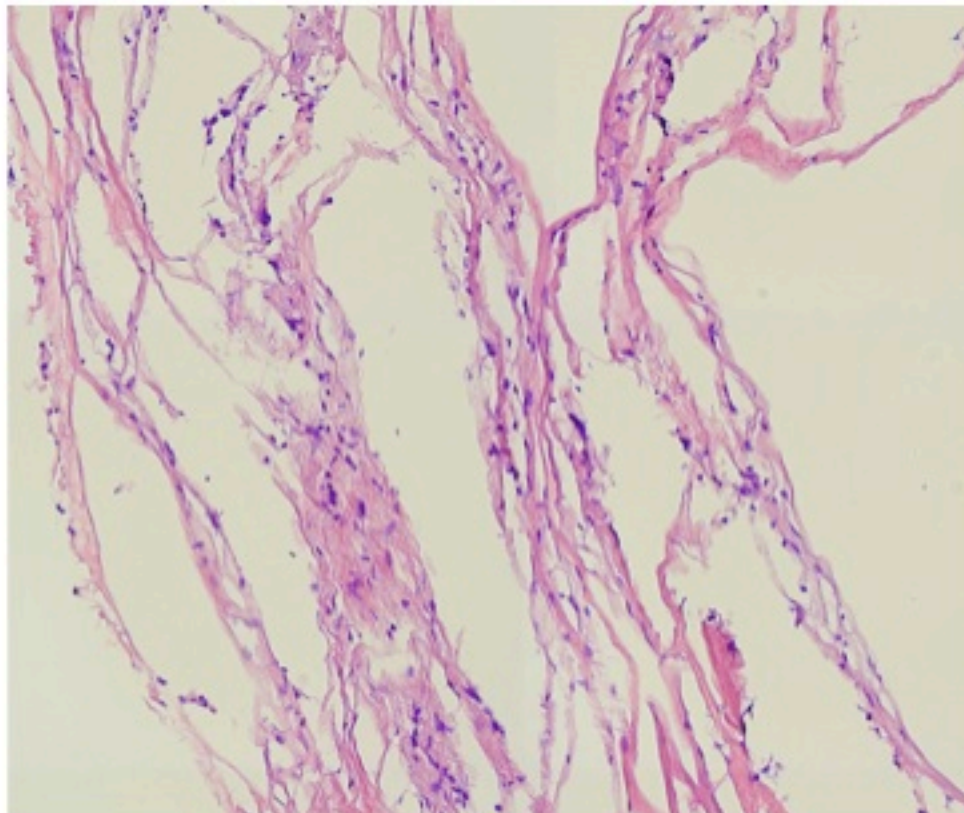
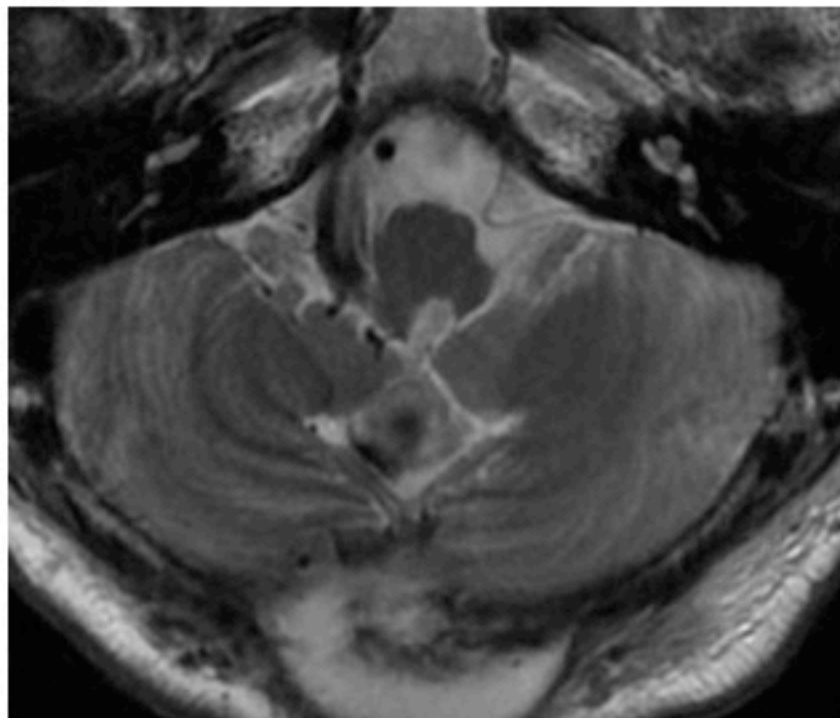


Figure 4

Yasuhiko Hayashi

(a)



(b)

