

Does Degree of the Pelvic Deformity Affect the Accuracy of Computed Tomography-Based Hip Navigation?

著者	Kajino Yoshitomo, Kabata Tamon, Maeda Toru, Iwai Shintaro, Kuroda Kazunari, Tsuchiya Hiroyuki
journal or publication title	Journal of Arthroplasty
volume	27
number	9
page range	1651-1657
year	2012-10-01
URL	http://hdl.handle.net/2297/32850

doi: 10.1016/j.arth.2012.03.009

Title

Does Degree of the Pelvic Deformity Affect the Accuracy of Computed Tomography–Based Hip Navigation?

Authors

Yoshitomo Kajino, MD, Tamon Kabata, MD, PhD, Toru Maeda, MD, PhD, Shintaro Iwai, MD, Kazunari Kuroda, MD, Hiroyuki Tsuchiya, MD, PhD

Abstract

Some navigation systems have been used for improvement of component positioning, there have been few reports regarding cases of severe pelvic deformity. We performed a retrospective review of 25 cases of THA with a computed tomography (CT)–based navigation system in patients with severe pelvic deformities and estimated acetabular component position and angle between severe deformity group and mild dysplastic group as a control. There were no significant differences in accuracy of navigation system between two groups in terms of three–dimensional component position or angle. Accuracy of CT–based hip navigation does not depend on the degree of pelvic deformity, and this system is also useful to identify acetabular orientation and for precise component implantation in cases of pelvic deformity.

Keywords:

total hip arthroplasty, pelvic deformity, computed tomography (CT)–based navigation system, acetabular component, developmental dysplasia.

Brief title:

Hip Navigation in Severe Pelvic Deformity

Introduction

The position of the acetabular component affects the results of total hip arthroplasty (THA) in terms of postoperative range of motion, dislocation, impingement, wear and osteolysis, and is also associated with long–term implant survival [1–4]. Precise positioning of the acetabular components in the normal native acetabulum also decreases shearing force on the component, and is thought to be ideal from a biomechanical viewpoint [4, 5]. Modification of the operative procedures and breakthroughs in implant technology have made it possible to perform THA even in patients with severe deformities. However, it is very difficult to place the acetabular component in the appropriate position in cases with severe acetabular deformity either freehand or with a mechanical device because of the difficulty of identifying the orientation around the acetabulum [3, 6, 7]. Although various navigation systems, including imageless, fluoroscopy–based and computed tomography (CT)–based navigation systems, have been developed to improve component positioning in THA and their usefulness has been reported [2, 6–10], there have been few reports regarding the accuracy of these navigation systems in THA in cases with severe acetabular deformities. For the treatment of such cases, we have used an intraoperative CT–based navigation system

for more precise implantation of acetabular components. The goal of the present study was to implant acetabular component accurately in normal native acetabulum using CT-based navigation system in the cases of severe pelvic deformity and to compare the accuracy of this system with regard to three-dimensional component position and angle with that of mild dysplastic group as a control

Materials and Methods

From May 2006 to April 2011, we performed a retrospective review of 25 hips in 22 patients with severe pelvic deformities and matched 25 hips in 25 patients with low-grade subluxation as a control group. The degree of subluxation in the dysplastic hip was graded according to the classification of Crowe *et al* [11]. Three patients in the study group had bilateral THAs. The patients' demographics are shown in Table 1. With the exception of the diagnosis, there were no significant differences in age, sex, side, height, weight or body mass index between the two groups. Preoperative diagnoses in the study group included severe developmental dysplasia of Crowe group III (75% – 100% subluxation) in 9 hips and Crowe group IV (> 100% subluxation) in 9 hips, ankylosis in 3 hips, destructive arthritis after infection in 1 hips, Charcot joint in 1 hip and one arthrodesed hip. Preoperative diagnoses in the control group were Crowe group I in 18 hips and primary osteoarthritis in 7 hips. Although femoral valgus osteotomy was performed in two cases and arthrodesis was performed in one case in the study group before THA, no previous operation in the pelvic side was performed between both groups.

Preoperative CT scan from the iliac wing to the femoral condyle was performed using a helical CT scanner (LightSpeed VCT, GE Medical Systems, Milwaukee, WI). The slice thickness was 1mm, and the pitch was 2.5–3.0 mm (almost 160–250 slices dependant on body constitution). The CT data were transferred to the planning module. Then, preoperative planning was performed to determine the optimal component size, angle and position using three-dimensional templating software (CT-based Hip, Version 1.0; Stryker Navigation, Freiburg, Germany). The acetabular component position was determined to place the implant at the site of the normal acetabulum, and the target angle of the components was set at anatomical inclination of 40° and anteversion of 20° which were equal to 38.3° of inclination and 12.7° of anteversion in radiographic manner [12]. The anterior pelvic plane (APP) defined by both the bilateral anterior superior iliac spine (ASIS) and pubic tubercle was used as a reference plane of the pelvis. If this plane was tilted in sagittal plane when the patient was lying in the supine position due to spine and pelvic deformities, the correction of anterior–posterior axis was performed in both groups during preoperative templating according to the previous studies [10], in brief, “functional pelvic plane“ was used as a reference plane [13].

All surgeries were performed by a single surgeon (senior author, TK) through a posterolateral approach in the lateral decubitus position under general anaesthesia using a CT-based and surface registration-type hip navigation system (CT-based Hip, Version 1.0; Stryker Navigation). Intraoperative surface registration was performed according to the method reported previously by Sugano *et al* [10]. Briefly, a reference tracker was mounted on the pelvic wing and surface matching was performed by touching more than 30 points around the acetabulum with a pointer after resection of the femoral head. In severe deformity group, digitising area were determined as wide as possible including native acetabulum, pseudo

acetabulum, the ala of the ilium, acetabular rim and posterior wall. The additional time for setup and registration of navigation system was almost five to ten minutes in both groups. After registration, it was possible for the surgeon to ream the acetabulum and implant the acetabular component with real-time confirmation of both the component position and angle on the navigation monitor. In this study, femoral components were implanted without use of the navigation system. In seven hips in the study group, subtrochanteric osteotomies were performed to prevent neurological problems, such as sciatic nerve palsy, due to the large degree of limb lengthening necessary (> 4 cm) and in the cases of excessive femoral anteversion, derotation was performed at subtrochanteric osteotomy site or using modular stem. The acetabular components used in both groups consisted of the same press fit titanium shell (TriAD®; Stryker Orthopaedics, Mahwah, NJ). The superolateral acetabular defect was filled with morselized autograft obtained from the reamed bone and femoral head. After implantation of the acetabular component, final cup orientation was recorded (intraoperative record).

The postoperative CT scan was performed at about 10 days after the operation in all cases and was uploaded to the same planning module to determine the postoperative component position and angle. We made the same coordinate plane manually as the plane determined in preoperative planning on the workstation, and measured various parameters to allow superposition of virtual computer-aided design (CAD) models of the acetabular component on the images of the actual implanted component (Fig. 1) [14, 15]. We evaluated the deviation of the three-dimensional position of the acetabular component from the center of the anterior pelvic plane between the position planned preoperatively and that calculated from postoperative CT scans. In addition, the deviation of anatomical anteversion and inclination angle between the preoperative plan, the intraoperative records from the navigation system and the data from postoperative CT scans were evaluated. We also investigated whether the size of the component planned preoperatively was the same as that actually implanted. Intraoperative error was evaluated by root mean square (RMS) analysis of registration to compare the accuracy of the registration process between the two groups [16]. Measurements were performed by the author (YK) who was independent of the operating surgeon. To reduce intra-observer error, each measurement was performed three times and the mean value was used. The inter-observer variability of postoperative measurements was also assessed in the first 10 hips by two other authors (SI, KK). Informed consent was obtained from the patients and the research protocol was approved by the hospital investigational review board. The authors received no benefits or funds in relation to this study.

Statistical analysis

A mean difference of 3° and 3 mm in navigation accuracy of the cup placement was identified as significant according to a previous report [8]. Then a sample size power analysis was performed and showed that 24 patients in each group would be sufficient to determine whether there was a significant difference with the power = 0.8 and $P < 0.05$. All statistical analyses were performed using SPSS ver. 19.0 (SPSS Inc., Chicago, IL). Mann-Whitney U test was used to compare the categorical data and the χ^2 test or Fisher's test was applied to compare the nominal observations. In all analyses, $P < 0.05$ was taken to indicate statistical significance.

Results

The mean deviations between preoperative planning and the actual component position were 3.2 ± 2.5 mm for the horizontal position, 3.4 ± 3.6 mm for the vertical position and 3.3 ± 2.3 mm for the anteroposterior position in the study group and 2.7 ± 2.3 mm, 2.7 ± 1.7 mm and 2.7 ± 1.7 mm, respectively, in the control group. There were no significant differences ($P=0.719$, 0.696 , and 0.609 , respectively) between the two groups (Table 2).

Intraoperative records were $39.4^\circ \pm 1.4^\circ$ inclination and $19.3^\circ \pm 2.0^\circ$ anteversion, respectively, in the study group and $39.0^\circ \pm 1.6^\circ$ and $19.4^\circ \pm 1.7^\circ$, respectively, in the control group. Postoperative measurements were $39.5^\circ \pm 1.7^\circ$ and $17.5^\circ \pm 2.9^\circ$, respectively, in the study group and $38.1^\circ \pm 1.8^\circ$ and $17.7^\circ \pm 2.9^\circ$, respectively, in the control group.

The mean deviations between preoperative planning and postoperative measurement were $1.5^\circ \pm 1.2^\circ$ inclination and $2.9^\circ \pm 1.8^\circ$ anteversion in the study group and $2.0^\circ \pm 1.7^\circ$ and $3.2 \pm 1.8^\circ$, respectively, in the control group (Table 3, Fig. 2). The mean deviations between intraoperative records and postoperative measurement were $1.5^\circ \pm 1.2^\circ$ and $2.5^\circ \pm 1.7^\circ$, respectively, in the study group and $1.4^\circ \pm 1.1^\circ$ and $2.7^\circ \pm 1.4^\circ$, respectively, in the control group (Table 3). There were no significant differences between the two groups ($P=0.657$, 0.632 , 0.744 and 0.645 , respectively). There were no complications related to use of the navigation system. The intraclass correlation coefficients (ICC) of the intra-observer measurement in inclination and anteversion were 0.826 and 0.823 , respectively. ICC of the measurements in the horizontal position, vertical position, and anteroposterior position were 0.995 , 0.999 and 0.999 , respectively. ICC of the inter-observer measurement were 0.824 and 0.865 , respectively and that of the measurements in the horizontal position, vertical position, and anteroposterior position were 0.987 , 0.993 and 0.997 , respectively. The accuracy of planning of the component size and RMS error of registration are shown in Table 4. There were no significant differences in the accuracy of planning of the component size and RMS error between the two groups ($P=0.702$ and 0.612).

Representative cases are shown in Figs. 3 and 4.

Discussion

Malpositioning of the acetabular component in THA increases the risk of reduced postoperative range of motion, dislocation, impingement, wear, osteolysis, *etc* [1–4]. Acetabular component malpositioning was reported as the single greatest factor determining the likelihood of both early and late revision surgery [17]. Lewinnek [18] investigated cases of postoperative dislocation and proposed a so-called “safe zone” of the acetabular component with radiographic inclination of $40^\circ \pm 10^\circ$ and anteversion of $15^\circ \pm 10^\circ$. Using a mathematical model, Widmer *et al.* [19] suggested combined femoral and acetabular anteversion to avoid impingement and achieve better postoperative range of motion. In our hospital, the target is to implant the acetabular component at the normal native acetabulum if possible, with anatomical inclination of 40° and anteversion of 20° which were equal to 38.3° of inclination and 12.7° of anteversion in radiographic manner [12] and which were almost center of the safe zone defined by Lewinnek. From the biomechanical viewpoint, it is thought to be ideal to implant the acetabular component in the normal

acetabulum [20]. Stans *et al.* [5] reviewed 82 patients with Crowe type III dysplasia undergoing cemented total hip arthroplasty, and reported that loosening of the acetabular components occurred significantly more frequently for those positioned outside compared to those inside the true acetabular region.

However, it is extremely difficult even for expert surgeons to place the acetabular component in the appropriate position in a freehand manner or using a conventional mechanical device in cases of severe acetabular deformity caused by severe developmental dysplasia, arthrodesed hip, *etc.* [4, 6, 7, 21] This is because the acetabulum in such cases has many deformities and bone defects, and there is neither a normal acetabular rim nor soft tissues, such as transverse acetabular ligament, to enable the surgeon to implant the component accurately [3,4]. These deformities are also related to the risk of postoperative complications [20].

On the other hand, many types of navigation system, including imageless, fluoroscopy-based and CT-based navigation systems, have been developed and have been shown to improve the accuracy of component positioning in THA and reduce postoperative complications [2, 6–10]. Imageless and fluoroscopy-based navigation systems have some advantages with regard to both radiation exposure and the lack of a necessity for intraoperative surface matching [2, 9]. However, these navigation systems were based on the morphology of the normal pelvis and therefore there is a risk of marked registration deviation and misalignment of the component in cases with severe acetabular deformities [8]. With the exception of a few case reports, there have been no previous investigations regarding the accuracy of these navigation systems in THA for the cases with severe acetabular deformities [6, 7].

In such cases, we used both preoperative three-dimensional templating and an intraoperative surface registration type CT-based navigation system to estimate whether the target position and angle of the component can be achieved, to facilitate precise implantation. Kalteis reported that this type of navigation system has advantages over imageless navigation systems in patients with abnormal anatomy, such as hip dysplasia, posttraumatic deformities or in revision procedures [8]. The CT-based navigation system used in the present study requires a preoperative CT scan, preoperative templating and intraoperative surface registration [10], and therefore it has disadvantages in terms of both cost and radiation exposure [16]. However, accurate component implantation is especially important in cases of severe deformity. Sugano *et al.* [22] investigated the mid-term results of cementless ceramic-on-ceramic THA with and without a CT-based navigation system similar to that used in the present study. They concluded that the navigation system made it possible to achieve acetabular orientation within the safe zone with reduced variance, and that there were higher rates of postoperative dislocation and mechanical problems related to impingement in the non-navigated group than in the navigated group because of malorientation of the acetabular component. In the present study, the accuracy of component placement was significantly improved by using the CT-based navigation system in patients with severe acetabular deformity. In addition, there were no significant differences between the severe deformity group and the control group in terms of the mean component position or angle. Pelvic deformities in the study group could affect the accuracy of the intraoperative registration, however there was no significant reference in RMS analysis of surface registration in both groups.

The present study had some limitations. First, the number of patients included in the study was small

since severe pelvic deformities such as Crowe III and IV were extremely rare and there might be some type II errors. Second, this was not a randomised and retrospective study. The selection of patients of the severe pelvic deformity was our own criteria and the pathologies in the study group were heterogeneous. Additionally, pathologies in both groups were not the same. However there were no significant differences in age, sex, side, height, weight or body mass index between the two groups and the patients' demographic factors were unlikely to affect the results. Third, clinical results were lacked in the present study since postoperative follow-up period was short. There was only one case of posterior dislocation in the cases of Crowe IV dislocated hip in the study group in early postoperative period due to inappropriate femoral anteversion and soft tissue imbalance, not a malposition of the acetabular component. And it was single event and didn't repeat any more. Also, there were no other major complications associated with cup position such as leg length discrepancy, iliopsoas pain, and so on. To elucidate the effectiveness of this type of navigation system, it will be necessary to accumulate long-term clinical results, including data regarding dislocation rate, implant survival and wear rate with or without this type of navigation system. However, our results were consistent with those of previous studies, and suggest that this system is useful for cases with severe acetabular deformities considering the relatively low degree of deviation from the target position.

In conclusion, 25 hips with severe acetabular deformities in 22 patients who underwent THA with a CT-based navigation system were retrospectively reviewed and compared with mild dysplastic group. There were no significant differences in accuracy of navigation system between two groups in terms of three-dimensional component position and angle. The use of CT-based computer navigation helps the surgeon to orient the acetabular component with minimal variation with regard to both component position and angle in cases of severe pelvic deformity.

Legend to Figures

Fig. 1.

Component position and angle were measured by superposition of CAD model of the acetabular component on the image of the actual implanted component.

Fig. 2.

Accuracy of the anteversion and inclination angles between preoperative planning and actual component position. The boundaries of the boxes indicate the 25th and 75th percentiles, and the lines within the boxes indicate the mean values. The whiskers above and below the boxes indicate the 90th and 10th percentiles.

Fig. 3.

(A) Preoperative anteroposterior radiograph of a 68-year-old woman with left arthrodesed hip and (B) postoperative radiograph at 1-year follow-up.

Fig. 4.

A 70-year-old woman with bilateral severe dislocated hip. (A) Preoperative and (B) postoperative anteroposterior radiographs at 8 (right) and 7-month (left) follow-up.

References

1. Soong M, Rubash HE, Macaulay W. Dislocation after total hip arthroplasty. *J Am Acad Orthop Surg* 2004;12:314.
2. Kalteis T, Handel M, Herold T, et al. Greater accuracy in positioning of the acetabular cup by using an image-free navigation system. *Int Orthop* 2005;29:272.
3. Kelley TC, Swank ML. Role of navigation in total hip arthroplasty. *J Bone Joint Surg Am* 2009;91 (Suppl 1):153.
4. Moskal JT, Capps SG. Improving the accuracy of acetabular component orientation: avoiding malposition. *J Am Acad Orthop Surg* 2010;18:286.
5. Stans AA, Pagnano MW, Shaughnessy WJ, et al. Results of total hip arthroplasty for Crowe Type III developmental hip dysplasia. *Clin Orthop Relat Res* 1998;348:149.
6. Jingushi S, Mizuuchi H, Nakashima Y, et al. Computed tomography-based navigation to determine the socket location in total hip arthroplasty of an osteoarthritis hip with a large leg length discrepancy due to severe acetabular dysplasia. *J Arthroplasty* 2007;22:1074.
7. Akiyama H, Kawanabe K, Ito T, et al. Computed tomography-based navigation to determine the femoral neck osteotomy and location of the acetabular socket of an arthrodesed hip. *J Arthroplasty* 2009;24:1292.
8. Kalteis T, Handel M, Balthis H, et al. Imageless navigation for insertion of the acetabular component in total hip arthroplasty: is it as accurate as CT-based navigation? *J Bone Joint Surg Br* 2006;88:163.
9. Weil Y, Mattan Y, Kandel L, et al. Navigation-assisted minimally invasive two-incision total hip arthroplasty. *Orthopedics* 2006;29:200.
10. Sugano N, Takao M, Sakai T, et al. Comparison of mini-incision total hip arthroplasty through an anterior approach and a posterior approach using navigation. *Orthop Clin North Am* 2009;40:365.
11. Crowe JF, Mani VJ, Ranawat CS. Total hip replacement in congenital dislocation and dysplasia of the hip. *J Bone Joint Surg Am* 1979;61:15.

12. Murray DW. The definition and measurement of acetabular orientation. *J Bone Joint Surg Br* 1993;75:228.
13. Miki H, Yamanashi W, Nishii T, et al. Anatomic hip range of motion after implantation during total hip arthroplasty as measured by a navigation system. *J Arthroplasty* 2007;22:946.
14. Kitada M, Nakamura N, Iwana D, et al. Evaluation of the Accuracy of Computed Tomography–Based Navigation for Femoral Stem Orientation and Leg Length Discrepancy. *J Arthroplasty* 2011;26:674.
15. Lin F, Lim D, Wixson RL, et al. Limitations of Imageless Computer–Assisted Navigation for Total Hip Arthroplasty. *J Arthroplasty* 2011;26:596.
16. Sugano N, Sasama T, Sato Y, et al. Accuracy evaluation of surface–based registration methods in a computer navigation system for hip surgery performed through a posterolateral approach. *Comput Aided Surg* 2001;6:195.
17. Steppacher SD, Kowal JH, Murphy SB. Improving cup positioning using a mechanical navigation instrument. *Clin Orthop Relat Res* 2011;469:423.
18. Lewinnek GE, Lewis JL, Tarr R, et al. Dislocations after total hip–replacement arthroplasties. *J Bone Joint Surg Am* 1978;60:217.
19. Widmer KH, Zurfluh B. Compliant positioning of total hip components for optimal range of motion. *J Orthop Res* 2004;22:815.
20. Numair J, Joshi AB, Murphy JC, et al. Total hip arthroplasty for congenital dysplasia or dislocation of the hip. Survivorship analysis and long–term results. *J Bone Joint Surg Am* 1997;79:1352.
21. Minoda Y, Kadowaki T, Kim M. Acetabular component orientation in 834 total hip arthroplasties using a manual technique. *Clin Orthop Relat Res* 2006;445:186.
22. Sugano N, Nishii T, Miki H, et al. Mid–term results of cementless total hip replacement using a ceramic–on–ceramic bearing with and without computer navigation. *J Bone Joint Surg Br* 2007;89:455.

Table 1. Patient demographic data of the two groups

Patient characteristics	Study group (n=25)	Control group (n=25)	P-value
Age	62.8 ± 10.3 (36-81)	64.9 ± 10.0 (51-87)	0.686
Sex (female / male)	24 / 1	21 / 4	0.349
Side (left / right)	13 / 12	19 / 6	0.141
Height (cm)	149.3 ± 6.5 (137-163)	152.1 ± 6.6 (137-165)	0.614
Weight (kg)	56.0 ± 9.6 (38-75)	53.8 ± 10.7 (38-77)	0.733
Body mass index (kg/m ²)	25.3 ± 5.0 (16.4-36.7)	23.1 ± 3.7 (18.5-30.2)	0.681
Diagnosis	Crowe III: 9 Crowe IV: 9 ankylosis: 3 destructive arthritis: 1 Charcot joint: 1 arthrodesed hip: 1	Crowe I: 18 primary osteoarthritis: 7	

All values are means ± standard deviation (range).

Table 2. Results of mean deviation between preoperative planning and actual component position

Parameters	Study group (n=25)	Control group (n=25)	P-value
Horizontal position (mm)	3.2 ± 2.5 (0-9.7)	2.7 ± 2.3 (0-8.0)	0.719
Vertical position (mm)	3.4 ± 3.6 (0-15.0)	2.7 ± 1.7 (0.3-6.3)	0.696
Anteroposterior position (mm)	3.3 ± 2.3 (0-8.7)	2.7 ± 1.7 (0-6.3)	0.609

All values are means ± standard deviation (range).

Table 3. Results of component angle

Parameters	Inclination		Anteversion	
	Study group	Control group	Study group	Control group
Preoperative planning (Pre)	40.0 ± 0.0 (40)	40.0 ± 0.0 (40)	20.0 ± 0.0 (20)	20.0 ± 0.0 (20)
Intraoperative record (Intra)	39.4 ± 1.4 (35-41)	39.0 ± 1.6 (37-43)	19.3 ± 2.0 (12-22)	19.4 ± 1.7 (17-24)
Postoperative measurement (Post)	39.5 ± 1.7 (36.3-43.0)	38.1 ± 1.8 (34.7-40.7)	17.5 ± 2.9 (10.3-22.3)	17.7 ± 2.9 (14.3-23.0)
Pre – Post	1.5 ± 1.2 (0-3.7)	2.0 ± 1.7 (0-5.3)	2.9 ± 1.8 (0.3-7.0)	3.2 ± 1.8 (0-5.7)
P-value	0.657		0.632	
Intra – Post	1.5 ± 1.2 (0-4.7)	1.4 ± 1.1 (0-4.3)	2.5 ± 1.7 (0-7.0)	2.7 ± 1.4 (0-5.7)
P-value	0.744		0.645	

All values are means ± standard deviation (range).

Table 4. Results of component size and RMS analysis

Parameters	Study group (n=25)	Control group (n=25)	<i>P</i> -value
Accuracy of the component size	20 / 25 (80.0%)	22 / 25 (88.0%)	0.702
Error of RMS analysis (mm)	0.78 ± 0.21 (0.45–1.31)	0.87 ± 0.23 (0.51–1.53)	0.612

All values are means ± standard deviation (range).

RMS: root mean square

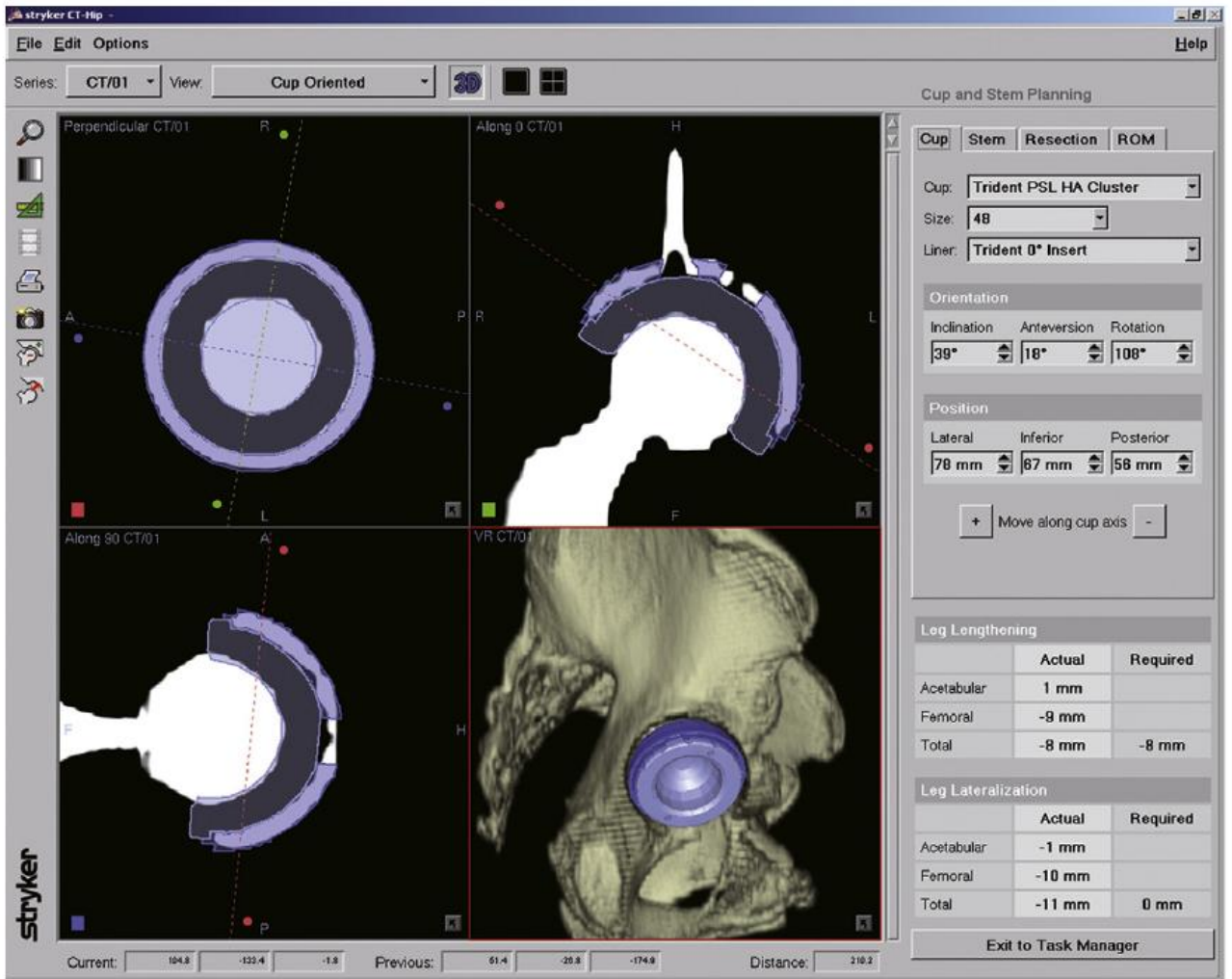


Fig. 1. Component position and angle were measured by superposition of computer-aided design model of the acetabular component on the image of the actual implanted component.

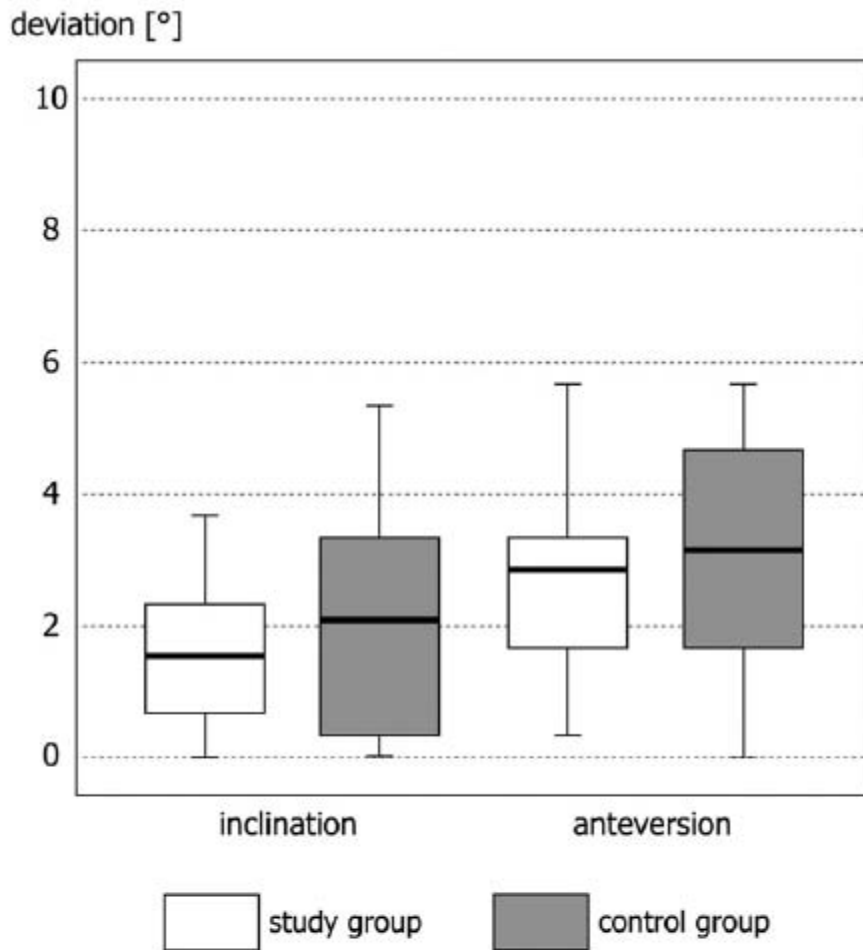


Fig. 2. Accuracy of the anteversion and inclination angles between preoperative planning and actual component position. The boundaries of the boxes indicate the 25th and 75th percentiles, and the lines within the boxes indicate the mean values. The whiskers above and below the boxes indicate the 90th and 10th percentiles.

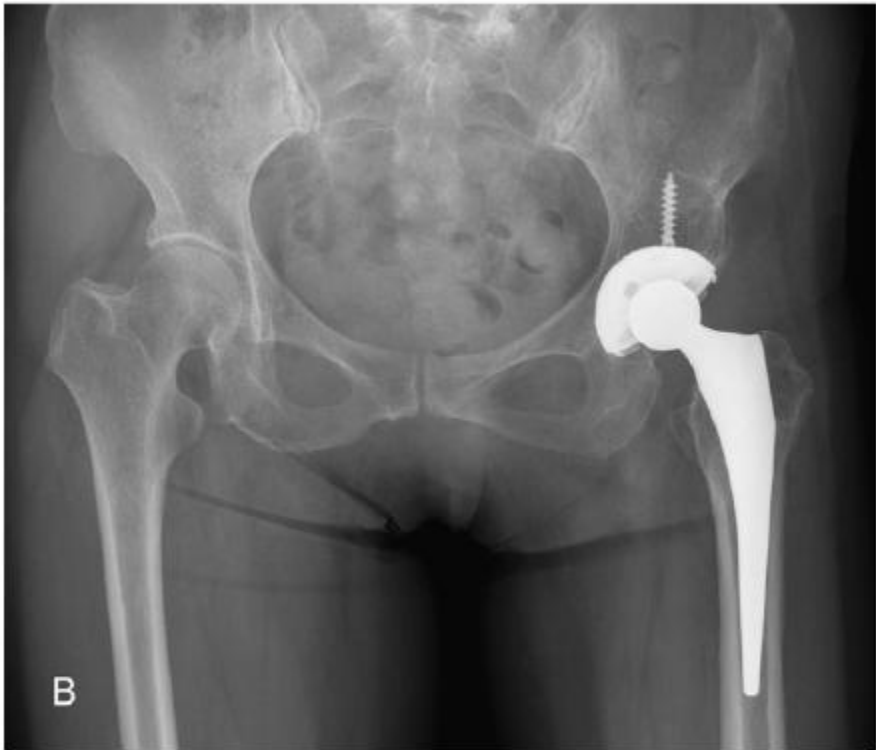
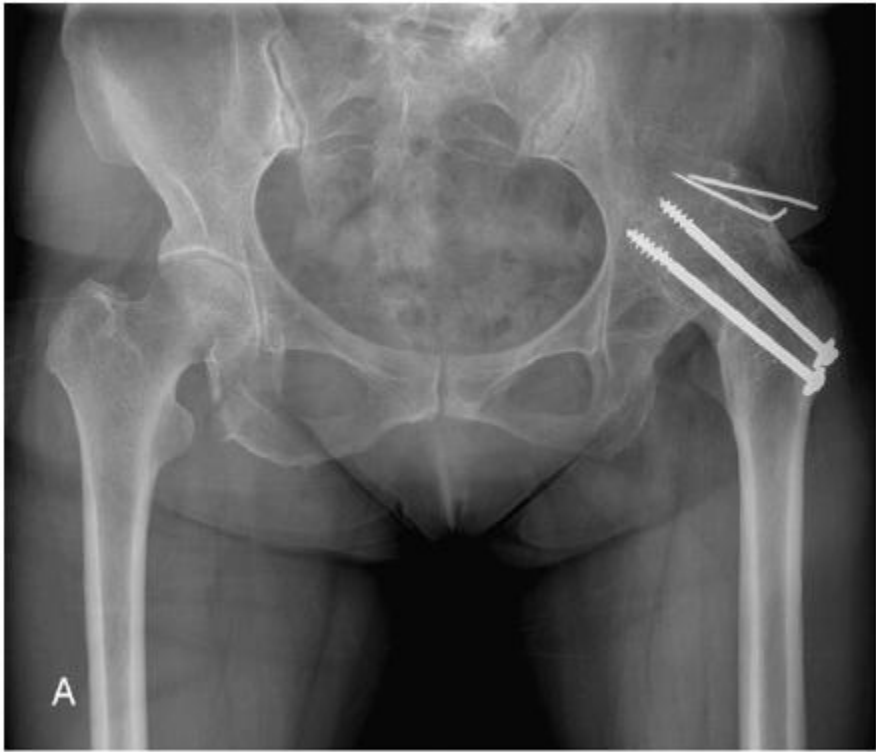
Fig. 3. (A) Preoperative anteroposterior radiograph of a 68-year-old woman with left arthrodesed hip and (B) postoperative radiograph at 1-year follow-up.

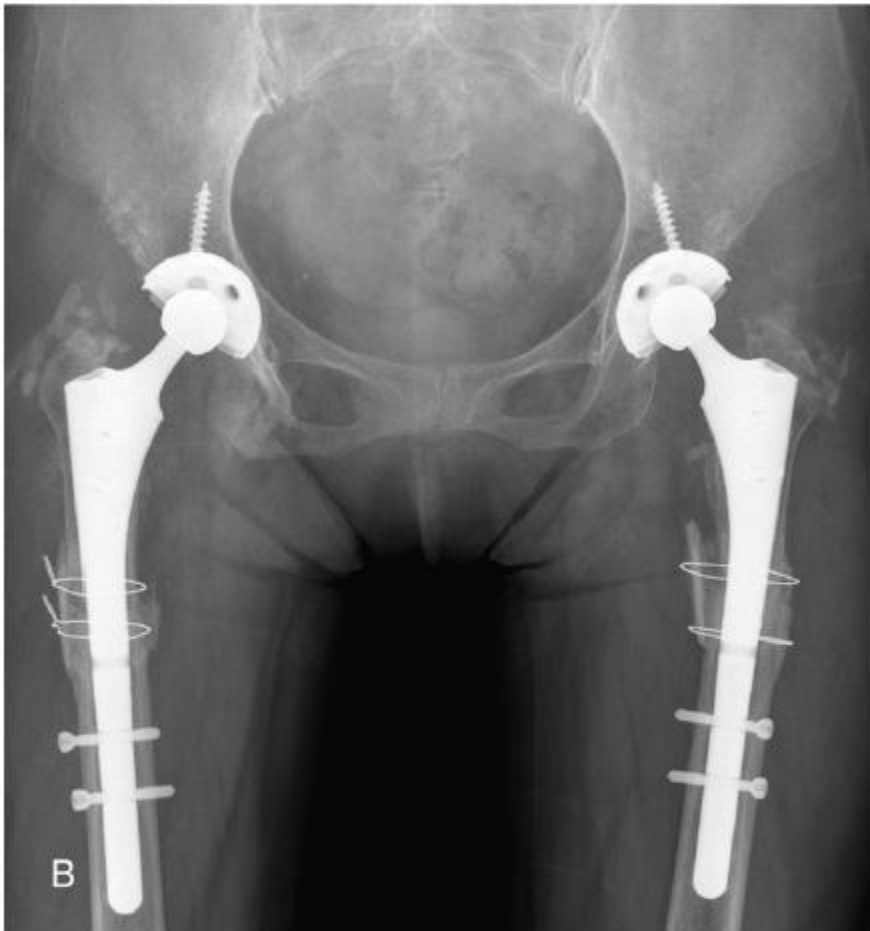
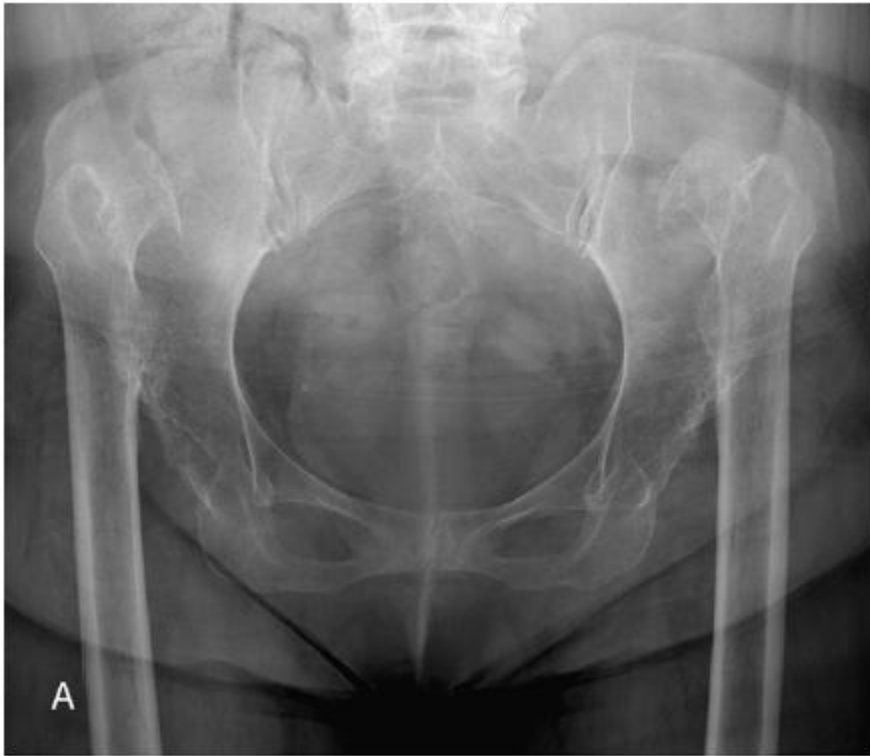
Fig. 4. A 70-year-old woman with bilateral severe dislocated hip. Preoperative (A) and postoperative (B) anteroposterior radiographs at 8- (right) and 7-month (left) follow-up.