

14-Cmethionine uptake as a potential marker of inflammatory processes after myocardial ischemia and reperfusion

著者	Taki Junichi, Wakabayashi Hiroshi, Inaki Anri, Imanaka-Yoshida Kyoko, Hiroe Michiaki, Ogawa Kazuma, Morooka Miyako, Kubota Kazuo, Shiba Kazuhiro, Yoshida Toshimichi, Kinuya Seigo
journal or publication title	Journal of Nuclear Medicine
volume	54
number	3
page range	431-436
year	2013-03-01
URL	http://hdl.handle.net/2297/34158

doi: 10.2967/jnumed.112.112060

¹⁴C-Methionine Uptake as a Potential Marker of Inflammatory Process after Myocardial Ischemia and Reperfusion

Junichi Taki¹, Hiroshi Wakabayashi¹, Anri Inaki, MD¹, Kyoko Imanaka-Yoshida², Michiaki Hiroe³, Kazuma Ogawa⁴, Miyako Morooka⁵, Kazuo Kubota⁵, Kazuhiro Shiba⁶, Toshimichi Yoshida², and Seigo Kinuya¹

¹*Department of Nuclear Medicine, Kanazawa University Hospital, Kanazawa, Japan;* ²*Department of Pathology and Matrix Biology, Mie University School of Medicine, Tsu, Japan;* ³*Department of Cardiology, National Center for Global Health and Medicine, Tokyo, Japan;* ⁴*Graduate School of Natural Science and Technology, Kanazawa University, Kanazawa, Japan;* ⁵*Division of Nuclear Medicine, Department of Radiology, National Center for Global Health and Medicine, Tokyo, Japan;* ⁶*Division of Tracer Kinetics, Advanced Science Research Center, Kanazawa University, Kanazawa, Japan.*

This work has been supported by Grants-in-aid for scientific research (C-23591756 to Junichi Taki and 21590927 to Kyoko Imanaka-Yoshida) from the Ministry of Education, Culture, Sports, Science, and Technology, Japan; by a research grant for intractable diseases from the Ministry of Health, Labor and Welfare of Japan (to Kyoko Imanaka-Yoshida and to Michiaki. Hiroe), and by a grant from the Japan Foundation for the Promotion of the International Medical Center of Japan (to Michiaki Hiroe); by a grant from the National Center for Global Health and Medicine (No.21-126 to Junichi Taki).

The authors have reported that they have no relationships to disclose.

Address for correspondence and reprint requests:

Junichi Taki, MD, PhD

Department of Nuclear Medicine, Kanazawa University Hospital,

13-1 Takara-machi, Kanazawa, 920-8641, Japan.

Tel; +81-76-265-2333

Fax;+81-76-234-4257

E-mail; taki@med.kanazawa-u.ac.jp

Short running foot line: Methionine uptake in AMI

Total word count:4160

Abstract

A relation between ^{11}C -methionine uptake and angiogenesis has been suggested in gliomas. However, methionine uptake in myocardial ischemia and reperfusion has received little attention. We investigated the serial changes and mechanisms of ^{14}C -methionine uptake in a rat model of myocardial ischemia and reperfusion.

Methods: The left coronary artery was occluded for 30-minutes followed by reperfusion for 1 day to 28 days. At the time of the study, ^{14}C -methionine (0.74 MBq) and ^{201}Tl (14.8MBq) were injected intravenously at 20 and 10 minutes before sacrifice, respectively. One minute before sacrifice the left coronary artery was reoccluded, and $^{99\text{m}}\text{Tc}$ -MIBI (150-180 MBq) was injected to verify the area at risk. Histological sections of the heart were immunohistochemically analyzed using anti-CD68, anti- α -smooth muscle actin (SMA) and anti-troponin I, and compared with the autoradiography findings.

Results: Both ^{14}C -methionine (uptake ratio 0.71 ± 0.13) and ^{201}Tl uptake were reduced in the area at risk at 1 day after reperfusion. However, 3 days after reperfusion, an increased ^{14}C -methionine uptake (1.79 ± 0.23) was observed corresponding to the area of still reduced ^{201}Tl uptake, and the ^{14}C -Methionine uptake gradually declined until 28 days. The increased ^{14}C -methionine uptake area at 3 and 7 days corresponded well to the macrophage infiltrations demonstrated by positive CD68 staining. Anti α -SMA staining appeared at 7 days, after which CD68 staining was gradually replaced by the SMA staining, suggesting that methionine uptake in the early phase after ischemia and reperfusion might reflect inflammatory activity.

Conclusions: ^{14}C -methionine accumulated in the infarcted area, and its uptake

corresponded closely to macrophage infiltration at 3-7 days after reperfusion. Methionine imaging may be useful for inflammatory imaging early after myocardial infarction.

Key words: methionine, myocardial ischemia, reperfusion, myocardial infarction, macrophage.

INTRODUCTION

L-[methyl- ^{11}C]methionine (^{11}C -methionine) has been used for the evaluation of various tumors, especially for brain tumors because of its low physiologic uptake by brain tissue (1). The uptake mechanism of ^{11}C -methionine in tumors depends mainly on carrier mediated transport systems (2) and correlates with the proliferative activity (3) and microvessel density (4), which reflects angiogenesis. However, since it has also been reported that the cell density contributes more to ^{11}C -methionine uptake than the microvessel density in human glioma (5, 6), the mechanism of ^{11}C -methionine uptake remains to be clarified.

Other than in tumors, radiolabeled amino acids including ^{11}C -methionine have been investigated in only a few studies. In canine myocardium, ^{13}N and ^{11}C -labeled L-amino acid kinetics were investigated in the evaluation of the amino acid metabolism (7, 8). In pacing induced ischemia, ^{13}N -glutamine and ^{13}N -alanine accumulate in the ischemic area demonstrated as perfusion defects by ^{13}N -ammonia (7). During low flow ischemia and after reperfusion, a higher retention of ^{13}N -labeled-amino acids compared with controls was observed (8).

Recently, we reported that ^{11}C -methionine uptake is elevated in the infarcted areas in patients with acute myocardial infarction and successful percutaneous coronary intervention (9). We speculated that this may reflect the early phase of damage healing involving processes such as inflammatory process and angiogenesis.

Therefore, to evaluate the underlying mechanisms of methionine uptake in myocardial infarction, we explored its spatial and temporal changes after myocardial ischemia and reperfusion using ^{14}C -methionine in a rat model of acute ischemia and reperfusion. Furthermore, we correlated the spatiotemporal uptake

pattern of methionine to the histopathological features during the healing process of acute myocardial infarction.

MATERIAL AND METHODS

Animal Model of Acute Ischemia and Reperfusion

All experimental procedures involving animals were conducted in accordance with the institutional guidelines set by the Institute for Experimental Animals, Kanazawa University Advanced Science Research Center. Eight to ten-week-old male Wistar rats (n=28) were anesthetized with an intraperitoneal administration of 40 mg of pentobarbital per kilogram and ventilated mechanically with room air. After left thoracotomy and exposure of the heart, a 7-0 polypropylene suture on a small curved needle was passed through the myocardium beneath the proximal portion of the left coronary artery (LCA), and both ends of the suture were passed through a small vinyl tube to make a snare. The suture material was pulled tight against the vinyl tube to occlude the LCA. Myocardial ischemia was confirmed by regional cyanosis of the myocardial surface and ST-segment elevation on the electrocardiogram. After 30 minutes interval of LCA occlusion, reperfusion was obtained by release of the snare and confirmed by a myocardial blush over the area at risk. The snare was left loose on the surface of the heart until repeated thoracotomy for reocclusion of the LCA just before sacrifice to identify the area at risk (10). Groups of animals were studied at 1 day (n=6), 3 days (n=5), 7 days (n=5), 14 days (n=6), and 28 days (n=6) after reperfusion. At the time of the study ^{14}C -methionine (0.74 MBq) (Methionine, L-[methyl- ^{14}C], American Radiolabeled

Chemicals, Inc, St. Louis; specific activity: 2.04 GBq / mmol, Radiochemical purity: greater than 98%) was administered via a tail vein 20 minutes before sacrifice. Then ^{201}Tl (14.8 MBq) was administered at 10 minutes before sacrifice to measure the infarcted area. One minute before sacrifice, 150-180 MBq of $^{99\text{m}}\text{Tc}$ -hexakis-2-methoxyisobutylisonitrile (MIBI) was injected via a tail vein just after the reocclusion of the proximal portion of the LCA for delineation of the area at risk. One minute later, the rat was euthanized and the heart was removed for analysis (Fig. 1). The excised heart was rinsed in saline, frozen in isopentane, cooled in dry ice, and embedded in methyl cellulose. Serial short-axis heart sections of 20 μm thickness were obtained by sectioning on a cryostat to create a series of rings for autoradiography.

Triple-Tracer Autoradiography

Triple tracer autoradiography of the left ventricular short axis slices was performed for the assessment of ^{14}C -methionine uptake, ^{201}Tl uptake, and ischemic area ($^{99\text{m}}\text{Tc}$ -MIBI image). The first autoradiographic exposure on an imaging plate (BAS-MS, Fuji Film) was performed for 15-20 minutes to visualize the area at risk expressed by $^{99\text{m}}\text{Tc}$ -MIBI distribution at 1 to 2 hours after sacrifice. Three days later (12 half-lives of $^{99\text{m}}\text{Tc}$) the second exposure was made for 5-8 hours to image the distribution of ^{201}Tl . One month later, the third exposure, for visualization of methionine uptake, was performed for 1-2 weeks.

Data Analysis

Tracer accumulations were evaluated in 3 myocardial slices at the mid ventricular level spaced 1 mm apart from one another. The distribution of the tracers was determined by analysis of the digitized autoradiography. The photostimulated luminescence in each pixel (50 X 50 μm) was determined using a

bioimaging analyzer (BAS-5000, Fuji Film). For quantitative analysis, the uptake values of each region of interest (ROI) were expressed as the background-corrected photostimulated luminescence per unit area (0.25 mm²). A background ROI was set adjacent to the left ventricle. Ischemic and normally perfused areas were defined from the ^{99m}Tc-MIBI image, and these ROIs were applied to both the ¹⁴C-methionine and ²⁰¹Tl images to evaluate the uptake of ¹⁴C-methionine and ²⁰¹Tl. Ischemic area was divided into salvaged and infarcted area arbitrarily by ²⁰¹Tl uptake (equal to or more than 60% uptake and less than 60% of normally perfused area, respectively) (11). Significant ¹⁴C-methionine uptake area was also defined manually as an ROI. ¹⁴C-methionine uptake ratio in an ischemic area was calculated by dividing the uptake value in an ischemic area by that of a normally perfused area. ¹⁴C-methionine uptake ratios of salvaged and infarcted areas were also calculated. The ratio of ¹⁴C-methionine uptake ROI area to ischemic ROI area was defined as the percentage of the ¹⁴C-methionine uptake area. All parameters in each rat were expressed as the average value obtained from the analysis of 3 representative slices.

Immunohistochemical Staining

Short axis frozen sections in 5 μm thick and adjacent to the slices for autoradiography were mounted on slides. They were washed with PBS and immunostained with **mouse anti-rat CD68 macrophage antibody (clone ED1; MBA Biomedical, Augst, Switzerland)** to determine macrophage infiltration after ischemia and reperfusion. Viable cardiomyocytes were immunostained with rabbit polyclonal anti-cardiac troponin I antibody (Abcam, **Cambridge, MA**). The following secondary antibodies were used: peroxidase conjugated goat anti-rabbit IgG **or anti-mouse** IgG (MBL, Nagoya, Japan). Diaminobenzidine/H₂O₂ solution

was used to demonstrate peroxidase conjugated secondary antibody binding. Also the slices were immunofluorescently double stained with anti-cardiac troponin I antibody and either anti-CD68, or FITC-conjugated anti-smooth muscle α actin (SMA, clone 1A4, Sigma). The following secondary antibodies were also used: FITC-conjugated goat anti-mouse IgG (MBL, Nagoya, Japan), Alexa Fluor 546 F(ab')₂ fragment of goat anti-rabbit IgG (H+L) (Molecular Probes). The samples were observed under a conventional fluorescent or light microscope (Olympus, Tokyo, JAPAN), and images were recorded with a cooled CCD camera. The immunofluorescent signals for each stain were converted into pseudo-color and superimposed using Photoshop.

Statistical Analysis

All results were expressed as the mean \pm 1 SD. Statistical analyses were performed using a Macintosh computer with software JMP 8.0.1J. Group comparisons were performed using the Tukey-Kramer method to identify differences among groups. Comparisons of methionine uptake ratio between salvaged and infarcted areas at each reperfusion time were performed by paired t test. A value of $P < 0.05$ was considered statistically significant.

RESULTS

Size of Area with ¹⁴C-methionine Uptake Against Area at Risk

The percentages of ¹⁴C-methionine uptake areas against area at risk in rats with 30 min ischemia and reperfusion at 3, 7, 14, 28 days were similar (41.1 ± 18.7 %, 38.7 ± 11.4 %, 52.9 ± 10.5 %, 44.0 ± 8.8 %, respectively, $p = \text{ns}$) (Fig. 2).

¹⁴C-methionine and ²⁰¹Tl Uptake in Autoradiography

In the visual analysis, 1 day after reperfusion, both ²⁰¹Tl and ¹⁴C-methionine

uptakes were reduced in the area at risk. Thereafter ^{201}Tl uptake recovered slightly but was still reduced compared to the remote area from ischemia and reperfusion until 28 days after reperfusion (Fig. 3). In contrast, significantly increased ^{14}C -methionine uptake was observed at 3 days after reperfusion in the area at risk, after which the uptake gradually decreased until 28 days after reperfusion. The distribution of ^{14}C -methionine uptake roughly corresponded to the area with the more reduced ^{201}Tl uptake in the area at risk (Fig. 3).

In the quantitative analysis, ^{201}Tl uptake ratio at 1 day after reperfusion was severely suppressed (0.35 ± 0.13) and was significantly increased at 3 days to 0.66 ± 0.10 . Thereafter the ratios were similar at around 0.6 to 0.7: uptake ratios at 7, 14, and 28 days were 0.70 ± 0.21 , 0.72 ± 0.09 , 0.64 ± 0.09 , respectively.

^{14}C -methionine uptake ratio at 1 day after reperfusion was also suppressed (0.71 ± 0.13); however, the uptake at 3 days after reperfusion increased significantly to 1.79 ± 0.23 . Subsequently, the ratios declined gradually until 28 days: uptake ratios at 7, 14, 28 days were 1.52 ± 0.20 , 1.31 ± 0.12 , and 1.12 ± 0.08 , respectively (Fig. 4). When ^{14}C -methionine uptake was compared between salvaged and infarcted areas, the uptake ratios in the infarcted area were always higher than those in the salvaged area except for day 28: ^{14}C -methionine uptake ratios in infarcted and salvaged areas were 0.88 ± 0.15 and 0.58 ± 0.094 at day 1 ($p < 0.001$), 1.87 ± 0.27 and 1.65 ± 0.25 at day 3 ($p < 0.05$), 1.60 ± 0.45 and 1.28 ± 0.26 at day 7 ($p < 0.05$), 1.38 ± 0.16 and 1.26 ± 0.10 at day 14 ($p < 0.05$), 1.14 ± 0.097 and 1.10 ± 0.075 at day 28 ($p = \text{ns}$), respectively.

Comparison of Autoradiography and Histopathological findings

The significant accumulation of ^{14}C -methionine uptake in autoradiography corresponded closely to the area with positive immunohistopathological staining

with anti CD68 macrophage antibody at days 3 and 7 (Fig. 5). At 14 days, although anti-CD 68 staining was greatly reduced, ^{14}C -methionine uptake continued to be detected in the reduced ^{201}Tl uptake area (Fig. 5).

Double immunofluorescent staining demonstrated that many CD68 positive macrophages accumulated in the absent part of troponin I positive viable cardiomyocytes, peaked at day 3, and then gradually decreased after day 7 (Fig. 6).

No SMA positive cells were found in the troponin I negative area at day 3, while numerous SMA positive cells were seen at day 7 (Fig. 6). Direct comparison of staining with anti-CD68 and anti-SMA (Fig. 7) showed that no SMA positive cells were detected in the macrophage rich area at 3 days, while numerous SMA positive cells were present in the area where macrophages infiltrated at 7 days. At 14 days and later, with decreased number of macrophages, SMA positive cells became predominant. Some of the SMA staining showed ring-like and tubular configurations, suggesting that SMA positive cells may form luminal structures, possibly being recruited as mural cells of newly formed blood vessels (Fig. 7).

DISCUSSION

The present study documented spatiotemporal profiling of ^{14}C -methionine uptake after myocardial ischemia and reperfusion in the myocardium with 30 minutes of ischemia and reperfusion in rats. ^{14}C -methionine accumulated in the infarcted area, and the uptake corresponded well to the macrophage infiltration at 3-7 days after reperfusion. Accordingly, methionine imaging may be useful for inflammatory imaging early after myocardial infarction.

In general, the process of myocardial tissue repair and healing following acute myocardial infarction is considered to consist of 4 phases based on the pathological

findings: cardiomyocyte death, acute inflammation, formation of granulation tissue, and scar formation (12). In the phase of acute inflammation, macrophages play multiple roles, including phagocytosis of the dead myocardial cells and debris, secreting a variety of cytokines and growth factors (13). Then, monocyte-derived macrophages secrete a variety of fibrogenic and angiogenic growth factors and cytokines (14), inducing formation of granulation tissue and fibroblast proliferation, and fibroblasts undergo phenotypic change expressing SMA, which are then called myofibroblasts. Myofibroblasts may be capable of assuming a variety of different roles, such as production of extracellular matrix proteins and late scar formation, wound contractile activity (15), and passive involvement in neovessel formation as mural cells such as pericytes expressing SMA (16).

Our previous study found significant ^{11}C -methionine uptake in the infarcted area with reduced uptake of both ^{201}Tl and ^{18}F -FDG after oral glucose loading within 2 weeks in patients with myocardial infarction and revascularization (9). However, the uptake of ^{14}C -methionine in the infarcted area was relatively low, possibly because of delayed reperfusion time after infarction and the procedure of ^{11}C -methionine PET. Our previous clinical data on the spatiotemporal uptake of ^{11}C -methionine in the infarcted areas may not have been clear from the aspect of histopathological changes after ischemia and reperfusion.

In this study, we confirmed that the marked accumulation of ^{14}C -methionine in the infarcted areas corresponded to infiltration of numerous macrophages at 3 and 7 days after reperfusion. While the number of CD 68 positive cells decreased around day 7 and later, anti-SMA positive cells appeared, suggesting that activated myofibroblasts may infiltrate the damaged sites in the process of tissue repair after 7-14 days of reperfusion. In addition, some of the anti-SMA staining showed

ring-like or tubular configurations, suggesting that SMA positive mural cells were recruited to newly formed vascular wall. Therefore, strong ^{14}C -methionine uptake within 1 week of reperfusion would imply macrophage infiltration. Less marked uptake at the later stage might reflect, in part, activity by myofibroblasts and neo-vessel formation by mural cells as pericytes in granulomatous tissues, in addition to residual macrophage infiltration.

We thought that ^{11}C -methionine imaging might become a valuable method to evaluate inflammatory processes about to undergo healing processes. The application of target radionuclide imaging of regional methionine uptake as proposed in the present study holds the potential to quantify the extent, amount and localization of macrophage infiltrations early after myocardial infarction. Furthermore, the proposed imaging approach provides the opportunity to monitor novel therapeutic interventions directed to mitigation of the severity of the inflammatory process and promotion of proper transition to the reparative process and remodeling after myocardial infarction.

Acute inflammation can also be detected by ^{18}F -FDG PET, although, FDG uptake due to inflammatory change in myocardium might be obscured by physiological FDG uptake. Therefore, prolonged fasting, heparin loading, and dietary modification would be necessary to suppress the physiological FDG uptake in normal myocardium as has been recommended in the evaluation of cardiac sarcoidosis (17). In this respect, ^{11}C -methionine PET has an advantage over FDG-PET because ^{11}C -methionine PET can be performed easily without any special preparation.

Although the current study demonstrated the changes in the spatiotemporal ^{14}C -methionine accumulation after myocardial ischemia and reperfusion, further

study is needed to investigate the relation between the early degree of ^{14}C -methionine uptake or temporal prolongation of the uptake and the later ventricular dilatation or remodeling and pump failure after myocardial infarction. Assessments as to whether interventional therapy aimed to protect against myocardial damage and ventricular remodeling is related to changes in ^{14}C -methionine uptake, and whether these really reflect the therapeutic effect or not, are also required.

This study had some limitations. First, direct evidence that ^{14}C -methionine accumulates in each macrophage was absent, because no histological autoradiography was undertaken to evaluate which cells in the infarcted tissue accumulated ^{14}C -methionine. However, our pathological and immunohistological studies found inflammation cells to be mainly macrophages during acute inflammation after 3 to 7 days post reperfusion, while the areas of ^{14}C -methionine uptake corresponded to the infarcted tissue occupied by macrophages. Second, angiogenesis was not histopathologically confirmed. But, we surmised that SMA positive cells were myofibroblasts and mural cells were pericytes because some of the SMA staining showed ring-like and tubular configurations, suggesting luminal structures. Further study on ^{14}C -methionine accumulation in the SMA positive cells is needed.

CONCLUSIONS

The present study clarified the spatiotemporal uptake pattern of ^{14}C -methionine after 30 min of ischemia and reperfusion. The current data demonstrated that, corresponding to the area with reduced ^{201}Tl uptake, strong ^{14}C -methionine uptake was observed after 3-7 days of reperfusion and declined gradually until 28 days after reperfusion. The immunohistological examinations suggested that the

methionine uptake might indicate macrophage infiltrations in infarcted areas.

These findings would help to clarify the ^{11}C -methionine uptake in patients with acute myocardial infarction with reperfusion. In addition, methionine imaging may be useful for inflammatory imaging early after myocardial infarction.

ACKNOWLEDGMENTS

The authors thank **Miyuki** Namikata for providing technical assistance.

This work has been supported by Grants-in-aid for scientific research (C-23591756 to **Junichi Taki**. and 21590927 to **Kyoko Imanaka-Yoshida**) from the Ministry of Education, Culture, Sports, Science, and Technology, Japan; by a research grant for intractable diseases from the Ministry of Health, Labor and Welfare of Japan (to **Kyoko Imanaka-Yoshida**. and to **Michiaki Hiroe**), and by a grant from the Japan Foundation for the Promotion of the International Medical Center of Japan (to **Michiaki Hiroe**); by a grant from the National Center for Global Health and Medicine (No.21-126 to **Junichi Taki**).

REFERENCES

1. Cook GJ, Maisey MN, Fogelman I. Normal variants, artefacts and interpretative pitfalls in PET imaging with 18-fluoro-2-deoxyglucose and carbon-11 methionine. *Eur J Nucl Med.* 1999;26:1363-1378.
2. Crippa F, Alessi A, Serafini GL. PET with radiolabeled aminoacids. *Q J Nucl Med Mol Imaging.* 2012 ;56:151-162.
3. Kato T, Shinoda J, Oka N, et al. Analysis of ¹¹C-methionine uptake in low-grade gliomas and correlation with proliferative activity. *AJNR Am J Neuroradiol.* 2008;29:1867-1871.
4. Kracht LW, Friese M, Herholz K, et al. Methyl-[11C]- l-methionine uptake as measured by positron emission tomography correlates to microvessel density in patients with glioma. *Eur J Nucl Med Mol Imaging* 2003;30:868-873.
5. Okita Y, Kinoshita M, Goto T, et al. ¹¹C-methionine uptake correlates with tumor cell density rather than with microvessel density in glioma: A stereotactic image-histology comparison. *Neuroimage.* 2010;49:2977-2982.
6. Arita H, Kinoshita M, Kagawa N, et al. ¹¹C-methionine uptake and intraoperative 5-aminolevulinic acid-induced fluorescence as separate index markers of cell density in glioma: a stereotactic image-histological analysis. *Cancer.* 2012;118:1619-1627.

7. Henze E, Schelbert HR, Barrio JR, et al. Evaluation of myocardial metabolism, with N-13- and C-11-labeled amino acids and positron computed tomography. *J Nucl Med.* 1982;23:671-681.
8. Barrio JR, Baumgartner FJ, Henze E, et al. Synthesis and myocardial kinetics of N-13 and C-11 labeled branched-chain L-amino acids. *J Nucl Med.* 1983;24:937-944.
9. Morooka M, Kubota K, Kadowaki H, et al. ¹¹C-methionine PET of acute myocardial infarction. *J Nucl Med.* 2009;50:1283-1287.
10. Taki J, Higuchi T, Kawashima A, et al. Effect of postconditioning on myocardial ^{99m}Tc-annexin-V uptake: comparison with ischemic preconditioning and caspase inhibitor treatment. *J Nucl Med.* 2007;48:1301–1307.
11. Sahul ZH, Mukherjee R, Song J, et al. Targeted imaging of the spatial and temporal variation of matrix metalloproteinase activity in a porcine model of postinfarct remodeling: relationship to myocardial dysfunction. *Circ Cardiovasc Imaging.* 2011;4: 381-391.
12. Blankesteyn WM, Creemers E, Lutgens E, Cleutjens JP, Daemen MJ, Smits JF.
Dynamics of cardiac wound healing following myocardial infarction: observations in genetically altered mice. *Acta Physiol Scand.* 2001;173:75–82.

13. Lambert JM, Lopez EF, Lindsey ML. Macrophage roles following myocardial infarction. *Int J Cardiol.* 2008;130:147-158.

14. Weihrauch D, Arras M, Zimmermann R, Schaper J. Importance of monocytes/macrophages and fibroblasts for healing of micronecroses in porcine myocardium. *Mol Cell Biochem.* 1995;147:13-19.

15. Serini G, Gabbiani G. Mechanisms of myofibroblast activity and phenotypic modulation. *Exp Cell Res.* 1999 ;250:273-283.

16. Armulik A, Genove G, Betsholtz C. Pericytes. developmental, physiological, and pathological perspectives, problems, and promises. *Dev Cell.* 2011 ;21:193-215.

17. Ohira H, Tsujino I, Yoshinaga K. ¹⁸F-Fluoro-2-deoxyglucose positron emission tomography in cardiac sarcoidosis. *Eur J Nucl Med Mol Imaging.* 2011;38:1773-1783.

FIGURE LEGENDS

FIGURE 1

Experimental protocol. LCA = left coronary artery.

FIGURE 2

Time course of the ^{14}C -methionine uptake area against area at risk (% area).

One day after reperfusion, no increased uptake of ^{14}C -methionine was observed. % area of methionine uptake was similar at 3, 7, 14, and 28 days after reperfusion.

FIGURE 3

Autoradiography of ^{14}C -methionine, ^{201}Tl , and $^{99\text{m}}\text{Tc}$ -MIBI.

One day after reperfusion, both ^{14}C -methionine and ^{201}Tl uptake decreased in the area at risk ($^{99\text{m}}\text{Tc}$ -MIBI defect). However, 3 days after reperfusion, ^{14}C -methionine uptake increased significantly, followed by the gradual reduction of uptake until 28 days. The distribution of Methionine uptake roughly corresponds to the reduced ^{201}Tl uptake area.

FIGURE 4

Time course of the ^{14}C -methionine uptake ratio.

^{14}C -methionine uptake ratios were calculated by dividing the ^{14}C -methionine count density in the area at risk by that of non-ischemic area. ^{14}C -methionine uptake reduced at 1 day after reperfusion, but increased dramatically at 3 days, followed by a gradual decrease to the basal level until 28 days. * = $P < 0.005$ vs 28d, $P < 0.0001$ vs 3, 7, and 14 days.

FIGURE 5

Comparison of ^{201}Tl and ^{14}C -methionine autoradiograms and anti CD68 antibody staining (marker of macrophages). ^{14}C -methionine uptake was observed predominantly in the area with reduced ^{201}Tl uptake at 3 to 14 days after reperfusion. On the other hand ^{14}C -methionine uptake corresponded closely to the anti CD68 antibody positive area at 3 and 7 days, while anti CD68 antibody staining was weak compared to the ^{14}C -methionine uptake at 14 days.

FIGURE 6

Double staining with cardiac troponin I and either anti CD68 or anti- α smooth muscle actin (SMA) of serial sections of heart at 3 and 7 days. Strong CD68 staining (red) was seen in troponin I (blue) defect area at 3 days. Anti-SMA positive cells (green) were not observed at 3 days in troponin I defect area, but numerous SMA positive cells were found at 7 days.

FIGURE 7

Double staining of anti CD68 antibody (red) and anti SMA (green) in the area corresponding to ^{14}C -methionine uptake. At 3 days after reperfusion, strong staining of the anti CD68 antibody but little anti SMA staining was observed. At 7 days, a significant amount of anti SMA staining appeared in the area of CD68 antibody red staining. The enlarged image of the boxed area clearly demonstrated that some of the green staining showed ring-like or tubular configurations, suggesting new formation of blood vessels. At 14 days, anti CD68 antibody stain decreased, while anti SMA staining increased and still showed ring-like and

tubular configurations. Scale bars = 100 μm .

FIGURE 1.

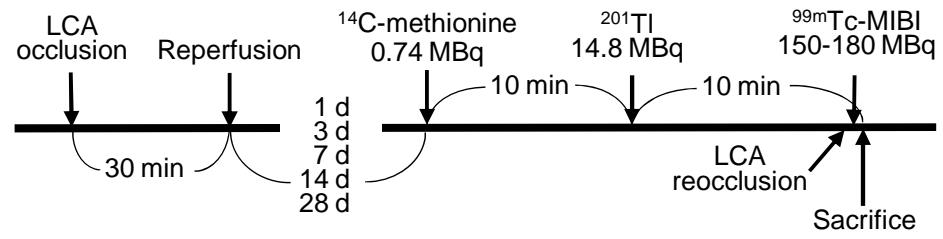


FIGURE 2.

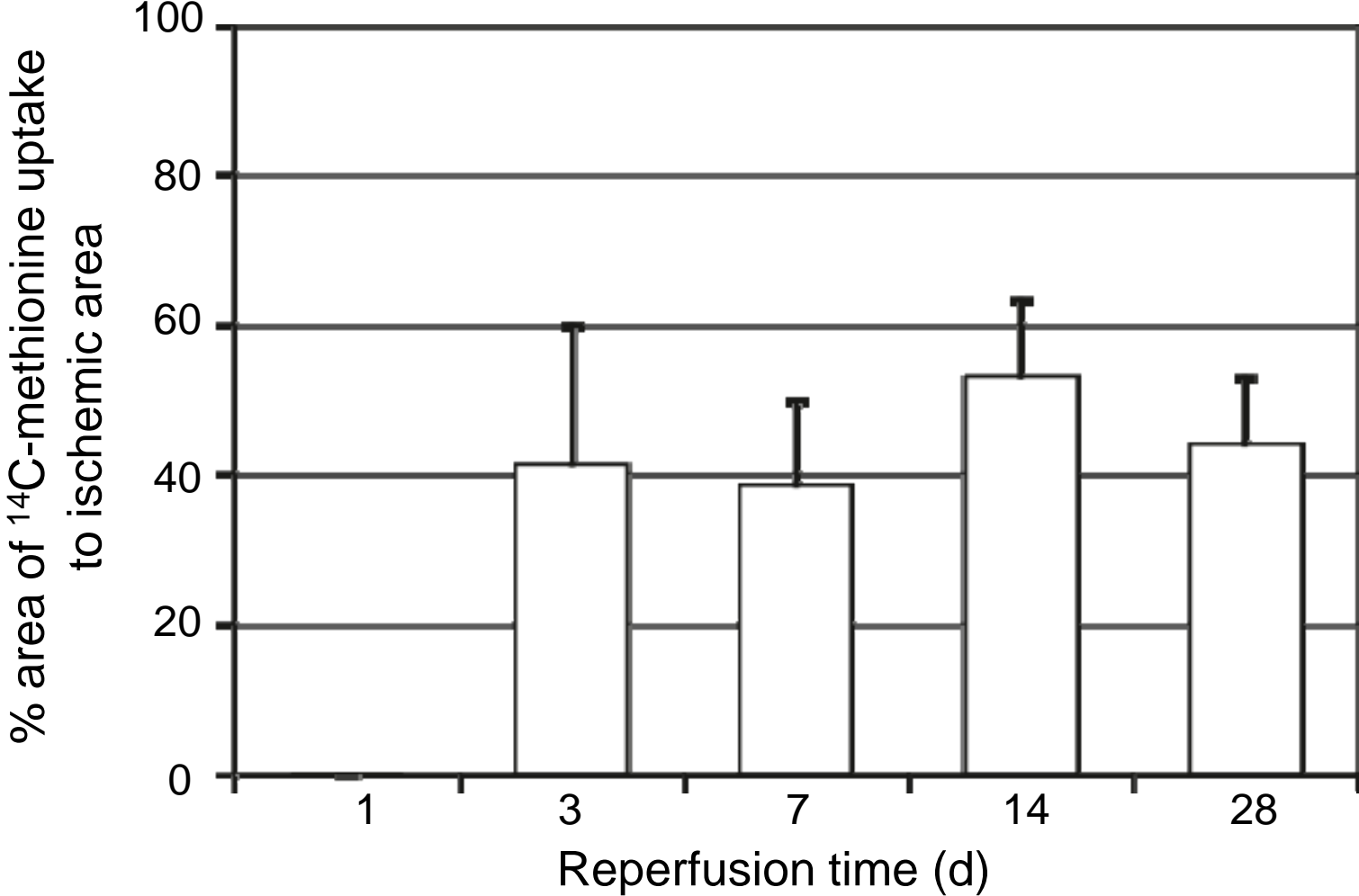


FIGURE 3.

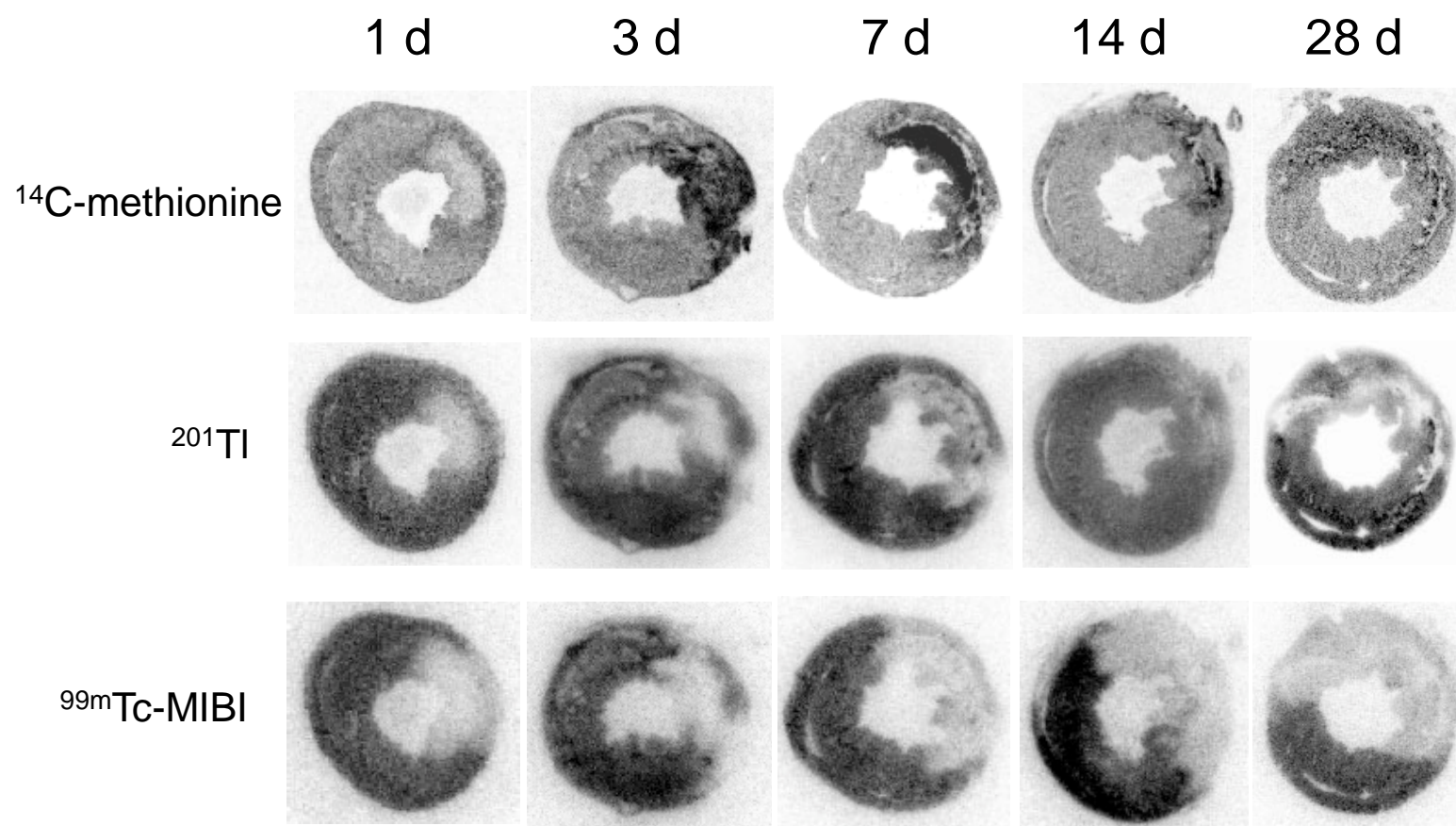


FIGURE 4

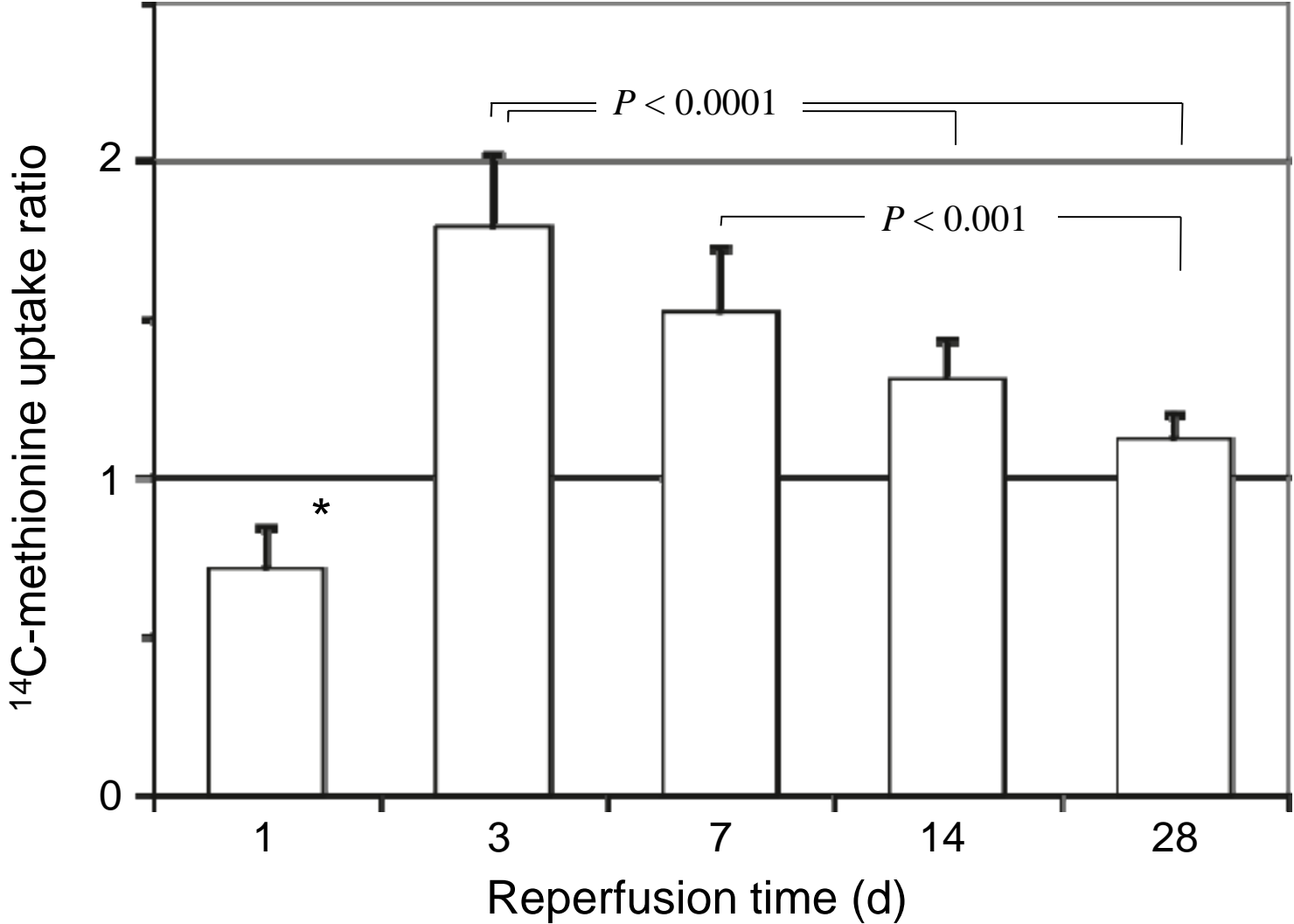


FIGURE 5.

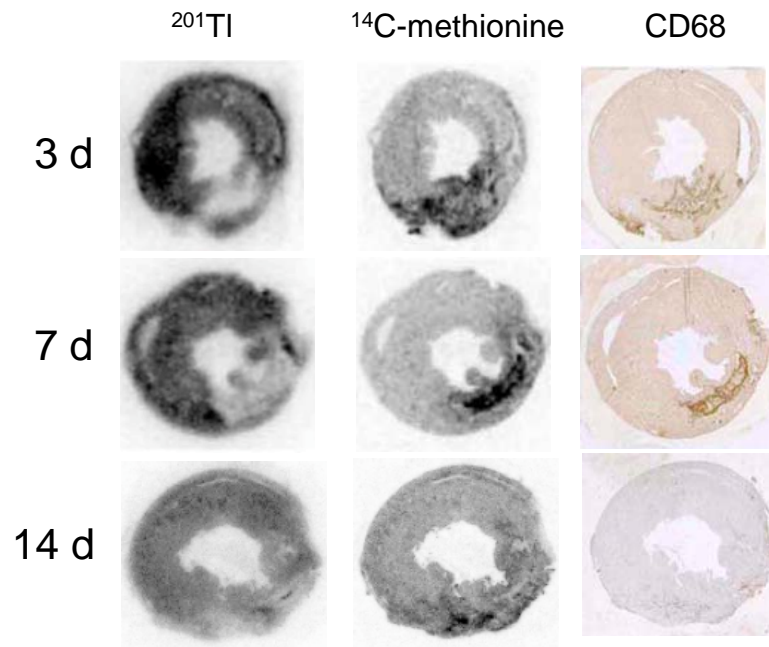


FIGURE 6.

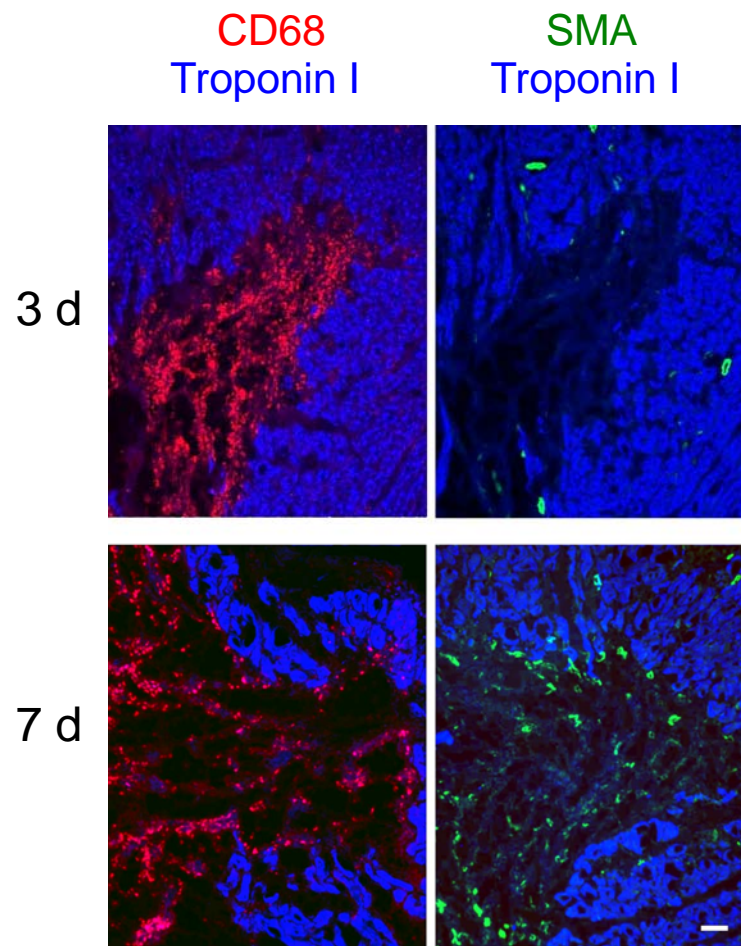


FIGURE 7.

