

# Pedicle versus free frozen autograft for reconstruction in malignant bone and soft tissue tumors of the lower extremities

著者	Shimozaki Shingo, Yamamoto Norio, Shirai Toshiharu, Nishida Hideji, Hayashi Katsuhiro, Tanzawa Yoshikazu, Kimura Hiroaki, Takeuchi Akihiko, Igarashi Kentaro, Inatani Hiroyuki, Kato Takashi, Tsuchiya Hiroyuki
journal or publication title	Journal of Orthopaedic Science
volume	19
number	1
page range	156-163
year	2014-01-01
URL	<a href="http://hdl.handle.net/2297/36269">http://hdl.handle.net/2297/36269</a>

doi: 10.1007/s00776-013-0487-x

## Pedicle versus free frozen autograft for reconstruction in malignant bone and soft tissue tumors of the lower extremities

Shingo Shimozaki · Norio Yamamoto · Toshiharu Shirai · Hideji Nishida · Katsuhiko Hayashi · Yoshikazu Tanzawa · Hiroaki Kimura · Akihiko Takeuchi · Kentaro Igarashi · Hiroyuki Inatani · Takashi Kato · Hiroyuki Tsuchiya

Received: 6 March 2013 / Accepted: 10 October 2013  
© The Japanese Orthopaedic Association 2013

### Abstract

**Background** Of the biological reconstruction methods for malignant bone and soft tissue tumors, reconstruction with liquid nitrogen has the advantage of maintaining continuity on the distal side of the tumor bone site (pedicle freezing procedure; PFP). This method is expected to result in early blood flow recovery, with early union and low complication rate. The purpose of this study was to compare the outcomes of the PFP and free freezing procedure (FFP) in the lower extremities.

**Methods** The study included 20 patients (12 men and 8 women) with frozen autografts (FFP, 13 cases; PFP, 7 cases). The mean age of the subjects was 36.3 years (range 11–79 years), and the mean follow-up period was 56.4 months (range 12–142 months).

**Results** Final bone union occurred in 11 patients in the FFP group (84.6 %) and in 7 patients in the PFP group (100 %). The mean union period in patients who did not need additional surgery was 9.8 months (range 4–21 months) in the FFP group and 4.8 months (range 2–7 months) in the PFP group. Postoperative complications occurred in 8 cases: infection in 3 cases, fracture in 3 cases, and joint destruction in 2 cases. Six FFP patients, and 2 PFP patients (two cases of fracture), developed postoperative complications.

**Conclusions** The union period was shorter and the rate of postoperative complications was lower with the PFP than

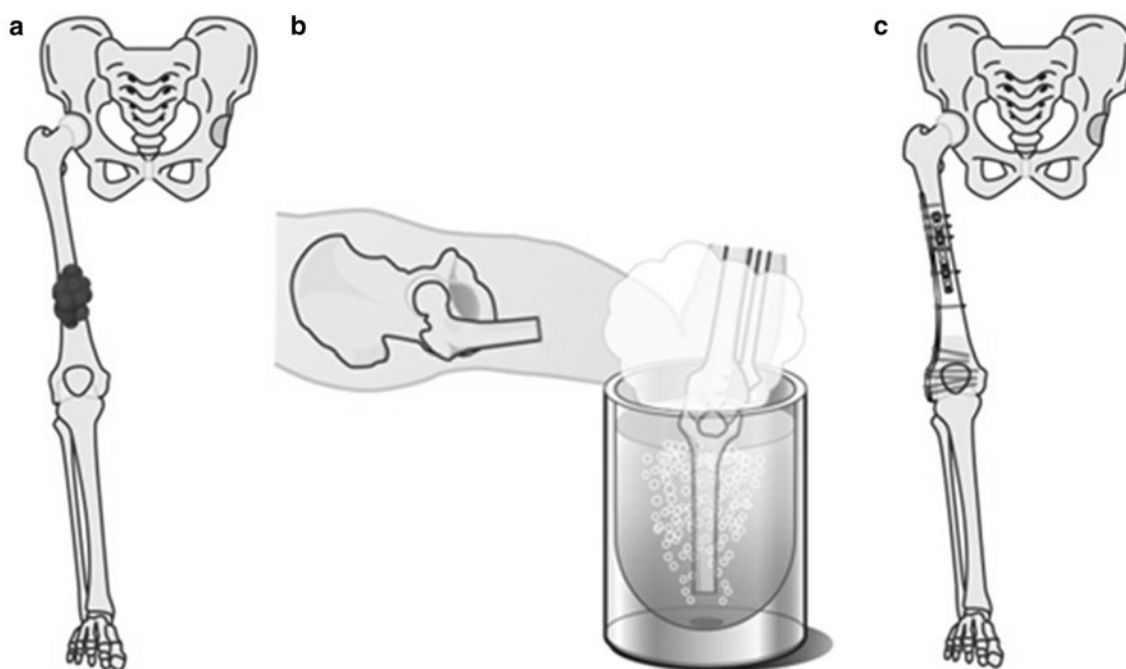
with the FFP. We considered that early blood flow recovery might have led to the above results in the PFP.

### Introduction

With improvement in survival rates for patients with sarcoma comes a need for more functional and durable methods of reconstruction following resection of tumors in the extremities. Standard management of the defects that exist after bone resection has included massive prostheses and allograft implantation. However, although a massive prosthesis provides immediate postoperative stability and early return to activities of daily living, in the long term, patients are at risk for prosthesis complications such as loosening and breakage [1–3]. Furthermore, although reconstruction with an allograft is performed in some countries, it has been less available in Japan because of socio-religious reasons.

Several oncological reconstruction methods have been developed as alternative reconstruction methods, including irradiation [4], autoclaving [5], and pasteurization [6]. In particular, a novel method of reconstruction with liquid nitrogen (frozen autograft) was developed and has been implemented in patients since 1999 [7]. The advantages of using frozen autografts are as follows: simplicity, osteoinduction, osteoconduction, short treatment time, preservation of the cartilage matrix, perfect fit, sufficient biochemical strength, no contagion, no need for bone banking, easy attachment of tendons and ligaments, desirable bone stock, and cryo immunological activity [7–10]. The developers also modified this technique to produce a pedicle frozen autograft to maintain anatomical continuity on one side (Fig. 1) [11]. With this method, cutting both sides of the tumor site is not necessary, thus providing the

S. Shimozaki · N. Yamamoto · T. Shirai · H. Nishida · K. Hayashi · Y. Tanzawa · H. Kimura · A. Takeuchi · K. Igarashi · H. Inatani · T. Kato · H. Tsuchiya (✉)  
Department of Orthopedic Surgery, Graduate School of Medical Science, Kanazawa University, 13-1 Takaramachi, Kanazawa 920-8641, Japan  
e-mail: tsuchi@med.kanazawa-u.ac.jp



**Fig. 1** Pedicle freezing procedure. **a** Tumor of the diaphyseal femur. **b** Pedicle freezing in liquid nitrogen. **c** Osteosynthesis with plates

following advantages: shorter operating time, maintenance of continuity of the joint in selected patients, preservation of joint stability and function in selected patients because no important ligaments need to be sacrificed, early functional recovery after surgery, fewer osteotomy sites, preservation of initial strength at the host–graft junction, and a lower rate of graft healing complications because of early blood flow recovery. Both the free freezing procedure (FFP) and pedicle freezing procedure (PFP) could be indicated for bone and soft tissue sarcoma.

There is no study to verify the clinical outcomes by comparing results of the PFP and FFP. The purpose of this retrospective study was to compare the outcomes of the PFP and FFP in the lower extremities by considering the rate of bone union, union period, and postoperative complications.

### Patients and methods

Since 1999, we have used a frozen autograft technique with liquid nitrogen in >100 patients for a wide variety of surgical sites such as the humerus, radius, femur, tibia, calcaneus, ilium, and hip-bone. Considering bone union, union period, and postoperative complications such as infection, fracture, and joint destruction, most of these cases have had a good course after reconstruction with frozen autografts.

The PFP was performed following the method of Tsuchiya et al. [11]. Osteotomy was performed at 2 cm from

the proximal side of the bony margin. The soft tissue was divided along the extremity beyond the surface of the surgical margin until the arc of rotation was adequate. The surrounding soft tissue was protected by surgical sheets. The intramedullary canals were then curetted to remove the bone marrow and tumor content, to prevent graft fracture due to watery volume expansion during freezing. The bony lesions connecting to the limb were rotated cautiously and frozen in liquid nitrogen while continuing to protect the surrounding soft tissue with surgical sheets. The part of the bone 2 cm away from the bony margin was positioned at the surface level of the liquid nitrogen. All tumors were treated using a single-cycle liquid nitrogen protocol, which consisted of freezing in liquid nitrogen for 20 min, thawing at room temperature for 15 min, and further thawing in distilled water for an additional 10 min. This pedicle freezing method was performed under tourniquet control to prevent tumor dissemination and bleeding.

Bone union and postoperative complications depended on the surgical site environment, the stability of the host–graft junction, and the load weight. Therefore, in this study, we selected only those patients who received treatment in a lower extremity (femur or tibia), and compared the clinical outcomes of the PFP and FFP in those cases. Sixty-nine frozen autografts were used for lower extremity reconstructions from 1999 through 2011. The exclusion criteria included composite prosthesis and short-term follow-up (<12 months), which yielded a study population of 20 cases from the original 69 cases. The patients consisted of 12 men and 8 women, and their average age at the time of

**Table 1** Treatment outcomes of frozen autograft in lower extremities

Case	Sex/age (years)	Site	Stage	Histological diagnosis	Surgical method	Frozen procedure	Union period (months)	Chemotherapy <sup>a</sup>	Response to chemotherapy	Function	Postoperative complication	Second surgery for delayed union	Follow-up (months)	Prosthesis at final	Outcome
1	M/52	Femur (dia)	M1	Metastatic tumor (lung)	W + IM	Free	27	K2	Yes	Exc		+	142	-	NED
2	F/13	Femur (dis)	M0	Osteosarcoma	M + IM	Free	-	K2	Yes	Exc	Joint destruction	+	142	+	NED
3	M/11	Femur (dia)	M1	Ewing's sarcoma	W + IM	Free	15	K2	Yes	Exc		+	32	-	DOD
4	M/14	Tibia (p)	M0	Osteosarcoma	M + IM	Free	9	K2	Yes	Exc		-	38	-	NED
5	M/34	Femur (dis)	M0	MFH	W + IM + C	Free	30	K2	No	Exc	Joint destruction	+	108	+	NED
6	M/39	Femur (dis) Tibia (p)	M0	MFH	W + IM	Free	5	K2	No	Exc	Infection	-	101	+	CDF
7	M/60	Femur (dis)	M0	Leiomyosarcoma	W + IM	Free	45	K2	No	Good		+	82	-	CDF
8	M/62	Femur (dia)	M0	Osteosarcoma	W + IM + C	Pedicle	18	K2	Yes	Exc		+	64	-	NED
9	F/18	Tibia (dia)	M1	Osteosarcoma	W + IM + C	Pedicle	35			Exc	Fracture	+	66	-	AWD
10	M/20	Tibia (dis)	M0	Osteosarcoma	M + IM + C	Free	32	K2	Yes	Exc	Infection	-	55	-	CDF
11	M/51	Femur (dis)	M0	Osteosarcoma	W + IM + C	Free	-	K2	Yes	Good	Infection	-	52	+	CDF
12	M/18	Femur (dis)	M1	Osteosarcoma	W + IM + plate	Free	8	K2	Yes	Exc		-	24	-	DOD
13	M/14	Femur (dis)	M0	Osteosarcoma	W + IM + plate	Free	7	K2	Yes	Exc	Fracture	-	43	+	CDF
14	M/69	Femur (p)	M1	Metastatic tumor (lung)	W + plate + C	Pedicle	5			Exc		-	44	-	CDF
15	F/60	Femur (dis)	M1	Metastatic tumor (kidney)	W + plate + C	Pedicle	2			Exc	Fracture	-	43	-	AWD
16	F/75	Tibia (dia)	M1	Metastatic tumor (breast)	W + plate + C	Free	21			Exc		-	21	-	NED
17	F/11	Tibia (p)	M0	Osteosarcoma	M + plate	Free	4	K2	Yes	Exc		-	28	-	CDF
18	F/12	Tibia (p)	M0	Osteosarcoma	M + plate	Pedicle	7	K2	Yes	Exc		-	19	-	CDF
19	F/13	Femur (dia)	M0	Osteosarcoma	W + plate	Pedicle	4	K2	Yes	Exc		-	14	-	AWD

Table 1 continued

Case	Sex/ age (years)	Site	Stage	Histological diagnosis	Surgical method	Frozen procedure	Union period (months)	Chemotherapy <sup>a</sup>	Response to chemotherapy	Function	Postoperative complication	Second surgery for delayed union	Follow- up (months)	Prosthesis at final	Outcome
20	F/79	Femur (p)	M1	Metastatic tumor (kidney)	W + plate + C	Pedicle	6		Exc	Exc	–	–	12	–	NED

*dis* distal, *p* proximal, *dia* diaphyseal, *M0* no metastasis, *M1* with metastasis, *MFH* malignant fibrous histiocytoma, *M* marginal excision, *W* wide excision, *IM* intramedullary nail, *C* cement, *Exc* excellent, *AWD* alive with disease, *CDF* continuously disease-free, *DOD* died of disease, *NED* no evidence of disease

<sup>a</sup> K2 protocol consists of five courses of intra-arterial cisplatin/caffeine/doxorubicin at intervals of 3 weeks [13]

diagnosis was 36.3 years (range 11–79 years). The mean follow-up period was 56.4 months (range 12–142 months): 66.8 months (range 21–142 months) in the FFP group and 37.4 months (range 12–66 months) in the PFP group. The histological diagnoses of these cases were 15 primary bone and soft tissue tumors (11 osteosarcomas, 2 malignant fibrous histiocytomas, 1 leiomyosarcoma, and 1 Ewing's sarcoma) and 5 metastatic bone tumors (2 lung cancers, 2 renal cancers, and 1 breast cancer). The sites were the femur in 13 patients, tibia in 6 patients, and both in 1 patient. Reconstruction with osteoarticular graft was performed in 8 cases. In this study, we classified the cases of reconstruction with osteoarticular graft into the FFP group.

Bone union was defined as the presence of indistinct bone incision lines (both sides in the FFP group) or bridging callus on radiographs. The presence of postoperative infection was assessed at the site of the frozen bone, not in the superficial tissues. Fracture and joint destruction were evaluated on radiographs.

The function at the final follow-up assessment was evaluated by the International Society of Limb Salvage and Musculoskeletal Tumor Society (ISOLS/MSTS) scoring system [12].

This study was approved by the local institutional review board. All subjects were informed that data from this study would be submitted for publication, and gave their consent for participation.

## Results

### Bone union

Details of the treatment results are shown in Table 1. There were 13 cases in the FFP group and 7 cases in the PFP group. Final bone union was observed in 11 cases (84.6 %) in the FFP group and 7 cases (100 %) in the PFP group. The union period in patients who did not need additional surgery was 9.8 months (range 4–21 months) in the FFP group and 4.8 months (range 2–7 months) in the PFP group. Five cases in the FFP group and 2 cases in the PFP group needed a second surgery for delayed union. There is no fixed standard time of second surgery for delayed union because it depends on the individual patient, surgeon availability, hospital protocol, and other factors. Therefore, the data of patients who received a second surgery were not used in the calculation of the union periods because it was difficult to precisely calculate the union period in those patients. Four of the 5 FFP cases and both PFP cases obtained union after the second surgery, and the mean union period after the second surgery was 20 months (range 8–40 months) and 2.5 months (range 2–3 months) in the FFP and PFP cases, respectively.

## Postoperative complications

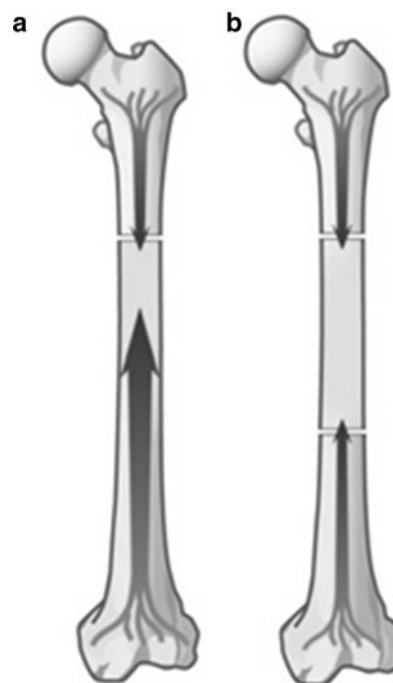
Postoperative complications occurred in 8 cases: infection in 3 cases, fracture in 3 cases, and joint destruction in 2 cases. Two of these complications (2 cases of fracture) occurred in the PFP group. The postoperative infection rate was 23.1 % (3 of 13 cases) in the FFP and 0 % (0 of 7 cases) in the PFP group. Case 6 showed postoperative infection at 7 months after reconstruction. In this case, bone union at the host–graft junction had already occurred on radiographs taken 5 months after reconstruction. Furthermore, bone union was seen at the time of surgery for infection. After surgery for infection, the function of the affected limb with the tumor prosthesis was excellent. Case 10 exhibited infection at 21 months after reconstruction. Bone union occurred after revision surgery at 32 months after the first surgery with a frozen autograft. The function of the diseased limb was excellent without a massive prosthesis. The patient of case 11 developed infection at 7 months after reconstruction. Because of failure to achieve bone union, this patient finally received prosthetic surgery. The function of the diseased limb was good. Cases 9, 13, and 15 developed fracture of the procedure bone. Although case 9 was an atraumatic fracture, the fracture in cases 13 and 15 was caused by trauma. We performed reimplantation and bone graft for the fracture of case 9, and bone union occurred after the second surgery. Because the fracture of case 13 reached the joint surface, prosthetic surgery was performed. For case 15, bone union had already occurred at the time of fracture, and we performed reimplantation and bone graft at the fracture site. All these cases had excellent function at the final follow-up period. Joint destruction occurred in 2 FFP cases. The patient of case 2 underwent surgery for joint destruction at 69 months after reconstruction with a frozen autograft, and the patient of case 5 received surgery at 14 months. Prosthetic surgery was performed in these 2 cases, and both patients achieved excellent function in the affected limbs. Although 5 cases in the FFP group and none in the PFP group ultimately underwent prosthetic surgery, 18 patients had excellent function and 2 patients had good function at the end of the follow-up period. From the viewpoint of the function of diseased limb at the final follow-up assessment, the treatment for postoperative complications, including infection, fracture, and joint destruction, was successful.

## Discussion

Several biological reconstruction methods are available for malignant bone and soft tissue tumors. The treatment outcomes using frozen autografts were superior to those of other biological reconstructions [9, 14, 15]. In addition,

frozen autografts contain autogenous proteins, growth factors, and cytokines [16], and they do not elicit an immune reaction. Furthermore, a new method of pedicle freezing (the PFP) has been developed. More than 40 cases have been treated using this method, and most of those cases have acquired excellent or good function. The important advantage of the PFP, in comparison with the FFP, is the need to cut only one side of the tumor site while maintaining continuity on the other side. Because the bone marrow cavity between the host and frozen bones is intact, it is expected that blood flow recovery of the PFP is faster than that of the FFP (Figs. 2, 3). Furthermore, the continuity on one side leads to improved stability of the frozen bone in the PFP compared with the FFP. This study suggests that the PFP has beneficial outcomes with respect to bone union and postoperative complications, including infection, fracture, and joint destruction.

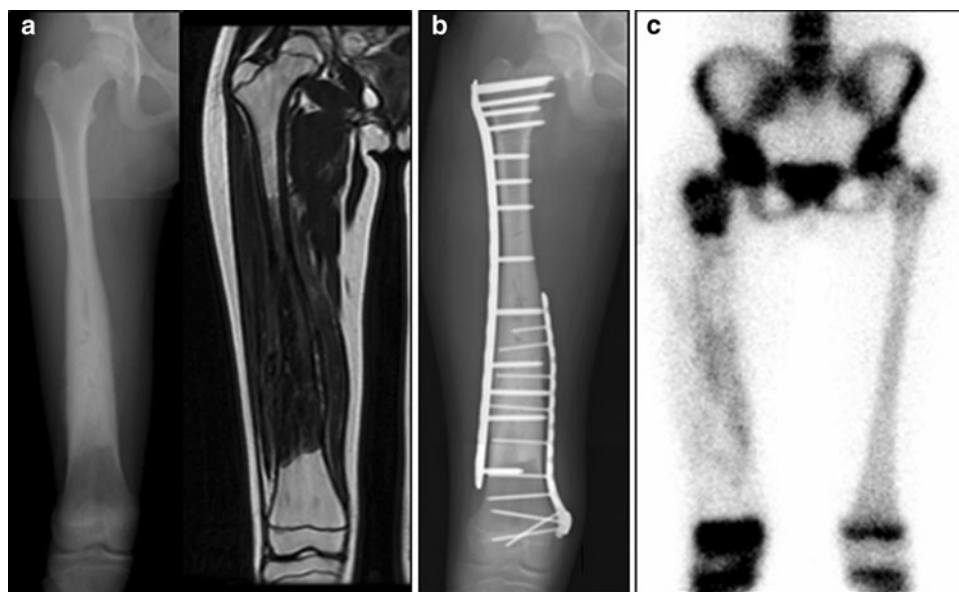Since 2002, we have chosen to use the PFP as often as possible. However, in some cases in which we could not preserve the articular cartilage because the tumor was close to the joint surface, and in cases in which we could not perform hemicortical resection, we performed the FFP rather than the PFP. Because it can preserve the continuity of the other side to the resected side, the hemicortical resection was expected to lead to better stability than the PFP and earlier blood flow recovery than the conventional FFP. In this study, we performed reconstruction with a frozen autograft using a hemicortical resection for case 17. In 2 cases we



**Fig. 2** Early blood flow recovery is expected in the frozen pedicle bone. **a** After the pedicle freezing procedure (PFP). **b** After the free freezing procedure (FFP)



**Fig. 3** A 13-year-old girl with osteosarcoma of the right femur (case 19). **a** Pretreatment radiograph and magnetic resonance image showing osteosarcoma of the right femur. **b** Postoperative radiograph; osteotomy was performed on the proximal side of the tumor site, and PFP was used for the reconstruction. **c** Bone scan at 1 month after reconstruction showing the uptake in the frozen bone



treated before 2002 (cases 1 and 3), we performed the FFP; however, at present, we would prefer to treat such cases using the PFP.

In this study, bone union was seen in all the PFP cases, although 2 FFP cases did not achieve union of the host-graft junction. The mean union period in the patients who did not need additional surgery was 9.8 months in the FFP group and 4.8 months in the PFP group. The rate of union was 84.6 % (11 of 13) in the FFP group and 100 % (7 of 7) in the PFP group. The essential elements of bone union are classified according to biological and biomechanical factors [17, 18]. Biological factors include various cytokines, growth factors, angiogenetic factors, and proteolytic enzymes. Biomechanical factors include perfect fit, stability, and contact area. Compared with the FFP, the PFP has superior angiogenetic potential and stability. These biological and biomechanical factors probably contributed to the higher union rate and shorter union period in the PFP than in the FFP.

With regard to the cases of nonunion in our study, reconstruction was performed in these cases by using an intramedullary nail without a plate. In general, stability at the fracture site is better with a plating system compared with an intramedullary nailing system [19, 20]. Therefore, we considered that this biomechanical factor contributed to the nonunion at the host-graft junction, and we have since adopted the plating system for reconstruction.

Postoperative infection occurred in 3 cases. Vascularity and stability are critical factors to avoiding postoperative infection [21–24]. The 3 cases of infection were all in the

FFP group. The PFP is expected to facilitate early vascularity because of the continuity of one side of the host-graft junction, and this might have helped prevent postoperative infection. In addition, these 3 cases underwent reconstruction without a plating system, and stability is also important in preventing postoperative infection. We considered that the free freezing procedure and fixation with only an intramedullary nail contributed to postoperative infection in these cases.

Fracture occurred in 3 cases after reconstruction. The first case exhibited an atraumatic fracture. This patient had a metabolic disease called Hutchinson–Gilford progeria syndrome (persons with this condition have an average life span of 13 years). At the time of reconstruction with a frozen autograft, this patient was 18 years old, and because the disease led to progeria, the bones of this patient were considered weaker than normal. The other 2 fracture cases were due to trauma. Therefore, comparing the postoperative fracture rate between the FFP and the PFP was difficult in this study.

Joint destruction occurred in 2 cases, both of which were treated using the FFP. The common feature of these cases was freezing of the joint surface. Because cryo injury of the articular cartilage causes osteoarthritic change [25], joint destruction eventually developed. It is important to prevent cryo injury of the joint surface in reconstruction with the FFP or the PFP.

In this study, patients were followed up for <10 years. Because almost 50 % of the patients in this study were <20 years old at the time of the surgery, we need to monitor

them for >50 years. If massive prostheses are used for reconstruction, multiple surgeries will be required because of wear of the implant. However, biological reconstruction does not require such surgeries because the procedure bone will regenerate after the reconstruction. Popken et al. [26] reported that the stability of frozen bone almost matched that of the normal bone at 4 months after cryosurgery in the lower extremities of sheep. Their study also indicated histological repair of frozen bone 4 months after cryosurgery. Furthermore, Yamamoto et al. [27] reported that the cortical bone of the host-graft junction had repaired to >80 % of the normal 8 years after reconstruction in humans. These studies indicate that bone frozen with liquid nitrogen regenerates after reconstruction. However, there are no reports on the long-term stability of the procedure bone. Our patients need to be followed up for life regardless of whether they are disease-free or have a recurrence.

This study had some limitations. A randomized double-blind trial for the FFP and PFP was difficult because of the small number of patients. However, this study is the first report to compare the FFP and PFP; therefore, our results are significant because they may be used as a reference for the bone union rate or postoperative complication rate between these two freezing methods. Moreover, the PFP had fewer complications than the FFP. Because the mean follow-up period of the PFP was shorter than that of the FFP, it is possible that the postoperative complication rate for the PFP will increase in the future.

**Conflict of interest** The authors declare that they have no conflict of interest.

## References

- Bickels J, Witting JC, Kollender Y, Henshaw RM, Kellar-Graney KL, Meller I, Malawar MM. Distal femur resection with endoprosthesis reconstruction: a long-term followup study. *Clin Orthop Rel Res.* 2002;400:225–35.
- Gerrand CH, Currie D, Grigoris P, Reid R, Hamblen DL. Prosthetic reconstruction of the femur for primary bone sarcoma. *Int Orthop.* 1999;23:286–90.
- Shih LY, Sim FH, Pritchard DJ, Rock MG, Chao EY. Segmental total knee arthroplasty after distal femoral resection for tumor. *Clin Orthop Rel Res.* 1993;292:269–81.
- Uyttendaele D, De Schryver A, Claessens H, Roels H, Berkvens P, Mondelaers W. Limb conservation in primary bone tumours by resection, extracorporeal irradiation and re-implantation. *J B Jt Surg Br.* 1988;70:348–53.
- Thompson VP, Steggall CT. Chondrosarcoma of the proximal portion of the femur treated by resection and bone replacement; a six-year result. *J B Jt Surg Am.* 1956;38:357–67.
- Manabe J. Experimental studies on pasteurized autogenous bone graft. *Nihon Seikeigeka Gakkai Zasshi (J Jpn Orthop Assoc).* 1993;67:255–66.
- Tsuchiya H, Wan SL, Sakayama K, Yamamoto N, Nishida H, Tomita K. Reconstruction using an autograft containing tumour treated by liquid nitrogen. *J B Jt Surg Br.* 2005;87(2):218–25.
- Nishida H, Tsuchiya H, Tomita K. Re-implantation of tumour tissue treated by cryo treatment with liquid nitrogen induces anti-tumour activity against murine osteosarcoma. *J B Jt Surg Br.* 2008;90:1249–55.
- Tanzawa Y, Tsuchiya H, Shirai T, Hayashi K, Yo Z, Tomita K. Histological examination of frozen autograft treated by liquid nitrogen removed after implantation. *J Orthop Sci.* 2009;14:761–8.
- Nishida H, Yamamoto N, Tanzawa Y, Tsuchiya H. Cryo-immunology for malignant bone and soft-tissue tumors. *Int J Clin Oncol.* 2011;16:109–17.
- Tsuchiya H, Nishida H, Srisawat P, Shirai T, Hayashi K, Takeuchi A, Yamamoto N, Tomita K. Pedicle frozen autograft reconstruction in malignant bone tumors. *J Orthop Sci.* 2010;15:340–9.
- Enneking WF, Dunham W, Gebhardt MC, Malawar M, Pritchard DJ. A system for the functional evaluation of reconstructive procedures after surgical treatment of tumors of the musculo-skeletal system. *Clin Orthop Rel Res.* 1993;286:241–6.
- Tsuchiya H, Tomita K, Mori Y, Asada N, Yamamoto N. Marginal excision for osteosarcoma with caffeine assisted chemotherapy. *Clin Orthop.* 1999;358:27–35.
- Marciani RD, Giansanti JS, Massey GB. Re-implantation of freeze-treated and saline-treated mandibular bone. *J Oral Surg.* 1976;34:314–9.
- Garusi C, Calabrese L, Giugliano G, Mazzarol G, Prodrecca S, Chiesa F, Fassati R. Mandible reconstruction and autogenous frozen bone graft: experimental study on rats. *Microsurgery.* 2001;21:131–4.
- Bünger MH, Langdahl BL, Andersen T, Husted L, Lind M, Eriksen EF, Bünger CE. Semiquantitative mRNA measurements of osteoinductive growth factors in human iliac-crest bone: expression of LMP splice variants in human bone. *Calcif Tis Int.* 2003;73:446–54.
- Hulth A. Current concepts of fracture healing. *Clin Orthop Rel Res.* 1989;249:265–84.
- Zimmermann G, Schmeckenbecher KH, Boeuf S, Weiss S, Bock R, Moghaddam A, Richter W. Differential gene expression analysis in fracture callus of patients with regular and failed bone healing. *Injury.* 2012;43:347–56.
- Strauss EJ, Alfonso D, Kummer FJ, Egol KA, Tejwani NC. The effect of concurrent fibular fracture on the fixation of distal tibia fractures: a laboratory comparison of intramedullary nails with locked plates. *J Orthop Trauma.* 2007;21:172–7.
- Casstevens C, Le T, Archdeacon MT, Wyrick JD. Management of extra-articular fractures of the distal tibia: intramedullary nailing versus plate fixation. *J Am Acad Orthop Surg.* 2012;20:675–83.
- Friedrich B, Klaue P. Mechanical stability and post-traumatic osteitis: an experimental evaluation of the relation between infection of bone and internal fixation. *Injury.* 1977;9:23–9.
- Iizuka T, Lindqvist C. Rigid internal fixation of mandibular fractures. An analysis of 270 fractures treated using the AO/ASIF method. *Int J Oral Maxillofac Surg.* 1992;21:65–9.
- McClinton MA, Helgemo SL Jr. Infection in the presence of skeletal fixation in the upper extremity. *Hand Clin.* 1997;13:745–60.
- Schmidt AH, Swiontkowski MF. Pathophysiology of infections after internal fixation of fractures. *J Am Acad Orthop Surg.* 2000;8:285–91.
- Hayashi M, Tsuchiya H, Otoi T, Agung B, Yamamoto N, Tomita K. Influence of freezing with liquid nitrogen on whole-knee joint grafts and protection of cartilage from cryo-injury in rabbits. *Cryobiology.* 2009;59:28–35.
- Popken F, Michael JW, Zarghooni K, Sobottke R, Kasper HU, Blaecker D, Niehoff A, Emrich F, Eysel P. Stability changes after



cryosurgery in long tubular bones in correlation to histological results: an animal trial. *Arch Orthop Trauma Surg.* 2009;129:857–62.

27. Yamamoto N, Inatani H, Shirai T, Nishida H, Hayashi K, Kimura H, Takeuchi A, Igarashi K, Shimozaki S, Kato T, Tsuchiya H.

Histological study on liquid nitrogen-treated tumor-bearing bone of the proximal femur excised 8 years after transplantation. *Low Temp Med.* 2012;38:5–8.