

# Uncommon co-localization of pituitary adenoma and parasellar cavernous angioma

著者	Hayashi Yasuhiko, Tachibana Osamu, Mohri Masanao, Kinoshita Masashi, Hayashi Yutaka, Yoshinaga Tomofumi, Hamada Jun-ichiro
journal or publication title	European Journal of Radiology Extra
volume	66
number	1
page range	e1-e3
year	2008-04-01
URL	<a href="http://hdl.handle.net/2297/9559">http://hdl.handle.net/2297/9559</a>

doi: 10.1016/j.ejrex.2008.01.018

# **Uncommon co-localization of pituitary adenoma and parasellar cavernous angioma –**

## **Case Report**

### ***Abstract***

We encountered a 49-year-old female presenting with left oculomotor palsy who was found to be co-localized cavernous sinus CA and pituitary adenoma. Although cavernous angiomas (CA) originated from parasellar regions are not so rare, on neuroimaging studies, the characteristics of CA may be difficult to differentiate from those of pituitary adenomas. The co-localization of the two tumors was identified by preoperative dynamic MRI study. As intraoperative histological examination confirmed our preoperative diagnosis, we performed biopsy of the CA only to avoid uncontrollable intraoperative hemorrhage.

**KEY WORDS:** parasellar, cavernous angioma, pituitary adenoma, MRI, dynamic study

### ***Introduction***

Cavernous angiomas (CA) are not so rare vascular anomalies even in the parasellar region. On neuroradiological imagings, pituitary adenomas with the extension into cavernous sinus could share the characteristics with parasellar CAs if they progress into intrasellar region [1]. Cavernous angiomas located within the cavernous sinus are very difficult to remove because of uncontrollable intraoperative bleeding. Therefore, if we encounter the intrasellar CAs or parasellar CAs with extension into sellar region, it would be important to make an accurate diagnosis of CAs preoperatively to avoid the surgical risk [1,2].

We presented a patient who was found to be a rare case of co-localized parasellar CA and pituitary adenoma. These two tumors were clearly distinguished by preoperative dynamic MRI study.

## ***Case Report***

This 49-year-old woman presented with diplopia and left-eye pain. Neurological examination revealed left oculomotor palsy. Endocrinological examination returned no abnormal findings except for a mildly elevated serum prolactin level. MRI revealed two masses; One of them originated within the left cavernous sinus, with secondary intrasellar extension and compression of the pituitary gland to the right without contact with the optic chiasm. T1-weighted MRI showed hypointensity in isointensity with marked enhancement. Hyperintensity in isointense at the center of the sella was noted on T2-weighted images (Fig.1). This finding suggested that the mass was a pituitary adenoma with necrotic change. The other mass revealed multilobular compartments; on T1-weighted images we noted isointensity with marked enhancement while T2-weighted images disclosed hyperintensity (Fig.1).

Dynamic MRI study was performed as follows; with 1.5T Signa Horizon, Fast spin echo sequences were used for the coronal viewing. TR was 400-500ms, TE 7.5-20, and echo train was four. Parameters of 256 X 128 or 160, one excitation, and slice thickness was 2-5mm and the scan time was 18 sec. Six sequential images including the pre-injection images were obtained at each six locations 15-20sec after an intravenous bolus injection of the contrast media.

Dynamic study showed delayed homogeneous enhancement of the isointense area in one mass; the other manifested early, homogeneous, intense enhancement (Fig.2). Angiograms revealed no abnormal findings. Finally, we made a preoperative diagnosis of pituitary adenoma and CA. We posited that her left oculomotor palsy was attributable to the compression by CA.

We used the transsphenoidal approach to explore both lesions. Intraoperative pathological examination confirmed that the mass located at the cavernous sinus was CA (Fig.3A), and the other was a pituitary adenoma with necrotic changes as expected (Fig.3B). To avoid uncontrollable bleeding from the CA, we restricted our intervention to biopsy of both masses.

Postoperatively, we administered prednisolone (50mg per day) to relieve compression of the oculomotor nerve. Her postoperative course was uneventful, and left oculomotor palsy recovered completely within three weeks.

## ***Discussion***

Neuroradiologically, CAs and pituitary adenomas can have a similar appearance [1]. On MRI, CA in the cavernous sinus manifested as a well-defined mass with hypo or isointensity and was markedly enhanced on T1-weighted images, while on T2-weighted images it was hyperintense [3]. In our patient, the mass with multilobular compartments locating at the parasellar region with extension into the sellar region exhibited isointensity, and was markedly enhanced on T1-weighted images and hyperintensity on T2-weighted images.

Dynamic MRI study demonstrated differences between the two masses; the central sellar lesion exhibited delayed and homogeneous enhancement. On the other hand, the lateral sellar lesion, like the mass in the pituitary gland, was enhanced early, homogeneously and intensely. Suzuki performed dynamic MRI study of lesions adjacent to the pituitary gland, and reported that intracavernous CAs appeared as peripheral nodular stains with gradually increasing intensity [4]. In our case, dynamic study showed very early staining, as the staining pattern was nodular and gradual, we considered it as CA. By dynamic MRI study, tumor vascularity can be assessed accurately. For example, meningiomas show early and intense enhancement; for their identification, dynamic- is superior to delayed study.

On the other hand, pituitary adenomas are maximally enhanced later than the normal gland and cavernous sinus; their typical enhancement pattern is homogeneous and these tumors manifest less enhanced than the pituitary gland [5]. In our case, the area exhibiting hypointensity on T1- and hyperintensity on T2-weighted images was confirmed to be necrosis inside the pituitary adenoma.

The surgical removal of the component originating within the cavernous sinus may be associated with high

morbidity due to uncontrollable bleeding [3,6-8]. Although complete CA resection is curative, other methods to reduce the mass and its vascularity have been proposed. Therefore, we chose to perform diagnostic biopsy to avoid the risk of hemorrhage. In patients similar to the highly unusual case presented here, an accurate preoperative diagnosis is necessary to avoid a detrimental treatment outcome.

### **Reference**

- [1] Chuang CC, Jung SM, Yang JT et al. Intracellar cavernous hemangioma. J Clin Neurisci 2006;13(6):672-5
- [2] Kim IM, Yim MB, Lee CY, et al. Merits of intralesional fibrin glue injection in surgery for cavernous sinus cavernous hemangiomas: Technical note. J Neurosurg 2002;97(3):718-21
- [3] Shi J, Hang C, Pan Y, Liu C, Zhang Z. Cavernous hemangiomas in the cavernous sinus. Neurosurgery. 1999;45(6):1308-13
- [4] Suzuki M, Matsui O, Ueda F, et al. Dynamic MR imaging for diagnosis of lesions adjacent to pituitary gland. Eur J Radiol 2005;53(2):159-67
- [5] Sakamoto Y, Takahashi M, Korogi Y, et al. Normal and abnormal pituitary glands: gadopentetate dimeglumine-enhanced MR imaging. Radiology 1991;178(2):441-5
- [6] Rigamonti D, Pappas CT, Spetzler RF, et al. Extracerebral cavernous angiomas of the middle fossa. Neurosurgery 1990;27(2):306-10
- [7] Goel A, Muzumdar D, Sharma P. Extradural approach for cavernous hemangioma of the cavernous sinus: experience with 13 cases. Neurol Med Chir 2003;43(3):112-118
- [8] Zhou LF, Mao Y, Chen L. Diagnosis and surgical treatment of cavernous sinus hemangiomas: an experience of 20 cases. Surg Neurol. 2003;60(1):31-6

## Abbreviations

CA; cavernous angioma, MRI; magnetic resonance imaging

## Figure Legends

### Figure 1

Coronal T1-weighted MRI revealed a mass lesion compressing the pituitary gland to right, and showed a hypo- and an iso-intensity (a, arrow) with homogeneous enhancement (b, arrow). T2-weighted MRI showed a hyper-intensity (c, arrow) at the center of the sellar region. Multilobular compartments of the mass in the parasellar region extending into the intrasellar region showed an iso-intensity (a, double arrows) with marked enhancement (b, double arrows) on T1- and hyper-intensity on T2-weighted MRI (c;double arrows).

### Figure 2.

Dynamic T1-weighted MRI study showed delayed, homogeneous enhancement of the mass in the center of the sellar region. There was early, homogeneous, intense enhancement of the mass in the cavernous sinus with extension into the intrasellar region.

### Figure 3.

(a) Photomicrograph of the biopsy specimen of the mass in the cavernous sinus showing multiple dilated vascular channels separated by a matrix of fibrous tissue without intervening brain tissue. The pathological diagnosis was cavernous angioma. (b) Photomicrograph of the biopsy specimen of the mass in the central sellar region showing a pituitary adenoma. Note the necrotizing tissue (arrows) corresponding with the area of hypo-intensity on T1-weighted MRI without enhancement. (H&E, Original magnification x 100)

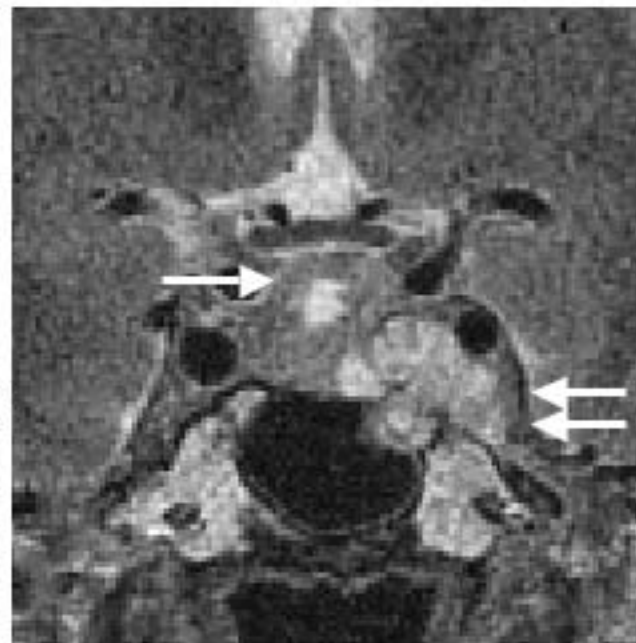
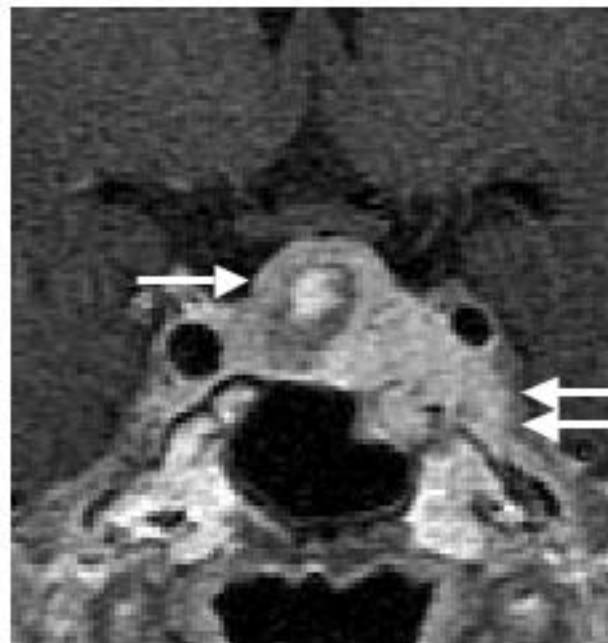
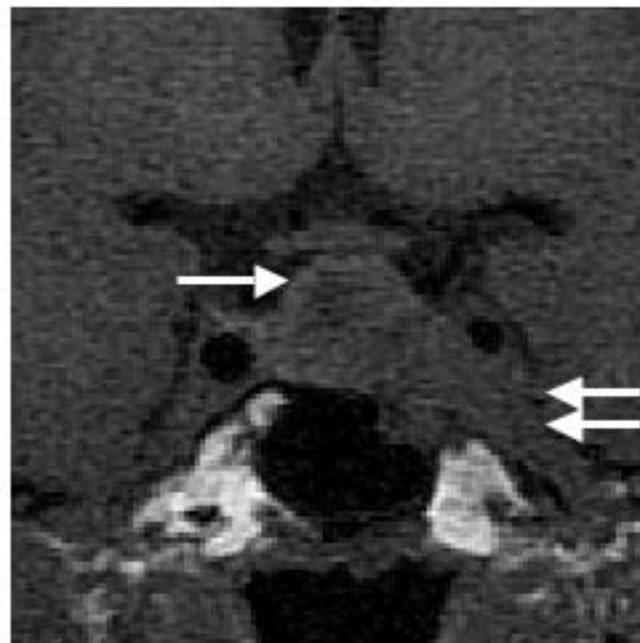
# Figure 1

Yasuhiko Hayashi ↑

(A)

(B)

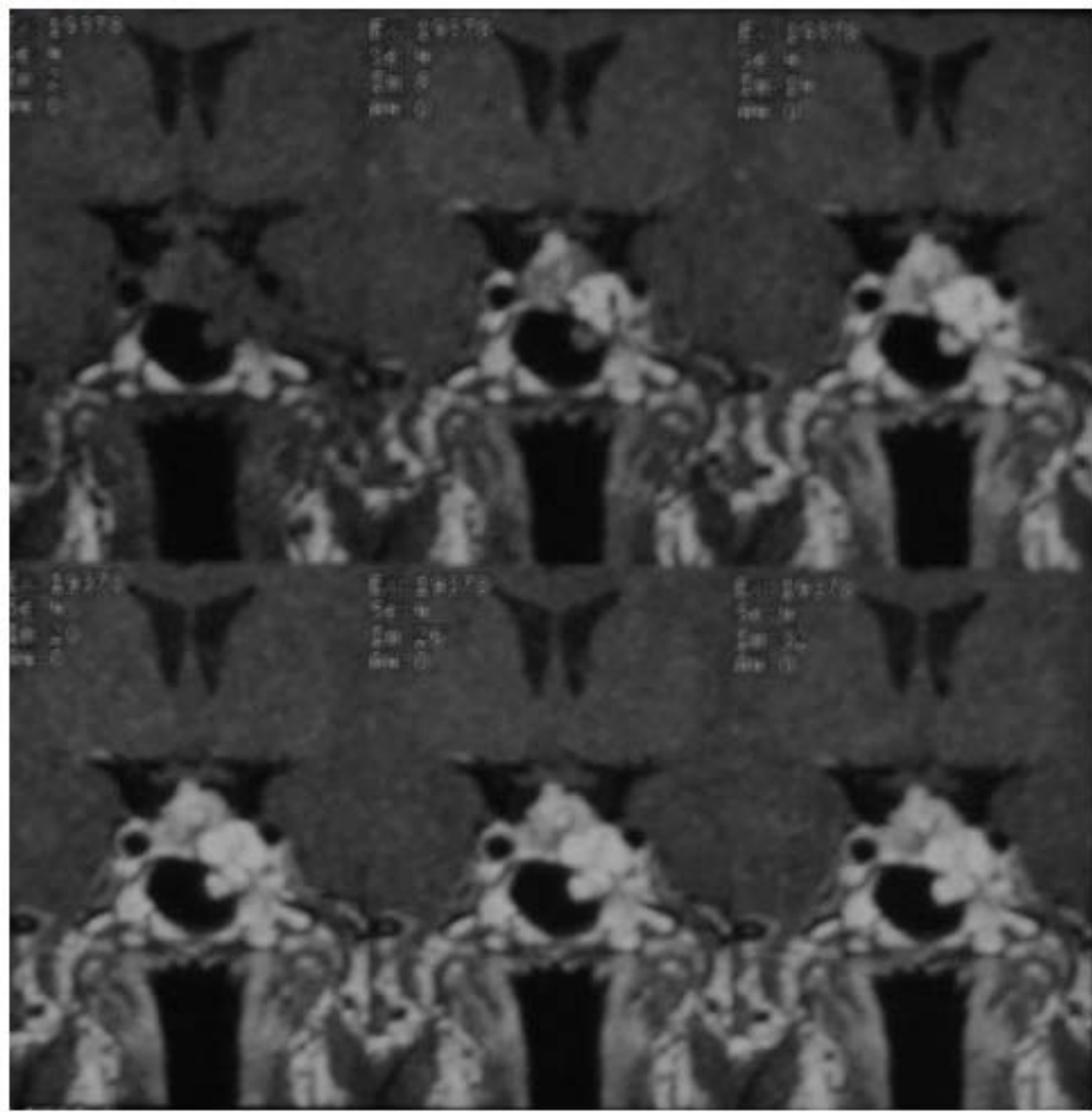
(C)



# Figure 2

Yasuhiko Hayashi ↑

(A)

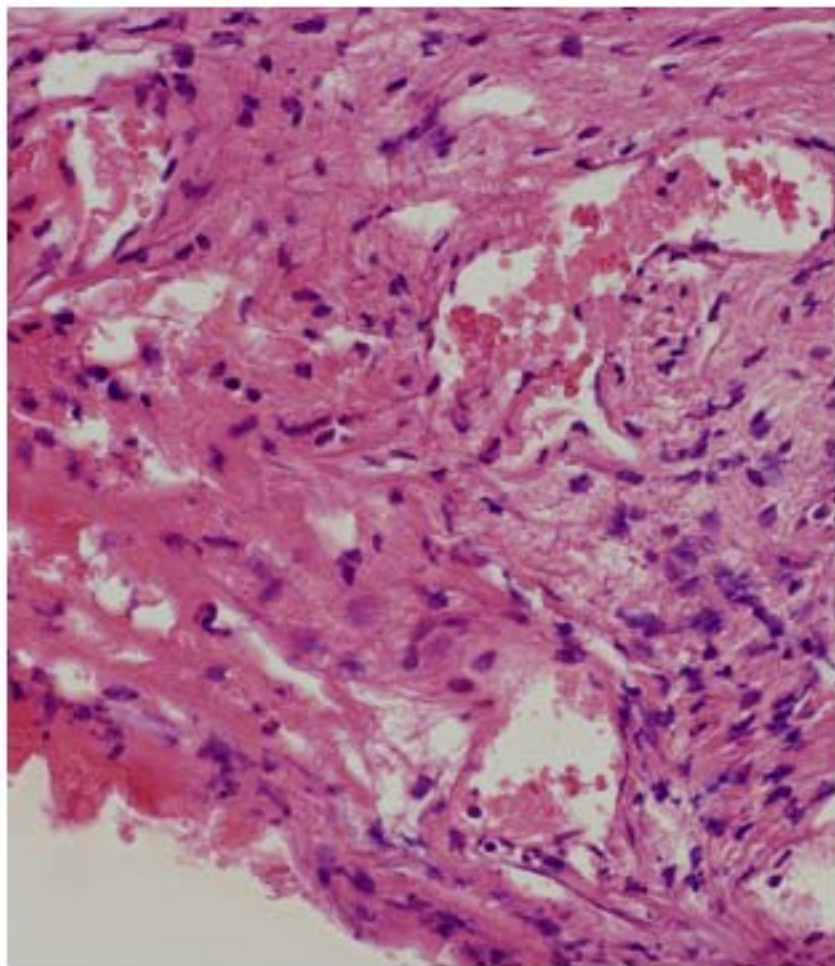




# Figure 3

Yasuhiko Hayashi ↑

(A)



(B)

