

Cricoid ossification mimicking an impacted foreign body.

著者	Wakisaka Naohiro, Miwa Takaki, Yoshizaki Tomokazu, Furukawa Mitsuru
journal or publication title	The Journal of laryngology and otology
volume	120
number	7
page range	E24
year	2006-07-01
URL	http://hdl.handle.net/2297/9548

(a) Case Report: Cricoid Ossification Mimicking an Impacted Foreign Body

(b) Naohiro Wakisaka, MD, Takaki Miwa, MD, Tomokazu Yoshizaki, MD, Mitsuru
Furukawa, MD

Department of Otolaryngology, School of Medicine, Kanazawa University

(c) Naohiro Wakisaka, MD

Department of Otolaryngology, School of Medicine, Kanazawa University,

Takara-machi 13-1, Kanazawa, Ishikawa 920-8640, Japan

Phone: +81-76-265-2413

Fax: +81-76-234-4265

E-mail: wakisaka@med.kanazawa-u.ac.jp

Abstract

A 54-year-old man complained of severe throat pain and showed subglottic edema on fiberscopy, with a distinctly narrow subglottic space on anteroposterior radiograph of the neck and dense linear opacity at the level of the cricoid cartilage on lateral plain radiograph. These examinations suggested acute subglottitis accompanied by foreign body just posterior to the cricopharyngeus. Computed tomography (CT) scan was performed to exclude a foreign body embedded in the hypopharyngeal mucosa. The CT scan demonstrated a dense calcified ridge on the posterior lamina of the cricoid cartilage, but there was no foreign body. It was determined that the patient had a simple acute subglottitis. The patient was treated with systemic antibiotics and topical steroids, and symptoms were gradually resolved. Gastrointestinal fiberscopy did not detect any foreign body in the upper digestive tract. This is an extremely rare case of vertical ossification of the cricoid lamina masquerading as foreign body.

Key Words

cricoid cartilage; physiological calcification; foreign body; computed tomography scan

Introduction

Osseous changes, which occur in the cartilages of the larynx, are often described as a degenerative process in hyaline cartilage, associated with advancing age (1). Ossifications of the laryngeal cartilages normally begin when skeletal growth is otherwise complete, in males at age 20 and females at 22 (2). Ossifications of laryngeal cartilages are a physiological process, but there have been some reports of laryngeal ossification masquerading as foreign bodies of the upper digestive tract (2, 3, 4, 5). Here we report a case of acute subglottic laryngitis masquerading as a foreign body at the level of the cricopharyngeus. We could find only two previous descriptions of vertical ossification of the cricoid lamina mimicking an impacted foreign body (3, 4).

Case report

A 54-year-old man complained of severe throat pain at the level of the thyroid cartilage two days after swallowing a fish bone during dinner. Fiberscopic examination demonstrated swelling and congestion of the subglottis, but did not demonstrate any foreign body in the oropharynx or hypopharynx (Fig. 1). Palpation of the left neck caused slight tenderness. Radiography of the neck on lateral view demonstrated a linear opacity posterior to the calcified cricoid cartilage. This linear opacity was not continuous with the cricoid cartilage calcification (Fig. 2A). Anteroposterior radiographs of the neck showed a narrowed subglottic space, which is characteristic of an acute subglottitis (Fig. 2B). These examinations suggested an impacted foreign body at the level of the cricopharyngeal sphincter accompanied by acute subglottitis. A computed tomography (CT) scan of the hypopharynx was performed to exclude a foreign body embedded in the hypopharyngeal mucosa or formation of deep neck space abscess. The CT scan demonstrated a densely calcified ridge on the posterior lamina of the cricoid cartilage (Fig.3). There was no foreign body shown on CT scan. Throat pain was diagnosed as simple acute subglottitis.

The patient's pain was gradually resolved by treatment with infusion of antibiotics (PAPM/BP 1 g/day, and CLDM 1.2 g/day) for 4 days. Anteroposterior radiograph of the neck clearly demonstrated the disappearance of swelling in the subglottic space (Fig. 4). Gastrointestinal fiberoscopy did not demonstrate any foreign body in the upper digestive tract, and the patient was discharged from the ward thereafter.

Discussion

The cricopharyngeus, which is the first sphincter in the digestive tract, is one of the sites at which a swallowed foreign body may frequently impact. Ossification of airway cartilages on plain X-ray film may masquerade as a foreign body in the digestive tract in some patients with a history of foreign body ingestion. This process may cause confusion to the clinician, who then has to rely on other investigations to exclude the possibility of an impacted foreign body.

Ossification of the cricoid cartilage begins first in the curvilinear superior border of the lamina (1, 2). Separate areas of linear ossification often occur in the posterior border of the lamina and in the oblique superior border of the arch. The rest of the lamina and the posterior half of the arch usually show a hazy ossification that spreads downwards and forwards. The anterior half of the arch is the last to ossify. Two areas in the cricoid are likely to be confused with a foreign body (2). First, the superior tip of the cricoid lamina is often the only part to be ossified for some time, and because of its curvilinear appearance, may resemble a bony foreign body. Second, vertical ossification of the posterior margin of the cricoid lamina may also occur separately and mimic a

bony fragment, as shown in our case (3).

The clinician must be aware of the radiographic feature of normal cricoid calcification to prevent misdiagnosis of this condition as an impacted foreign body. The linear cricoid opacity of a physiological calcification is usually thin and never extends beyond the upper or lower cricoid borders (4). The absolute difference from the linear opacification of an impacted foreign body may extend beyond the cricoid borders and may be irregular, depending on the shape of the foreign body (4). Although, in our case, the linear opacification was between the level of the upper and lower borders of the cricoid cartilage on plain X-ray film, findings in our patient were highly suggestive of an impacted foreign body in the hypopharynx, because symptom onset was subsequent to swallowing a fish bone. Thus, we performed a CT scan to confirm the possibility of an impacted foreign body. However, a CT scan of the cricoid cartilage did not show a break between the densely calcified ridge and the rest of the calcified cricoid posterior lamina, clearly suggesting that the linear opacification on plain X-ray film was the cricoid calcification.

Thus, when it is difficult to determine on a plain lateral neck radiograph whether

the linear opacity is a calcified ridge on the cricoid or a foreign body impacted at the cricopharyngeal sphincter, a CT scan should be the first choice for further investigations. Lim *et al.* recommended excluding the possibility of an impacted foreign body by performing endoscopy or CT scan (4). However, if we had performed endoscopy, the procedure might have stimulated laryngeal inflammation, including swelling due to subglottic edema following intubation for general anesthesia, which might have increased airway obstruction in this patient. When there is accompanying airway obstruction, endoscopic procedures should be avoided. Finally, we propose performing a CT scan first, and only when the presence of an impacted foreign body continues to be strongly suggested, endoscopy should be performed while carefully monitoring the airway status of the patients.

References

1 Keen JA, Wainwright J. Ossification of the thyroid, cricoid and arytenoids cartilages.

S. Afr. J. Lab. Clin. Med. 1958;**4**:83-108.

2 Hatley W, Evison G, Samuel E. The pattern of ossification in the laryngeal cartilages:

a radiological study. *Br. J. Radiol.* 1965;**38**:585-591.

3 Richardson GS, Albuquerque NM. Unusual calcification of cricoid cartilage

masquerading as foreign body in esophagus. *A. M. A. Arch. Otolaryngol.*

1955;**62**:316-318.

4 Lim CT, Tan KP, Stanley RS. Imaging case study of the month: cricoid calcification

mimicking an impacted foreign body. *Ann. Otol. Rhinol. Laryngol.* 1993;**102**:735-

737.

5 O'Bannon, R. P., Grunow, O. H. The larynx and pharynx radiologically considered.

South. Med. J. 1954;**47**:310-316.

6 Sundgren PC, Burnett A, Maly PV. Value of radiography in the management of

possible fishbone ingestion. *Ann. Otol. Rhinol. Laryngol.* 1994;**103**:628-631.

Legend for Figures

Fig. 1: Fiberscopic view of the larynx showing subglottic swelling parallel to the vocal cords. (▲ :epiglottis; —▶:vocal cords, —▶:subglottic edema)

Fig.2: (A) Plain lateral neck radiograph showing linear opacity separated from cricoid calcification, which may mimic a foreign body impacted at the cricopharyngeus. (arrow) (B) Anteroposterior view showed a distinctly narrowed subglottic space. (arrows)

Fig. 3:Computed tomography scan shows dense ossification ridge on cricoid posterior lamina continuous with the rest of the cricoid calcification. (arrow) There was no foreign body demonstrated.

Fig. 4: Anteroposterior view showed a widened airway 5 days after treatment.

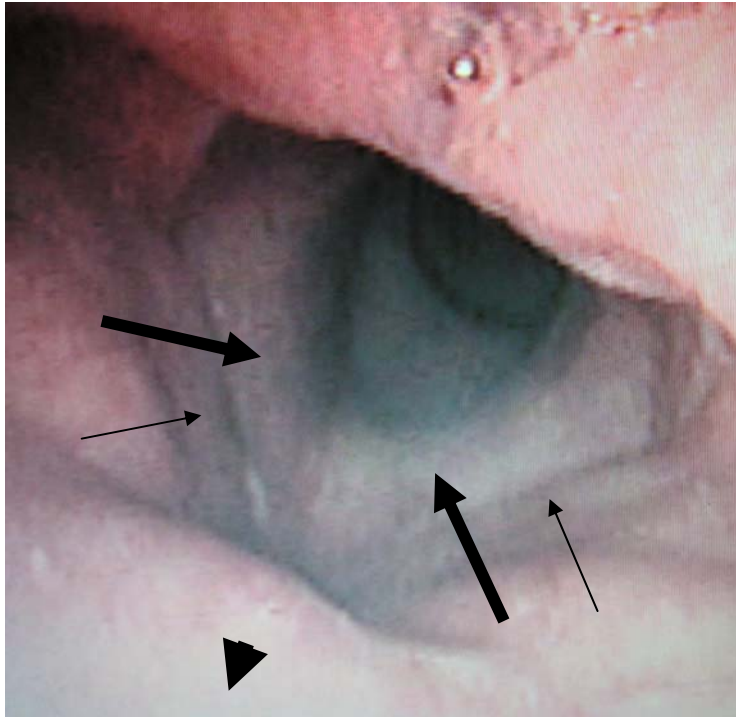
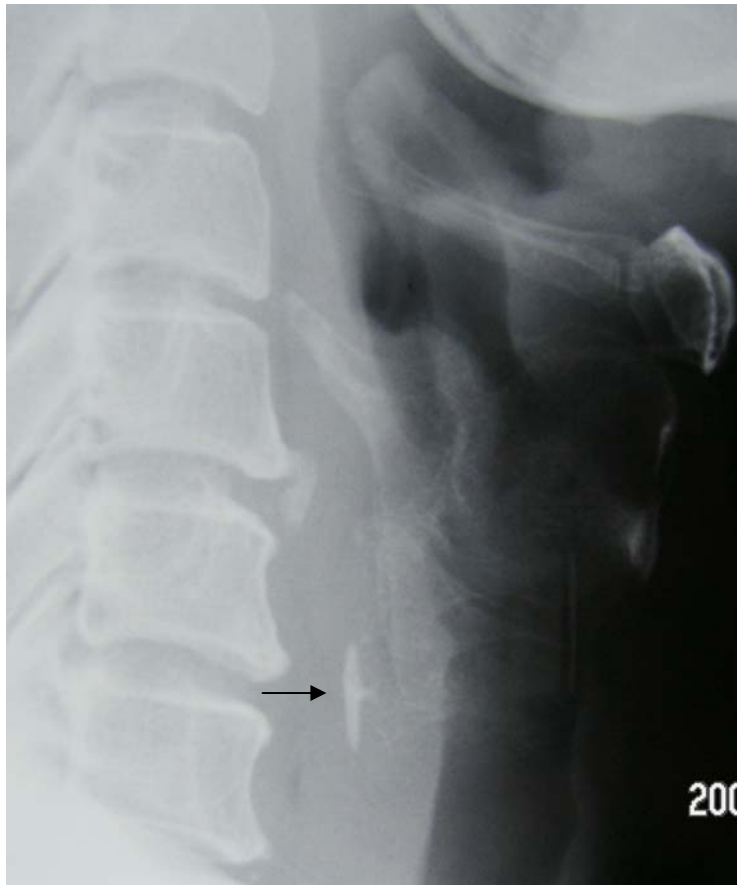
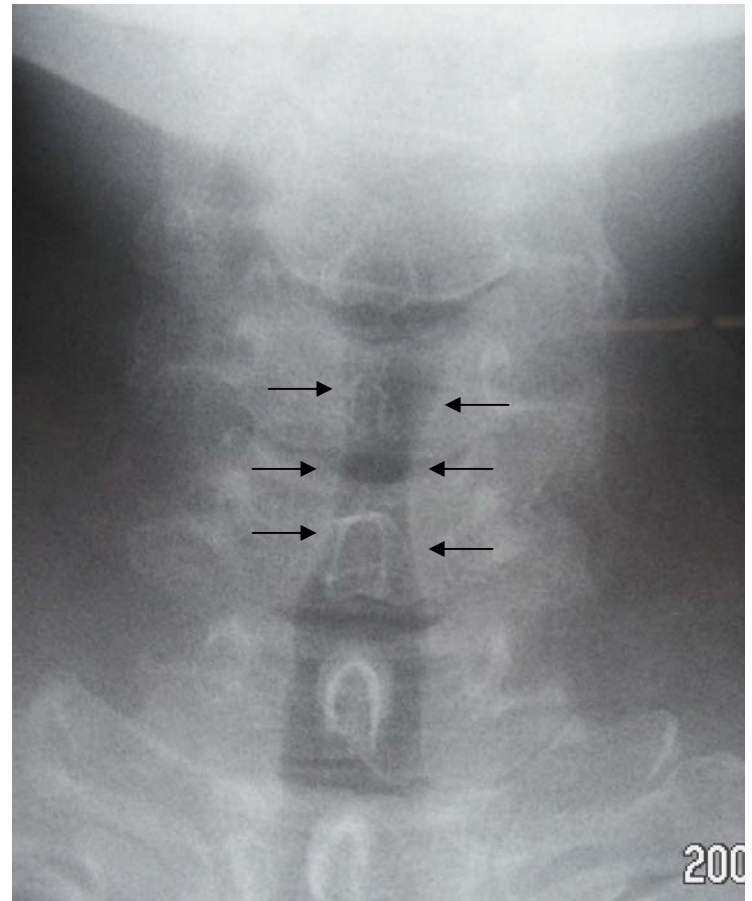


Fig. 1



A



B

Fig. 2

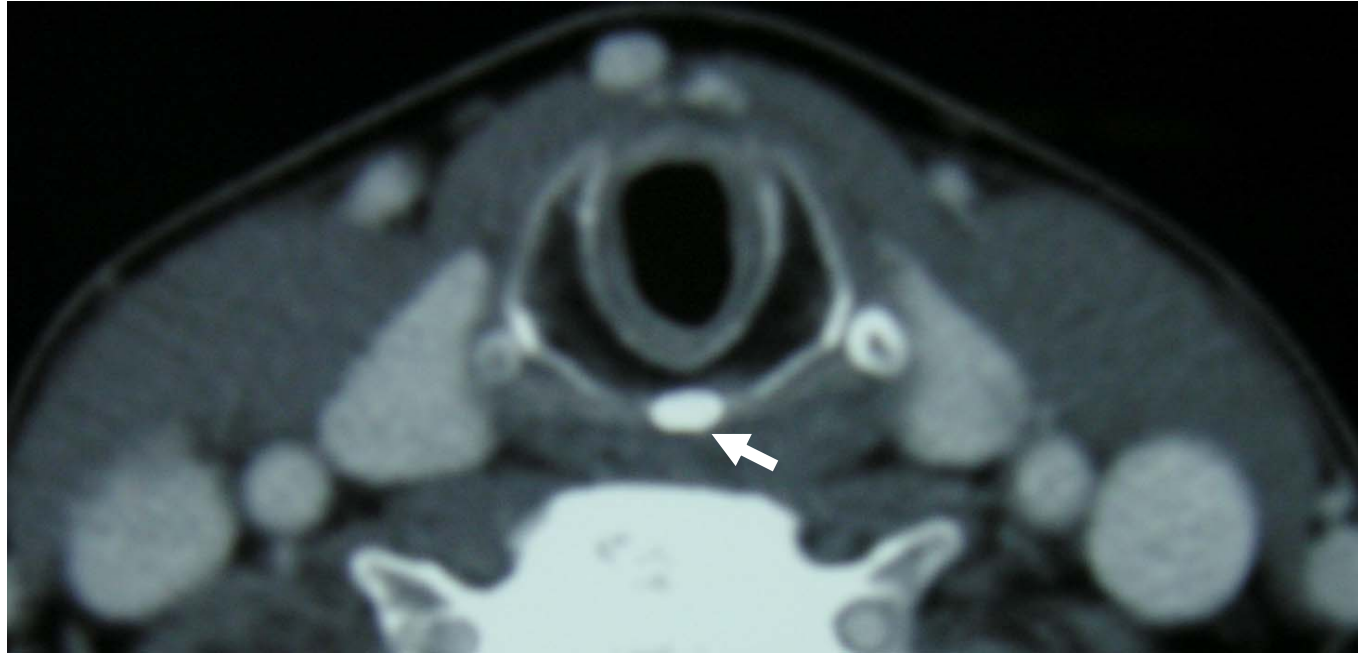


Fig. 3

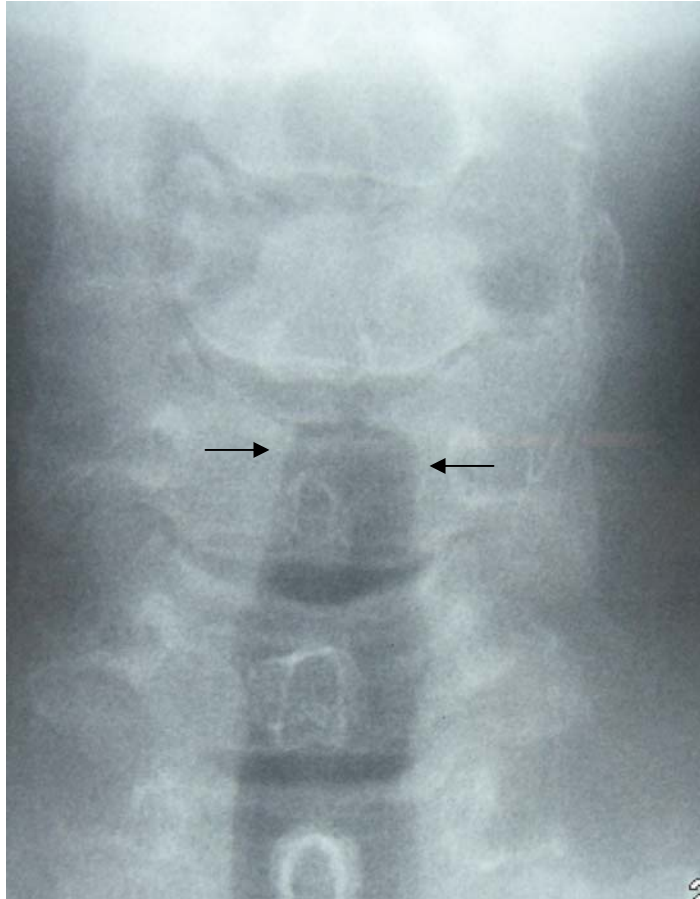


Fig. 4