

# Use of the Sonopet ultrasonic curettage device in intraoral vertical ramus osteotomy

著者	Ueki Koichiro, Nakagawa Kiyomasa, Marukawa Kohei, Shimada Mayumi, Yamamoto Etsuhide
journal or publication title	International Journal of Oral and Maxillofacial Surgery
volume	36
number	8
page range	745-747
year	2007-08-01
URL	<a href="http://hdl.handle.net/2297/6928">http://hdl.handle.net/2297/6928</a>

doi: 10.1016/j.ijom.2007.01.022

**The use of the Sonopet ultrasonic curettage device in intraoral vertical ramus osteotomy**

KOICHIRO UEKI<sup>1</sup>, KIYOMASA NAKAGAWA<sup>1</sup>, KOHEI MARUKAWA<sup>1</sup>, MAYUMI SHIMADA<sup>1</sup>, ETSUhide YAMAMOTO<sup>1</sup>

Key words:

Intra-oral vertical ramus osteotomy, ultrasonic bone curette, cortex

Address correspondence to: Koichiro Ueki, DDS, PhD.

<sup>1</sup> Department of Oral and Maxillofacial Surgery, Graduate School of Medicine, Kanazawa University, 13-1 Takaramachi, Kanazawa 920-8641, Japan.

Tel: +81-76-265-2444; Fax: +81-76-234-4268

E-mail: [kueki@med.kanazawa-u.ac.jp](mailto:kueki@med.kanazawa-u.ac.jp)

## **Abstract**

This study was designed to evaluate the usefulness of the Sonopet UST-2001 (Miwatec Co., Ltd., Kawasaki, Kanagawa, Japan) ultrasonic curettage device and to assess the outcome after intraoral vertical ramus osteotomy (IVRO). The 13 Japanese adults (ranging in age from 20 to 41 years, with a mean age of 29.6 years) in this study presented with jaw deformities diagnosed as mandibular prognathism and asymmetry; they all underwent IVRO of the mandible. This procedure was followed by ultrasonic bone curettage using the Sonopet to make a guiding notch or groove in the lateral cortex of the ramus without damaging the vessels and nerves. After surgery, the osteotomy line was evaluated by three-dimensional computed tomography (3DCT). In all patients, osteotomy with the Sonopet device was achieved safely, with minimal bleeding and no notable complications. The distal segment could be moved into its ideal position and all patients achieved their ideal profiles. Ultrasonic bone curettage represents safe modality for making a guiding groove, without damage to surrounding tissue, prior to complete IVRO.

## **Introduction**

Intraoral vertical ramus osteotomy (IVRO) has become a common procedure.<sup>1</sup> It is used for patients with temporomandibular joint dysfunction (TMD) with and without jaw deformity.<sup>2</sup> Furthermore, it is faster and associated with a lower incidence of hypoesthesia of the inferior alveolar nerve than sagittal split ramus osteotomy (SSRO)<sup>1,2</sup>. However, the osteotomy line is located close to the mandibular foramen, so that it is essential to identify this structure accurately and to perform a very precise osteotomy. It has become possible to identify the mandibular foramen by three-dimensional computed tomography (3DCT). However, it is difficult to transfer the resulting image to the clinical scenario.

After surrounding tissue, including the masseter muscle, is detached from the lateral mandibular ramus, direct visualization of the osteotomy region at the posterior site of the lateral ramus becomes difficult. Even if the retractor is used, considerable force is required to exclude the masseter muscle and surrounding tissue and also to maintain the retractor in position during work with the conventional saw. After the posterior border of the mandibular ramus is identified by using the retractor, the initial point of osteotomy can be determined. However, enough space to accommodate the oscillating saw blade is necessary; adequate space is also needed for accurate determination of the osteotomy line and correct incision of the ramus. It is especially difficult to make the guiding groove in the cortex of the lateral ramus after the osteotomy line has been determined. The precise determination of this first groove is of vital importance if an ideal line is to be achieved. Therefore we prefer to use the Sonopet ultrasonic bone

curette to make the first groove as well as to decrease the force required to hold the retractor in place.

The purpose of this study was to evaluate the usefulness of this instrument and to assess the outcome after intraoral vertical ramus osteotomy (IVRO).

## **Surgical technique**

### Patients

The 13 Japanese adults in this study presented with jaw deformities diagnosed as mandibular prognathism, bimaxillary asymmetry, or mandibular asymmetry. At the time of orthognathic surgery, the patients ranged in age from 20 to 41 years, with a mean age of 29.6 years.

### Surgery

Of the 13 patients in this study, 4 underwent IVRO alone, without fixation. Six patients underwent IVRO with Le Fort I osteotomy, 2 patients underwent IVRO and mandibular anterior alveolar osteotomy, and 1 patient underwent IVRO and posterior alveolar osteotomy for distraction osteogenesis. After several days of maxillomandibular fixation (MMF), elastic was placed to maintain the ideal occlusion. All patients received orthodontic treatment before and after surgery.

### IVRO Procedure

Preoperatively, the osteotomy line was simulated with 3DCT so as to avoid the mandibular foramen. After surrounding tissue, including the masseter muscle was

detached from the lateral mandibular ramus, the antelingual prominence was identified with a dental mirror as an anatomic landmark. Then the final site of the osteotomy line determined. The Sonopet device was used to make a precise guiding groove and decrease the holding force required of the retractor. A curved osteotomy line running through the posterior site of the antelingual prominence was easily performed. After a guiding notch in the lateral cortex of the ramus had been made, osteotomy with an angled oscillating saw and curved osteotome was completed through the notch. After osteotomy, the medial pterygoid muscle was stripped in a vertical plane to establish the desired setback of the distal segment. The muscle posterior to the stripped area was partially maintained.

The Sonopet UST-2001 Ultrasonic Bone Curette (Miwatec Co., Ltd., Kawasaki, Kanagawa, Japan)

This ultrasonic surgical device comprises a power supply unit, foot switch, and handpiece. The handpiece weights 110 g, is 140 mm in length from tip to angled section, and is 20 mm in diameter. The longitudinal vibration amplitude is variable from 120 to 365  $\mu\text{m}$  at an ultrasonic frequency of 25 kHz. Furthermore, longitudinal-torsional amplitude is also available for more effective cutting of bone. The adjustable cooling irrigation fluid (20 °C) emerges through the sheath near the tip of the hand piece; , a suction equipment is also attached.<sup>4</sup>

CT Assessment

To assess the localization of the osteotomy line and mandibular foramen, tomographs were obtained using a high-speed advantage-type CT generator (GE Medical Systems, Milwaukee, WI), with each sequence taken 2 mm apart in the horizontal plane (parallel to the Frankfort plane) both pre- and postoperatively. The postoperative images were also obtained in order to determine whether osteotomy line had damaged the mandibular foramen.

## **Results**

After surgery, no patient had wound infection or dehiscence. The mean setback was  $2.5 \pm 2.8$  mm on the right side and  $3.1 \pm 2.8$  mm on the left. Operation time and amount of bleeding were not recorded separately for maxillary and mandibular osteotomy, making statistical comparisons difficult.

In all cases, the mandibular segments could be moved to their ideal position and all patients achieved their ideal profiles. In no instance was the mandibular foramen damaged by the osteotomy procedure (Fig.3).

## **Discussion**

Although ultrasonic osteotomies were first described by Horton et al. in 1975,<sup>5,6</sup> this approach was not pursued for many years. It was not until 2000 that Vercellotti<sup>10</sup> took it up for surgery designed to protect nerves and soft tissue. The results of piezosurgery (Mectron Medical Technology, Carasco, Italy) in dentistry and veterinary medicine have demonstrated promising possibilities, confirmed by Stübinger et al.<sup>8</sup> However, when deep cuts into the bone were necessary, the system was less efficient. While the

cutting speed decreased, temperatures rose; therefore pauses were necessary to let the system cool down.

On the other hand, in the field of neurosurgery, ultrasonic instruments (Sonopet) are used to remove brain tumors. The hand pieces of such equipment are becoming smaller and lighter; with adjusted power, safe evacuating systems have become available. An ultrasonic scalpel-type osteotome has recently been developed and used for spinal surgery.<sup>7</sup> This instrument can be used to make a narrow incision in the vertebral arch for laminectomy and splitting laminoplasty.<sup>4</sup> Although the device is highly efficient for cutting with its longitudinal torsional tip, precise cutting for procedures such as interdental osteotomy is not possible because of the tip's shape and excessive vibration. However, we have used the Sonopet instrument in Le Fort I osteotomy and have reported that it was possible to perform artificial fracture of pterygoid plate without damaging the descending palatine artery and surrounding soft tissue.<sup>9</sup> This device can cut hard cortical bone, such as mandibular ramus or angle, so that it can facilitate IVRO. It takes just a few minutes to cut the cortex using the device, so that operation time could not be extended. Furthermore, in comparison with use of the oscillating saw alone, use of this device was very easy in similar to use of periodontic ultrasonic scaler, because it did not need to retract surrounding tissue such as masseter muscle largely. However, this device unit was very expensive, approximately 7 million Japanese yen. Although, SSRO can be performed with an approach from the front of mouth, the IVRO procedure must be approached from the lateral side. In SSRO, the conventional drill or saw may be preferred to the Sonopet device. Although no complications have been experienced, the angled edge of the tip of the Sonopet was



too short (bone cut was approximately width 3 mm and depth 3mm) to reach the deep site of ramus by the intraoral approach. In short, this device can cut just create a minimal groove in the bone in intraoral approach. However, it could be used make the guide groove prior to use of the oscillating saw. If the extraoral approach was used, complete osteotomy could be achieved with only this device. Furthermore, this device can be used in combination with an endoscope. Although, further modification of hand piece design is necessary, this device will replace current bone cut instrument partially. CT imaging was used to assess the outcome of IVRO in this study. The CT results indicated that the osteotomy procedure caused no damage to the mandibular foramen. It was possible to perform these osteotomies precisely according to the preoperative design. A curved osteotomy line could be easily designed and implemented, so that damage of mandibular foramen could be avoided.

## **Conclusion**

Ultrasonic bone curettage represents a safe approach to the establishment of a guiding notch prior to complete IVRO without damage to surrounding tissue.

## References

1. Bell WH, Proffit WR, White RP. Surgical Collection of Dentofacial Deformities. Philadelphia: Saunders 1980.
2. Bell WH: Mandibular prognathism. In: Modern Practice in Orthognathic and Reconstructive Surgery. Philadelphia, PA: Saunders, 1992: 61: 2111-2137.
3. Hadeishi H, Suzuki A, Yasui N, Satou Y. Anterior clinoidectomy and opening of the internal auditory canal using an ultrasonic bone curette. Neurosurgery 2003: 52: 867-871.
4. Hidaka K, Chiba Y, Takada H. Clinical application of the ultrasonic osteotome for the spinous process-splitting laminoplasty. Spinal Surg 1998: 12: 19-24.
5. Horton JE, Tarpley TM Jr, Jacoway J: Clinical applications of ultrasonic instrumentation in the surgical removal of bone. Oral Surg Oral Med Oral Pathol 1981: 51: 236-242.
6. Horton JE, Tarpley TM Jr, Wood LD: The healing of surgical defects in alveolar bone produced with ultrasonic instrumentation, chisel and rotary bur. Oral Surg Oral Med Oral Pathol 1975: 39: 536-546.

7. Sawamura Y, Fukushima T, Terasaka S, Sugai T. Development of a handpiece and probes for a microsurgical ultrasonic aspirator: Instrumentation and application. *Neurosurgery* 1999; 45: 1192-1197.
8. Stübinger S, Kuttenger J, Filippi A, Sader R, Zeihofer HF: Intraoral piezosurgery: Preliminary results of a new technique. *J Oral Maxillofac Surg* 2005; 63: 1283-1287.
9. Ueki K, Nakagawa K, Marukawa K, Yamamoto E. Le Fort I osteotomy using ultrasonic bone curette to fracture the pterygoid plates. *J Cranio Maxillofac Surg* 2004; 32: 381-386.
10. Vercellotti T: Piezoelectric surgery in implantology: A case report –A new piezoelectric ridge expansion technique. *Int J Periodontics Restorative Dent* 2000; 20: 358-368.

### **Figure Legends**


FIGURE 1. Ultrasonic bone curette (Sonopet<sup>®</sup>). A) Main unit with panel. B) Schema of longitudinal-torsional amplitude of tip. C) Handpiece (straight type).

FIGURE 2. A) Schematic drawing of intra-operative findings. Bone cut was approximately 3mm width and 3mm depth. B) Intra-operative photograph. Arrows show the guide groove by ultrasonic bone curette (Sonopet<sup>®</sup>).

FIGURE 3. Postoperative 3DCT image. Arrows show the osteotomy line. A)lateral view, B) medial view.



A

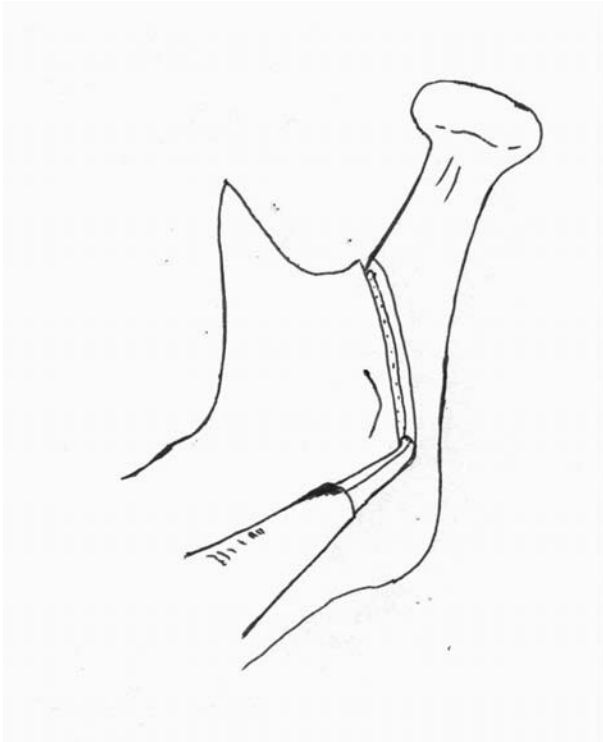


B

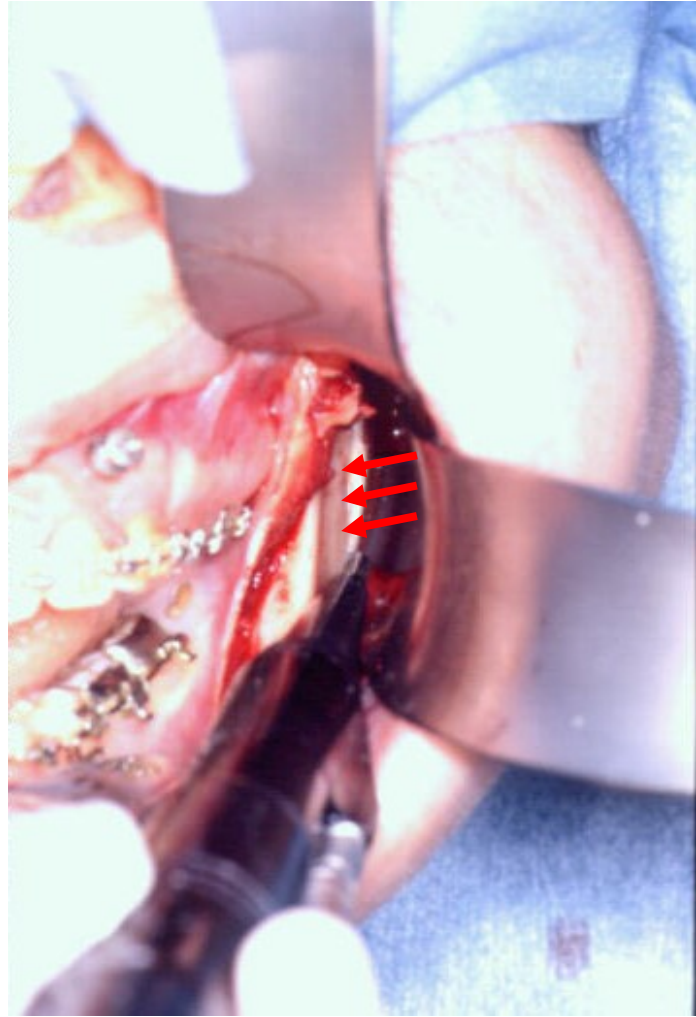


C

Fig. 1

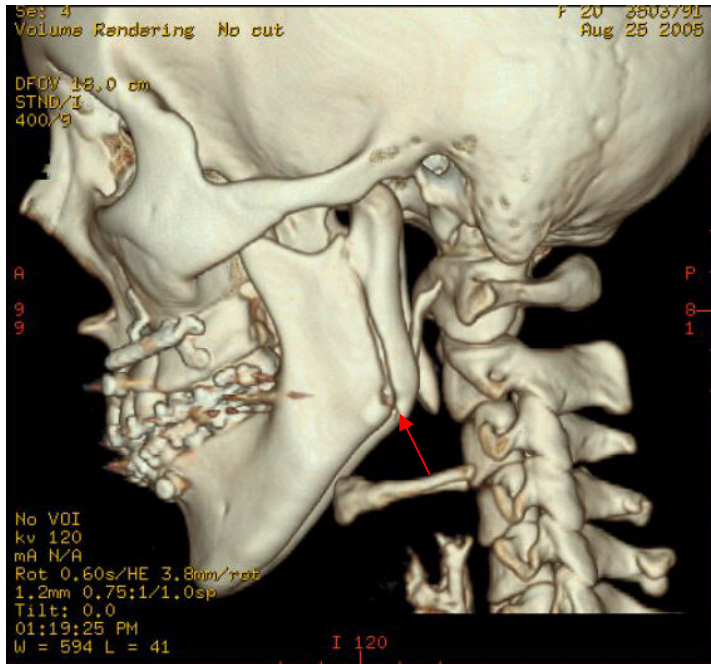


A

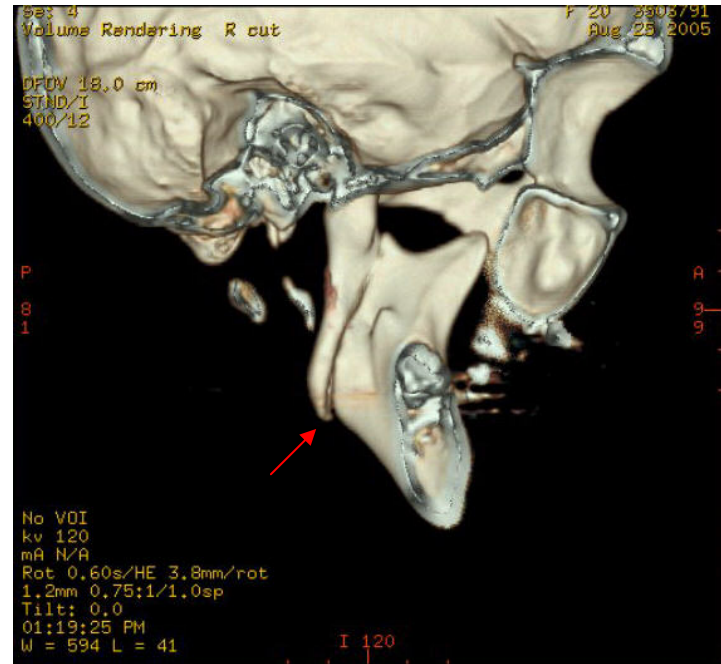


B

Fig. 2



A



B

Fig. 3