

Living-donor lobar lung transplantation for broncho-bronchiolitis obliterans after allogeneic hematopoietic stem cell transplantation: does bronchiolitis obliterans recur in transplanted lungs?

著者	Okumura Hirokazu, Ohtake Shigeki, Ontachi Yasuo, Ozaki Jun, Shimadoi Shigeru, Waseda Yuko, Kondo Yukio, Yamazaki Hirohito, Takami Akiyoshi, Yasui Masahide, Date Hiroshi, Nakao Shinji
journal or publication title	International journal of hematology
volume	86
number	4
page range	369-373
year	2007-11-01
URL	<a href="http://hdl.handle.net/2297/9573">http://hdl.handle.net/2297/9573</a>

doi: 10.1532/IJH97.07045

## **Living-Donor Lobar Lung Transplantation for Broncho-Bronchiolitis Obliterans after Allogeneic Hematopoietic Stem Cell Transplantation: Does Bronchiolitis Obliterans Recur in Transplanted Lungs?**

Hirokazu Okumura,<sup>a</sup> Shigeki Ohtake,<sup>b</sup> Yasuo Ontachi,<sup>a</sup> Jun Ozaki,<sup>a</sup> Shigeru Shimadoi,<sup>a</sup> Yuko Waseda,<sup>a</sup> Yukio Kondo,<sup>a</sup> Hirohito Yamazaki,<sup>a</sup> Akiyoshi Takami,<sup>a</sup> Masahide Yasui,<sup>a</sup> Hiroshi Date,<sup>c</sup> Shinji Nakao<sup>a</sup>

<sup>a</sup>Department of Cellular Transplantation Biology, Kanazawa University Graduate School of Medical Science, Kanazawa, Japan; <sup>b</sup>Department of Laboratory Science, Kanazawa University Graduate School of Medical Science, Kanazawa, Japan; <sup>c</sup>Department of Cancer and Thoracic Surgery, Okayama University Graduate School of Medicine and Dentistry, Okayama, Japan

Received March 12, 2007; received in revised form June 11, 2007; accepted June 20, 2007

### **Abstract**

We report a successful case of living-donor lobar lung transplantation (LDLLT) for therapy-resistant broncho-bronchiolitis obliterans (BBO) after allogeneic hematopoietic stem cell transplantation (HSCT). Bronchiolitis obliterans (BO) is one of the late-onset noninfectious pulmonary complications that occur after allogeneic HSCT and is usually resistant to immunosuppressive therapy. A 17-year-old girl with acute lymphoblastic leukemia (ALL) had undergone allogeneic bone marrow transplantation (BMT) from an HLA-matched sibling in 1997. Five years later, she relapsed with ALL and was treated with chemotherapy following stem cell rescue and donor lymphocyte infusion from the original BMT donor. Eight months later, BBO resistant to immunosuppressive therapies, including rituximab, developed in combination with chronic graft-versus-host disease (GVHD). In February 2004, the patient underwent LDLLT from 2 other family members who were mismatched at 3 HLA loci. The patient has been in good health for more than 30 months following LDLLT and shows no sign of BBO in the transplanted lungs, just as with other patients who have undergone lung transplantation for BO associated with chronic GVHD. LDLLT may therefore be considered a viable therapeutic option for the treatment of BO after allogeneic HSCT.

*Int J Hematol.* 2007;86:xxx-xxx. doi: 10.1532/IJH97.07045

© 2007 The Japanese Society of Hematology

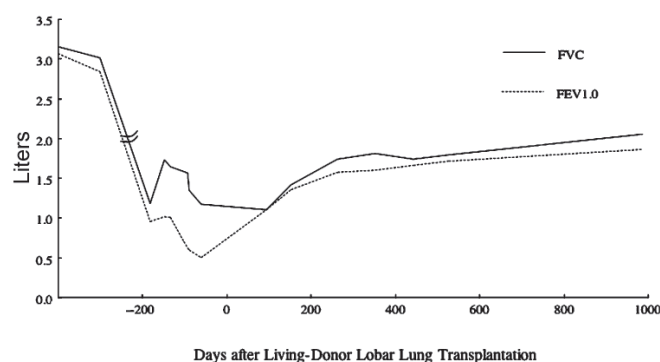
**Key words:** Living-donor lung transplantation; Bronchiolitis obliterans (BO); Allogeneic hematopoietic stem cell transplantation; Graft-versus-host disease (GVHD)

### **1. Introduction**

Pulmonary complications develop in 40% to 60% of recipients of allogeneic hematopoietic stem cell transplantation (HSCT) [1-3]. In 1998, Palmas et al [4] defined noninfectious pulmonary complications that occur later than 3 months after allogeneic SCT as late-onset noninfectious pulmonary complications (LONIPCs). Once LONIPCs

occur, the recipient's quality of life is markedly impaired; therefore, LONIPCs are recognized as a major cause of morbidity and mortality after allogeneic HSCT [4,5]. LONIPCs include bronchiolitis obliterans (BO), bronchiolitis obliterans with organizing pneumonia (BOOP), diffuse alveolar damage, lymphocytic interstitial pneumonia (LIP), and nonclassifiable interstitial pneumonia (NCIP) [4]. Although the pathogenesis of LONIPCs remains unclear, LONIPCs are strongly associated with chronic graft-versus-host disease (GVHD) [4,6,7]. Immunosuppressive therapies have been considered to be the standard treatments for LONIPCs. In fact, LIP, NCIP, and BOOP have all been shown to successfully respond to these treatments [4,7]. BO, however, is usually resistant to such treatments [4,7,8]. The mortality rate for BO following allogeneic HSCT therefore may be as high as 100% [1,9,10].

Correspondence and reprint requests: Hirokazu Okumura, Department of Cellular Transplantation Biology, Kanazawa University Graduate School of Medical Science, Takara-machi 13-1, Kanazawa 920-8641, Japan; 81-76-265-2273; fax: 81-76-234-4252 (e-mail: hokumura@med3.m.kanazawa-u.ac.jp).



**Figure 1.** The pulmonary function test before and after living-donor lobar lung transplantation. FVC indicates forced vital capacity; FEV1.0, forced expiratory volume in 1 second.

Lung transplantation (LT) is an alternative therapeutic option for BO in some selected patients; however, the long-term efficacy of LT for BO and the recurrence rate of BO in transplanted lungs are unknown. We describe a patient who underwent living-donor lobar LT (LDLLT) for therapy-resistant BO after allogeneic HSCT and who has demonstrated no disease recurrence for more than 30 months after LDLLT.

## 2. Case Report

A 17-year-old girl received a diagnosis of acute lymphoblastic leukemia (ALL) in February 1997. She was treated with combination chemotherapy [11] and obtained complete remission. The patient underwent allogeneic bone marrow transplantation from her HLA-matched sibling in July 1997. The preconditioning regimen consisted of 3 Gy total body irradiation once daily for 4 consecutive days (total dose, 12 Gy), 2 g/m<sup>2</sup> cytarabine administered intravenously twice daily for 2 consecutive days (total, 4 doses), and 60 mg/kg cyclophosphamide administered intravenously once daily for 2 consecutive days (total dose, 120 mg/kg). GVHD prophylaxis consisted of cyclosporine (CsA) and short-term methotrexate. No GVHD was observed, and CsA was tapered off until February 1998. The patient relapsed with ALL in October 2002. An anthracycline-containing regimen [11] induced a second complete remission. Eight days after consolidation therapy consisting of 2 g/m<sup>2</sup> cytarabine administered intravenously twice daily for 5 consecutive days (total, 10 doses), the patient received donor buffy coat containing 5.4 × 10<sup>6</sup>/kg CD34<sup>+</sup> cells and 0.7 × 10<sup>8</sup>/kg CD3<sup>+</sup> cells, which were collected after administration of granulocyte colony-stimulating factor. No GVHD prophylaxis was given. Because GVHD did not develop until day 70 after the buffy coat infusion, the patient received donor leukocyte infusions at a dose of 0.7 × 10<sup>8</sup>/kg of CD3<sup>+</sup> cells on day 34 and 1.4 × 10<sup>8</sup>/kg on day 70 after the buffy coat infusion. In March 2003, 10 days after receiving the second donor lymphocyte infusion, the patient developed lichenoid lesions and ulcers on the buccal mucosa and eruptions on the skin. A lip biopsy revealed pathologic changes compatible with chronic GVHD. Oral administration of CsA was initiated in April

2003. The lichenoid lesions of the buccal mucosa gradually improved, but the symptoms of dry eyes and skin eruptions did not improve. In April 2003, the patient began complaining of dry cough, which gradually worsened. She was hospitalized in August 2003 because of an exacerbation of dry cough and dyspnea. A computed tomography examination of the chest showed atelectases of the right lower lobes, diffuse parenchymal hypoattenuation, and proximal bronchiectases. Her forced vital capacity (FVC) and forced expiratory volume in 1 second (FEV1.0) had also decreased markedly (Figure 1). A bronchofiberscopy examination showed obstructions at the level of the broncho-bronchiols, predominantly in the lower lobes on both sides. The patient then received a diagnosis of broncho-bronchiolitis obliterans (BBO), a variant of BO. The CsA dose was increased, and oral administration of prednisolone was initiated; however, no response was observed. As the patient's symptoms worsened, CsA was replaced with tacrolimus. In addition, rituximab was administered at 375 mg/m<sup>2</sup> once a week for 4 weeks to treat scleroderma caused by the chronic GVHD [12]. We concluded that scleroderma had partially contributed to her constrictive respiratory failure by limiting chest wall compliance; however, the patient's respiratory failure associated with hypercapnia became exacerbated to such a degree that she became completely dependent on oxygen support. The patient became totally bedridden and had to undergo a tracheostomy in January 2004 to receive mechanical ventilation. At this time, her family requested that LT be performed. The patient was considered a candidate for LDLLT because she had end-stage BO (which is listed as a clinical status meeting the indication criteria for LT), because of the impossibility of waiting for a cadaveric lung graft owing to her rapid exacerbation of respiratory failure, and because there were no contraindications for LT except for the coexistence of malignant disease [13,14]. The patient's ALL had been in the second complete remission for more than a year, however, and the level of Wilms tumor gene in the bone marrow was 120 copies/μg RNA, thus indicating a low potential for an ALL relapse [15]. The ethics committee of the lung-transplantation center approved LDLLT for this patient because she was considered to have neither newly treated malignant disease nor widespread malignancy. LDLLT was performed on February 16, 2004, with a right lower lobe from her older brother (who was mismatched at 3 HLA loci in the direction of graft rejection) and a left lower lobe from her mother, who was mismatched at 3 antigens in the direction of graft rejection (Table 1). The patient's own lungs were removed completely. The ABO antigens of the recipient and donors were compatible

**Table 1.**

HLA of the Patient and Donors\*

	A	B	DR
Recipient	11/24	52/-	9/15
HSCT donor (younger brother)	11/24	52/-	9/15
LDLLT donor (elder brother)	2/11	46/52	8/15
LDLLT donor (mother)	2/11	13/52	12/15

\*HSCT indicates hematopoietic stem cell transplantation; LDLLT, living-donor lobar lung transplantation.

**Table 2.** Reported Cases of Lung Transplantation (LT) for Bronchiolitis Obliterans (BO) after Hematopoietic Stem Cell Transplantation (HSCT)\*

Case No.	Hematologic Disease	Age at LT, y	Time from HSCT to LT	cGVHD	Diagnosis of Lung Complication	LT Donor Type	Prophylaxis for Rejection	Survival Time from LT	Outcome	Reference
1	ALL	34	2 y	NE	Interstitial fibrosis with lymphoid infiltrates	Cadaver	CsA + AZP + PDN	9 mo	Alive	[18]
2	AA	14	8 y	+	Interstitial and focal parenchymal fibrosis, BO	Cadaver	FK506 + AZP + PDN	15 mo	Alive	[19]
3	ALL	27	NE	+	BO	Cadaver	NE	271 d	Died of BO	[20]
4	Immunodeficiency	11	6 mo	NE	Pulmonary fibrosis	Living	mPDN	14 mo	Alive	[21]
5	CML	38	15 mo	+	BO	Cadaver	CsA + MMF + mPDN	23 mo	Alive	[22]
6	AML	30	14 y	–	Radiation pneumonia	Cadaver	CsA + PDN	3 y	Died of pulmonary infections	[23]
7	AA	9	3 y	+	Diffuse interstitial and focal parenchymal fibrosis with compensatory emphysema and BO with cGVHD	Cadaver	FK506 + AZP + PDN	6 y	Died of lung rejection	[23]
8	Wiskott-Aldrich syndrome	6	3 y	+	Acute and chronic inflammatory change, bronchiectasis, BO, and extensive peribronchial fibrosis	Cadaver	FK506 + AZP + PDN	6 y	Alive	[23]
9	ALL	14.5	5.5 y	+	BO	Cadaver	FK506 + AZP + PDN	24 mo	Alive	[23]
10	AA	34	5 y	+	BO with interstitial pneumonia	Living	FK506 + MMF + PDN	38 mo	Alive	[24]
11	CML	17	14 mo	+	BO	Living	CsA + AZP + PDN	3 wk	Died of pulmonary hemorrhage	[25]
12	ALL	NR	7 y	+	BO	NR	CsA + AZP + PDN	NR	NR	[25]
13	ALL	NR	1 y	–	Pulmonary fibrosis	NR	CsA + AZP + PDN	NR	NR	[25]
14	ALL	NR	5 y	+	BO	NR	CsA + AZP + PDN	NR	NR	[25]
15	AML	NR	6 y	+	Pulmonary fibrosis	NR	CsA + AZP + PDN	NR	NR	[25]
Present case	ALL	24	23 mo	+	BBO	Living	FK506 + AZP + PDN	30 mo	Alive	—

\*cGVHD indicates chronic graft-versus-host disease; ALL, acute lymphoblastic leukemia; NE, not evaluated; CsA, cyclosporine; AZP, azathioprine; PDN, prednisone or prednisolone; AA, aplastic anemia; FK506, tacrolimus; mPDN, methylprednisolone; CML, chronic myeloid leukemia; MMF, mycophenolate mofetil; AML, acute myeloid leukemia; NR, not reported; BBO, broncho-bronchiolitis obliterans.

(Table 1). The immunosuppressive therapy to prevent graft rejection consisted of tacrolimus, prednisolone, and azathioprine. Signs of acute rejection appeared after LDLLT, but rejection was successfully avoided by the intravenous administration of methylprednisolone and mycophenolate mofetil. The hypercapnia rapidly improved, and the vital capacity increased immediately after LDLLT. This progress allowed the patient to be weaned from mechanical ventilation on day 15, and she was discharged from the hospital on day 64 after LDLLT. BBO has not recurred in the transplanted lungs, and tests of pulmonary function have shown improvements in both the FVC and FEV1.0 for more than 30 months following LDLLT, despite the persistence of dry eyes and impaired lacrimal secretion. A pathologic examination of the explanted lungs revealed focal desquamation of the broncho-bronchiolar epithelium with an aggregate of foamy macrophages and lymphocytes and occlusions of the broncho-bronchiolar lumen, observations compatible with a diagnosis of either BBO or BO [16].

### 3. Discussion

BO is one of the LONIPCs and occurs 3 to 15 months following allogeneic HSCT [4,5,7,8]. The clinical symptoms of BO include a nonproductive cough, rapidly progressive dyspnea, and wheezing. The incidence of BO following allogeneic HSCT varies from 2.7% to 7.6% according to the published studies [4,7,8]. BO is one of the most devastating complications of allogeneic HSCT. Once it occurs in a patient, the prognosis tends to be extremely poor. The mortality rate reportedly varies from 14% to 100% [7,17,18]. The response to BO treatment has a significant effect on survival: 79% of responders survived more than 5 years from the diagnosis of BO, but only 13% of nonresponders survived [8]. Patients with LONIPCs have been treated with immunosuppressive agents such as antithymocyte globulin, methylprednisolone, prednisolone, CsA, tacrolimus, and azathioprine. Most patients with LIP and BOOP responded well to such treatments, whereas only 16% to 49% of BO patients improved owing to these treatments [4,7,8]. Consequently, no standard therapy for BO has yet been established.

Because BO often develops in association with chronic GVHD, this complication is thought to be one of the pulmonary manifestations of chronic GVHD [7,8,19]. However, the development of BO following autologous bone marrow transplantation in 2 patients [20] and a lower incidence of BO in recipients of allogeneic HSCT following reduced-intensity conditioning than in HSCT recipients with myeloablative conditioning [21] suggest that tissue damage due to high-dose radiochemotherapy plays a role in the development of BO. Our patient had extensive chronic GVHD, as manifested by sicca symptoms, at the time of LDLLT, and these symptoms persisted for more than 30 months, even after LDLLT. Because her lungs were suspected to be a target of the chronic GVHD, an LT from the donor of the allogeneic HSCT was thought to be ideal; however, because the donor and patient's family did not consent, she received an LT from 2 family members who were mismatched at 3 HLA loci. Despite the presence of

HLA mismatches between the lung donors and the patient and the persistence of chronic GVHD, there has been no recurrence of BO in the transplanted lungs.

Fifteen cases of LT for post-SCT pulmonary complications following allogeneic HSCT, including 10 BO patients, have been reported (Table 2) [22-29]. The indications for LT in patients demonstrating BO following allogeneic HSCT are limited by many factors, such as the criteria of the donor and recipient, the existence of a suitable donor, the status of hematologic disease, and the timing of LT, especially for LDLLT [30]. Four of the 10 BO patients died after LT [24,27,29]. The patient in case 7 died of chronic rejection 6 years after undergoing LT, patient 11 died of pulmonary hemorrhaging 3 weeks after receiving LT, and patient 3, who received a single LT from a cadaver, died of BO on day 271, following recurrent episodes of both perivascular and bronchial rejection. Pechet et al [29] described 2 patients who had complications of BO long after LT; however, the authors did not report the details of these patients. The development of post-LT BO was thought to be due in part to a manifestation of chronic rejection [31,32]; however, preexisting chronic GVHD may have played some role in the development of BO in the transplanted lung early after transplantation. The other 5 BO patients (except for those described by Pechet et al [29]) and our patient have not experienced BO in the transplanted lungs from more than 15 months to 6 years after LT, despite the existence of chronic GVHD. These findings indicate that factors other than chronic GVHD, such as high-dose chemoradiotherapy and viral infections, may contribute to the development of BO following allogeneic HSCT. Another possibility is that the development of BO may require the presence of specific minor histocompatibility antigen (mHa) mismatches between the donor of the LT and the patient's immune system. The transplanted lungs may have evaded the immune attack responsible for BO because of a lack of mHas mismatches. LT is therefore considered to be a promising therapy for BO, even for patients associated with active chronic GVHD.

### References

1. Krowka MJ, Rosenow EC 3rd, Hoagland HC. Pulmonary complications of bone marrow transplantation. *Chest*. 1985;87:237-246.
2. Soubani AO, Miller KB, Hassoun PM. Pulmonary complications of bone marrow transplantation. *Chest*. 1996;109:1066-1077.
3. Chan CK, Hyland RH, Hutcheon MA. Pulmonary complications following bone marrow transplantation. *Clin Chest Med*. 1990;11:323-332.
4. Palmas A, Tefferi A, Myers JL, et al. Late-onset noninfectious pulmonary complications after allogeneic bone marrow transplantation. *Br J Haematol*. 1998;100:680-687.
5. Afessa B, Litzow MR, Tefferi A. Bronchiolitis obliterans and other late onset non-infectious pulmonary complications in hematopoietic stem cell transplantation. *Bone Marrow Transplant*. 2001;28:425-434.
6. Duncker C, Dohr D, Harsdorf S, et al. Non-infectious lung complications are closely associated with chronic graft-versus-host disease: a single center study of incidence, risk factors and outcome. *Bone Marrow Transplant*. 2000;25:1263-1268.
7. Sakaida E, Nakaseko C, Harima A, et al. Late-onset noninfectious pulmonary complications after allogeneic stem cell transplantation are significantly associated with chronic graft-versus-host disease

- and with the graft-versus-leukemia effect. *Blood*. 2003;102:4236-4242.
8. Dudek AZ, Mahaseth H, DeFor TE, Weisdorf DJ. Bronchiolitis obliterans in chronic graft-versus-host disease: analysis of risk factors and treatment outcomes. *Biol Blood Marrow Transplant*. 2003;9:657-666.
  9. Holland HK, Wingard JR, Beschoner WE, Saral R, Santos GW. Bronchiolitis obliterans in bone marrow transplantation and its relationship to chronic graft-v-host disease and low serum IgG. *Blood*. 1988;72:621-627.
  10. Paz HL, Crilley P, Topolsky DL, Coll WX, Patchefsky A, Brodsky I. Bronchiolitis obliterans after bone marrow transplantation: the effect of preconditioning. *Respiration*. 1993;60:109-114.
  11. Takeuchi J, Kyo T, Naito K, Sao H, et al. Induction therapy by frequent administration of doxorubicin with four other drugs, followed by intensive consolidation and maintenance therapy for adult acute lymphoblastic leukemia: the JALSG-ALL93 study. *Leukemia*. 2002;16:1259-1266.
  12. Ratanatharathorn V, Ayash L, Reynolds C, et al. Treatment of chronic graft-versus-host disease with anti-CD20 chimeric monoclonal antibody. *Biol Blood Marrow Transplant*. 2003;9:505-511.
  13. DeMeo DL, Ginns LC. Clinical status of lung transplantation. *Transplantation*. 2001;72:1713-1724.
  14. Cohen RG, Starnes VA. Living donor lung transplantation. *World J Surg*. 2001;25:244-250.
  15. Inoue K, Ogawa H, Yamagami T, et al. Long-term follow-up of minimal residual disease in leukemia patients by monitoring WT1 (Wilms tumor gene) expression levels. *Blood*. 1996;88:2267-2278.
  16. Yokoi T, Hirabayashi N, Ito M, et al. Broncho-bronchiolitis obliterans as a complication of bone marrow transplantation: a clinicopathological study of eight autopsy cases. Nagoya BMT Group. *Virchows Arch*. 1997;431:275-282.
  17. Philit F, Wiesendanger T, Archimbaud E, Mornex JF, Brune J, Cordier JF. Post-transplant obstructive lung disease ("bronchiolitis obliterans"): a clinical comparative study of bone marrow and lung transplant patients. *Eur Respir J*. 1995;8:551-558.
  18. Clark JG, Crawford SW, Madtes DK, Sullivan KM. Obstructive lung disease after allogeneic marrow transplantation: clinical presentation and course. *Ann Intern Med*. 1989;111:368-376.
  19. Yousem SA. The histological spectrum of pulmonary graft-versus-host disease in bone marrow transplant recipients. *Hum Pathol*. 1995;26:668-675.
  20. Paz HL, Crilley P, Patchefsky A, Schiffman RL, Brodsky I. Bronchiolitis obliterans after autologous bone marrow transplantation. *Chest*. 1992;101:775-778.
  21. Yoshihara S, Tateishi U, Ando T, et al. Lower incidence of bronchiolitis obliterans in allogeneic hematopoietic stem cell transplantation with reduced-intensity conditioning compared with myeloablative conditioning. *Bone Marrow Transplant*. 2005;35:1195-1200.
  22. Calhoun JH, Levine S, Anzueto A, Bryan CL, Trinkle JK. Lung transplantation in a patient with a prior bone marrow transplant. *Chest*. 1992;102:948.
  23. Boas SR, Noyes BE, Kurland G, Armitage J, Orenstein D. Pediatric lung transplantation for graft-versus-host disease following bone marrow transplantation. *Chest*. 1994;105:1584-1586.
  24. Gascoigne A, Corris P. Lung transplants in patients with prior bone marrow transplants. *Chest*. 1994;105:327.
  25. Svendsen UG, Aggestrup S, Heilmann C, et al. Transplantation of a lobe of lung from mother to child following previous transplantation with maternal bone marrow. *Eur Respir J*. 1995;8:334-337.
  26. Rabitsch W, Deviatko E, Keil F, et al. Successful lung transplantation for bronchiolitis obliterans after allogeneic marrow transplantation. *Transplantation*. 2001;71:1341-1343.
  27. Heath JA, Kurland G, Spray TL, et al. Lung transplantation after allogeneic marrow transplantation in pediatric patients: the Memorial Sloan-Kettering experience. *Transplantation*. 2001;72:1986-1990.
  28. Sano Y, Date H, Nagahiro I, Aoe M, Shimizu N. Living-donor lobar lung transplantation for bronchiolitis obliterans after bone marrow transplantation. *Ann Thorac Surg*. 2005;79:1051-1052.
  29. Pechet TV, de le Morena M, Mendeloff EN, Sweet SC, Shapiro SD, Huddleston CB. Lung transplantation in children following treatment for malignancy. *J Heart Lung Transplant*. 2003;22:154-160.
  30. Veeken C, Palmer SM, Davis RD, Grichnik KP. Living-related lobar lung transplantation. *J Cardiothorac Vasc Anesth*. 2004;18:506-511.
  31. Burke CM, Theodore J, Dawkins KD, et al. Post-transplant obliterative bronchiolitis and other late lung sequelae in human heart-lung transplantation. *Chest*. 1984;86:824-829.
  32. Al-Githmi I, Batawil N, Shigemura N, et al. Bronchiolitis obliterans following lung transplantation. *Eur J Cardiothorac Surg*. 2006;30:846-851.