

Case of three delayed complications of radiotherapy: Bilateral vocal cord immobility, esophageal obstruction and ruptured pseudoaneurysm of carotid artery

著者	Maruyama Yumiko, Arai Kazunori, Hoshida Shigeru, Yoneda Kenzi, Furukawa Mitsuru, Yoshizaki Tomokazu
journal or publication title	Auris Nasus Larynx
volume	36
number	4
page range	505-508
year	2009-08-01
URL	http://hdl.handle.net/2297/18756

doi: 10.1016/j.anl.2008.11.005

**Case of three delayed complications of radiotherapy: bilateral
vocal cord immobility, esophageal obstruction and ruptured
pseudoaneurysm of carotid artery**

Yumiko Maruyama¹, Kazunori Arai², Shigeru Hoshida¹, Kenzi Yoneda²,

Mitsuru Furukawa³, and Tomokazu Yoshizaki³

Departments of ¹Otolaryngology-Head and Neck Surgery and ²Radiology, Kurobe City

Hospital, 1108-1 Mikkaichi, Kurobe, Toyama 938-8502, Japan

³Department of Otolaryngology-Head and Neck Surgery, Division of Neuroscience,

Kanazawa University Graduate School of Medical Science, 13-1 Takaramamachi,

Kanazawa, Ishikawa 920-8640, Japan

Address correspondence and reprint requests to: Yumiko Maruyama, M.D., Ph.D.

Department of Otorhinolaryngology and Head and Neck surgery Kurobe City Hospital

Tel: +81-765-54-2211; Fax: +81-765-54-2962

E-mail: maruyama@med.kurobe.toyama.jp

Running Head: Delayed three complications of irradiation

Introduction

Radiotherapy is the accepted treatment for head and neck carcinomas, with the advantage of organ preservation. It is however, not without complications, some of which are potentially lethal. Here, we present a patient who developed dysfunction of the airway, digestive tract and vascular system of the cervix decades after irradiation for laryngeal carcinoma. Clinicians should be aware of these rare complications of radiation therapy.

Case report

A 67-year-old female initially visited our hospital with dyspnea and dysphasia in July 2000. She received irradiation to the neck for laryngeal carcinoma in another hospital 28 years earlier, at age 39 years. Radiation therapy was reported to be given to laryngeal field with parallel opposing portal technique dose of 6,000R using X-ray betatron. Examination of nasopharyngoscopy and esophagogastroscope revealed the medial fixation of bilateral vocal cords and stenosis of the cervical part of esophagus. CT and MRI examination were performed, and multiple biopsies were taken under suspicion of recurrent or secondary malignancies, but organic abnormalities including malignant lesion were ruled out and cicatrization following irradiation was considered to be the cause of these conditions. She underwent tracheostomy with a cuff button-like

silicone cannula, a retainer cannula, to allow her to phonate, and had been eating paste food.

She visited a neurosurgeon about bilateral carotid stenosis in May 2007, and was diagnosed as having post-radiotherapy asymptomatic arteriosclerosis. However, it was concluded that calcification of the carotid arteries was too severe for vascular reconstruction.

The patient consulted us of aggravated dysphagia in December 2007. Because stenosis of the cervical esophagus worsened at age 74 years, 35 years after irradiation, the esophagogastroscope could not pass the stenotic esophagus, though she could swallow liquid food. CT was performed, which revealed no cervical tumor lesion, carotid aneurysm or dissection; however, bilateral marked arteriosclerosis of the carotid artery, severe stenosis of the arterial lumen, and scattered destruction of the thyroid cartilage were confirmed.

Celiotomy gastrostomy was planned for aggravated esophageal stenosis, but the patient expectorated over 2000 ml of blood a few days prior to the scheduled surgery; gastrostomy was thus postponed and she was admitted. The tracheostomy tube was replaced with a tube having a balloon cuff for airway management.

Nasopharyngoscopy showed a right hypopharyngeal bulging mass, which was dark reddish and obliterating from the right sinus pyriformis to glottis (Fig. 1). Enhanced CT

revealed a soft tissue mass over the right hypopharynx continuous with the right common carotid artery, whose margin was irregularly enhanced (Fig. 2).

Pseudoaneurysm of the right common carotid artery into the hypopharynx was suspected. On the day of admission, the patient began to haemorrhage again from the pharynx. To stop the bleeding, the pharynx was firmly packed with 11 sheets of gauze and pressure was applied via a doctor's finger. The patient lost more than 1500 ml of blood in 20 min, and her systolic blood pressure fell to about 50 mmHg. Doppler ultrasonography confirmed a tear in the common carotid artery, and blood ejection out of the carotid lumen (Fig. 3). After obtaining informed consent, angiographic examination was performed, which revealed a pseudoaneurysm of the right common carotid artery with severe carotid stenosis near the aneurysm (Fig. 4). Balloon test occlusion of the right common carotid artery was performed for 20 min without neurologic sequelae. Vascular occlusion devices consisting of four coils were placed in the common carotid artery. The first two coils were placed distal to the neck of the aneurysm but in the common artery (Fig. 5 A) and the other two coils were placed proximal to the pseudoaneurysm (Fig. 5 B). Complete occlusion of the artery was achieved after embolization, with no further bleeding. No neurological deficits were noted.

Follow-up nasopharyngoscope after embolization confirmed the disappearance

of the hypopharyngeal mass. After embolization, the tracheostomy tube was replaced with the retainer cannula and the patient was again able to phonate. However, esophagram revealed complete obstruction of the cervical esophagus.

There was no evidence of rheumatoid arthritis, gout or ankylosing spondylitis in this patient, and she had no trauma or surgery, other than tracheostomy, in the head and neck area. Infectious disease was ruled out, including cervical lymphadenitis and abscess, sepsis, infectious endocarditis and tuberculosis. Systemic angitis or congenital anomalies, such as Takayasu arteritis and Marfan syndrome, were also ruled out.

She was discharged after celiotomy gastrostomy. CT was performed at 3 months after embolization, and revealed no recurrence of aneurysm or tissue-destructive tumor.

Discussion

Irradiation is one of the most effective therapies for head and neck cancer. It is however, not without complications.

Complications of radiotherapy to the head and neck region are well documented. They include mucositis, skin reactions, decreased salivary function, soft tissue fibrosis and perichondritis. However, these complications are typically evident within a few months of treatment, and presentation after many years is rather unusual.

Herein, we presented a unique case of dysfunction of the airway, digestive tract

and vascular system in the cervix long after irradiation treatment for laryngeal carcinoma.

Bilateral immobility of the vocal cords is commonly due to abductor palsy of the vocal cord caused by paralysis of the recurrent laryngeal nerves. However, in recurrent laryngeal nerve palsies, there is adducting movement of the vocal cords and the vocal cords are usually in the paramedian position. Bilateral vocal cord immobility can also be caused by fixation of the cricoarytenoid joint, which occurs in cricoarytenoid arthritis secondary to rheumatoid arthritis, gout and ankylosing spondylitis, as well as after radiation [1]. The patient described here showed no evidence of rheumatoid arthritis, gout or ankylosing spondylitis.

Stenosis of the cervical esophagus was also seen in this patient, and this developed to obstruction of the digestive tract. There are a very few reports regarding late chondronecrosis of the laryngeal framework and fibrosis with stricture formation of the hypopharynx after radiotherapy [2,3]. The mechanism for total obliteration of the cervical esophagus and immobility of bilateral vocal cords is not clear. Radiotherapy may have induced laryngeal chondronecrosis, cricoarytenoid ankylosis, laryngeal and pharyngoesophageal fibrosis, and cicatrix, resulting in stricture or obstruction of the aerodigestive tract [1-3]. A probable reason is idiosyncratic sensitivity to irradiation [2].

Aneurysms of the extracranial carotid arteries are both rare and dangerous

due to the possibility of hemorrhage and of cerebrovascular damage. They can be caused by trauma, surgery, infection, vasculitis, congenital anomalies, endarterectomy and irradiation. The patient described here did not undergo surgery, except tracheostomy, and there was no history of trauma in the head and neck area. No infection, systemic arteritis or congenital anomalies were seen about the patient. We believe that the cause of pseudoaneurysm formation in our patient was radiation vasculopathy.

Experimental studies suggest that endothelial cell damage and platelet and fibrin deposition can be seen as early as 48 h after radiation exposure. At the subacute stage, morphological changes in the irradiated artery are characterized by fibrosis of media with focal necrosis and hemorrhage. These ischemic alterations are ascribed to injury to the vasa vasorum and, together with periadventitial fibrosis, weaken the arterial wall[4]. Irradiation also causes fragmentation of the elastic fibers of the tunica media, as well as subendothelial vascularization and edema. These conditions are thought to contribute to aneurysm formation of large irradiated arteries and the rupture of arteries [4,5]. Pseudoaneurysm formation of the carotid artery due to irradiation is extremely rare [6-9]. Disruption of aneurysm causes sudden, life-threatening hemorrhage and necessitates emergency surgery. Embolization was effective in our patient.

To the best of our knowledge, there have been no reports of cases developing

bilateral vocal cord immobility, obstruction of esophagus and spontaneously ruptured pseudoaneurysm of the common carotid artery into hypopharynx in the same patient decades after irradiation for laryngeal carcinoma.

Radiotherapy is a major treatment for patients with head and neck carcinoma, as it allows organ preservation. However, there also are complications in the acute to late phases of irradiation. Clinicians should be aware of these complications in order to ensure prompt and accurate diagnosis and treatment.

References

1. Prepageran N, Raman R. Delayed complication of radiotherapy: laryngeal fibrosis and bilateral vocal cord immobility. *Med J Malaysia* 2005;60:377-378
2. Nageris B, Elidan J, Sichel JY. Aerodigestive tract obstruction as a late complication of radiotherapy. *J Laryngol Otol* 1995;109:68-69
3. Varghese BT, Paul S, Elizabeth MI, Somanathan T, Elizabeth KA. Late post radiation laryngeal chondronecrosis with pharyngoesophageal fibrosis. *Indian J Cancer* 2004;41:81-84
4. Fonkalsrud EW, Sanchez M, Zerubavel R, Mahoney A. Serial changes in arterial structure following radiation therapy. *Surg Gynecol Obstet* 1977;145:395-400

5. Okamura HO, Kamiyama R, Takiguchi Y, et al. Histopathological examination of ruptured carotid artery after irradiation. *ORL J Otorhinolaryngol Relat Spec* 2002;64:226-228
6. Tanaka S, Kimura Y, Furukawa M. Pseudoaneurysm of the carotid artery with haemorrhage into the hypopharynx. *J Laryngol Otol* 1995;109:889-891
7. Li SH, Hsu SW, Wang SL, Chen HC, Huang CH. Pseudoaneurysm of the external carotid artery branch following radiotherapy for nasopharyngeal carcinoma. *Jpn J Clin Oncol* 2007;37:310-313
8. Buerger T, Meyer F, Halloul Z. Ruptured cervical aneurysm of the carotid artery--case report of a rare disease. *Vasa* 1998;27:122-124
9. Girishkumar HT, Sivakumar M, Andaz S, et al. Pseudo-aneurysm of the carotid bifurcation secondary to radiation. *J Cardiovasc Surg (Torino)* 1999;40:877-878

Figure legends

< Fig. 1: Pseudoaneurysm of right carotid artery in hypopharynx >

A dark reddish, bulging mass on the right side of the hypopharynx was seen on nasopharyngoscopy. The mass was obliterating from the right sinus pyriformis to glottis (arrows).

< Fig. 2: Enhanced axial CT scan of the neck >

Enhanced computed tomography revealed a soft tissue mass (black arrows) over the right hypopharynx continuous with the right common carotid artery (white arrow). The margin of the mass was irregularly enhanced.

< Fig. 3: Doppler ultrasonography of the right neck >

Doppler ultrasonography showed that the carotid wall (broken line) had a tear (arrow) at the neck of the pseudoaneurysm, and that blood flow was ejected out of the carotid lumen.

< Fig. 4: Angiography of the lesion >

Angiography of right carotid artery revealed a pseudoaneurysm of the common carotid artery (arrow) with severe carotid stenosis near the aneurysm.

< Fig. 5: Angiogram during and after embolization >

(A) Angiogram during embolization. Two metallic coils were placed distal to the aneurysm, but in the common carotid artery (arrow).

(B) Angiogram after embolization showing complete occlusion of the common carotid artery. Two additional coils were placed proximal to the aneurysm (arrows).

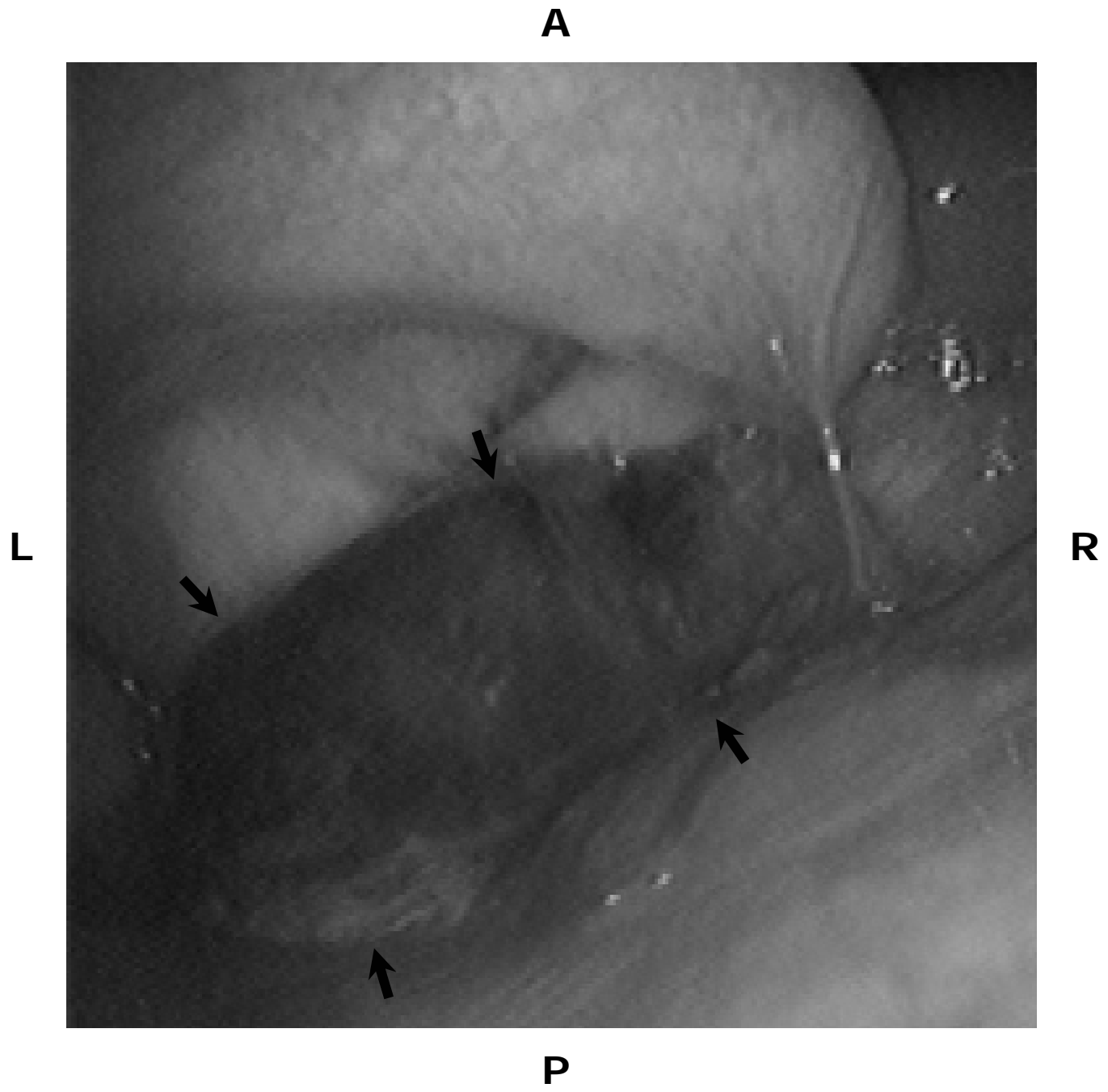


Fig. 1

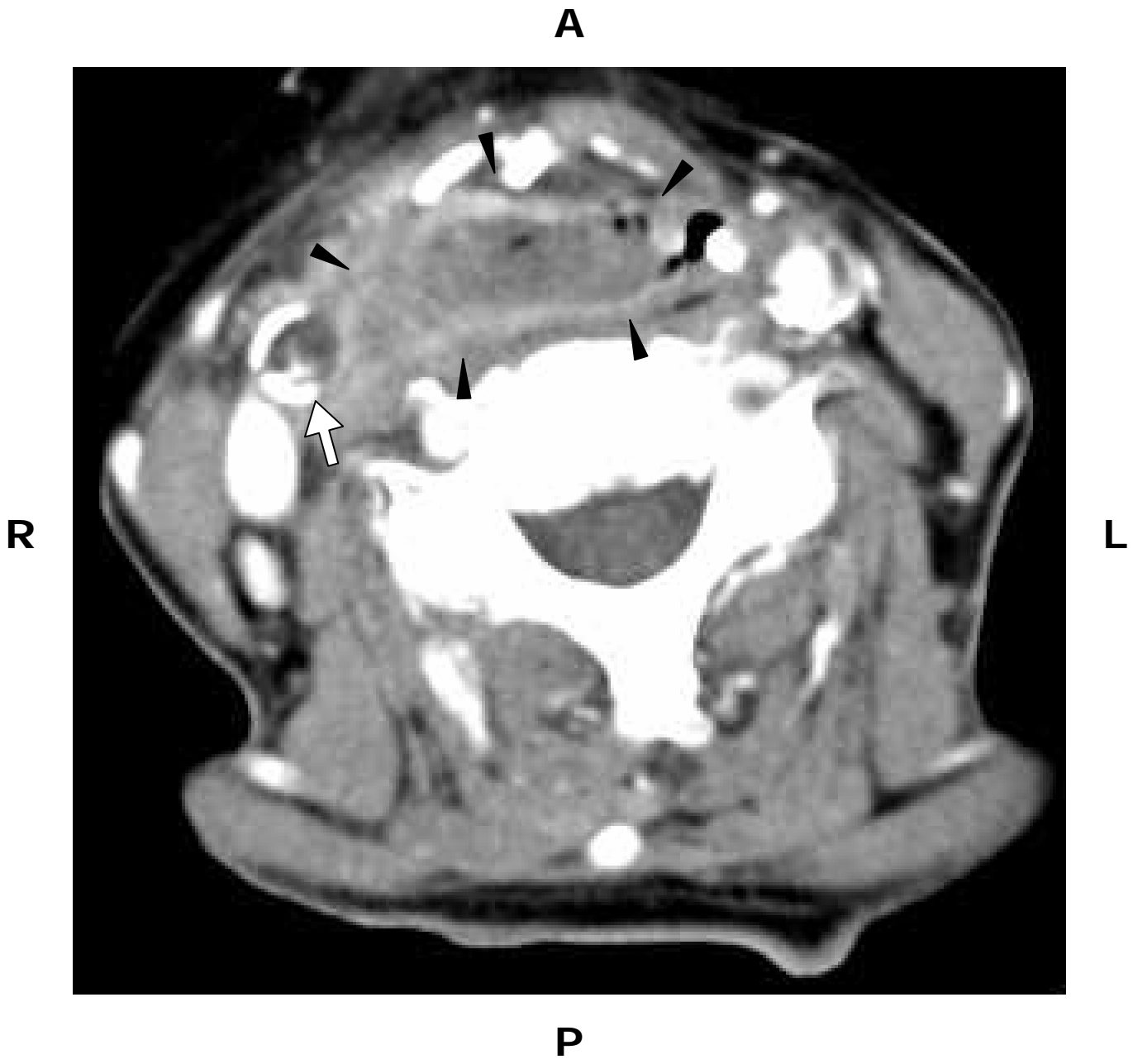


Fig. 2

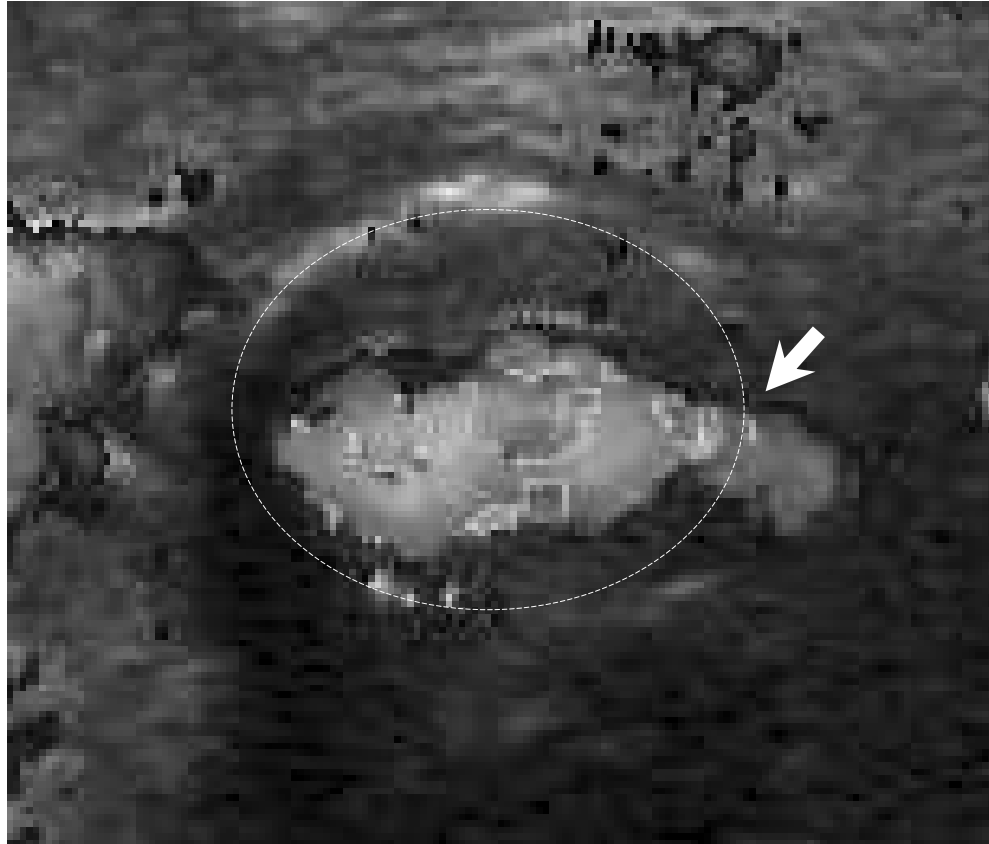

Fig. 3

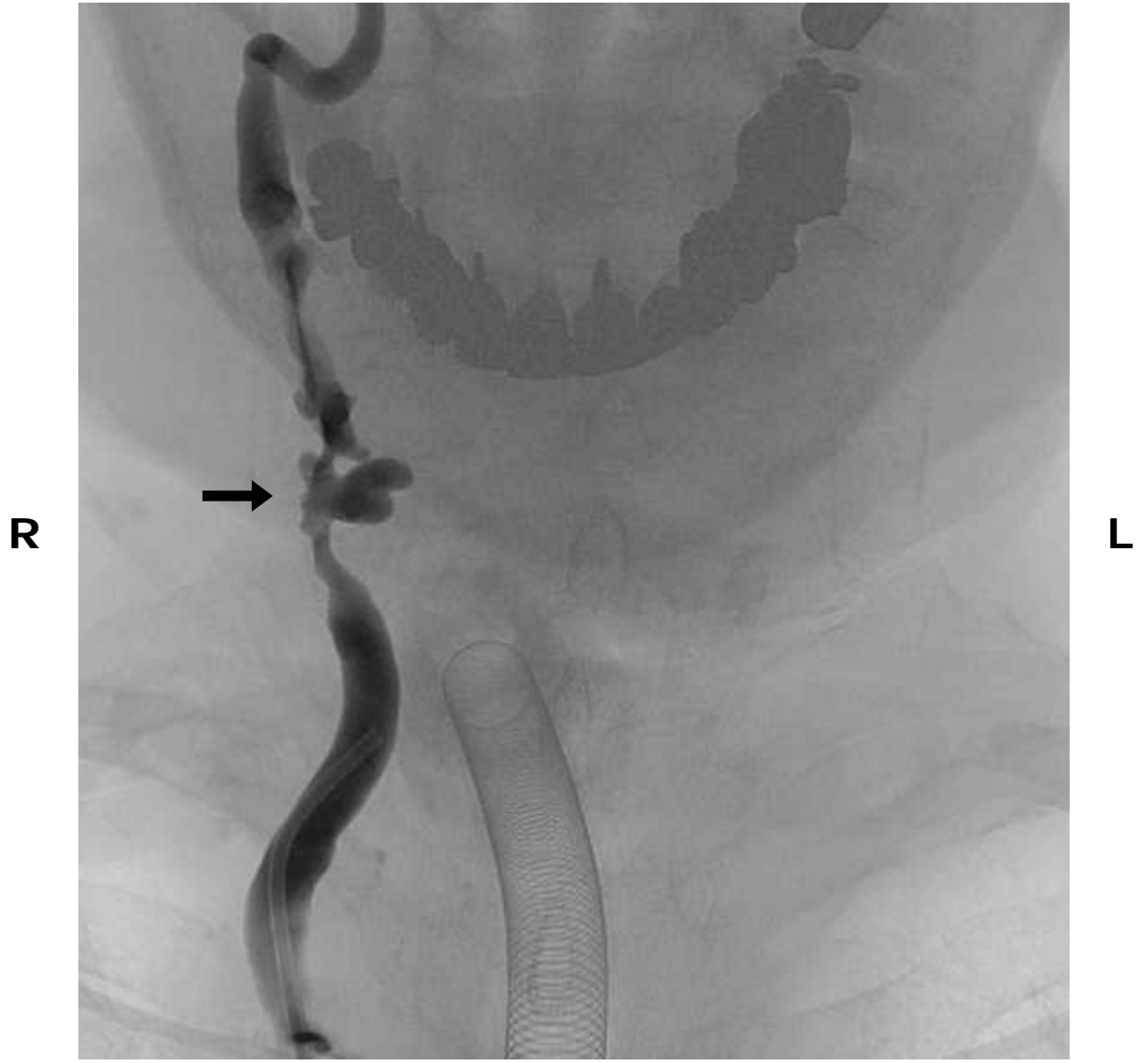
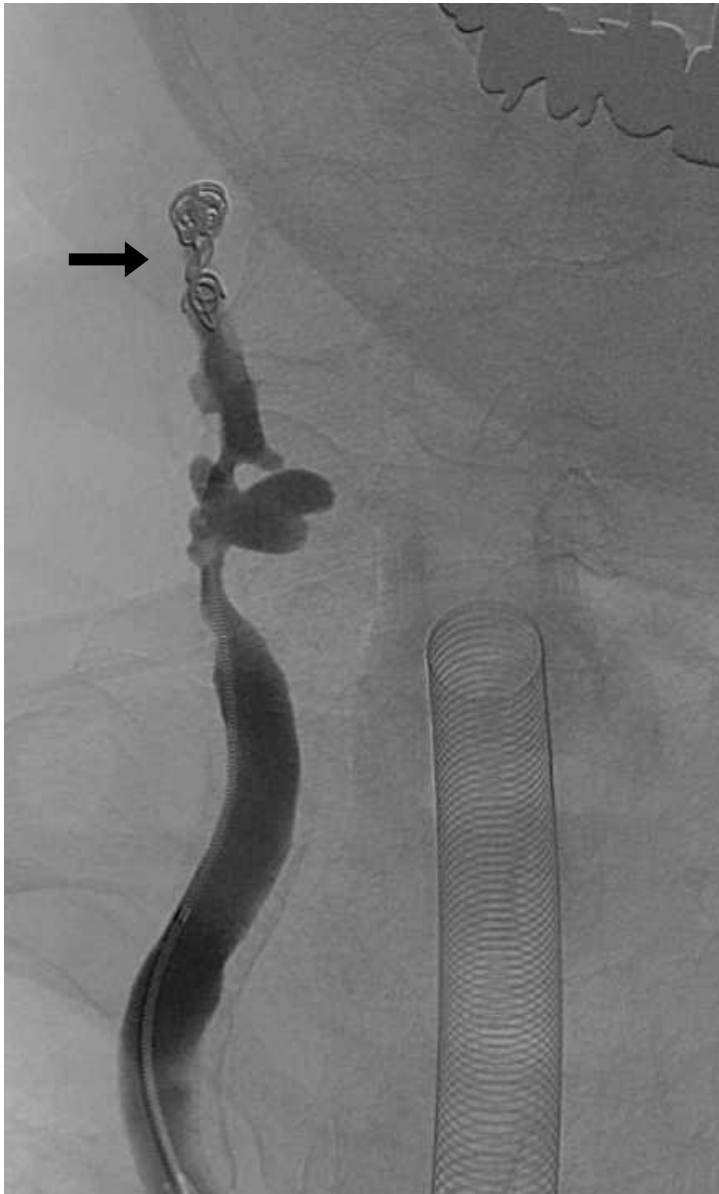
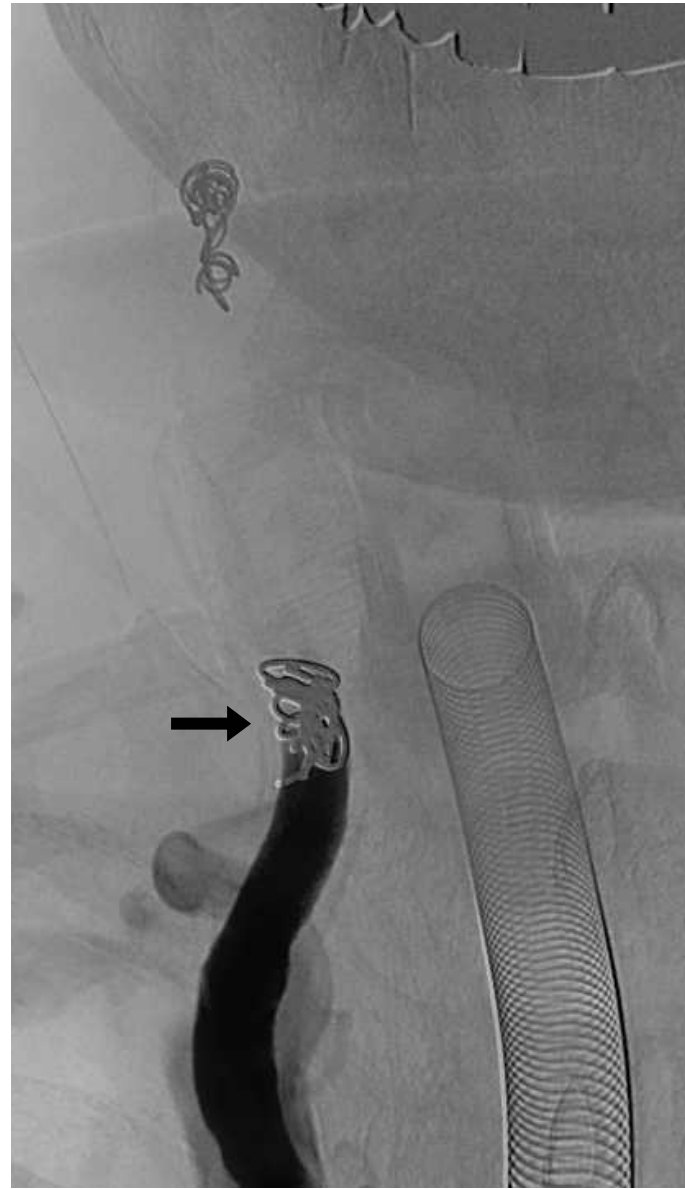


Fig. 4



(A)



(B)

Fig. 5