

Position of mandibular canal and ramus morphology before and after sagittal split ramus osteotomy

著者	Ueki Koichiro, Okabe Katsuhiko, Miyazaki Mao, Mukozawa Aya, Marukawa Kohei, Nakagawa Kiyomasa, Yamamoto Etsuhide
journal or publication title	Journal of Oral and Maxillofacial Surgery
volume	68
number	8
page range	1795-1801
year	2010-01-01
URL	http://hdl.handle.net/2297/25211

doi: 10.1016/j.joms.2009.07.106

Position of mandibular canal and ramus morphology before and after sagittal split ramus osteotomy

KOICHIRO UEKI, DDS, PhD,[#] KATSUHIKO OKABE, DDS,[§] MAO MIYAZAKI, DDS,[§] AYA MUKOZAWA, DDS,[§] KOHEI MARUKAWA, DDS, PhD, ¶ KIYOMASA NAKAGAWA, DDS, PhD,[†] and ETSUHIDE YAMAMOTO, DDS, PhD, ‡

Department of Oral and Maxillofacial Surgery, Graduate School of Medicine, Kanazawa University, 13-1 Takaramachi, Kanazawa 920-8641, Japan.

[#] Assistant Professor

[§] Graduate Student

¶ Clinical Instructor

[†] Associate Professor

[‡] Professor and Head

Address correspondence to: Koichiro Ueki, DDS, PhD.

Department of Oral and Maxillofacial Surgery, Graduate School of Medicine, Kanazawa University, 13-1 Takaramachi, Kanazawa 920-8641, Japan.

Tel: +81-76-265-2444; Fax: +81-76-234-4268

E-mail: kueki@med.kanazawa-u.ac.jp

Abstract

Purpose. The purpose of this study was to evaluate changes in the mandibular canal and ramus morphology before and after a sagittal split ramus osteotomy (SSRO).

Subjects and Methods. The subjects were 30 patients (60 sides) with mandibular prognathism who had undergone bilateral SSRO setback surgery. The mandibular canal position and ramus morphology were measured at the three horizontal planes under the mandibular foramen level (level A), 1cm lower (level B) of level A and 2cm lower (level C) of level A preoperatively and 1 year postoperatively by computed tomography (CT).

Results. Postoperative ramus width, lateral distance, lateral marrow distance and canal length were significantly larger than the pre-operative values, at the foramen, 1cm lower and 2 cm lower levels. The mandibular canal completely contacted the lateral cortex without lateral bone marrow in 6 sides (10%) in level A and B, and 4 sides (6.7%) in level C pre-operatively and 6 sides (10%) in level C post-operatively.

Conclusion. This study suggested that postoperative mandibular canal position was located more posteriorly and the postoperative lateral bone marrow became thicker compared to the pre-operative state.

Key words:

Sagittal split ramus osteotomy

Mandibular canal

Ramus morphology

Computed tomography

Introduction

Sagittal split ramus osteotomy (SSRO) is the most common surgical method for correcting jaw deformities. However, osteoperative hypoesthesia after mandibular orthognathic surgery is a known complication, caused by direct or indirect intraoperative damage to the inferior alveolar nerve.¹ The incidence of this postoperative trigeminal nerve hypoesthesia is reported to be highest among patients undergoing sagittal splitting ramus osteotomy (SSRO).² The induction of neural impairment is thought to be influenced by multiple causal factors, including fixation methods,³⁻⁵ patient's age,^{6, 7} postoperative swelling,⁸ and surgical procedures, particularly a bad split.^{9, 10}

With regards to the effect of a fixation method, Lemke at al.¹¹ reported that rigid fixation resulted in more anesthesia in the mental nerve distribution than wire fixation when tested with brush stroke direction. Fujioka at al.¹² also reported that mono-cortical osteosynthesis caused less damage to the inferior alveolar nerve. Some surgeons have suggested that compressive forces can occur when fixing the 2 mandibular segments together, resulting in the nerve being sandwiched. Takeuchi at al.¹³ reported that in SSRO setback cases, the distance between the mental foramen and the mandibular ramus always decreased, and that this change may cause trigeminal nerve hypoesthesia by compression of the nerve trunk due to posterior shifting of the proximal segments. There is evidence that wire fixation and mono-cortical fixation is less likely to cause direct trauma and has no risk of compressing the segments.¹¹ However, the results of our previous study suggested that mono-cortical or bi-cortical fixation methods did not influence the recovery period from hypoesthesia.¹⁴

Although it still unclear what factors affect the incidence of lower lip hypoesthesia after SSRO, it is very important to know the relationship between the mandibular bone and inferior alveolar canal to avoid direct damage to the inferior alveolar nerve preoperatively. The post-operative change in the location of the inferior mandibular canal and bone healing and regeneration is also important. There are some studies regarding the location of the mandibular canal in mandibular prognathism before SSRO, however no report has described any postoperative change in the relationship between the mandibular canal and

ramus morphology.

The purpose of this study was to evaluate the change in the mandibular canal and ramus morphology before and after sagittal split ramus osteotomy (SSRO).

Patients and Methods

Patients

The 30 Japanese adults (men: 4, women: 26) in this study presented with jaw deformities diagnosed as mandibular prognathism. At the time of orthognathic surgery, the patients ranged in age from 16 to 42 years, with a mean age of 25.8 years (standard deviation, 7.6 years). Informed consent was obtained from the patients and the study was approved by Kanazawa University Hospital. 26 of 30 patients were diagnosed as mandibular prognathism and the remaining 4 patients were diagnosed as mandibular prognathism with maxillary retrognathia.

Surgery

Of the 30 patients in this study, 26 underwent bilateral SSRO. The other 4 patients underwent SSRO and a Le Fort I osteotomy; rigid fixation was achieved with min-plates and monocortical screws. The plates were bent to prevent the proximal segments from rotating internally. Therefore the gap was created between the osteotomy surfaces on both sides (Fig.1).¹⁵ Elastic was placed to maintain the ideal occlusion without inter-maxillary fixation. The patients did not receive any physical therapy after surgery. All patients received orthodontic treatment before and after surgery.

CT measurement

CT was taken for all patients preoperatively and one year after surgery. The patients were placed in the gantry with the tragacanth line perpendicular to the ground for CT scanning.

They were instructed to breathe normally and to avoid swallowing during the scanning process. CT scans were obtained in the radiology department by skilled radiology technicians using a high-speed, advantage-type CT generator (Light Speed Plus; GE Healthcare, Milwaukee, WI, USA) with each sequence taken 1.25 mm apart for 3D reconstruction (120 kV, average 150 mA, 0.7 sec/rotation, helical pitch 0.75). The resulting images were stored in the attached workstation computer (Advantage workstation version 4.2; GE Healthcare, Milwaukee, WI, USA) and the 3D reconstruction was performed using the volume rendering method. ExaVision LITE version 1.10 medical imaging software (Ziosoft, Inc, Tokyo, Japan) was used for 3D morphologic measurements.

The RL line was determined as the line between the most anterior points of the bilateral auricles. Multi planner reconstruction can be established with the software, so that the arbitrary plane can be moved parallel to the plane that the RL line was determined (Fig. 2). Three horizontal planes at the mandibular foramen level (Level A)(Fig. 3), a 1 cm level under the mandibular foramen (Level B)(Fig. 4) and a 2 cm level under the mandibular foramen (Level C)(Fig. 5) parallel to the FH plane was identified in the right and left sides, and ramus area was measured pre- and postoperatively and bilaterally as follows (Fig. 6).

- 1) Ramus length: the distance between the most anterior point and most posterior point of ramus.
- 2) Ramus width: the distance between the most medial point and the cross point between the lateral outline of the ramus and the line through the most medial point parallel to the RL line.
- 3) Anterior length: the distance between the most anterior point of the ramus and the most anterior point of the mandibular canal.
- 4) Posterior length: the distance between the most posterior point of the ramus and the most posterior point of the mandibular canal.
- 5) Medial distance: the distance between the most medial point of the mandibular canal and the medial outline of the ramus on the parallel line to the RL line.
- 6) Lateral distance: the distance between the most lateral point of the mandibular canal and

the lateral outline of the ramus on the parallel to the RL line.

7) Medial marrow distance: the distance between the most medial point on the outer cortex of the mandibular canal and the most lateral point of the medial cortex of the ramus on the parallel line to the RL line.

8) Lateral marrow distance: the distance between the most lateral point on the outer cortex of the mandibular canal and the most medial point of the lateral cortex of the ramus on the parallel line to the RL line.

9) Canal length: the antero-posterior length of the mandibular canal

10) Canal width: the medio-lateral length of the mandibular canal

All CT images were measured by an author (K.U.). Fifteen patients were selected calculated using Dahlberg's formula¹⁶:

$$ME = \sqrt{\frac{\sum d^2}{2n}}$$

where d is the difference between 2 registrations of a pair, and n is the number of double registrations. The random errors did not exceed 0.21 mm for the linear measurements.

Statistical analysis

Data were statistically analyzed with StatView software, version 4.5 (ABACUS Concepts, Inc., Berkeley, CA, USA) and Dr. SPSSII (SPSS Japan Inc., Tokyo, Japan). The statistical significance of a difference between pre- and postoperative values was analyzed by paired t-test. The statistical significance of differences among three levels was analyzed by Bonferroni/Dunn (Dunn's procedure as a multiple comparison procedure) test.

Results

No patient had post-surgical wound infection or dehiscence, bone instability or non-union, or long-term malocclusion. The mean setback amount was 6.5 ± 3.2 mm on the

right side and 6.7 ± 3.2 mm on the left side. These differences were not significant.

Comparison among three levels

Preoperative ramus width in the lowest level (level C) significantly showed the largest value than those in the upper levels (level A versus B; $P=0.0001$, level B versus C; $P=0.0106$, level A versus C; $P<0.0001$). Preoperative anterior length in level A was a significantly larger value than that in level B ($P<0.0001$), however preoperative posterior length in Level A was significantly smaller value than that in level B ($P<0.0001$) and C ($P<0.0001$). Preoperative medial distance in the lowest level (level C) was the largest value than those in the upper levels (level A versus B; $P<0.0001$, level B versus C; $P=0.0072$, level A versus C; $P<0.0001$). Preoperative lateral distance in the lowest level (level C) was significantly larger value than that in the upper level A ($P=0.0003$) and level B ($P<0.0001$). Preoperative medial marrow distance in level A was significantly smaller value than that in level B ($P<0.0001$) and level C ($P=0.0001$). With regard to lateral marrow distance, canal length and canal width, there were no significant differences among the three levels.

Postoperative ramus width in the lowest level (level C) was the largest value compared to those in the upper levels (level A versus B; $P=0.0076$, level A versus C; $P=0.0006$). Postoperative anterior length in level A was significantly larger value than that in level B ($P<0.0001$), however postoperative posterior length in Level A was significantly smaller value than that in levels B ($P<0.0001$) and C ($P<0.0001$). In postoperative lateral distance, there were no significant differences among the three levels. Postoperative medial marrow distance in level A was significantly smaller value than that in level B ($P=0.0091$) and level C ($P=0.0009$). Postoperative lateral marrow distance in level B was significantly larger value than that in level C ($P=0.0101$). In postoperative canal length, there was no significant difference among the three levels. Postoperative canal width in level C was significantly smaller than that in level A ($P<0.0001$) and Level B ($P=0.0079$).

Comparisons between pre and post-operative findings

Postoperative ramus length was significantly smaller than the preoperative one in level B ($P < 0.0001$). Postoperative ramus width was significantly larger than the preoperative value in levels A ($P < 0.0001$), B ($P < 0.0001$) and C ($P = 0.0005$). Postoperative anterior length was significantly larger than the preoperative value in level A ($P < 0.0001$). Postoperative posterior length was significantly smaller than the preoperative value in level A ($P < 0.0001$), B ($P < 0.0001$) and C ($P < 0.0001$). In medial distance, there were no significant differences in all the levels. Postoperative lateral distance was significantly larger than the preoperative value in levels A ($P < 0.0001$), B ($P < 0.0001$) and C ($P = 0.0001$). In medial marrow distance, there were no significant differences in all the levels. Postoperative lateral marrow distance was significantly larger than the preoperative value in levels A ($P < 0.0001$), B ($P < 0.0001$) and C ($P = 0.0064$). Postoperative canal length was larger than the preoperative value in levels A ($P = 0.0071$), B ($P = 0.0331$) and C ($P = 0.0122$). Postoperative canal width was larger than the preoperative value in level A ($P = 0.0001$) and B ($P = 0.0211$).

Six sides (10%) in levels A and B, and 4 sides (6.7%) in level C showed a lateral marrow distance of 0, pre-operatively. Six sides (10%) in level C showed a lateral marrow distance of 0, post-operatively.

Discussion

SSRO is one of the preferred orthognathic surgical procedures. The disadvantages associated with this procedure, such as causing alveolar nerve damage during the operation, are generally understood and accepted. However, it was difficult to determine how much these factors were related to hypoesthesia of the lower lip after SSRO.

With the use of CT, the cross-sectional area has been used frequently as a parameter of ramus and the mandibular canal.¹⁷ Our previous study using horizontal images of CT

showed that the distance between the mandibular canal and the split surface correlated with TSEP latency recovery.¹⁸ In a previous study¹⁹, the sagittal split area in the Obwegeser-Dal Pont group was more prominently displayed than that in the Obwegeser group, and the distance between the plate (the most medial positioned screw) and the mental foramen in the Obwegeser-Dal Pont group was more prominently displayed than that in the Obwegeser group. Both the sagittal split area of osteotomy and the distance between the plate (the most medial point of screw) and the mental foramen were strongly associated with the recovery period of lower lip hypoesthesia. However, based on the results of our statistical analysis, the recovery period of lower lip hypoesthesia was affected by the distance between the plate screw and the mental foramen more strongly than the sagittal split area.¹⁸

Anyway, special attention should be given to the exact location of the mandibular canal. The anatomic features (i.e., the width and thickness) of the ascending rami as well as the relationship between the positions of the canals have been studied earlier.^{20,21} In the case of thin ramus, the sagittal splitting technique involves a risk for a bad split or neurologic injury. It has also been shown, however, that vascular and nerve bundles may be extremely close to the buccal cortex of the mandible in both broad and thick ramus. In the study by Tamas et al.,²¹ this was observed in only 6 % (10/164) of the mandible. In the study by Ylikontiola et al.,²² the mandibular canal was in direct contact with the buccal cortex of the mandible in 7 % (3/40) of the mandibular sides. Yamamoto et al.²³ found that the mandibular canal came into contact with the external cortical bone in 10 out of 40 rami (25 %), however, that study did not clarify the entire course of the mandibular canal from the mandibular foramen to the mandibular body. Tsuji et al.¹⁷ found that 16 out of 70 rami (22.9%) had this contact or fusion type of mandibular canal, and in many cases, it was observed from the mandibular foramen to the mandibular angle. In this study, 6 sides (10%) in the mandibular foramen level and 1cm lower level, and 4 sides (6.7%) in the 2 cm lower level showed the contact between the lateral cortex and mandibular canal pre-operatively. However, 6 sides (10%) in the 2cm lower level showed a contact post-operatively. This suggested that the horizontal distance between the mandibular canal and lateral cortex in the mandibular foramen level was made by SSRO with the bent plate fixation.

In this study, postoperative decrease in ramus length in level B suggested that the absorption might occur by set back surgery. In contrast, ramus width in all the levels increased. This indicated that the space between the proximal and distal segments was filled with new bone. This fixation method could not induce the compressive force between the proximal and distal segment. Although the anterior length in level A was increased by set back of the distal segment, post-operative posterior length was significantly shorter than the pre-operative value in all levels. This suggested that the posterior portion of the ramus could be absorbed after one year. Epker²⁴ presented the short lingual osteotomy technique that limited the vertical cutting range to the area just posterior to the lingual to reduce post-operative relapse. Kim et al.²⁵ stated that applying the distal osteotomy following conventional SSRO could prevent post-operative relapse. The purpose of these methods was to reduce tension in the pterygomasseter sling in the posterior mandible after setback surgery. However, the results of this study suggest that natural resorption in the posterior part of the ramus also could enable dynamic stability even after conventional SSRO. However, when re-operation is necessary in the mandibular ramus, intra-oral vertical ramus osteotomy (IVRO) can not be selected because of post-operative changes such as shorter posterior length and posterior location of the mandibular canal.

Tsuji et al. suggested that a vertical cut of the buccal side of the mandible performed just anterior to the mandibular angle may be advantageous on the basis of the result that buccal thickness of the ramus in the mandibular angle level was larger than that in upper level. In this study, in both of pre-operative medial distance and lateral distance, values in the lower level were larger than those in the upper level. A similar tendency was shown in both the pre-operative medial marrow distance and lateral marrow distance. Pre-operative mean lateral distances in level B and C were 5.1 and 6.1 mm, and the respective post-operative values were 7.0 mm and 7.0 mm. Pre-operative lateral marrow distances in level B and C were 1.6 mm and 2.1 mm and the respective post-operative values were 3.6 mm and 2.7mm. Data obtained when vertical cut and internal fixation with plate system mono-cortically is performed in level B or C could be useful to determine the depth of the vertical cut and choosing the screw length. Even if the screw that is shorter than the lateral distance is

inserted into the buccal cortex beside the mandibular canal, direct damage to the inferior alveolar nerve can be avoided.

In both canal length and width, there were no differences among the three levels pre-operatively. But, a post-operative increase was found in canal length in all the levels and in canal width in levels A and B. Post-operative length and width might be due to position and angle changes in the distal segment. Furthermore, after the split line overlapped the inner line of the mandibular canal, the fixation was performed with the space between the proximal and distal segments. This might cause a spread in the canal width one year after surgery, although measurement errors should also be considered.

In conclusion, this study suggested that postoperative mandibular canal position was changed more posteriorly because the posterior distance of the ramus decreased post-operatively. Post-operative lateral bone marrow became thicker than the pre-operative one, due to bent plate fixation. Therefore, it was suggested that post-operative mandibular canal position was changed more medially.

References

1. Donoff RB, Colin WC: Complication, poor results, and treatment failures: Diagnosis, prevention, and management. *Oral Maxillofac Surg Clin North Am* 2:453, 1990
2. Coghlan KM, Irvine GH: Neurological damage after sagittal split osteotomy. *Int J Oral Maxillofac Surg* 15:369, 1986
3. Westermarck A, Bystedt H, Konow L: Inferior alveolar nerve function after mandibular osteotomies. *Br J Oral Maxillofac Surg* 36:425, 1998
4. Pratt CA, Tippet H, Barnard JD, Birnie DJ: Labial sensory function following sagittal split osteotomy. *Br J Oral Maxillofac Surg* 34:75, 1996
5. Lemke RR, Rugh JD, Van Sickels J, Bays RA, Clark GM. Neurosensory differences after wire and rigid fixation on patients with mandibular advancement. *J Oral Maxillofac Surg* 58:1354, 2000
6. Yikontiola L, Kinnunen J, Oikarinen K: Factors affecting neurosensory disturbance after mandibular bilateral sagittal split osteotomy. *J Oral Maxillofac Surg* 58:1234, 2000
7. Joseph EVS, John PH: Effects of age, amount of advancement, and genioplasty on neurosensory disturbance after a bilateral sagittal split osteotomy. *J Oral Maxillofac Surg* 60:1012, 2002
8. Jones DL, Wolford LM: Intraoperative recording of trigeminal evoked potentials during orthognathic surgery. *Int J Adult Orthod Orthognath Surg* 5:167, 1990
9. Brusati R, Fiamminghi L, Sesenna E, Gazzotti A: Functional disturbances of the inferior alveolar nerve after sagittal osteotomy of the mandibular ramus: operating technique for prevention. *J Maxillofac Surg* 9:123, 1998
10. August M, Marchena J, Cinady J, Kaban L: Neurosensory deficit and functional impairment after sagittal ramus osteotomy: a long-term follow-up study. *J Oral Maxillofac Surg* 56:1231, 1998

11. Lemke RR, Rugh JD, Van Sickels J, Bays RA, Clark GM: Neurosensory differenced after wire and rigid fixation in patients with mandibular advancement. *J Oral Maxillofac Surg* 58: 1354, 2000.
12. Fujioka M, Akiyoshi H, Fuji: Comparative study of inferior alveolar distribution restoration after sagittal split osteotomy by means of bicortical versus monocortical osteosynthesis. *Plast Reconstr Surg* 102: 37, 1998.
13. Takeuchi T, Furusawa K, Hirose I: Mechanism of transient mental nerve paraesthesia in sagittal split mandibular ramus osteotomy. *Br J Oral Maxillofac Surg* 32: 105, 1994.
14. Hashiba Y, Ueki K, Marukawa K, et al: comparison of lower lip hypoesthesia measured by trigeminal somatosensory-evoked potential between different types of mandibular osteotomies and fixation. *Oral Surg Oral Med Oral Pathol Oral Radiol Endod* 104: 17, 2007
15. Ueki K, Degerliyurt K, Hashinba Y, et al: Horizontal changes in the condylar head after sagittal split ramus osteotomy with bent plate fixation. *Oral Surg Oral Med Oral Pathol Oral Radiol Endod* 106: 656, 2008.
16. Dahlberg G: Statistical methods for medical and biological students. George Allen and Unwin, London, pp. 122-132. 1940.
17. Tsuji Y, Muto T, Kawakami J, Takeda S: Computed tomographic analysis of the position and course of the mandibular canal: relevance to the sagittal split ramus osteotomy. *Int J Oral Maxillofac Surg*. 34:243, 2005.
18. Hashiba Y, Ueki K, Marukawa K, et al: Matsubara K. Relationship between recovery period of lower lip hypoesthesia and sagittal split area or plate screw position after sagittal split ramus osteotomy. *Oral Surg Oral Med Oral Pathol Oral Radiol Endod* 105: 11, 2008.
19. Takazakura D, Ueki K, Nakagawa K, et al: A comparison of postoperative hypoesthesia between two types of sagittal split ramus osteotomy and intraoral vertical ramus osteotomy, using the trigeminal somatosensory-evoked potential method. *Int J Oral Maxillofac Surg* 36: 11, 2006.

20. Raveh J, Vuillemin T, Ladrach K, Sutter F: New techniques for reproduction of the condyle relation and reduction of complications after sagittal ramus split osteotomy of the mandible. *J Oral Maxillofac Surg* 46: 751, 1988.
21. Tamas F: Position of the mandibular canal. *Int J Oral Maxillofac Surg* 16: 65, 1987.
22. Ylikontiola L, Moberg K, Huuonen S, et al: Comparison of three radiographic methods used to locate the mandibular canal in the buccolingual direction before bilateral sagittal split osteotomy. *Oral Surg Oral Med Oral Pathol Oral Radiol Endod* 93: 736, 2008.
23. Yamamoto R, Nakamura A, Ohno K, Michi K: Relationship of the mandibular canal to the lateral cortex of the mandibular ramus as a factor in the development of neurosensory disturbance after bilateral sagittal split osteotomy. *J Oral Maxillofac Surg* 60: 490, 2002.
24. Epker BN: Modification in the sagittal osteotomy of the mandible. *J Oral Surg* 35: 157, 1997.
25. Kim MJ, Kim SG, Park YW: Positional stability following internal posterior osteotomy of the distal segment in bilateral sagittal split ramus osteotomy for correction of mandibular prognathism. *J Cranio-Maxillofac Surg* 30: 35, 2002.

Legends

Fig 1. Simulation of plate bending. The plates were bent to prevent the proximal segments from rotating internally. Note the gap between the osteotomy surfaces on both sides.

Fig 2. 3DCT image. Multi planner reconstruction can be established with the software, so that the arbitrary plane can be moved parallel to the plane that the RL line was determined.

Fig 3. Horizontal CT image at the mandibular foramen level (level A).

Fig 4. Horizontal CT image of the 1 cm level under the mandibular foramen (level B).

Fig 5. Horizontal CT image of the 2 cm level under the mandibular foramen (level C).

Fig 6. Measurement of ramus and mandibular canal. 1) Ramus length, 2) Ramus width, 3) Anterior length, 4) Posterior length, 5) Medial distance, 6) Lateral distance, 7) Medial marrow distance, 8) Lateral marrow distance, 9) Canal length: the antero-posterior length of mandibular canal, 10) Canal width

Table 1. Results of measurements. SD indicates standard deviation.

Same alphabet letters (a, b,...and s): significant difference between pre and post-operation at $P < 0.05$.

*: significant difference between levels at $P < 0.05$.

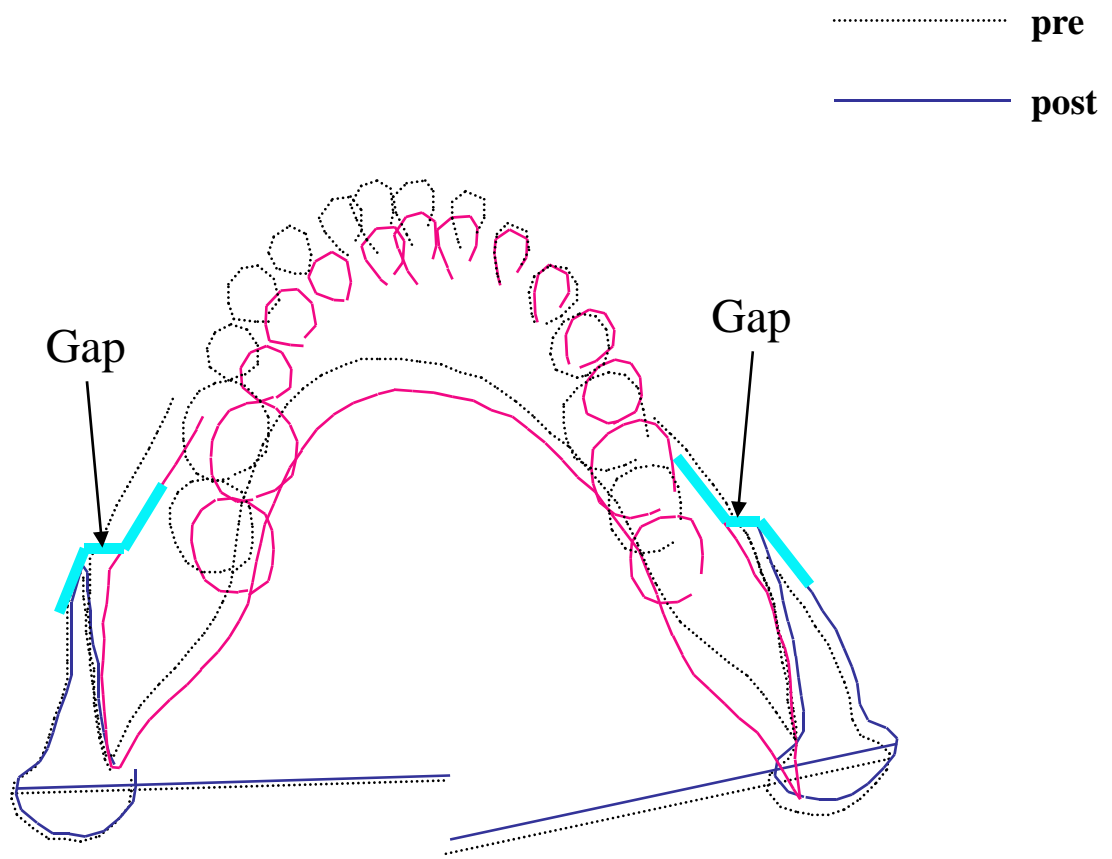


Fig.1

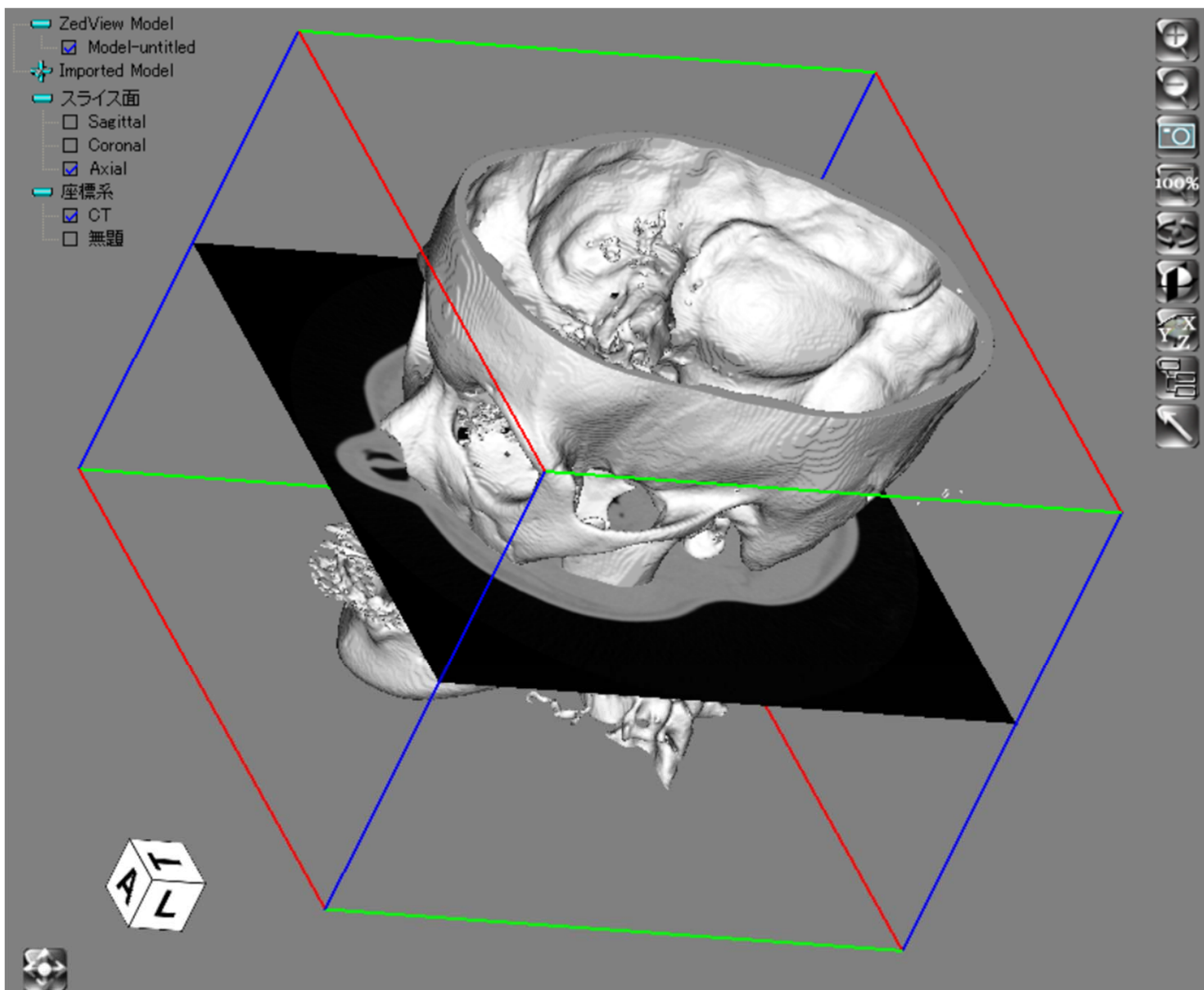


Fig.2

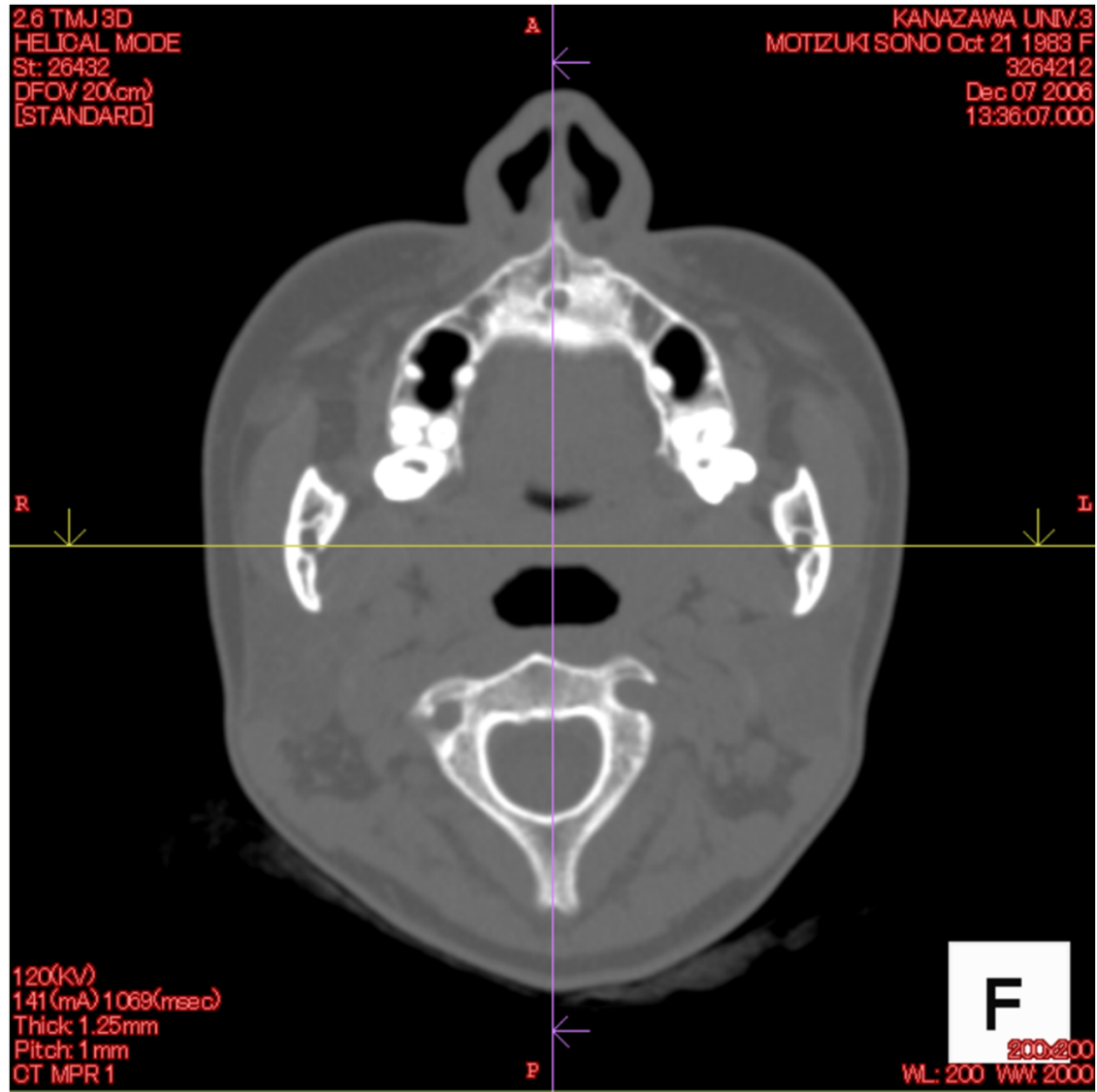


Fig.3

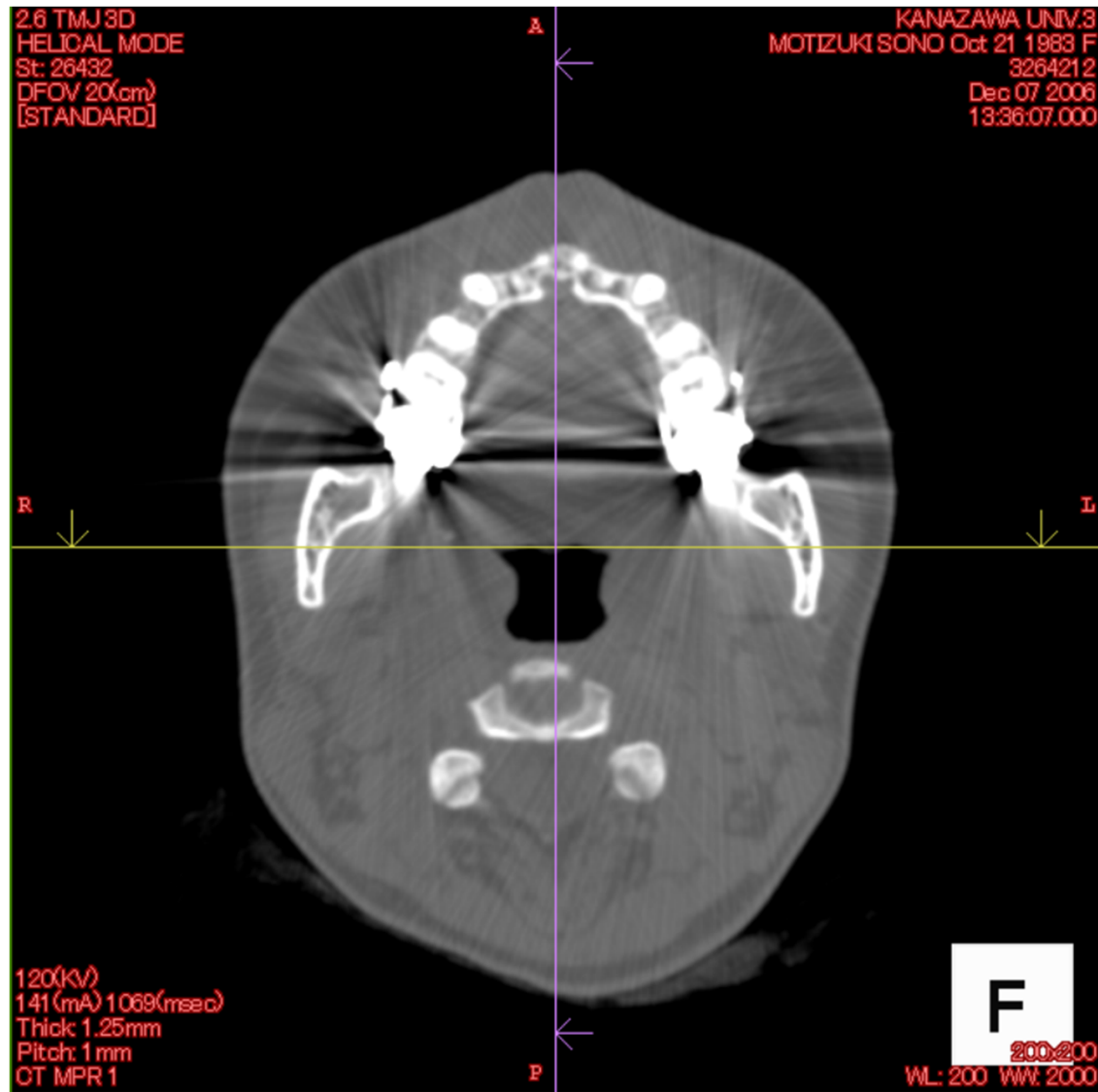


Fig.4

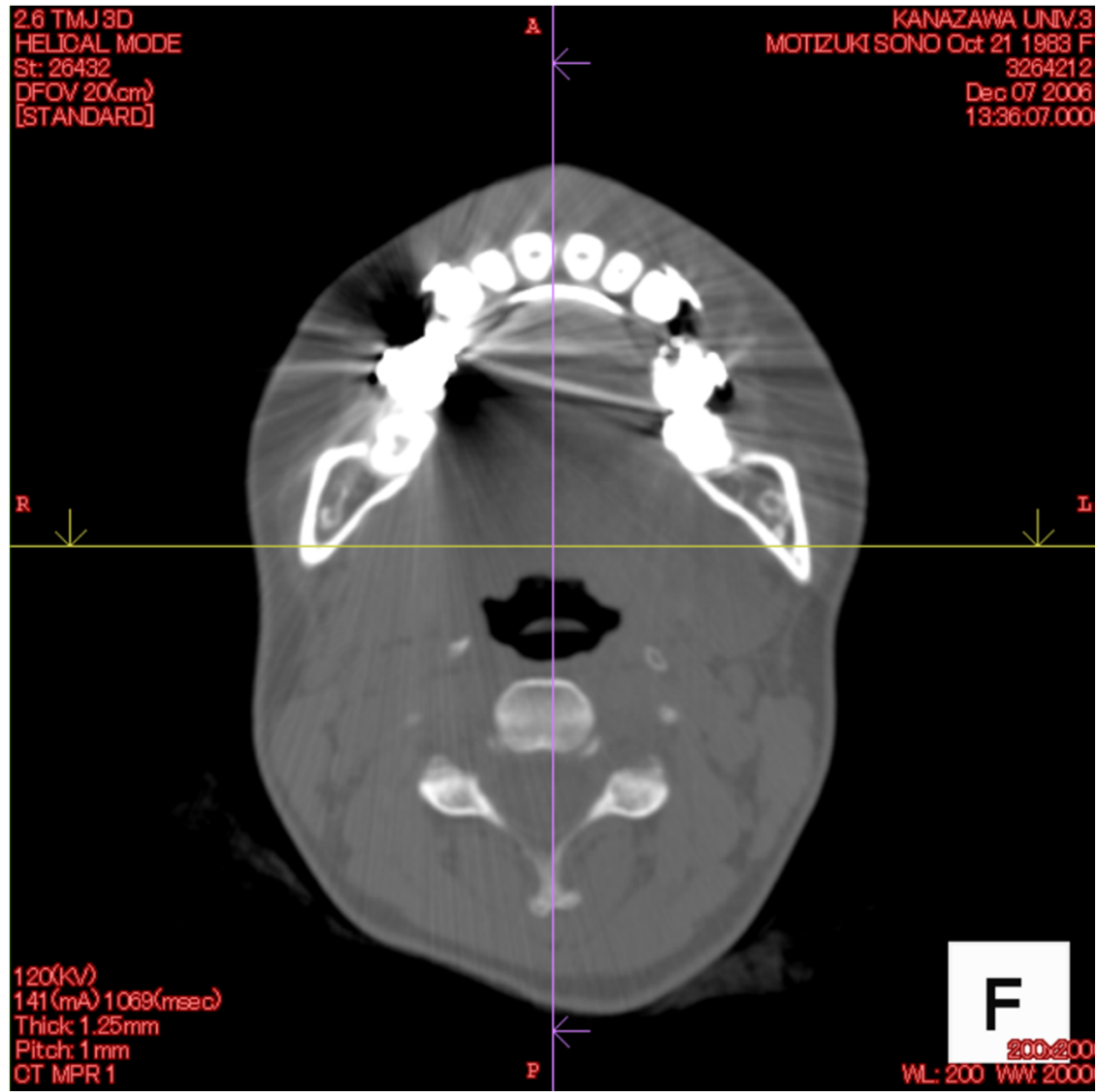


Fig.5

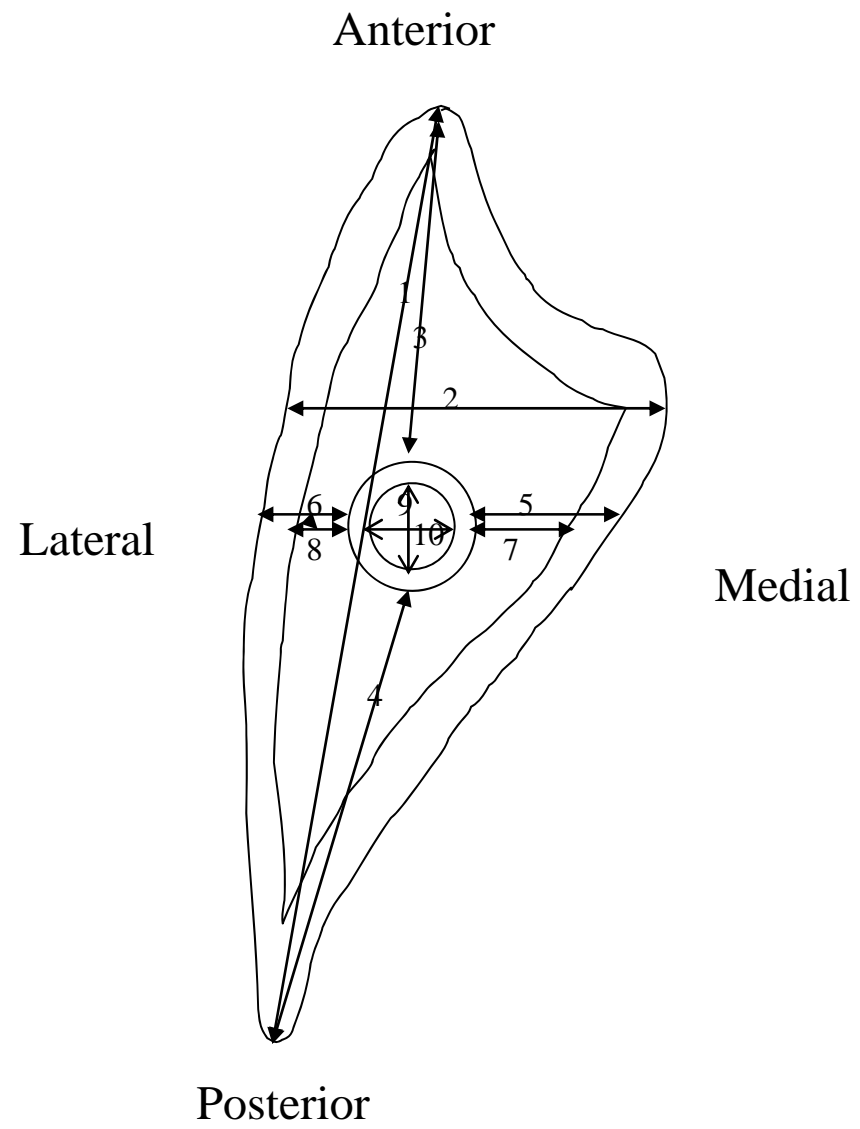


Fig.6

Pre-operation		Ramus length	Ramus width	Anterior length	Posterior length	Medial distance	Lateral distance	Medial marrow distance	Lateral marrow distance	Canal length	Canal width
Foramen level (Level A)	Mean	31.9	9.6 b	13.8 e	14.5 f	1.7	5.2 i	0.0	2.1 l	2.6 o	2.1 r
	SD	3.5	1.5								
1cm lower level (Level B)	Mean	32.9 a	10.6 c	11.7	18.7 g	2.9	5.1 j	0.6	1.6 m	2.5 p	2.0 s
	SD	4.2	2.3								
2cm lower level (Level C)	Mean		12.0 d		17.8 h	3.6	6.1 k	0.9	2.1 n	2.3 q	1.9
	SD		2.2								

Post-operation		Ramus length	Ramus width	Anterior length	Posterior length	Medial distance	Lateral distance	Medial marrow distance	Lateral marrow distance	Canal length	Canal width
Foramen level (Level A)	Mean	31.3	11.5 b	15.2 e	13.0 f	1.9	6.8 i	0.0	3.4 l	2.9 o	2.5 r
	SD	4.5	1.7								
1cm lower level (level B)	Mean	30.0 a	12.5 c	11.5	16.3 g	3.1	7.0 j	0.9	3.6 m	2.7 p	2.3 s
	SD	5.0	2.2								
2cm lower level (Level C)	Mean		12.8 d		14.9 h	3.4	7.0 k	1.1	2.7 n	2.5 q	1.8
	SD		2.2								

Table.1