

Improvement on detectability of early ischemic changes for acute stroke using nonenhanced computed tomography: Effect of matrix size

著者	Ogura Akio, Hayakawa Katsumi, Miyati Tosiaki, Maeda Fumie
journal or publication title	European Journal of Radiology
volume	76
number	2
page range	162-166
year	2010-01-01
URL	http://hdl.handle.net/2297/19222

doi: 10.1016/j.ejrad.2009.06.013

Improvement on detectability of early ischemic changes for acute stroke using of nonenhanced computed tomography - effect of matrix size-

Akio Ogura, MS^{1,2)}

Katsumi Hayakawa, MD¹⁾

Tosiaki Miyati, PhD²⁾

Fumie Maeda, RT¹⁾

1) Department of Radiology, Kyoto City Hospital

2) Graduate School of Medical Science, Kanazawa University

Corresponding Author: Akio Ogura

Department of Radiology, Kyoto City Hospital

1- 2, Higashitakada-cho, Mibu, Nakagyo-ku, Kyoto, JAPAN

TEL: +8175-311-5311(2183)

E-mail address: a-ogura@mbox.kyoto-inet.or.jp

Running Title: Improvement on detectability of early ischemic changes

The Abbreviated Title Page

Improvement on detectability of early ischemic changes for acute stroke using of nonenhanced computed tomography - effect of matrix size-

Abstract**Purpose:**

It has recently been reported that intravenous recombinant tissue plasminogen activator improves the clinical outcome after acute stroke. Computed tomography (CT) is the standard imaging method used to determine the indication for thrombolysis. However, detection of early ischemic change often results in an increase in local radiation exposure. Therefore, the effects of decreased matrix size and use of a noise reduction filter were evaluated.

Materials and Methods:

The low contrast resolution was compared for different matrix sizes and imaging filters using a contrast-detail phantom. In addition, early ischemic change in clinical images with matrix sizes of 256×256 and 128×128 processed using three imaging filters (Gaussian, smoothing, unsharp mask) from 11 patients within 3 h of stroke onset were evaluated by seven radiologists in a blind manner.

Results:

The use of images with a matrix size of 256×256 and processed with the Gaussian filter increased the detection of early signs of acute stroke.

Conclusions:

This study was performed to determine whether the converted matrix size and use of imaging filters could improve the detectability of early ischemic change on CT images in acute stroke. To reduce the dose of radiation exposure for patients, it was effective to use an optimal noise reduction filter and reasonable matrix size. In particular, changing the matrix size to 256×256 was the most effective for detection of early ischemic change in examinations using clinical images.

Key words: acute stroke, early ischemic change, matrix size, detectability

1. Introduction

Intravenous thrombolysis using recombinant tissue plasminogen activator (rt-PA) has recently been approved for acute stroke within 3 h of symptom onset.(1) Although this type of therapy has been shown to be effective if begun less than 3 h after onset, its effectiveness if begun more than 3 h after onset has not been established.(2)

In addition, early thrombolysis in acute stroke often results in dramatic symptom improvement, but there is a risk of serious complications, including cerebral hemorrhage.(3) Therefore, careful judgment regarding the appropriateness of treatment is very important. Some institutions use Magnetic Resonance Image (MRI) to determine whether individual cases should be treated by thrombolysis, but Computed Tomography (CT) examination is used in many cases to avoid serious complications related to the timing of rt-PA treatment. It has been reported that identification of early ischemic change reduces the incidence rate of serious complications and improves patient convalescence.(4–8) However, identification of early ischemic change is difficult, and diagnosis is difficult for less experienced operators.(9–10) Diagnosis of early ischemic change requires a high signal-to-noise ratio to detect reduced contrast and loss of precise delineation of the gray–white interface in the margins. The simplest method is to use a low speed scan per rotation with a slice thickness of 8–10 mm and high tube current. However, these imaging techniques are unavoidably associated with exposure of the patient to high levels of radiation. In particular after a recent paper reporting an estimated risk of radiation induced malignancy from brain CT of up to 0.04%. (11)

Therefore, the present study was performed to investigate the effects of decreased matrix size and addition of noise reduction filters to improve the detectability of early ischemic change.

2. Materials and Methods

In this study, physical evaluation using a phantom and clinical evaluation using clinical images were performed. The institutional review board

approved the study design and review of patient records and images. The device used was ProSeed-SA helical CT scanner (General Electric Co.).

2-1. Phantom image evaluation

A contrast-detail phantom (CD-phantom) was used for evaluation of low contrast resolution measurement. The contrast-detail phantom was constructed for the project. The CD-phantom consisted of an acrylic board with holes 10, 9, 7, 5, 4, 3.5, 3, 2.5, 2, 1, 1.5, and 1 mm in diameter and 10, 9, 8, 7, 6, 5, 4, 3, 2, 1, and 0.5 mm in depth. The CD-phantom is shown in Figure 1.

First, scanning parameters were set at a peak kilovoltage (kVp) of 120 with a section thickness of 10 mm, and the tube current was set to 200, 160, 100, or 60 mA. The slice position was the center of the phantom, and the non-helical scanning was used in this experiment.

Next, scanning parameters were set at 120 kVp and 100 mA, and section thickness was set to 10, 5, 3, or 1 mm. In this case, the slice position was 1/2 of the section thickness from the side of the open holes for the phantom shown in Figure 2.

Gaussian, smoothing, and unsharp mask image filters were applied to the CD-phantom image with 120 kVp, 100mA and a section thickness of 10 mm using imageJ (image processing software - <http://rsb.info.nih.gov/ij/>). Gaussian filters was used a radius parameter=2. Unsharp masking filter was used of the Gaussian radius=2 and mask weight=0.6 for the amount of sharpening effect that is produced. These images were saved as new images after processing. In addition, images in which the matrix size was converted to 256×256 or 128×128 using imageJ were also saved. For these images, the limited visible size and depth of hole for the CD phantom were evaluated by five observers.

2-2. Clinical image evaluation

The visibility and detectability of early CT signs were evaluated for CT images of 11 patients (4 women, 7 men; mean age, 64 years; range, 53–75

years) in whom CT was performed within 3 h of symptom onset and diffusion weighted MRI confirmed an ischemic lesion. The scanning parameters of all images were set at 120 kVp and 200 mA, and section thickness was set to 5 mm. The convolution kernel used in the reconstruction process is standard. We used images in which the matrix size was converted to 256×256 or 128×128 processed with three image filters (Gaussian, smoothing, unsharp mask) using imageJ. Gaussian filters was used a radius parameter=2. Unsharp masking filter was used of the Gaussian radius=2 and mask weight=0.6. One series of processed images is shown in Figure 3.

A total of 66 images from the 11 patients processed in 6 ways (original, 256×256, 128×128, Gaussian, smoothing, unsharp mask) were shown on a monitor at random and evaluated by 7 radiologists. The evaluation method was as follows:

1. First, indicate the position that you think shows ischemic stroke.
2. Second, indicate degree of conviction for the decision on a six-point scale.

The evaluation standard is shown in Table 1. As last count, we marked false positions selected by the observers with “0.” Observers were blinded to the processing techniques, results of MRI study, and other information, such as the patients’ symptoms or histories. Observation time was not set and the observer was allowed to freely adjust the window width and window level on the monitor. In addition, images were presented to each observer at random.

3. Results

3-1. Phantom image evaluation

A contrast-detail diagram (CD-diagram) with changes in tube current is shown in Figure 4. Image of decrease a tube current was necessary to detect more deep depth and large hole size for the CD phantom. This was regarded as due to the influence of quantum mottle.

Figure 5 shows a CD-diagram with changes in section thickness.

Detectability improved with thinner sections, which was thought to be due to the partial volume effect.

Detectability of CD-diagrams improved with application of the smoothing and Gaussian imaging filters, but deteriorated as compared to the original image in those processed using the unsharp mask filter.(Figure 6)

Detectability improved by changing the matrix size to 256×256 for original images with a matrix size of 512×512 , but deteriorated when the matrix size was changed to 128×128 .(Figure 7)

The greatest improvement in signal detectability was seen with a matrix size of 256×256 and application of “Gaussian and smoothing.” (Figure 8)

3-2. Clinical image evaluation

Figure 9 shows the average detectability for early CT signs of clinical images by the seven radiologists. The highest of degree of correct answer conviction was for the images in which the matrix size had been converted to 256×256 . Detectability was significantly greater for these processed images in comparison with the original images by Wilcoxon’s signed rank test ($P < 0.05$). However, there was no significant difference for images with a converted matrix size of 128×128 and addition of all three image filters.

4. Discussion

The present study was performed to examine whether the converted matrix size and application of image filters could improve the detectability of early ischemic change on CT images in cases of acute ischemic stroke. It was thought that high spatial resolution was not necessary but good contrast resolution was required to detect early CT signs. Therefore, we reviewed methods of improving low contrast resolution using a contrast-detail phantom. Improvement of noise characteristics leads to improvement of low contrast detectability. It was effective to increase the tube current and scanning time as shown in Figure 4, but the radiation dose was also increased. Increased section thickness led to improvement in the quantum mottle effect, but increasing the section thickness made it more difficult to

detect early signs and contrast was reduced by the partial volume effect, as shown in Figure 5.

Detectability using the CD-diagram improved when smoothing and Gaussian filters were applied to the images. In contrast, detectability was reduced when the unsharp mask was applied to the images.(Figure 6) In addition, decreasing the matrix size led to improvements in noise characteristics due to the increased area of one pixel, but spatial resolution was also reduced.

Detectability improved in images with a matrix size of 256×256 as shown in Figure 7, but did not improve with a matrix size of 128×128 due to the reduced spatial resolution. Therefore, the matrix size should be chosen appropriate for the purpose of each study. The most effective image processing procedure was to change the matrix size to 256×256 , as shown in Figure 8.

Similar results were obtained with clinical images. The best detection rates of early CT signs on clinical images by the seven radiologists were observed with a matrix size of 256×256 . The detectability increased with the addition of smoothing and Gaussian filter, but the differences were not significant. These image processing techniques shades off an original image and are effective in improving the noise characteristics. In contrast, unsharp mask processing increases image sharpness, with deterioration of noise characteristics, and detectability became poorer than for the original image.

On MRI, the operator always scans with an adequate matrix size for the purposes of a given examination. Thus, the operator can coordinate the noise characteristics and spatial resolution for diagnosis purposes. However, it is currently impossible for the CT operator to change the matrix size. The results of the present study predict that it will be possible to increase the detectability for diagnosis if future developments allow the selection of an appropriate matrix size at back projection. In general, a 50% reduction in matrix size is expected to be accompanied by a fourfold increase in signal-to-noise ratio (SNR). This improvement leads to low contrast

resolution and reduced patient radiation exposure dose. Therefore, it will be necessary to develop software to allow the CT operator to choose the matrix size for a given scan.

5. Conclusions

For detection of early ischemic change, it was necessary to increase contrast resolution but high spatial resolution was not necessary. Application of an optimal image filter and use of a reasonable matrix size were effective to reduce patient radiation exposure dose. In the present study using clinical images, changing the matrix size to 256×256 was the most effective for detection of early ischemic change.

The use of thrombolysis treatment by rt-PA for treatment of acute stroke is predicted to increase in the near future. Therefore, the image processing methods described here should be implemented in CT scanning as soon as possible to facilitate treatment judgment.

References

1. The National Institute of Neurological Disorders and Stroke rt-PA Stroke Study Group. Tissue plasminogen activator for acute ischemic stroke. *N Engl J Med* 1995; 333; 1581-1587
2. Hecke W, Kaste M, Fieschi c, et al: Safety and efficacy of intravenous thrombolysis with a recombinant tissue plasminogen activator in the treatment of acute ischemic stroke. *JAMA* .274, 1017-1025, 1995.
3. The National Institute of Neurological Disorders and Stroke rt-PA Stroke Study Group. Intracerebral hemorrhage after intravenous t-PA therapy for ischemic stroke. *Stroke*.28, 2109-2118, 1997.
4. Adams HP, Adams RJ, Brott T, et al: Guidelines for the early management of patients with ischemic stroke. *Stroke*2003;34,1056-1083.
5. Barber PA, Demchuk AM, Zhang J, et al: Validity and reliability of a quantitative computed tomography score in predicting outcome of

- hyperacute stroke before thrombolytic therapy. *Lancet*.355, 1670-1674, 2000.
6. Schellinger PD, Chalela JA, Kang DW, et al: Diagnostic and prognostic value of early MR imaging vessel signs in hyperacute stroke patients imaged <3 hours and treated with recombinant tissue plasminogen activator, *AJNR*26, 618-624, 2005.
 7. Aronovich BD, Reider GI, Segev Y, et al: Early CT changes and outcome of ischemic stroke, *European Journal of Neurology*(11), 63-65, 2004.
 8. Bernd FT, Ernst K, Rene H, et al: Comprehensive imaging of ischemic stroke with multisection CT. *Radiographics*, 23, 565-592, 2003.
 9. Wardlaw JM, Mielke O: Early signs of brain infarction at CT: observer reliability and outcome after thrombolytic treatment-systematic review. *Radiology*(235), 444-453, 2005.
 10. von Kummer R: Effect of training in reading CT scans on patient selection for ECASS II. *Neurology* (51), S50-52, 1998
 11. Brenner DJ, Hall EJ, et al: Computed tomography – an increasing source of radiation exposure. *N Engl J Med*(357),2277-2284, 2007.

Figure legend

Fig. 1 Contrast-detail phantom (CD-phantom) image for evaluation of low contrast resolution. The CD-phantom consisted of an acrylic board with holes 10, 9, 7, 5, 4, 3.5, 3, 2.5, 2, 1, 1.5, and 1 mm in diameter and 10, 9, 8, 7, 6, 5, 4, 3, 2, 1, and 0.5 mm in depth.

Fig. 2 Positions of slices for CD-phantom with thickness of 10, 5, 3, and 1 mm. The slice position was at 1/2 of the section thickness from the side of the open holes for the phantom.

Fig. 3 The image matrix size was converted to 256×256 or 128×128 and three imaging filters were applied (Gaussian, smoothing, unsharp mask) using imageJ for CT within 3 h of stroke onset. In addition, an image of DWI on MRI within 8 h of stroke onset in the same patient is also shown.

Fig. 4 Contrast-detail diagrams (CD-diagrams) with tube current of 200, 160, 100, or 60 mA. It was necessary to decrease the tube current to detect deeper depths and larger holes.

Fig. 5 CD-diagrams with section thicknesses of 1, 3, 5, and 10 mm. Detectability improved with thinner section thickness, which was thought to be due to the partial volume effect.

Fig. 6 CD-diagrams with addition of imaging filters. Smoothing and Gaussian imaging filters showed improved results, but the results with the unsharp mask filter were inferior to those with the original images.

Fig. 7 CD-diagrams with changes in matrix size. Detectability improved by changing the matrix size to 256×256 for an original image matrix of 512×512 , but deteriorated with a change in matrix size to 128×128 .

Fig. 8 CD-diagrams with changes in matrix size and addition of imaging filters. The result greatest improvement in signal detectability was observed with a change in matrix size to 256×256 .

Fig. 9 Average detectability of early CT signs on clinical images by seven radiologists. The highest degree of correct answer conviction was for images with a matrix size of 256×256 . No significant difference was seen for the matrix size of 128×128 and addition of all imaging filters.




Fig.1

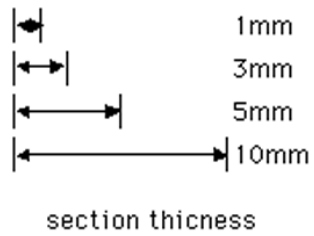



Fig.2

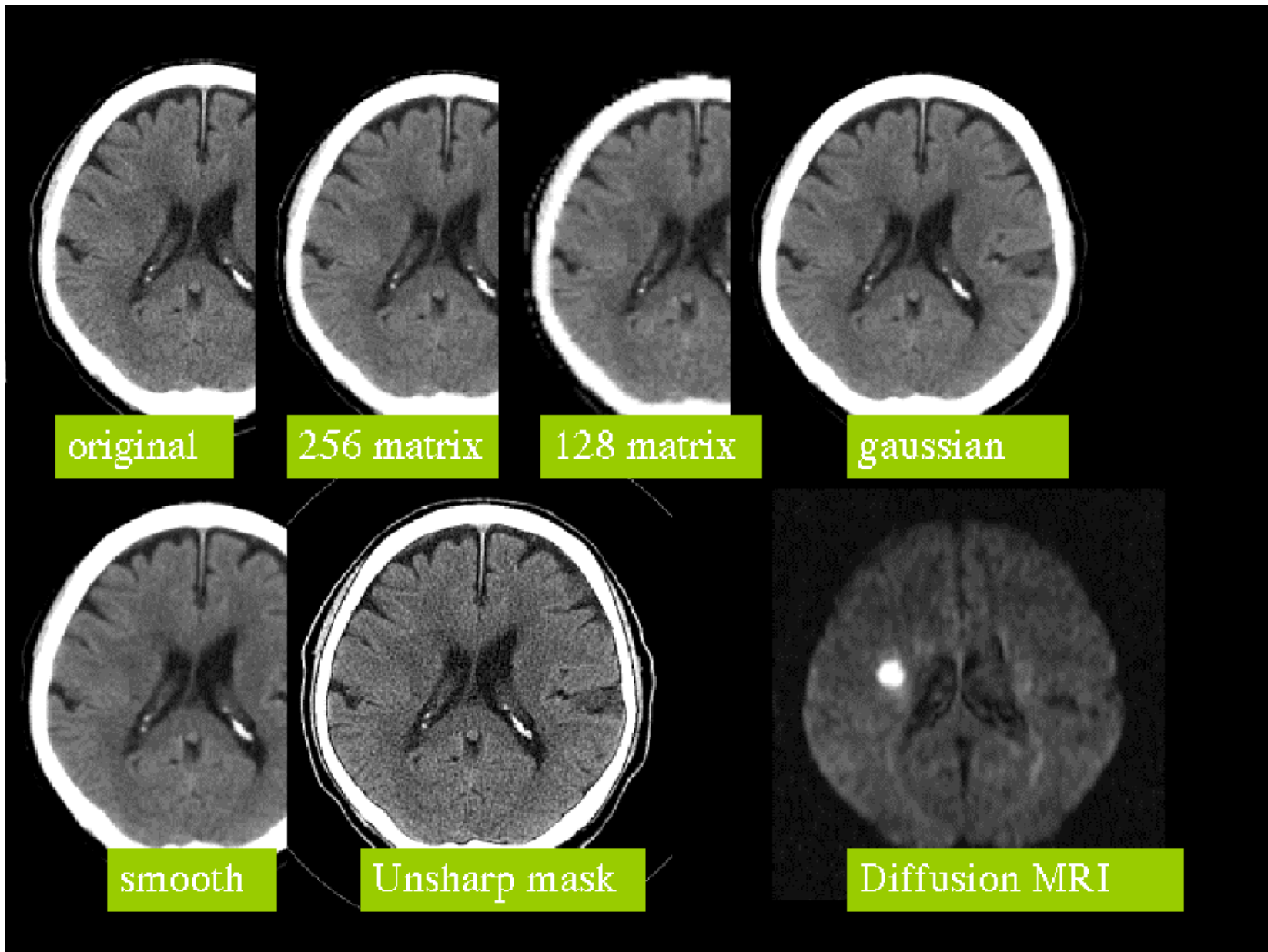


Fig.3

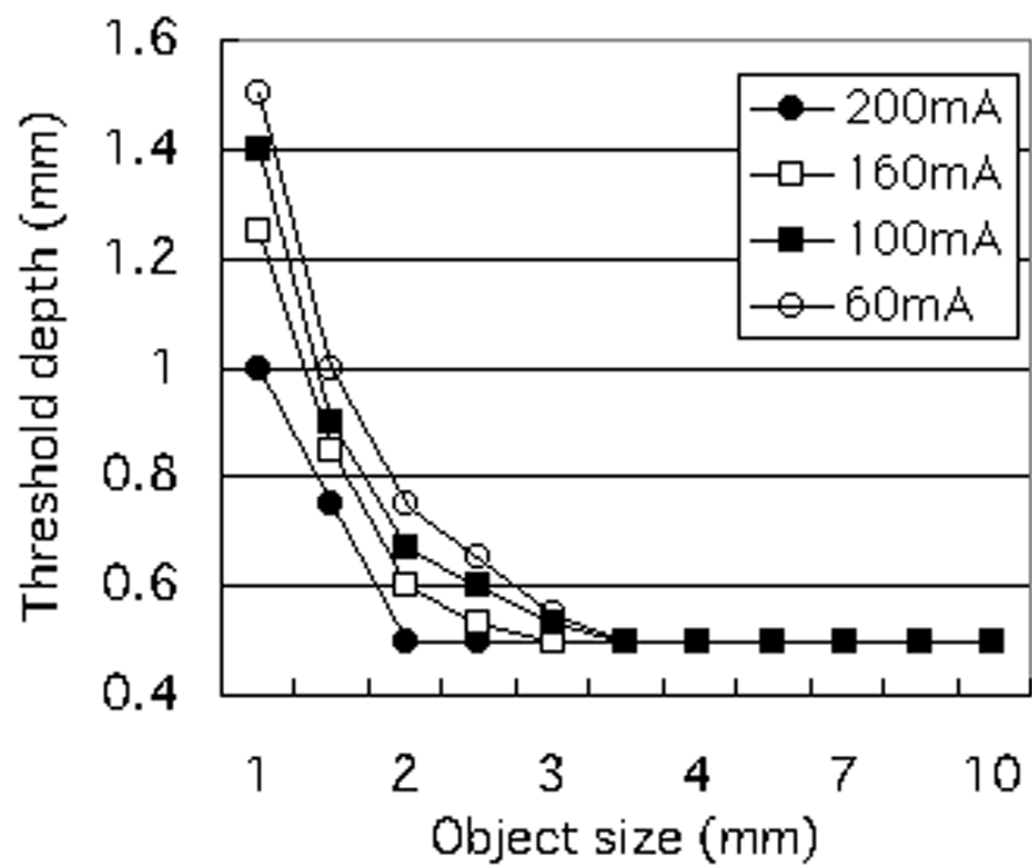


Fig.4

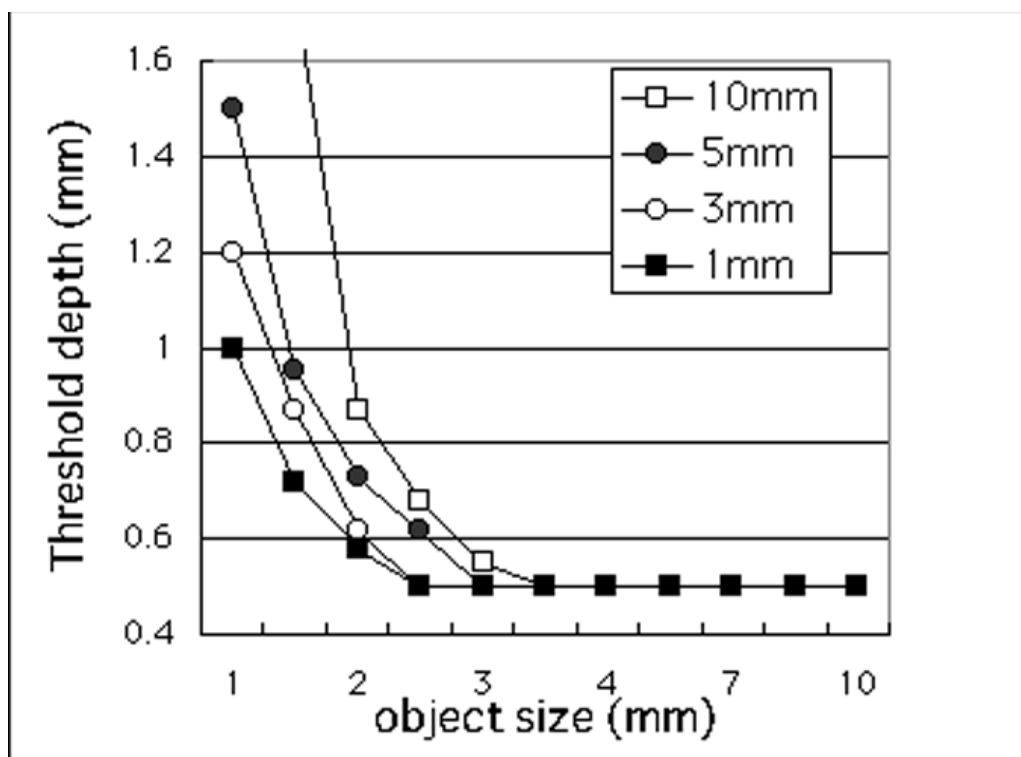


Fig.5

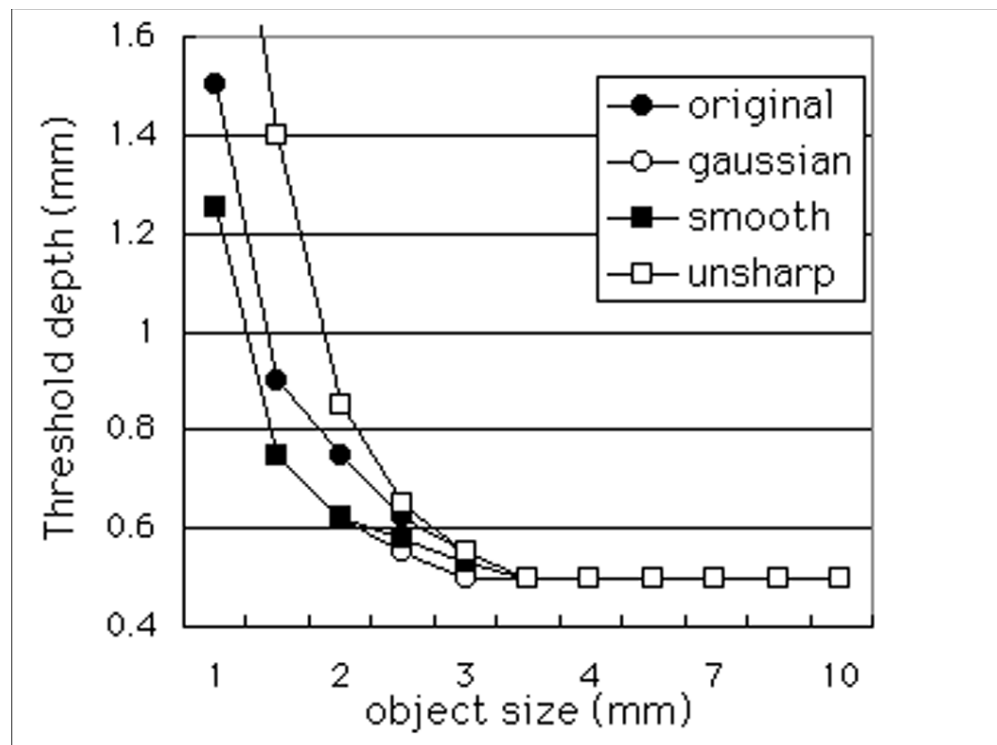


Fig.6

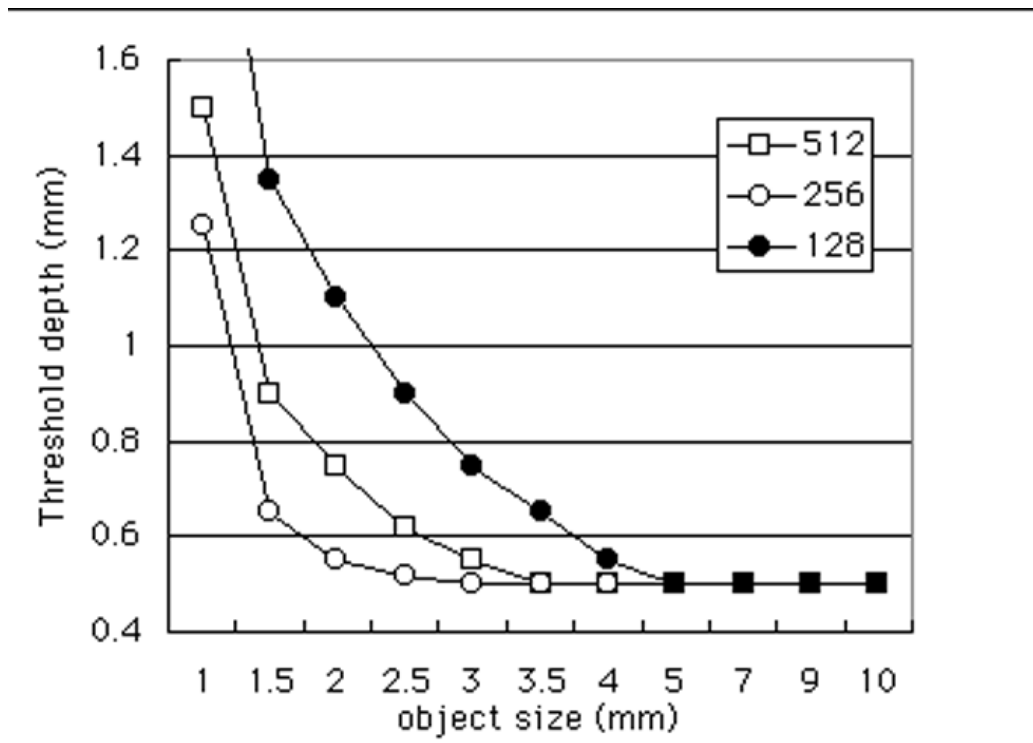


Fig.7

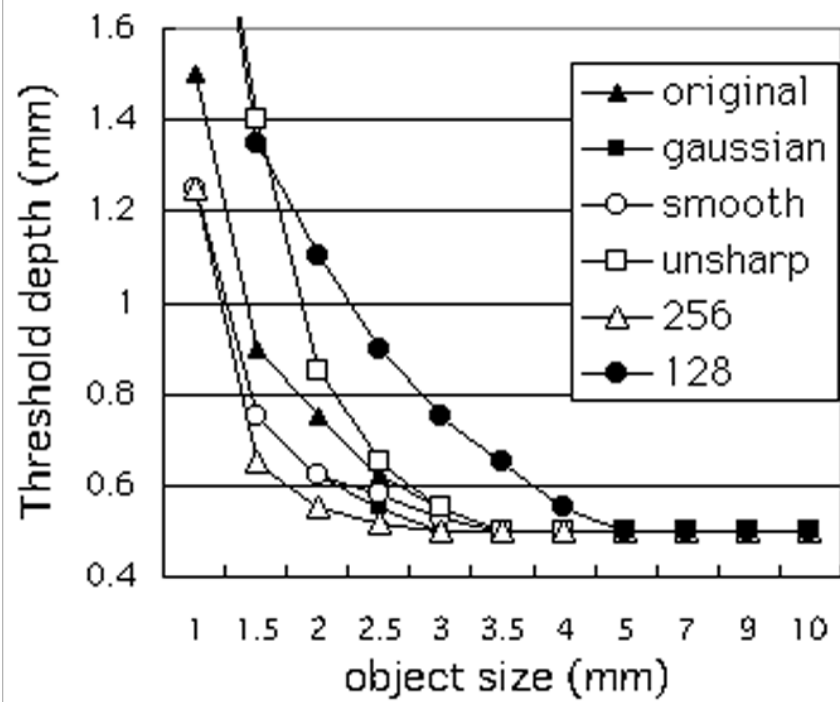


Fig.8

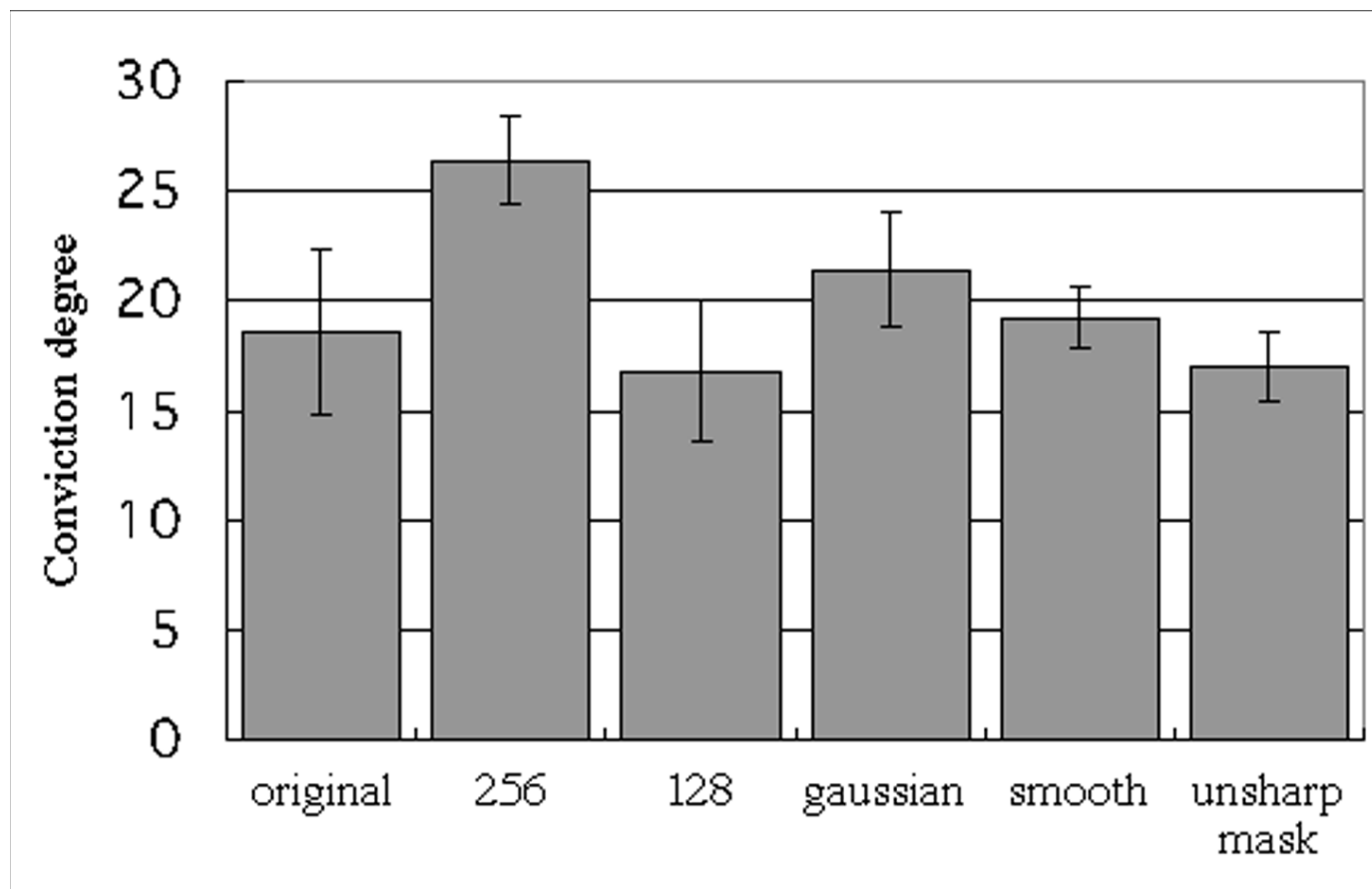


Fig.9

The degree of conviction for the decision on a six-point scale of evaluation standard.

point	decision standard
5	There is Early CT signs by all means.
4	There is Early CT signs by conviction degree of 80%.
3	There is Early CT signs by conviction degree of 60%.
2	There is Early CT signs by conviction degree of 40%.
1	There is Early CT signs by conviction degree of 20%.
0	There is not Early CT signs or does not understand it.

Table