

# The effects of changing position and angle of the proximal segment after intraoral vertical ramus osteotomy

著者	Ueki Koichiro, Hashiba Yukari, Marukawa Kohei, Nakagawa Kiyomasa, Alam Shamiul, Okabe Katsuhiko, Yamamoto Etsuhide
journal or publication title	International Journal of Oral and Maxillofacial Surgery
volume	38
number	10
page range	1041-1047
year	2009-10-01
URL	<a href="http://hdl.handle.net/2297/19611">http://hdl.handle.net/2297/19611</a>

doi: 10.1016/j.ijom.2009.04.021

**The effects of changing position and angle of the proximal segment after intraoral vertical ramus osteotomy**

KOICHIRO UEKI<sup>1</sup>, YUKARI HASHIBA<sup>1</sup>, KOHEI MARUKAWA<sup>1</sup>, KIYOMASA NAKAGAWA<sup>1</sup>, SHAMIUL ALAM<sup>1</sup>, KATSUHIKO OKABE<sup>1</sup> and ETSUhide YAMAMOTO<sup>1</sup>

**Key words:**

Intra-oral vertical ramus osteotomy, Proximal segment, Temporomandibular joint, hypoesthesia

Address correspondence to: Koichiro Ueki, DDS, PhD.

<sup>1</sup>Department of Oral and Maxillofacial Surgery, Graduate School of Medicine, Kanazawa University, 13-1 Takaramachi, Kanazawa 920-8641, Japan

Tel: +81-76-265-2444; Fax: +81-76-234-4268

E-mail: [kueki@med.kanazawa-u.ac.jp](mailto:kueki@med.kanazawa-u.ac.jp)

**Abstract.** We evaluated changes in position and angle of the proximal segment, including the condyle, after intraoral vertical ramus osteotomy (IVRO) with and without a Le Fort I osteotomy to verify whether displacement of the proximal segment could induce postoperative complications.

Of 29 Japanese patients with mandibular prognathism with asymmetry, 16 underwent IVRO and 13 underwent IVRO in combination with a Le Fort I osteotomy. The changes in condylar angle, ramus angle, and displacement of the proximal segment were measured pre and post-operatively using computed tomography (CT). The position of the temporomandibular joint (TMJ) disc was examined with magnetic resonance imaging (MRI) pre and postoperatively. Trigeminal nerve hypoesthesia in the lower lip was assessed bilaterally by the trigeminal somatosensory evoked potential (TSEP).

The postoperative horizontal condylar angle was significantly smaller than the preoperative one on both the deviated and non-deviated sides ( $P < 0.0001$ ). The postoperative coronal condylar angle was significantly larger than the preoperative one on the deviated side ( $P = 0.0483$ ). The postoperative sagittal ramus angle was larger than the preoperative one on both the deviated ( $P < 0.0001$ ) and non-deviated side ( $P = 0.00005$ ). Most (6 of 8 joints) with an anteriorly-displaced disc with (ADDwR) and without reduction (ADDwoR) improved on the non-deviated side, and 5 joints of 16 improved on the deviated side. Medial displacement of the proximal segment was observed in 14 sides (24.1%); in 4 of these, recovery from lower lip hypoesthesia was delayed until 6 months after surgery.

These results suggest that the position and the angle of the proximal segment, including the condyle, could change after IVRO. Although this could be associated with symptomatic improvement in TMJ, extreme medial displacement of the proximal segment could delay recovery from lower lip hypoesthesia.

## **Introduction**

The intraoral vertical ramus osteotomy (IVRO) is a common surgical procedure for treating prognathic mandibles,<sup>2</sup> in large part because of predictable outcomes and the low complication rate.<sup>14,16,17</sup> IVRO can be performed on patients with temporomandibular dysfunction with or without jaw deformity, especially mandibular prognathism or mandibular asymmetry, based on the inherent displacement of the condyle, moving it away from the disc and posterior attachment, and decompressing the temporomandibular joint (TMJ) apparatus<sup>2,5-8</sup>. Our previous studies also showed that IVRO could improve the disc-condyle relationship in patients with jaw deformities<sup>19,22</sup>. However, medial displacement of the segment occurs in 3% to 8% of cases.<sup>14,16,17</sup> This medial displacement of the proximal segment can induce severe complications such as injury to the neurovascular bundle.<sup>1,9</sup> Hematomas can then develop and prevent the masseter muscle from reattaching to the medially displaced proximal segment, hindering the revascularization process. The distal tip of the proximal segment, which is the most susceptible bone, may become necrotic.<sup>11</sup> Moreover, a rare Eagle-like syndrome may occur.<sup>17</sup> Flattening of the face and asymmetry can also occur on the side of the medially displaced proximal segment. Therefore, every effort should be made to position the proximal segment laterally and keep it there at the end of surgery.<sup>4</sup>

Using IVRO without internal fixation in asymmetry cases often leads to medial displacement of the proximal segment. However, few studies have examined the position and angle changes of the proximal segment after IVRO using computed tomography (CT) and magnetic resonance imaging (MRI). We therefore evaluated changes in the position and angle of the proximal segment, including the condyle, after IVRO with and without a Le Fort I osteotomy, and verified whether displacement of the proximal segment induced postoperative complications.

## **Patients and Methods**

## Patients

The 29 Japanese adults (7 men and 22 women) in this study presented with jaw deformities diagnosed as mandibular prognathism with mandibular asymmetry, mandibular prognathism with bimaxillary asymmetry, and bimaxillary asymmetry. At the time of orthognathic surgery, the patients ranged in age from 16 to 41 years, with a mean age of 25.4 years (standard deviation, 6.1 years).

## Surgery

Of the 29 patients in this study, 16 underwent IVRO without fixation for correction of their mandibular deformities. The medial pterygoid muscle was stripped in a vertical plane the amount of the desired setback of the distal segment. The muscle posterior to the stripped area was partially maintained. The other 13 patients underwent IVRO and a Le Fort I osteotomy. After approximately 1 week of intermaxillary fixation, elastic was placed to maintain an ideal occlusion. All the patients received orthodontic treatment before and after surgery, and were assessed with CT pre and postoperatively within 3 months and MRI pre and postoperatively within 6 months. Objective TMJ symptoms were recorded and evaluated. Preoperative TMJ symptoms most frequently reported were abnormal sound (clicking and crepitus) and slight pain when opening the mouth; none of the patients reported trismus.

## Frontal cephalogram analysis

In the frontal cephalogram, the angle between the ANS-Menton line and the line perpendicular to the bilateral zygomatic frontal suture line was defined as the Mx-Md midline angle. A positive value of this Mx-Md midline angle represents mandibular deviation to the left and a negative value represents mandibular deviation to the right. The Mx-Md midline angles of all cases were then given a positive value so that all consecutive measurements could be attributed to either the deviation or the non-deviation side (Fig. 1).

## Magnetic resonance imaging assessment

A detailed MRI assessment of each pair of TMJs was performed by a 1.5-Tesla MRI system (Signa Scanner, General Electric Medical Systems, Milwaukee, WI, USA), using bilateral 3-inch dual surface coils with the jaw first in the closed, resting position and then at its maximally opened position. An initial axial localizer was introduced to obtain exact midcondylar sections perpendicular and parallel to the long axis of each condyle. Images of the bilateral orthogonal sagittal planes and coronal planes of the TMJs in the closed jaw position were acquired first with a repetition pulse ( $T_R$ ) of 2000 msec, echo time ( $T_{ES}$ ) of 20 msec, a 3-mm image slice thickness, and a field of view of 10 cm. Then images of the bilateral sagittal planes of the TMJs in the open mouth position were obtained with a  $T_R$  of 1000 msec and  $T_{ES}$  of 20 msec.

In the sagittal plane images, the center point was determined to be the midpoint of the antero-posterior length of the condyle on the line between the lowest point of the articular eminence and the squamotympanic fissure. The lowest point of the articular eminence was considered to be  $0^\circ$  and the squamotympanic fissure became  $180^\circ$ .

## Definitions

All joint discs were classified according to following definitions, as shown in our previous report<sup>22</sup>.

Anterior displacement: the entire disc is antero-inferior to the most anterior point on the contour of the condyle. These are divided into anteriorly displaced disc with(ADDwR) and without(ADDwoR) reduction.

Anterior type: the center of the intermediate zone is between  $0^\circ$  and  $90^\circ$  and the most posterior point of the posterior band is postero-superior to the most anterior point on the contour of the condyle and less than  $180^\circ$ .

Fully-covered type: the most anterior point of the anterior band is less than  $0^\circ$  and the

most posterior point of the posterior band is greater than  $180^\circ$ .

Posterior type: the most anterior point of the anterior band is more than  $0^\circ$  and the most posterior point of the posterior band is greater than  $180^\circ$ .

Anterior type, fully-covered type and posterior type were defined as variants of normal in skeletal Class III<sup>18</sup>.

### Measurements using CT

The patients were placed in the gantry with the tragacanth line perpendicular to the ground for CT scanning. They were instructed to breathe normally and to avoid swallowing during the scanning process. CT scans were obtained in the radiology department by skilled radiology technicians using a high-speed, advantage-type CT generator (Light Speed Plus; GE Healthcare, Milwaukee, WI, USA) with each sequence taken 1.25 mm apart for the 3D reconstruction (120 kV, average 150 mA, 0.7 sec/rotation, helical pitch 0.75). The resulting images were stored in the attached workstation computer (Advantage workstation version 4.2; GE Healthcare, Milwaukee, WI, USA) and 3D reconstruction was performed using the volume rendering method. ExaVision LITE version 1.10 medical imaging software (Ziosoft, Inc, Tokyo, Japan) was used for 3D morphologic measurements. CT scanning of head was taken parallel to the FH plane (Frankfurt horizontal) using a laser beam pointer, so that the FH (Frankfurt horizontal) plane could be identified easily. Furthermore, it could be confirmed using 3D reconstruction image so that the plane could be reproducible.

The horizontal slice image parallel to the FH (Frankfurt horizontal) plane where two condyles could be recognized at maximum square (including medial and lateral pole of the condyle) was selected to measure the condylar angle. The RL line was determined as the line between the most anterior points of the bilateral auricles.

The following items were measured pre- and postoperatively and bilaterally.

1) Horizontal condylar angle: the angle between the RL line and the condylar long axis (the line between the most medial and lateral points) (Fig. 2)

The coronal image perpendicular to the FH plane passed through the bilateral condyle

was selected to measure as follows.

- 2) Coronal condylar angle: the angle between the FH plane and the condylar long axis (the line between the most medial and lateral points) (Fig. 3)
- 3) Coronal ramus angle: the angle between the FH plane and the tangential line to the lateral outline of ramus (Fig.3)
- 4) ML distance (only post-operation): the distance parallel to the RL line between the most anterior point on the lateral aspect of the proximal segment and the most posterior point on the lateral aspect of the distal segment. A positive value showed the proximal segment displaced laterally (Fig. 4).
- 5) AP distance (only post-operation): the distance perpendicular to the RL line between the most anterior point on the lateral aspect of the proximal segment and the most posterior point on the lateral aspect of the distal segment. A positive value showed the proximal segment displaced posteriorly. In short, there was no overlap between segments (Fig. 4).

The sagittal image perpendicular to the FH plane including the condylar head and mandibular angle was selected to measure as follows.

- 6) Sagittal ramus angle: the angle between the FH plane and the tangential line to the posterior outline of ramus (Fig. 5).
- 7) SI distance (only post-operation): the distance parallel to the FH plane between the most inferior points of the osteotomy edge of the distal segment and proximal segment (Fig. 5).

All CT images were measured by one author (K.U.). Fifteen patients were selected at random and CT images were measured again 10 days later. Paired t test was applied to the first and second measurements. The difference between the first and second CT measurements was insignificant ( $p>.05$ ).

#### Measurement of lower lip hypoesthesia with trigeminal sensory evoked potential (TSEP)

Trigeminal nerve hypoesthesia was assessed bilaterally by the TSEP method. The methodology and values of TSEP have been described previously in our preliminary studies.<sup>10-12</sup> The electrodes were placed exactly under the highest point of the vermilion



border and on the mucosa of the lower lip. An electroencephalograph recording system (Neuropack Sigma™; Nihon Kodan Corp., Tokyo, Japan) was used to measure the potentials. The right and left sides were measured separately so that a total of 58 sides could be assessed. Each patient was evaluated pre-operatively and then post-operatively at 1 and 2 weeks, 1, 3 and 6 months.

Trigeminal hypoesthesia was assessed by the latency of P1 and N2 in the recorded TSEP spectra. An earlier pilot study in healthy volunteers showed that these peaks produced an accurate figure and tended to result in better reproducibility. Measurable periods of TSEP were defined as periods before the peaks of N1 (N13), P1(P17), N2(N27), P2(P36) and N3(N46) that were identified clearly as early components of the TSEP wave. Actual data was recorded as the latency period (msec) in each peak (Fig. 6).

### Statistical analysis

Data were compared between the pre and postoperative value, and between the deviation and non-deviation side with paired t-test using the Stat View™ version 4.5 software program (Abacus Concepts, Inc., Berkeley, CA, USA). The differences were considered significant at  $p < 0.05$ .

## **Results**

### Condylar and ramus angle, position of proximal segment

The horizontal condylar angle was significantly different on the deviated and non-deviated sides ( $P=0.00299$ ), but was not different postoperatively. The postoperative horizontal condylar axis was significantly smaller than the preoperative one on both sides ( $P < 0.0001$ ). The postoperative coronal condylar angle was significantly larger than the

preoperative one on the deviated side ( $P=0.0483$ ). The preoperative difference in coronal angle between the sides ( $P=0.0005$ ) disappeared postoperatively.

The coronal ramus angle was larger on the deviated side than the non-deviated side preoperatively ( $P=0.0005$ ), but there was no difference postoperatively. The sagittal ramus angle was not different on the two sides, but was significantly larger postoperatively on both the deviated side ( $P=0.0005$ ) and non-deviated side ( $P<0.0001$ ).

Postoperatively, 7 deviated sides and 7 non-deviated sides were displaced medially (Fig. 7). The ML and AP distances were not different on the deviated and non-deviated sides. However, the SI distance in the non-deviated side was larger than the deviated side ( $P=0.0211$ ) (Table. 1).

#### Anterior disc displacement with and without reduction

Joints preoperatively classified as anterior, fully-covered, or posterior showed no postoperative changes. Most (6 of 8 joints, 75%) anteriorly-displaced discs with (ADDwR) and without reduction (ADDwoR) improved on the non-deviated side, and 5 joints (31.3%) of 16 improved on the deviated side. The total ratio of improvement of anteriorly-displaced discs was 45.8% (11/24 joints). No changes occurred in preoperative normal joint discs (anterior, fully-covered, or posterior types).

#### Temporomandibular joint symptoms

Symptoms were improved by surgery in 96.6% (28/29 joints) of patients who underwent IVRO on both sides.

#### TSEP

In 49 of 58 (82.8%) sides of lower lips, TSEP was measurable within 1 week; 7 sides (12.1 %) were measurable within 2 weeks. The 3 sides (5.2 %) with the proximal

segments displaced medially (ML distance was negative) had lip hypoesthesia for 6 months, although all sides eventually recovered. The other remaining 4 sides with the proximal segments medially did not delay the recovery of lip hypoesthesia.

## **Discussion**

IVRO offers several advantages: ease of the procedure, absence of external facial scar, less need for bone decortilization,<sup>17</sup> reduced surgical time, and minimal incidence of facial and inferior nerve injury and bleeding. IVRO is an alternative surgery for certain cases of internal derangement of TMJ.<sup>2,5-8</sup> The most troublesome sequelae are skeletal instability and antero-inferior condylar displacement (sag), with resultant unpredictability of postoperative mandibular position.<sup>2</sup>

We found an improvement in preoperative ADDwR and ADDwoR, but did not find changes in preoperative normal joint discs (anterior, fully-covered, or posterior types). The IVRO with and without Le Fort I osteotomy could improve ADD for a short post-surgical period. TMJ symptoms were improved in 96.6% of preoperative symptomatic joints.

The horizontal condylar angle increased postoperatively, as shown in our other studies.<sup>19, 22</sup> A surgically-induced increase in the horizontal condylar angle correlates with an increase in the side range and incisor path angle<sup>20</sup>. The change in the horizontal condylar angle is important for the postoperative chewing path, and the preoperative angle of the condylar long axis is not always adequate postoperatively. In this study, the postoperative coronal condylar angle on the deviated side also increased significantly, although there was no significant change in coronal ramus angle. Thus, the tip of the proximal segment on the deviated side tended towards medial displacement. Surgery abolished the preoperative difference in the bilateral coronal ramus angle, suggesting that the medial displacement in the tip of the proximal segment on the deviated side could increase the coronal ramus angle and correct facial asymmetry. The sagittal ramus angle was larger postoperatively, indicating posterior displacement in the tip of the proximal segment.

The postoperative displacement of the proximal segment incorporates antero-inferior

displacement (sag) as well as position and angle changes in the horizontal, coronal, and sagittal planes. This displacement of the proximal segment may affect skeletal stability. However, 3-dimensional displacement of the proximal segment could reduce TMJ symptoms and improve the disc-condylar relationship. Displacement of the proximal segment showed a dynamic neutral position as it attached to the lateral pterygoid muscle. As the pathologic, anteriorly displaced disc improved, the disc position moved to a superior-posterior position, allowing for exact condylar positioning in the glenoid fossa. However, we could not predict improvements in the anteriorly displaced disc, making it difficult to place the proximal segment in IVRO. Long-term inter-maxillary traction with elastic could maintain the occlusion and skeletal stability by improving TMJ structure, including disc-condylar relationship, as prolongation of intermaxillary fixation with wire could delay the recovery of postoperative mandibular motion. We previously reported that condylar sag occurred immediately after surgery so that the condyle could change from an inferior-anterior position to a superior-posterior position with relapse of the proximal segment and after bony adhesion and reattachment of the medial pterygoid muscle. However, the difference was very small, and would not be a problem clinically.<sup>21</sup>

The TSEP method is non-invasive, highly objective, and extremely reliable for investigating trigeminal sensory hypoesthesia of the lower lip after mandibular ramus osteotomy.<sup>10-12</sup> Simple sensory tests, such as 2-point sensory discrimination, allow for patient bias despite objective parameters such as stimulating pressure. However, TSEP data is directly collected from electroencephalography of the cerebral cortex, and is therefore more objective and reliable. IVRO shows the earliest recovery from hypoesthesia with TSEP, and lower lip hypoesthesia was lower with the Obwegeser method than the Obwegeser Dal-Pont method.<sup>15</sup> Postoperative hypoesthesia of the lower lip is rare, but we show that extreme medial displacement can induce transient postoperative hypoesthesia.

Rosenqvist<sup>14</sup> found unilateral medial displacement of the proximal segment in 10 out of 125 patients receiving an oblique sliding osteotomy of the mandibular rami. In 8 of these, minor retro-positioning of the distal segment during surgery was combined with lateral rotation. Medial displacement of the proximal segment did not affect postoperative stability.

In 6 of the 10 patients, transient anesthesia of the inferior alveolar nerve occurred on the side where the proximal segment was medially displaced.

Colderon et al.<sup>4</sup> reported that there might be intraoperative difficulty in lateral positioning of the proximal segment, which was frequently trapped medially, and introduced three techniques for lateral relocation of the medially-displaced proximal segment.

Medial displacement of the proximal segment is often observed in asymmetry cases. Lateral positioning of the proximal segment leads to large displacement or dislocation of the condyle. Furthermore, a dynamic neutral location of the proximal segment can improve TMJ symptoms. If overlap between the distal and proximal segments of the inferior alveolar nerve near the mandibular foramen is not expected postoperatively, the proximal segment can be positioned medially.

Here, we examined postoperative changes within 3 months using CT, but longer-term followup is needed.

In conclusion, the position and angle of the proximal segment, including the condyle, can change after IVRO. Although this could improve TMJ symptoms, extreme medial displacement of the proximal segment could delay recovery from lower lip hypoesthesia.

## References

- 1) Akin RK, Walters PJ: Experience with the vertical subcondylar osteotomy. *J Oral Surg* 1975; 33: 342-5.
- 2) Bell WH. Mandibular prognathism. In: *Modern Practice in Orthognathic and Reconstructive Surgery*. Philadelphia, PA: Saunders, 1992, pp 61, 2111-2137.
- 3) Boyne PJ. Osseous healing after oblique osteotomy of the mandibular ramus. *J Oral Surg* 1966; 24:125-33.
- 4) Calderon S, Gal G, Anavi Y, Gonshorowitz M: Techniques for ensuring the lateral position of the proximal segment following intraoral vertical ramus osteotomy. *J Oral Maxillofac Surg* 1992; 50: 1044-47.
- 5) Hall HD. A technique to improve predictability of condylar position with modified condylotomy. *Oral Surg Oral Med Oral Radiol Endod* 1999; 88: 127-8.
- 6) Hall HD, Indresano AT, Kirk WS, Dietrich MS. Prospective multicenter comparison of 4 temporomandibular joint operations. *J Oral Maxillofac Surg* 2005; 63: 1174-9.
- 7) Hall HD, Navarro EZ, Gibbs SJ. One- and three- year prospective outcome study of modified condylotomy for treatment of reducing disc displacement. *J Oral Maxillofac Surg* 2000; 58: 7-17.
- 8) Hall HD, Navarro EZ, Gibbs SJ. Prospective study of modified condylotomy for treatment of nonreducing disk displacement. *Oral Surg Oral Med Oral Radiol Endod* 2000; 89: 147-58.
- 9) Hall HD, Chase DC, Payor LG: Evaluation and refinement of the intraoral vertical subcondylar osteotomy. *J Oral Surg* 1975; 33: 333-41.
- 10) Nakagawa K, Ueki K, Matsumoto N, Takatsuka S, Yamamoto E, Ooe H. The assessment of trigeminal sensory nerve paraesthesia after bilateral sagittal split osteotomy: modified somatosensory evoked potentials recording method. *J Craniomaxillofac Surg* 1997; 25: 97-101.
- 11) Nakagawa K, Ueki K, Takatsuka S, Daisuke T, Yamamoto E. Somatosensory-evoked potential to evaluate the trigeminal nerve after sagittal split osteotomy. *Oral Surg Oral Med*

Oral Pathol Oral Radiol Endod 2001; 91: 146-152.

12) Nakagawa K, Ueki K, Takatsuka S, Yamamoto E. Trigeminal nerve hypesthesia after sagittal split osteotomy in setback cases: Correlation of postoperative computed tomography and long-term trigeminal somatosensory evoked potentials. J Oral Maxillofac Surg 2003; 61: 898-903.

13) Quinn PD, Wedell D. Complications from intraoral vertical subsigmoid osteotomy: Review of the literature and report of two cases. Int J Adult Orthod Orthognath Surg 1988; 3: 189-96.

14) Rosenquist B. Medial displacement of proximal segment. Int J Oral Maxillofac Surg 1990; 19:226-229.

15) Takazakura D, Ueki K, Nakagawa K, Marukawa K, Shimada M, Shamiul A, Yamamoto E. A comparison of postoperative hypoesthesia between two types of sagittal split ramus osteotomy and intraoral vertical ramus osteotomy, using the trigeminal somatosensory-evoked potential method. Int J Oral Maxillofac Surg 2007; 36:11-4.

16) Tuinzing DB, Greebe RB. Complications relating to the intraoral vertical ramus osteotomy. Int J Oral Surg 1985; 14: 319-24.

17) Tuinzing DB, Creebe RB, Van Der Kwast AM. Eagle-like syndrome. Int J Oral Surg 1983; 14:319-23.

18) Ueki K, Nakagawa K, Takatsuka S, Shimada M, Marukawa K, Takazakura D, Yamamoto E. Temporomandibular joint morphology and disc position in skeletal class III patients. J Cranio Maxillofac Surg 2000; 28:362-8.

19) Ueki K, Marukawa K, Nakagawa K, Yamamoto E. Condylar and temporomandibular joint disc positions after mandibular osteotomy for prognathism. J Oral Maxillofac Surg 2002; 60:1424-32.

20) Ueki K, Marukawa K, Shimada M, Nakagawa K, Yamamoto E, Niizawa S. Changes in the chewing path of patients in skeletal class III with and without asymmetry before and after orthognathic surgery. J Oral Maxillofac Surg 2005; 63:442-8.

21) Ueki K, Marukawa K, Shimada M, Nakagawa K, Yamamoto E. Change in condylar long axis and skeletal stability following sagittal split ramus osteotomy and intraoral

vertical ramus osteotomy for mandibular prognathia. *J Oral Maxillofac Surg* 2005; 63: 1494-1499.

22) Ueki K, Marukawa K, Shimada M, Yoshida K, Hashiba Y, Shimizu C, Nakagawa K, Alam S, Yamamoto E. Condylar and disc positions after intraoral vertical ramus osteotomy with and without a Le Fort I osteotomy. *Int J Oral Maxillofac Surg*. 2007 ;36:207-13.



## Legends

Table 1. Results of measurements with CT. SD indicates standard deviation.

Figure 1. Measurements of the frontal cephalogram

Figure 2. Measurements of the horizontal image with CT. Arrows show the horizontal condylar angle.

Figure 3. Measurements of the coronal image with CT. A) shows the coronal condylar angle. B) shows the coronal ramus angle.

Figure 4. Measurements of the postoperative horizontal image. A) shows the ML distance. B) shows the AP distance.

Figure 5. Measurements of the sagittal image with CT. A) shows the sagittal ramus angle. B) shows the SI distance.

Figure 6. A typical wave of trigeminal somatosensory-evoked potential. Five peaks were identified: N1(N13), P1(P17), N2(N27), P2(P36), and N3(N46).

Figure 6. Medial displacement of the proximal segment.

Zygomatic frontal suture

Zygomatic frontal suture

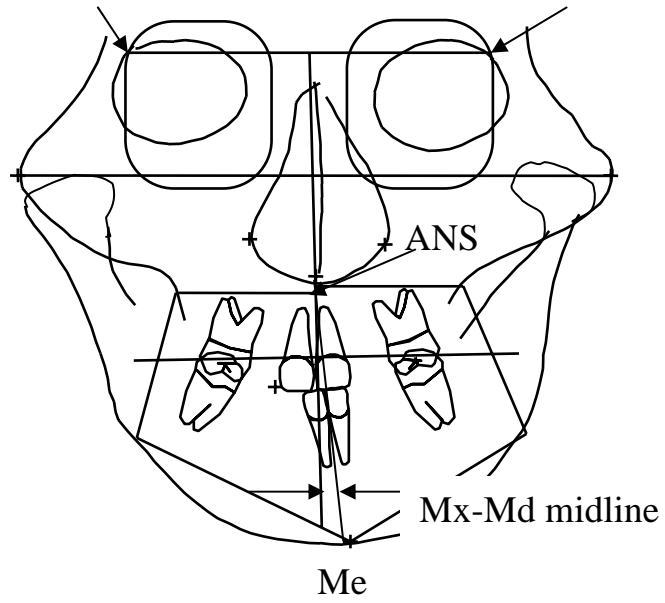


Fig. 1

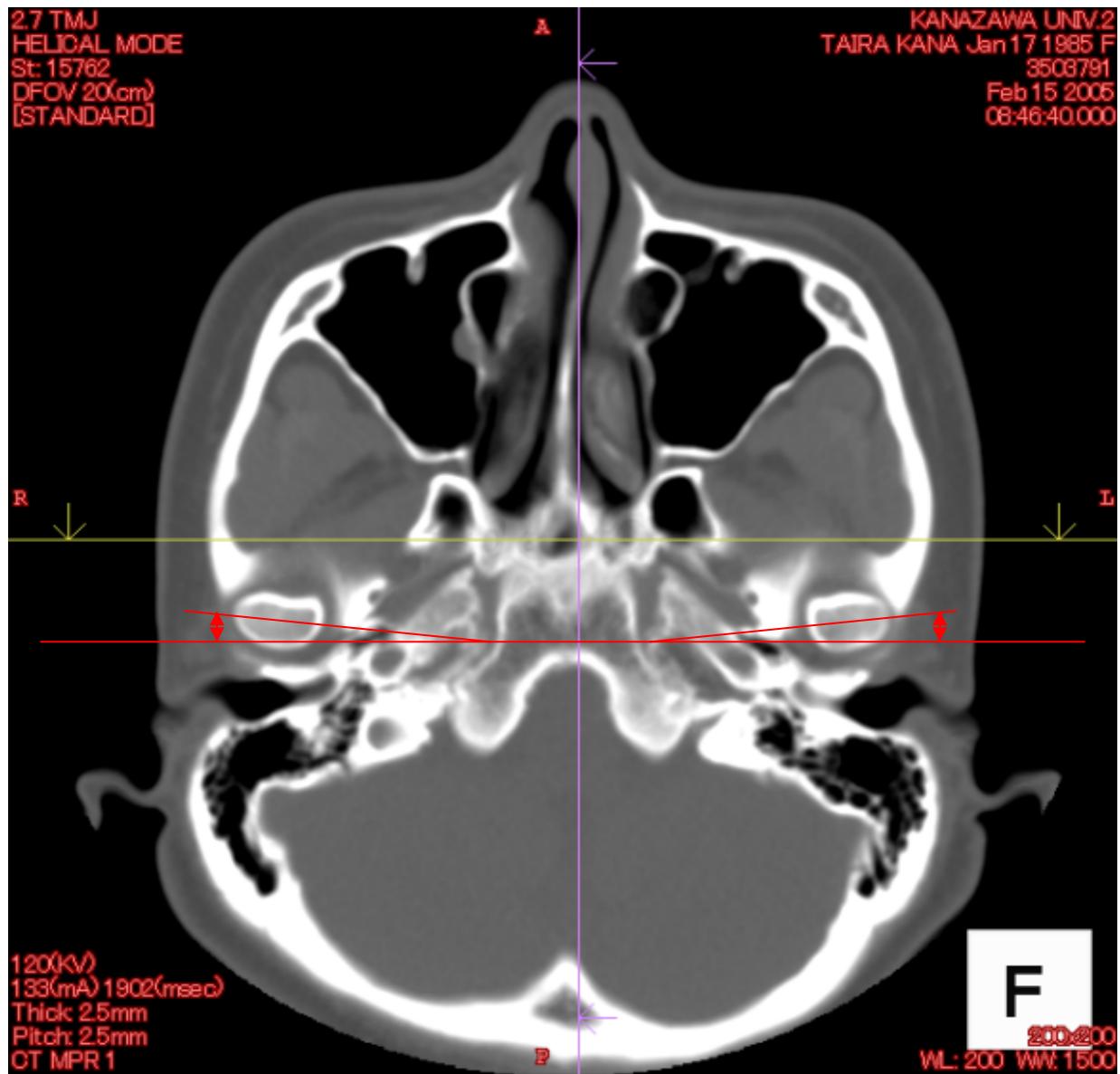


Fig. 2

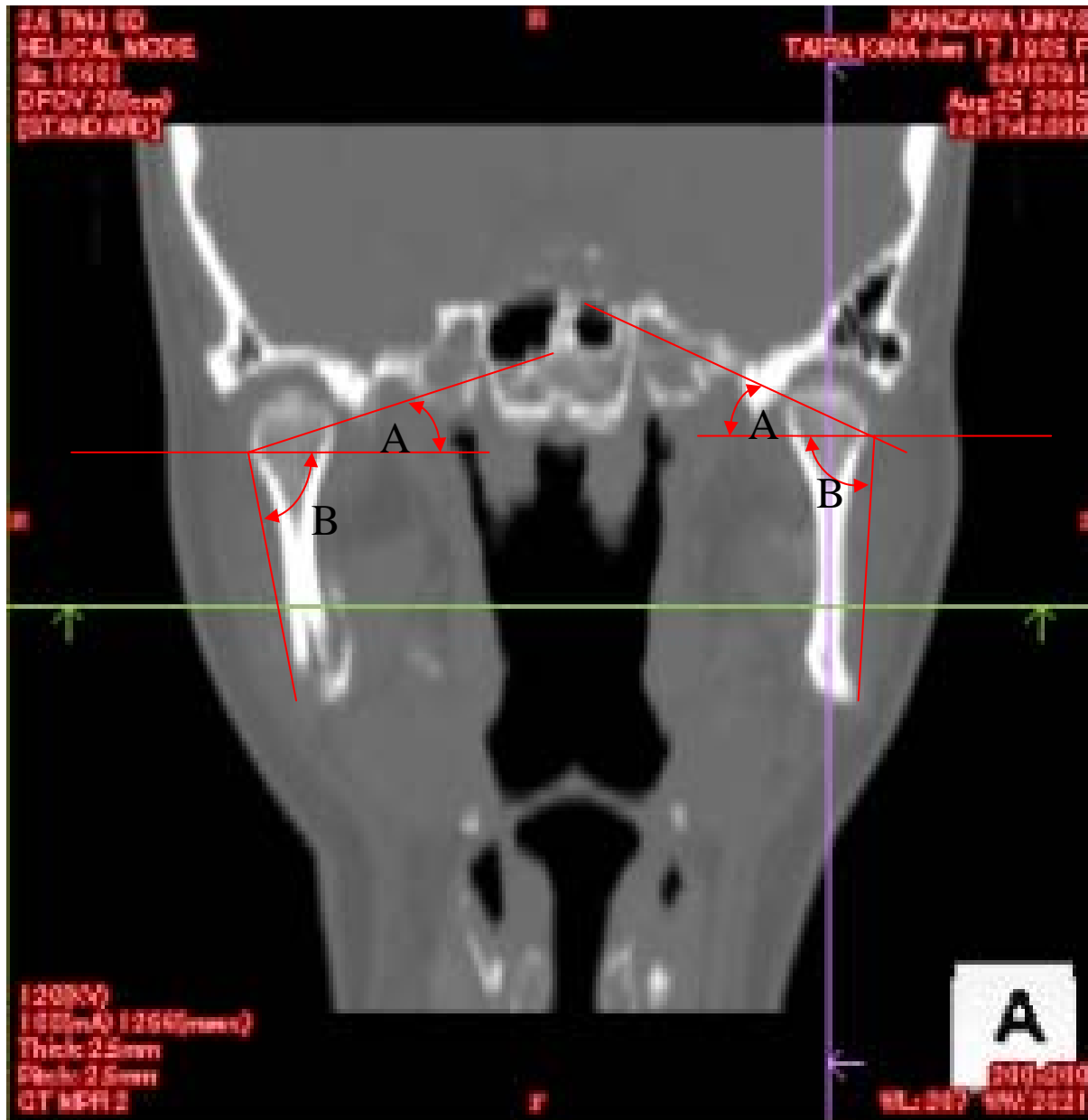


Fig. 3

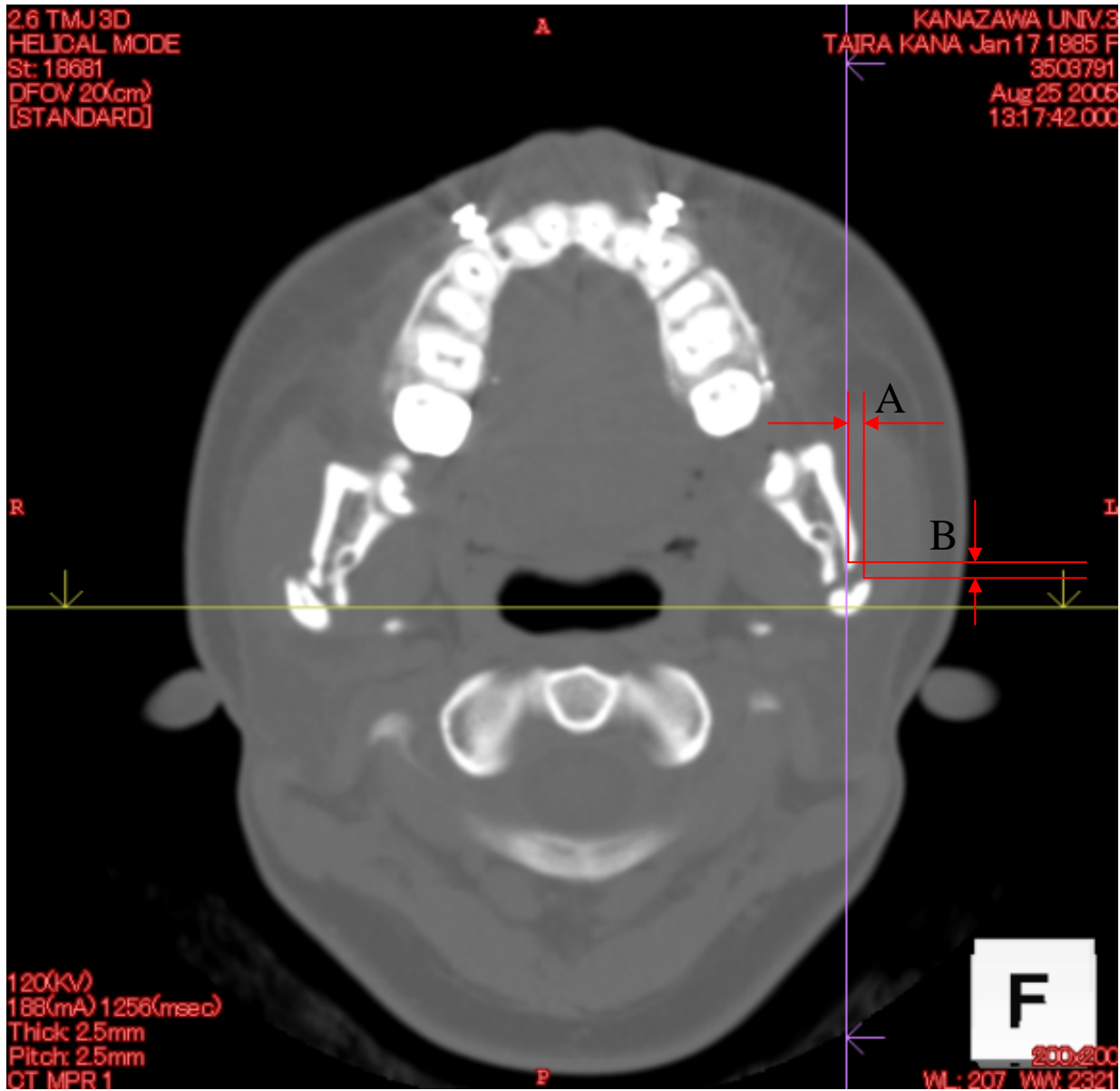


Fig. 4

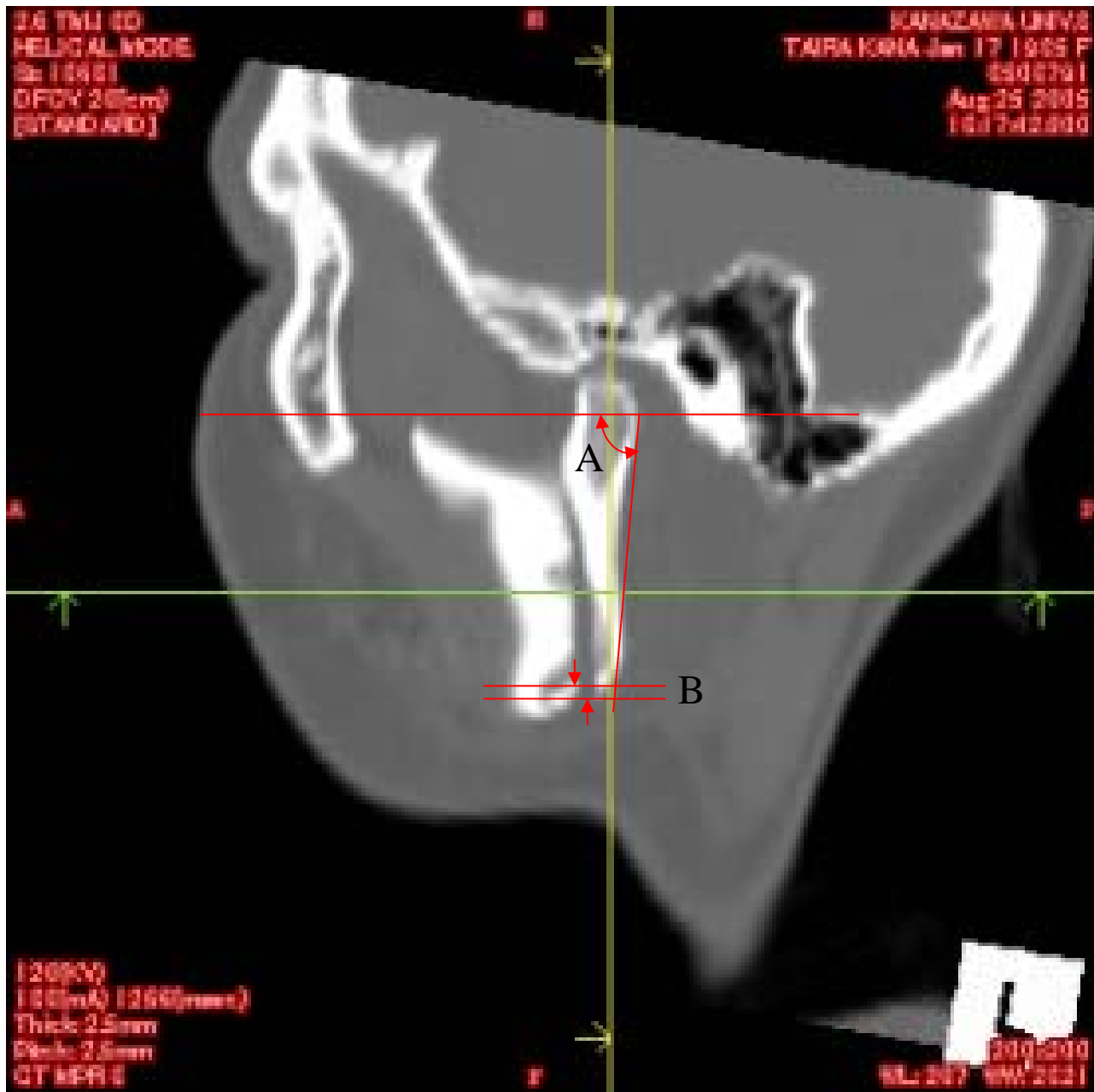


Fig. 5

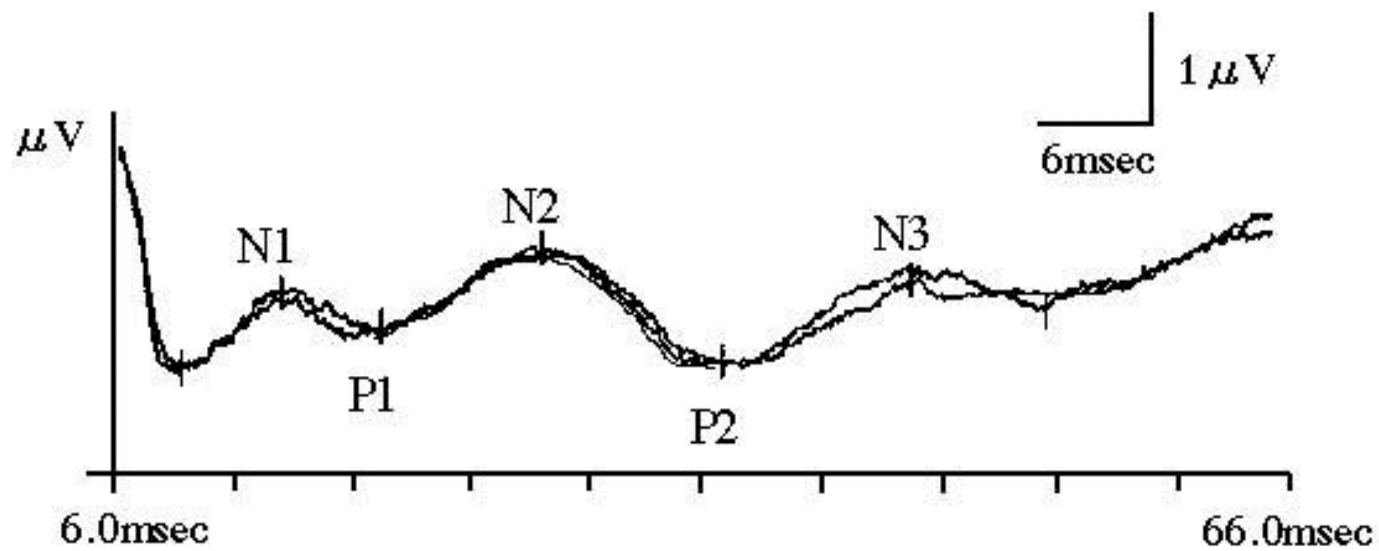


Fig. 6

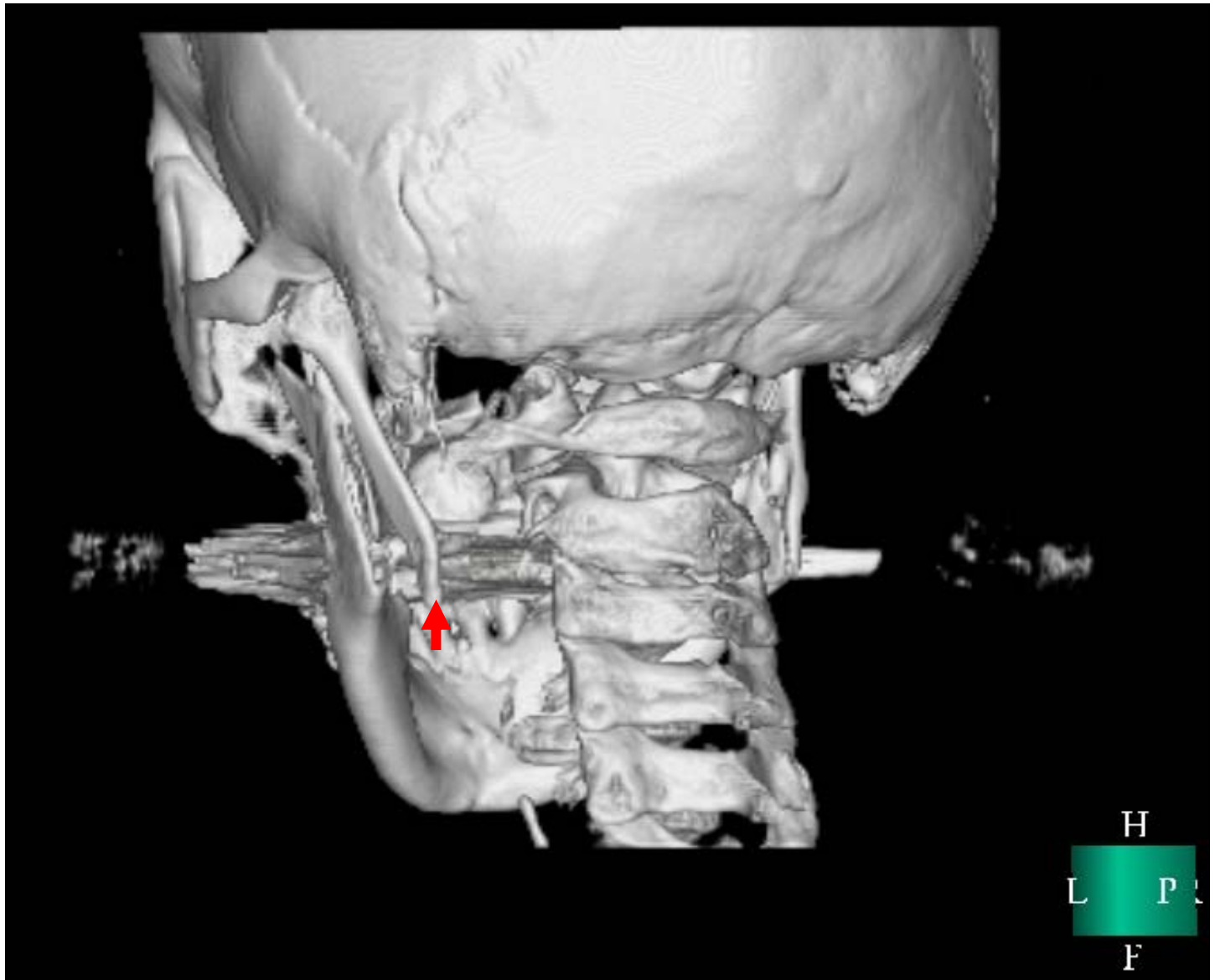


Fig. 7



	Non-deviation side				Deviation side				Comparison between pre and post		Comparison between both sides	
	Pre-operation Mean	Post-operation SD	Post-operation Mean	Pre-operation SD	Pre-operation Mean	Post-operation SD	Post-operation Mean	Pre-operation SD	Non-deviation side P-value	Deviation side P-value	Pre-operation P-value	Post-operation P-value
Horizontal condylar (degree)	17.9	9.3	8.8	9.7	22.7	12.1	10.7	15.3	<0.0001	<0.0001	0.0299	0.5115
Coronal condylar angle (degree)	16.7	8.6	14.4	10.8	10.3	11.4	13.7	12.7	0.1042	0.0483	0.7737	0.0039
Coronal ramus angle (degree)	74.5	4.3	76.8	7.4	78.8	6.4	78.4	6.7	0.1626	0.7397	0.0005	0.3369
ML distance (mm)			1.5	4.4			0.5	3.6				0.3607
Sagittal ramus angle (degree)	86.4	7.6	94.9	6.6	86.9	7.5	93.7	7.1	<0.0001	0.0005	0.2906	0.3144
AP distance (mm)			1.3	3.5			1.9	2.1				0.4613
SI distance (mm)			2.6	2.4			0.7	3.2				0.0211

Table. 1