

The evaluation of surgical factors related to recovery period of upper lip hypoaesthesia after Le Fort I osteotomy

著者	Ueki Koichiro, Hashiba Yukari, Marukawa Kohei, Nakagawa Kiyomasa, Alam S., Yamamoto Etsuhide
journal or publication title	Journal of Cranio-Maxillofacial Surgery
volume	36
number	7
page range	390-394
year	2008-10-01
URL	http://hdl.handle.net/2297/11737

doi: 10.1016/j.jcms.2008.02.008

**The evaluation of surgical factors related to recovery period of upper lip
hypoesthesia after Le Fort I osteotomy**

Short title: Upper lip hypoesthesia after Le Fort I osteotomy

Koichiro UEKI¹, Yukari HASHIBA¹, Kohei MARUKAWA¹, Kiyomasa
NAKAGAWA¹, Shamiul ALAM¹, Etsuhide YAMAMOTO¹

¹Department of Oral and Maxillofacial Surgery (Head: Prof. Dr. E. Yamamoto),
Graduate School of Medicine, Kanazawa University, 13-1 Takaramachi, Kanazawa
920-8641, Japan.

Address correspondence to: Koichiro Ueki, DDS, PhD

Department of Oral and Maxillofacial Surgery, Graduate School of Medicine,
Kanazawa University, 13-1 Takaramachi, Kanazawa 920-8641, Japan.

Tel: +81-76-265-2444; Fax: +81-76-234-4268

E-mail: kueki@med.kanazawa-u.ac.jp

Key words: Le Fort I osteotomy, upper lip, hypoesthesia, trigeminal somatosensory evoked
potential (TSEP), computed tomography (CT)

Summary

Purpose: It is unclear whether surgical factors can affect the upper lip sensitivity. The aim of this study was to assess the factors that can affect the recovery period of hypoesthesia of the upper lip after Le Fort I osteotomy, using trigeminal somatosensory evoked potential (TSEP) objectively.

Patients and Methods: 29 patients with mandibular prognathism underwent Le Fort I osteotomy with and without artificial pterygoid plate fracture. Trigeminal nerve hypoesthesia at the region of the upper lip was assessed bilaterally by the trigeminal somatosensory evoked potential (TSEP) method. The distance between the infraorbital foramen and the osteotomy line (IO) or the nearest plate/screw position (IP) was measured on three-dimensional computed tomography (CT). The relationship between the recovery period in upper lip hypoesthesia and surgical factors (these distances, movement amount, pterygoid plate fracture) were analysed statistically.

Results: The recovery period in upper lip hypoesthesia did not significantly correlate with IO, IP and movement amount. There was no significant difference between pterygoid plate fracture group and non fracture group.

Conclusion: Temporary hypoesthesia of upper lip after Le Fort I osteotomy could not be avoided, however, osteotomy line, plate/screw position and pterygoid plate fracture in Le Fort I osteotomy did not affect the recovery period of upper lip hypoesthesia with TSEP.

Le Fort I osteotomy is mainly used in maxillary advancement. Sensory innervation of the area affected by Le Fort I osteotomy occurs mainly through the maxillary division of the trigeminal nerve. Where the maxillary nerve crosses the pterygopalatine fossa, it branches into the posterior superior alveolar nerve, which supplies the mucous membrane of the maxillary sinus, the three molar teeth, and the vestibular mucosa and gingival around the maxillary molars. After the maxillary nerve enters the orbit through the infraorbital groove, at which point it is called the infraorbital nerve, the middle and anterior superior alveolar nerves branch off to supply the remaining upper teeth. After emerging through the infraorbital foramen, the infraorbital nerve sends out palpebral, nasal, and labial branches to supply the skin of the lower eyelid, conjunctiva, lateral surface of the external nose and upper lip including skin, mucous membrane and vestibular mucosa, and gingival from the midline as far posterior as the second gingival.

In the Le Fort I osteotomy, after the infraorbital nerve emerges from the infraorbital foramen, it is subject either to direct laceration or traction injury resulting from the forceful use of retractors during operation (Posnic et al., 1994).

According to previous reports, an osteotomy line (bone cut) close to the apices of the teeth should be avoided in order to protect the teeth from devitalisation (Emshoff et al., 2000; Justus et al., 2001; Sato et al., 2003; Harada et al., 2004). However, when superior repositioning of the maxilla is indicated, a high cut osteotomy far from the apices of the teeth is not always feasible due to the position of the infraorbital foramen. Furthermore, the osteotomy line is also determined from the view of stability derived from the method of fixation or the materials (Nagasao et al., 2007). On the

other hand, in cases that were unsuitable for maxillary advancement, especially those with maxillary asymmetry or maxillary protrusion, the mobility of the pterygoid process is necessary to achieve ideal maxillary movement. For this reason, we have reported the modified Le Fort I technique with “artificial” fracture of pterygoid process using the ultrasonic bone curette (Ueki et al., 2004). However, there was no report regarding the relationship between upper lip hypoesthesia and the position of the osteotomy line after Le Fort I osteotomy. Furthermore, it also remained unclear whether the “artificial” fracture of pterygoid process could affect the hypoesthesia of upper lip.

Therefore, the purpose of this study was to assess whether the factors such as osteotomy line, fixation position, degree of movement and the pterygoid plate fracture, can affect the recovery period of hypoesthesia of the upper lip after Le Fort I osteotomy using trigeminal somatosensory evoked potential (TSEP) objectively.

Patients and Methods

Patients:

Subjects comprised 29 Japanese adults (8 men, 22 women) presenting with jaw deformities diagnosed as mandibular prognathism, both with or without bimaxillary asymmetry. At the time of orthognathic surgery, mean patient age was 24.3 years (standard deviation: 6.1 years; range: 16-38 years).

Surgery:

Of the 29 patients in this study, 20 underwent Le Fort I osteotomy and bilateral sagittal split ramus osteotomy (SSRO) using the Obwegeser method, while one patient underwent Le Fort I osteotomy alone.

Eight of the patients underwent Le Fort I osteotomy and intra-oral vertical ramus osteotomy (IVRO) without fixation to alter the occlusal cant, predominantly for correction of asymmetry. After approximately 1 week of maxillo-mandibular fixation, elastics were placed to maintain ideal occlusion.

In 24 of the 29 patients, 2 PLLA (poly-L-lactic acid) L-type mini-plates (10×22×1.5 mm with 4 screws (2×8 mm), Fixorb[®]-MX; Takiron Co., Osaka, Japan) and 2 straight PLLA plates (28×4.5×1.5 mm with 4 screws (2×8 mm), Fixorb[®]-MX; Takiron Co.) were used to fix the maxilla. In the other 5 patients, 2 L-type titanium miniplates and 2 straight titanium miniplates (4 holes / thickness 0.55 mm with 4 screws (2×5 mm), Würzburg titanium miniplate system; Leibinger Co., Freiburg, Germany) were used to fix the maxilla.

Eighteen of the 29 patients underwent Le Fort I osteotomy with “artificial“ fracture of pterygoid plate to remove the interference between pterygoid plates and the posterior part of maxilla by using the ultrasonic bone curette (SONOPET[®]) as reported previously (Ueki et al., 2004). The other 11 patients underwent conventional Le Fort I osteotomy without pterygoid plate fracture.

Trigeminal nerve hypoesthesia was assessed bilaterally by the TSEP method. The methodology and values of the TSEP have been previously described in a preliminary study (Nakagawa et al., 1997; Nakagawa et al., 2001; Nakagawa et al., 2003). This method was applied to the upper lip. The electrodes were placed just above the highest

point of the vermilion border and on the mucosa of the upper lip. An electroencephalograph recording system (Neuropack Sigma™; Nihon Kodan Corp., Tokyo, Japan) was used to analyse the potentials. Right and left sides were measured separately, with a total of 58 sides being assessed. Each patient was evaluated preoperatively and then postoperatively at 1 week, 2 weeks, 1 month, 3 months, 6 months and 1 year.

Trigeminal hypoaesthesia was assessed by the latency of P1 and N2 in the recorded TSEP spectra because these peaks produce an accurate figure and have a tendency of higher reproducibility among healthy volunteers. Measurable periods of TSEP defined as those periods before the peaks of N1 (N13), P1 (P17), N2 (N27) and P2 (P36), were clearly identified on early components of the TSEP wave (Fig. 1).

The measurable period was determined as the time when the TSEP was first measured postoperatively. Attempts to record TSEP after surgery continued until it became measurable.

Measurements with three-dimensional computed tomography

Tomographs were obtained in the resting position of the mandible using a high-speed advantage-type computed tomography (CT) generator (Light Speed Plus: GE Healthcare, Milwaukee, WI, USA), with each sequence taken 1.25 mm apart in the horizontal plane parallel to the Frankfurt horizontal (FH) plane for a three-dimensional (3-D) reconstruction image (120 kV, average 150 mA, 0.7 sec / rotation, helical pitch 0.75). The resulting images were stored in the attached workstation computer (Advantage Workstation ver. 4.2: GE healthcare, Milwaukee, WI, USA), and 3-D reconstruction was performed using a volume- rendering method. A frontal view of the

3-D image was reconstructed by superimposition. The distances between the infraorbital foramen and the nearest osteotomy line (IO), as well as between the infraorbital foramen and the nearest plate/screw position (IP), were measured using the attached computer (Figs. 2A and B).

Furthermore, correlation to the amount of maxillary advancement and impaction (elongation) were also examined.

29 patients were divided into the PLLA plate group and titanium plate group. Next, they were divided into pterygoid plate fracture and non fracture group, and compared statistically.

Data was statistically analysed with StatView™ version 4.5 software (ABACUS Concepts, Inc., Berkeley, CA, USA). Differences were considered significant at $P < 0.05$.

Results

In 23 of 58 (39.7%) sides of upper lips following Le Fort I osteotomy, TSEP was measurable within 1 week; 30 sides (67.2%) within 2 weeks; 40 sides (69.0%) within 1 month; 41 sides (70.7 %) within 3 months; 52 sides (89.7 %) within 6 months; and all 58 sides (100 %) recovered within 1 year.

The average measurable period and standard deviation of TSEP of the upper lip was 9.7 ± 13.9 weeks following Le Fort I osteotomy.

The average IO and standard deviation was 12.8 ± 3.2 mm, and the average IP and standard deviation was 10.2 ± 2.3 mm.

There was no significant correlation between the recovery period in upper lip hypoesthesia and IO ($R=0.066$, $R^2=0.004$, RMS Residual=15.453, $p=0.6251$). There was also no significant correlation between the recovery period in upper lip hypoesthesia and IP ($R=0.113$, $R^2=0.013$, RMS Residual=15.387, $p=0.3965$) (Fig. 3).

There were no significant correlations between the recovery period in upper lip hypoesthesia and the amount of maxillary advancement ($R=0.061$, $R^2=0.004$, RMS Residual=15.457, $p=0.6474$) or between the recovery period of hypoesthesia and impaction ($R=0.094$, $R^2=0.009$, RMS Residual=15.418, $p=0.4818$).

There was no significant difference between the PLLA plate (10.7 ± 14.4 weeks) and the titanium plate (13.5 ± 21.3 weeks) in the recovery period in upper lip hypoesthesia.

When comparing the pterygoid plate fracture group and non fracture group, the average measurable period and standard deviation of TSEP of upper lip was 8.6 ± 11.7 weeks following Le Fort I osteotomy with pterygoid plate fracture, and 11.7 ± 17.1 weeks in the patients who underwent Le Fort I osteotomy without pterygoid plate fracture. There was no significant difference between pterygoid plate fracture group and non fracture group.

Discussion

The sensory nerve disturbance following Le Fort I osteotomy has been reviewed (AL-Din et al., 1996; Schultze-Mosgau et al., 2001). AL-Din et al. (1996) reported that cold sensation, pin-prick sensation, and fine touch on the face returned to the

preoperative level in all patients by 6 weeks postoperatively. Schultze-Mosgau et al. (2001) reported that with conventional clinical sharp-blunt and 2-point discrimination tests, the incidence of temporary impairment was 81% for the infraorbital nerve. The rate of permanent sensory disturbance with conventional clinical testing was 6% and obvious infraorbital recovery was found after 1 to 3 months.

TSEP, one of the somatosensory evoked potentials of the peripheral nerves, has been previously been used to investigate the causal factors of trigeminal sensory hypoesthesia after sagittal ramus osteotomy. The potential changes of cerebral origin can be detected on the scalp in human subjects after electrical stimulation of the peripheral nerves. Trigeminal hypoesthesia is indicated by a prolonged detection of potential changes on the scalp after peripheral electrical stimulation (a latency delay). It may be induced by various causal factors, such as compression or decompression injury, bone cut, fixation method, patient age, or the amount of segmental movement (August et al., 1998; Blomqvist et al., 1998; Westermark et al., 1998a; Westermark et al., 1998b).

Rosenberg and Sailer (1994) reported that no correlation could be found between the amount of anterior maxillary movement and size of the hypoesthetic area of infraorbital nerve distribution. They speculated that the difficulty in positioning the maxilla, the duration of the operation, and last but not least, the position of the hooks are of the utmost importance regarding the degree of postoperative hypoesthesia. These factors are probably more important than the amount of maxillary movement. In this study, there was also no correlation between upper lip hypoesthesia and the amount of maxillary movement. In their comparison between miniplate and wires in

Le Fort I osteotomy, miniplates gave rise to more hypoesthesia of the oral mucosa than wires. This may be due to the fact that more periosteal reflection is needed for the fixation of miniplates and so more fine nerve endings are traumatized. Although, there was no significant difference between the titanium miniplate and PLLA plates in this study, it was impossible to make comparisons between wire and titanium fixation (rigid and non-rigid fixation).

The generally accepted classification of peripheral nerve lesions is as follows (Stitik et al., 1999.; Kumar et al, 2007). 1. Neuropraxia: involves no nerve lesion, but only a temporary conduction block of several hours to months; 2. Axontmesis: a lesion of the axons with intact endoneurium and perineurium, and the distal part of the nerve will demonstrate a Wallerian degeneration; and 3. Neurotmesis: the complete transection of the peripheral nerve. In this study, there was no significant correlation between the recovery period in upper lip hypoesthesia and the distances (IP and IO). Hypoesthesia of the upper lip was recovered within 1 year in all subjects. Furthermore, the average IO and standard deviation was 12.8 ± 3.2 mm, and the average IP and standard deviation was 10.2 ± 2.3 mm. These results suggested that hypoesthesia of the upper lip was a transient phenomenon, and IO and IP were distant enough not to damage the infraorbital alveolar nerve. This temporary hypoesthesia in this study must be classified as neuropraxia. When the labial flap was detached from maxillary bone, this phenomenon could be avoided more or less.

The problem of pterygomaxillary separation during Le Fort I osteotomies has been investigated in numerous studies aimed at reducing complications. Many reports describe major and minor complications related to the pterygomaxillary junction.

These include arteriovenous fistulae, ophthalmologic complications, and neurologic complications (Precious et al., 1991; Precious et al., 1993; Cheng and Robinson, 1993; Lanigan and Guest, 1993). The majority of these complications are caused by malpositioning of the osteotome or by fractures that occur during separation and extend to the pterygoid plate, the base of skull, or the tuberosity. However, the pterygoid plate fracture does not directly cause the complication but subsequent bleeding and neural damage may create severe problems. When the maxillary segment is moved and positioned after fracture, interference between the maxilla and the pterygoid process may occur in the pterygomaxillary region. The palatine artery also runs in the medial wall of sinus, so trimming the posterior part of the maxillary segment, including the medial wall of the sinus, may be difficult.

Hai and Egyedi (1989) reported a technique to reposition the maxilla posteriorly while preserving the pterygoid plates and the greater palatine neurovascular bundle. This approach to the bone was a combination of the conventional Le Fort I and Wassmund procedure. However, it was difficult to remove the interference between segments using this method. Therefore, the “artificial” fracture of the pterygoid process is occasionally necessary to make this technique safer.

In preoperative simulations, we generally do not plan for a maxillary setback. However, a complete or partial maxillary setback rarely produces an ideal profile, especially in cases of maxillary protrusion, retrognathism, or bimaxillary asymmetry. Furthermore, Japanese patients with prognathism or asymmetry tend to have comparatively lower noses than similar Caucasian patients. For example, in a case of asymmetry with an anteroposteriorly normal maxillary position, maxillary

advancement may change the shape of the nose so that it is not aesthetically acceptable. To avoid this, we frequently use a Le Fort I osteotomy to change just the maxillary occlusal plane tilt in the lateral or frontal view without maxillary advancement.

Our previous study demonstrated that safe artificial fracture of the pterygoid process could be performed with the ultrasonic bone curette (SONOPET®) (Ueki et al., 2004). The patients who had undergone Le Fort I osteotomy and “artificial” fracture of the pterygoid plates had no complications postoperatively. However, if the ultrasonic bone curette was not used, such a safe operation could not be performed. From the result of this study, even if the pterygoid plates were fractured, it was found that there was no difference in postoperative hypoaesthesia of upper lip.

Conclusion

Hypoaesthesia could appear in the upper lip following Le Fort I osteotomy. However, osteotomy line, plate/screw position and pterygoid plate fracture in Le Fort I osteotomy did not affect the recovery period of upper lip hypoaesthesia with TSEP. Furthermore, the correlations between the recovery period of upper lip hypoaesthesia and the amount of maxillary movement could not be found. Although surgical factors affect the recovery period of the upper lip after Le Fort I osteotomy could not be found, it could be shown that hypoaesthesia of the upper lip could recover objectively in most cases. Thus, to prevent long-term hypoaesthesia of the upper lip, it is most important to avoid damaging the infraorbital nerve directly, as was the case in this study.

References

1. Al-Din OF, Coghlan KM, Magennis P: Sensory nerve distance following Le Fort I osteotomy. *Int J Oral Maxillofac Surg* 25:13-19, 1996.
2. August M, Marchena J, Conady J, Kaban L: Neurosensory deficit and functional impairment after sagittal split ramus osteotomy: a long-term follow-up study. *J Oral Maxillofac Surg* 56:1231-1235, 1998.
3. Blomqvist JE, Alberius P, Isaksson S: Sensibility following sagittal split osteotomy in the mandible: a prospective clinical study. *Plast Reconstr Surg* 102:325-333, 1998.
4. Cheng LH, Robinson PP: Evaluation of a swan's neck osteotome for pterygomaxillary dysfunction in the Le Fort I osteotomy. *Br J Oral Maxillofac Surg* 31: 52-53, 1993.
5. Emshoff R, Kranewitter R, Gerhard S, Norer B, HellB. Effect of segmental Le Fort I osteotomy on maxillary tooth type-related pulpal blood-flow characteristics. *Oral Surg Oral Med Oral Pathol Oral Radiol Endod* 89:749-752, 2000.
6. Hai HK, Egyedi P: Preserving the pterygoid plates in posterior repositioning of the Le Fort I osteotomy. *J Cranio-Maxillofac Surg* 17: 219-221, 1989.
7. Harada K, Sato M, Omura K. Blood-flow neurosensory changes in the maxillary dental pulp after differing Le Fort I osteotomies. *Oral Surg Oral Med Oral Pathol Oral Radiol Endod* 97:12-17, 2004.
8. Justus T, Change BL, Bloomquist D Ramsay DS: Human gingival and pulpal blood flow during healing after Le Fort osteotomy. *J Oral Maxillofac Surg* 59:2-7, 2001.

9. Kumar S, Hassouna H, Penematsa S. Clinical and user-friendly classification of traumatic digital nerve injuries of hand. *Arch Orthop Trauma Surg* 127:527-530, 2007.
10. Lanigan DT, Guest P: Alternative approaches to pterygomaxillary separation. *Int J Oral Maxillofac Surg* 22: 131-138, 1993.
11. Nagasao T, Miyamoto J, Hikosaka M, Nagasao M, Tokumaru Y, Ogawa K, Nakajima T: Appropriate diameter for screws to fix the maxilla following Le Fort I osteotomy: An investigation utilizing finite element analysis. *J Craniomaxillofac Surg* 35:227-233, 2007.
12. Nakagawa K, Ueki K, Matsumoto N, Takatsuka, Yamamoto E, Ooe H: The assessment of trigeminal sensory nerve paraesthesia after bilateral sagittal split osteotomy: modified somatosensory evoked potentials recording method. *J Craniomaxillofac Surg* 25: 97-101, 1997.
13. Nakagawa K, Ueki K, Takatsuka S, Takazakura D, Yamamoto E: Somatosensory-evoked potential to evaluate the trigeminal nerve after sagittal split osteotomy. *Oral Surg Oral Med Oral Pathol Oral Radiol Endod* 91: 146-152, 2001.
14. Nakagawa K, Ueki K, Takatsuka S, Yamamoto E: Trigeminal nerve hyperesthesia after sagittal split osteotomy in setback cases: Correlation of postoperative computed tomography and long-term trigeminal somatosensory evoked potentials. *J Oral Maxillofac Surg* 61: 898-903, 2003.
15. Posnic JC, Al-Qattan MM, Pron G: Facial sensitivity in Adolescents with and without cleft 1 year after undergoing Le Fort I osteotomy. *Plast Reconstr Surg* 94: 431-435, 1994.

16. Precious DS, Morrison A, Ricard D: Pterygomaxillary separation without the use of an osteotome. *J Oral Maxillofac Surg* 49: 98-99, 1991.
17. Precious DS, Goodday RH, Bourget L, Skulsky FG: Pterygoid plate fracture in Le Fort I osteotomy with and without pterygoid chisel: a computed tomography scan evaluation of 58 patients. *J Oral Maxillofac Surg* 51: 151-153, 1993.
18. Rosenberg A, Sailer HF: A prospective study on change in the sensibility of the oral mucosa and the mucosa of the upper lip after Le Fort I osteotomy. *J Cranio-Maxillofac Surg* 22: 286-293, 1994.
19. Sato M, Harada K, Okada Y, Omura K: Blood-flow change and recovery of sensitivity in the maxillary dental pulp after a single-segment Le Fort I osteotomy. *Oral Surg Oral Med Oral Pathol Oral Radiol Endod* 95:660-664, 2003.
20. Scultze-Mosgau S, Krems H, Ott R, Neukan FW: A prospective electromyographic and computer-aided thermal sensitivity assessment of nerve lesions after sagittal split osteotomy and Le Fort I osteotomy. *J Oral Maxillofac Surg* 59:128-138, 2001.
21. Stitik TP, Foye PM, Nadler SF: Electromyography in craniomaxillofacial trauma. *J Cranio-Maxillofac Trauma* 52:39-46, 1999.
22. Ueki K, Nakagawa K, Marukawa K, Yamamoto E: Le Fort I osteotomy using an ultrasonic bone curette to fracture the pterygoid plates. *J Cranio-Maxillofac Surg* 32:381-386, 2004.
23. Westermark A, Bystedt H, von Konow L: Inferior alveolar nerve function after mandibular osteotomies. *Br J Oral Maxillofac Surg* 36:425-428, 1998a.
24. Westermark A, Bystedt H, von Konow L: Inferior alveolar nerve function after sagittal split osteotomy of the mandible: correlation with degree of intraoperative

nerve encounter and other variables in 496 operations. Br J Oral Maxillofac Surg
36:429-433, 1998b.

Figure legends

Fig.1 TSEP wave form. Measurable periods of TSEP were defined as those periods before the peaks of N1, P1, N2, P2 and N3 that were clearly identified in early components of the TSEP wave. Amplitude value (μV) and latency periods (msec) are shown in this graph.

Fig.2 Measurement with the 3DCT image. (A) Distance between the infraorbital foramen and the nearest osteotomy line (IO). (B) Distance between the infraorbital foramen and the nearest plate screw position (IP).

Fig.3 Results of the simple regression analysis. (A) Between recovery period in upper lip hypoaesthesia and the distance between the infraorbital foramen and the nearest osteotomy line (IO). (B) Between recovery period in upper lip hypoesthesia and the distance between the infraorbital foramen and the nearest plate screw position (IP).

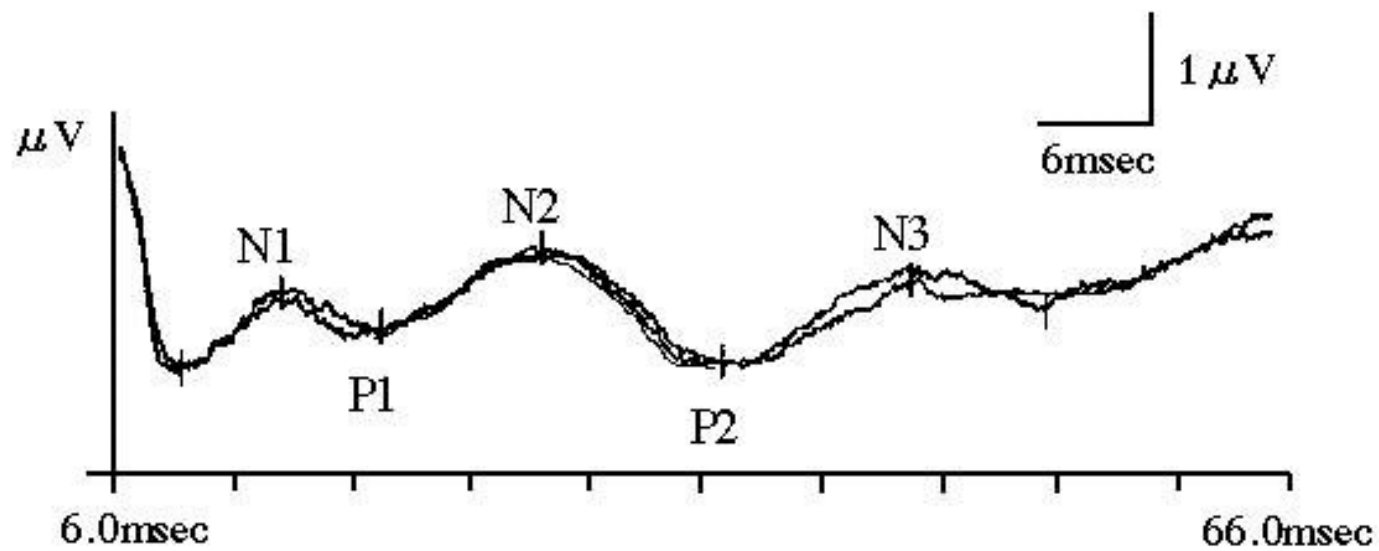
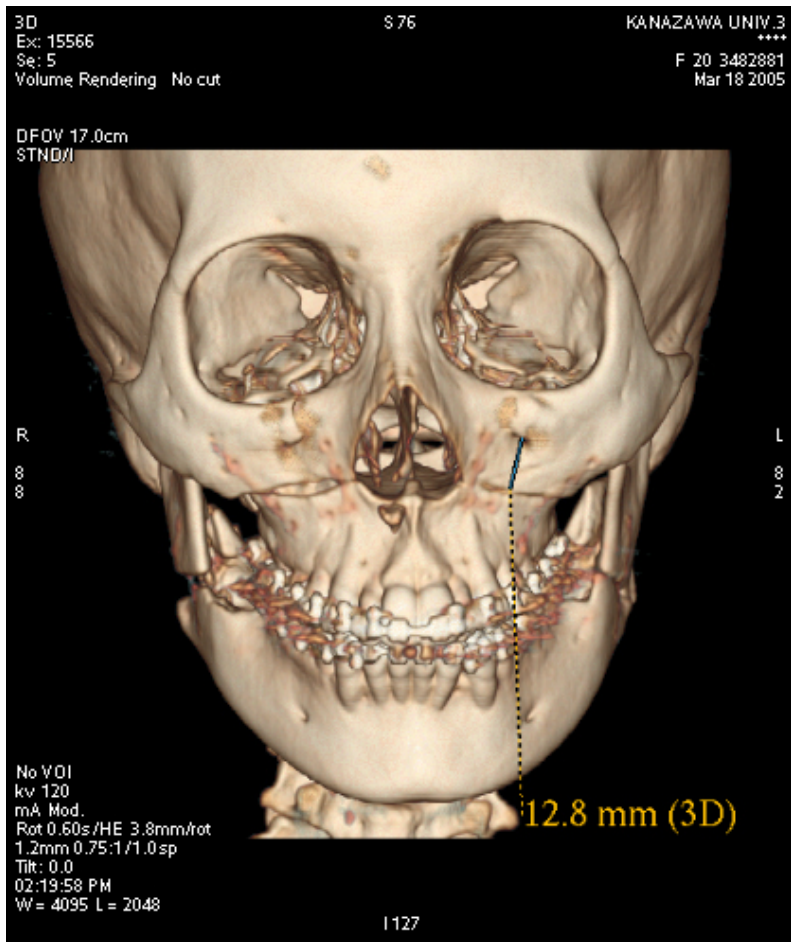
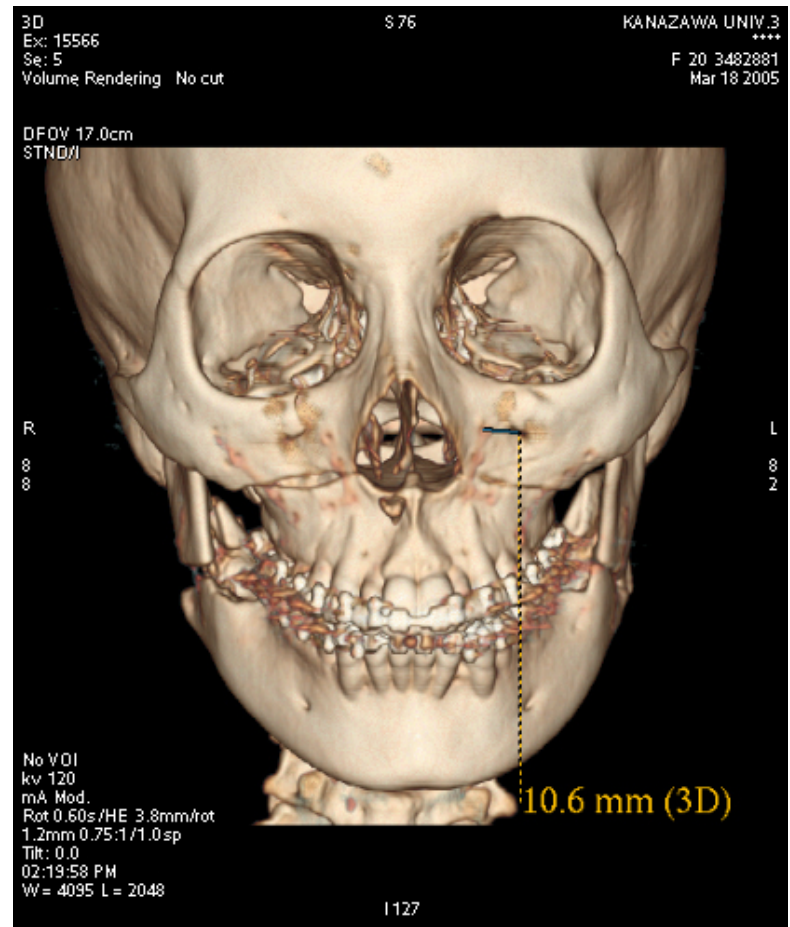


Fig.1

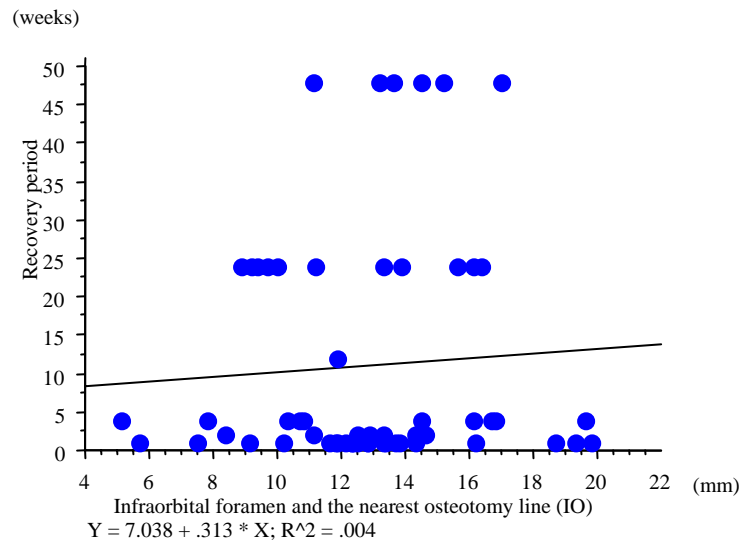


A

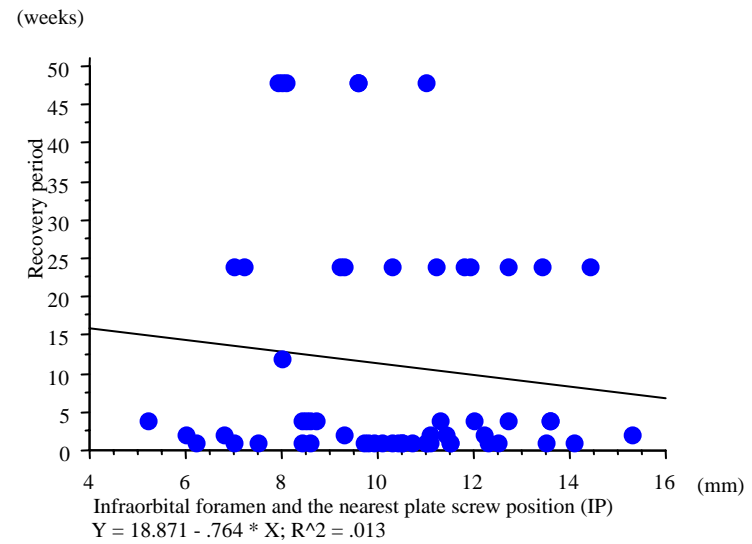


B

Fig.2



A



B

Fig.3