

# Horizontal changes in the condylar head after sagittal split ramus osteotomy with bent plate fixation

著者	Ueki Koichiro, Degerliyurt Kagan, Hashiba Yukari, Marukawa Kohei, Nakagawa Kiyomasa, Yamamoto Etsuhide
journal or publication title	Oral Surgery, Oral Medicine, Oral Pathology, Oral Radiology, and Endodontics
volume	106
number	5
page range	656-661
year	2008-11-01
URL	<a href="http://hdl.handle.net/2297/11736">http://hdl.handle.net/2297/11736</a>

doi: 10.1016/j.tripleo.2008.03.016

## **Horizontal changes in the condylar head after sagittal split ramus osteotomy with bent plate fixation**

KOICHIRO UEKI, DDS, PhD, # KAGAN DEGERLIYURT, DDS, \* YUKARI HASHIBA, DDS, § KOHEI MARUKAWA, DDS, PhD, ¶ KIYOMASA NAKAGAWA, DDS, PhD, † and ETSUHIDE YAMAMOTO, DDS, PhD, ‡

<sup>1</sup>Department of Oral and Maxillofacial Surgery, Graduate School of Medicine, Kanazawa University, 13-1 Takaramachi, Kanazawa 920-8641, Japan.

<sup>2</sup> Gazi University, School of Dentistry, Department of Oral and Maxillofacial Surgery, 8. Cad 82. Sok. 06510 Emek, Ankara, Turkey.

# Assistant Professor<sup>1</sup>

\* Research fellow<sup>1</sup> and Resident<sup>2</sup>

§ Graduate Student<sup>1</sup>

¶ Clinical Instructor<sup>1</sup>

† Associate Professor<sup>1</sup>

‡ Professor and Head<sup>1</sup>

Address correspondence to: Koichiro Ueki, DDS, PhD.

Department of Oral and Maxillofacial Surgery, Graduate School of Medicine, Kanazawa University, 13-1 Takaramachi, Kanazawa 920-8641, Japan.

Tel: +81-76-265-2444; Fax: +81-76-234-4268

E-mail: kueki@med.kanazawa-u.ac.jp

**Horizontal changes in the condylar head after sagittal split ramus osteotomy with bent plate fixation**

## **Horizontal changes in the condylar head after sagittal split ramus osteotomy with bent plate fixation**

### **Abstract**

**Purpose.** The purpose of this study was to evaluate the horizontal changes in the condylar head with bent plate fixation after sagittal split ramus osteotomy (SSRO) with and without a Le Fort I osteotomy.

**Subjects and Methods.** Of 47 Japanese patients with mandibular prognathism, 24 underwent SSRO and 23 underwent SSRO in combination with a Le Fort I osteotomy. A 3-5 mm gap was made between the proximal and distal segments and a bent plate was fixed with 4 screws in each side of the mandible. The angle of the condylar long axis, as well as the antero-posterior and medio-lateral displacement of the condylar head were assessed preoperatively and postoperatively by computed tomography (CT).

**Results.** There was no significant difference in reduction in mandibular length between SSRO alone and SSRO with Le Fort I on the axial view of a 3D CT. There were no significant differences between pre- and postoperative horizontal changes in the condylar long axis or in the antero-posterior and medio-lateral displacement of the condylar head, although the length of the proximal segment in SSRO with Le Fort I osteotomy was significantly shorter than in SSRO alone ( $P < 0.05$ ).

**Conclusion.** These results suggest that the use of a bent plate for SSRO does not change preoperative angle or position significantly in setback surgery, regardless of the addition of Le Fort I osteotomy.

### **Key words:**

Sagittal split ramus osteotomy

Le Fort I osteotomy

Bent plate

condylar position

## **Introduction**

The sagittal split ramus osteotomy (SSRO) is a standard surgical method<sup>1</sup> for the correction of jaw deformities. Alterations in condylar position from surgery can lead to malocclusion associated with the risk of early relapse,<sup>2,3</sup> and also favor the development of temporomandibular disorders (TMD).<sup>4-6</sup> For these reasons, several positioning devices have been proposed and applied, but generally do not provide better long-term outcomes in either mandibular advancement or setback surgery.<sup>7</sup>

We previously used bent titanium plates to secure fragments in 20 patients without a positioning device. The angle of the bent plates was adjusted to avoid displacement of the condyle after osteotomy using the preoperative position of the condyle on submental-vertical (S-V) cephalograms. The postoperative position of the condyle was assessed on X-ray film, and changes in temporomandibular joint (TMJ) function were evaluated. The condylar long axis differed significantly on X-ray film between patients using a standard titanium plate and those using a bent plate; there was no sign of TMJ functional impairment in the bent-plate group.<sup>8</sup> However, we did not compare outcomes with SSRO with Le Fort I osteotomy. The comparison in horizontal condylar position change antero-posteriorly and medio-laterally was also not examined, although it was considered to be as important as horizontal angle change of condyle.

The Le Fort I osteotomy is a popular technique for correcting and treating dentofacial deformities,<sup>9</sup> and particularly severe mandibular prognathia with and without maxillary deformity. The purpose of this study is to evaluate the horizontal changes in the condylar head with bent plate fixation without a condylar repositioning device after SSRO with and without a Le Fort I osteotomy.

## **Patients and Methods**

### Patients

The 47 Japanese adults (men: 13, women: 34) in this study presented with jaw deformities diagnosed as mandibular prognathism with and without maxillary deformity. At

the time of orthognathic surgery, the patients ranged in age from 16 to 42 years, with a mean age of 23.3 years (standard deviation, 6.3 years). Informed consent was obtained from patients and the study was approved by Kanazawa University Hospital.

### Surgery

Of the 45 patients in this study, 24 patients (men: 7, women: 17, mean age: 24.0 years, standard deviation: 7.0 years) underwent bilateral SSRO. The other 23 patients (men: 6, women: 17, mean age: 22.7, standard deviation: 5.7 years) underwent SSRO and a Le Fort I osteotomy; rigid fixation was achieved with mini-plates and monocortical screws.

To prevent intraoperative condylar axial rotation, model surgery was performed preoperatively with reference to the S-V projection .

Before surgery, all patients were taken S-V cephalogram, and the simulation was performed. At first a distal segment including the lower dental arch was set back and rotated according to the upper dental arch on the submental-vertical cephalometric trace. A cross point between the contours of preoperative and postoperative mandible was mostly found on the deviation side (Fig. 1).

When the proximal and distal segments are fixed with straight plates after BSSO, proximal segments containing the condylar head cause internal rotation, and the posterior aspect of the distal segment on the deviated side sometimes interferes with the proximal segment (Fig. 2).

Suggesting that setting the osteotomy line at the cross point can reduce the distance of the gap between the proximal and distal segments on the deviation side. On the other hand, on the non-deviation side the cross point did not exist on the geometrical model in most of the cases of mandibular prognathism with asymmetry. In other words, the gap mostly occurs between the proximal and distal segments on the non-deviation side, wherever the osteotomy line is set. Osteotomy lines and bending angle were determined. As a result of this simulation, it was found that the osteotomy line on the deviation side should be set at the posterior part of the mandibular body to prevent interference between the proximal segment and the distal segment in patients with mandibular asymmetry. It was assumed that

the use of bent plates was the most efficient and simple method to prevent proximal segments internal rotation (Fig. 3)<sup>8</sup>.

After approximately 1 week of inter-maxillary fixation, elastic was placed to maintain ideal occlusion. All patients received orthodontic treatment before and after surgery. Condylar angle was stable 3 month after surgery according to our previous study<sup>8</sup>, so that CT could be taken just before surgery and 3 months after surgery for all patients. TMJ symptoms were objectively examined with manipulation by surgeons, there were recorded and evaluated preoperatively and 1 year postoperatively.

The patients were placed in the gantry with the tragacanthal line perpendicular to the ground for CT scanning. They were instructed to breathe normally and to avoid swallowing during the scanning process. CT scans were obtained in the radiology department by skilled radiology technicians using a high-speed, advantage-type CT generator (Light Speed Plus; GE Healthcare, Milwaukee, WI, USA) with each sequence taken 1.25 mm apart for the 3D reconstruction (120 kV, average 150 mA, 0.7 sec/rotation, helical pitch 0.75). The resulting images were stored in the attached workstation computer (Advantage workstation version 4.2; GE Healthcare, Milwaukee, WI, USA) and 3D reconstruction was performed using the volume rendering method. ExaVision LITE version 1.10 medical imaging software (Ziosoft, Inc, Tokyo, Japan) was used for 3D morphologic measurements.

#### Measurements of condylar position and angle using CT

The following items were measured with a submento-vertex projection from the 3DCT image (Fig 4).

1, Mandibular length: the distance between Pog (pogonion) to the most lateral point of the condyle.

2, Proximal segment length: the distance between the most anterior point of the proximal segment and the most lateral point of the condyle, measured postoperatively.

Next, the horizontal slice image where two condyles could be recognized at maximum square (including medial and lateral pole of the condyle) was selected to measure the condylar position and angle. The RL line was determined as the line between the most

anterior points of bilateral auricles. A perpendicular line through the most posterior point of nasal septum to the RL line was determined as the AP line.

The following items were measured pre- and postoperatively and bilaterally (Fig 5).

1, Condylar angle: the angle between the RL line and the condylar long axis (the line between the most medial and lateral points)

2, RL distance: the distance between the most medial point of the condyle and the AP line.

3, AP distance: the distance between the most medial point of the condyle and the RL line.

All CT images were measured by an author (K.D). Fifteen patients were selected randomly and CT images were measured again 10 days later. A paired t test was applied to the first and second measurements. The difference between first and second CT measurements was insignificant ( $p > .05$ ).

### Statistical analysis

Data were compared between groups with a non-paired t-test and between pre and postoperative value with a paired t-test using the Stat View™ version 4.5 software program (Abacus Concepts, Inc., Berkeley, CA, USA). The differences were considered significant at  $p < 0.05$ .

### **Results**

The mean setback amount was  $7.0 \pm 3.1$  mm on the right side and  $7.0 \pm 3.4$  mm on the left side in the SSRO group, and  $7.3 \pm 3.0$  mm on the right side and  $6.6 \pm 3.3$  mm on the left side in the SSRO with Le Fort I osteotomy group. These differences were not significant. The pre- and postoperative mandibular lengths were not different between groups, but the SSRO group with Le Fort I osteotomy produced a shorter proximal segment length than SSRO group ( $P < 0.05$ ). The changes in RL distance, AP difference and condylar angle were not significant between groups (Tables 1 and 2).



## TMJ symptoms

The most frequent preoperative TMJ symptoms were abnormal sound (clicking and crepitus) and slight pain when opening the mouth; none of the patients reported trismus. Symptoms were improved by surgery in 90.0% of patients (84.6% of joints) who underwent only SSRO, and in 88.8% of patients (90.0% of joints) who underwent SSRO with a Le Fort I osteotomy, which was not significantly different (Table 3).

## **Discussion**

The position of the condyle frequently changes after orthognathic procedures such as SSRO and intraoral vertical ramus osteotomy (IVRO).<sup>10-15</sup> Displacement of the condyle from/in the fossa can be caused by abnormal mandibular movement, methods used for fixation, segment rigidity, or masticatory muscle tension. Condylar displacement, especially after SSRO, can cause postoperative complications. Furthermore, condylar displacement with altered inclination of the condylar long axis can substantially affect postoperative function of the TMJ. Simple sagittal displacement of the condyle can usually be corrected by postoperative adjustment of the occlusion. However, condylar displacement with axial rotation does not respond to occlusal adjustment and has an increased risk of TMD.<sup>13,15</sup> Rotational changes also contribute to idiopathic condylar resorption after SSRO.<sup>8,16,17</sup>

Westesson et al<sup>18</sup> found that the mean horizontal condylar angle was most acute in joints with normal superior disc position (mean 21.2 degrees) and was less so in joints with disk displacement (29.7 degrees for disk displacement without reduction) and/or with degenerative joint disease (36.5 degrees). Fernandez Sanroman et al<sup>19</sup> found that the mean horizontal condylar angle in the class II group was significantly larger than in the control group, and that the larger condylar angle could be an etiological factor for disc displacement and degenerative joint disease. Our previous study also showed a mean

horizontal condylar angle for the class III symmetry group of 12.0 degrees on the right and 11.8 degrees on the left<sup>8</sup>. If the skeletal pattern is different, TMJ morphology and the condylar long axis would also be different, and changing the occlusion and underlying skeleton may change in condylar long axis.

In our previous study, the horizontal condyle long axis increased significantly on the right side in the SSRO alone group.<sup>20</sup> However, here there were no differences between the pre and postoperative angle of the condylar long axis, and we found no medio-lateral or antero-posterior displacement. This result suggests that even if the condylar repositioning device was not used, the condylar position and angle would not change significantly, even though we did not strive to maintain the preoperative condylar position. The condylar position data were widely dispersed, which may have prevented statistical significance. The most favorable postoperative condylar angle may not match the preoperative one, but would not be dramatically different except for cases with TMD or asymmetry. The dynamic stable position in TMJ is the most favorable on the basis of our previous study.<sup>8</sup>

SSRO improved TMJ symptoms despite being unable to change preoperative disc position or correct anterior disc displacement.<sup>20</sup> Using CT here, we also did not observe significant changes in condylar position or angle, but the gap between the proximal and distal segment created by the bent plate might reduce the stress on TMJ.

Ellis stated that the gap has to be eliminated, minimized, or maintained to prevent displacement of the condyles medially or laterally within the mandibular fossa.<sup>21</sup> However, there is a difference between setback surgery and advance surgery. In fact, we did not observe a postoperative displacement of the condyle despite the gap formation. Removal of the bony interference between the segments is necessary to minimize the gap between the proximal and distal segments. In class II advance surgery, the gap may induce postoperative facial asymmetry. However, in Japanese class III cases, the gap can correct facial asymmetry. The bony contact area between the segments can be kept in setback surgery to adjust the osteotomy line position at the anterior part of the proximal segment. Moving this osteotomy line to the posterior site can minimize the gap. This might be performed in bimaxillary cases in this study. Therefore, bimaxillary cases might have

shorter proximal segment length. If the osteotomy line moves the posterior site of the ramus to the deviated side in mandibular prognathism with severe asymmetry, SSRO would need to be abandoned<sup>8</sup> and IVRO or intra-oral vertico-sagittal ramus osteotomy (IVSRO)<sup>22</sup> chosen instead.

Surgically-induced increases in the condylar long axis is correlated with increases in side range and incisor path angle, although surgical orthodontic treatment does not significantly change the chewing pattern.<sup>23</sup> This result suggests that changing the condylar long axis is important for the postoperative chewing path and that the preoperative angle of the condylar long axis is not always adequate.

In conclusion, SSRO with and without Le Fort I osteotomy with a bent plate did not change condylar position or angle significantly, but could improve TMJ symptoms without a condylar repositioning device.

## References

- 1) Trauner R, Obwegeser H. The surgical correction of mandibular prognathism and retrognathia and consideration of genioplasty: Surgical procedures to correct mandibular prognathism and reshaping the chin. *Oral Surg Oral Med Oral Pathol* 1957; 10:677-689.
- 2) Harada K, Okada Y, Nagura H, Enomoto S. A new condylar positioning appliance for two-jaw osteotomies (Le Fort I and sagittal split ramus osteotomy). *Plast Reconstr Surg* 1996;98:363-5.
- 3) Leonard M. Preventing rotation of the proximal fragment in the sagittal ramus split operation. *J Oral Surg* 1976;34:942.
- 4) Isberg AM, Isacsson G. Tissue reactions of the temporomandibular joint following retrusive guidance of the mandible. *Cranio* 1986;4:143-8.
- 5) Ellis E 3rd, Hinton RJ. Histologic examination of the temporomandibular joint after mandibular advancement with and without rigid fixation: An experimental investigation in adult *Macaca mulata*. *J Oral Maxillofac Surg* 1991;49:1316-27.
- 6) Rotskoff KS, Herbosa EG, Villa P. Maintenance of the condyle proximal segment position in orthognathic surgery. *J Oral Maxillofac Surg* 1991;49:2-7.
- 7) Gerressen M, Zadeh MD, Stockbrink, Riediger D, Ghassemi A: The functional long-term results after bilateral sagittal split osteotomy (BSSO) with and without a condylar position device. *J Oral Maxillofac Surg* 2006;64:1624-30.
- 8) Ueki K, Nakagawa K, Takatsuka S, Yamamoto E. Plate fixation after mandibular osteotomy. *Int J Oral Maxillofac Surg* 2001;30:490-6.
- 9) Proffit WR, Phillips C, Prewitt JW, Turvey TA. Stability after surgical-orthodontic correction of skeletal Class III malocclusion. 2. Maxillary advancement. *Int J Adult Orthodn Orthognath Surg* 1991; 6: 71-80.
- 10) Hall HD: Mandibular prognathism. 1. Intraoral surgery. Bell WH: Modern practice in orthognathic and reconstructive surgery. 2<sup>nd</sup> Ed, Saunders Co, Philadelphia 1992.p. 2113-2121.

- 11) Nishimura A, Sakurada S, Iwase M, Nagumo M. Position change in the mandibular condyle and amount of mouth opening after sagittal split ramus osteotomy with rigid or nonrigid osteosynthesis. *J Oral Maxillofac Surg* 1997;55:672-676.
- 12) Petersson A, Willmar-Hogeman K: Radiographic change of the temporomandibular joint after oblique sliding osteotomy of the mandibular rami. *Int J Oral Maxillofac Surg* 1989;18:27-31.
- 13) Rotskoff KS, Herbosa EG, Nickels B. Correction of condylar displacement following intraoral vertical ramus osteotomy. *J Oral Maxillofac Surg* 1991;49:1255-6.
- 14) Ritzau M, Wenzel A, Williams S: Changes in condyle position after bilateral vertical ramus osteotomy with and without osteosynthesis. *Am J Orthod* 1989;96:507-13.
- 15) Tornes K, Gilhuus-Moe O, McCallum CA Jr, Wisth PJ. Positioning and mobility of the mandibular condyle after surgical correction of the asymmetric, prognathic mandible. *Int J Adult Orthod Orthognath Surg* 1990;5:29-34.
- 16) Hawang SJ, Haers PE, Sailer HF. The role of posteriorly inclined condylar neck in condylar resorption after orthognathic surgery. *J Craniomaxillofac Surg* 2000; 28: 85-90
- 17) Hoppenreijts TJ, Stoelinga PJ, Grace KL, Robben CM. Long-term evaluation of patients with progressive condylar resorption following orthognathic surgery. *Int J Oral Maxillofac Surg* 1999;28:411-8.
- 18) Westesson PL, Bifano JA, Tallents RH, Hatala MP. Increased horizontal angle of the mandibular condyle in abnormal temporomandibular joints. *Oral Surg Oral Med Oral Pathol* 1991;72:359-63.
- 19) Fernandez Sanroman J, Gomez Gonzalez JM, del Hoyo JA. Relationship between condylar position, dentofacial deformity, and temporomandibular joint dysfunction: an MRI and CT prospective study. *J Cranio-Maxillofac Surg* 1998;26:35-42.
- 20) Ueki K, Marukawa K, Shimada M, Hashiba Y, Nakagawa K, Yamamoto E. Condylar and disc positions after sagittal split ramus osteotomy. *Oral Surg Oral Med Oral Pathol Oral Radiol Endod* 2007;103:342-8.
- 21) Ellis E 3rd. A method to passively align the sagittal ramus osteotomy segments. *J Oral Maxillofac Surg* 2007; 65: 2125-30.

- 22) Choung PH. A new osteotomy for the correction of mandibular prognathism: techniques and rationale of the intraoral vertico-sagittal ramus osteotomy. *J Craniomaxillofac Surg* 1992; 20:153-62.
- 23) Ueki K, Marukawa K, Shimada M, Nakagawa K, Yamamoto E, Niizawa S. Changes in the chewing path of patients in skeletal class III with and without asymmetry before and after orthognathic surgery. *J Oral Maxillofac Surg*. 2005;63:442-8.

## Legends

Fig 1. Model surgery using submental-vertical cephalograms. After the distal segment including the lower dental arch was set back and rotated according to the upper dental arch, osteotomy lines and bending angle were determined.

Fig 2. Use of straight plates. When the proximal and distal segments are fixed with straight plates after BSSO, proximal segments containing the condylar head cause internal rotation, and the posterior aspect of the distal segment on the deviated side sometimes interferes with the proximal segment.

Fig 3. Simulation of the plate bending. The plates were bent to prevent the proximal segments from rotating internally. Note the gap between the osteotomy surfaces on the both sides.

Fig 4. 3DCT image from the axial view. 1) Mandibular length: the distance between Pog (pogonion) to the most lateral point of the condyle. 2) Proximal segment length: the distance between the most anterior point of the proximal segment and the most lateral point of the condyle.

Fig 5. Horizontal CT image. 1) Condylar angle :the angle between the RL line and condylar long axis ( the line between the most medial point and lateral point). 2) RL distance: the distance between the most medial point of the condyle and the AP line. 3) AP distance: the distance between the most medial point of the condyle and the RL line.

Table 1. Result of SSRO group. SD indicates standard deviation.

Table 2. Result of SSRO with Le Fort I osteotomy. SD indicates standard deviation.

Table 3. Number of symptomatic TMJ.

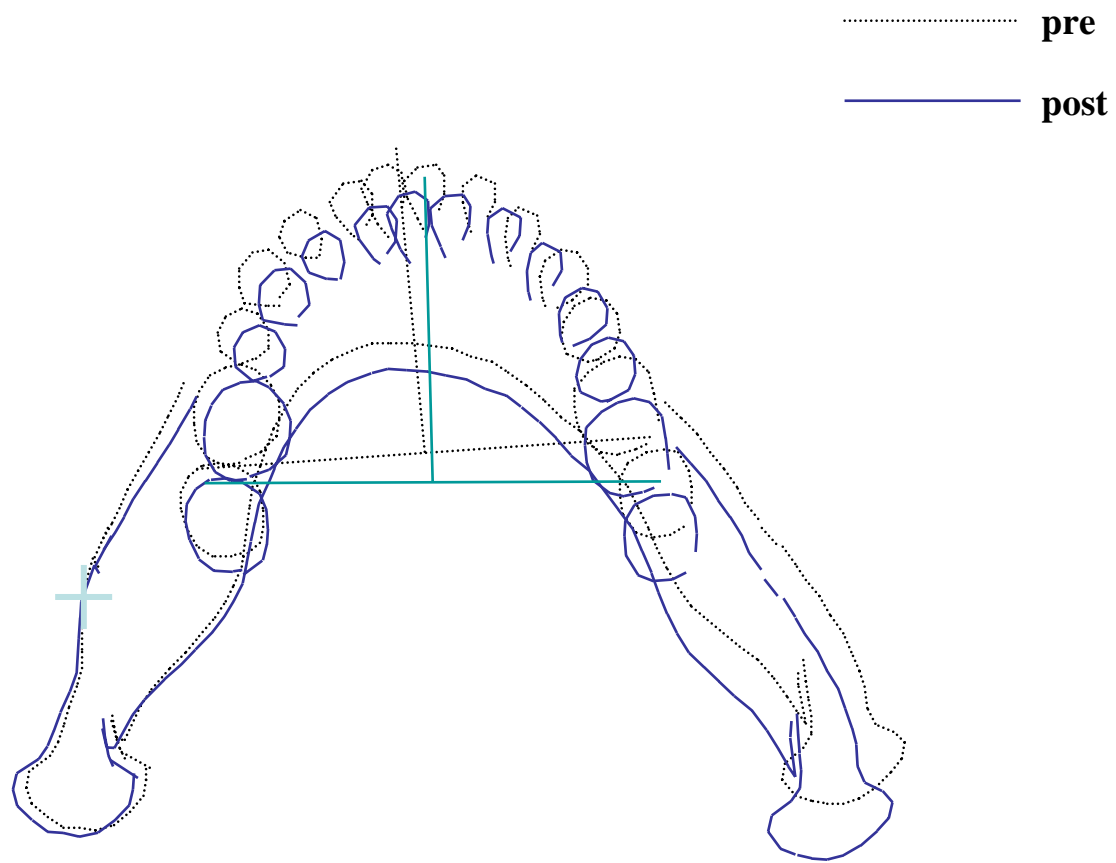


Fig. 1.



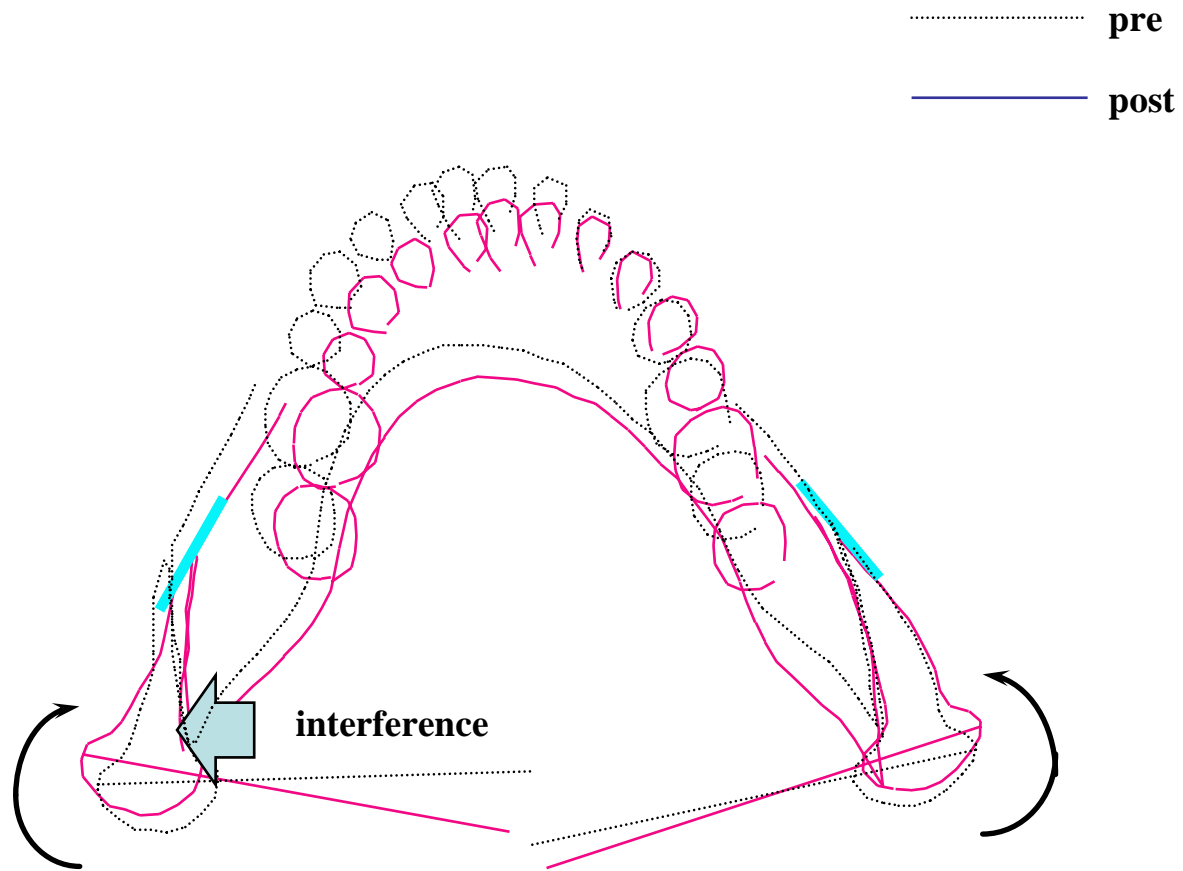


Fig.2.

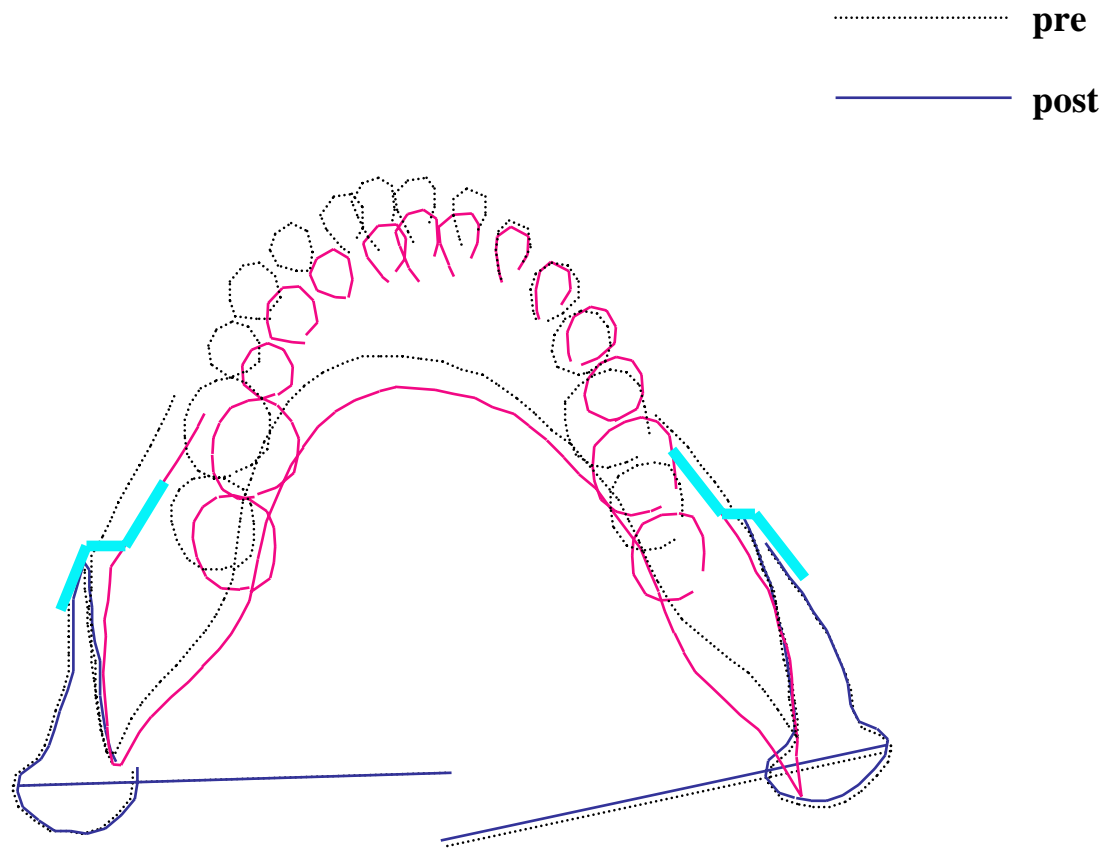


Fig. 3.

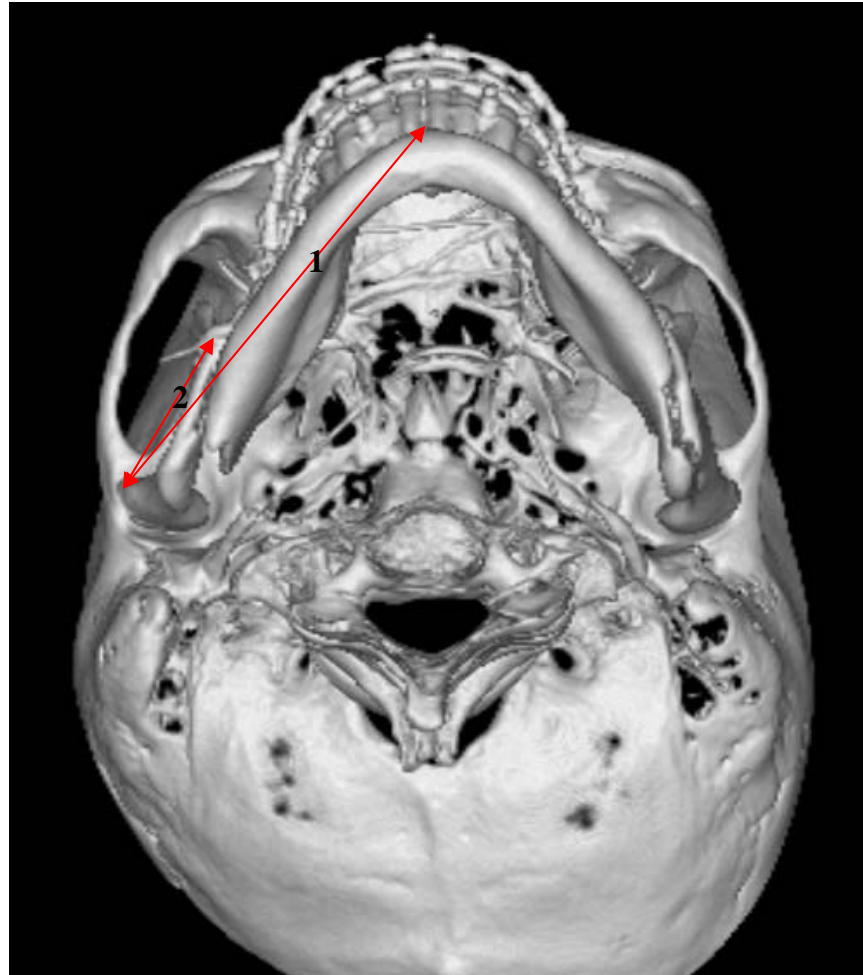

Fig.4.

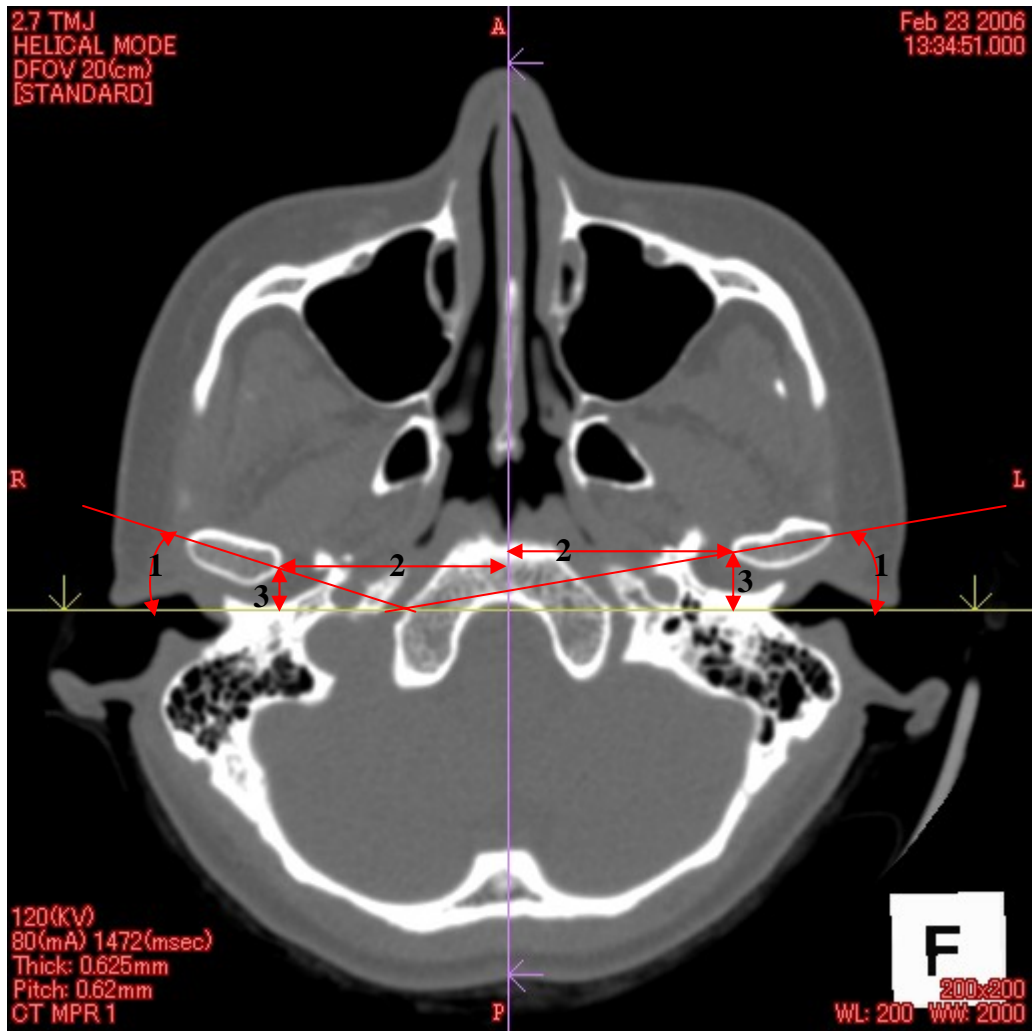


Fig.5.

Table 1.

SSRO alone		Preoperation		Postoperation		Difference	
		Average	SD	Average	SD	Average	SD
Mandibular length(right)	(mm)	89.4	6.6	84.6	6.4	4.7	3.0
Mandibular length(left)	(mm)	88.2	5.8	83.0	5.5	5.2	2.9
Proximal segment length(right)	(mm)			34.5	7.7		
Proximal segment length(left)	(mm)			33.0	8.2		
Condylar angle(right)	(degree)	14.3	6.1	14.7	7.9	0.4	4.4
Condylar angle(left)	(degree)	13.6	5.9	13.5	6.9	-0.1	3.2
RL distance (right)	(mm)	41.4	2.6	41.6	3.1	0.2	1.5
RL distance (left)	(mm)	42.4	2.5	42.1	2.5	-0.4	1.9
AP distance (right)	(mm)	10.0	2.9	10.2	3.5	0.3	2.2
AP distance (left)	(mm)	10.5	2.6	10.4	3.1	-0.1	1.5

Table 2.

SSRO+Le Fort I		Preoperation		Postoperation		Difference	
		Average	SD	Average	SD	Average	SD
Mandibular length(right)	(mm)	88.3	5.4	83.5	6.0	4.8	3.2
Mandibular length(left)	(mm)	87.0	5.0	83.3	4.9	3.8	2.0
Proximal segment length(right)	(mm)			28.5	5.8		
Proximal segment length(left)	(mm)			28.6	5.8		
Condylar angle(right)	(degree)	13.7	9.5	15.3	7.7	1.6	7.1
Condylar angle(left)	(degree)	14.5	8.1	13.6	8.8	-0.8	6.6
RL distance (right)	(mm)	41.0	2.4	40.9	2.4	-0.1	1.4
RL distance (left)	(mm)	41.0	2.8	41.3	2.9	0.3	1.4
AP distance (right)	(mm)	11.3	3.2	11.5	3.0	0.1	1.5
AP distance (left)	(mm)	11.5	3.2	11.3	3.2	-0.2	1.4

Table 3.

Symptomatic patients			
	Preoperatively	Postoperatively	Rate of improvement(%)
SSRO(n=24)	10	1	90
SSROwith Le Fort I (n=23)	9	1	88.8
Symptomatic joints			
	Preoperatively	Postoperatively	Rate of improvement(%)
SSRO(n=48)	13	2	84.6
SSROwith Le Fort I (n=46)	10	1	90