

3 Tesla MRI detects accelerated hippocampal volume reduction in postmenopausal women

著者	Goto Masami, Abe Osamu, Miyati Tosiaki, Inano Sachiko, Hayashi Naoto, Aoki Shigeki, Mori Harushi, Kabasawa Hiroyuki, Ino Kenji, Yano Keiichi, Iida Kyouhito, Mima Kazuo, Ohtomo Kuni
journal or publication title	Journal of Magnetic Resonance Imaging
volume	33
number	1
page range	48-53
year	2011-01-01
URL	http://hdl.handle.net/2297/30542

Title: 3 Tesla MRI Detects Accelerated Hippocampal Volume Reduction in
Postmenopausal Women

Masami Goto, RT,^{1,2*} Osamu Abe, MD,³ Tosiaki Miyati, PhD,² Sachiko Inano, MD,³
Naoto Hayashi, MD,⁴ Shigeki Aoki, MD,⁵ Harushi Mori, MD,³ Hiroyuki Kabasawa,
PhD,⁶ Kenji Ino, RT,¹ Keiichi Yano, RT,¹ Kyouhito Iida, RT,¹ Kazuo Mima, RT,¹ and
Kuni Ohtomo, MD,³

¹Department of Radiological Technology, University of Tokyo Hospital, 7-3-1 Hongo,
Bunkyo-ku, Tokyo 113-8655, Japan

²Graduate School of Medical Science, Kanazawa University

³Department of Radiology, ⁴Department of Computational Diagnostic Radiology and
Preventive Medicine, University of Tokyo Hospital

⁵Department of Radiology, Juntendo University

⁶Japan Applied Science Laboratory, GE Yokogawa Medical Systems

Corresponding Author: Masami Goto

Department of Radiological Technology, University of Tokyo Hospital,
7-3-1 Hongo, Bunkyo-ku, Tokyo 113-8655, Japan

Office: +81-3-3815-5411

Fax: +81-4-7183-3337

E-mail: car6_pa2_rw@yahoo.co.jp

Grant Support: This study was supported in part by a Grant-in-Aid for Scientific Research (C) (2) 18591330 from the Ministry of Education, Science, Sports, and Culture of Japan.

Key Words: Central nervous system; Estrogen; Hippocampus; Magnetic resonance imaging; Menopause; Voxel-based morphometry

ACKNOWLEDGEMENTS

This study was supported in part by a Grant-in-Aid for Scientific Research (C) (2) 18591330 from the Ministry of Education, Science, Sports and Culture of Japan.

ABSTRACT

Purpose: To clarify age-related structural changes specific to hippocampal volume by hierarchizing according to age, gender, and menopausal status. Many studies report the neuroprotective effects of estrogen and age-related brain volume changes; however, there are no studies regarding age-related change specific to hippocampal volume in terms of age, gender, and menopausal status.

Materials and Methods: T1-weighted magnetic resonance images were obtained in 412 healthy adults divided into 8 groups according to age and gender, to analyze brain volume change focusing on hippocampal volume.

Results: Voxel-based morphometry (VBM) revealed significantly smaller gray matter volume in the hippocampus bilaterally in females aged in their fifties (51 of 59 females were at menopause) compared with females in their forties (3 of 46 females were at menopause). No significant difference was found, however, between female groups in their fifties vs. sixties, or sixties vs. seventies; or between male groups in their forties vs. fifties, fifties vs. sixties, or sixties vs. seventies. In addition, VBM revealed significant hippocampal volume reduction bilaterally in all post-menopausal women compared with all pre-menopausal women.

Conclusion: The results of the current study suggest that the menopause may be associated with hippocampal volume reduction.

Introduction

Many studies report the neuroprotective effects of estrogen and describe the relation between estrogen therapy and hippocampal volume (1), the association between hippocampal glucose metabolism and cerebrospinal fluid 17β -estradiol concentration in post-menopausal women (2), the lower risk of incident Alzheimer's disease in post-menopausal women using estrogen (3), and atrophy of hippocampal volume in patients with Alzheimer's disease (4). However, some studies have suggested otherwise (5–8). For example, Low et al. reported that no differences were observed between the control group and the hormone replacement therapy (HRT) group in terms of total gray matter, white matter, hippocampal or amygdalar volumes, severity or volume of white matter hyperintensities, or in different measures of brain atrophy (5). Furthermore, the neuroprotective role of estrogen remains a controversial issue because analytical results are influenced by the type of menopause (i.e., surgical menopause and natural menopause) and the type of cognitive test (i.e., verbal, visual and other memory) (9).

Numerous studies have investigated age-related structural brain changes using MRI, showing a negative correlation between gray matter volume and age, predominantly in the frontal lobes (10–15). These studies reported that the rate of brain volume decline differed according to the focal region and gender (11,13,16–20), as well as a negative correlation between hippocampal volume and age (12,20,21); however, to the best of our knowledge, no study has reported a correlation between menopause and

hippocampal volume.

The aim of the present study was to investigate hippocampal volume change in normal adults divided into eight groups according to their age and gender, using high spatial resolution T1-weighted images with 3.0 tesla (3.0-T) magnetic resonance scanners and voxel-based morphometry (VBM) (22). In addition, we compared hippocampal volume between the pre-menopausal women and post-menopausal women.

MATERIALS AND METHODS

Subjects

A total of 470 subjects who visited our hospital for a personal health-screening program between October 2006 and March 2007 participated in this study. Subjects with a Mini-Mental State Examination (23) score of 26 or lower were excluded from this study. We were not able to exclude mild cognitive impairment. Age at menopause was obtained from all female subjects at interview. The MR images were inspected by a board-certified radiologist (N.H.), and subjects with the following findings were excluded from the study: brain tumors, infarctions, hemorrhage, and white matter lesions graded higher than grade 2 of Fazekas's classification (24). A total of 58 subjects were excluded from this study. We divided the remaining 412 subjects into the following groups according to age and sex: females aged in their forties (mean \pm standard deviation (SD), 45.1 ± 2.9 years, $n = 46$), females in their fifties (55.4 ± 2.7 years; $n = 59$), females in their sixties (64.2 ± 2.6 years; $n = 49$), females in their seventies (74.1 ± 3.0 years; $n = 17$), males in their forties (44.9 ± 2.8 years; $n = 85$), males in their fifties (54.2 ± 3.1 years; $n = 80$), males in their sixties (64.8 ± 2.7 years; $n = 63$), and males in their seventies (73.6 ± 3.0 years; $n = 13$).

Hypertension was defined as maximal blood pressure of 140 mmHg or more, or minimal blood pressure of 90 mmHg or more. Drinking index was defined as amount of alcohol consumed per day (we assumed 33.6 ml ethanol to be equal to 1, i.e. the volume

of ethanol that is approximately equal to one glass of wine) \times (number of drinking days per week). Smoking index was equal to the Brinkmann index and was expressed as (number of cigarettes smoked per day) \times (years of smoking). These data and the subjects' characteristics are summarized in Table 1. Although some studies report that brain atrophy is associated with hypertension (25–28), alcoholism (29,30), and blood glucose level (31–33), subjects were not excluded on the basis of clinical information because we did not wish to generate a supernormal group of subjects. Analysis of variance (ANOVA) with the Bonferroni–Dunn method as a post hoc test was used to compare drinking index, smoking index, and blood glucose level among the groups. The Kruskal–Wallis test was used to compare the number of subjects with hypertension among the age groups. In both tests, statistical significance was set as P value < 0.05 . The protocol was approved by the Ethics Committee of our institution. After the study had been explained to each subject, written informed consent was obtained from all participants.

MRI Scanning Protocol

MRI data were obtained using a 3.0-T scanner (Signa Excite HDx, GE Medical Systems, Waukesha, WI). An 8-channel phased-array brain coil was used as the receiver coil. Three-dimensional fast spoiled-gradient recalled acquisition in the steady state (3D-

FSPGR) was used to obtain 180 contiguous sagittal T1-weighted images with a slice thickness of 1.0 mm for VBM analysis (TR / TE = 5.3 / 1.8 ms; inversion time = 450 ms; flip angle = 15°; field of view = 24 cm; number of excitations = 0.5; 256 × 256 pixel matrix). The voxel dimensions were 0.9375 × 0.9375 × 1.0 mm. An acceleration factor of R = 2.0 was employed for parallel imaging using the Array Spatial Sensitivity Encoding Technique.

Image Preprocessing for VBM

We used Statistical Parametric Mapping 5 (SPM5) software (Wellcome Department of Imaging Neuroscience Group, London, UK; <http://www.fil.ion.ucl.ac.uk/spm>) (34). The 3D-FSPGR images in native space were bias-corrected, spatially normalized, and segmented into gray matter, white matter, and cerebrospinal fluid images (22); voxel size of the normalized images was 2 × 2 × 2 mm. The affine regularization space template from the International Consortium for Brain Mapping was changed from the European to the East Asian brain template. During the modulation step, the voxel values of the normalized gray and white matter images were multiplied by a measure of the relative volumes of the warped and unwarped structures derived from the nonlinear step of spatial normalization using the Jacobian determinant. The total gray and white matter volume, and the total intracranial volume (TIV; measured in ml) were computed by

multiplying the voxel value by the voxel volume and summing the results for all voxels.

The resulting gray matter images were smoothed with a Gaussian kernel of 6 mm full width at half-maximum.

Statistical Analyses for VBM

The normalized data smoothed with 6-mm isotropic Gaussian kernels were analyzed with SPM5 employing the framework of the general linear model. Statistical significance for gray matter volume between the paired sequential age groups (subjects in their forties vs. fifties, fifties vs. sixties, sixties vs. seventies) of both males and females was tested with TIV as the confounding covariate to control for brain volume differences between subjects. To test hypotheses with respect to regionally specific group effects, the estimates were compared with two linear contrasts (increased or decreased gray matter volume). The significance of each region was estimated by distributional approximations from the theory of random Gaussian fields. A *P* value of less than 0.05 corrected with family-wise error (FWE) in voxel difference and a cluster size greater than 30 voxels was considered to be statistically significant.

In addition, regional gray matter volume of the group of all pre-menopausal women (mean \pm SD, 45.8 \pm 3.6 years; n = 51) was compared with that of all post-menopausal women (61.3 \pm 6.7 years; n = 120) in a voxel-wise manner to avoid type 1 or type 2 error due to multiple pairs of group comparisons (e.g. forties vs. fifties, fifties vs. sixties,

sixties vs. seventies for each sex). Because we hypothesized that menopause might have a certain effect on hippocampal volume, we employed small-volume correction for multiple comparisons ($20 \times 30 \times 26$ -mm regions at center ($\pm 26, -24, -8$)) (35). We treated age and TIV as confounding covariates, in this analysis. Previous neuroimaging studies reported that hippocampal volume negatively correlates. We treated age as a confounding covariate to control for age-related volume changes because subjects with a wide range of age were enrolled in this analysis. A *P* value of less than 0.05 corrected with FWE in voxel difference was considered to be statistically significant.

RESULTS

Subjects

ANOVA revealed no significant differences in drinking index ($P = 0.120$), smoking index ($P = 0.204$), or blood glucose level ($P = 0.286$) among the female groups; or in smoking index ($P = 0.948$) or blood glucose level ($P = 0.064$) among the male groups. There was significant difference in drinking index ($P = 0.014$) among the male groups tested with ANOVA. Significant difference was found in drinking index only between the groups of males in their forties vs. sixties ($P = 0.004$) with a post hoc test. Kruskal–Wallis test revealed no significant difference in the number of subjects with hypertension among the female groups ($P = 0.391$) or the male groups ($P = 0.061$).

Differences in Gray Matter Volume Using VBM

Bilateral hippocampal volumes were significantly smaller for females in their fifties than in their forties (Fig. 1). Montreal Neurological Institute (MNI) coordinates of local maxima were 26, -24, -18 (max P value < 0.001, T value = 6.96, cluster size = 208) for the right hippocampus, and -28, -22, -18 (max P value < 0.001, T value = 6.16, cluster size = 161) for the left hippocampus. There was no significant difference in hippocampal volume between the female groups in fifties vs. sixties, sixties vs. seventies, or the male groups in forties vs. fifties, fifties vs. sixties, or sixties vs. seventies. In addition, regional gray matter volume in the group of all pre-menopausal

women was compared with that of all post-menopausal women in a voxel-wise manner. Significant hippocampal volume reduction was found bilaterally in the post-menopausal group compared with the pre-menopausal group, in good agreement with the results of group comparison between females in their forties vs. fifties. MNI coordinates of local maxima were 26, -26, -18 (max P value = 0.031, T value = 4.51) for the right hippocampus, and -30, -18, -24 (max P value = 0.043, T value = 3.59) for the left hippocampus.

DISCUSSION

In the present study, voxel-wise comparison revealed that gray matter volumes in the bilateral hippocampus were significantly smaller in females in their fifties (51 of 59 females were at menopause) than in their forties (only 3 of the 46 females were at menopause). In addition, a significantly smaller hippocampus was found in the post-menopausal group than in the pre-menopausal group. The significant volume reduction found in females in their fifties might have type 1 or type 2 errors due to multiple pairs of group comparisons; however, the significant volume reduction found in the post-menopausal group did not suffer from type 1 or type 2 errors because no multiple comparisons were made. Furthermore, these results were consistent, and complementary to each other. To the best of our knowledge, no previous studies have compared hippocampal volume change in detail according to age and sex. In our study, it is not clear that post-menopause women show faster age-related effects than the pre-menopause women or that there is a sudden drop in hippocampus volume after menopause. We expect that it be clarified by longitudinal study in future investigation.

Many studies have reported a negative correlation between gray matter volume and age, while others have reported that the rate of decline of brain volume differs according to the focal region and sex (11,16-20). Several studies reported findings consistent with age-related reduction in hippocampal volume; however, these reports did not consider the rate of decline between groups divided according to age.

In the present study, hippocampal volume measurements revealed a significant difference bilaterally between the groups of females in their forties vs. fifties; there was no significant difference between the groups of females in their fifties vs. sixties, or in their sixties vs. seventies. We consider that the reason for this discrepancy is that reduced hippocampal volume over one decade was so small compared to the SD in each group that a statistically significant reduction was not found in group comparisons. Previous longitudinal studies indicate that the process of atrophy differs among individuals (36,37). In other words, within-group variance in people in their forties and fifties is lower than that in people in their sixties and seventies; i.e., comparison of data between people in their sixties and seventies is more insensitive to change than comparison between data of those in their forties and fifties. We were not able to eliminate this problem; however, significant difference was found in brain volume between the female groups in their forties and fifties but not between the male groups in their forties and fifties. We think that the different results between the sexes could be indirect evidence of the effects of menopause on hippocampal volume. Several studies report various rates of hippocampal volume reduction (12,19,20,38) because the rate of reduction might be affected by varying factors in the studies (age range, male–female ratio, ROI, etc.). Therefore, we must interpret the results of the rate of hippocampal volume reduction quantitatively and with much caution.

Lord et al. studied the relation between estrogen therapy and hippocampal volume in

estrogen therapy users, past users, never users, and men, and suggested a positive association between estrogen and hippocampal volume (1). In a study that measured the 17β -estradiol levels in cerebrospinal fluid (CSF) and regional cerebral (18F) 2-fluoro 2-deoxy-D-glucose uptake in six female post-menopausal patients with probable Alzheimer's disease (mean age = 70.3 ± 7.7 years, age range = 68–78 years), Schonknecht et al. suggested an association between estrogen and hippocampal glucose metabolism (2). Tang et al. reported that estrogen use in post-menopausal women might delay the onset and decrease the risk of Alzheimer's disease (3) by the neuroprotective effect of estrogen (9,39). In contrast, Amagai et al. studied 4683 females (age range = 36–89 years) and reported the mean age \pm SD at menopause as 48.3 ± 4.8 , with 80% of females experiencing menopause between 45 and 54 years of age (40). Furthermore, in the present study, only 3 of 46 females in their forties were at menopause, while 51 of 59 females in their fifties were at menopause. Therefore, we speculate that the reduced estrogen levels in post-menopausal women might accelerate the rate of decline in hippocampal volume through forty and fifty years old.

A major limitation of the current study is the lack of information regarding estrogen levels in the blood and in CSF. Unfortunately, because estrogen level was not measured as part of our hospital's personal health screening program, we are not able to infer a direct relationship between estrogen level and hippocampal volume. However, previous reports indicate that the prevalence of HRT use in Japan is approximately 2% (41).

Therefore, we consider that HRT would have had very little effect on the present results.

Previous studies report that as well as estrogen level, hypertension (15,25–28), drinking index (29,30), smoking index (42,43), and blood glucose level (31–33) have a certain effect on brain volume. We consider, however, that these additional factors would have had very little effect on the present analysis because we found no significant difference in hypertension, drinking index, smoking index, or blood glucose level among the female groups. Furthermore, significant difference was found in brain volume between the female groups in their forties and fifties but not between the male groups in their forties and fifties. We think that these different results between the sexes could be indirect evidence of menopausal effects on hippocampal volume, and we therefore speculate that the reduction in estrogen levels in post-menopausal women accelerates the rate of hippocampal volume decline in the female group in their fifties compared to that in their forties. However, to confirm our prediction, we consider that future investigation is needed, using information regarding estrogen levels and HRT.

The second limitation of our study was that a significant difference in drinking index was found only between the groups of males in their forties vs. sixties. This result suggests that alcohol consumption affects age-related reduction of hippocampal volume and could cause overestimation of the rate of hippocampal volume reduction in males from a quantitative viewpoint; however, a significant difference in drinking index was not seen in the results of female group differences between the forties and fifties. To

investigate the effect of alcohol intake on brain volume, we tested correlations between gray matter volume and drinking index in a voxel-wise manner, treating age and TIV as confounding covariates among all subjects. The results revealed no significant correlation between hippocampal volume and drinking index. Therefore, a significant difference in drinking index between the groups of males in their forties vs. sixties had a minor effect on our morphometric results.

Although hypertension was more prevalent in the older groups, there was no significant difference in the number of persons with hypertension among the female groups or the male groups. Therefore, we did not exclude subjects on the basis of hypertension or drinking because we thought that these factors would have very little effect on the volumetric findings, and we did not wish to generate a supernormal group of subjects. Because we considered influence from third variables, we tried to exclude the influence of various factors (i.e., hypertension, drinking index, smoking index, and blood glucose level); however, we consider that influence from other variables may not have been completely excluded. Therefore, the results of the present study need to be interpreted with caution because third variables may explain the group differences.

We performed an additional ROI study using linear regression and polynomial correlation analyses. These results showed a negative correlation between gray matter volume and age, but were not able to prove a difference within the critical age window for menopausal status; however, when groups were divided according to age and sex,

we detected accelerated reduction in the group of females in their forties compared with fifties. It is arbitrary to group the subjects by decades of age, but correlational analyses (such as linear, polynomial, and logarithmic regression) may not enable detection of volume changes at specific decades of age. In other words, using this method of analysis, we could detect accelerated volume changes in the hippocampus between women in their forties and fifties, but not in other decades. Furthermore, because we treated age as a confounding covariate in our analysis, age-related volume change could be controlled.

In conclusion, VBM revealed significant hippocampal volume reduction only between groups of females in their forties vs. fifties. A similar reduction was found between the pre-menopausal and post-menopausal groups. The results of the current study suggest that the menopause may be associated with hippocampal volume reduction.

REFERENCES

1. Lord C, Buss C, Lupien SJ, Pruessner JC. Hippocampal volumes are larger in postmenopausal women using estrogen therapy compared to past users, never users and men: a possible window of opportunity effect. *Neurobiol Aging* 2008;29:95-101.
2. Schonknecht P, Henze M, Hunt A, Klinga K, Haberkorn U, Schroder J. Hippocampal glucose metabolism is associated with cerebrospinal fluid estrogen levels in postmenopausal women with Alzheimer's disease. *Psychiatry Res* 2003;124:125-127.
3. Tang MX, Jacobs D, Stern Y, et al. Effect of oestrogen during menopause on risk and age at onset of Alzheimer's disease. *Lancet* 1996;348:429-432.
4. Shiino A, Watanabe T, Maeda K, Kotani E, Akiguchi I, Matsuda M. Four subgroups of Alzheimer's disease based on patterns of atrophy using VBM and a unique pattern for early onset disease. *Neuroimage* 2006;33:17-26.
5. Low LF, Anstey KJ, Maller J, et al. Hormone replacement therapy, brain volumes and white matter in postmenopausal women aged 60-64 years. *Neuroreport* 2006;17:101-104.
6. Yue Y, Hu L, Tian QJ, et al. Effects of long-term, low-dose sex hormone replacement therapy on hippocampus and cognition of postmenopausal women of different apoE genotypes. *Acta Pharmacol Sin* 2007;28:1129-1135.

7. de Moraes SA, Szklo M, Knopman D, Park E. Prospective assessment of estrogen replacement therapy and cognitive functioning: atherosclerosis risk in communities study. *Am J Epidemiol* 2001;154:733-739.
8. Mulnard RA, Cotman CW, Kawas C, et al. Estrogen replacement therapy for treatment of mild to moderate Alzheimer disease: a randomized controlled trial. Alzheimer's Disease Cooperative Study. *Jama* 2000;283:1007-1015.
9. Zec RF, Trivedi MA. The effects of estrogen replacement therapy on neuropsychological functioning in postmenopausal women with and without dementia: a critical and theoretical review. *Neuropsychol Rev* 2002;12:65-109.
10. Abe O, Yamasue H, Aoki S, et al. Aging in the CNS: Comparison of gray/white matter volume and diffusion tensor data. *Neurobiol Aging* 2008;29:102-116.
11. Good CD, Johnsrude IS, Ashburner J, Henson RN, Friston KJ, Frackowiak RS. A voxel-based morphometric study of ageing in 465 normal adult human brains. *Neuroimage* 2001;14:21-36.
12. Miyahira Y, Yu J, Hiramatsu K, Shimazaki Y, Takeda Y. Brain volumetric MRI study in healthy elderly persons using statistical parametric mapping. *Seishin Shinkeigaku Zasshi* 2004;106:138-151.
13. Resnick SM, Goldszal AF, Davatzikos C, et al. One-year age changes in MRI brain volumes in older adults. *Cereb Cortex* 2000;10:464-472.
14. Smith CD, Chebrolu H, Wekstein DR, Schmitt FA, Markesbery WR. Age and

- gender effects on human brain anatomy: a voxel-based morphometric study in healthy elderly. *Neurobiol Aging* 2007;28:1075-1087.
15. Taki Y, Goto R, Evans A, et al. Voxel-based morphometry of human brain with age and cerebrovascular risk factors. *Neurobiol Aging* 2004;25:455-463.
 16. Coffey CE, Wilkinson WE, Parashos IA, et al. Quantitative cerebral anatomy of the aging human brain: a cross-sectional study using magnetic resonance imaging. *Neurology* 1992;42:527-536.
 17. Gur RC, Mozley PD, Resnick SM, et al. Gender differences in age effect on brain atrophy measured by magnetic resonance imaging. *Proc Natl Acad Sci U S A* 1991;88:2845-2849.
 18. Nunnemann S, Wohlschlagel AM, Ilg R, et al. Accelerated aging of the putamen in men but not in women. *Neurobiol Aging* 2009;30:147-151.
 19. Raz N, Gunning FM, Head D, et al. Selective aging of the human cerebral cortex observed in vivo: differential vulnerability of the prefrontal gray matter. *Cereb Cortex* 1997;7:268-282.
 20. Raz N, Gunning-Dixon F, Head D, Rodrigue KM, Williamson A, Acker JD. Aging, sexual dimorphism, and hemispheric asymmetry of the cerebral cortex: replicability of regional differences in volume. *Neurobiol Aging* 2004;25:377-396.
 21. Lupien SJ, Evans A, Lord C, et al. Hippocampal volume is as variable in young

- as in older adults: implications for the notion of hippocampal atrophy in humans. *Neuroimage* 2007;34:479-485.
22. Ashburner J, Friston KJ. Voxel-based morphometry--the methods. *Neuroimage* 2000;11:805-821.
 23. Folstein MF, Folstein SE, McHugh PR. "Mini-mental state". A practical method for grading the cognitive state of patients for the clinician. *J Psychiatr Res* 1975;12:189-198.
 24. Fazekas F, Chawluk JB, Alavi A, Hurtig HI, Zimmerman RA. MR signal abnormalities at 1.5 T in Alzheimer's dementia and normal aging. *Am J Roentgenol* 1987;149:351-356.
 25. DeCarli C, Miller BL, Swan GE, et al. Predictors of brain morphology for the men of the NHLBI twin study. *Stroke* 1999;30:529-536.
 26. Salerno JA, Murphy DG, Horwitz B, et al. Brain atrophy in hypertension. A volumetric magnetic resonance imaging study. *Hypertension* 1992;20:340-348.
 27. Strassburger TL, Lee HC, Daly EM, et al. Interactive effects of age and hypertension on volumes of brain structures. *Stroke* 1997;28:1410-1417.
 28. Yamano S, Sawai F, Yamamoto Y, et al. Relationship between brain atrophy estimated by a longitudinal computed tomography study and blood pressure control in patients with essential hypertension. *Jpn Circ J* 1999;63:79-84.
 29. Jernigan TL, Butters N, DiTraglia G, et al. Reduced cerebral grey matter

- observed in alcoholics using magnetic resonance imaging. *Alcohol Clin Exp Res* 1991;15:418-427.
30. Pfefferbaum A, Sullivan EV, Mathalon DH, Lim KO. Frontal lobe volume loss observed with magnetic resonance imaging in older chronic alcoholics. *Alcohol Clin Exp Res* 1997;21:521-529.
31. Kumar R, Anstey KJ, Cherbuin N, Wen W, Sachdev PS. Association of type 2 diabetes with depression, brain atrophy, and reduced fine motor speed in a 60- to 64-year-old community sample. *Am J Geriatr Psychiatry* 2008;16:989-998.
32. Puri BK, Lewis HJ, Saeed N, Davey NJ. Volumetric change of the lateral ventricles in the human brain following glucose loading. *Exp Physiol* 1999;84:223-226.
33. Burns JM, Donnelly JE, Anderson HS, et al. Peripheral insulin and brain structure in early Alzheimer disease. *Neurology* 2007;69:1094-1104.
34. Ashburner J, Friston KJ. Unified segmentation. *Neuroimage* 2005;26:839-851.
35. Yamasue H, Kasai K, Iwanami A, et al. Voxel-based analysis of MRI reveals anterior cingulate gray-matter volume reduction in posttraumatic stress disorder due to terrorism. *Proc Natl Acad Sci U S A* 2003;100:9039-9043.
36. Fox NC, Schott JM. Imaging cerebral atrophy: normal ageing to Alzheimer's disease. *Lancet* 2004;363:392-394.
37. Resnick SM, Pham DL, Kraut MA, Zonderman AB, Davatzikos C. Longitudinal

- magnetic resonance imaging studies of older adults: a shrinking brain. *J Neurosci* 2003;23:3295-3301.
38. Szentkuti A, Guderian S, Schiltz K, et al. Quantitative MR analyses of the hippocampus: unspecific metabolic changes in aging. *J Neurol* 2004;251:1345-1353.
39. Jaffe AB, Toran-Allerand CD, Greengard P, Gandy SE. Estrogen regulates metabolism of Alzheimer amyloid beta precursor protein. *J Biol Chem* 1994;269:13065-13068.
40. Amagai Y, Ishikawa S, Gotoh T, Kayaba K, Nakamura Y, Kajii E. Age at menopause and mortality in Japan: the Jichi Medical School Cohort Study. *J Epidemiol* 2006;16:161-166.
41. Ohta H. Hormone replacement Up-to-date. Practical tips for hormone replacement therapy in women. *Clin Calcium* 2007;17:1407-1413.
42. Brody AL, Mandelkern MA, Jarvik ME, et al. Differences between smokers and nonsmokers in regional gray matter volumes and densities. *Biol Psychiatry* 2004;55:77-84.
43. Gazdzinski S, Durazzo TC, Studholme C, Song E, Banys P, Meyerhoff DJ. Quantitative brain MRI in alcohol dependence: preliminary evidence for effects of concurrent chronic cigarette smoking on regional brain volumes. *Alcohol Clin Exp Res* 2005;29:1484-1495.

Table 1 Subjects data

female								
group	number of subjects	number of subjects at menopause	age (years)	age at menopause (years)	number of hypertension	drinking index	smoking index	blood glucose level (mg/dl)
forties	46	3	45.1 ± 2.9	45.7 ± 2.9	4	3.05 ± 6.21	83.8 ± 181.3	91.3 ± 7.8
fifties	59	51	55.4 ± 2.7	50.6 ± 3.1	8	1.85 ± 3.25	58.7 ± 190.4	95.2 ± 11.5
sixties	49	49	64.2 ± 2.6	50.7 ± 4.3	10	1.07 ± 2.54	15.7 ± 63.6	93.8 ± 9.3
seventies	17	17	74.1 ± 3.0	49.6 ± 3.6	6	1.34 ± 3.16	83.2 ± 228.5	93.4 ± 12.5

male								
group	number of subjects	number of subjects at menopause	age (years)	age at menopause (years)	number of hypertension	drinking index	smoking index	blood glucose level (mg/dl)
forties	85	-	44.9 ± 2.8	-	9	10.36 ± 9.55	489.0 ± 384.5	101.1 ± 15.7
fifties	80	-	54.2 ± 3.1	-	23	7.15 ± 7.92	470.0 ± 515.0	109.8 ± 31.9
sixties	63	-	64.8 ± 2.7	-	18	6.39 ± 7.28	449.2 ± 497.8	101.5 ± 16.0
seventies	13	-	73.6 ± 3.0	-	8	6.51 ± 5.32	430.0 ± 337.0	104.9 ± 21.3

Age, age at menopause, drinking index, smoking index, and blood glucose level are shown as average ± standard deviation.

Hypertension was defined as maximal blood pressure ≥ 140 mmHg or minimal blood pressure ≥ 90 mmHg.

Drinking index was defined as (amount of alcohol consumed per day) × (number of drinking days per week).

Smoking index was equal to the Brinkmann index and was expressed as (number of cigarettes smoked per day) × (years of smoking).

FIGURES

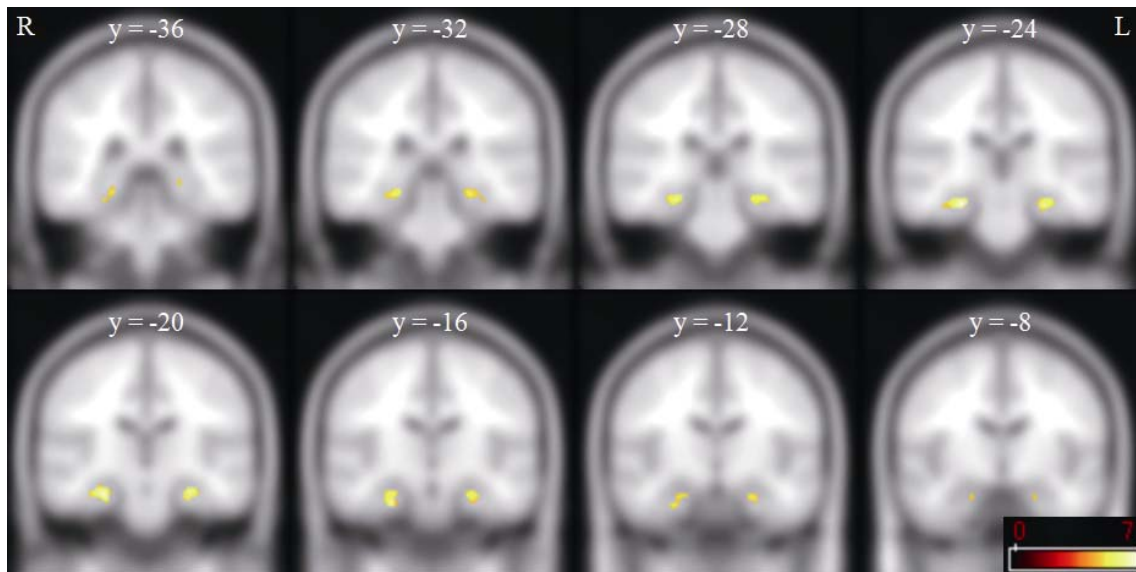


Figure 1. Areas of decreased gray matter volume between females in their forties vs. fifties. Regions of gray matter volume difference are superimposed onto the T1 template image. The color bar (bottom right) represents the T score. R and L indicate the right and left sides of the subjects, respectively. Right hippocampus: max T value = 6.96, cluster size = 208, $(x, y, z) = (26, -24, -18)$. Left hippocampus: max T value = 6.16, cluster size = 161, $(x, y, z) = (-28, -22, -18)$.