

Canals of Hering loss relates to the progression of the histological stages of primary biliary cirrhosis

著者	Kakuda Yuko, Harada Kenichi, Nakanuma Yasuni
journal or publication title	Journal of Clinical Pathology
volume	68
number	2
page range	141-147
year	2015-02-01
URL	http://hdl.handle.net/2297/45515

doi: 10.1136/jclinpath-2014-202417

Canals of Hering loss relates to the progression of the histologic stages of primary biliary cirrhosis

Yuko Kakuda,¹⁾²⁾ Kenichi Harada¹⁾ and Yasuni Nakanuma¹⁾²⁾

¹⁾ Department of Pathology, Shizuoka Cancer Center, Shizuoka, and ²⁾ Department of Human Pathology, Kanazawa University Graduate School of Medicine, Kanazawa, Japan

Address correspondence to:

Yasuni Nakanuma, MD, PhD

Department of Pathology, Shizuoka Cancer Centre, Shizuoka 411-8777, Japan

Tel: 81-55-989-5222, Fax: 81-55-989-5783

E-mail: nakanuma@staff.kanazawa-u.ac.jp

Financial support: The authors declare that they do not have anything to disclose with regard to funding with respect to this manuscript.

Conflict of interest: The authors declare that they do not have anything to disclose with regard to conflicts of interest with respect to this manuscript.

Key Words: primary biliary cirrhosis, hepatic progenitor cells, canal of Hering, stage

Word count: 2905 words

Abstract

Aims: The Canals of Hering (CoH), which are the most peripherally located bile drainage pathway, are considered a niche of hepatic progenitor cells. Recently, CoH loss has been described as an early feature of primary biliary cirrhosis (PBC). We investigated the correlation between CoH loss and the histopathological variables of PBC.

Methods: Liver biopsy specimens from 62 PBC patients (M:F = 8:54, age = 58 ± 12 years) were evaluated prior to ursodeoxycholic acid treatment. Liver biopsies of patients with normal liver ($n = 11$), chronic viral hepatitis ($n = 36$), and non-alcoholic fatty liver disease ($n = 13$) were used as controls. The number of CoH per definite area of hepatic parenchyma (c/p ratio) was calculated in individual cases. We compared the c/p ratios of PBC patients with that of controls and analysed the correlations with histological variables and clinical features.

Results: The c/p ratios in PBC patients with mild and extensive fibrosis were lower than those in controls with each degree of fibrosis. The c/p ratios were negatively correlated with stage, fibrosis, bile duct loss, orcein-positive granule deposition and hepatitis activities in PBC ($p < 0.01$) and with alkaline phosphatase and total bilirubin levels at liver biopsies ($p < 0.05$).

Conclusions: The number of CoH was low in early stages and further decreased with stage progression in PBC. CoH loss, reflecting a reduced supply of progenitor cells to the biliary tree, may be involved in the histologic progression of PBC.

Introduction

Primary biliary cirrhosis (PBC) is an autoimmune liver disease that is characterised by an immune-mediated destruction of intrahepatic bile ducts. Histologically, interlobular bile ducts are selectively affected, and this presents as chronic non-suppurative destructive cholangitis (CNSDC). The progressive loss of these small bile ducts is followed by prolonged cholestasis and cirrhosis(1-4). Enhanced apoptosis has been suggested as the major mechanism of bile duct loss in PBC(5). The balance of cell proliferation and loss is important in the maintenance of tissue homeostasis, including that of the biliary system(6), but the mechanisms that compensate for the enhanced loss of biliary epithelial cells in PBC have not been adequately clarified.

Canals of Hering (CoH), which are the most peripherally located bile drainage pathway connecting bile ducts and bile canaliculi, are considered to be a niche of hepatic progenitor cells (HPCs)(7, 8), and play important roles in liver and biliary regeneration in hepatobiliary diseases(9-16). CoH are visualised using immunohistochemistry for biliary markers, such as cytokeratin (CK) 7 and CK19. In various chronic liver diseases, such as chronic viral hepatitis and non-alcoholic steatohepatitis, a correlation between HPC activation and fibrotic and necroinflammatory activity has been reported(9, 13, 17, 18). While the CoH loss has been reported as a feature of PBC, particularly in its early

stages(19, 20), the relationships between the CoH loss and other histological findings of PBC, such as bile duct loss and fibrosis, are unclear.

Here we investigated the correlation between CoH loss and other histological variables, particularly those that are related to the staging and activity of PBC and the clinical features of PBC, to clarify the clinicopathological significance of CoH loss in PBC.

Materials and Methods

Patient selection and tissue preparations

A total of 62 PBC patients who were clinicopathologically diagnosed based on liver biopsies (59 needle and 3 wedge liver biopsies) were enrolled in this study. These patients were selected from the hepatobiliary disease files of Kanazawa University Hospital. They were divided into 2 groups: i) patients with adverse outcome [$n = 16$, cases showed cirrhosis-related conditions at biopsy ($n = 6$) or during 7.6 ± 5.8 years follow up ($n = 10$); histologically proven cirrhosis or cirrhosis-related complications and/or symptoms, such as ascites, ruptured and/or endoscopically treated gastroesophageal varices, hepatic encephalopathy, hyperbilirubinemia (≥ 2.0 mg/dL) or hepatocellular carcinoma]; and ii) patients without adverse outcome ($n = 46$, without these conditions during the 6.7 ± 6.2 years of follow-up). Biochemical data [levels of alkaline phosphatase (ALP), gamma-glutamyl transpeptidase (γ -GTP), aspartate aminotransferase (AST), alanine aminotransferase (ALT), and total bilirubin] were collected for 6 months before the first biopsies ($n = 62$) and after 1 year of therapy in 34 of the 62 patients who were treated with ursodeoxycholic acid (UDCA) only for 1 year or more. We examined 62 liver biopsies that were taken prior to UDCA therapy and 8 additional needle liver biopsies that were taken at the follow-up biopsies.

Needle liver biopsy specimens of patients with normal livers ($n = 11$), chronic viral hepatitis types C ($n = 20$) and B ($n = 16$) and non-alcoholic fatty liver disease (NAFLD, $n = 13$) were used as controls. All liver biopsy specimens were routinely processed; thin consecutive sections were stained with haematoxylin and eosin, reticulin, Azan–Mallory and Sirius Red stains and CK19 immunohistochemistry. Furthermore, orcein staining was performed in PBC cases.

CK19 immunohistochemistry

The slides were deparaffinised, and antigen retrieval was performed by microwaving in 10 mM citrate buffer (pH 6) for 20 min. After blocking of endogenous peroxidase and incubation in normal goat serum (1:10; Vector Laboratories, Inc., Burlingame, CA, USA) for 20 min, the deparaffinised sections were incubated overnight at 4 °C with a monoclonal mouse antibody against CK19 (clone RCK108; 1:100; DakoCytomation; Dako Japan, Tokyo, Japan). The sections were then incubated at room temperature for 1 h with goat anti-mouse immunoglobulins that were conjugated to peroxidase-labelled dextran polymer (EnVision; DakoCytomation). The reaction products were developed by immersing the sections in a 3,3'-diaminobenzidine tetrahydrochloride (DAB) solution containing 0.03% hydrogen peroxide. Nuclei were lightly counterstained with haematoxylin.

Immunohistochemical and histological evaluation

Using CK19 immunohistochemistry, CoH were defined according to Saxena et al(19). In brief, single to small clusters of less than 5 CK19-positive cells within hepatic lobules were counted. CK19-positive cells on limiting plates were not counted to eliminate ductular reactions (shown in Fig. 1). Furthermore, the ratios of the total number of CoH per definite area of hepatic parenchyma of each liver biopsy specimen were calculated to evaluate the relative number of CoH in individual cases according to the procedure summarised in Fig. 2. Namely, the hepatic parenchyma area was measured as follows. The sections were stained with Sirius Red and photographed at 20× magnification under an Olympus light microscope. Furthermore, the digital images were created and reproduced on a computer using the image processing software cellSens Standard (Olympus Corporation, Tokyo, Japan). Image analysis was performed with a resolution of 400 pixels/inch using Photoshop software (version 7.0.1; Adobe Systems Inc.) to quantify the parenchymal area of the specimens, which were expressed as pixels.

PBC liver biopsy specimens were routinely examined and evaluated with reference to the new grading and staging systems proposed by us(21, 22), which are summarised in Table 1. In controls, liver biopsies were routinely examined, and liver biopsies of patients with chronic viral hepatitis and NAFLD were evaluated with reference to the staging

according to Metavir and Brunt(23, 24), respectively; liver biopsies of the former were from F 0, 1, 2, 3 and 4, and those of the latter from stage 0, 1, 2, 3 and 4.

Statistical analyses

Continuous variables are expressed as mean \pm standard deviation (SD). Non-normally distributed variables were expressed as medians and interquartile ranges (IQR). The correlations and comparisons of the c/p ratio with each histological and clinical finding were examined using Spearman's correlation coefficients by rank tests and Wilcoxon signed-rank tests, respectively. All analyses were 2-sided and a *p* value of <0.05 was considered significant. All statistical analyses were performed using JMP software 8.0 (SAS Institute Inc., Cary, NC, USA).

Results

A summary of the clinical and histological findings of the 62 patients with PBC at the time of diagnosis are shown in Table 2. The immunohistochemistry for CK19 of CoH is shown in Figure 1. In normal livers, several CK19-positive CoH were scattered around portal tracts, whereas CoH were few or absent in patients with PBC (Fig. 1).

Relationship between histological grade and stage and CoH in PBC

The c/p ratios of PBC stages 1, 2, 3 and 4 ($n = 11, 35, 9$ and 7 , respectively) were 6.9 ± 4.6 , 5.7 ± 4.7 , 3.2 ± 3.4 and 0.23 ± 0.60 ($\times 10^{-6}$ each), respectively. In addition, the c/p ratio was negatively correlated with hepatitis activity ($\rho = -0.339$; $p < 0.01$), stage ($\rho = -0.475$; $p < 0.01$) and fibrosis, bile duct loss and orcein-positive granule deposition scores ($\rho = -0.385, -0.529$ and -0.559 , respectively; $p < 0.01$; Fig. 3A–F). The c/p ratio was not associated with cholangitis activities ($\rho = -0.052$; $p = 0.69$).

In 8 (cases A–H) of the 62 patients, follow-up biopsies were obtained after 8 ± 5 years of therapy, including UDCA. The CoH and histological grades, scores and stage of the liver biopsies are summarised in Table 3. Although the cohort was too small for statistical analysis, CoH decreased in 3 cases (cases A–C) whose follow-up biopsies showed bile duct loss and orcein-positive granule deposition that was advanced more

than 2 scores. In contrast, neither CoH loss nor histological progression were observed in 2 cases (cases D and E). In case F, there was already no CoH in the specimen at diagnosis. Two cases (cases G and H) showed increasing CoH, despite stage progression. As for case G, an association with NAFLD was observed at the follow-up biopsy. In case H, there was discrepancy between bile duct loss/orcein-positive granule deposition and fibrosis progression, which may indicate the presence of superimposed autoimmune hepatitis features in this case(3).

CoH and clinical features of PBC

The c/p ratio was not associated with age (Fig. 4A), sex (Fig. 4B) or symptomatic or asymptomatic presentation (data not shown). As for laboratory data, the c/p ratio was negatively correlated with ALP, total bilirubin and IgG levels at the time of the biopsies ($\rho = -0.310, -0.256$ and -0.285 , respectively; $p < 0.05$; Fig. 4C–E). Anti-mitochondrial antibody and antinuclear antibody positivity and the levels of γ GTP, AST, ALT, serum albumin and IgM showed no clear significant correlation (data not shown).

Among 34 patients (stage 1/2/3/4 = 5/18/8/3 cases) who were treated with UDCA for more than 1 year, the ones with increased levels of total bilirubin in response to UDCA

(poor responders, 4 cases) showed no CoH in the specimens and significantly lower c/p ratios compared with responders (30 cases) ($p < 0.01$) (Fig. 4F).

The c/p ratios of PBC patients showed histologically proven cirrhosis or cirrhosis-related complications and/or symptoms (i.e. ascites, hyperbilirubinemia, ruptured and/or endoscopically-treated gastroesophageal varices, hepatic encephalopathy or hepatocellular carcinoma) at the biopsies or during the 7.6 ± 5.8 years after follow-up ($n = 16$) were also significantly lower compared with those of the patients without these conditions for 6.7 ± 6.2 years ($n = 46$; $p < 0.05$) (Fig. 4G).

CoH in PBC and control livers

Furthermore, the c/p ratios of PBC patients were compared with those of the controls obtained from patients with normal livers [$n = 18$, c/p ratio = $15 \pm 13 (\times 10^{-6})$], chronic viral hepatitis of F0–1 [$n = 12$, c/p ratio = $18 \pm 11 (\times 10^{-6})$] and F2–4 [$n = 24$, c/p ratio = $34 \pm 33 (\times 10^{-6})$], NAFLD of stage 0–2 [$n = 7$, c/p ratio = $26 \pm 16 (\times 10^{-6})$] and stage 3–4 [$n = 6$, c/p ratio = $82 \pm 45 (\times 10^{-6})$] (Fig. 5). The c/p ratios of the controls were significantly higher compared with those of the PBC cases with a fibrosis score of 0–1 [$n = 45$, c/p ratio = $6.0 \pm 4.6 (\times 10^{-6})$] and 2–3 [$n = 17$, c/p ratio = $1.9 \pm 2.9 (\times 10^{-6})$]. In addition, the c/p ratios were positively correlated with the fibrosis stage of patients with

NAFLD ($\rho = 0.641$; $p < 0.05$), and NAFLD stage 3–4 cases showed increased c/p ratios compared with those of the normal livers ($p < 0.05$). Regarding chronic viral hepatitis, the correlation between the c/p ratios and fibrosis was not significant.

Discussion

The data obtained here are summarised as follows: i) the number of CoH was decreased in patients with PBC not only in the early stages but also in advanced stages in comparison with controls of comparable stages; ii) the decrease in CoH correlates with the histological stage and findings related to PBC staging; iii) CoH decreased in follow-up biopsies, showing stage progression with bile duct loss and a greater than 2-score increase in orcein-positive granule deposition; iv) CoH loss was also associated with liver dysfunction and v) the responders to therapy showed higher c/p ratios than the non-responders, and the cases with cirrhotic conditions showed lower c/p ratios than those without cirrhotic conditions. Although this study using liver biopsies has some limitations regarding the evaluation of clinicopathological features with respect to disease progression or severity given the patchy distribution of histological changes in PBC, the results listed above, particularly ii) and iii), suggest that CoH loss parallels disease progression in PBC. Moreover, an observation of CoH loss in the early stage may reflect advanced bile duct damage and associated conditions in PBC.

Several studies have suggested that CoH loss is observed in early stages and that such a loss may be a feature of the earliest changes in PBC(19, 20). In the present study, we confirmed these findings and additionally demonstrated an association between CoH

loss and disease progression, particularly bile duct loss and cholestasis. Furthermore, not only the histological variables but also the clinical findings, such as biochemical data and patient outcomes (Fig. 4), were associated with the c/p ratios in this study. This study observed that the c/p ratio was higher in biochemical responders to UDCA and in patients with non-cirrhotic conditions than in non-responders to UDCA and those with cirrhotic conditions, respectively, in PBC. These data suggested that the degree of CoH loss differed among patients and that patients with lesser reduction of CoH may respond well to UDCA and belong to a less advanced stage. This suggests that in addition to staging, higher c/p ratios may reflect favourable conditions and prognoses. A prospective study appears mandatory to verify this hypothesis. Moreover, 2 of 8 patients in this study with follow-up biopsies showed no progression of PBC. The c/p ratios appeared to increase in these histological responders to UDCA; however, this number of cases is too small to allow any speculation. Further studies with a larger cohort will be needed to investigate whether UDCA is able to reverse CoH loss.

Saxena et al.(25) reported an increase in the numbers of CoH in cases involving Scheuer's stage II and III in comparison with histological stage 0, which is defined as a normal portal tract containing a normal bile duct. The disparity between our findings and those reported by Saxena et al. may be due to the different staging system. Scheuer's

staging system is defined by a mixture of ductopathy and fibrosis(26). The difference in the definition of the c/p ratios may also be responsible for this disparity; the c/p ratio in our study, which was the ratio of the number of CoH in a definite area of parenchyma, is used to evaluate biopsies with or without extensive fibrosis and lobular disarray precisely, and that used in Saxena's data was the ratio of CoH/portal tracts. To confirm this prospect, we counted the c/p ratio in accordance with Scheuer's staging system, and the c/p ratio was shown to decrease gradually along with stage as in the new staging system (data not shown). Therefore, the difference in staging and definition with respect to counting CoH did not affect the gradual loss of CoH observed in this study along with the histological stage.

Kahn et al.(20) suggested that there are two hypothetical mechanisms of CoH loss in the minimal change of PBC: i) their being destroyed by an immune attack(19) or ii) their disappearing as a result of differentiation into hepatocytes(8, 15). In PBC livers at early stages, focal necrosis occasionally occurs with lymphocytic infiltration and Kupffer cell hyperplasia in the hepatic parenchyma, suggesting that these lesions may reflect progenitor loss by immunological cells, as observed in the chronic non-suppurative destructive cholangitis characterizing PBC. The findings that the c/p ratios correlated with hepatitis activities in this study (Fig. 3F) support the idea of an

immunopathological attack on HPCs, although there was no correlation between cholangitis activities and c/p ratios (Fig. 3E). While the reason(s) for progressive CoH loss remains speculative, the loss or absence of such progenitor cells in the liver may be followed by an insufficient supply of biliary committed cells to the bile ductules and interlobular bile ducts. This may be followed by the impaired replacement of biliary epithelia in the damaged interlobular bile ducts and by the irreversible loss of interlobular bile ducts as well in PBC. More studies are needed to answer the question of what causes the CoH decrease in PBC.

In comparison with other control liver diseases, PBC cases showed significantly lower c/p ratios than other diseases in each degree of fibrosis (Fig. 5), which corresponded to the findings of previous studies(19, 20, 25). It has been reported that the activation of HPCs is associated with fibrosis progression(27) in chronic viral hepatitis(9, 12, 18, 28) and NAFLD(10, 13, 29). Namely, liver injury due to viral infection or oxidative stress causes hepatic stellate cell activation as well as also HPC expansion for liver regeneration. HPC expansion, including ductular reaction, has been thought to drive fibrosis through the production of agents such as connective tissue growth factor and/or epithelial–mesenchymal transition, which contributes to the portal myofibroblast pool. Our results were partially compatible with these findings. Specifically, NAFLD cases

showed statistical correlations between the c/p ratios and the degree of fibrosis. However, in cases with chronic viral hepatitis, such a relationship was unclear. This may be because of the large variation in the c/p ratios and the small number of cases with each degree of fibrosis. At least, unlike in PBC, there was no tendency for CoH loss according to stage progression in chronic viral hepatitis and NAFLD. Moreover, an evaluation of the follow-up biopsies of PBC patients showed that the c/p ratio of a case with accompanied NAFLD was preserved, while the score of bile duct loss progressed in the follow-up biopsy compared with that in the biopsy performed at diagnosis (Table 3, case G). These facts suggested that the fibrogenesis in PBC may not be mediated by HPCs within CoH. The prolonged cholestasis and the destruction of limiting plates associated with progressive fibrosis of PBC may be responsible for activation of hepatic stellate cells followed by fibrosis(30, 31).

In conclusion, CoH loss was observed in PBC livers in the early stages, and it was worse in advanced stages. PBC patients who were responders to therapy and the ones with non-cirrhotic conditions showed relatively higher c/p ratios. Further studies on CoH loss would provide potential insights in the prevention of disease progression for PBC.

Table 1-1. Grading of the necroinflammatory activity of primary biliary cirrhosis

A. Cholangitis activity (CA)

Grade	Criteria
0 (no activity)	No cholangitis but mild damage to the epithelium of the duct may be present
1 (mild activity)	One evident chronic cholangitis in the specimen
2 (moderate activity)	More than two bile ducts with evident chronic cholangitis
3 (marked activity)	At least one CNSDC in the specimen

Abbreviation: CNSDC, chronic non-suppurative destructive cholangitis

B. Hepatitis activity (HA)

Grade	Criteria
0 (no activity)	No interface hepatitis and no or minimum lobular hepatitis
1 (mild activity)	Interface hepatitis affecting 10 continuous hepatocytes at a limiting plate in one portal tract or fibrous septa and mild-to-moderate lobular hepatitis
2 (moderate activity)	Interface hepatitis affecting 10 continuous hepatocytes at a limiting plates in more than two portal tracts or fibrous septa and mild-to-moderate lobular hepatitis
3 (marked activity)	Interface hepatitis affecting 20 continuous hepatocytes at limiting plate in more than half of theportal tracts and modetatelobular hepatitis or bridging/zonal necrosis

Table 1-2. Scoring for the staging of primary biliary cirrhosis

A. Fibrosis

Score	Criterion
0	No portal fibrosis or fibrosis limited to portal tracts
1	Portal fibrosis with periportal fibrosis or incomplete septal fibrosis
2	Bridging fibrosis with variable lobular disarray
3	Liver cirrhosis with regenerative nodules and extensive fibrosis

B. Bile duct loss

Score	Criterion
0	No bile duct loss
1	Bile duct loss in <1/3 of portal tracts
2	Bile duct loss in 1/3–2/3 of portal tracts
3	Bile duct loss in >2/3 of portal tracts

(Continue)

C. Orcein-positive granules deposition (orcein)

Score	Criterion
0	No deposition of granules
1	Deposition of granules in a couple of zone 1 hepatocytes at <1/3 of portal tracts
2	Deposition of granules in a variable number of zone 1 hepatocytes at 1/3–2/3 of portal tracts
3	Deposition of granules in most zone 1 hepatocytes at >2/3 of portal tracts

Table 2. Main clinical, laboratory and pathological characteristics of the 62 patients with primary biliary cirrhosis

Age (mean \pm SD years)	57 \pm 11
Sex (males:females)	8:54
AMA or M2Ab (+:-)	43:19 (positivity 69%)
ANA (+:-)	39:23 (positivity 63%)
Symptomatic:asymptomatic	22:40
Laboratory data at the time of biopsy	median (IQR)
ALP (normal range: 115–359) (IU/L)	482 (750–295)
γ -GTP (normal range: 10–47) (IU/L)	130 (272–79)
AST (normal range: 13–33) (IU/L)	42 (55–28)
ALT (normal range: 6–27) (IU/L)	40 (55–27)
Total bilirubin (normal range: 0.3–1.2) (mg/dL)	0.7 (0.9–0.5)
Albumin (normal range: 4.0–5.0) (g/dL)	4.0 (4.4–3.7)
Prothrombin time (normal range: 10.6–13.0) (s)	11.3 (11.9–10.9)
IgG (normal range: 870–1,700) (mg/dL)	1,917 (2,238–1,525)
IgM (normal range: 46–260) (mg/dL)	302 (446–174)
Histological characteristics ^{a)}	
Grade	
CA 0/1/2/3 (cases)	10/16/10/26
HA 0/1/2/3 (cases)	12/29/17/4
Stage 1/2/3/4 (cases)	11/35/9/7
Scores	
Fibrosis 0/1/2/3 (cases)	14/31/14/3
Bile duct loss 0/1/2/3 (cases)	26/28/5/3
Orcein 0/1/2/3 (cases)	37/13/3/9

Abbreviations: SD, standard deviation; AMA, anti-mitochondrial antibodies; M2Ab, M2 antibodies; ANA, anti-nuclear antibodies; IQR, interquartile range, ALP, alkaline phosphatase; γ -GTP, gamma-glutamyl transpeptidase; AST, aspartate aminotransferase; ALT, alanine aminotransferase; IgG, Immunoglobulin G; IgM, Immunoglobulin M; ^{a)} histological findings related to the new grading and staging system, CA, cholangitic activities; HA, hepatic activities; orcein, orcein-positive granules deposition.

Table 3. Comparison of findings at the time of diagnosis and in follow-up biopsies

Case	Biopsy	CA	HA	Fibrosis score	BDL score	Orcein score	Stage	CoH (n)	Parenchymal area (pixels)	c/p ratio ^{a)}
A	1st	2	2	1	0	0	2	6	1,734,440	3.5
	2nd	3	2	2	3	3	4	1	1,063,931	0.94
B	1st	1	0	1	0	0	2	5	450,394	11.1
	2nd	0	1	1	3	3	4	3	591,106	5.1
C	1st	3	1	1	1	0	2	11	1,433,944	7.7
	2nd	0	2	2	3	3	4	5	813,556	6.1
D	1st	3	0	1	0	0	2	2	424,735	4.7
	2nd	3	0	0	1	0	2	4	627,909	6.4
E	1st	0	1	1	1	1	2	0	306,375	0
	2nd	0	0	1	1	1	2	2	347,983	5.7
F	1st	2	2	2	1	3	3	0	572,812	0
	2nd	0	2	3	3	3	4	0	343,570	0
G	1st	3	1	1	0	0	2	3	712,440	4.2
	2nd	2	1	2	2	1	3	9	618,688	14.5
H	1st	3	2	1	0	0	2	2	266,990	7.5
	2nd	3	3	3	1	1	3	28	889,556	31.5

Abbreviations: CA, cholangitic activities; HA, hepatic activities; BDL, bile duct loss; Orcein score, orcein-positive granules deposition score, CoH; canals of Hering.

a) $\frac{\text{number of CoH}}{\text{parenchymal area}} \times 10^6$

Figure legends

Fig. 1 Representative pictures of cytokeratin (CK)19 immunohistochemistry of portal tracts. (A) A normal liver, (B) a patient with primary biliary cirrhosis (PBC) of CA3, HA1, stage 2 (scores of fibrosis 1, bile duct loss 1, orcein 1) and (C) a patient with PBC of CA3, HA1, stage 4 (scores of fibrosis 2, bile duct loss 3, orcein 3). The arrows denote the Canals of Hering (CoH; 100× magnification). To distinguish these from bile ductules, CK19 positive cells on the limiting plates (arrowheads) and clusters of more than 5 cells were eliminated in this study. Abbreviations: CA, cholangitic activity; HA, hepatic activity.

Fig. 2 (A) Diagram of the procedure used to calculate the c/p ratio. (B) A representative digital image of a specimen stained with Sirius Red. The hepatic parenchymal area (yellowish zone) was quantified using pixels. All image analyses were performed at a resolution of 400 pixels/inch.

Fig. 3 The c/p ratio of each grade, score and stage in PBC livers. (A) CA, (B) HA, (C) stage, (D) fibrosis score, (E) bile duct loss score and (F) orcein score. Abbreviations: c/p ratio, the ratio of the number of CoH to the parenchymal area; CA, cholangitic activity; HA, hepatic activity; ρ , correlation coefficient; n.s., not significant.

Fig. 4 The c/p ratio and clinical features of PBC. (A) Sex, (B) age, (C) serum level of ALP, (D) total bilirubin, (E) IgG at biopsy, (F) total bilirubin response to 1 year UDCA therapy and (G) those with or without adverse outcomes (an adverse outcome being defined by histologically proven cirrhosis or cirrhosis-related complications and/or symptoms). As for the laboratory data and UDCA responses, this figure includes only the variables that reached statistical significance. Abbreviations: c/p ratio, the ratio of the number of CoH to the parenchymal area; ρ , correlation coefficient; n.s., not significant; ALP, alkaline phosphatase; UDCA, ursodeoxycholic acid.

Fig. 5 The c/p ratios of patients with PBC and control livers. The c/p ratios of the PBC livers with (A) none to mild and (B) severe fibrosis were significantly lower compared with those of controls. Abbreviations: c/p ratio, the ratio of the number of CoH to the parenchymal area; fibrosis, fibrosis score according to PBC new evaluation system; CVH, chronic viral hepatitis; *, $p < 0.01$ compared with PBC.

Take home messages

In PBC, the number of canals of Hering (CoH) is low in early stages and further decrease with stage progression.

CoH loss parallels the histological findings related to the staging of PBC, particularly bile duct loss and chronic cholestasis, and also associates with liver dysfunction.

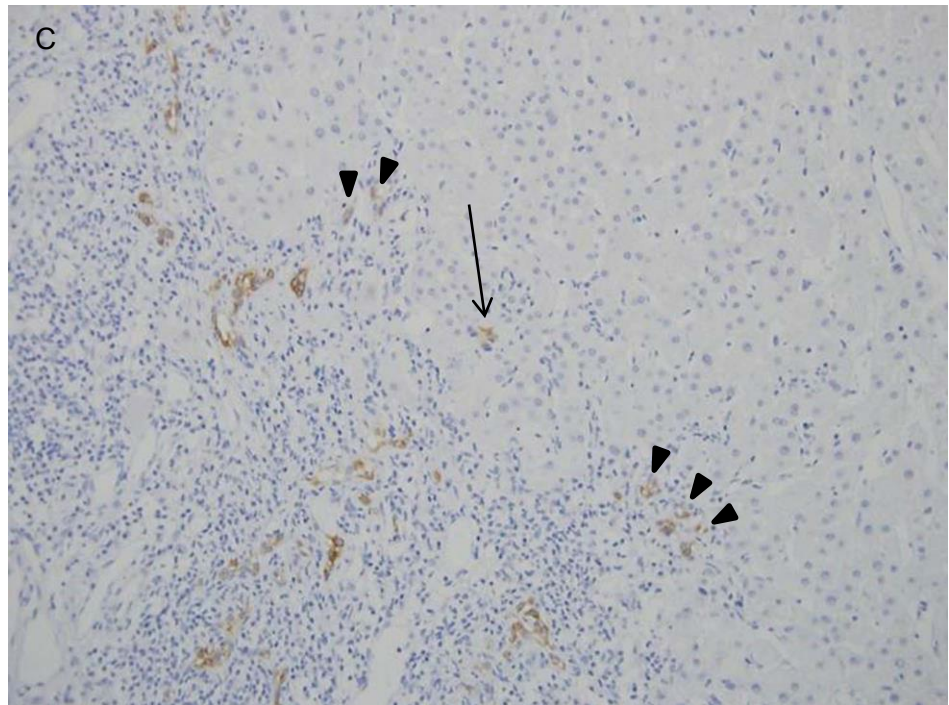
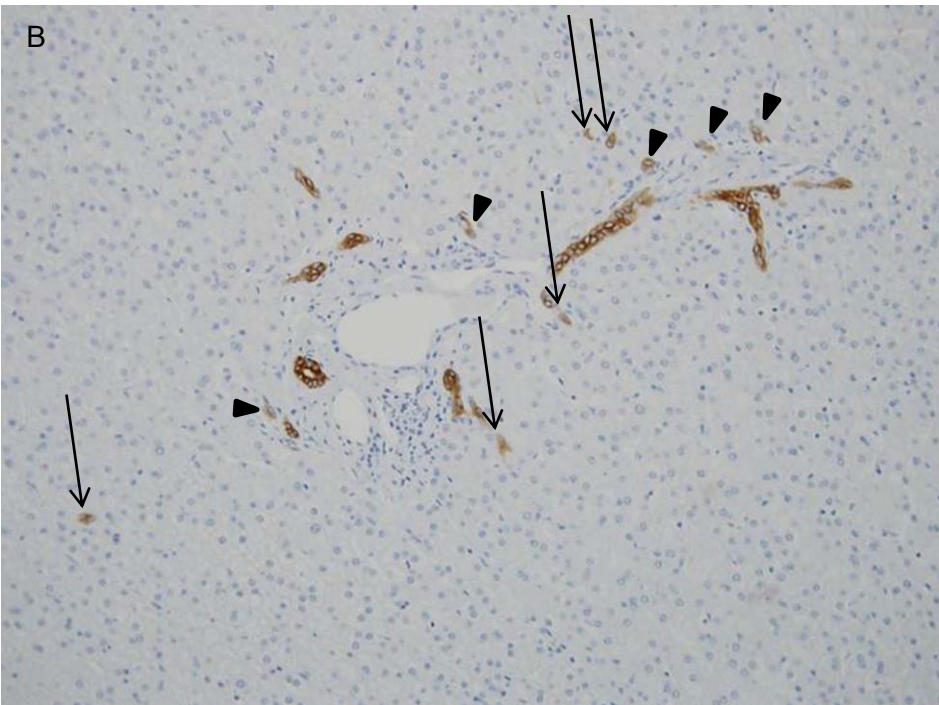
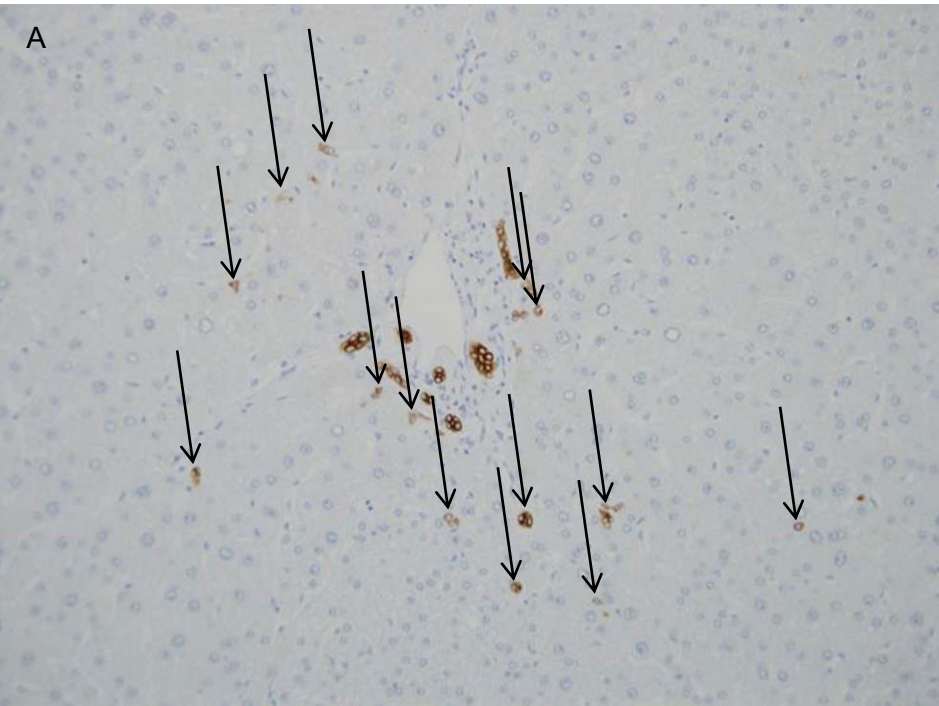
CoH loss, reflecting a reduced supply of progenitor cells to the biliary tree, may be involved in the histologic progression of PBC.

References

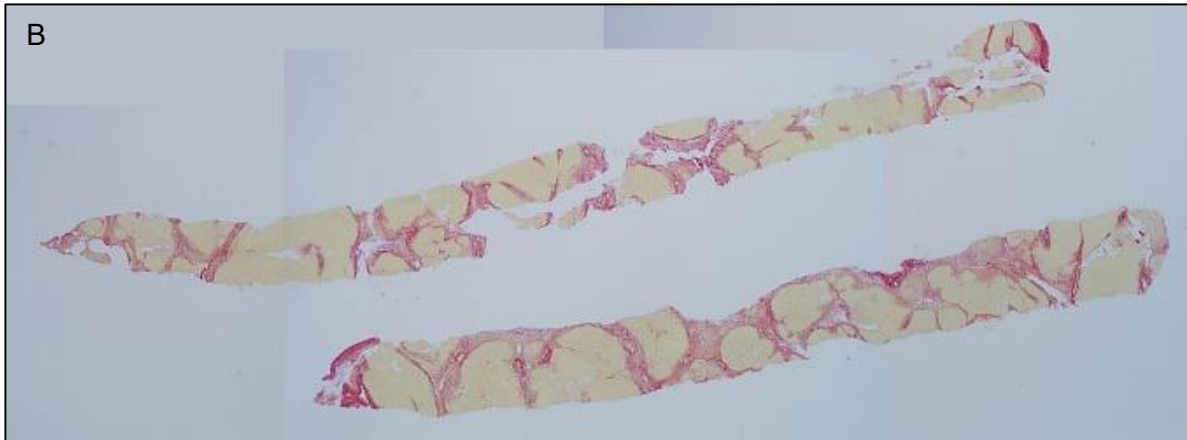
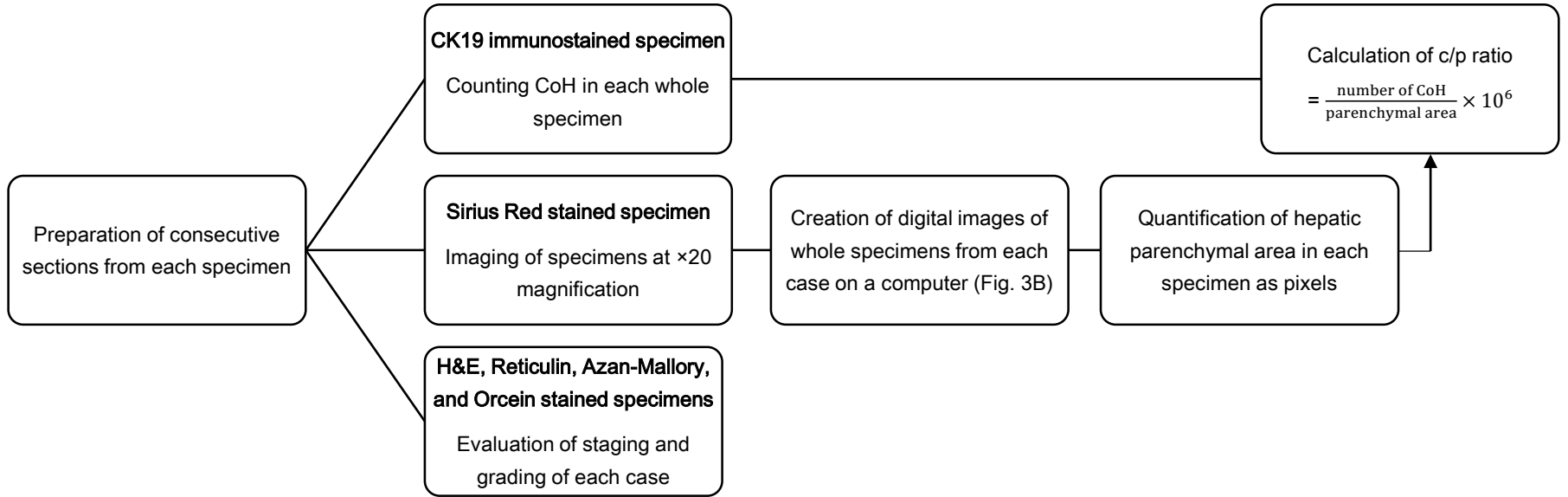
1. Kaplan MM, Gershwin ME. Primary biliary cirrhosis. *The New England journal of medicine*. 2005 Sep 22;353(12):1261-73. PubMed PMID: 16177252. Epub 2005/09/24. eng.
2. Selmi C, Bowlus CL, Gershwin ME, Coppel RL. Primary biliary cirrhosis. *Lancet*. 2011 May 7;377(9777):1600-9. PubMed PMID: 21529926. Epub 2011/05/03. eng.
3. Poupon R. Primary biliary cirrhosis: A 2010 update. *Journal of hepatology*. 2010;52:745–58.
4. Nakanuma Y, Ohta G. Histometric and serial section observations of the intrahepatic bile ducts in primary biliary cirrhosis. *Gastroenterology*. 1979 Jun;76(6):1326-32. PubMed PMID: 437429. Epub 1979/06/01. eng.
5. Harada K, Ozaki S, Gershwin ME, Nakanuma Y. Enhanced apoptosis relates to bile duct loss in primary biliary cirrhosis. *Hepatology*. 1997 Dec;26(6):1399-405. PubMed PMID: 9397977. Epub 1997/12/16. eng.
6. Harada K, Iwata M, Kono N, Koda W, Shimonishi T, Nakanuma Y. Distribution of apoptotic cells and expression of apoptosis-related proteins along the intrahepatic biliary tree in normal and non-biliary diseased liver. *Histopathology*. 2000 Oct;37(4):347-54. PubMed PMID: 11012742. Epub 2000/09/30. eng.
7. Theise ND, Saxena R, Portmann BC, Thung SN, Yee H, Chiriboga L, et al. The canals of Hering and hepatic stem cells in humans. *Hepatology*. 1999 Dec;30(6):1425-33. PubMed PMID: 10573521. Epub 1999/11/26. eng.
8. Kuwahara R, Kofman AV, Landis CS, Swenson ES, Barendswaard E, Theise ND. The hepatic stem cell niche: identification by label-retaining cell assay. *Hepatology*. 2008 Jun;47(6):1994-2002. PubMed PMID: 18454509. Pubmed Central PMCID: 2847183.
9. Clouston AD, Powell EE, Walsh MJ, Richardson MM, Demetris AJ, Jonsson JR. Fibrosis correlates with a ductular reaction in hepatitis C: roles of impaired replication, progenitor cells and steatosis. *Hepatology*. 2005 Apr;41(4):809-18. PubMed PMID: 15793848.
10. Nobili V, Carpino G, Alisi A, Franchitto A, Alpini G, De Vito R, et al. Hepatic progenitor cells activation, fibrosis, and adipokines production in pediatric nonalcoholic fatty liver disease. *Hepatology*. 2012 Dec;56(6):2142-53. PubMed PMID: 22467277.
11. Espanol-Suner R, Carpentier R, Van Hul N, Legry V, Achouri Y, Cordi S, et al. Liver progenitor cells yield functional hepatocytes in response to chronic liver injury in mice. *Gastroenterology*. 2012 Dec;143(6):1564-75 e7. PubMed PMID: 22922013.

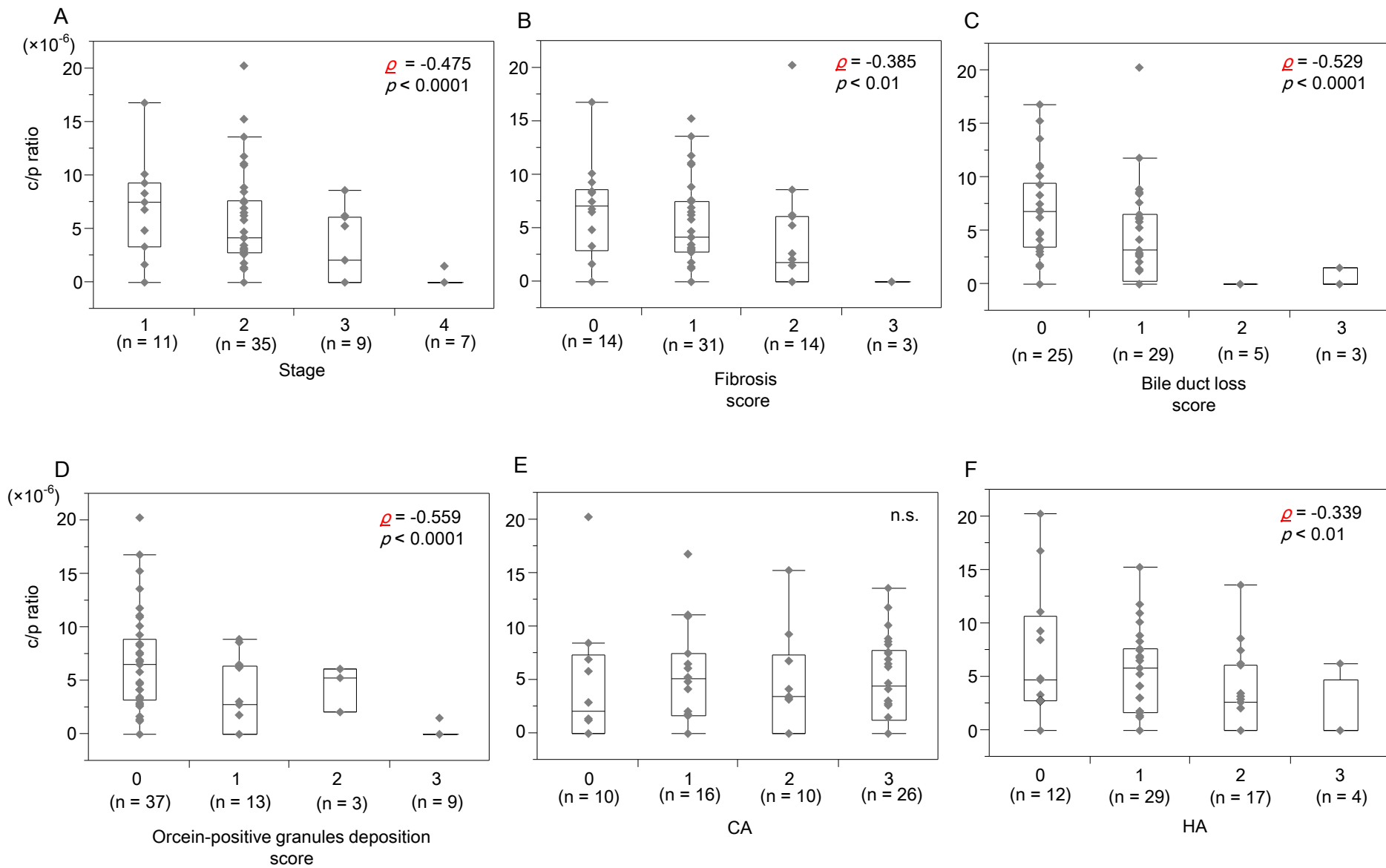
12. Eleazar JA, Memeo L, Jhang JS, Mansukhani MM, Chin S, Park SM, et al. Progenitor cell expansion: an important source of hepatocyte regeneration in chronic hepatitis. *Journal of hepatology*. 2004 Dec;41(6):983-91. PubMed PMID: 15582132.
13. Richardson MM, Jonsson JR, Powell EE, Brunt EM, Neuschwander-Tetri BA, Bhathal PS, et al. Progressive fibrosis in nonalcoholic steatohepatitis: association with altered regeneration and a ductular reaction. *Gastroenterology*. 2007 Jul;133(1):80-90. PubMed PMID: 17631134.
14. Falkowski O, An HJ, Ianus IA, Chiriboga L, Yee H, West AB, et al. Regeneration of hepatocyte 'buds' in cirrhosis from intrabiliary stem cells. *Journal of hepatology*. 2003;39(3):357-64.
15. Zhang L, Theise N, Chua M, Reid LM. The stem cell niche of human livers: symmetry between development and regeneration. *Hepatology*. 2008 Nov;48(5):1598-607. PubMed PMID: 18972441.
16. Itoh T, Miyajima A. Liver regeneration by stem/progenitor cells. *Hepatology*. 2013 Oct 1. PubMed PMID: 24115180.
17. Roskams T, Yang SQ, Koteish A, Durnez A, DeVos R, Huang X, et al. Oxidative Stress and Oval Cell Accumulation in Mice and Humans with Alcoholic and Nonalcoholic Fatty Liver Disease. *The American journal of pathology*. 2003;163(4):1301-11.
18. Fotiadu A, Tzioufa V, Vrettou E, Koufogiannis D, Papadimitriou CS, Hytioglou P. Progenitor cell activation in chronic viral hepatitis. *Liver international : official journal of the International Association for the Study of the Liver*. 2004 Jun;24(3):268-74. PubMed PMID: 15189279. Epub 2004/06/11. eng.
19. Saxena R, Hytioglou P, Thung SN, Theise ND. Destruction of canals of Hering in primary biliary cirrhosis. *Human Pathology*. 2002;33(10):983-8.
20. Khan FM, Komarla AR, Mendoza PG, Bodenheimer HC, Jr., Theise ND. Keratin 19 demonstration of canal of Hering loss in primary biliary cirrhosis: "minimal change PBC"? *Hepatology*. 2013 Feb;57(2):700-7. PubMed PMID: 22911653.
21. Nakanuma Y, Zen Y, Harada K, Sasaki M, Nonomura A, Uehara T, et al. Application of a new histological staging and grading system for primary biliary cirrhosis to liver biopsy specimens: Interobserver agreement. *Pathology international*. 2010 Mar;60(3):167-74. PubMed PMID: 20403042.
22. Kakuda Y, Harada K, Sawada-Kitamura S, Ikeda H, Sato Y, Sasaki M, et al. Evaluation of a new histologic staging and grading system for primary biliary cirrhosis in comparison with classical systems. *Hum Pathol*. 2013 Jun;44(6):1107-17. PubMed PMID: 23313306.

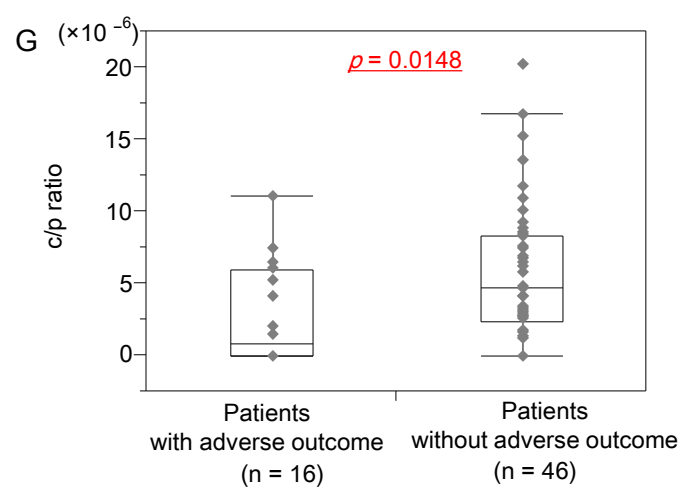
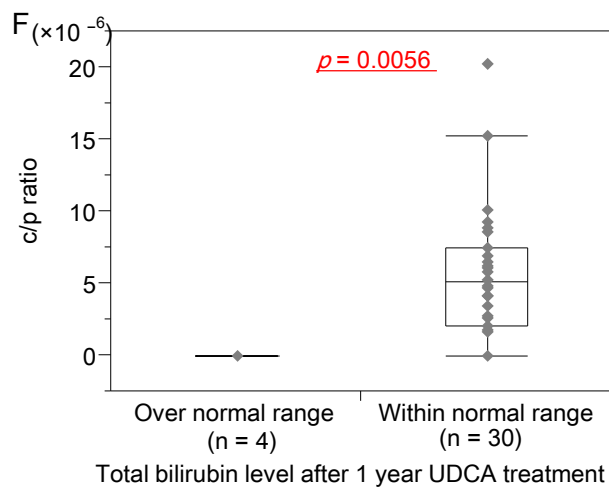
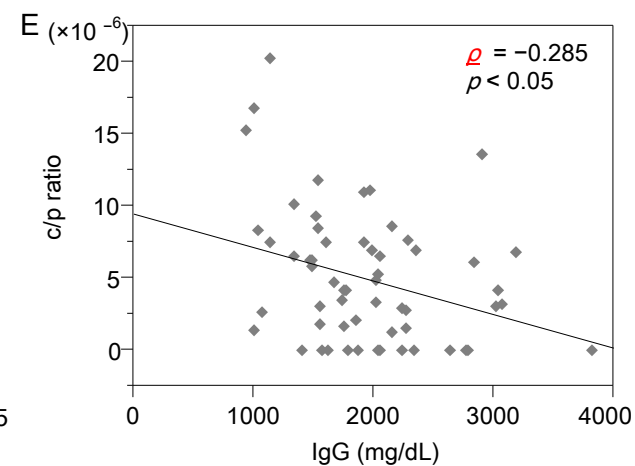
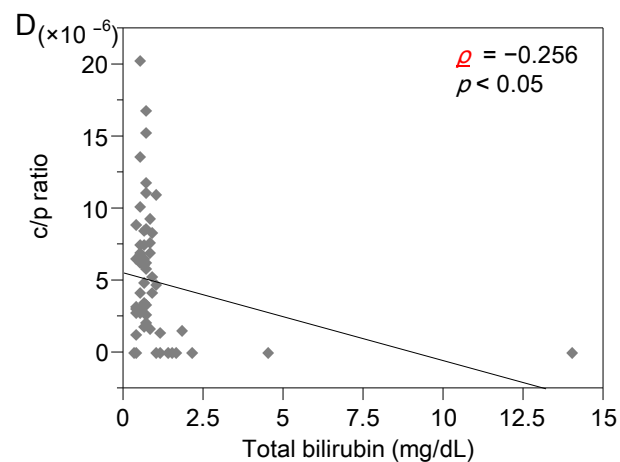
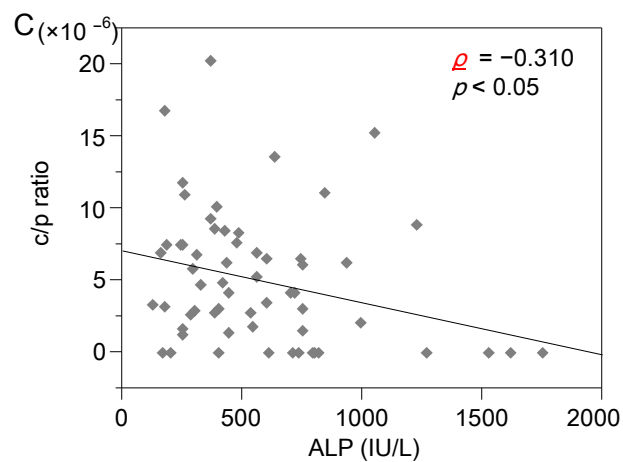
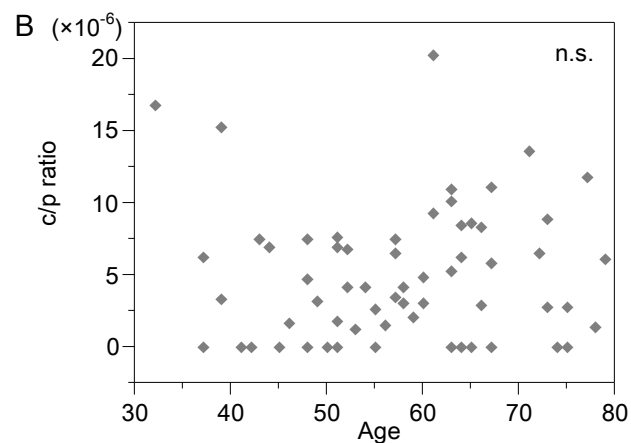
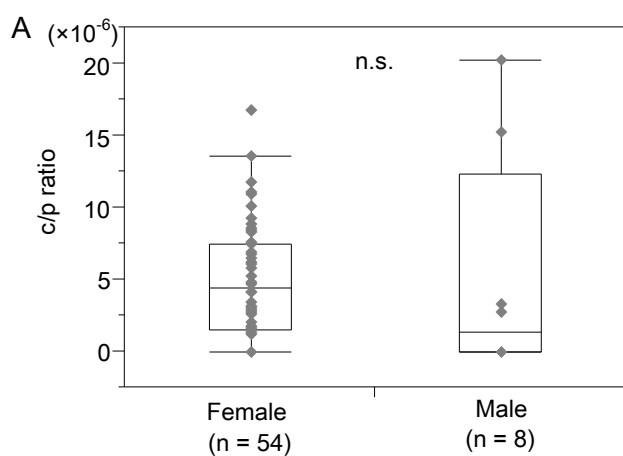
23. Brunt EM, Janney CG, Di Bisceglie AM, Neuschwander-Tetri BA, Bacon BR. Nonalcoholic steatohepatitis: a proposal for grading and staging the histological lesions. *The American journal of gastroenterology*. 1999 Sep;94(9):2467-74. PubMed PMID: 10484010. Epub 1999/09/14. eng.
24. Intraobserver and interobserver variations in liver biopsy interpretation in patients with chronic hepatitis C. The French METAVIR Cooperative Study Group. *Hepatology*. 1994 Jul;20(1 Pt 1):15-20. PubMed PMID: 8020885. Epub 1994/07/01. eng.
25. Saxena R, Theise N. Canals of Hering: recent insights and current knowledge. *Seminars in liver disease*. 2004 Feb;24(1):43-8. PubMed PMID: 15085485. Epub 2004/04/16. eng.
26. Scheuer P. Primary biliary cirrhosis. *Proceedings of the Royal Society of Medicine*. 1967 Dec;60(12):1257-60. PubMed PMID: 6066569. Pubmed Central PMCID: PMC1901478. Epub 1967/12/01. eng.
27. Ding ZY, Jin GN, Liang HF, Wang W, Chen WX, Datta PK, et al. Transforming growth factor beta induces expression of connective tissue growth factor in hepatic progenitor cells through Smad independent signaling. *Cellular signalling*. 2013 Oct;25(10):1981-92. PubMed PMID: 23727026.
28. Delladetsima J, Alexandrou P, Giaslakitiotis K, Psychogiou M, Hatzis G, Sypsa V, et al. Hepatic progenitor cells in chronic hepatitis C: a phenomenon of older age and advanced liver disease. *Virchows Archiv : an international journal of pathology*. 2010 Oct;457(4):457-66. PubMed PMID: 20721577.
29. Skoien R, Richardson MM, Jonsson JR, Powell EE, Brunt EM, Neuschwander-Tetri BA, et al. Heterogeneity of fibrosis patterns in non-alcoholic fatty liver disease supports the presence of multiple fibrogenic pathways. *Liver international : official journal of the International Association for the Study of the Liver*. 2013 Apr;33(4):624-32. PubMed PMID: 23356584.
30. Svegliati-Baroni G, Ridolfi F, Hannivoort R, Saccomanno S, Homan M, de Minicis S, et al. Bile acids induce hepatic stellate cell proliferation via activation of the epidermal growth factor receptor. *Gastroenterology*. 2005;128(4):1042-55.
31. Harada K, Nakanuma Y. Cholangiopathy with respect to biliary innate immunity. *International journal of hepatology*. 2012;2012:793569. PubMed PMID: 21994888. Pubmed Central PMCID: 3168927.



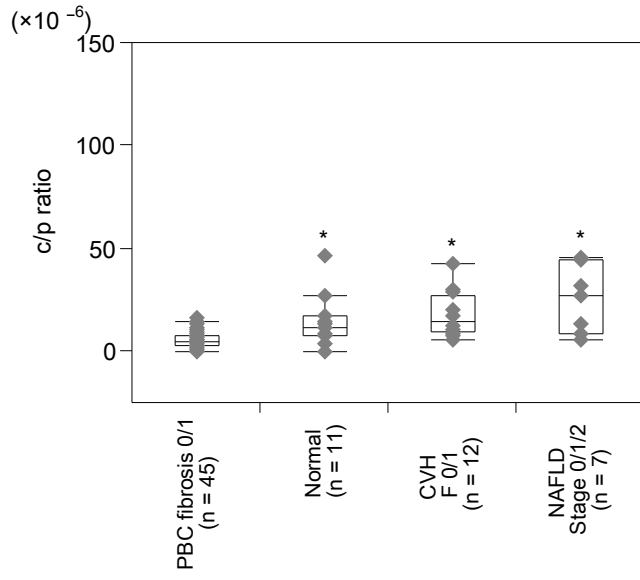
A







A



B

