

Unique Venous Drainage of a Sphenoid Wing Dural Arteriovenous Fistula with Ocular Symptoms

著者	Misaki Kouichi, Uchiyama Naoyuki, Mohri Masanao, Aida Yasuhiro, Uno Takehiro, Nakada Mitsutoshi
journal or publication title	World Neurosurgery
volume	97
page range	753.e1-753.e5
year	2017-01-01
URL	http://hdl.handle.net/2297/46753

doi: 10.1016/j.wneu.2016.10.055

Title:

Unique venous drainage of a sphenoid wing dural arteriovenous fistula with ocular symptoms

Authors:

Kouichi Misaki, MD, Naoyuki Uchiyama, MD, Masanao Mohri, MD, Yasuhiro Aida, MD, Takehiro Uno, MD, Mitsutoshi Nakada, MD

Affiliations:

Department of Neurosurgery, Division of Neuroscience, Graduate School of Medical Science, Kanazawa University, Japan

Corresponding author

Kouichi Misaki

Department of Neurosurgery, Division of Neuroscience, Graduate School of Medical Science, Kanazawa University, 13-1 Takara-machi, Kanazawa, Ishikawa 920-8641, Japan

Phone: 076-265-2384, Fax: 076-234-4262, E-mail: misaki@med.kanazawa-u.ac.jp

Conflict of interest

We declare that we have no conflict of interest.

Abstract

Dural arteriovenous fistulas (DAVFs) presenting with ocular symptoms, such as exophthalmos and chemosis, are commonly situated in cavernous sinus (CS). DAVFs at the sphenoid wing with a drainage route into the superior orbital vein (SOV) should be considered as one of differential diagnosis of ocular symptoms. A 41-year-old woman presented with progressive left-sided chemosis and proptosis after left pulsating tinnitus that disappeared spontaneously. Cerebral angiography showed that the fistula was situated along the inferior edge of the superior orbital fissure on the greater sphenoid wing and drained solely into the SOV without flowing into the CS that caused ocular symptoms. Transvenous selective catheterization was performed via the facial vein and SOV. The fistula was then embolized using detachable coils. After embolization, the ocular symptoms resolved, and the patient was discharged without neurological deficit. Herein, we discuss the developmental mechanism of the unique drainage pattern, including the clinical symptoms and anatomical features of greater sphenoid wing DAVFs.

Key word: dural arteriovenous fistula, greater sphenoid wing, superior orbital vein, transvenous embolization, target coil embolization, venous thrombus

Introduction

Dural arteriovenous fistulas (DAVFs) at the cavernous sinus (CS) commonly involve drainage flow into the superior orbital vein (SOV) accompanied by ocular symptoms such as exophthalmos and chemosis. Although a rare entity, a DAVF situated at the sphenoid wing with drainage flow into the SOV should be considered one of the differential diagnoses of ocular symptoms. Transvenous embolization (TVE) for such cases after an inaccurate evaluation of the fistulous area may lead to deteriorating ocular symptoms due to the mass effect of too many coils inserted into the SOV.¹ Herein, we present a rare case of a greater sphenoid wing DAVF with a unique drainage pattern, a single drainage route into the SOV without involvement of the CS or the cortical vein. To our knowledge, this is the first report to describe the developmental mechanism of this sole drainage route into the SOV, including the clinical symptoms and anatomical features of greater sphenoid wing DAVFs.

Case report

A 41-year-old woman presented with left pulsatile tinnitus that disappeared in 2 weeks. She then experienced progressive left exophthalmia and chemosis for 1 month, and was referred to our hospital by an ophthalmologist. Physical examination revealed increased conjunctival vascularity and painless left exophthalmia. No apparent oculomotor paralysis or loss of visual acuity was found. Intraocular pressure in the left eye was 31.0 mmHg (17.9 mmHg in the right). She had no history of trauma, surgery, infection or autoimmune disease.

Magnetic resonance angiography demonstrated enlarged left SOV and extending narrow hyperintense area in the anterior part of the middle temporal fossa without abnormal hyperintensity in the CS (Fig. 1A). On magnetic resonance image, both T1- and T2-weighted images without contrast media showed a hyperintense area in the anterior part of the CS that was considered a thrombus (Fig. 1B). Contrast-enhanced three-dimensional computed tomography also revealed the dilated SOV and a rod-like

enhanced area in the greater sphenoid wing, which connected to the SOV in the superior orbital fissure (Fig. 1D). Left common carotid angiography revealed a DAVF supplied concurrently by the meningeal branches from ophthalmic artery and middle meningeal artery, and that drained into the SOV and facial vein (Fig. 2A, B). A frontal view on left common carotid angiography revealed contrast media concentrating on the rod-like region, which was a shunt point on the greater wing, and flowing medially to drain into the SOV (Fig. 2B). Venous-phase left internal carotid artery angiography showed normal venous flow in the left hemisphere from the superior middle cerebral vein to the CS, and there was no communication in the normal venous flow between the CS and shunt flow in the SOV.

We planned TVE for the DAVF via the SOV. To approach the SOV, we chose not the trans-CS approach but the trans-facial vein approach because opening the channel between the CS and the SOV, which had arterial pressure because of the fistula, may raise the pressure of normal venous flow. Under general anesthesia, coaxial 4-French and 6-French guiding catheters were introduced into the left facial vein **via the femoral vein**. An Excelsior SL-10 microcatheter (Stryker Neurovascular, Fremont, CA) was advanced into the SOV via the facial vein. After the microcatheter was introduced into the rod-like area in the greater sphenoid wing, superselective angiography suggested reflux into the SOV (Fig. 2C). We assigned this area in the greater sphenoid wing as the fistulous point, and first, the fistula was occluded using a 3.0-mm/8-cm Target 360 soft coil (Stryker Neurovascular, Fremont, CA) followed by the use of additional down-sized coils. Complete obliteration of the fistula was achieved by the insertion of 10 coils, equaling the length of 35 cm (Fig. 2D, E). Post-treatment cone-beam computed tomography and skull roentgen examination revealed that the location of inserted coils (the fistulous point) was the anterior part of middle temporal fossa at the greater sphenoid wing (Fig. 3 A-C).

After the procedure, the patient experienced a decrease in chemosis and exophthalmia. The intraocular pressure decreased to 14.0 mmHg. The 3-month angiographic follow-up revealed no evidence of fistula recurrence.

Discussion

Sphenoid wing DAVFs have been reported as DAVFs of the middle cranial fossa,² sphenoid bone,³ lesser sphenoid wing,^{4,5} greater sphenoid wing,¹ sphenobasal sinus,^{6, 7} or sphenoparietal sinus.⁸⁻¹⁰ Shi et al classified sphenoid wing DAVFs into two entities, DAVFs in the lesser and greater sphenoid wings. And they revealed that DAVFs in the sinus of the lesser sphenoid wing tend to drain into the CS, whereas those within the greater wing are located in the sphenobasal or sphenopetrosal sinus and tend to drain into the superficial middle cerebral vein (SMCV).¹¹ DAVFs of the greater sphenoid wing tend to be accompanied by harmful cortical venous drainage, and some cases presenting with subarachnoid hemorrhage have been reported.^{6, 7, 11, 12}

Two systems of venous drainage in the region of the sphenoid bone have been defined embryologically.¹³ One is the prootic sinus system and the other is the primitive tentorial sinus system. The former system receives blood from the primitive maxillary vein, which later develops into the ophthalmic vein, and the prootic sinus finally forms the CS in the 12-week-old embryo. The latter system develops into the SMCV and runs posteriorly, connecting with the transverse sinus in the 8-week-old embryo. Then these two systems anastomose with each other to various degrees until the prenatal stage.¹³⁻¹⁵ Based on this embryological theory, DAVFs in the sphenoid bone seem to drain into either the CS or the cortical vein, or both simultaneously. The mechanism of the draining system solely into the SOV without the CS involvement in present case was unexplainable only by embryology.

Table 1 summarizes the drainage patterns of DAVFs in the greater sphenoid wings. Among four cases with drainage routes including both the SOV and CS, one case was associated with drainage into the CS first, and then into the SOV. Greater sphenoidal wing DAVFs draining solely into the SOV with no involvement of the CS are very rare, and only two previous cases are reported.^{1, 2} In these cases, the blood is collected in the sphenoid greater wing, and then drained directly into the SOV. A fistulous point located

near the junction of SOV and CS, and obstructive lesions, such as thrombosis or compartmentalization in the CS, blocking the flow into the CS are potentially involved in the pathogenesis of SOV-only drainage.¹ In the present case, T1- and T2-weighted images showed a hyperintense area in the anterior part of the CS that was considered a subacute thrombus.¹⁶ The fact that the patients experienced left pulsative tinnitus 2 weeks before presenting with exophthalmos and chemosis may indicate that the shunt flowed into the CS and the SOV first, causing left-sided tinnitus (Fig. 4A), followed by obstruction of the drainage into CS, causing drainage into the SOV with subsequent resolution of tinnitus (Fig. 4B). **Reports on the natural history of DAVFs demonstrated that arteriovenous fistulae cause an increase in pressure, resulting in thickening of the intima in the affected sinus and adjacent draining venous channels. This progressive steno-occlusive change was then followed by spontaneous occlusion with thrombus formation.**^{17,18}

The two reported cases of greater wing DAVFs with a single drainage route into the SOV were treated with transarterial embolization in one case, and TVE of the SOV by direct cannulation with surgical exposure in the other.^{1,2} In the latter case, proptosis remained due to the mass effect caused by coils inserted in the SOV. Recently, superselective shunt occlusion has been reported, which involves complete extirpation of DAVFs achieved by the insertion of few coils into the restricted loci of arteriovenous shunts.¹⁹ Closer evaluation of the fistulous sites using three-dimensional angiography and the use of appropriate coils enabled us to perform superselective shunt occlusion with a minimum number of coils and improve the patient's proptosis. **Trans-arterial embolization with glue or Onyx was another possible therapeutic option for this present case. However, this alternative presented a risk of visual disturbance due to potential embolization to the central retinal artery, either directly, or indirectly through the anastomosis from the middle meningeal artery. Moreover, trans-arterial embolization often results in incomplete radiographic occlusion of the fistula, and is therefore best avoided. The fistulous point in the greater sphenoid wing and the SOV was accessible via a direct surgical approach. However, surgical exposure of the fistula may cause exclusion of the thrombus in the anterior part of the CS, and is more**

invasive than endovascular therapy. Thus, we considered surgical closure of the fistula as a second-line option.

Intraocular DAVFs, which involve a fistula from the ophthalmic artery to the draining ophthalmic veins and are associated with ocular symptoms, must be differentiated from CS DAVFs. The drainage route of intraocular DAVFs involves only the SOV and subsequent flow into the CS.^{2, 20, 21} Although the fistulous points of intraocular DAVFs are not identified in the optic nerve sheath in all cases, Piske and Lasjaunias reported that DAVFs situated along the optic nerve may be quite similar to conventional intracranial meningeal arteriovenous shunts because the optic nerve is contained within an arachnoid and dural sheath.²

In conclusion, greater wing DAVFs should be considered during the differential diagnosis of CS DAVFs. The thrombus formation in the anterior part of the CS contributed to the establishment of a unique drainage pattern that solely flowed into the SOV without involving the CS. The fistulous point should be carefully evaluated throughout treatment to obtain favorable endovascular surgery results.

References

1. Cohen JE, Gomori JM, Grigoriadis S, Spektor S, Rajz G: Dural arteriovenous fistula of the greater sphenoid wing region in neurofibromatosis type 1. *Pediatr Neurosurg.* 2008;44:172-175.
2. Piske RL, Lasjaunias P: Extrasinusal dural arteriovenous malformations. Report of three cases. *Neuroradiol.* 1988;30:426-432.
3. Park ES, Jung YJ, Yun JH, Ahn JS, Lee DH: Intraosseous arteriovenous malformation of the sphenoid bone presenting with orbital symptoms mimicking cavernous sinus dural arteriovenous fistula: a case report. *J Cerebrovasc Endovasc Neurosurg.* 2013;15:251-254.
4. Rezende MT, Piotin M, Mounayer C, Spelle L, Abud DG, Moret J: Dural arteriovenous fistula of the lesser sphenoid wing region treated with Onyx: technical note. *Neuroradiol.* 2006;48:130-134.
5. San Millan Ruiz D, Fasel JH, Rufenacht DA, Gailloud P: The sphenoparietal sinus of breschet: does it exist? An anatomic study. *AJNR Am J Neuroradiol.* 2004;25:112-120.
6. Nomura S, Anegawa S, Nakagawa S, Tomokiyo M, Koga H, Hayashi T: Subarachnoid hemorrhage caused by dural arteriovenous fistula of the sphenobasal sinus--case report. *Neurol Med Chir.* 2002;42:255-258.
7. Zhou LF, Chen L, Song DL, Gu YX, Leng B: Dural arteriovenous fistula of the sphenobasilar sinus with concomitant meningioma: case report and review of the literature. *Neurosurg Rev* 2007;30:269-274; discussion 274.
8. Pakarinen S: Arteriovenous fistula between the middle meningeal artery and the sphenoparietal sinus. A case report. *J Neurosurg.* 1965;23:438-439.
9. Smith JE, Epps J, Press HC, Jr., Adair LB: Traumatic arteriovenous fistula between the middle meningeal artery and the sphenoparietal sinus: a case report and review of the world literature. *J Natl Med Assoc.* 1981;73:274-278.
10. Watanabe T, Matsumaru Y, Sonobe M, Asahi T, Onitsuka K, Sugita K, Takahashi S, Nose T: Multiple dural arteriovenous fistulae involving the cavernous and sphenoparietal sinuses. *Neuroradiol.* 2000;42:771-774.
11. Shi ZS, Ziegler J, Feng L, Gonzalez NR, Tateshima S, Jahan R, Martin NA, Vinuela F, Duckwiler GR: Middle cranial fossa sphenoidal region dural arteriovenous fistulas: anatomic and treatment considerations. *AJNR Am J Neuroradiol.* 2013;34:373-380.
12. Fukuda H, Miyake K, Kunieda T, Murao K: Endovascular treatment of sphenoid wing dural arteriovenous fistula with pure cortical venous drainage. *J Stroke Cerebrovasc Dis.* 2014;23:1730-1735.
13. Padget DH: The cranial venous system in man in reference to development, adult configuration, and relation to the arteries. *Am J Anat.* 1956;98:307-355.

14. Tanoue S, Kiyosue H, Okahara M, Sagara Y, Hori Y, Kashiwagi J, Mori H: Para-cavernous sinus venous structures: anatomic variations and pathologic conditions evaluated on fat-suppressed 3D fast gradient-echo MR images. *AJNR Am J Neuroradiol.* 2006;27:1083-1089.
15. Suzuki Y, Matsumoto K: Variations of the superficial middle cerebral vein: classification using three-dimensional CT angiography. *AJNR Am J Neuroradiol.* 2000;21:932-938.
16. Ginat DT, Meyers SP: Intracranial lesions with high signal intensity on T1-weighted MR images: differential diagnosis. *Radiographics.* 2012;32:499-516.
17. Tanioka S, Sato Y, Nampei M, Tsuda K, Niwa S, Suzuki H: Cavernous sinus dural arteriovenous fistula presenting with intracerebral hemorrhage associated with chronological angiographic demonstration of disturbed leptomeningeal venous drainage as the sole outflow route: a case report. *World Neurosurg.* 2016 in press.
18. Satomi J, Satoh K, Matsubara S, Nakajima N, Nagahiro S: Angiographic changes in venous drainage of cavernous sinus dural arteriovenous fistulae after palliative transarterial embolization or observational management: a proposed stage classification. *Neurosurgery.* 2005;56:494-502.
19. Satow T, Murao K, Matsushige T, Fukuda K, Miyamoto S, Iihara K: Superselective shunt occlusion for the treatment of cavernous sinus dural arteriovenous fistulae. *Neurosurgery.* 2013;73:ons100-105.
20. Hamada J, Morioka M, Kai Y, Sakurama T, Kuratsu J: Spontaneous arteriovenous fistula of the orbit: case report. *Surgical neurology.* 2006;65:55-57.
21. Williamson RW, Ducruet AF, Crowley RW, McDougall CG, Albuquerque FC: Transvenous coil embolization of an intraorbital arteriovenous fistula: case report and review of the literature. *Neurosurgery.* 2013;72:E130-134.

Figure legends

Figure 1

- A: A source magnetic resonance angiography image demonstrating enlarged left superior orbital vein (SOV, large arrow) and extending narrow hyperintensity area in the anterior part of the middle temporal fossa (arrowhead) without abnormal hyperintensity in the cavernous sinus (small arrow).
- B, C: T1- (B) and T2- (C) weighted images showing a small hyperintense area (double arrow) just behind the flow void at the anterior part of the middle cranial fossa (dotted arrow), which is considered the shunt flow.
- D: A three-dimensional computed tomography angiography image with reconstruction at the middle cranial fossa, posterior view shows a rod-like fistulous region in the middle cranial fossa (arrowheads).

Figure 2

- A: Left common carotid angiography, lateral view demonstrates an arteriovenous shunt fed by the recurrent meningeal artery from the ophthalmic artery (large arrowhead) and middle meningeal artery (small arrowhead), and subsequently draining into the superior orbital vein (SOV) (large arrow) and facial vein (small arrow).
- B: The frontal view of left common carotid angiography reveals contrast media concentrated on the rod-like region of the greater wing (arrowhead) and then flows medially to drain into the SOV (arrow).
- C: An injection from a microcatheter at the shunt point (arrowhead) reveals the fistulous zone and drainage route into the SOV (arrow).
- D: The coil mass is limited to the narrow area of the fistulous zone (arrowhead).
- E: Final left common carotid angiography showing complete obliteration of the fistula.

Figure 3

A-C: Post-treatment computed tomography (A) and skull roentgenogram images, frontal (B) and lateral (C) view show the coil mass located at the anterior part of the middle cranial fossa at the greater sphenoid wing.

Figure 4

A, B: Changes in the drainage flow pattern. Initial drainage (A) flowed into both the superior orbital vein and the cavernous sinus (arrows) from the fistulous area of the greater sphenoid bone (arrowhead) when the patient complained of left pulsating tinnitus. After the thrombus formed in the anterior part of the cavernous sinus (B; dotted arrow), the shunt flow from the fistulous area (arrowhead) drained solely into the superior orbital vein (arrows) without involving the cavernous sinus. At this point, the exophthalmos and chemosis became rapidly exacerbated instead of the tinnitus disappearing.

Highlights

- Greater wing dural arteriovenous fistulas should be considered during the differential diagnosis of cavernous sinus dural arteriovenous fistulas.
- The thrombus formation in the anterior part of the cavernous sinus contributed to the establishment of a unique drainage pattern that solely flowed into the superior orbital vein without involving the cavernous sinus.
- The fistulous point should be carefully evaluated throughout treatment to obtain favorable endovascular surgery results.

Title:

Unique venous drainage of a sphenoid wing dural arteriovenous fistula with ocular symptoms

Authors:

Kouichi Misaki, MD, Naoyuki Uchiyama, MD, Masanao Mohri, MD, Yasuhiro Aida, MD, Takehiro Uno, MD, Mitsutoshi Nakada, MD

Affiliations:

Department of Neurosurgery, Division of Neuroscience, Graduate School of Medical Science, Kanazawa University, Japan

Corresponding author

Kouichi Misaki

Department of Neurosurgery, Division of Neuroscience, Graduate School of Medical Science, Kanazawa University, 13-1 Takara-machi, Kanazawa, Ishikawa 920-8641, Japan

Phone: 076-265-2384, Fax: 076-234-4262, E-mail: misaki@med.kanazawa-u.ac.jp

Conflict of interest

We declare that we have no conflict of interest.

Abstract

Dural arteriovenous fistulas (DAVFs) presenting with ocular symptoms, such as exophthalmos and chemosis, are commonly situated in cavernous sinus (CS). DAVFs at the sphenoid wing with a drainage route into the superior orbital vein (SOV) should be considered as one of differential diagnosis of ocular symptoms. A 41-year-old woman presented with progressive left-sided chemosis and proptosis after left pulsating tinnitus that disappeared spontaneously. Cerebral angiography showed that the fistula was situated along the inferior edge of the superior orbital fissure on the greater sphenoid wing and drained solely into the SOV without flowing into the CS that caused ocular symptoms. Transvenous selective catheterization was performed via the facial vein and SOV. The fistula was then embolized using detachable coils. After embolization, the ocular symptoms resolved, and the patient was discharged without neurological deficit. Herein, we discuss the developmental mechanism of the unique drainage pattern, including the clinical symptoms and anatomical features of greater sphenoid wing DAVFs.

Key word: dural arteriovenous fistula, greater sphenoid wing, superior orbital vein, transvenous embolization, target coil embolization, venous thrombus

Introduction

Dural arteriovenous fistulas (DAVFs) at the cavernous sinus (CS) commonly involve drainage flow into the superior orbital vein (SOV) accompanied by ocular symptoms such as exophthalmos and chemosis. Although a rare entity, a DAVF situated at the sphenoid wing with drainage flow into the SOV should be considered one of the differential diagnoses of ocular symptoms. Transvenous embolization (TVE) for such cases after an inaccurate evaluation of the fistulous area may lead to deteriorating ocular symptoms due to the mass effect of too many coils inserted into the SOV.¹ Herein, we present a rare case of a greater sphenoid wing DAVF with a unique drainage pattern, a single drainage route into the SOV without involvement of the CS or the cortical vein. To our knowledge, this is the first report to describe the developmental mechanism of this sole drainage route into the SOV, including the clinical symptoms and anatomical features of greater sphenoid wing DAVFs.

Case report

A 41-year-old woman presented with left pulsatile tinnitus that disappeared in 2 weeks. She then experienced progressive left exophthalmia and chemosis for 1 month, and was referred to our hospital by an ophthalmologist. Physical examination revealed increased conjunctival vascularity and painless left exophthalmia. No apparent oculomotor paralysis or loss of visual acuity was found. Intraocular pressure in the left eye was 31.0 mmHg (17.9 mmHg in the right). She had no history of trauma, surgery, infection or autoimmune disease.

Magnetic resonance angiography demonstrated enlarged left SOV and extending narrow hyperintense area in the anterior part of the middle temporal fossa without abnormal hyperintensity in the CS (Fig. 1A). On magnetic resonance image, both T1- and T2-weighted images without contrast media showed a hyperintense area in the anterior part of the CS that was considered a thrombus (Fig. 1B). Contrast-enhanced three-dimensional computed tomography also revealed the dilated SOV and a rod-like

enhanced area in the greater sphenoid wing, which connected to the SOV in the superior orbital fissure (Fig. 1D). Left common carotid angiography revealed a DAVF supplied concurrently by the meningeal branches from ophthalmic artery and middle meningeal artery, and that drained into the SOV and facial vein (Fig. 2A, B). A frontal view on left common carotid angiography revealed contrast media concentrating on the rod-like region, which was a shunt point on the greater wing, and flowing medially to drain into the SOV (Fig. 2B). Venous-phase left internal carotid artery angiography showed normal venous flow in the left hemisphere from the superior middle cerebral vein to the CS, and there was no communication in the normal venous flow between the CS and shunt flow in the SOV.

We planned TVE for the DAVF via the SOV. To approach the SOV, we chose not the trans-CS approach but the trans-facial vein approach because opening the channel between the CS and the SOV, which had arterial pressure because of the fistula, may raise the pressure of normal venous flow. Under general anesthesia, coaxial 4-French and 6-French guiding catheters were introduced into the left facial vein via the femoral vein. An Excelsior SL-10 microcatheter (Stryker Neurovascular, Fremont, CA) was advanced into the SOV via the facial vein. After the microcatheter was introduced into the rod-like area in the greater sphenoid wing, superselective angiography suggested reflux into the SOV (Fig. 2C). We assigned this area in the greater sphenoid wing as the fistulous point, and first, the fistula was occluded using a 3.0-mm/8-cm Target 360 soft coil (Stryker Neurovascular, Fremont, CA) followed by the use of additional down-sized coils. Complete obliteration of the fistula was achieved by the insertion of 10 coils, equaling the length of 35 cm (Fig. 2D, E). Post-treatment cone-beam computed tomography and skull roentgen examination revealed that the location of inserted coils (the fistulous point) was the anterior part of middle temporal fossa at the greater sphenoid wing (Fig. 3 A-C).

After the procedure, the patient experienced a decrease in chemosis and exophthalmia. The intraocular pressure decreased to 14.0 mmHg. The 3-month angiographic follow-up revealed no evidence of fistula recurrence.

Discussion

Sphenoid wing DAVFs have been reported as DAVFs of the middle cranial fossa,² sphenoid bone,³ lesser sphenoid wing,^{4,5} greater sphenoid wing,¹ sphenobasal sinus,^{6, 7} or sphenoparietal sinus.⁸⁻¹⁰ Shi et al classified sphenoid wing DAVFs into two entities, DAVFs in the lesser and greater sphenoid wings. And they revealed that DAVFs in the sinus of the lesser sphenoid wing tend to drain into the CS, whereas those within the greater wing are located in the sphenobasal or sphenopetrosal sinus and tend to drain into the superficial middle cerebral vein (SMCV).¹¹ DAVFs of the greater sphenoid wing tend to be accompanied by harmful cortical venous drainage, and some cases presenting with subarachnoid hemorrhage have been reported.^{6, 7, 11, 12}

Two systems of venous drainage in the region of the sphenoid bone have been defined embryologically.¹³ One is the prootic sinus system and the other is the primitive tentorial sinus system. The former system receives blood from the primitive maxillary vein, which later develops into the ophthalmic vein, and the prootic sinus finally forms the CS in the 12-week-old embryo. The latter system develops into the SMCV and runs posteriorly, connecting with the transverse sinus in the 8-week-old embryo. Then these two systems anastomose with each other to various degrees until the prenatal stage.¹³⁻¹⁵ Based on this embryological theory, DAVFs in the sphenoid bone seem to drain into either the CS or the cortical vein, or both simultaneously. The mechanism of the draining system solely into the SOV without the CS involvement in present case was unexplainable only by embryology.

Table 1 summarizes the drainage patterns of DAVFs in the greater sphenoid wings. Among four cases with drainage routes including both the SOV and CS, one case was associated with drainage into the CS first, and then into the SOV. Greater sphenoidal wing DAVFs draining solely into the SOV with no involvement of the CS are very rare, and only two previous cases are reported.^{1, 2} In these cases, the blood is collected in the sphenoid greater wing, and then drained directly into the SOV. A fistulous point located

near the junction of SOV and CS, and obstructive lesions, such as thrombosis or compartmentalization in the CS, blocking the flow into the CS are potentially involved in the pathogenesis of SOV-only drainage.¹ In the present case, T1- and T2-weighted images showed a hyperintense area in the anterior part of the CS that was considered a subacute thrombus.¹⁶ The fact that the patients experienced left pulsative tinnitus 2 weeks before presenting with exophthalmos and chemosis may indicate that the shunt flowed into the CS and the SOV first, causing left-sided tinnitus (Fig. 4A), followed by obstruction of the drainage into CS, causing drainage into the SOV with subsequent resolution of tinnitus (Fig. 4B). Reports on the natural history of DAVFs demonstrated that arteriovenous fistulae cause an increase in pressure, resulting in thickening of the intima in the affected sinus and adjacent draining venous channels. This progressive steno-occlusive change was then followed by spontaneous occlusion with thrombus formation.^{17, 18}

The two reported cases of greater wing DAVFs with a single drainage route into the SOV were treated with transarterial embolization in one case, and TVE of the SOV by direct cannulation with surgical exposure in the other.^{1,2} In the latter case, proptosis remained due to the mass effect caused by coils inserted in the SOV. Recently, superselective shunt occlusion has been reported, which involves complete extirpation of DAVFs achieved by the insertion of few coils into the restricted loci of arteriovenous shunts.¹⁹ Closer evaluation of the fistulous sites using three-dimensional angiography and the use of appropriate coils enabled us to perform superselective shunt occlusion with a minimum number of coils and improve the patient's proptosis. Trans-arterial embolization with glue or Onyx was another possible therapeutic option for this present case. However, this alternative presented a risk of visual disturbance due to potential embolization to the central retinal artery, either directly, or indirectly through the anastomosis from the middle meningeal artery. Moreover, trans-arterial embolization often results in incomplete radiographic occlusion of the fistula, and is therefore best avoided. The fistulous point in the greater sphenoid wing and the SOV was accessible via a direct surgical approach. However, surgical exposure of the fistula may cause exclusion of the thrombus in the anterior part of the CS, and is more

invasive than endovascular therapy. Thus, we considered surgical closure of the fistula as a second-line option.

Intraocular DAVFs, which involve a fistula from the ophthalmic artery to the draining ophthalmic veins and are associated with ocular symptoms, must be differentiated from CS DAVFs. The drainage route of intraocular DAVFs involves only the SOV and subsequent flow into the CS.^{2, 20, 21} Although the fistulous points of intraocular DAVFs are not identified in the optic nerve sheath in all cases, Piske and Lasjaunias reported that DAVFs situated along the optic nerve may be quite similar to conventional intracranial meningeal arteriovenous shunts because the optic nerve is contained within an arachnoid and dural sheath.²

In conclusion, greater wing DAVFs should be considered during the differential diagnosis of CS DAVFs. The thrombus formation in the anterior part of the CS contributed to the establishment of a unique drainage pattern that solely flowed into the SOV without involving the CS. The fistulous point should be carefully evaluated throughout treatment to obtain favorable endovascular surgery results.

References

1. Cohen JE, Gomori JM, Grigoriadis S, Spektor S, Rajz G: Dural arteriovenous fistula of the greater sphenoid wing region in neurofibromatosis type 1. *Pediatr Neurosurg.* 2008;44:172-175.
2. Piske RL, Lasjaunias P: Extrasinusal dural arteriovenous malformations. Report of three cases. *Neuroradiol.* 1988;30:426-432.
3. Park ES, Jung YJ, Yun JH, Ahn JS, Lee DH: Intraosseous arteriovenous malformation of the sphenoid bone presenting with orbital symptoms mimicking cavernous sinus dural arteriovenous fistula: a case report. *J Cerebrovasc Endovasc Neurosurg.* 2013;15:251-254.
4. Rezende MT, Piotin M, Mounayer C, Spelle L, Abud DG, Moret J: Dural arteriovenous fistula of the lesser sphenoid wing region treated with Onyx: technical note. *Neuroradiol.* 2006;48:130-134.
5. San Millan Ruiz D, Fasel JH, Rufenacht DA, Gailloud P: The sphenoparietal sinus of breschet: does it exist? An anatomic study. *AJNR Am J Neuroradiol.* 2004;25:112-120.
6. Nomura S, Anegawa S, Nakagawa S, Tomokiyo M, Koga H, Hayashi T: Subarachnoid hemorrhage caused by dural arteriovenous fistula of the sphenobasal sinus--case report. *Neurol Med Chir.* 2002;42:255-258.
7. Zhou LF, Chen L, Song DL, Gu YX, Leng B: Dural arteriovenous fistula of the sphenobasilar sinus with concomitant meningioma: case report and review of the literature. *Neurosurg Rev* 2007;30:269-274; discussion 274.
8. Pakarinen S: Arteriovenous fistula between the middle meningeal artery and the sphenoparietal sinus. A case report. *J Neurosurg.* 1965;23:438-439.
9. Smith JE, Epps J, Press HC, Jr., Adair LB: Traumatic arteriovenous fistula between the middle meningeal artery and the sphenoparietal sinus: a case report and review of the world literature. *J Natl Med Assoc.* 1981;73:274-278.
10. Watanabe T, Matsumaru Y, Sonobe M, Asahi T, Onitsuka K, Sugita K, Takahashi S, Nose T: Multiple dural arteriovenous fistulae involving the cavernous and sphenoparietal sinuses. *Neuroradiol.* 2000;42:771-774.
11. Shi ZS, Ziegler J, Feng L, Gonzalez NR, Tateshima S, Jahan R, Martin NA, Vinuela F, Duckwiler GR: Middle cranial fossa sphenoidal region dural arteriovenous fistulas: anatomic and treatment considerations. *AJNR Am J Neuroradiol.* 2013;34:373-380.
12. Fukuda H, Miyake K, Kunieda T, Murao K: Endovascular treatment of sphenoid wing dural arteriovenous fistula with pure cortical venous drainage. *J Stroke Cerebrovasc Dis.* 2014;23:1730-1735.
13. Padget DH: The cranial venous system in man in reference to development, adult configuration, and relation to the arteries. *Am J Anat.* 1956;98:307-355.

14. Tanoue S, Kiyosue H, Okahara M, Sagara Y, Hori Y, Kashiwagi J, Mori H: Para-cavernous sinus venous structures: anatomic variations and pathologic conditions evaluated on fat-suppressed 3D fast gradient-echo MR images. *AJNR Am J Neuroradiol.* 2006;27:1083-1089.
15. Suzuki Y, Matsumoto K: Variations of the superficial middle cerebral vein: classification using three-dimensional CT angiography. *AJNR Am J Neuroradiol.* 2000;21:932-938.
16. Ginat DT, Meyers SP: Intracranial lesions with high signal intensity on T1-weighted MR images: differential diagnosis. *Radiographics.* 2012;32:499-516.
17. Tanioka S, Sato Y, Nampei M, Tsuda K, Niwa S, Suzuki H: Cavernous sinus dural arteriovenous fistula presenting with intracerebral hemorrhage associated with chronological angiographic demonstration of disturbed leptomeningeal venous drainage as the sole outflow route: a case report. *World Neurosurg.* 2016 in press.
18. Satomi J, Satoh K, Matsubara S, Nakajima N, Nagahiro S: Angiographic changes in venous drainage of cavernous sinus dural arteriovenous fistulae after palliative transarterial embolization or observational management: a proposed stage classification. *Neurosurgery.* 2005;56:494-502.
19. Satow T, Murao K, Matsushige T, Fukuda K, Miyamoto S, Iihara K: Superselective shunt occlusion for the treatment of cavernous sinus dural arteriovenous fistulae. *Neurosurgery.* 2013;73:ons100-105.
20. Hamada J, Morioka M, Kai Y, Sakurama T, Kuratsu J: Spontaneous arteriovenous fistula of the orbit: case report. *Surgical neurology.* 2006;65:55-57.
21. Williamson RW, Ducruet AF, Crowley RW, McDougall CG, Albuquerque FC: Transvenous coil embolization of an intraorbital arteriovenous fistula: case report and review of the literature. *Neurosurgery.* 2013;72:E130-134.

Figure legends

Figure 1

- A: A source magnetic resonance angiography image demonstrating enlarged left superior orbital vein (SOV, large arrow) and extending narrow hyperintensity area in the anterior part of the middle temporal fossa (arrowhead) without abnormal hyperintensity in the cavernous sinus (small arrow).
- B, C: T1- (B) and T2- (C) weighted images showing a small hyperintense area (double arrow) just behind the flow void at the anterior part of the middle cranial fossa (dotted arrow), which is considered the shunt flow.
- D: A three-dimensional computed tomography angiography image with reconstruction at the middle cranial fossa, posterior view shows a rod-like fistulous region in the middle cranial fossa (arrowheads).

Figure 2

- A: Left common carotid angiography, lateral view demonstrates an arteriovenous shunt fed by the recurrent meningeal artery from the ophthalmic artery (large arrowhead) and middle meningeal artery (small arrowhead), and subsequently draining into the superior orbital vein (SOV) (large arrow) and facial vein (small arrow).
- B: The frontal view of left common carotid angiography reveals contrast media concentrated on the rod-like region of the greater wing (arrowhead) and then flows medially to drain into the SOV (arrow).
- C: An injection from a microcatheter at the shunt point (arrowhead) reveals the fistulous zone and drainage route into the SOV (arrow).
- D: The coil mass is limited to the narrow area of the fistulous zone (arrowhead).
- E: Final left common carotid angiography showing complete obliteration of the fistula.

Figure 3

A-C: Post-treatment computed tomography (A) and skull roentgenogram images, frontal (B) and lateral (C) view show the coil mass located at the anterior part of the middle cranial fossa at the greater sphenoid wing.

Figure 4

A, B: Changes in the drainage flow pattern. Initial drainage (A) flowed into both the superior orbital vein and the cavernous sinus (arrows) from the fistulous area of the greater sphenoid bone (arrowhead) when the patient complained of left pulsating tinnitus. After the thrombus formed in the anterior part of the cavernous sinus (B; dotted arrow), the shunt flow from the fistulous area (arrowhead) drained solely into the superior orbital vein (arrows) without involving the cavernous sinus. At this point, the exophthalmos and chemosis became rapidly exacerbated instead of the tinnitus disappearing.

Table 1 Review of cases with the greater sphenoid wing dural arteriovenous fistulas

Reference	Age (years) , sex	Clinical presentation	Venous Drainage			Treatment	Outcome
			SOV	CS	Cortical vein		
Shi et al. ¹¹	60, F	Proptosis, chemosis, tinnitus	+	+	+	TAE+TVE	Cure
	29, F	Proptosis, chemosis	+	+	+	TAE	Cure
	37, F	Proptosis, tinnitus	+	+	-	TAE	Cure
	54, M	Proptosis, Chemosis, visual disturbance	+	+	-	TAE	Cure
	62, M	Visual disturbance	-	+	+	TAE+TVE	Cure
	78, M	Temporal lobe hematoma	-	-	+	TAE	Cure
Zhou et al. ⁷	42, M	Subarachnoid hemorrhage	-	-	+	TAE+Surgery	Cure
Nomura et al. ⁶	59, F	Subarachnoid hemorrhage	-	-	+	Surgery	Cure
Fukuda et al. ¹²	44, M	Headache	-	-	+	TAE	Cure
	58, M	Dizziness	-	-	+	TAE+TVE	Cure
Piske et al. ²	56, M	Visual disturbance	-	-	+	TAE	Cure
	52, F	Proptosis, chemosis, tinnitus	+	-	-	TAE	Cure
Cohen et al. ¹	8, F	Proptosis, chemosis, tinnitus	+	-	-	TVE	Proptosis persisted
Present case	42, F	Proptosis, chemosis, tinnitus	+	-	-	TVE	Cure

CS; cavernous sinus, SOV; superior orbital vein, TAE; transarterial embolization, TVE; transvenous embolization

Figure 1

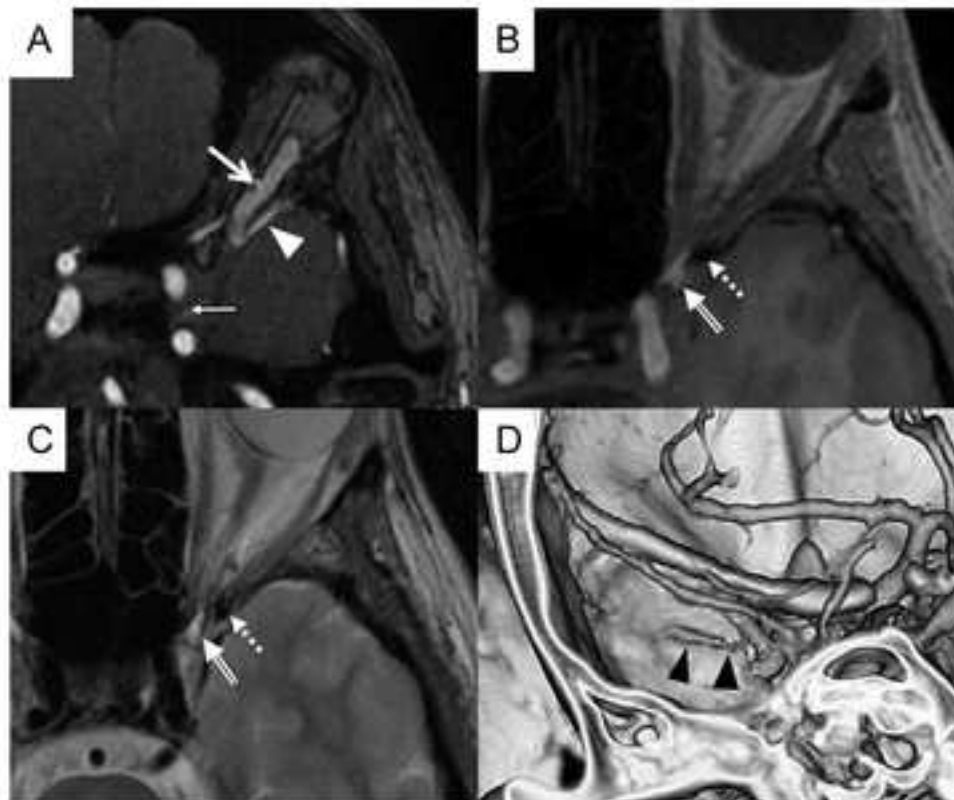


Figure 2

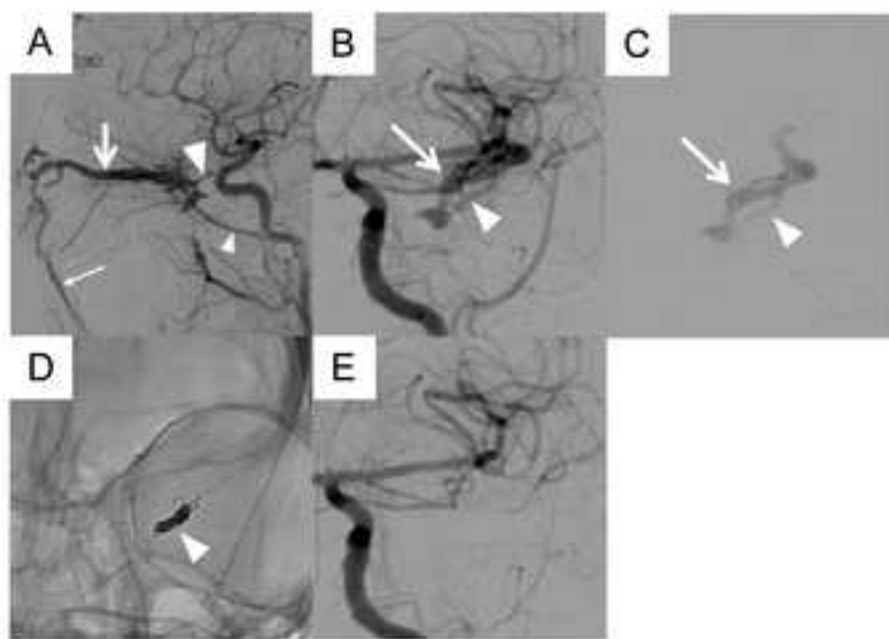


Figure 3

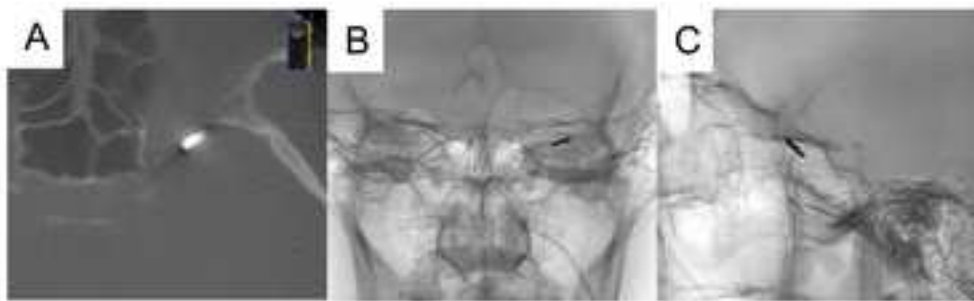


Figure 4

