

Applications of external fixation in long bone tumor

著者	Tsuchiya Hiroyuki, Hayashi Katsuhiro
journal or publication title	The Basic Principles of External Skeletal Fixation Using the Ilizarov and Other Devices
page range	1379-1389
year	2012-01-01
URL	http://hdl.handle.net/2297/44878

doi: 10.1007/978-88-470-2619-3_27

2.19 Applications of External Fixation in Long Bone Tumor

Hiroyuki Tsuchiya, MD, PhD, & Katsuhiko Hayashi, MD, PhD

Department of Orthopedic Surgery, Graduate school of Medical Science, Kanazawa University, 13-1 Takara-machi, Kanazawa-shi, Isikawa-ken, 920-8641, Japan

2.19.1 Introduction

There has been a dramatic improvement in the survival rate of patients with sarcomas and in the successful salvage of limbs as a result of progress in chemotherapy, radiological evaluation, surgical technique and the technology of materials and implants. Complications, however, such as deep infection, fracture, bone resorption, and breakages of prostheses still occur. The challenge to provide long-lasting survival and function of the limb after reconstruction is now being met with biological solutions using living bone. The ideal reconstruction should have biological affinity, resistance to infection, sufficient biomechanical strength, and durability. Vascularised bone transfer has limitations in length and strength and since 1990 distraction osteogenesis which can regenerate bone of sufficient strength for reconstruction has been adopted for tumor surgery.

In this chapter, we describe the Ilizarov method to reconstruct bone defects after tumor excision and the classification of the technique (Tsuchiya H. et al., 1996-2008). The bone defect can be reconstructed by distraction osteogenesis combined with bone grafting (Fig. 2.19.1). Type 2 (Fig. 2.19.2) is the typical procedure for bone tumor surgery because of the frequent affecting location. When the remaining epiphysis is too thin to insert wires, the procedure should be performed as type 4. In type 4, the epiphysis should contain some length of metaphyseal lateral wall in order to stabilize the bone fragment.

2.19.2 Indications

Distraction osteogenesis can be applied for any kind of tumors such as benign and malignant tumor. Some cases of benign or low grade malignant lesion including giant cell tumor, fibrous dysplasia, osteofibrous dysplasia, chondrosarcoma and adamantinoma are suitable for this reconstruction method when the bone defect is too large to reconstruct with bone grafting or other material. It is more indicated when the epiphysis is preserved. If the lesion is high grade malignancy such as osteosarcoma, Ewing's sarcoma and malignant fibrous histiocytoma, and the preoperative chemotherapy is effective, this

method is indicated. When the preoperative chemotherapy is not effective and soft tissue surrounding tumor lesion should be widely excised, this technique is not expected because of poor blood supply and insufficient osteogenesis. In a case with distant metastasis, we do not recommend distraction osteogenesis, because it takes much longer time than prosthetic replacement, taking care of the patient's average life span.

We studied the safety of external fixation during post-operative chemotherapy patients who had undergone distraction osteogenesis after resection of a tumor. Post-operative chemotherapy for malignant bone tumors had only a minimal effect on distraction osteogenesis. When infection occurred, it was controllable in most patients by local antiseptic care and the intravenous administration of antibiotics.

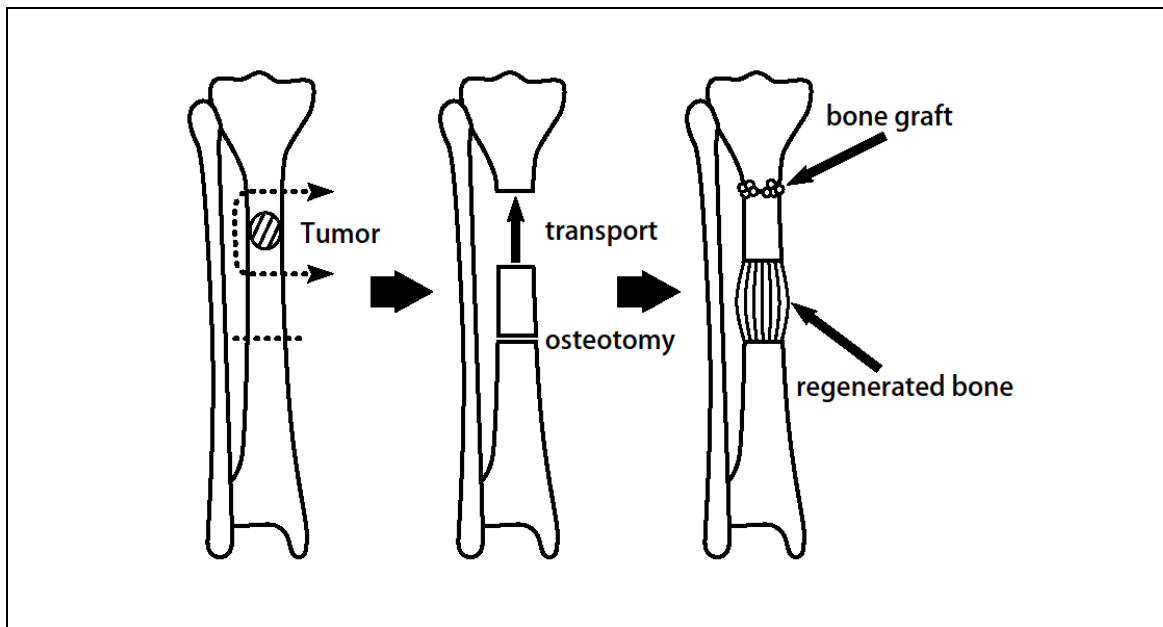


Fig. 2.19.1. The bone defect can be reconstructed by distraction osteogenesis combined with bone grafting

2.19.3 Classification of reconstruction with distraction osteogenesis

We have classified reconstruction with distraction osteogenesis into five types based on the location of the defect after resection of the tumor.

- Type 1. Diaphyseal reconstruction.
- Type 2. Metaphyseal reconstruction.
- Type 3. Epiphyseal reconstruction.
- Type 4. Subarticular reconstruction.
- Type 5. Arthrodesis.

B

In type 1, the diaphyseal defect is reconstructed by bone transport or

shortening-distraction (Fig. 2.19.2). To reconstruct the metaphyseal defect in type 2 Ilizarov wires or half pins for fixation may be used through the remaining epiphysis. In addition to bone transport or shortening-distraction, the metaphyseal defect may be reconstructed with a bone cylinder from the diaphysis, filling the defect by bone transport (Fig. 2.19.3).

Type 3 includes defects of the metaphysis and unilateral defects of the epiphysis. Type-3 metaphyseal defects are reconstructed by shortening the diaphysis or by using a bone cylinder from the diaphysis. A unilateral defect of the epiphysis is repaired with the articular surface of the ipsilateral patella and a strut graft from the iliac crest. The diaphyseal defect is then filled in by bone transport. When the defect has been shortened, a standard lengthening procedure is performed at the diaphysis (Fig. 2.19.4).

The type-4 procedure is used for reconstruction of subarticular defects. Articular cartilage with or without some subchondral bone is left in situ after excision of the tumor, and Ilizarov wires cannot be applied through the epiphysis. A bone cylinder is taken from the diaphysis and fixed by wires to the remaining lateral or medial wall. The newly-created diaphyseal defect is then filled by bone transport (Fig. 2.19.5).

In type-5 procedures arthrodesis is used to reconstruct defects after joint resection and to correct subsequent discrepancy of leg length (Fig. 2.19.6). A unilateral external fixator is convenient for a type-1 reconstruction and for diaphyseal lengthening in a type-5 arthrodesis. An Ilizarov apparatus is useful for the fixation of epiphyseal or metaphyseal structures and for simultaneous bone lengthening in the management of reconstructions of types 2, 3 and 4.

2.19.4 Type 1: Diaphyseal Reconstruction

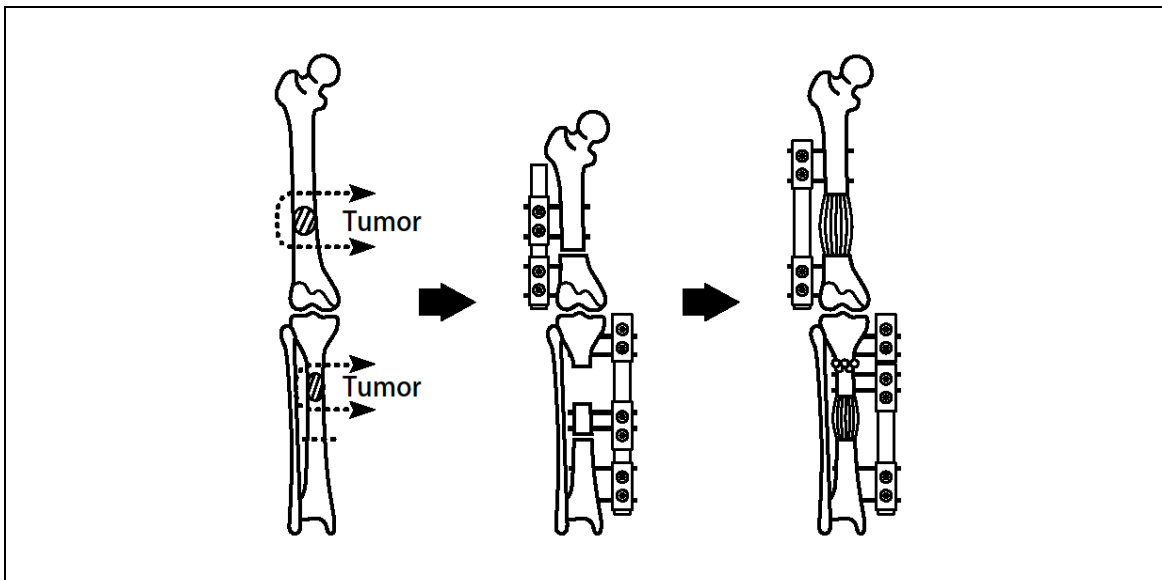


Fig. 2.19.2 Type 1 reconstruction

Type 1 is the simplest procedure used to reconstruct the diaphyseal defect utilizing bone transport or shortening-distraction. The combination of an intramedullary nail and distraction osteogenesis may reduce the period of treatment with a decrease in the incidence of wire or pintrack infections. The external fixation index can be reduced as the maturation index approaches zero. We therefore apply intramedullary nailing for distraction osteogenesis whenever feasible. A thin, stress-resistant intramedullary nail is appropriate for combined use to preserve the intramedullary blood supply and allow space for the insertion of wires or half pins.

If shortening-distraction is applied, bone graft at the docking site is not necessary. Femoral shortening of about 10 to 15 cm can be achieved if wound closure is feasible. Careful attention should be paid to the shortening of the tibia because of circulatory disturbance, but tibial defects can be satisfactorily treated by bone transport for extensive bone loss.

2.19.5 Type 2: Metaphyseal reconstruction

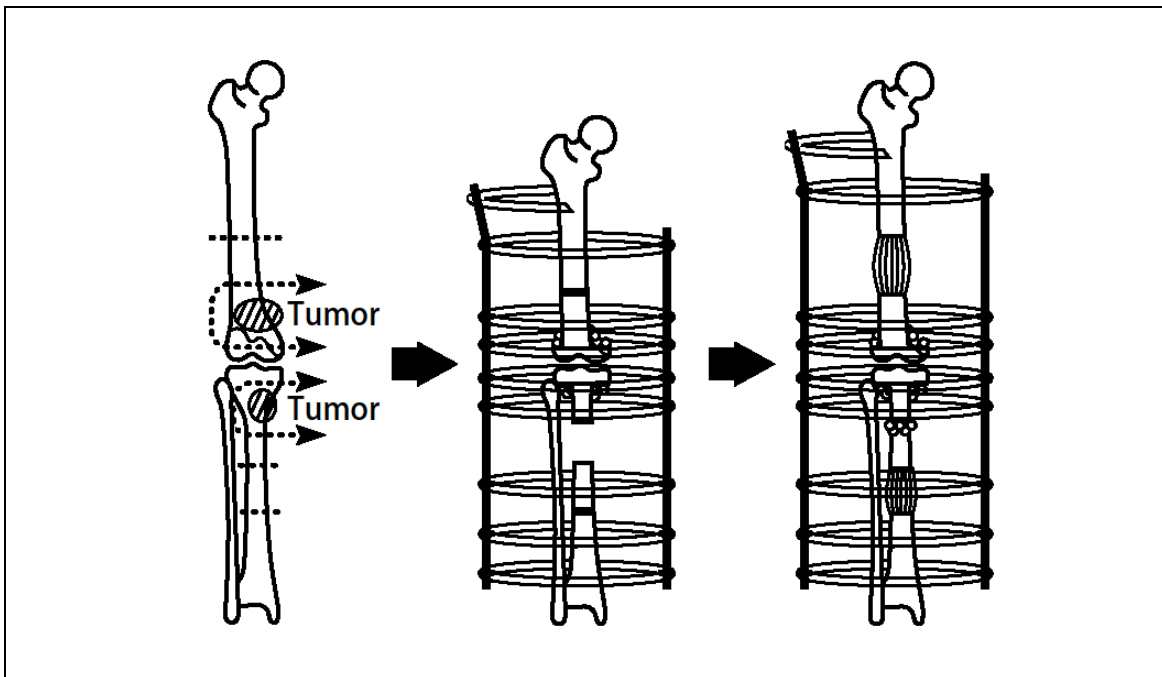


Fig. 2.19.3.1 Type 2 reconstruction

Type 2 is used to reconstruct the metaphyseal defect Iizarov wires or half pins for fixation can be used through the remaining epiphysis. In addition to bone transport or shortening-distraction, the metaphyseal defect can be reconstructed with a bone cylinder from the diaphysis, and the newly-created diaphyseal defect is filled by bone transport. It is necessary to reattach the patellar ligament to the bone cylinder grafted for reconstruction of the metaphyseal defect of the proximal tibia Careful attention should be paid when shortening the tibia because of circulatory disturbance. Intramedullary nailing can be applied for the femur pre- and post-distraction while it can be used for the tibia only after distraction for selected cases.

Before excising the tumor, the external fixater frame should be applied on the affected bone, otherwise the alignment shifts after tumor excision and it requires much more effort to restrain the correct alignment. Fig. 2.19.3.2 shows, as an example, the stages of external fixation in case of bone tumor of proximal metaphysical tibia. Two rings are applied as the first step, and then the tumor is excised with adequate margin. Usually, proximal bone segment remains very thin and metaphysical reconstruction is performed in advance. If the epiphysis preserved more than 1 cm thick, it can be fixed with 3 wires. Cylinder bone is obtained from remaining diaphysial bone and grafted on proximal epiphysis with fixation of II,1,90 half pin. Autologeous bone grafting can be plated besides the cylinder bone to create metaphysis. The detached patellar tendon is reattached on the cylinder bone with spike washer. The middle ring is attached for bone transport and osteotomy is performed.

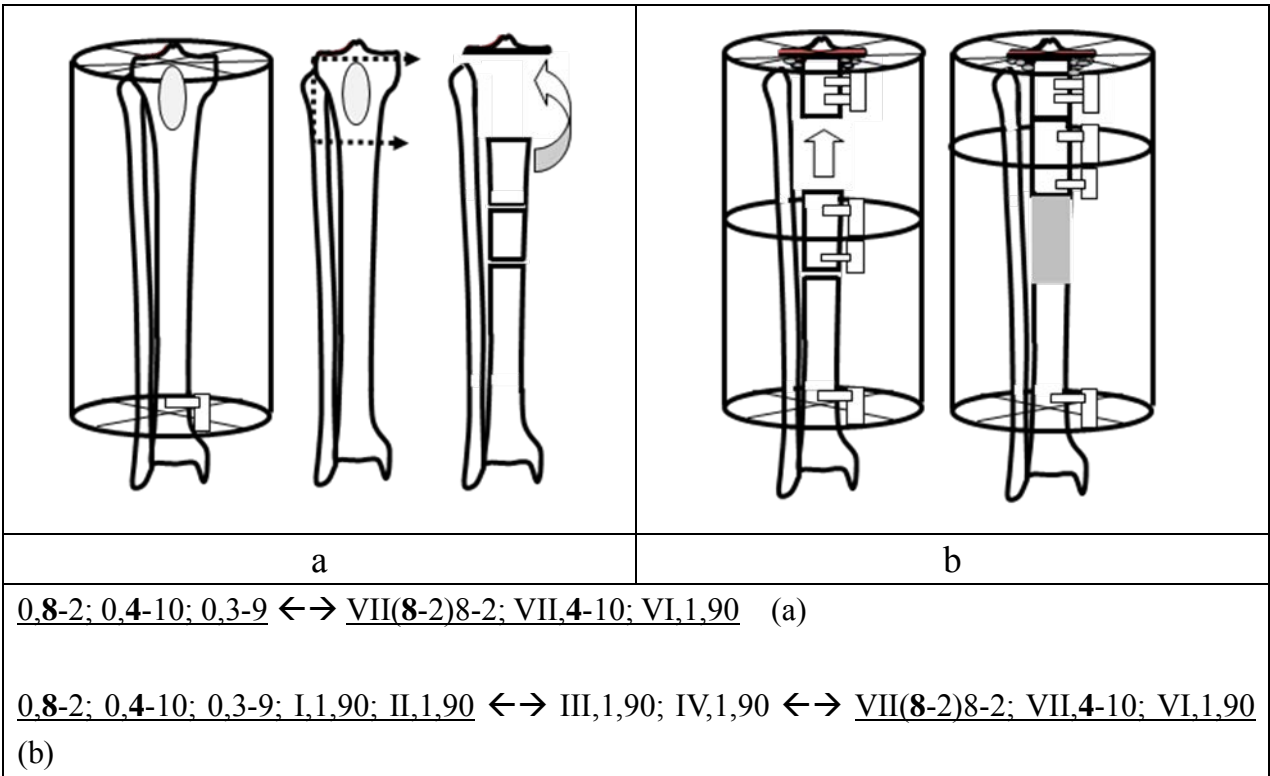


Fig. 2.19.3.2 An example of Type 2 reconstruction. Tumor of proximal tibia is excised and bone transport is performed

2.19.6 Type 3: Epiphyseal reconstruction

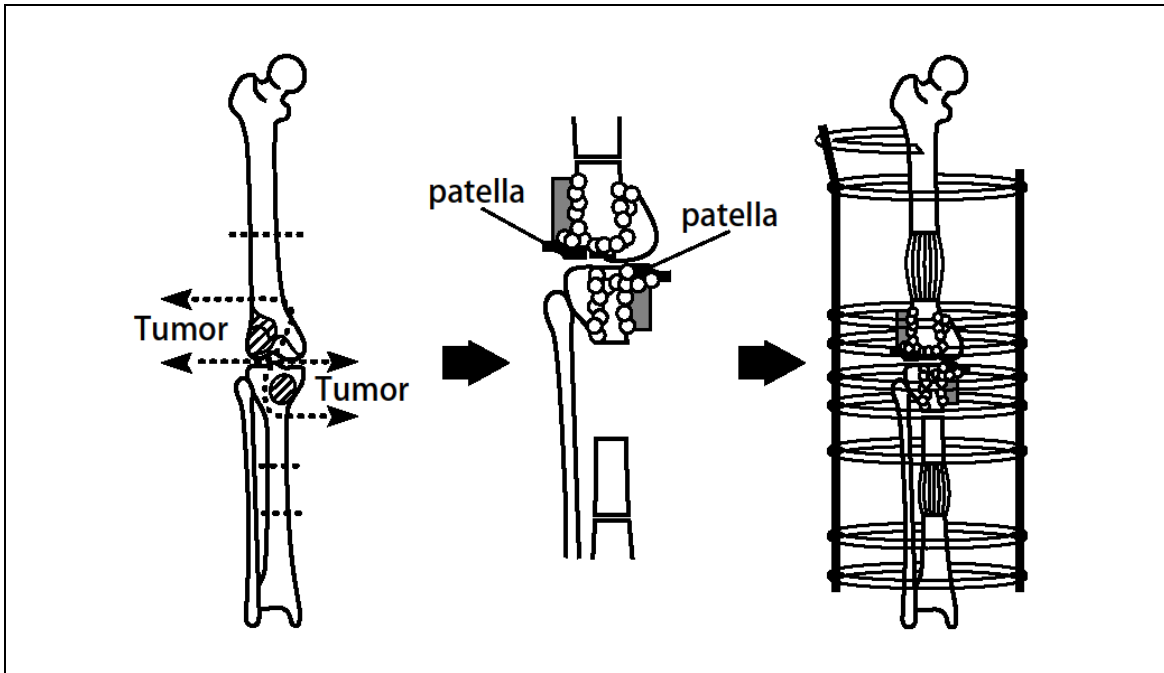


Fig. 2.19.4 Type 3 reconstruction

Type 3 is used to reconstruct defects of the metaphysis and unilateral epiphysis. Metaphyseal defects are reconstructed by shortening of the diaphysis or with a bone cylinder from the diaphysis, While the articular surface of the ipsilateral patella and a strut iliac crest graft are used to reconstruct unilateral epiphyseal defects. The newly-created diaphyseal defect is then filled in by bone transport. When the defect is shortened, a standard lengthening procedure at the diaphysis is performed. The patellar ligament or collateral ligaments can be reattached to the bone cylinder or to the shortened diaphysis. Intramedullary nailing can be applied after the completion of the distraction and the union of the periarticular structure.

2.19.7 Type 4: Subarticular reconstruction

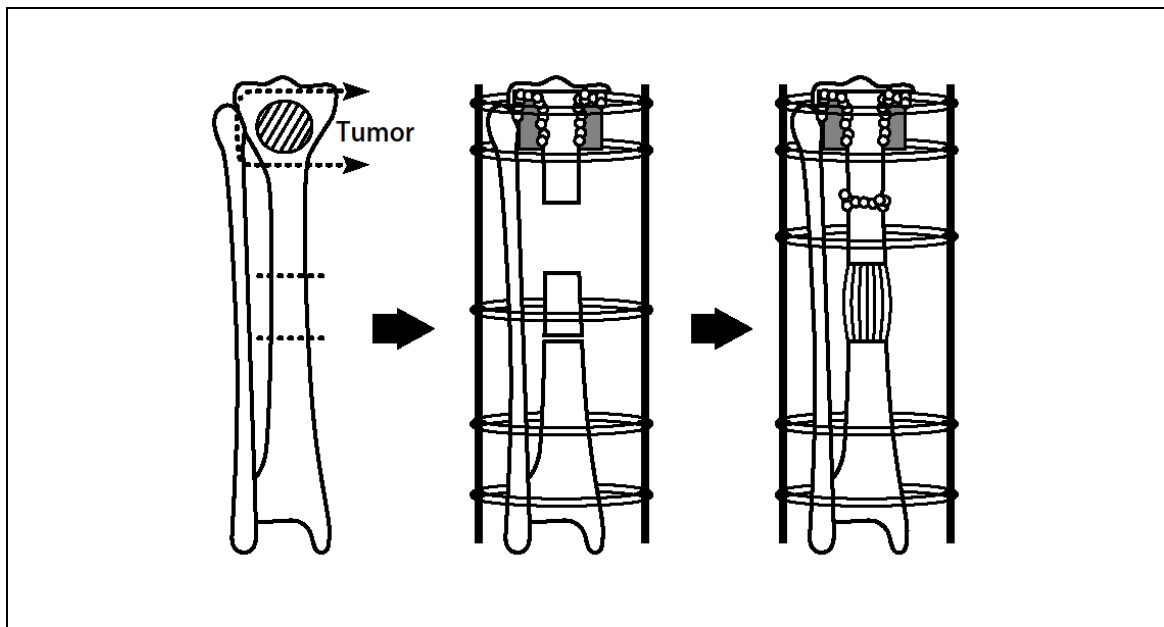


Fig. 2.19.5.1 Type 4 reconstruction

Type 4 is used for the reconstruction of subarticular defects (Fig. 2.19.5.1). Articular cartilage with or without subchondral bone is left after tumor excision. On the contrary to Type 2 reconstruction, Ilizarov wires cannot be applied through the epiphysis (Fig. 2.19.5.2). The primary periarticular reconstruction should be performed to stabilize the knee joint and to avoid the collapse of the articular surface. The bone cylinder from the diaphysis and the remaining lateral or medial wall should be fixed by the wires. The newly created diaphyseal defect is filled in by means of bone transport. This type of reconstruction would be applied for the proximal and distal end of the tibia. The patellar ligament or collateral ligaments can be reattached to the periarticular structure. Intramedullary nailing is not indicated for this reconstruction, therefore Type 4 reconstruction will take longer time for healing compared to the other types of

reconstruction.

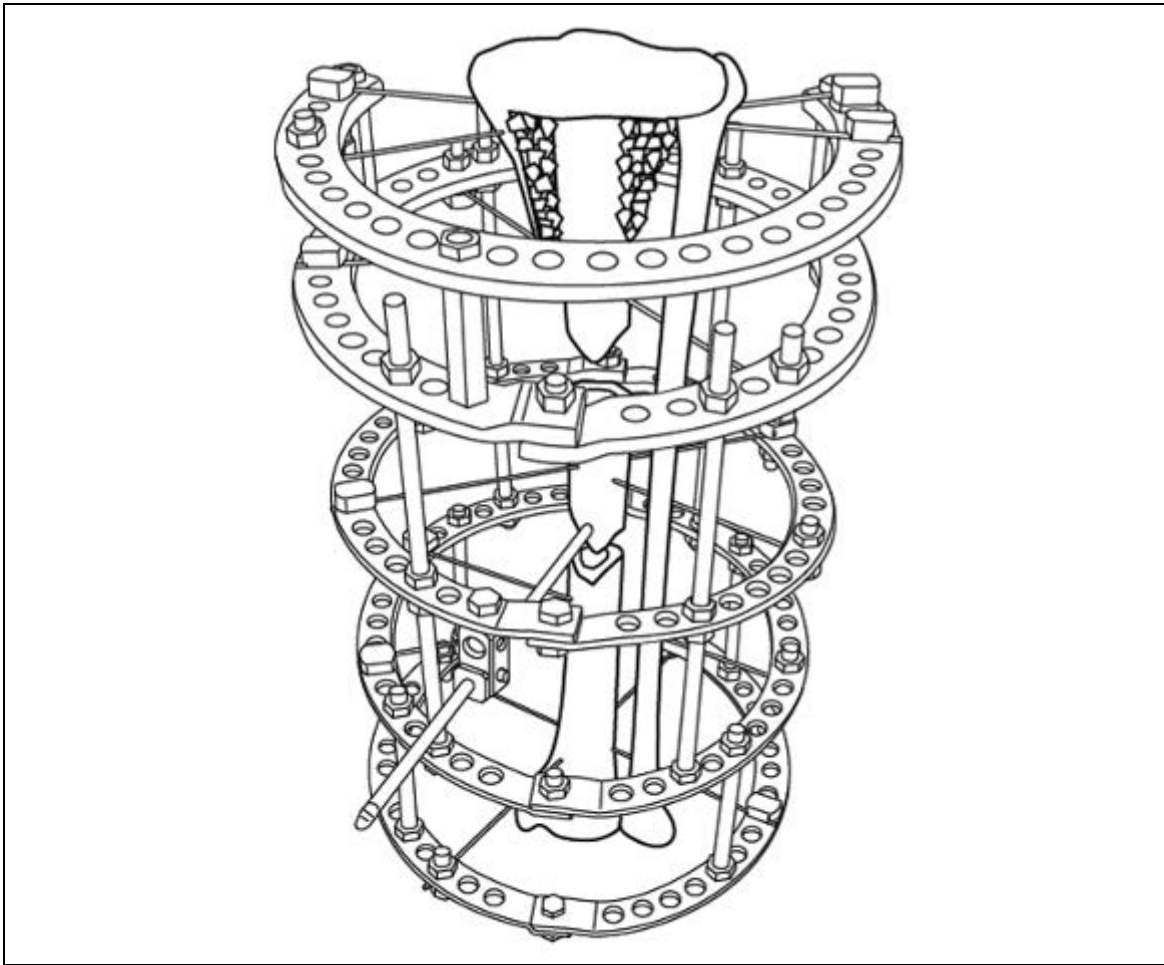


Fig. 2.19.5.2 An example of type 4 reconstruction. On the contrary to Type 2 reconstruction, Ilizarov wires cannot be applied through the epiphysis.

2.19.8 Type 5: Arthrodesis

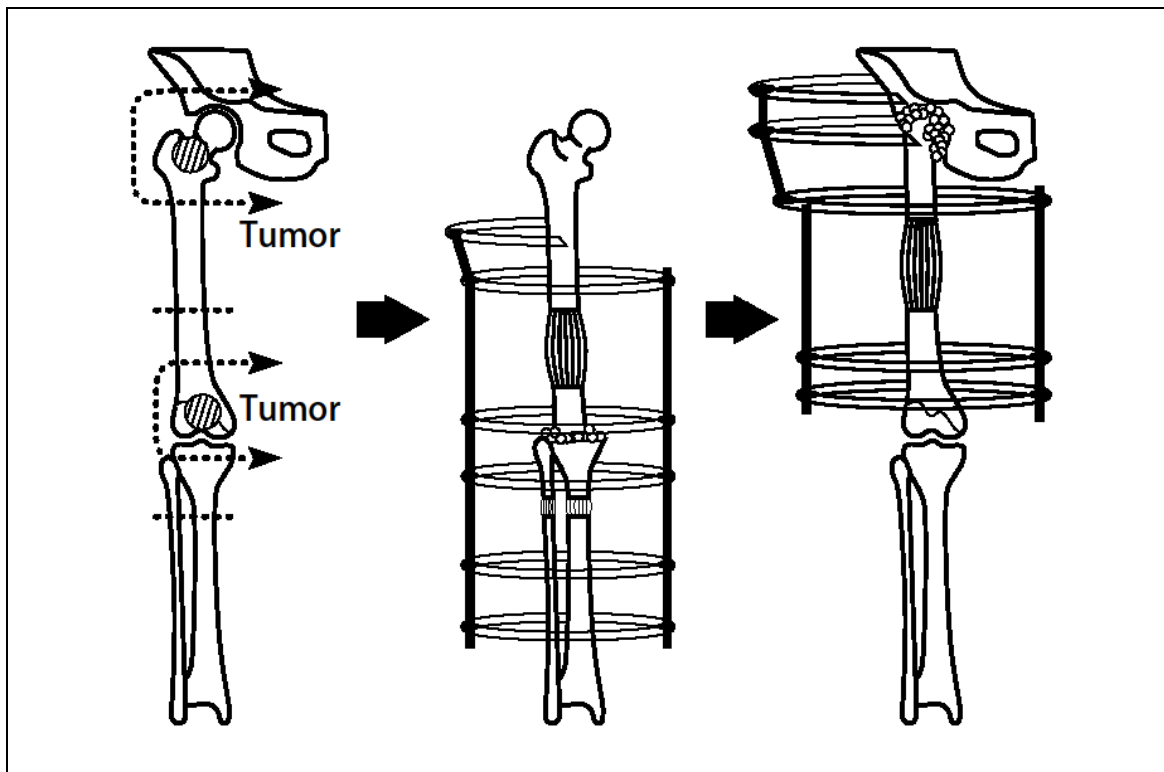


Fig. 2.19.6 Type 5 reconstruction

Type 5 is used to reconstruct defects after joint resection by arthrodesis and to correct subsequent leg length discrepancy. In hip arthrodesis, shortening of the defect and lengthening of the femur and/or tibia combined with intramedullary nailing is better used to reduce the treatment period. For long defects after tumor resection, bone transport is conducted because the wound cannot be primarily closed. Shortening of the defect would lead to the reduction of the treatment period if feasible.

2.19.9 Postoperative care

Distraction is initiated at 0.5 mm twice daily or 0.25 mm four times daily approximately 7 to 14 days after the operation, and is then either reduced to zero or increased to 1.5 mm per day according to the degree of bone formation. The external fixator is removed as soon as sufficient consolidation is obtained. After removal of the external fixator, casting or an orthosis is applied for approximately 4 weeks. In cases with very poor callus formation, distraction is delayed, or compression and distraction of a moving segment (accordion maneuver) is applied.

Antibiotics (penicillins or second generation cephalosporins had been administered as a single intravenous dose before operation and then orally for

three to five days after. After careful attention to the maintenance of aseptic conditions during insertion, care of the wires and half pins was started immediately after operation using 0.05% chlorhexidine gluconate or just rinsing. All the patients (or parents) were taught how to perform pin-site care twice weekly at home after discharge from hospital.

All the patients who received post-operative chemotherapy after resection of the tumor and application of the external fixator received prophylactic intravenous antibiotics (second generation cephalosporins) for three to five days during chemotherapy.

Clinical examples of Ilizarov method application at tumours of long bones are submitted on Figs. 2.19.7 and 2.19.8.

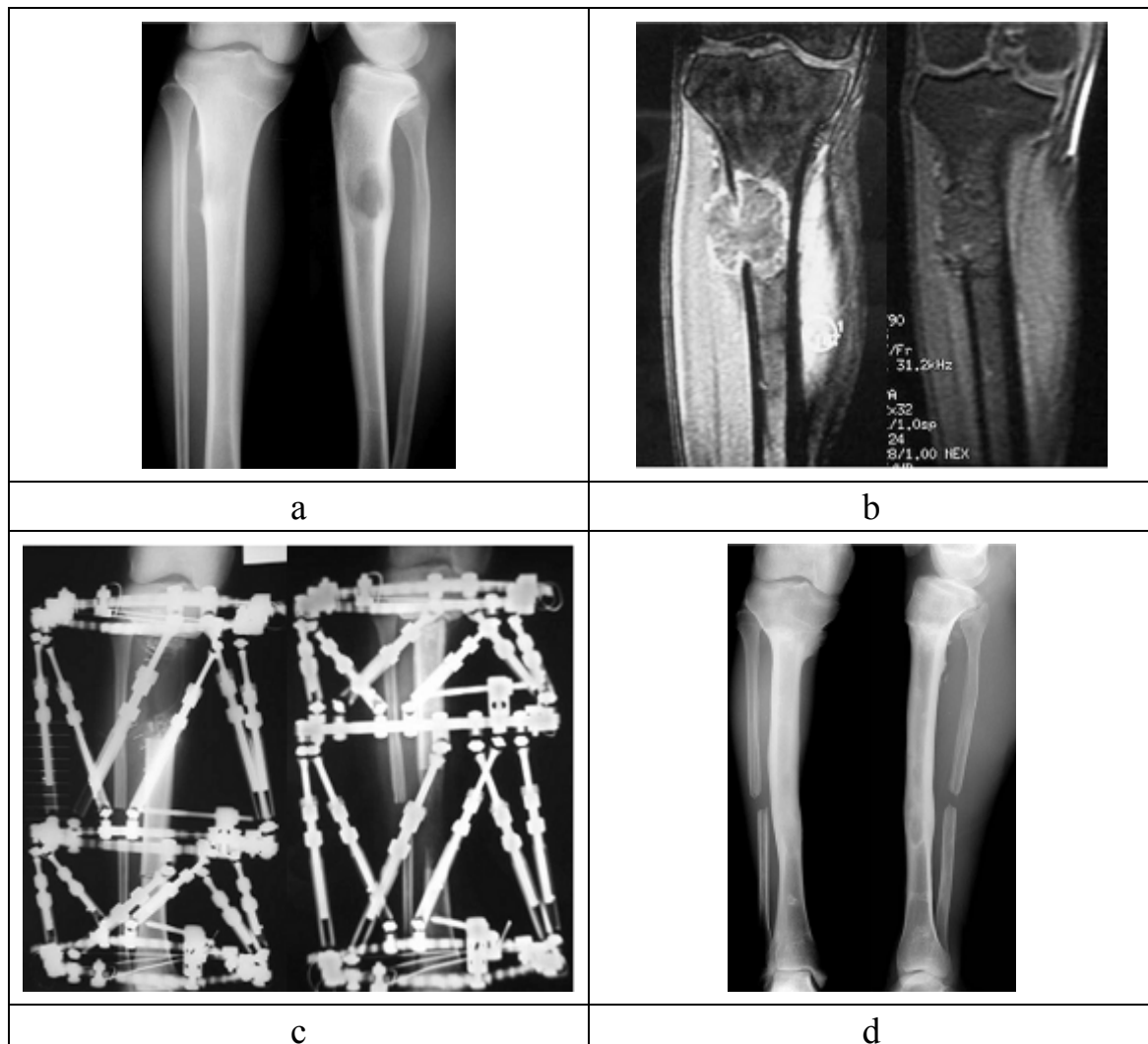


Fig. 2.19.7a-d. Osteosarcoma of proximal tibia (Type 1 reconstruction)

a – Initial X-ray examination

b - MRI findings before chemotherapy (left) and after chemotherapy (right). The tumor has been shrunk and stain is disappeared.

c - The tumor is excised and bone transport is performed from the distal part.

d - Latest X-ray photograph (4 years after surgery). The patient can run and play soccer.

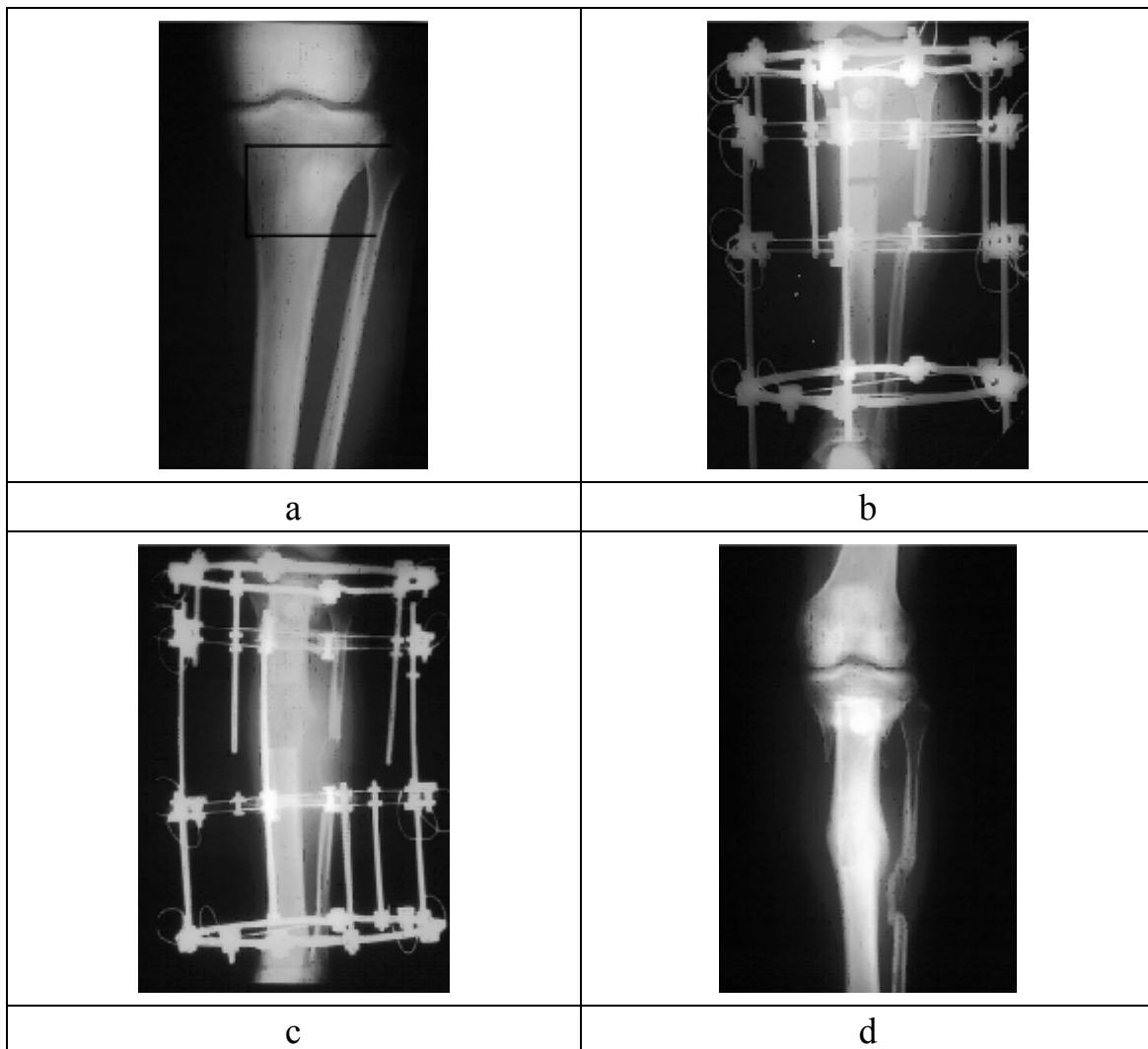


Fig. 2.19.8a-d. Osteosarcoma of proximal tibia (Type 2 reconstruction, shortening distraction method)

a - Initial X-ray examination

b - Tumor is excised and proximal part is reconstructed by shortening method. Patellar tendon is reattached with spike washer.

c - Distraction osteogenesis is finished

d - final follow-up

1. Treatment of benign bone tumours using external fixation.

Tsuchiya H, Morsy AF, Matsubara H, Watanabe K, Abdel-Wanis ME, Tomita K. J Bone Joint Surg Br. 2007 Aug;89(8):1077-83.

2. Successful management of complications from distraction osteogenesis after osteosarcoma resection: a case report.

Shirai T, Tsuchiya H, Yamamoto N, Sakurakichi K, Karita M, Tomita K.
J Orthop Sci. 2004;9(6):638-42.

3. Distraction osteogenesis for treatment of bone loss in the lower extremity.
Tsuchiya H, Tomita K.
J Orthop Sci. 2003;8(1):116-24.

4. The Ilizarov method in the management of giant-cell tumours of the proximal tibia.
Tsuchiya H, Tomita K, Shinokawa Y, Minematsu K, Katsuo S, Taki J.
J Bone Joint Surg Br. 1996 Mar;78(2):264-9.

5. Safety of external fixation during postoperative chemotherapy.
Tsuchiya H, Shirai T, Morsy AF, Sakayama K, Wada T, Kusuzaki K, Sugita T, Tomita K.
J Bone Joint Surg Br. 2008 Jul;90(7):924-8.

6. Functional outcome in patients with osteosarcoma around the knee joint treated by minimised surgery.
Hayashi K, Tsuchiya H, Yamamoto N, Takeuchi A, Tomita K.
Int Orthop. 2008 Feb;32(1):63-8. Epub 2007 Feb 15.

7. Biological reconstruction after excision of juxta-articular osteosarcoma around the knee: a new classification system.
Tsuchiya H, Abdel-Wanis ME, Tomita K.
Anticancer Res. 2006 Jan-Feb;26(1B):447-53.

8. Distraction osteogenesis of a previously irradiated femur with malignant lymphoma: a case report.
Matsubara H, Tsuchiya H, Sakurakichi K, Yamashiro T, Watanabe K, Tomita K.
J Orthop Sci. 2005 Sep;10(5):555. No abstract available.

9. Osteosarcoma around the knee. Intraepiphyseal excision and biological reconstruction with distraction osteogenesis.
Tsuchiya H, Abdel-Wanis ME, Sakurakichi K, Yamashiro T, Tomita K.
J Bone Joint Surg Br. 2002 Nov;84(8):1162-6.

10. The natural limb is best: joint preservation and reconstruction by distraction osteogenesis for high-grade juxta-articular osteosarcomas.
Tsuchiya H, Abdel-Wanis ME, Kitano S, Sakurakichi K, Yamashiro T, Tomita K.

Anticancer Res. 2002 Jul-Aug;22(4):2373-6.

11. Marginal excision for osteosarcoma with caffeine assisted chemotherapy.

Tsuchiya H, Tomita K, Mori Y, Asada N, Yamamoto N.

Clin Orthop Relat Res. 1999 Jan;(358):27-35.

12. Limb salvage using distraction osteogenesis. A classification of the technique.

Tsuchiya H, Tomita K, Minematsu K, Mori Y, Asada N, Kitano S.

J Bone Joint Surg Br. 1997 May;79(3):403-11. Erratum in: J Bone Joint Surg Br 1997 Jul;79(4):693.