

# Acute urinary retention as an unusual manifestation of aseptic meningitis

著者	Zenda Takahiro, Soma Ryuichirou, Muramoto Hiroaki, Hayase Hideo, Orito Matsuo, Okada Toshihide, Mabuchi Hiroshi, Okino Soichi
journal or publication title	Internal Medicine
volume	41
number	5
page range	392-394
year	2002-01-01
URL	<a href="http://hdl.handle.net/2297/24305">http://hdl.handle.net/2297/24305</a>

## Acute Urinary Retention as an Unusual Manifestation of Aseptic Meningitis

Takahiro ZENDA, Ryuichirou SOMA, Hiroaki MURAMOTO, Hideo HAYASE\*, Matsuo ORITO\*\*, Toshihide OKADA\*\*\*, Hiroshi MABUCHI\*\*\* and Soichi OKINO\*\*\*\*

### Abstract

A formerly healthy 32-year-old woman was hospitalized for a closer examination of undiagnosed fever with mild headache. Despite lack of distinct findings on physical and laboratory examinations at admission, she suddenly developed anuresis due to acontractile neurogenic bladder. On the basis of her symptoms and the faint nuchal rigidity revealed later, as well as the results of cerebrospinal fluid analyses, a diagnosis of aseptic meningitis was eventually reached. While aseptic meningitis subsided within 3 weeks, about 10 weeks, including a 26-day period of anuria, was necessary for complete restoration of normal voiding function, necessitating intermittent self-catheterization. Acute urinary retention should be considered an uncommon but critical manifestation of aseptic meningitis.

(Internal Medicine 41: 392-394, 2002)

**Key words:** neurogenic bladder, sacral myeloradiculitis, Elsberg syndrome

### Introduction

Acute urinary retention with pleocytosis in the cerebrospinal fluid (CSF), known as the Elsberg syndrome (1, 2), is encountered infrequently and specifically in healthy young adults (1-8). In most of such cases, this disorder is ascribed to a sacral myeloradiculitis of viral origin (1-8). On the other hand, diagnosis of viral or aseptic meningitis is not always easy, since its typical symptoms or identifiable neurological signs are often mild or even absent (3, 9). We present here a unique case whose acute urinary retention provided a critical clue to the presence of aseptic meningitis as a cause of undiagnosed fever.

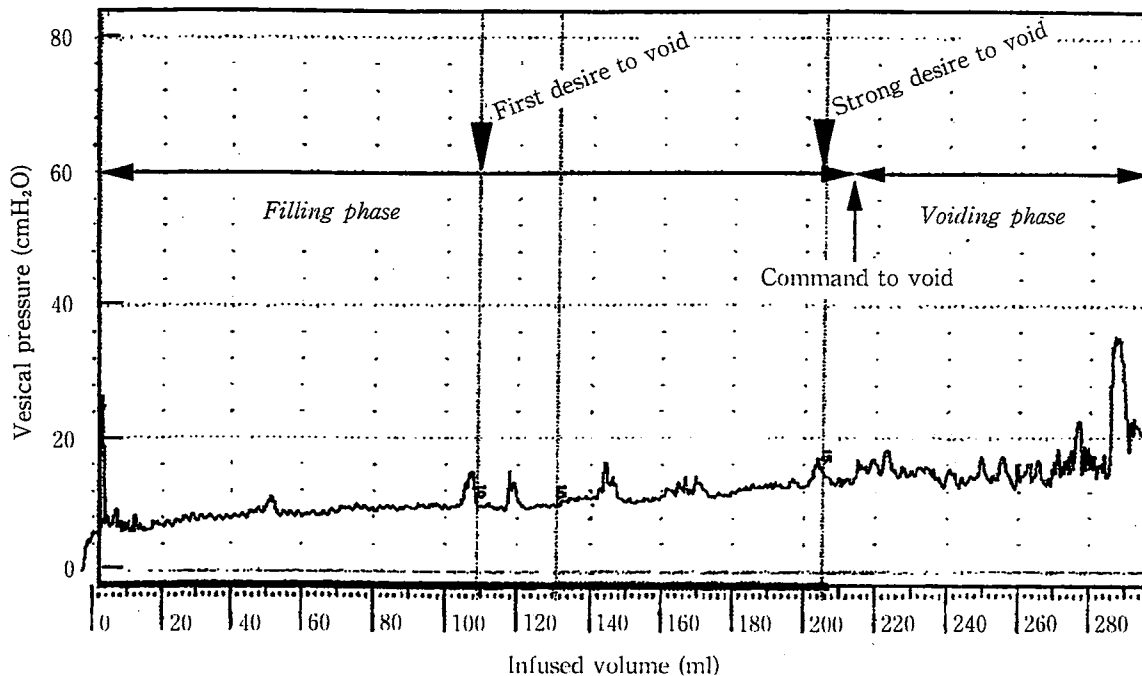
### Case Report

A 32-year-old Japanese woman was hospitalized with a 7-day history of spiking fever over 38°C accompanied by mild headache. She had been followed up for fever of unknown cause and had been treated with a nonsteroidal antiinflammatory drug for relief of symptoms. She had a record of satisfactory health except for surgery for ectopic pregnancy. On admission, she was febrile at 38.8°C, but physical examination revealed no distinct findings, nor any definite signs of meningeal irritation or mucocutaneous lesions. Laboratory hematologic studies produced no specific findings, including no inflammatory reaction: white blood cell (WBC) count was 7,000 /mm<sup>3</sup> with a normal differential cell count, C-reactive protein 0.1 mg/dl, and the erythrocyte sedimentation rate 15 mm/h. She had begun to experience some difficulty with micturition a few days before admission, and complete urinary retention suddenly developed during the night of admission. The urinary bladder was distended and palpable four fingerbreadths above the symphysis pubis. Catheterization of the urinary bladder yielded some 600 ml of clear urine. Cystometrography (Fig. 1) revealed an acontractile neurogenic bladder, but the bladder sensation was spared with a first urge to void at about 110 ml. When anuresis occurred, no other neurologic abnormalities specifically related to impairment of lumbosacral segments of the spinal cord or roots were found, i.e., no palsy or muscle weakness of the lower limbs, normal sensory findings, normal deep tendon reflexes without pathological reflexes, lack of fecal incontinence or constipation, normal gait, and negative Lasègue sign. Results of magnetic resonance imaging of the brain and spinal cord were normal. Lumbar puncture, which was performed in order to investigate the relationship between the patient's undiagnosed fever and neurogenic bladder, demonstrated a clear CSF with a normal opening pressure of 15 cmH<sub>2</sub>O. CSF protein concentration was 116 mg/dl, and glucose concentration 39 mg/dl (simultaneous serum glucose concentration was 86 mg/dl). Lymphocytic pleocytosis was found in the CSF at 370 cells/mm<sup>3</sup> with 97% mononuclear WBC. Routine bacterial culture

From the Departments of Internal Medicine, \*Neurosurgery, \*\*Urology, Kanazawa Social Insurance Hospital, Kanazawa, \*\*\*the Second Department of Internal Medicine and \*\*\*\*Neurology, Kanazawa University School of Medicine, Kanazawa

Received for publication April 9, 2001; Accepted for publication January 16, 2002

Reprint requests should be addressed to Dr. Takahiro Zenda, the Department of Internal Medicine, Kanazawa Social Insurance Hospital, HA-15, Oki-machi, Kanazawa 920-8610



**Figure 1.** Cystometrogram revealed an acontractile type of neurogenic bladder. Despite a strong desire and attempt to void, the increase of intravesical pressure due to constriction of the detrusor muscle was only slightly evoked.

yielded no growth. Serological examination of the blood and CSF revealed no significant elevation of viral antibody titer between the acute and convalescent phases. On the basis of clinical symptoms such as fever with mild headache, results of CSF analyses, and faint nuchal rigidity demonstrated first by maximal neck anteflexion during lumbar puncture and urethral self-catheterization for urinary retention, the patient was assumed to have aseptic meningitis, which would account for her persistent undiagnosed fever. Since complete urinary retention lasted for 26 days despite administration of an  $\alpha_1$ -sympatholytic drug (urapidil, 30 mg/day) and cholinesterase inhibitor (distigmine bromide, 15 mg/day), she was instructed in the technique of clean intermittent self-catheterization. Symptoms except dysuria subsided within 3 weeks with supportive therapy alone. When she left our hospital on the 35th day, voiding function had partially recovered with about 100 ml of urine remaining after each voluntary voiding, and finally recovered completely after another five weeks.

## Discussion

The case presented here is unique in that acute urinary retention provided an important clue to the presence of aseptic meningitis as a cause of fever of unknown origin. Diagnosis of aseptic meningitis is sometimes difficult, since patients with it often lack conclusive meningeal irritation or notable findings on laboratory examination other than CSF analysis (3, 9). In our case, nuchal rigidity was not obvious until maximal neck anteflexion (9) associated with lumbar puncture and urethral

self-catheterization for urinary retention. Further, unlike similar documented cases (1, 4, 5, 7, 10), absence of other concomitant symptoms such as disturbance of consciousness, convulsions, paresthesia, lower extremity weakness, fecal incontinence, constipation or intestinal obstruction due to abnormality of bowel motility, or anogenital herpetic vesicles, made involvement of the central nervous system or viral illness unlikely as a cause of fever. On the other hand, the present patient had the following characteristic features in common with patients previously reviewed as viral or aseptic meningitis accompanied by acute urinary retention (3, 7, 8): occurrence in a healthy young individual, a 7-day interval between symptoms of onset of meningitis and acute anuresis [average 9 days (7)], atonic-type neurogenic bladder, a 26-day period of anuria [average 10 (4) to 32 (8) days], and the eventual complete resolution of urinary retention. It is therefore advisable to duly inform patients of the favorable outcome of neurogenic bladder, since they, especially when young, worry about prolonged urinary retention and tend to suffer from stress resulting from intermittent self-catheterization (8), as in our case.

As the cause of neurogenic bladder associated with aseptic meningitis, either sacral myeloradiculitis due to a direct viral inflammation (1, 5, 10–12) or a process of post-infectious inflammatory demyelination in the peripheral and/or central nervous system (3, 11, 12) has been postulated. The combination of acute urinary retention and CSF pleocytosis is known as Elsberg syndrome (1, 2). This infrequent disorder occurs especially in healthy young adults, and is believed, in the majority of cases, to result from sacral myeloradiculitis of viral origin

(1, 2). In cases of isolated myeloradiculitis, the concurrent neurological symptoms and signs are often mild, transient, or even absent (1, 13), and, so far as we could determine, CSF pleocytosis is not greater than 100 cells/mm<sup>3</sup> in most of the reported cases (1, 2, 12, 13). While our case is compatible with this syndrome, the patient's high fever accompanied by mild headache, a sign of meningeal irritation, and relatively high degree of lymphocytic CSF pleocytosis (370 cells/mm<sup>3</sup>) also suggest the presence of aseptic meningitis as a preceding infection. These differences in symptoms, physical and CSF findings may provide clues to distinguish acute urinary retention due to meningo-myeloradiculitis from isolated myeloradiculitis. The finding of acontractile type of neurogenic bladder with intact sensation implies some impairment of the lower motor neurons in the ventral roots, i.e., a lesion of the efferent parasympathetic neurons from the sacral voiding center to the bladder, but the sound sensory neurons in the dorsal roots (11–13). While no viruses causative of meningitis were detected in either the blood or CSF in our case, the herpes simplex virus is the most common virus responsible for concurrent acute urinary retention and meningitis (7, 8), probably because of its neurotropic nature or its reactivation from ganglionic latency (3–6, 10, 11). A few studies have suggested post-infectious-immune-mediated demyelination as a cause of neurogenic bladder (11), but anti-GM<sub>1</sub> ganglioside antibody, which plays a principal role in demyelination in autoimmune motor neuropathy (14), was not detected in our case.

Since the following conditions such as psychogenic urinary retention, the first manifestation of multiple sclerosis, drug intoxication, lumbosacral disc protrusion, and rheumatological disorders must all be considered in the differential diagnosis of acute urinary retention in a healthy young individual (1–3, 5, 10, 12), it is essential to promptly examine the CSF (1, 3, 12) and to test for viruses, especially by means of nucleic acid amplification (9, 11), to examine the central nervous system by magnetic resonance imaging, and to test for autoimmune abnormalities in addition to a careful review of the patient's history and physical examination. Although acute urinary re-

tention in patients with aseptic meningitis may be self-limited (5, 7, 8) and there is no evidence that any treatment affects its clinical course (6, 11), physicians should be aware of acute urinary retention as a rare but critical manifestation of viral or aseptic meningitis.

## References

- 1) Herbaut AG, Voordecker P, Monseu G, Germeau F. Benign transient urinary retention. *J Neurol Neurosurg Psychiatry* 50: 354–355, 1987.
- 2) Vanneste JA, Karthaus PP, Davies G. Acute urinary retention due to sacral myeloradiculitis. *J Neurol Neurosurg Psychiatry* 43: 954–956, 1980.
- 3) Steinberg J, Rukstalis DB, Vickers MA Jr. Acute urinary retention secondary to herpes simplex meningitis. *J Urol* 145: 359–360, 1991.
- 4) Oates JK, Greenhouse PR. Retention of urine in anogenital herpetic infection. *Lancet* 1: 691–692, 1978.
- 5) Caplan LR, Kleeman FJ, Berg S. Urinary retention probably secondary to herpes genitalis. *N Engl J Med* 297: 920–921, 1977.
- 6) Riehle RA Jr, Williams JJ. Transient neuropathic bladder following herpes simplex genitalis. *J Urol* 122: 263–264, 1979.
- 7) Shimizu Y, Yamamoto S, Inoue K, et al. Two cases of urinary retention secondary to aseptic meningitis. *Hinyokika Kyo (Acta Urol Jpn)* 45: 435–437, 1999 (In Japanese, Abstract in English).
- 8) Urakawa M, Ueda Y. A case of urinary retention secondary to aseptic meningitis. *No To Shinkei (Brain and Nerve)* 53: 742–746, 2001 (In Japanese, Abstract in English).
- 9) Tyler KL. Aseptic Meningitis, Viral Encephalitis, and Prion Diseases. in: *Harrison's Principles of Internal Medicine*. 14th ed. Fauci AS, Braunwald E, Isselbacher KJ, et al, Eds. McGraw-Hill, New York, 1998: 2439–2451.
- 10) White WB, Hanna M, Stewart JA. Systemic herpes simplex virus type 2 infection. Proctitis, urinary retention, arthralgias, and meningitis in the absence of primary mucocutaneous lesions. *Arch Intern Med* 144: 826–827, 1984.
- 11) Sasadeusz JJ, Sacks SL. Herpes latency, meningitis, radiculomyelopathy and disseminated infection. *Genitourin Med* 70: 369–377, 1994.
- 12) Herbaut AG, Nogueira MC, Wespes E. Urinary retention due to sacral myeloradiculitis: a clinical and neurophysiological study. *J Urol* 144: 1206–1208, 1990.
- 13) Patel BR, Rivner MH. Herpes zoster causing acute urinary retention. *South Med J* 81: 929–930, 1988.
- 14) Sadiq SA, Thomas FP, Kilidireas K, et al. The spectrum of neurologic disease associated with anti-GM<sub>1</sub> antibodies. *Neurology* 40: 1067–1072, 1990.