

# Total port-access lobectomy via a subcostal trans-diaphragmatic approach for lung cancer

著者	Oda Makoto, Matsumoto Isao, Waseda Ryuichi, Watanabe Go
journal or publication title	Interactive CardioVascular and Thoracic Surgery
volume	16
number	2
page range	211-213
year	2013-02-01
URL	<a href="http://hdl.handle.net/2297/34698">http://hdl.handle.net/2297/34698</a>

doi: 10.1093/icvts/ivs446

# Total port-access lobectomy via a subcostal trans-diaphragmatic approach for lung cancer<sup>†</sup>

Makoto Oda\*, Isao Matsumoto, Ryuichi Waseda and Go Watanabe

Department of General and Cardiothoracic Surgery, Kanazawa University, Kanazawa, Japan

\* Corresponding author. Department of General and Cardiothoracic Surgery, Kanazawa University, 13-1 Takara-machi, Kanazawa, Ishikawa 920-8641, Japan.  
Tel: +81-76-2652355; fax: +81-76-2226833; e-mail: odamak@med.kanazawa-u.ac.jp (M. Oda).

Received 28 June 2012; received in revised form 9 September 2012; accepted 24 September 2012

## Abstract

Video-assisted thoracic surgery has been recognized as an acceptable technique for the treatment of early-stage lung cancer, with the potential advantage of lower postoperative pain than that experienced after open thoracotomy. However, the procedure cannot completely alleviate postoperative pain and paraesthesia and causes some degree of intercostal nerve damage. To minimize postoperative pain in video-assisted thoracic surgery, several new approaches have recently been reported. We describe the case of a 51-year old woman who successfully underwent total port-access, video-assisted thoracoscopic lobectomy for Stage IA lung cancer via the subcostal trans-diaphragmatic approach. Our results demonstrate the feasibility and safety of this procedure, which offers the advantages of minimizing intercostal nerve damage and facilitating better handling of staplers.

**Keywords:** Lung cancer surgery • Lobectomy • Video-assisted thoracic surgery • Minimally invasive surgery

## INTRODUCTION

Video-assisted thoracic surgery (VATS) lobectomy has been performed frequently in patients with early-stage lung cancer. Although the postoperative pain associated with VATS is lower than that experienced after open thoracotomy, some degree of intercostal nerve damage is inevitable because the staplers, the thoracoscopic camera and other instruments are introduced through thoracoports placed in the intercostal spaces. To minimize this damage, we attempted total port-access, video-assisted thoracoscopic lobectomy via the subcostal trans-diaphragmatic approach by using three 5-mm intercostal ports and one 15-mm subcostal trans-diaphragmatic port for endostaplers and instruments >5 mm in diameter. Here, we provide a detailed description of this approach.

## CLINICAL SUMMARY

A 51-year old woman was referred to our hospital with an abnormal shadow on a screening chest radiograph. Computed tomography revealed a 1.0-cm mixed nodular ground-glass opacity in the middle lobe, and lung cancer was suspected. Since bronchoscopic diagnosis seemed difficult and the tumour was centrally located in the middle lobe, making partial resection difficult, we attempted middle lobectomy for a definite diagnosis.

<sup>†</sup>Presented at the 20th European Conference on General Thoracic Surgery, Essen, Germany, 10–13 June 2012.

## SURGICAL TECHNIQUE

The patient was placed in a lateral decubitus position under general anaesthesia with a double-lumen endotracheal tube. The first 5-mm thoracoport was placed in the fourth intercostal space on the anterior axillary line for observation of the intrathoracic space. The second and the third 5-mm thoracoports were placed in the fifth intercostal space on the posterior axillary line and in the seventh intercostal space on the middle axillary line, respectively (Fig. 1). Just anterior of the 10th rib, a 2-cm subcostal incision was made. The diaphragm was reached by blunt dissection, and a 15-mm port was placed trans-diaphragmatically into the chest cavity under visualization by a thoracoscopic camera through the intercostal 5-mm port (Fig. 1) Video 1. After all ports were placed, the thoracoscopic camera was placed via a port in the seventh intercostal space on the middle axillary line. Insufflation of CO<sub>2</sub> (pressure/flow, 8 mmHg and 10 l/min) introduced through a 15-mm port was maintained until the lung was well deflated.

After the pulmonary vein (V4 + 5) was encircled by a 5-mm roticulated forceps, it was ligated with an endoslide introduced through a 5-mm port and then divided (Fig. 2a and b). The middle lobe bronchus was encircled after hilar lymph node dissection and was divided with an endostapler introduced through the 15-mm port (Fig. 2c and d). After the pulmonary artery (A5) was ligated and divided in the same fashion as V4 + 5, the pulmonary artery (A4 + 5) was divided with the endostapler. Incomplete lobation between the middle and upper lobes was divided with the endostapler, and middle lobectomy was accomplished. The resected middle lobe was inserted into a removal bag and was withdrawn trans-diaphragmatically through

the subcostal incision Video 2. Frozen section diagnosis of the specimen revealed adenocarcinoma of the lung, and systematic mediastinal lymph node dissection was performed. Graspers of the lung and endostaplers were introduced through a subcostal port. A roticulated device was used to encircle the vein, artery and bronchus. One 5-mm flexible polyurethane multichannel drain was inserted through the subcostal incision. The diaphragm was not closed and subcutaneous muscle was closed with two or three stitches.

Total blood loss was <10 ml, and the operating time was 158 min. A total of 17 lymph nodes were dissected. The chest tube was removed on the first postoperative day. The postoperative

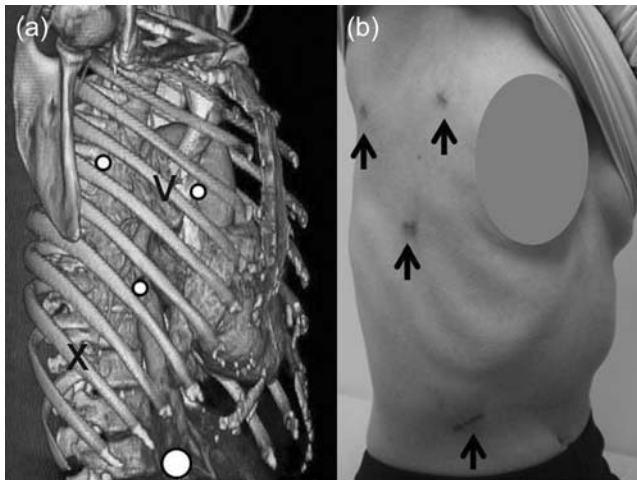
course was uneventful. Pathological examination revealed pT1aN0M0 Stage IA lung adenocarcinoma.

We performed this procedure on 16 patients with clinical Stage I lung cancer in both lobes over a recent 14-month period. For the first 2 patients, the operation times were 271 and 230 min, respectively. In the other 14 patients, however, the mean operation time was  $191 \pm 39$  min (mean  $\pm$  standard deviation). Postoperative complications were transient atrial fibrillation in 1 patient and transient recurrent nerve palsy in 1. No diaphragmatic hernia occurred for >60 patients with our approach including wedge resection of the lung.

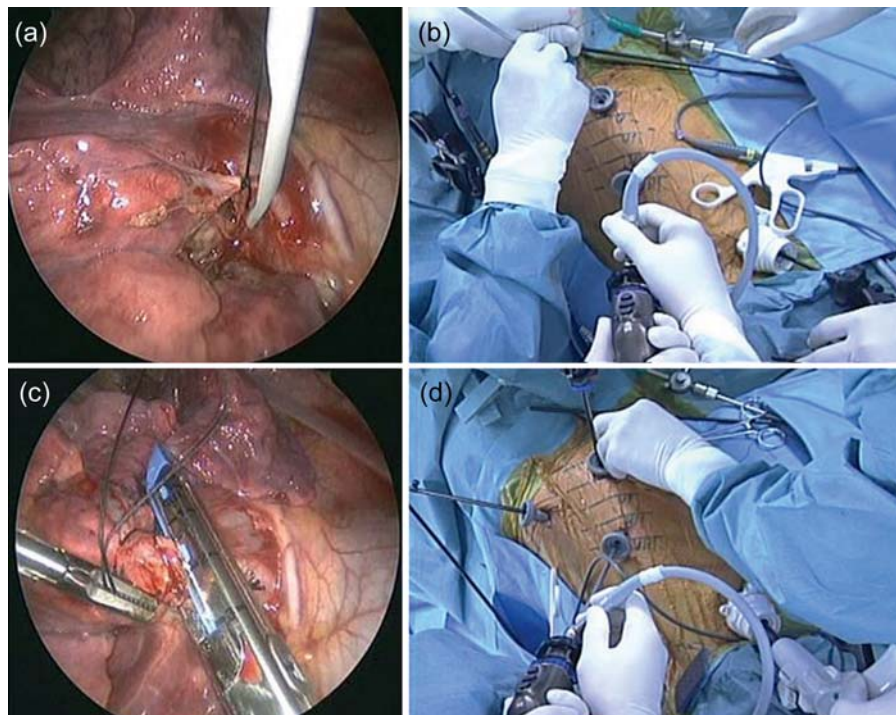
## DISCUSSION

VATS has been recognized as an acceptable technique for the treatment of early-stage lung cancer, and postoperative pain after VATS is less than that after thoracotomy. However, some degree of intercostal nerve damage is inevitable in VATS, and postoperative pain and paraesthesia, although less severe, are still present. To minimize postoperative pain in VATS, several approaches have recently been reported, such as complete port-accessed lobectomy by the muscle-sparing method [1], the transcervical approach with one intercostal 5-mm thoracoscopic camera port [2] and the single-port, video-assisted thoracoscopic lobectomy [3]. However, these procedures are not widely used because of technical difficulties.

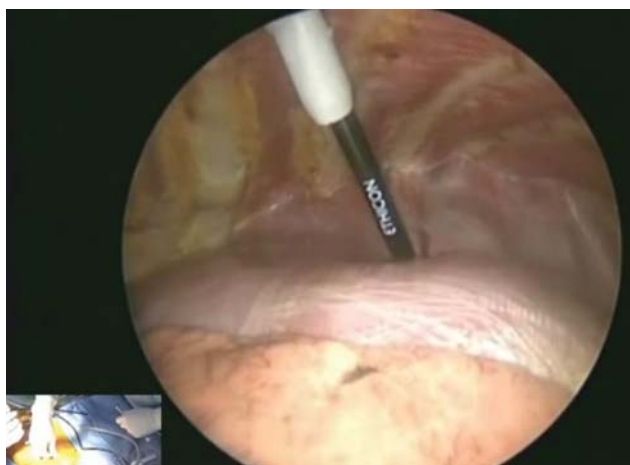
Ninan *et al.* [4] reported port-access, robot-assisted pulmonary lobectomy without utility thoracotomy, combined with the trans-diaphragmatic approach, wherein they made a subcostal trans-diaphragmatic incision for access to the pleural cavity. As described by Ninan *et al.*, the potential advantages of this procedure are its ability to allow resection of tumours of any size,



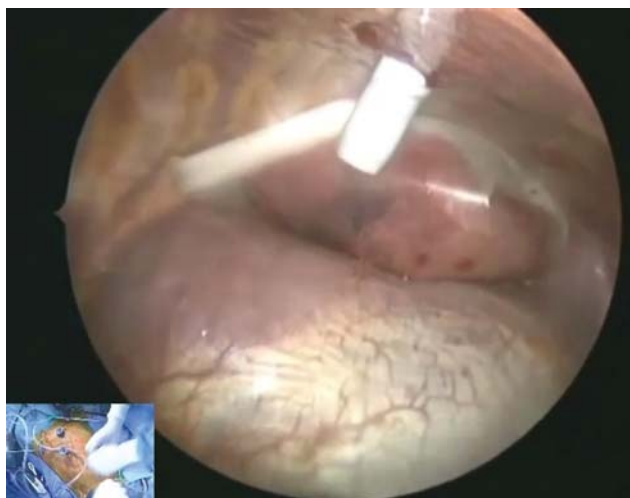**Figure 1:** (a) Approach to the right chest with three 5-mm intercostal ports (smaller circles) and one 15-mm subcostal port (larger circle). (b) View of the postoperative wound (arrows).



**Figure 2:** (a and b) Ligations of V4 + 5 with an endoslide introduced through a 5-mm intercostal port. (c and d) Division of the middle lobe bronchus with endostapler introduced through a 15-mm subcostal port.



**Video 1:** Preoperative computed tomography scan and placement of the thoraco-ports.



**Video 2:** Extraction of the resected middle lobe trans-diaphragmatically through the subcostal incision and the closure of the subcostal incision.

maintain CO<sub>2</sub> insufflation and dispense with the need to insert larger-sized instruments through intercostal port sites [4]. We adopted this procedure in VATS. We used only three 5-mm intercostal ports, through which we could insert ordinary VATS devices, thereby making our procedure less invasive than robotic ports. Long endostaplers and roticulated forceps for encircling the bronchus and pulmonary vessels were useful. Our approach facilitates the handling of stapling devices without the interference of other devices and the camera.

The benefit of CO<sub>2</sub> insufflation is that the lung can be collapsed to visualize the intrathoracic structures. The other potential benefit is the reduction in blood loss. The risk of CO<sub>2</sub> insufflation is haemodynamic collapse, but the clinical impact of positive-pressure pleural insufflation remains controversial [5]. CO<sub>2</sub> insufflation should be carefully used at low pressure, in close contact with an anaesthesiologist, and should be stopped once adequate collapse of the lung is obtained.

In our approach, there were no serious technical disadvantages such as limited field vision in single-port video-assisted thoracoscopic lobectomy [3], or prolonged operation time in the transcervical approach with one 5-mm intercostal thoracoscopic camera port [2]. In our experience, total port-access, video-assisted thoracoscopic lobectomy for Stage IA lung cancer via the subcostal trans-diaphragmatic approach is feasible and safe, easy for experienced VATS surgeons to learn, and has the potential advantage of minimizing postoperative pain.

## Funding

This work was supported by the 25th Hokkoku Cancer Foundation.

**Conflict of interest:** none declared.

## SUPPLEMENTARY MATERIAL

Supplementary material is available at *ICVTS* online.

## REFERENCES

- [1] Doki Y, Ichiki K, Tsuda M, Toge M, Misaki T, Usuda K *et al.* Complete port-accessed lobectomy by the muscle-sparing method. *Ann Thorac Surg* 2004;77:2230-1.
- [2] Zieliński M, Pankowski J, Hauer Ł, Kuzdzał J, Nabiałek T. The right upper lobe pulmonary resection performed through the transcervical approach. *Eur J Cardiothorac Surg* 2007;32:766-9.
- [3] Gonzalez D, Paradela M, Garcia J, Dela Torre M. Single-port video-assisted thoracoscopic lobectomy. *Interact CardioVasc Thorac Surg* 2011;12:514-5.
- [4] Ninan M, Dylewski MR. Total port-access robot-assisted pulmonary lobectomy without utility thoracotomy. *Eur J Cardiothorac Surg* 2010;38: 231-2.
- [5] Ohtsuka T, Nakajima J, Kotsuka Y, Takamoto S. Hemodynamic responses to intrapleural insufflation with hemipulmonary collapse. *Surg Endosc* 2001;15:1327-30.