

Over 10-year follow-up of functional outcome in patients with bone tumors reconstructed using distraction osteogenesis

著者	Watanabe Koji, Tsuchiya Hiroyuki, Yamamoto Norio, Shirai Toshiharu, Nishida Hideji, Hayashi Katsuhiko, Takeuchi Akihiko, Matsubara Hidenori, Nomura Issei
journal or publication title	Journal of Orthopaedic Science
volume	18
number	1
page range	101-109
year	2013-01-01
URL	http://hdl.handle.net/2297/32836

doi: 10.1007/s00776-012-0327-4

Over 10-year follow-up of functional outcome in patients with bone tumors reconstructed using distraction osteogenesis

Koji Watanabe · Hiroyuki Tsuchiya · Norio Yamamoto · Toshiharu Shirai · Hideji Nishida · Katsuhiko Hayashi · Akihiko Takeuchi · Hidenori Matsubara · Issei Nomura

Received: 28 September 2011 / Accepted: 4 October 2012
© The Japanese Orthopaedic Association 2012

Abstract

Background The aim of this study was to investigate the long-term functional capabilities of patients who underwent bone distraction for the treatment of bone defects caused by bone tumor excision.

Methods Bone distraction was indicated for patients with stage IIB malignant bone tumors when chemotherapy was judged to be effective and an epiphysis could be preserved or for patients with low-grade or aggressive benign bone tumors. Twenty-two patients who underwent reconstruction with bone distraction and were followed up for at least 10 years were retrospectively investigated. Patients included 8 males and 14 females, with a mean age of 25.3 years. Tumor types included seven osteosarcomas, two osteofibrous dysplasias, one Ewing's sarcoma, five low-grade osteosarcomas, two adamantinomas, and five giant cell tumors. Chemotherapy was performed during bone distraction in 8 cases. Bone transport was used in 17 cases, while shortening distraction was used in 5 cases.

Results The mean distraction length was 8.1 cm, and the mean external fixation period was 301 days. The average Musculoskeletal Tumor Society score (used to measure functional outcome) was 91.5 % at mean follow-up of 202 months. Fourteen patients were able to play sports without any difficulty.

Conclusions Epiphyseal preservation and reconstruction by bone distraction require both time and effort, but can

provide excellent long-term outcomes, resulting in a stable reconstruction that functionally restores the natural limb.

Introduction

Dramatic improvements in the survival rate of patients with musculoskeletal tumors and in the successful salvage of limbs have occurred as a result of progress in chemotherapy, radiological evaluation, and surgical technique, as well as in materials and implant technology, thereby making limb salvage an important alternative for the restoration of function [1–3]. Reconstruction of bone defects following en bloc resection of malignant or aggressive benign bone tumors is one of the major challenges in orthopedic surgery. Various methods, including biological (e.g., vascularized autograft, allograft, recycled bone treated by radiation, autoclaving, pasteurization, liquid nitrogen, and distraction osteogenesis) and non-biological (prosthesis) methods, have been established for the reconstruction of bone defects after malignant or benign bone tumor excision; however, no gold standard method for reconstruction exists yet [2]. Reconstruction with endoprosthetic replacements results in rapid postoperative recovery and is generally very effective in the short term; however, the longer patients who undergo reconstruction with these large implants survive, the more additional surgeries are required, not only for lengthening but also for management of complications such as stiffness, infection, wear, and loosening; together, these increase the risk of delayed amputation [4–6]. Ideally, grafted bones, including allografts and recycled bones, are replaced by living bone, although complete revascularization and incorporation into existing bone takes an extremely long time [7, 8]. The ultimate fate of the graft is uncertain, and reconstruction

K. Watanabe · H. Tsuchiya (✉) · N. Yamamoto · T. Shirai · H. Nishida · K. Hayashi · A. Takeuchi · H. Matsubara · I. Nomura
Department of Orthopaedic Surgery,
Graduate School of Medical Science, Kanazawa University,
13-1 Takara-machi, Kanazawa 920-8641, Japan
e-mail: tsuchi@med.kanazawa-u.ac.jp

with allografts or recycled bone is not considered to be a permanent reconstruction [9]. Generally, complications gradually increase with time spent on limbs reconstructed with tumor prosthesis or allograft, and limb function also worsens.

The ideal reconstruction should have biological affinity, resistance to infection, sufficient biomechanical strength, and durability [10]. We have been using distraction osteogenesis, a biological approach for repairing segmental bone defects, since 1990. Distraction osteogenesis can regenerate bone of sufficient strength and can preserve limb function [11–18]. Little has been reported about the long-term functional outcomes of patients who undergo distraction osteogenesis to reconstruct bone defects caused by excision of bone tumors. The aim of this study was to document the functional capabilities and patterns of recovery of patients who have undergone reconstruction with distraction osteogenesis for the treatment of bony defects caused by excision of bone tumors.

Patients and methods

Candidates for reconstruction with distraction osteogenesis included patients with malignant bone tumors who had good responses to chemotherapy, no metastasis, and ≥ 1 cm of epiphysis that could be preserved after adequate tumor excision, as well as patients with low-grade or aggressive benign bone tumors with epiphyseal preservation. Patients with bone defects >15 cm after tumor excision were excluded because of the risk of complications [15].

We retrospectively studied 22 patients who underwent reconstruction with distraction osteogenesis and who were followed up for at least 10 years. Patients included 8 males and 14 females, with a mean age of 25.3 years (range 4–71 years; median 19.1 years). Tumor types included seven conventional osteosarcomas, five central low-grade osteosarcomas, one Ewing's sarcoma, two adamantinomas, five giant cell tumors (aggressive), and two osteofibrous dysplasias (latent). Preoperative chemotherapy was not administered to patients with low-grade or aggressive benign tumors, but was given to those with high-grade tumors. The K2 chemotherapy protocol, which consists of five courses of intra-arterial cisplatin, caffeine, and doxorubicin at intervals of 3 weeks, was used [19]. Evidence of a good response to chemotherapy included sclerotic changes or good margination of the tumor observed on plain radiographs, marked shrinkage of any extension of the tumor into soft tissue demonstrated on MRI, disappearance of 'tumor' vessels on angiography, or disappearance of abnormal accumulation on thallium-201 scintigrams. Tumor responses were judged to be complete in all patients.

On histological examination, all patients with a complete response demonstrated complete tumor necrosis.

Tumors were located in the proximal tibia in 9 patients, the distal femur in 6 patients, the mid-tibia in 6 patients, and the mid-femur in 1 patient. Limb salvaging surgery was conducted by means of intentional marginal excision, which led to the preservation of important structures such as major neurovascular bundles, tendons, ligaments, muscles, and the epiphysis. Four different reconstruction methods were used, which involved two types of distraction osteogenesis: bone transport and shortening distraction [14, 23]. We performed type 1 reconstruction, which refills the diaphyseal defect by bone transport or shortening distraction, in all mid-femur and mid-tibia cases. In reconstruction of the metaphyseal defect, the metaphyseal defect may be reconstructed with a bone cylinder from the diaphysis adding to bone transport or shortening distraction. In all but one proximal tibia case, type 4 subchondral reconstruction with bone transport was performed. In the other the proximal tibia case, in which the epiphysis was partially excised, exceptional reconstruction was performed using the type 3 method. In all distal femur cases, type 2 metaphyseal reconstruction with bone transport or shortening distraction was performed (Fig. 1).

Gradual distraction started 7–14 days after surgery and was applied at a rate of 0.25–1 mm/day. Chemotherapy with the K2 regimen was continued during the postoperative period for patients with high-grade tumors; thus, chemotherapy was performed during distraction osteogenesis.

The mean follow-up period for all 22 patients was 202 months (range 125–278 months; median 201 months). Two indices were used to evaluate the results: the external fixation index (EFI, calculated as the total duration of external fixation divided by the length gained) and the distraction index (DI, calculated as the total duration of distraction divided by the length gained). Functional evaluation of patients was performed using the revised 30-point functional classification system established by the International Society of Limb Salvage and the Musculoskeletal Tumor Society [20]. This functional system measures six parameters: pain, function, emotional acceptance, use of walking supports, walking ability, and gait. A value ranging from 0 to 5 is assigned to each parameter according to specific criteria. The individual scores are then added together to obtain an overall functional score, with a maximum of 30 points, which is expressed as a percentage of normal. Functional capability was measured on the day before surgery and every 6 months after surgery. Complications related to bone distraction [21] and oncological outcomes were also investigated.

All patients and/or families received a detailed explanation concerning the surgical procedure and submission for publication of data from the case, and they gave their

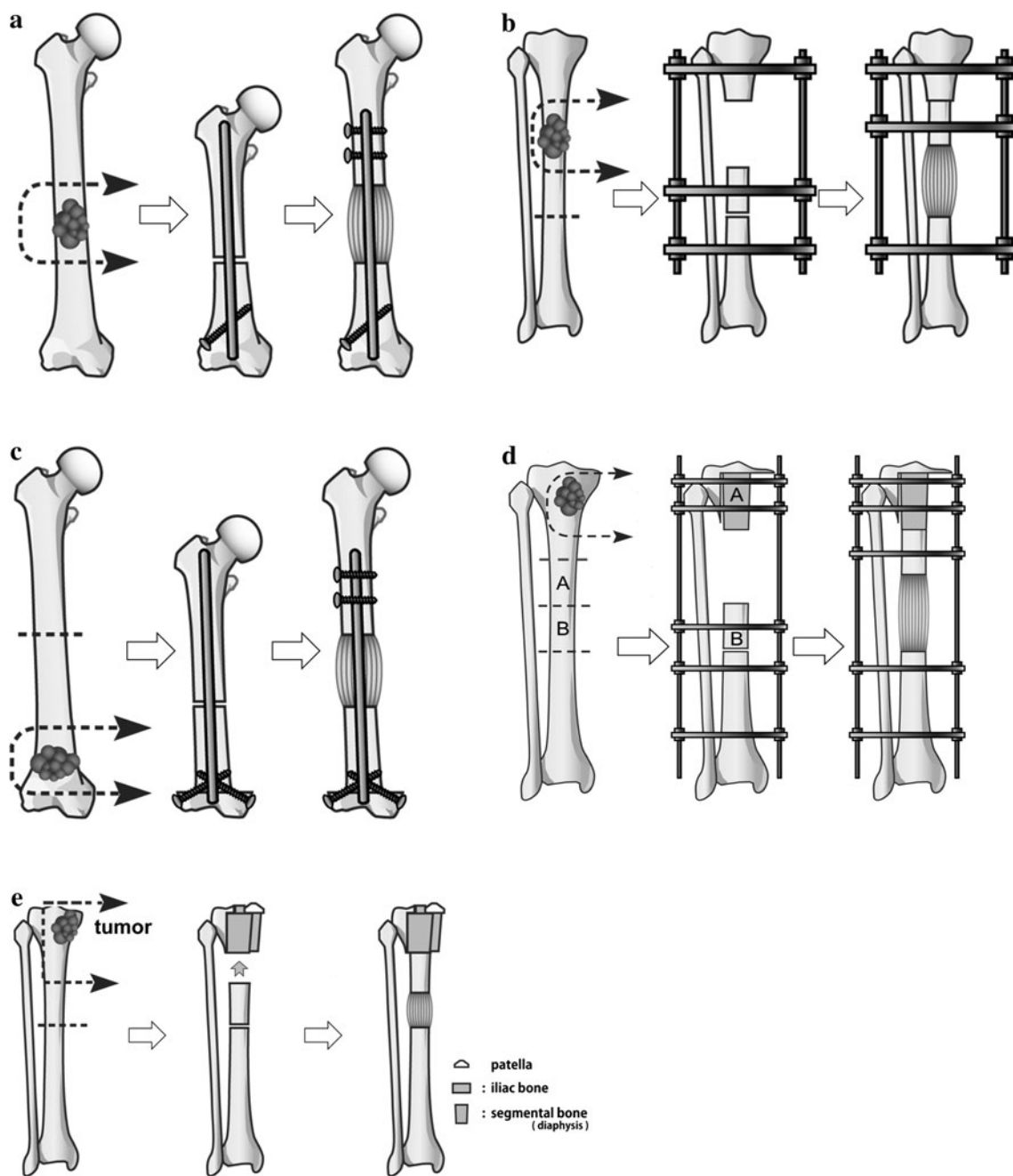


Fig. 1 Type of reconstruction by distraction osteogenesis. **a** Type 1 reconstruction of the femur with shortening distraction was applied in 1 case; **b** type 1 reconstruction of the tibia with bone transport was used in 6 cases; **c** type 2 reconstruction of the femur with shortening

distraction was applied in 3 cases and with bone transport in 3 cases; **d** type 4 reconstruction of the tibia with bone transport was used in 8 cases; **e** type 3 reconstruction of the tibia with bone transport was applied in 1 case

consent. This study was reviewed by an Independent Ethics Committee or Institutional Review Board.

Results

Patient details and a treatment summary are presented in Table 1. Bone transport was performed in 17 patients

(77 %), and shortening distraction was performed in 5 (23 %). Type I reconstruction was performed in 7 patients, type II reconstruction was performed in 6 patients, type III reconstruction was performed in 1 patient, and type IV reconstruction was performed in 8 patients. The mean length of bone distraction was 8.1 cm (range 4.5–14.0 cm; median 7.2 cm), the mean external fixation period (EFP) was 301 days (range 124–552 days; median 293 days), the

Table 1 Patient details and summary of treatment

Case	Age (years)	Gender	Site	Diag.	Chemo.	RR	Type of dist	Type of recon.	LG (cm)	DI (day/cm)	EFI (day/cm)	Complications	Outcome	Functional score (%)	Follow-up (months)
1	52	Female	MF	LGOS	No	(-)	SD	1	9.0	15.3	17.7	DC	CDF	100	145
2	8	Male	MT	Ewing	Yes	CR	BT	1	9.5	13.4	31.7	DU	AWD	100	180
3	14	Female	MT	LGOS	No	(-)	BT	1	13.5	10.2	28.6		CDF	100	278
4	4	Male	MT	ADM	No	(-)	BT	1	7.8	9.9	24.5		CDF	100	168
5	71	Female	MT	AMD	No	(-)	BT	1	4.5	18.4	72.9	Sever pin tract infection	CDF	100	175
6	13	Female	MT	OFD	No	(-)	BT	1	9.5	7.2	28.1		CDF	100	137
7	13	Female	MT	OFD	No	(-)	BT	1	5.5	16.9	63.5		CDF	100	164
8	9	Female	DF	OS	Yes	(-)	SD	2	9.0	13.0	13.8		CDF	100	213
9	9	Male	DF	OS	Yes	PR	BT	2	12.6	8.9	25.7	DU	DFOD	93	125
10	18	Female	DF	OS	Yes	CR	BT	2	14.0	8.8	37.4	Callus fracture	CDF	83	187
11	34	Female	DF	LGOS	No	(-)	SD	2	6.6	16.7	18.8		CDF	100	225
12	26	Female	DF	LGOS	No	(-)	BT	2	9.0	9.7	30.8		CDF	90	211
13	20	Male	DF	LGOS	No	(-)	SD	2	5.5	12.5	31.6	DU, peroneal nerve palsy	CDF	93	231
14	22	Male	PT	OS	Yes	CR	SD	3	9.2	15.4	39.6	DC, contracture	CDF	83	237
15	46	Female	PT	OS	Yes	PR	BT	4	5.5	17.3	100.4	DC, contracture	CDF	100	192
16	15	Male	PT	OS	Yes	CR	BT	4	12.5	20.6	39.7	Deep infection, delayed union	CDF	100	218
17	17	Female	PT	OS	Yes	CR	BT	4	5.7	20.0	56.5		CDF	100	131
18	44	Female	PT	GCT	No	(-)	BT	4	6.0	10.8	39.7		CDF	96	190
19	20	Male	PT	GCT	No	(-)	BT	4	6.5	20.0	42.6		CDF	96	261
20	54	Female	PT	GCT	No	(-)	BT	4	5.0	20.4	42.2	Callus fracture, contracture, OA of knee	NED	83	257
21	22	Female	PT	GCT	No	(-)	BT	4	4.5	34.9	35.8	Recurrence	NED	96	252
22	15	Male	PT	GCT	No	(-)	BT	4	6.5	20.5	43.7	Premature consolidation	CDF	96	257

MF middle femur, DF distal femur, PT proximal tibia, MT middle tibia, Diag. diagnosis, OS conventional osteosarcoma, LGOS low-grade osteosarcoma, Ewing Ewing's sarcoma, ADM adamantinoma, GCT giant cell tumor, OFD osteofibrous dysplasia, Chemo. chemotherapy, RR radiological response, PR partial response, CR complete response, Dist. distraction, SD shortening distraction, BT bone transport, Recon. reconstruction, LG length gained, DI distraction index, EFI external fixation index, DU delayed union, DC delayed consolidation, OA osteoarthritis, CDF continuous disease free, NED no evidence of disease, AWD alive with disease, DFOD death from other disease

Table 2 Complications and their management

Complication	Case	Treatment	Result
Delayed consolidation	1, 13, 14, 15	Bone grafting	Healed
Delayed union	2, 9, 16	Bone grafting	Healed
Pin tract infection	5	Removal	Cured
Callus fracture	10, 20	Refixation	Healed
Peroneal nerve palsy	13	Tendon transfer	No limitation of athletic activities
Contracture	14, 15, 20	Mobilization	Corrected
Deep infection	16	Resection of infected segment, shortening, then lengthening	Cured
Osteoarthritis of knee joint	20	Intra-articular hyaluronic acid injection	Good pain control
Recurrence	21	Curettage and artificial bone grafting	Cured
Premature consolidation	22	Reostotomy	No problems

mean DI was 15.5 day/cm (range 7.2–34.9 day/cm; median 15.4 day/cm), and the mean EFI was 40.3 day/cm (range 17.7–100.4 day/cm; median 36.6 day/cm).

We defined delayed union as a condition characterized by delayed bone healing at the docking site between the transported segment and host bone, and delayed consolidation as delayed bone consolidation in the distracted callus. Severe complications requiring additional surgeries included severe pin tract infection ($n = 1$), deep infection ($n = 1$), delayed union ($n = 5$), delayed consolidation ($n = 4$), premature consolidation ($n = 1$), joint contracture ($n = 3$), peroneal nerve palsy ($n = 1$), callus fracture ($n = 2$), and tumor recurrence ($n = 1$). Table 2 lists the complications that were encountered. Delayed bone healing occurred most commonly [7 patients (32 %)] as a complication of reconstruction with distraction osteogenesis and was managed successfully with bone grafting. All remaining complications were managed efficiently and did not affect the final outcome.

At a mean follow-up of 202 months, 18 patients remained disease-free, 2 patients had no evidence of disease, 1 patient was alive with disease, and 1 patient had died from another disease.

The results for change in function over time are also illustrated in Fig. 2. The mean Musculoskeletal Tumor Society functional score at final follow-up after a mean of 202 months (range 125–278 months) was 91.5 % (range 67–100 %). Functional outcomes gradually improved in

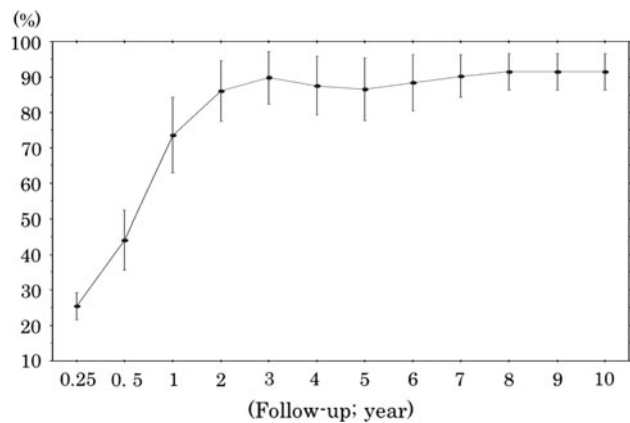


Fig. 2 Time-dependent change of the musculoskeletal tumor society functional score. Functional outcomes gradually improved in almost all patients within 2 years after initial reconstructive surgery and were maintained after their own best functional scores were achieved

almost all patients within 2 years after reconstruction surgery, and no patient lost functional ability after their own best functional score was restored. Fourteen patients (63.6 %) were able to participate in recreational sports at final follow-up.

Case presentation

Case 8

A 9-year-old female with stage IIB conventional osteosarcoma in the distal femur (Fig. 3).

The tumor size decreased markedly on MRI, and tumor stains disappeared on angiography after neoadjuvant chemotherapy. No tumor extension into the epiphysis was observed on T2-weighted MRI after chemotherapy. The epiphysis of the distal femur was preserved by intentional marginal excision. Total tumor necrosis was observed histologically. After tumor resection, a 7-cm bone defect was created, and the defect was refilled with acute shortening by 7 cm. The femur was distracted gradually by 9 cm at the diaphysis with an intramedullary nail. The affected limb was overextended by 2 cm to compensate for the anticipated limb length discrepancy. The EFP was 124 days, the DI was 13.0 day/cm, and the EFI was 13.8 day/cm. The patient currently has normal knee joint function and has displayed no evidence of disease for 213 months.

Case 16

A 15-year-old boy with stage IIB conventional osteosarcoma in the proximal tibia (Fig. 4).

The response to preoperative chemotherapy was judged to be complete. Marginal excision to preserve the epiphysis

was performed, and it was reconstructed with bone transport using type 2 reconstruction. The bone defect was 12.5 cm and filled gradually by the one transport technique. Two years after the initial reconstructive surgery, the patient developed a deep infection because of long-term external fixation. Curettage and a pedicle peroneal flap were performed, but the infection could not be resolved. Six months later, the infection required a third operation. The infected area was excised widely, and acute shortening by 2.5 cm was performed. Distraction was then applied gradually. The infection was successfully resolved; however, a leg length discrepancy of approximately 2 cm and a procurvatum deformity persisted. Four years after the initial operation, the patient experienced an intraarticular tibial plateau fracture of his reconstructed leg in a traffic accident. We reduced the fracture and corrected residual deformities with an Ilizarov ring fixator. In the 6 years since the initial surgery, all complications were treated, and

Fig. 4 Case 16: a 15-year-old boy with stage IIB conventional osteosarcoma in the proximal tibia. **a** Preoperative X-ray and MRI showed no tumor extension into the epiphysis. **b** Marginal excision to preserve the epiphysis was performed, and reconstructed with bone transport using type 2 reconstruction. The bone defect was 12.5 cm and filled gradually by the bone transport technique. **c** Two years later, the patient suffered a deep infection from pin site infection. The infected area was excised widely, and acute shortening by 2.5 cm was performed. Distraction was then applied gradually. The infection was successfully resolved. Four years after the initial operation, the patient suffered a tibial plateau fracture and was treated with an Ilizarov ring fixator. **d** The most recent X-rays showed remodeling of the metaphysis and native bone formation of the distracted area. The patient has been disease-free and able to maintain normal limb athletic function. **e** The limb functional score originally hovered at a low level; however, once the complications resolved, the score was gradually recovered and maintained

his limb function was gradually restored. At the latest follow-up, 19 years since the initial surgery, he has been disease-free and can maintain normal limb athletic function.

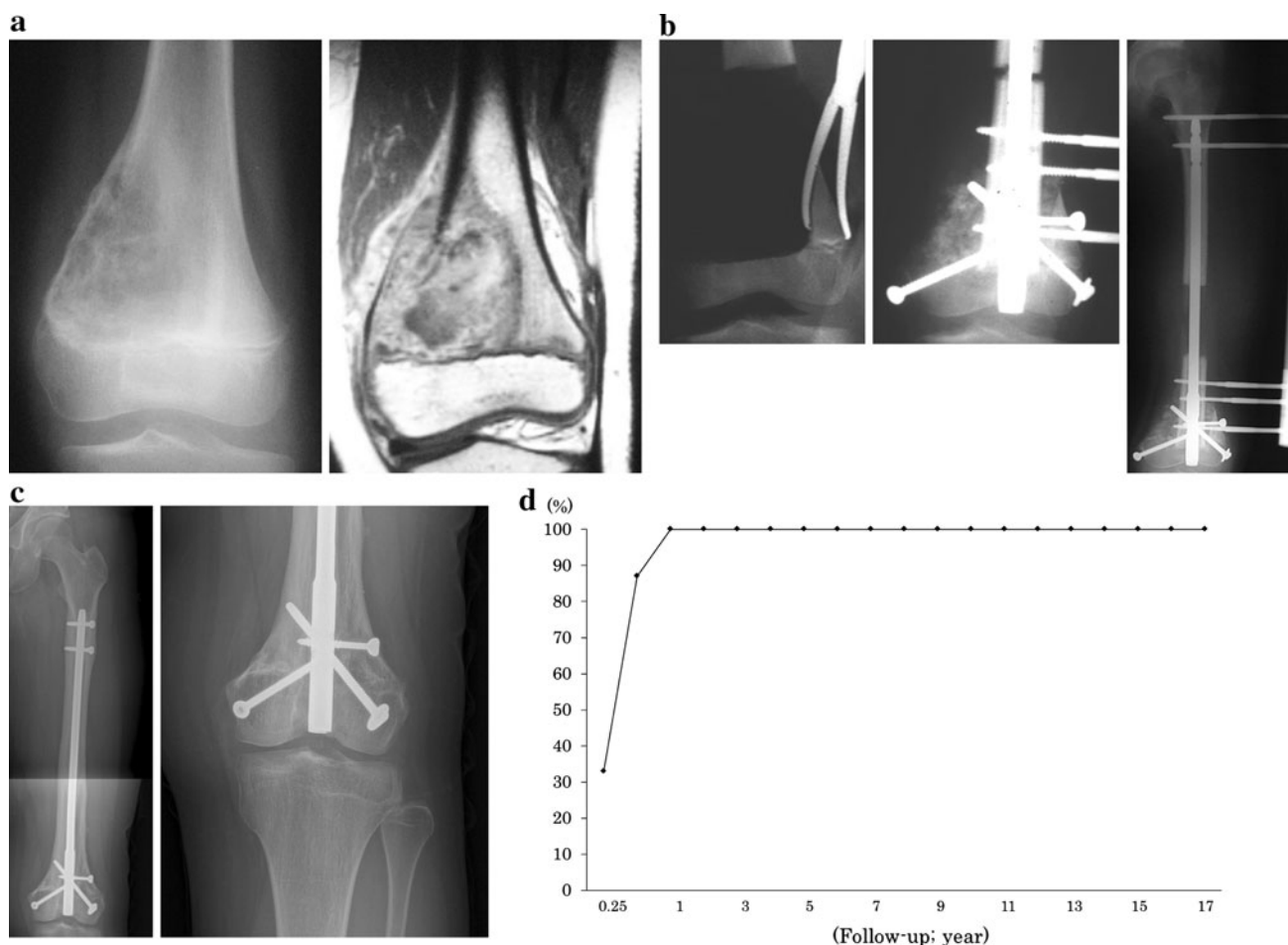
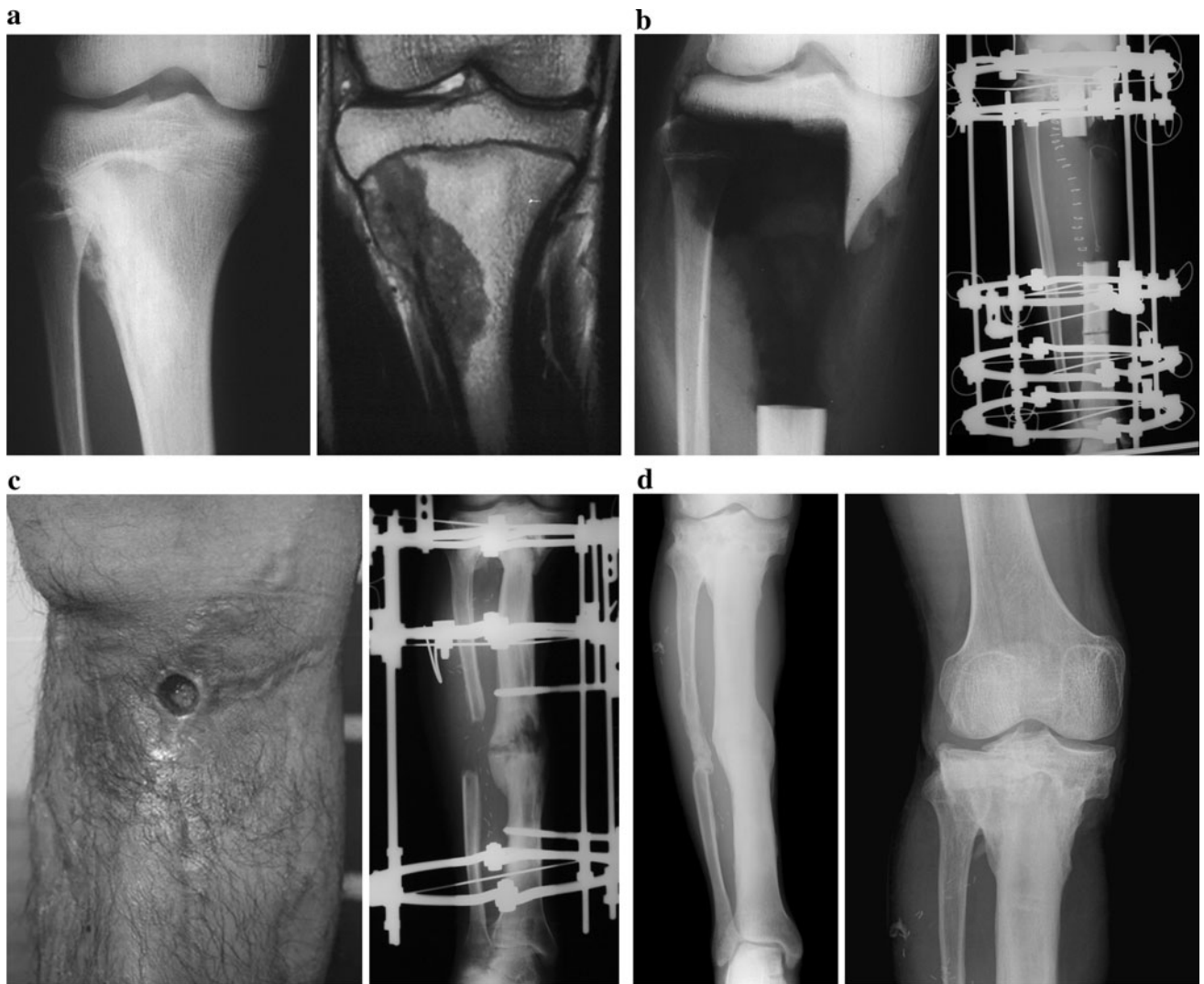

Fig. 3 Case 8: a 9-year-old female with stage IIB conventional osteosarcoma in the distal femur. **a** Preoperative X-ray and MRI showed no tumor extension into the epiphysis. **b** The epiphysis of the distal femur was preserved by intentional marginal excision, and a 7-cm bone defect was created. The defect was refilled with acute shortening by 7 cm, and the femur was distracted gradually by 9 cm

with an intramedullary nail. **c** The most recent X-rays showed full remodeling of the metaphysis to its normal shape and native bone formation of the distracted area. The patient currently has normal knee joint function and has displayed no evidence of disease for 213 months. **d** The limb functional score was gradually recovered and has been maintained for over 10 years



Discussion

Limb-salvaging surgery is currently a very commonly performed procedure [22]. Restoration of good function to a limb and maintaining it in the long term after resection of a bone tumor remain challenging. The ideal reconstruction should be biologically similar to existing bone, be resistant to infection, and be both strong and durable [23, 24]. In this study, we demonstrated that the mean Musculoskeletal Tumor Society functional score was 91.5 % at a mean of 202 months after reconstruction, and no patients lost their functional ability after recovering their own best functional score. We believe that epiphyseal preservation and reconstruction by distraction osteogenesis are currently the ideal reconstruction procedures.

Parameters critical for the success of this technique include a lesion ≤ 15 cm in length with at least 0.5 cm of subchondral bone and sufficient metaphyseal cortex retained after excision of tumors that responded well to chemotherapy. The presence of lung metastases must be considered as a relative, but not absolute, contraindication to the use of this technique.

In most cases, when the tumor extends into the metaphysis, intra-articular resection including the articular surface is required. Under these circumstances, reconstructive options include endoprosthesis, osteo-articular allograft, or a combination of these two techniques. Endoprosthetic replacement has many advantages, such as early stability, mobilization, and weight-bearing; a high level of emotional acceptance by the patient; and rapid restoration of function with a good functional outcome. However, problems such as infection, mechanical failure, and aseptic loosening may limit the long-term survival of the prosthesis, and the risk of revision increases with time, particularly in skeletally immature patients [25, 26]. If a prosthesis is used, both epiphyses are excised, leading to gross distortion of the normal anatomy and questionable durability for young patients.

The allograft may take up to 24 months to unite: a rate of nonunion of up to 20 % [27, 28] and a rate of infection as high as 20 % have been reported [27–29]. The incidence of fracture ranges from 15 to 45 %, depending on which definition of fracture is used [30]. An additional problem with osteo-articular allografts is degeneration of the articular surface. The high rate of complications and revision surgery associated with the use of osteo-articular allografts has led some investigators to believe that this procedure should only be considered as a temporary solution in the management of malignant bone tumors [9]. Recycled bone reconstruction involves the same problems as allograft reconstruction. With respect to allograft or recycled bone augmented

with vascularized bone, these procedures have length limitations and are technically difficult. Moreover, post-operative chemotherapy delays incorporation and union because of negative effects on healing and revascularization [37].

Distraction osteogenesis is widely known to regenerate living bone to sufficient strength and, being biological, it can be expected to remain permanent once it is formed [31]. For these patients, it is particularly important to have information regarding return to function so that they can make social and financial plans for the prolonged period of rehabilitation. Preserving the epiphysis is a surgical challenge and is required to achieve the best possible functional result [14, 32, 33]. In all diaphyseal reconstructions, the joint articular cartilage and soft tissue that stabilized the joint were completely preserved, so limb function was fully recovered. In some metaphyseal reconstructions, joint articular cartilage was preserved, but soft tissue around the joint was partially sacrificed. This resulted in some joint instability or contracture, which may have inhibited complete functional recovery. Excision of ligaments and muscles with epiphyses is also problematic, because it may cause joint instability and a decline of muscle strength.

The effect of chemotherapy on bone regeneration by distraction osteogenesis is a concern during the postoperative period. Our caffeine-potentiated chemotherapy protocol (the K2 regimen) appears to have had no hazardous effect on bone regeneration by distraction osteogenesis [34]. Although we have previously shown that chemotherapy decreases regional blood flow to the tumor area, it can be maintained within the normal range or even higher with distraction osteogenesis [35]. In our series, one patient developed a deep infection, but did not require amputation [36].

Advantages of distraction osteogenesis include regeneration of living bone with sufficient strength and durability, biological affinity, resistance against infection, and life-long restored function. Disadvantages include frequent delayed union at the docking site and pin- or wire-tract infection, as well as the fact that the procedure is time-consuming. However, complications can be resolved by additional surgeries, and once function has been restored, it can be maintained throughout life, without anxiety about loosening or revision. In conclusion, epiphyseal preservation and reconstruction by distraction osteogenesis can provide an excellent outcome, resulting in a stable reconstruction that functionally restores the native limb for selected cases.

Conflict of interest No benefits of any kind have been received or will be received from a commercial party related directly or indirectly to the subject of this article.

References

1. Messerschmitt PJ, Garcia RM, Abdul-Karim FW, Greenfield EM, Getty PJ. Osteosarcoma. *J Am Acad Orthop Surg.* 2009;17:515–27.
2. Grimer RJ. Surgical options for children with osteosarcoma. *Lancet Oncol.* 2005;6:85–92.
3. Heare T, Hensley MA, Dell'Orfano S. Bone tumors: osteosarcoma and Ewing's sarcoma. *Curr Opin Pediatr.* 2009;21:365–72.
4. Ottaviani G, Robert RS, Huh WW, Jaffe N. Functional, psychosocial and professional outcomes in long-term survivors of lower-extremity osteosarcomas: amputation versus limb salvage. *Cancer Treat Res.* 2010;152:421–36.
5. Jeys LM, Grimmer RJ, Carter SR, Tillman RM. Risk of amputation following limb salvage surgery with endoprosthesis replacement, in a consecutive series of 1261 patients. *Int Orthop.* 2003;27:160–3.
6. Biau D, Faure F, Katsahian S, Jeanrot C, Tomeno B, Anract P. Survival of total knee replacement with a megaprosthesis after bone tumor resection. *J Bone Joint Surg Am.* 2006;88-A:1285–93.
7. Asada N, Tsuchiya H, Kitaoka K, Mori Y, Tomita K. Massive autoclaved allografts and autografts for limb salvage surgery. A 1–8 year follow-up of 23 patients. *Acta Orthop Scand.* 1997;68:392–5.
8. Hayashi K, Tsuchiya H, Yamamoto N, Minato H, Tomita K. Histological examination of autoclaved bone removed 12 years after it was transplanted. *J Orthop Sci.* 2005;10:425–9.
9. Rödl RW, Ozaki T, Hoffmann C, Böttner F, Lindner N, Winkelmann W. Osteoarticular allograft in surgery for highgrade malignant tumors of bone. *J Bone Joint Surg Br.* 2000;82:1006–10.
10. Abed YY, Beltrami G, Campanacci DA, Innocenti M, Scoccianti G, Capanna R. Biological reconstruction after resection of bone tumors around the knee: long-term follow-up. *J Bone Joint Surg Br.* 2009;91:1366–72.
11. Tsuchiya H, Tomita K, Mori Y, Asada N, Morinaga T, Kitano S, Yamamoto N. Caffeine-assisted chemotherapy and minimized tumor excision for nonmetastatic osteosarcoma. *Anticancer Res.* 1998;18:657–66.
12. Tsuchiya H, Tomita K, Mori Y, Asada N, Yamamoto N. Marginal excision for osteosarcoma with caffeine assisted chemotherapy. *Clin Orthop.* 1999;358:27–35.
13. Tsuchiya H, Abdel-Wanis ME, Kitano S, Sakurakichi K, Yamashiro T, Tomita K. The natural limb is best: joint preservation and reconstruction by distraction osteogenesis for high-grade juxta-articular osteosarcomas. *Anticancer Res.* 2002;22:2373–6.
14. Tsuchiya H, Abdel-Wanis ME, Sakurakichi K, Yamashiro T, Tomita K. Osteosarcoma around the knee. Intraepiphyseal excision and biological reconstruction with distraction osteogenesis. *J Bone Joint Surg Br.* 2002;84:1162–6.
15. Tsuchiya H, Tomita K. Distraction osteogenesis for treatment of bone loss in the lower extremity. *J Orthop Sci.* 2003;8:116–24.
16. Tsuchiya H, Abdel-Wanis ME, Tomita K. Biological reconstruction after excision of juxta-articular osteosarcoma around the knee: a new classification system. *Anticancer Res.* 2006;26:447–53.
17. Tsuchiya H, Morsy AF, Matsubara H, Watanabe K, Abdel-Wanis ME, Tomita K. Treatment of benign bone tumors using external fixation. *J Bone Joint Surg Br.* 2007;89:1077–83.
18. Hayashi K, Tsuchiya H, Yamamoto N, Takeuchi A, Tomita K. Functional outcome in patients with osteosarcoma around the knee joint treated by minimised surgery. *Int Orthop.* 2008;32:63–8.
19. Tsuchiya H, Yasutake H, Yokogawa A, Baba H, Ueda Y, Tomita K. Effect of chemotherapy combined with caffeine for osteosarcoma. *J Cancer Res Clin Oncol.* 1992;118:567–9.
20. Enneking WF, Dunham W, Gebhardt MC, Malawer M, Pritchard DJ. A system for the functional evaluation of reconstructive procedures after surgical treatment of tumors of the musculoskeletal system. *Clin Orthop.* 1993;286:241–6.
21. Paley D. Problems, obstacles, and complications of limb lengthening by the Ilizarov technique. *Clin Orthop.* 1990;250:81–104.
22. Bacci G, Ferrari S, Lari S, Mercuri M, Donati D, Longhi A, Forni C, Bertoni F, Versari M, Pignotti E. Osteosarcoma of the limb. Amputation or limb salvage in patients treated by neoadjuvant chemotherapy. *J Bone Joint Surg Br.* 2000;84:88–92.
23. Tsuchiya H, Tomita K, Minematsu K, Mori Y, Asada N, Kitano S. Limb salvage using distraction osteogenesis: a classification of the technique. *J Bone Joint Surg Br.* 1997;79:403–11.
24. Plotz W, Rechl H, Burgkart R, Messmer C, Schelter R, Hipp E, Gradinger R. Limb salvage with tumor endoprosthesis for malignant tumors of the knee. *Clin Orthop.* 2002;405:207–15.
25. Jeon DG, Kawai A, Boland P, Healy JH. Algorithm for the surgical treatment of malignant lesions of the proximal tibia. *Clin Orthop.* 1999;358:15–26.
26. Kawai A, Muschler GF, Lane JM, Otis JC, Healey JH. Prosthetic knee replacement after resection of a malignant tumor of the distal femur: medium to long-term results. *J Bone Joint Surg Am.* 1998;80:636–47.
27. Aho AJ, Ekfors T, Dean PB, Aro HT, Ahonen A, Nikkanen V. Incorporation and clinical results of large allografts of the extremities and pelvis. *Clin Orthop.* 1994;307:200–13.
28. Ortiz-Cruz E, Gebhardt MC, Jennings L, Springfield DS, Mankin HJ. The results of transplantation of intercalary allografts after resection of tumors: a long-term follow-up study. *J Bone Joint Surg Am.* 1997;79:97–106.
29. Hornicek FJ Jr, Mnaymneh W, Lackman RD, Exner GU, Malinin TI. Limb salvage with osteoarticular allografts after resection of proximal tibia bone tumors. *Clin Orthop.* 1998;352:179–86.
30. Thompson RC Jr, Garg A, Clohisy DR, Cheng EY. Fractures in large-segment allografts. *Clin Orthop.* 2000;370:227–35.
31. Tsuchiya H, Tomita K, Shinokawa Minematsu K, Katsuo S, Taki J. The Ilizarov method in the management of giant-cell tumors of the proximal tibia. *J Bone Joint Surg Br.* 1996;78:264–9.
32. Kumta SM, Chow TC, Griffith J. Classifying the location of osteosarcoma with reference to the epiphyseal plate helps determine the optimal skeletal resection in limb salvage procedures. *Arch Orthop Trauma Surg.* 1999;119:327–31.
33. Manfrini M, Gasbarrini A, Malaguti C, Ceruso M, Innocenti M, Bini S, Capanna R, Campanacci M. Intraepiphyseal resection of the proximal tibia and its impact on lower limb growth. *Clin Orthop.* 1999;358:111–9.
34. Tsuchiya H, Shirai T, Morsy AF, Sakayama K, Wada T, Kusuzaki K, Sugita T, Tomita K. Safety of external fixation during postoperative chemotherapy. *J Bone Joint Surg Br.* 2008;90:924–8.
35. Minematsu K, Tsuchiya H, Taki J, Tomita K. Blood flow measurement during distraction osteogenesis. *Clin Orthop.* 1998;347:229–35.
36. Shirai T, Tsuchiya H, Yamamoto N, Sakurakichi K, Karita M, Tomita K. Successful management of complications from distraction osteogenesis after osteosarcoma resection: a case report. *J Orthop Sci.* 2004;9:638–42.
37. Hornicek FJ, Gebhardt MC, Tomford WW, Sorger JI, Zavatta M, Menzner JP, Mankin HJ. Factors affecting nonunion of the allograft-host junction. *Clin Orthop.* 2001;382:87–98.