

# The outcomes of reconstruction using frozen autograft combined with iodine-coated implants for malignant bone tumors: Compared with non-coated implants

著者	Shirai Toshiharu, Tsuchiya Hiroyuki, Terauchi Ryu, Tsuchida Shinji, Mizoshiri Naoki, Igarashi Kentaro, Miwa Shinji, Takeuchi Akihiko, Kimura Hiroaki, Hayashi Katsuhiko, Yamamoto Norio, Kubo Toshikazu
journal or publication title	Japanese Journal of Clinical Oncology
volume	46
number	8
page range	735-740
year	2016-08-01
URL	<a href="http://hdl.handle.net/2297/46534">http://hdl.handle.net/2297/46534</a>

doi: 10.1093/jjco/hyw065

**The outcomes of reconstruction using frozen autograft combined with iodine-coated implants for malignant bone tumors: compared with non-coated implants**

Toshiharu Shirai<sup>1,2\*</sup>, Hiroyuki Tsuchiya<sup>2</sup>, Ryu Terauchi<sup>1</sup>, Shinji Tsuchida<sup>1</sup>, Naoki Mizoshiri<sup>1</sup>, Kentaro Igarashi<sup>2</sup>, Shinji Miwa<sup>2</sup>, Akihiko Takeuchi<sup>2</sup>, Hiroaki Kimura<sup>2</sup>, Katsuhiko Hayashi<sup>2</sup>, Norio Yamamoto<sup>2</sup>, Toshikazu Kubo<sup>1</sup>

<sup>1</sup>Department of Orthopaedics, Graduate School of Medical Science, Kyoto Prefectural University of Medicine, 465 Kajii-cho, Kamigyo-ku, Kyoto 602-8566, Japan

<sup>2</sup>Department of Orthopaedic Surgery, Graduate School of Medical Science, Kanazawa University, 13-1 Takaramachi Kanazawa 920-8641, Japan

\*Corresponding author. E-mail address: shirai.t77@gmail.com (T Shirai).

Tel: +81-75-251-5549, Fax: +81-76-234-4261

**Running title:** Frozen autograft with iodine coated-implants

## **Abstract**

**Objective:** We perform reconstruction using frozen tumor bone treated by liquid nitrogen after excision of malignant bone tumors. To prevent postoperative infection, we use iodine-coated implants that we developed. The purpose of this study is to compare the outcome of reconstruction using frozen autograft with non-coated implants (group N) and iodine-coated implants (group I).

**Methods:** Sixty-two patients were included in group N. The mean age was  $31.9\pm 2.3$  years. A total of 20 patients died and two were lost to follow-up, averaging  $20.0\pm 2.9$  months post-operatively, leaving 40 patients available for an assessment at a mean of  $79.1\pm 5.8$  months post-operatively. There were 38 patients in group I. The mean age was  $29.8\pm 3.9$  years. The mean follow-up period was  $32.1\pm 3.0$  months. All patients were alive at the latest follow-up. Survival of frozen bone was determined by Kaplan-Meier analysis.

**Results:** In group N, survival of frozen bone was  $80.7\pm 6.0\%$  and  $57.4\pm 10.2\%$  at 5 and 10 years, respectively. Complications were encountered in 31 of 62 patients (50.0%), including deep infection in 10 (16.1%), fracture in 11 (17.7%), local soft-tissue recurrence in six (9.7%), and bone absorption in four (6.5%). In group I, survival of frozen bone was  $86.7\pm 6.3\%$  at 5

years. Complications were encountered in 8 of 38 patients (21.1%), including deep infection in one (2.6%), fracture in four (10.5%), local soft-tissue recurrence in two (5.3%), and bone absorption in one (2.6%). There was a significantly lower infection rate in group I (P=0.032).

**Conclusion:** Reconstruction using frozen autograft combined with iodine coated-implants for patients with malignant bone tumor is very useful method in which good limb function can be gained with minimized risk of infection.

#### **Mini-abstract**

Reconstruction using frozen tumor bone treated by liquid nitrogen combined with iodine coated-implants for patients with malignant bone tumor is very useful method in which good limb function can be gained with minimized risk of infection.

**Key words:** frozen autograft, iodine-coated implants, postoperative infection, sarcoma

## **Introduction**

Limb salvage surgery is a standard treatment for malignant musculoskeletal tumors with the development of a combined modality therapy (1,2). The reconstruction methods following tumor excision in limb salvage operation are tumor prosthesis (2), autograft (1,3), allograft (4), distraction osteogenesis (5), and vascularized fibular graft (6). Biological reconstruction by recycling the resected tumor-bearing bone is popular in Asian countries. Before re-implantation, the bone is subject to treatment including irradiation (1,7), pasteurization (8,9), or freezing with liquid nitrogen (3,10,11). In 1999, we developed and performed a re-implantation technique using frozen autografts treated with liquid nitrogen. The advantages of liquid nitrogen treatment include the following: simplicity, low cost, maintenance of osteoinductive and osteoconductive properties, perfect fit between graft and host bone, no disease transmission, no immunological rejection, preservation of the cartilage matrix, no need for a bone bank, no requirement of special equipment and strict thermal control, easy attachment of tendons and ligaments to bone, no harmful denatured substances, early revitalization and cryoimmunological effects (11).

Post-operative infection is one of the most serious complications for recycled autografts. We developed iodine-coated implants to prevent post-operative infection in 2005 (12). The anodic

oxide film was produced electrically, and use of a povidone-iodine electrolyte resulted in the formation of an adhesive porous anodic oxide with the antiseptic properties of iodine. The thickness of the anodic oxide film was between 5 and 10  $\mu\text{m}$ , with more than 100,000 pores/ $\text{mm}^2$  and capacity to support 10-12  $\mu\text{g}/\text{cm}^2$  iodine. The durability of the implants is not influenced, because it is just a coating. We have previously reported the clinical effects of iodine-coated implants (13,14,15).

The purpose of this study was to compare the outcomes of reconstruction using frozen autograft with non-coated implants (group N) and iodine-coated implants (group I).

## **Patients and methods**

Between 1999 and 2008, we recruited 62 patients with bone tumors, who underwent reconstruction using frozen autografts with non-coated implants (group N). The mean age of the patients was  $31.9 \pm 2.3$  years (range, 7 to 72). Thirty-nine patients were male and 23 were female. A total of 20 patients died and two were lost to follow-up, at a mean of  $20.0 \pm 2.9$  months (range, 2 to 48) post-operatively. Therefore, 40 patients were available for assessment at a mean of  $79.1 \pm 5.8$  months (range, 11 to 158) post-operatively. The diagnoses included 38

cases of osteosarcoma, seven of metastasis and chondrosarcoma, four of Ewing's sarcoma, two of malignant fibrous histiocytoma (MFH) and one case each of rhabdomyosarcoma, leiomyosarcoma, chordoma, and malignant hemangiopericytoma. The affected sites included 33 femur, 11 tibia, 10 pelvis, six humerus, and one radius and calcaneus. The following types of implants were used with frozen bone: 22 nails, 16 plates, 10 knee prostheses, eight hip prostheses, four screws, and two shoulder prostheses. Between 2008 and 2014, we included 38 patients, who underwent reconstruction using frozen autografts with iodine-coated implants (group I). The mean age of the patients was  $29.8 \pm 3.9$  years (range, 6 to 79). Twenty-two patients were male and 16 were female. The mean follow-up period was  $32.1 \pm 3.0$  months (range, 7 to 68). All patients were alive at the most recent follow-up. The diagnoses were 29 cases of osteosarcoma, three of metastasis, two of chondrosarcoma, and one each of Ewing's sarcoma (Fig. 1a-g), fibrosarcoma, MFH and adamantinoma. The affected sites included 19 femur, 12 tibia, three pelvis and humerus, and one radius. The following types of iodine-coated implants were used with frozen bone: 33 plates, 3 knee prostheses, and each one hip and shoulder prosthesis. The survival of frozen bone was determined by Kaplan-Meier analysis, and inter-group survival differences were determined using a log-rank test. The survival of frozen

bone was defined as the period until the surgical removal of the recycled bone. Post-operative complications during follow-up were evaluated in both groups. A Fisher's exact test was performed to examine post-operative complications such as infection, fracture, recurrence, and bone absorption. The function of the affected limbs of 46 patients in group N and 34 patients in group I, who were followed for at least one year, was evaluated with the Musculoskeletal Tumor Society (MSTS) functional scoring system (16). Functional outcomes in the two study groups were compared using a *t* test. Statistical analyses were performed using IBM SPSS Statistics software, version 19 (IBM SPSS, Armonk, NY, USA). A *P* value of less than 0.05 was considered significant.

## **Results**

Between group N and group I, there was no significant difference with regard to the diagnosis and affected sites.

In group N, the survival rate of frozen bone was  $80.7 \pm 6.0\%$  and  $57.4 \pm 10.2\%$  at 5 and 10 years, respectively (Fig. 2). Complications were encountered in 31 of 62 patients (50.0%), including 10 cases of deep infection (16.1%), 11 of fracture (17.7%), six of local soft-tissue



recurrence (9.7%), and four of bone absorption (6.5%). Most infections had occurred within 6 months during postoperative chemotherapy. Frozen autografts were removed in 14 patients because of infection (6 cases), fracture (5 cases), tumor recurrence (2 cases), and bone absorption (1 case) (Table 1). The mean period of graft removal was  $30.3 \pm 10.2$  months (range, 3.6 to 114.5).

In group I, survival of frozen bone was  $86.7 \pm 6.3\%$  at 5 years (Fig. 2). Complications were encountered in 8 of 38 patients (21.1%) including one case of deep infection (2.6%), four of fracture (10.5%), two of local soft-tissue recurrence (5.3%), and one of bone absorption (2.6%). Frozen autografts were removed in four patients because of infection (1 case), fracture (2 cases), and tumor recurrence (1 case) (Table 1). The mean period of graft removal was  $13.3 \pm 4.1$  months (range, 5.0 to 24.1). On Kaplan-Meier survival analysis, there was no significant difference ( $P=0.872$ ) (Fig. 2). However, there was a significantly lower infection rate in group I ( $P=0.032$ ) (Table I). The mean MSTS score was 85.2% in group N and 92.8% in group I. These differences were not statistically significant ( $P=0.12$ ).

## **Discussion**

The infection rate of group I was significantly lower for the reconstructions using frozen autografts, although there was no difference in the survival rate compared to previous recycled bone, such as allografts (17), irradiated autografts (18), pasteurized autografts (19), and frozen autografts (20) (Table 2). The results suggest that iodine-coated implants had antibacterial effects. Although the survival rate of the frozen bone was not significantly different using iodine-coated implants compared to frozen autografts alone, we expect that the survival rate may be improved by increasing the number of iodine-coated implant cases. The iodine coating is a revolutionary technology for implants because of its antibacterial efficacy. The iodine-coated implants make it possible for postoperative infection to be controlled. In 5 years, iodine-coated implants will be made available commercially in Japan.

In terms of functionality, the average MSTS scores were 90%, 62.6%, 78.7%, and 79.2% in allograft, irradiated autograft, pasteurized autograft and frozen autograft, respectively (18-21).

In this study, the average of functional score was 85.2% and 92.8% for group N and group I, respectively. Therefore, functional outcomes for both groups were favorable compared to the other recycled bone techniques. Group I in particular displayed good functional tendencies,

although there was no significant difference in the MSTS scores between group N and group I (P=0.12).

There are a few limitations to note in this study. First, a relatively small number of patients limit the interpretation of our results. However, these numbers are comparable or greater than previous reports using recycled bone grafts. Second, group N represents our previous treatment method, whereas group I represents the treatment group after our development of iodine coating. In other words, the two groups may not be compared directly, and the historical nature of this study limits its level of evidence. Thirds, this study was retrospective and the study period included a relatively broad time frame. As such, patient selection between each group was not standardized. Fourth, the follow-up duration of group I was shorter than group N. More long-term follow-up is needed in group I.

In conclusion, the study showed that reconstruction using frozen autograft combined with iodine-coated implants for patients with malignant bone tumor is a very useful method in which good limb function can be gained with minimal risk of infection.

#### **Conflict of interest statement**

None declared.

## References

1. Wang CS, Wu PK, Chen CF, Chen WM, Liu CL, Chen TH. Bone-prosthesis composite with rotating hinged-knee prosthesis in limb salvage surgery for high-grade sarcoma around the knee. *J Arthroplasty* 2015;30:90-4.
2. Tsagkozis P, Brosjö O, Bauer HC. Reconstruction with modular megaprotheses for sarcomas of the lower extremity. *Orthopedics* 2015;38:e401-6.
3. Igarashi K, Yamamoto N, Shirai T, et al. The long-term outcome following the use of frozen autograft treated with liquid nitrogen in the management of bone and soft-tissue sarcomas. *Bone Joint J* 2014;96-B:555-61.
4. Frisoni T, Cevolani L, Giorgini A, Dozza B, Donati DM. Factors affecting outcome of massive intercalary bone allografts in the treatment of tumours of the femur. *J Bone Joint Surg Br* 2012;94:836-41.

5. Watanabe K, Tsuchiya H, Yamamoto N, et al. Over 10-year follow-up of functional outcome in patients with bone tumors reconstructed using distraction osteogenesis. *J Orthop Sci* 2013;18:101-9.
6. Sainsbury DC, Liu EH, Alvarez-Veronesi MC, et al. Long-term outcomes following lower extremity sarcoma resection and reconstruction with vascularized fibula flaps in children. *Plast Reconstr Surg* 2014;134:808-20.
7. Araki N, Myoui A, Kuratsu S, et al. Intraoperative extracorporeal autogenous irradiated bone grafts in tumor surgery. *Clin Orthop Relat Res* 1999;368:196-206.
8. Manabe J, Ahmed AR, Kawaguchi N, Matsumoto S, Kuroda H. Pasteurized autologous bone graft in surgery for bone and soft tissue sarcoma. *Clin Orthop Relat Res* 2004;419:258-66.
9. Sugiura H, Nishida Y, Nakashima H, Yamada Y, Tsukushi S, Yamada K. Evaluation of long-term outcomes of pasteurized autografts in limb salvage surgeries for bone and soft tissue sarcomas. *Arch Orthop Trauma Surg* 2012;132:1685-95.

10. Tsuchiya H, Wan SL, Sakayama K, Yamamoto N, Nishida H, Tomita K. Reconstruction using an autograft containing tumour treated by liquid nitrogen. *J Bone Joint Surg Br* 2005;87:218-25.
11. Tsuchiya H, Nishida H, Srisawat P, et al. Pedicle frozen autograft reconstruction in malignant bone tumors. *J Orthop Sci* 2010;15:340-9.
12. Shirai T, Shimizu T, Ohtani K, Zen Y, Takaya M, Tsuchiya H. Antibacterial iodine-supported titanium implants. *Acta Biomater* 2011;7:1928-33.
13. Tsuchiya H, Shirai T, Nishida H, et al. Innovative antimicrobial coating of titanium implants with iodine. *J Orthop Sci* 2012;17:595-604.
14. Shirai T, Watanabe K, Matsubara H, et al. Prevention of pin tract infection with iodine-supported titanium pins. *J Orthop Sci* 2014;19:598-602.
15. Shirai T, Tsuchiya H, Nishida H, et al. Antimicrobial megaprotheses supported with iodine. *J Biomater Appl* 2014;29:617-23.
16. Enneking WF, Dunham W, Gebhardt MC, Malawar M, Pritchard DJ. A system for the functional evaluation of reconstructive procedures after surgical treatment of tumors of the musculoskeletal system. *Clin Orthop Relat Res* 1993;286:241-6.

17. Biau DJ, Dumaine V, Babinet A, Tomeno B, Anract P. Allograft-prosthesis composites after bone tumor resection at the proximal tibia. *Clin Orthop Relat Res* 2007;456:211-7.
18. Kim JD, Lee GW, Chung SH. A reconstruction with extracorporeal irradiated autograft in osteosarcoma around the knee. *J Surg Oncol* 2011;104:187-91.
19. Jeon DG, Kim MS, Cho WH, Song WS, Lee SY. Pasteurized autograft-prosthesis composite for reconstruction of proximal tibia in 13 sarcoma patients. *J Surg Oncol* 2007;96:590-7.
20. Paholpak P, Sirichativapee W, Wisanuyotin T, Kosuwon W, Jeeravipoolvarn P. Clinical results of primary malignant musculoskeletal tumor treated by wide resection and recycling autograft reconstruction using liquid nitrogen. *Asia Pac J Clin Oncol* 2015;11:114-20.
21. Mo S, Ding ZQ, Kang LQ, Zhai WL, Liu H. Modified technique using allograft-prosthetic composite in the distal femur after bone tumor resection. *J Surg Res* 2013;182:68-74.

## Legends

Figure 1: A 14 year-old boy with pelvic Ewing's sarcoma.

a: On initial MRI, there was a huge extraskeletal tumor mass (arrowhead).

b: On post-chemotherapeutic MRI, the extraskeletal mass had shrunk (arrowhead).

c: We performed reconstruction using a frozen autograft with iodine-coated implants after tumor excision.

d: The immediate post op computed tomography: osteotomy site was shown at sacrum (arrow)

e: Radiograph at 20 months after surgery.

f: Computed tomography showed excellent union between the host and frozen bone (arrow).

g: He is able to run normally at 20 months after surgery.

Figure 2: A Kaplan-Meier curve showing the survival rate of the frozen autografts according to the coating of implants.

Table 1: Complications and limb function according to the implant coating.

Table 2: Comparison with previous studies.



Figure1a

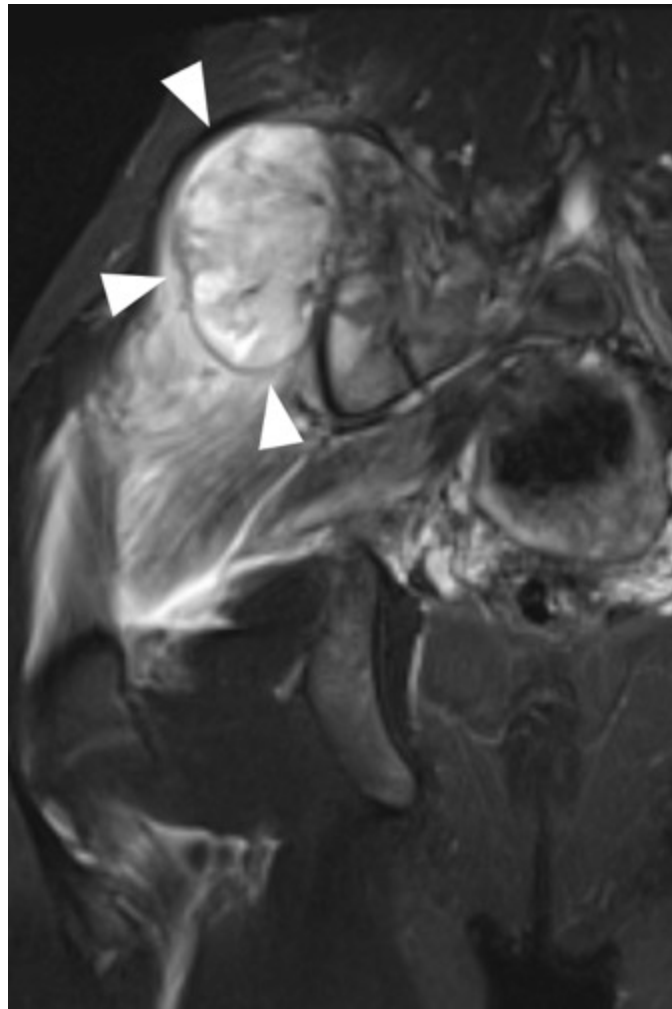


Figure1b

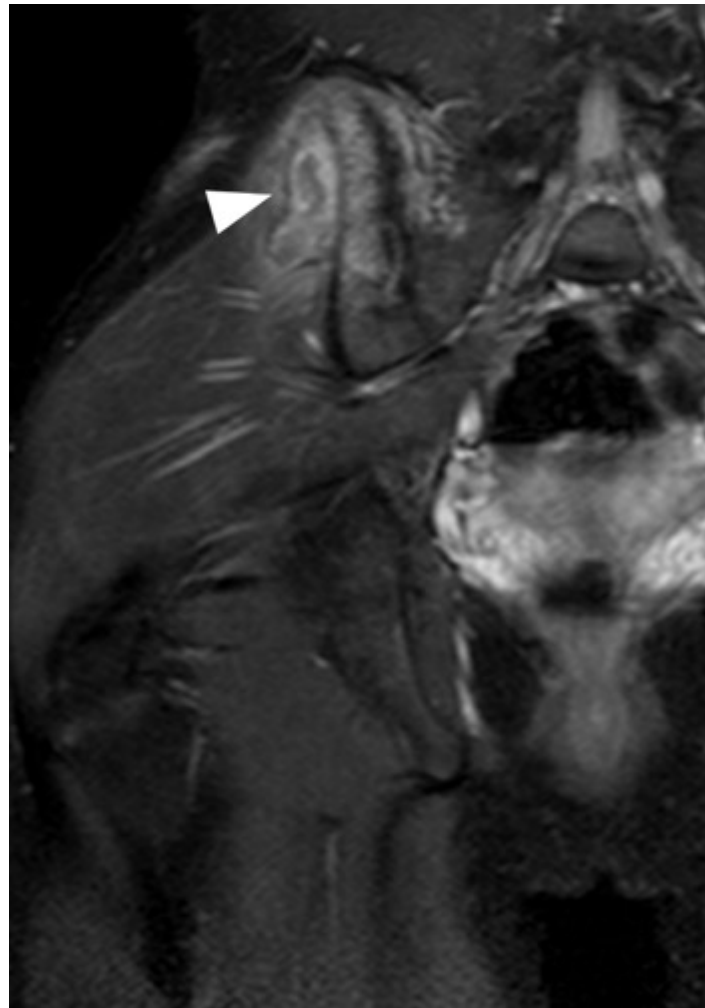


Figure 1c

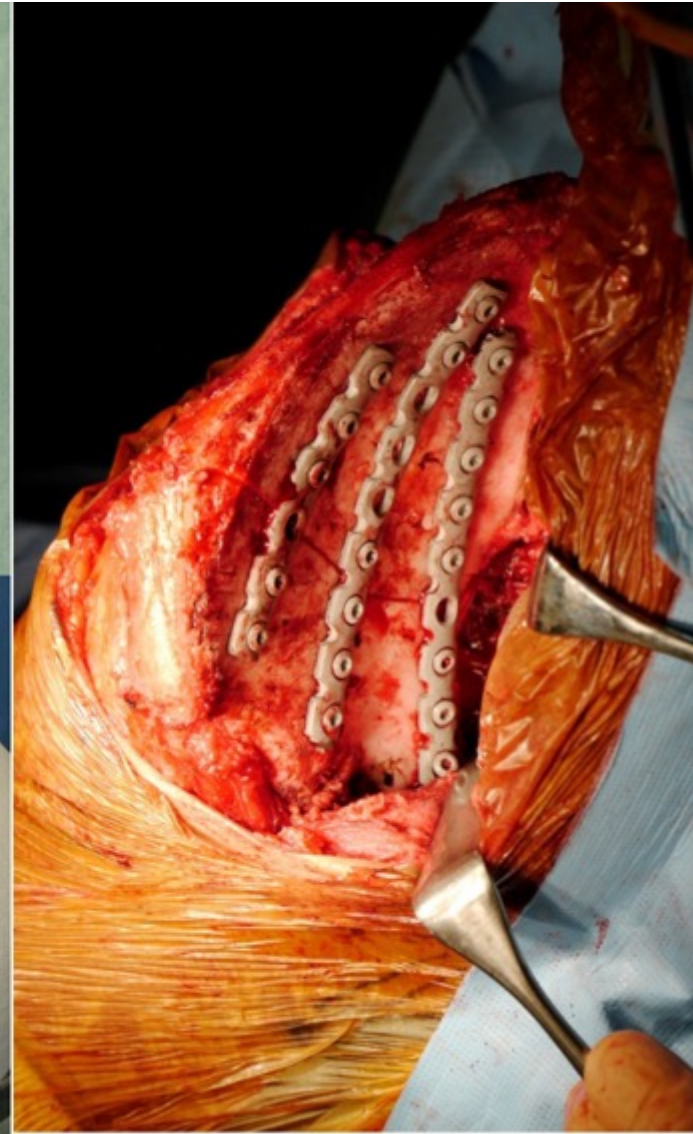
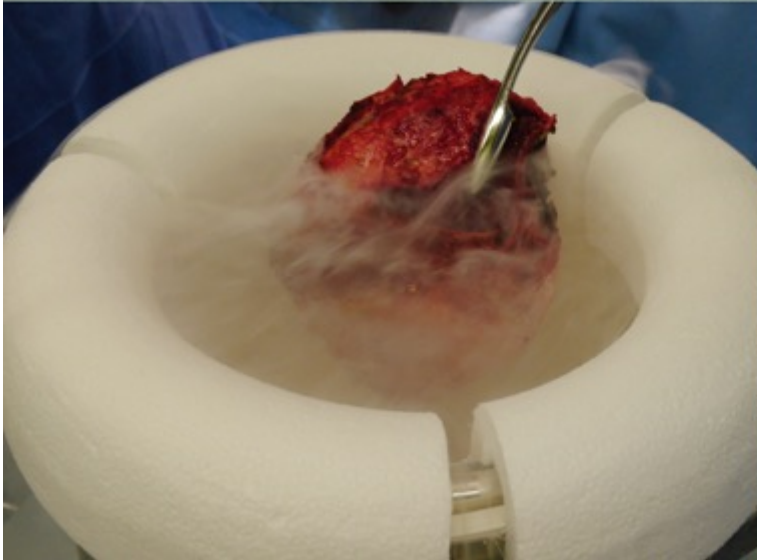
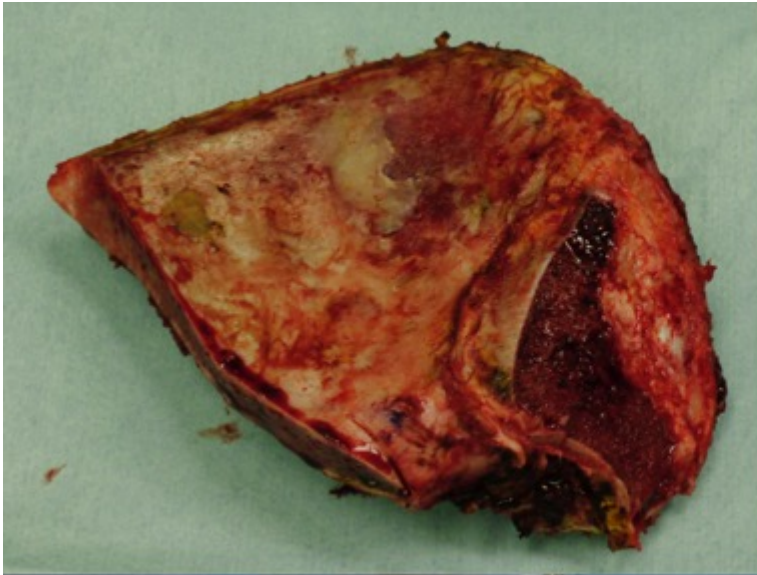


Figure1d

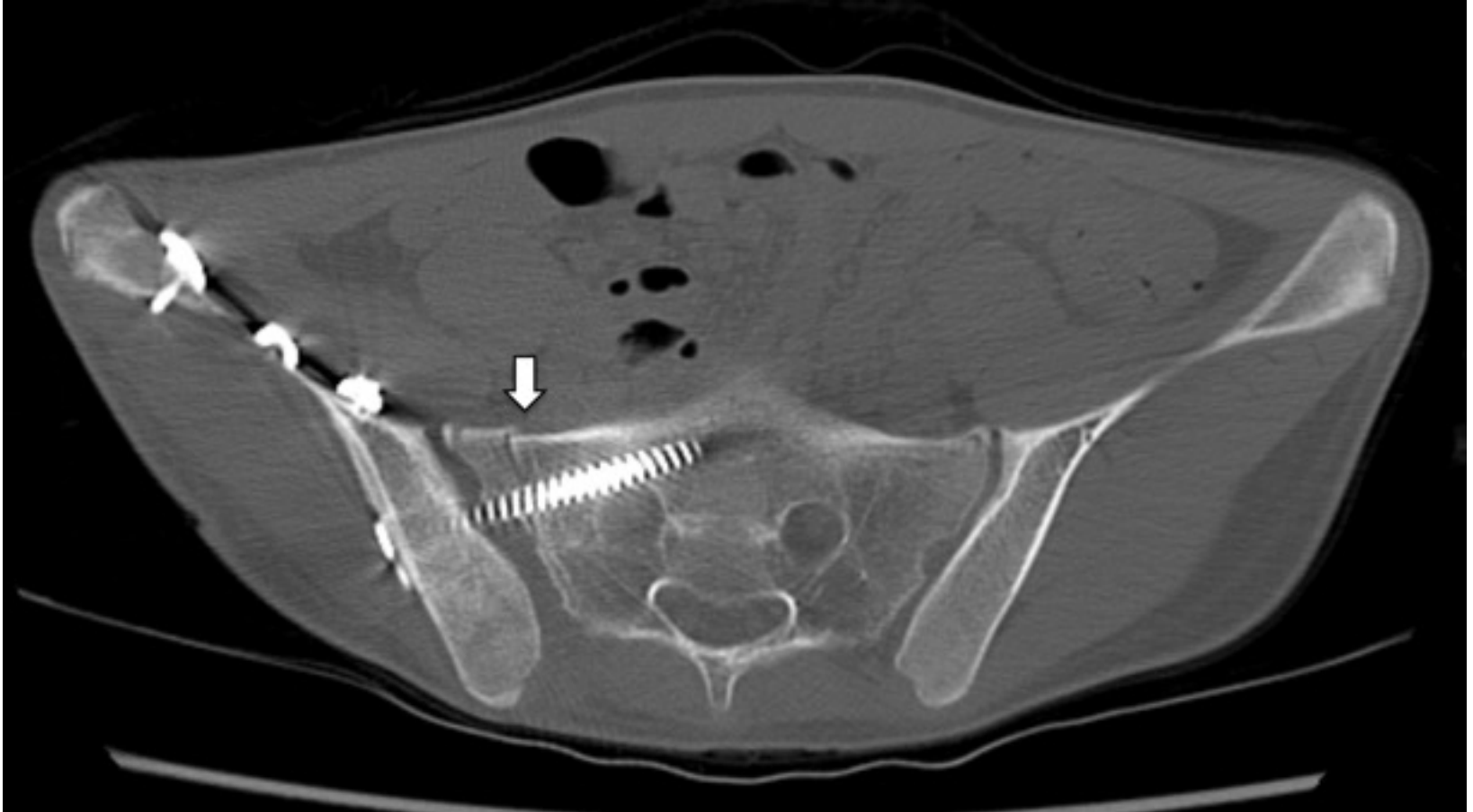


Figure 1e

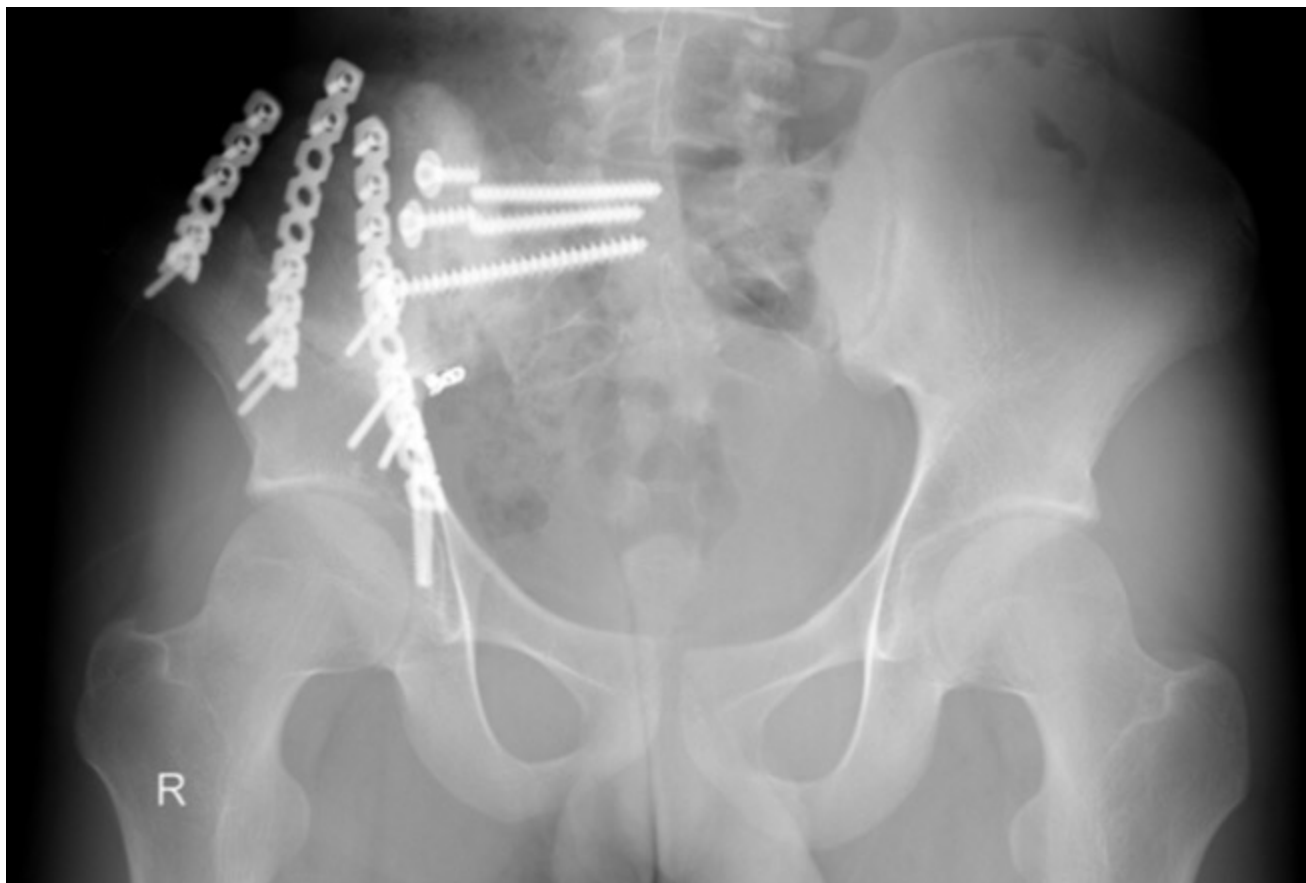

Figure1f

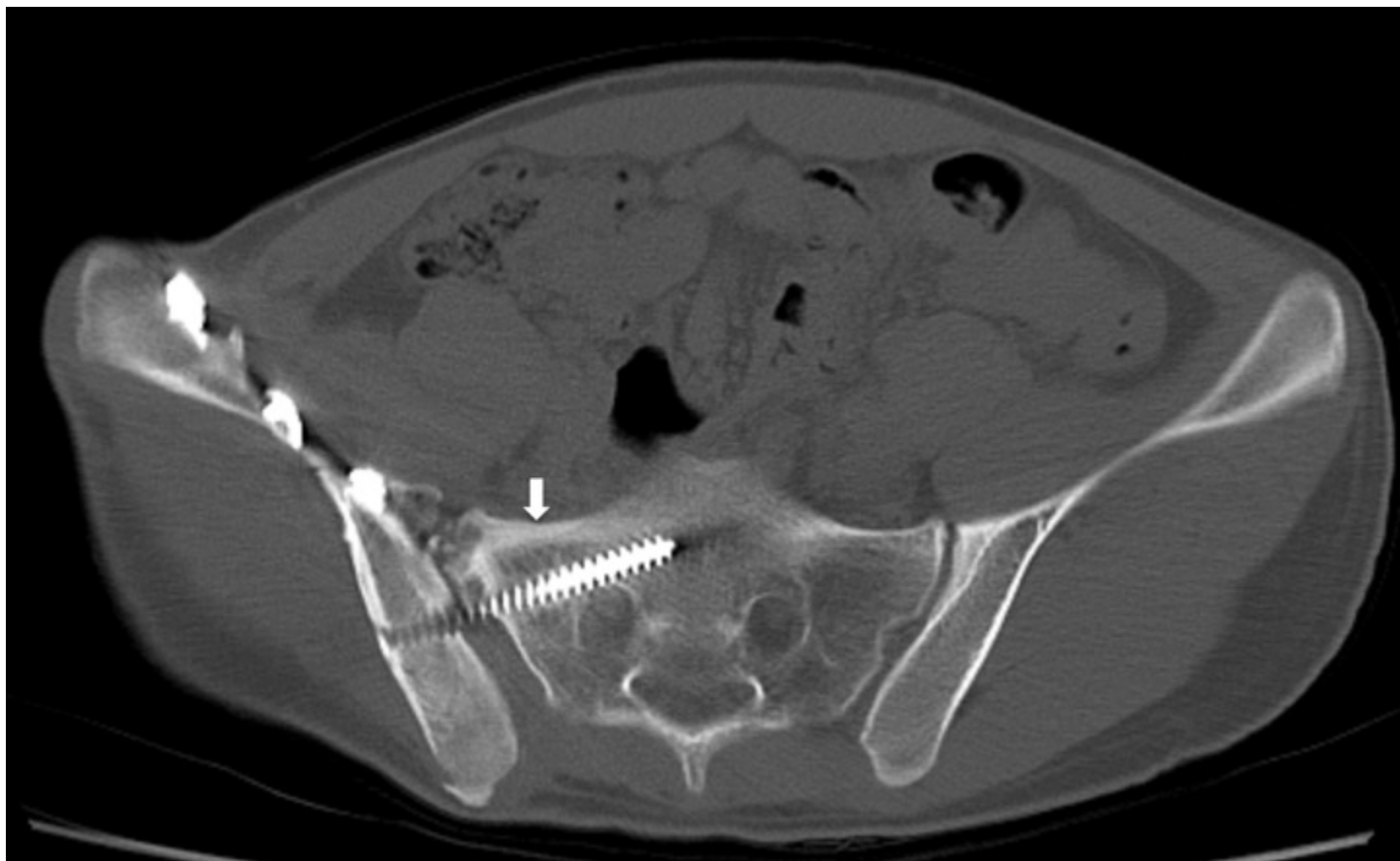
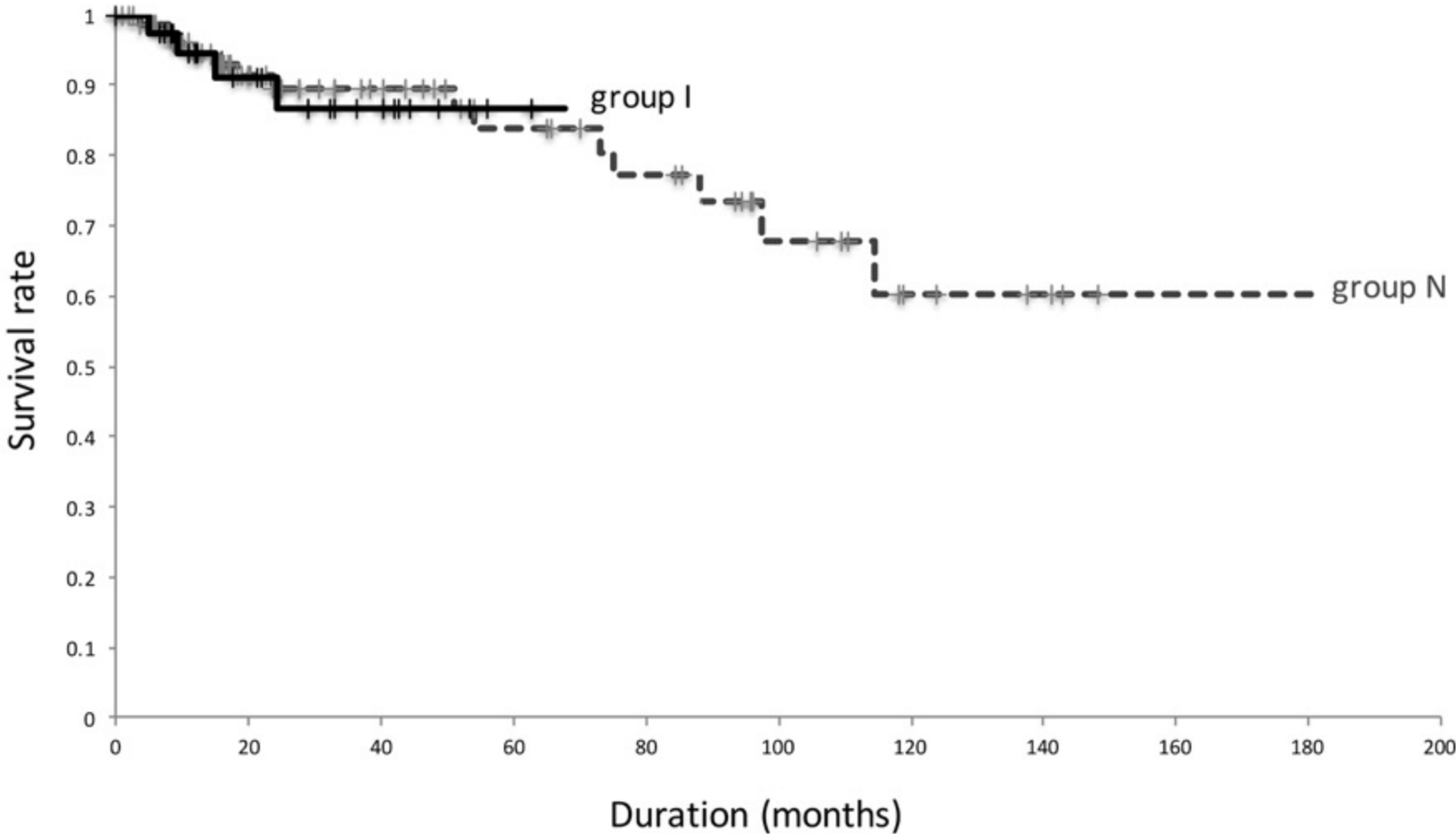


Figure1g



Figure 2





**Table 1**

Variables	Non-coating	Coating	p-value
Infection			.032
yes	11	1	
no	52	37	
Fracture			.247
yes	11	4	
no	51	34	
Recurrence			.351
yes	6	2	
no	56	36	
Bone absorption			.368
yes	4	1	
no	58	37	
MSTS			
score	85.2 %	92.8 %	.123

**Table 2**

References	Type of reconstruction	Recycled bone survival		Complication rate	Infection rate	Fracture rate	Bone absorption rate	MSTS score
		5-year	10-year					
Biau et al <sup>17)</sup>	Allograft	68 %	33 %	73 %	23 %	27 %	23 %	90 %
Kim et al <sup>18)</sup>	Irradiated autograft	NA	43 %	87 %	22 %	9 %	NA	62.6 %
Jeon et al <sup>19)</sup>	Pasteurized autograft	77 %	NA	38 %	23 %	0 %	8 %	78.7 %
Paholpak et al <sup>20)</sup>	Frozen autograft	NA	NA	42 %	25 %	8 %	8 %	79.2 %
Current series	Group N	80.7%	57.4 %	50.0%	16.1 %	17.7 %	6.5 %	85.2 %
	Group I	86.7 %	NA	21.1 %	2.6 %	10.5 %	2.6 %	92.8 %

NA, not assessed