

Erratum: Novel method for quantitative evaluation of cardiac amyloidosis using ^{201}Tl and $^{99\text{m}}\text{Tc}$ -PYP SPECT (Annals of Nuclear Medicine (2012) DOI: 10.1007/s12149-012-0627-y)

| | |
|------------------------------|-------------------------------------------------------------------------------------------------------------------------------------------------------------------------------------------------------------|
| 著者 | Yamamoto Yasushi, Onoguchi Masahisa, Haramoto Masuo, Kodani Nobuhiro, Komatsu Akio, Kitagaki Hajime, Tanabe Kazuaki |
| journal or publication title | Erratum: Novel method for quantitative evaluation of cardiac amyloidosis using ^{201}Tl and $^{99\text{m}}\text{Tc}$ -PYP SPECT (Annals of Nuclear Medicine (2012) DOI: 10.1007/s12149-012-0627-y) |
| volume | 26 |
| number | 9 |
| page range | 769 |
| year | 2012-11-01 |
| URL | http://hdl.handle.net/2297/33428 |

doi: 10.1007/s12149-012-0650-z

Novel quantitative cardiac amyloidosis evaluation method

Novel method for quantitative evaluation of cardiac amyloidosis using $^{201}\text{TlCl}$ and $^{99\text{m}}\text{Tc-PYP}$ SPECT

Short title: Novel quantitative cardiac amyloidosis evaluation method · Yamamoto *et al.*

Yasushi Yamamoto^{1),2)}, Masahisa Onoguchi²⁾, Masuo Haramoto¹⁾, Nobuhiro Kodani⁴⁾, Akio Komatsu¹⁾, Hajime Kitagaki³⁾, Kazuaki Tanabe⁴⁾

- 1) Department of Radiology, Shimane University Hospital
- 2) Department of Health Science, Graduate School of Medical Science, Kanazawa University
- 3) Department of Radiology, Faculty of Medicine, Shimane University
- 4) 4th Department of Internal Medicine, Shimane University Faculty of Medicine

Corresponding author

Masahisa Onoguchi

Department of Health Sciences, Graduate School of Medical Sciences, Kanazawa University, Kodatsuno 5-11-80, Kanazawa, Ishikawa 920-0942, Japan

E-mail: onoguchi@kenroku.kanazawa-u.ac.jp

Phone & Fax: +81 76 265 2526

Author

Yasushi Yamamoto

Department of Radiology, Shimane University Hospital

89-1 Enya-cho, Izumo, Shimane, Japan.

E-mail: yasushi@med.shimane-u.ac.jp

Phone : +81 853 20 2438

Fax : +81 853 20 2438

Masuo Haramoto,

Shimane University Hospital

89-1 Enya-cho, Izumo, Shimane, Japan.

E-mail: haramoto@med.shimane-u.ac.jp

Nobuhiro Kodani,

Shimane University Hospital

89-1 Enya-cho, Izumo, Shimane, Japan.

E-mail: nobkod@med.shimane-u.ac.jp

Akio Komatsu,

Novel quantitative cardiac amyloidosis evaluation method

Shimane University Hospital
89-1 Enya-cho, Izumo, Shimane, Japan.
E-mail: komatsu@med.shimane-u.ac.jp

Hajime Kitagaki,
Shimane University Hospital
89-1 Enya-cho, Izumo, Shimane, Japan.
E-mail: kitagaki@med.shimane-u.ac.jp

Kazuaki Tanabe
Shimane University Hospital
89-1 Enya-cho, Izumo, Shimane, Japan.
E-mail: kaz@med.shimane-u.ac.jp

Abstract

Objective: The degree of myocardial technetium-^{99m}-pyrophosphate (^{99m}Tc-PYP) accumulation in cardiac amyloidosis is conventionally evaluated by PYP score. This method involves qualitative visual evaluation on two-dimensional images. Here, we performed three-dimensional quantitative analysis using software developed in our laboratory. **Methods:** We performed dual myocardial imaging using thallium-²⁰¹-chloride (²⁰¹Tl-Cl) and ^{99m}Tc-PYP in cases of suspected cardiac amyloidosis and calculated the PYP accumulation rates of all myocardial pixels showing ^{99m}Tc-PYP accumulation. We defined this procedure as quantitative evaluation of the degree of ^{99m}Tc-PYP accumulation in the myocardium. Patients were divided into two groups with and without a diagnosis of cardiac amyloidosis, and we examined the PYP accumulation rates in both groups. In addition, we examined the PYP scores of the two

Novel quantitative cardiac amyloidosis evaluation method

groups by conventional qualitative evaluation. **Results:** The PYP scores of the cardiac amyloidosis group were significantly higher than those of the other group. The PYP accumulation rates of the cardiac amyloidosis group were significantly higher than those of the other group. There was a significant difference in the PYP accumulation rate and PYP score between the two groups. There was considered to be the threshold between two groups in the case of PYP accumulation rate. **Conclusions:** When the threshold of the PYP score was defined as 3+ and that of the PYP accumulation rate was defined as 41.5%, the sensitivity of the PYP score and PYP accumulation rate was 84.6%. However, the specificity of the PYP accumulation rate was higher than that of the PYP score. Quantitative evaluation by PYP accumulation rate of the degree of ^{99m}Tc -PYP accumulation in the myocardium may be useful in the diagnosis of cardiac amyloidosis.

Keywords: cardiac amyloidosis, PYP scores, ^{99m}Tc -PYP, dual myocardial imaging

1. Introduction

Amyloidosis is caused by the deposition of amyloid, an insoluble protein with a fibrous structure, in the organs. Amyloidosis is classified as either systemic amyloidosis in which amyloid is deposited in many organs throughout the whole body and localized amyloidosis in which amyloid shows localized deposition within one organ. Furthermore, amyloidosis is classified into various clinical types corresponding to the type of amyloid protein (amyloid precursor protein). The diagnosis of amyloidosis depends on vital histological examination, such as biopsy. Although the biopsy site varies according to the clinical form, the primary sites are the gastric mucosa, duodenal mucous membrane, skin, subcutaneous fat at the abdominal wall and kidney.[1].

In systemic amyloidosis, primary or myeloma merger AL amyloidosis (AL amyloidosis), familial amyloid polyneuropathy (FAP) I, II, and senile systemic amyloidosis (SSA) cause amyloid deposition in the heart and may cause cardiac symptoms (e.g. congestive heart failure, arrhythmia) [2-3]. However, it is rare for patients with secondary/responsive AA amyloidosis (AA amyloidosis) to suffer from serious cardiac symptoms because such cases show small amounts of amyloid deposition in the heart, which is often limited around blood vessels [4].

The cardiac symptoms caused by amyloid deposition in the heart are known as cardiac amyloidosis. The diagnosis of cardiac amyloidosis depends on the myocardial biopsy. The presence or absence of cardiac amyloidosis affects the decision regarding treatment strategy for systemic amyloidosis and is extremely important for prognosis. Therefore, a precise diagnosis of cardiac amyloidosis is essential [5]. It is important to

Novel quantitative cardiac amyloidosis evaluation method

consider cardiac amyloidosis in patients with suspected amyloidosis based on their symptoms.

Diffuse technetium-^{99m}-pyrophosphate (^{99m}Tc-PYP) accumulation in the heart in cardiac amyloidosis [2-9,13-14] is mentioned as the diagnostic reference for familial amyloid polyneuropathy (FAP) and is described as a supplemental diagnostic method for senile systemic amyloidosis (SSA) in the Guidelines for the Diagnosis of Amyloidosis 2011 [1]. In planar images, the degree of ^{99m}Tc-PYP accumulation in the myocardium (myocardial accumulation rate) is screened visually, and is judged as the PYP score with five phases of classification according to Falk *et al.* [8-9]. However, evaluation based on the PYP score is difficult because ^{99m}Tc-PYP accumulates at the ribs and calcified costal cartilage and is carried by the systemic circulation. Also, there has been no quantitative report on ^{99m}Tc-PYP myocardial SPECT images although there are qualitative reports on ones such as diffuse ^{99m}Tc-PYP accumulation or moderate ^{99m}Tc-PYP accumulation. [6-7,13]

2. Objectives

The degree of myocardial technetium-^{99m}-pyrophosphate (^{99m}Tc-PYP) accumulation in cardiac amyloidosis is conventionally evaluated by the PYP score. This method involves qualitative visual evaluation on two-dimensional images. Here, we performed three-dimensional quantitative analysis using software developed in our laboratory.

This study received the approval of the ethics committee of Shimane University School of Medicine.

3. Materials and methods

3-1) Study population

Fifty patients (average age \pm SD: 72 ± 11 , men 27, women 23) with heart failure accompanied by left ventricular hypertrophy due to suspected cardiac amyloidosis underwent biopsy, echocardiography and dual myocardial imaging using thallium-²⁰¹-chloride (²⁰¹Tl-Cl) and ^{99m}Tc-PYP in our hospital between September 2007 and May 2011. Patients were excluded from study if they suffered from ischemic heart disease or heart valve disease. Serum BNP (brain natriuretic peptide) was measured in all study subjects.

3-2) Testing protocol and equipment

The testing protocol was as follows: ^{99m}Tc-PYP (740 MBq) was administered to the subjects by IV infusion. Two hours later, ²⁰¹Tl-Cl (74 MBq) was administered to the subjects by IV infusion. Twenty minutes later, myocardial SPECT images and front planar images were acquired with a dual-isotope acquisition method using a SPECT camera (PRISM IRIX, Philips Healthcare) and the following acquisition settings: collimator: low-energy, high resolution; matrix planar: 256×256 ; SPECT: 64×64 ; condition planar: zoom 1.48, 2 min; SPECT: zoom 1.6, 30 s/step, 5° step 360°; energy: 74 keV \pm 10% for ²⁰¹TlCl, 140 keV \pm 7.5% for ^{99m}Tc-PYP; image processing device: Odyssey_FX. We reconfigured images in batch mode to allow acquisition of ²⁰¹TlCl and ^{99m}Tc-PYP images without a position gap. The filtered back projection method was

Novel quantitative cardiac amyloidosis evaluation method

used for image reconstruction, with a Butterworth preprocessing filter, ramp post-processing filter, and a voxel size of 2.7×2.7 mm. We did not perform crosstalk or scatter correction. Reconstructed images were transferred to a personal computer and analyzed using DRIP (Daemon Research Image Processor; Fuji Film Pharma) and SPECT_HertBlood (SPECT_HB) software developed in our laboratory.

3-3) Evaluation of the degree of ^{99m}Tc -PYP accumulation in the myocardium by PYP score

We evaluated the PYP score by five phases in the planar images of ^{99m}Tc -PYP according to the classification of Falk *et al.* as follows: 0: negative (no accumulation); 1+: slight ^{99m}Tc -PYP accumulation compared with background; 2+: less ^{99m}Tc -PYP accumulation in the myocardium than in the ribs; 3+: more ^{99m}Tc -PYP accumulation in the myocardium than in the ribs but less than in the sternum; 4+: ^{99m}Tc -PYP accumulation in the myocardium equivalent or greater than that in the sternum. A circulatory organ specialist with experience in diagnostic imaging, such as nuclear cardiology and cardiac computed tomography (CT) evaluated the degree of ^{99m}Tc -PYP accumulation by monitor diagnosis. Prior to evaluation and analysis, patients were divided into a group diagnosed with cardiac amyloidosis by biopsy (Direct Fast Scarlet stain, potassium permanganate test, polariscopy, immunostaining) and ultrasonography[1] and another group which was not diagnosed with cardiac amyloidosis. We defined the former as the cardiac amyloidosis group and the latter as the other group. The statistical method appropriate to the data of the two groups was used to examine the 5% of hazard ratios for determining the significance of the

Novel quantitative cardiac amyloidosis evaluation method

differences in PYP scores between the two groups. The diagnosis of cardiac amyloidosis by ultrasonography depends on whether there is cardiac hypertrophy, if the left ventricular wall and interventricular septum are hypertrophied by more than 12 mm, or there is a granular sparkling appearance, hyperechoic spot or Left ventricle ejection fraction (LVEF). In addition, when a case was not diagnosed as cardiac amyloidosis, we did not judge the case to be cardiac amyloidosis even though amyloid was identified by biopsy.

3-4) Evaluation of the degree of ^{99m}Tc -PYP accumulation in the myocardium by PYP accumulation rate

Figure 1 shows the procedure used for quantitative evaluation. We extracted the left ventricular and myocardial region from the ^{201}Tl -Cl SPECT short axis images using DRIP and then made an image mask. We set the threshold manually from the mask image using SPECT_HB and made a binarized image, and then identified the ventricular cavity and myocardium. We applied the identified three-dimensional region to the ^{99m}Tc -PYP SPECT short axis images. When the myocardial count was 0.93 or more times higher than the ventricular cavity mean count in the ^{99m}Tc -PYP SPECT short axis image, we identified ^{99m}Tc -PYP accumulation in the myocardium and then calculated the pixels. We calculated the rate of myocardial pixels judged for ^{99m}Tc -PYP to accumulate for total pixel number in the myocardium and the PYP accumulation rate. This procedure represented a quantitative evaluation of the degree of ^{99m}Tc -PYP accumulation in the myocardium. We divided the subjects into the cardiac amyloidosis group and the other group, and examined the degree of ^{99m}Tc -PYP accumulation in the

Novel quantitative cardiac amyloidosis evaluation method

myocardium as well as the PYP score in both groups. The method suitable for the data of the two groups was used to examine the 5% hazard ratios to determine the significance of the differences in PYP accumulation rate between the two groups. A specialist in nuclear medicine analyzed the degree of ^{99m}Tc -PYP accumulation in the myocardium by SPECT_HB in the presence of the circulatory organ specialist who performed the PYP score analysis. In addition, we identified ^{99m}Tc -PYP accumulation when the myocardial count was 0.93 or more times higher than the mean count in the ventricular cavity, as will be described in the next section.

3-5) Rationale for identification of ^{99m}Tc -PYP accumulation when myocardial count is 0.93 or more times higher than the mean count in the ventricular cavity

When we identified ^{99m}Tc -PYP accumulation in the myocardium, we calculated the ratio of the myocardial mean count to the ventricular cavity mean count (the PYP count ratio) in 50 patients. The average \pm SD of the PYP count ratio in the cardiac amyloidosis group was 1.28 ± 0.31 , while that of the other group was 0.795 ± 0.066 (Fig. 2). The PYP count ratio in the cardiac amyloidosis group and the other group showed a normal distribution and the population variance was unequal in both groups (F-test). Therefore, using Welch's t test, we examined the 5% hazard ratios to determine whether the population means of the two independent groups were significantly different. The results indicated a significant difference between the two groups ($P < 0.05$), with the PYP count ratio in the cardiac amyloidosis group being greater than that of the other group. Therefore, the threshold of the PYP count ratio between the two groups was 0.93 ($0.795 + 2 \times 0.066$); the value 0.93 included approximately 95% of the normal group,

Novel quantitative cardiac amyloidosis evaluation method

0.795 was the average PYP count ratio of the other group, and 0.066 was the SD. Therefore, we identified ^{99m}Tc -PYP accumulation in the myocardium when the myocardial count was 0.93 or more times higher than the ventricular cavity mean count.

3-6) Calculating the odds ratio

We determined the positive/negative threshold, the threshold of the PYP score and the PYP accumulation rate between the cardiac amyloidosis group and the other group. We then made a 2×2 contingency table and calculated the positive odds ratio in the cardiac amyloidosis group and the negative odds ratio in the other group.

4. Results

4-1) Clinical findings of the cardiac amyloidosis group and the other group

Table 1 shows the clinical evidence of 13 cases of the cardiac amyloidosis group and 5 cases of other groups. Of the 50 patients, 13 were diagnosed as having cardiac amyloidosis consisting of one case of AL amyloidosis, three of familial amyloid polyneuropathy, eight of senile systemic amyloidosis, and one of AA amyloidosis. The other group consisted of 37 cases. Three patients in the other group (Case 15-17) had AA amyloidosis and one patient (Case 14) had AL amyloidosis, but which was not a morbid condition of a cardiac amyloidosis. We listed Case 14-17 in Table 1. This is because these cases were diagnosed as amyloidoses although these cases belong to the other group. In addition, we listed Case 18 in Table 1. This is because PYP score of

Novel quantitative cardiac amyloidosis evaluation method

Case 18 is bigger than that of the other cases which belong to the other group. Table 2 shows the echocardiographic data and serum BNP. of the cardiac amyloidosis group and the other group.

4-2) PYP scores of the cardiac amyloidosis group and the other group

Figure 3 shows the PYP scores of the cardiac amyloidosis group and the other group. The cardiac amyloidosis group included one case with a PYP score of 1+, one case with a PYP score of 2+, two cases with PYP scores of 3+ and nine cases with scores of 4+ (average \pm SD: 3.4 ± 0.9). In the other group, 23 cases had PYP scores of 0, 1 had a score of 1+, 2 had scores of 2+, and 2 had scores of 3+ (average \pm SD: 0.5 ± 0.8). The Mann–Whitney U test was used to examine the 5% of hazard ratios to determine the significance of the differences in PYP scores between the two groups, because the PYP scores represent discrete data. The PYP scores of the cardiac amyloidosis group were significantly higher than those of the other group ($P < 0.05$).

4-3) The PYP accumulation rates in the cardiac amyloidosis group and the other group

The average \pm SD of the PYP accumulation rates of the cardiac amyloidosis group was $80.8 \pm 28.0\%$, while that of the other group was $19.8 \pm 10.85\%$ (Fig. 4). The Mann–Whitney U test was used to examine the 5% of hazard ratios to determine the significance of the differences in the median of the distribution between the two populations. The results indicated that the PYP accumulation rates in the myocardium were significantly higher in the cardiac amyloidosis group than in the other group ($P <$

0.05).

4-4) Odds ratio

The threshold of the PYP accumulation rate was considered to be the sum of the average degree of ^{99m}Tc -PYP accumulation and double SD, 41.5 (19.8 + 10.85×2) %. According to Falk *et al.*, the threshold of the PYP score was considered to be over 3+. We then made a 2×2 contingency table, which is shown in Table 3. In the cardiac amyloidosis group, the positive odds ratio was 1. This means that the possibility of judging a case to be positive from PYP score is equal to that from the PYP accumulation rate. In contrast, negative odds ratio was 2.05. This means the possibility of judging a case to be negative from the PYP accumulation rate is stronger than that from the PYP score.

5. Discussion

There were 4 cases of AA amyloidosis (Case 9, 15, 16, 17) among the 50 patients. In these cases, the ^{99m}Tc -PYP accumulation in the myocardium was predicted to be smaller than in the cases of the other amyloidosis. However, the PYP accumulation rate of Case 9 was 62.58%. This score was larger than expected. Case 9 shows the morbid condition of cardiac amyloidosis (chronic congestive heart failure) and was considered to be advanced AA amyloidosis accompanied by cardiopathy [1]. Case 15, 16, 17 were not cardiac amyloidosis. However, in the case of AA amyloidosis, it has been reported that there was no ^{99m}Tc -PYP accumulation in the myocardium even though there was amyloid accumulation in the heart and patients presented with symptoms of congestive

Novel quantitative cardiac amyloidosis evaluation method

heart failure [4, 13-14]. It is difficult to detect cardiopathy using ^{99m}Tc -PYP in these cases. Therefore, care is required in the case of AA amyloidosis and Case 15, 16, and 17 should receive careful follow-up. Follow-up by evaluating the PYP accumulation rate is considered to be useful in these cases.

In the cardiac amyloidosis group, Case 12 (39.83%) and Case 13 (10.06%) were determined to be senile systemic amyloidosis. Smirnov–Grubbs testing indicated that the PYP accumulation rate in Case 12 and 13 were outliers and were significantly smaller than those of the other cardiac amyloidosis cases. This means that little amyloid was deposited in the heart. In the cases of senile systemic amyloidosis, patients are considered to suffer from cardiomyopathy even though amyloid deposition in the heart is low. In addition, when we collect more data on the PYP accumulation rates in senile systemic amyloidosis, we may observe a clearer relation between cardiopathy and the degree of ^{99m}Tc -PYP accumulation. This is because the PYP accumulation rate is not discrete data.

In the cardiac amyloidosis group, Case 2 (99.87%), Case 3 (96.11%) and Case 6 (99.66%) were familial amyloid polyneuropathy. Fujii *et al.* have reported that the patients with familial amyloid polyneuropathy showed complete or partial defects in their ^{123}I -metaiodobenzylguanidine (^{123}I -MIBG) myocardial images [7]. We could calculate the rates of ^{123}I -MIBG accumulation in the myocardium of such cases.

In the other group, the PYP accumulation rate of Case 14 was 53.64% (PYP score was 0). Case 14 was diagnosed as multiple myeloma. We supposed that AL amyloidosis complicated with myeloma developed in Case 14 and this patient would have eventually developed cardiac amyloidosis. In addition, Smirnov–Grubbs testing indicated that the PYP accumulation rate in Case 14 was an outlier and was significantly greater than

Novel quantitative cardiac amyloidosis evaluation method

those of the other cases in the other group. In this case, the PYP accumulation rate is considered to be more useful than the PYP score.

We examined the relations of a significantly different heart function index (cf. table 2) in a PYP accumulation rate and cardiac amyloidosis group and other groups. There is weak negative correlation between PYP accumulation rate and LVEF. There is weak negative correlation between PYP accumulation rate and FS. There is weak negative correlation between PYP accumulation rate and DT. There is negative correlation between PYP accumulation rate and A. There is weak positive correlation between PYP accumulation rate and IVSth. There is weak positive correlation between PYP accumulation rate and LV mass index. There is positive correlation between PYP accumulation rate and PWth. There is positive correlation between PYP accumulation rate and E/A.

The sensitivity and specificity of the PYP accumulation rate were 84.6% and 97.3%, respectively and the sensitivity and specificity of the PYP score were 84.6% and 94.5%, respectively (Table 3). The specificity of the PYP accumulation rate was higher than that of the PYP score. Thus, quantitative evaluation by the PYP accumulation rate is considered to be more useful than the PYP score for diagnosis of cardiac amyloidosis. The sensitivity was higher than in previous reports [3-5, 8-9]. This is because in our study group of 50 patients, there were many senile systemic amyloidosis whose PYP accumulation rate is considered to be high [1], and few cases of AA amyloidosis and AL amyloidosis.

Figure 6 shows Case 9 and Case 18. The PYP score of Case 9 and that of Case 18 were 3+. Case 9 belongs to the cardiac amyloidosis group (AA amyloidosis) and had an

Novel quantitative cardiac amyloidosis evaluation method

accumulation rate of 62.59%. Case 18 belongs to the other group and had a PYP accumulation rate of 13.15%. When we compared $^{201}\text{Tl}\text{-Cl}$ myocardial SPECT images with $^{99\text{m}}\text{Tc}\text{-PYP}$ myocardial SPECT images, we found that $^{99\text{m}}\text{Tc}\text{-PYP}$ accumulated in the myocardium in Case 9 and $^{99\text{m}}\text{Tc}\text{-PYP}$ accumulated in the ventricular cavity in Case 18. It was difficult to diagnose Case 18 from the $^{99\text{m}}\text{Tc}\text{-PYP}$ planar images. Therefore, dual-isotope simultaneous acquisition (SPECT image) is useful in this case. In addition, in this case the PYP accumulation rate, which represents objective continuance data, was considered to be more useful than the PYP score which is a subjective discrete value.

In the $^{201}\text{Tl}\text{-Cl}$ myocardial SPECT images of Case 4, 5, 8 which belong to the cardiac amyloidosis group, $^{201}\text{Tl}\text{-Cl}$ accumulation decreases at the site where $^{99\text{m}}\text{Tc}\text{-PYP}$ strongly accumulates. We showed $^{99\text{m}}\text{Tc}\text{-PYP}$ myocardium images and $^{201}\text{Tl}\text{-Cl}$ myocardium images of case 5 in Figure 7. In the $^{201}\text{Tl}\text{-Cl}$ myocardial SPECT images of the other cases, decreases in $^{201}\text{Tl}\text{-Cl}$ accumulation were not apparent. This finding has also been reported [6-7, 13-14] and indicates that there may be degeneration and sloughing off of cardiac muscle cells because of amyloid deposition, as suggested by Imamoto *et al.* [6]. This finding could not be acquired only by $^{99\text{m}}\text{Tc}\text{-PYP}$ planar images. Thus, dual-isotope simultaneous acquisition (SPECT image) is considered to be useful in identifying this situation.

As shown in Figure 8, analyses of all 50 cases revealed a positive correlation between the PYP score and the PYP accumulation rate by the Spearman correlation coefficient by rank test (correlation coefficient = 0.69). The PYP score is discrete data and the PYP accumulation rate does not show a normal distribution. The PYP accumulation rate is

Novel quantitative cardiac amyloidosis evaluation method

related to the PYP score and is considered to be a useful new method for evaluation of the degree of ^{99m}Tc -PYP accumulation in the myocardium.

We acquired images of 29 patients at 2 hours 20 minutes after (First) and 5 hours or more after (Second) the administration of ^{99m}Tc -PYP. Then, we calculated the PYP count ratios of the First and Second acquisitions. The PYP count ratio of the First acquisition was 0.82 ± 0.18 and that of the Second acquisition was 0.84 ± 0.16 . The Wilcoxon signed-ranks test was used to examine the 5% of hazard ratios to determine the significance of the differences in the median of the 2 groups. This is because the data of the 2 groups do not show a normal distribution. The results indicated that there was a significant difference ($P = 0.04 < 0.05$). Therefore, when the time from administration of ^{99m}Tc -PYP to image pickup is different, the threshold is considered to be different. In addition, the threshold is considered to depend on the equipment, the image acquisition parameters and the image reconstruction parameters. These problems must be examined in future.

We collect cardiac amyloidosis cases and want to do more detailed examination.

6. Conclusions

We performed dual myocardial imaging using ^{201}Tl -Cl and ^{99m}Tc -PYP in cases of suspected cardiac amyloidosis and performed a quantitative evaluation of the degree of ^{99m}Tc -PYP accumulation in the myocardium. There was a significant difference in the PYP accumulation rate in the myocardium between the cardiac amyloidosis group and the other group. Therefore, we supposed that there was a threshold between the

Novel quantitative cardiac amyloidosis evaluation method

two groups, and quantitative evaluation of the degree of ^{99m}Tc -PYP accumulation in the myocardium using the PYP accumulation rate may be useful for the diagnosis of cardiac amyloidosis.

References

- 1) Yamada M , Ikeda S, Higuchi K, Tamaoka A, Takaichi K, Toshiyuki Y, et al. The guideline for the medical care of an amyloidosis ver. 2010. A Ministry of Health, Labour and Welfare research group report. 2010. <http://amyloid1.umin.ne.jp/guideline2010.pdf>.
- 2) Tanaka J, Sawayama T, Hasegawa K. A symptomatography of organopathy and diagnostic procedure to be found in a generalized amyloidosis. *Nihon Rinsho* 1991; 49(4): 841-6.
- 3) Hongo M, Misawa T, Yamada H, Hirayama J, Okubo S, Fujii T, et al. Diagnostic significance of Technetium- 99m -pyrophosphate, technetium- 99m -methylene diphosphonate and gallium-67-citrate scintigraphy in amyloid heart disease a study with AL amyloidosis and familial amyloid polyneuropathy. *Nihon Naika Gakkai Zasshi*. 1986;75(1):1-8.
- 4) Nagatomo Y, Ikushima I, Matsuyama A, Nakagawa S, Koiwaya Y, Kenjiro T. Cardiac manifestations in patient with systemic amyloidosis. *Shinzou*. 1987;19(3):277-85.
- 5) Hongo M, Yamada H, Okubo S, Hirayama J, Fujii T, Kusama S, et al. Cardiac involvement in systemic amyloidosis: myocardial scintigraphic evaluation. *J Cardiogr*. 1985;15(1):163-80.
- 6) Imamoto T, Morita K, Onodera S, Tanazawa S, Amoh K, Ishikawa Y, et al.

Novel quantitative cardiac amyloidosis evaluation method

Technetium-99m-pyrophosphate single photon emission computed tomography of the heart in familial amyloid polyneuropathy: comparison with thallium-201 myocardial scintigraphy--a case report. *Kaku Igaku*. 1988;25(10):1117-23.

7) Fujii T, Tanaka M, Yazaki Y, Kitabayashi H, Koizumi T, Hongou M, et al. Myocardial Scintigraphic Studies with ^{123}I -MIBG, ^{201}Tl and $^{99\text{m}}\text{Tc}$ -PYP in Patients with Cardiac Amyloidosis. *Kaku Igaku*.1997;34(11):1033-38.

8) Falk RH, Lee VW, Rubinow A, Hood WB, Cohen AS. Sensitivity of technetium-99m-pyrophosphate scintigraphy in diagnosing cardiac amyloidosis. *Am J Cardiol*. 1983;51(5):826-30.

9) Falk RH, Lee VW, Rubinow A, Skinner M, Cohen AS. Cardiac technetium-99m pyrophosphate scintigraphy in familial amyloidosis. *Am J Cardiol*. 1984;54(8):1150-1.

10) Yoshida K, Akasaka T, Itou H, Otsuji Y, Koyanagi S, Satomi M, et al. Guidelines for the Clinical Application of Echocardiography(JCS2010). The Japanese Circulation Society. <http://www.j-circ.or.jp/guideline/pdf/JCS2010yoshida.d.pdf>

11) Parkey RW, Bonte FJ, Meyer SL, Atkins JM, Curry GL, Stokely EM, et al. A new method for radionuclide imaging of acute myocardial infarction in humans. *Circulation*. 1974;50(3):540-6.

12) Yamamoto H, Fukuyama N, Aoki M, Inou T, Ashihara T, Nabeyama S, et al. Quantitative of Myocardial Infarct Size by Technetium-99m pyrophosphate Single Photon Emission Computed Tomography. *Kaku Igaku*.1989;26(4):469-76.

13) Takezaki M, Ishida Y, Morozumi R, Tani A, Satou H, Hori M, et al. Noninvasive Diagnosis of Cardiac Involvement by Technetium-99m-Pyrophosphate(Tc-99m PYP) Myocardial Scintigraphy in 2 Case with Familial Amyloid Polyneuropathy and 1Case with Secondary Amyloidosis. *Kaku Igaku*.1989;26(12): 1537-43.

Novel quantitative cardiac amyloidosis evaluation method

- 14) Morozumi R, Hori M, Kamada T, Uehara T, Kusuoka H, Nishimura T, et al. Usefulness of Technetium-99m pyrophosphoric acid Scintigraphy in cardiac amyloidosis diagnosis. Progress in Treatment of Cardiovascular Disease.1995;14(1):28-32.

Novel quantitative cardiac amyloidosis evaluation method

List of Figures

Figure 1

Procedure for quantitative evaluation using SPECT_HB.

We made left ventricular myocardial mask images from $^{201}\text{TlCl}$ images using DRIP. We used a threshold variable and mask images were binarized into the ventricular cavity and myocardium. The mask was applied to the $^{99\text{m}}\text{Tc-PYP}$ images using the coordinates of the myocardium and ventricular cavity. Finally, we quantitatively analyzed the myocardium and ventricular cavity on a voxel-by-voxel basis from the 3D coordinate axis. When the myocardial count was 0.93 or more times higher than the ventricular cavity count, we identified $^{99\text{m}}\text{Tc-PYP}$ accumulation in the myocardium. We calculated the rate of myocardial pixels judged positive for $^{99\text{m}}\text{Tc-PYP}$ as an indicator of accumulation for all myocardial pixels and determined the PYP myocardial accumulation rate.

Figure 2

“ The PYP count ratio “ of the cardiac amyloidosis group and the other group.

The cases are shown on the transverse axis (the cardiac amyloidosis group is shown on the left and the other group is on the right) and the PYP count ratio is shown on the vertical axis.

The PYP count ratio of the cardiac amyloidosis group was significantly higher than that of the other group ($P < 0.05$), and the threshold was 0.93.

Figure 3

PYP scores of the cardiac amyloidosis group and the other group.

Novel quantitative cardiac amyloidosis evaluation method

The cases are shown on the transverse axis (the cardiac amyloidosis group is shown on the left and the other group is on the right) and the PYP scores are shown on the vertical axis.

The PYP scores of the cardiac amyloidosis group were significantly higher than those of the other group ($P < 0.05$).

Figure 4

The PYP accumulation rates of the cardiac amyloidosis group and the other group.

The cases are shown on the transverse axis (the cardiac amyloidosis group is shown on the left and the other group is on the right) and the PYP accumulation rates (%) is shown on the vertical axis.

The PYP accumulation rates of the cardiac amyloidosis group were significantly higher than those of the other group ($P < 0.05$).

Figure 5

Relations of PYP accumulation rate and LVEF

Pearson's product-moment correlation coefficient: $r = -0.36$ ($n = 49$, $P < 0.05$)

There is weak negative correlation between PYP accumulation rate and LVEF.

Figure 6

^{99m}Tc -PYP planar image, ^{99m}Tc -PYP SPECT image, $^{201}\text{TlCl}$ SPECT image and dual isotope image of Case 9 and Case 18.

(a) Case 9 (PYP score is 3+) belongs to the cardiac amyloidosis group. ^{99m}Tc -PYP accumulation in the myocardium shown in the ^{99m}Tc -PYP planar image and ^{99m}Tc -PYP

Novel quantitative cardiac amyloidosis evaluation method

SPECT image is confirmed from the $^{201}\text{Tl-Cl}$ SPECT image and dual isotope image.

(b) Case 18 (PYP score is 3+) belongs to the cardiac amyloidosis group. $^{99\text{m}}\text{Tc-PYP}$ accumulation in the ventricular cavity shown in the $^{99\text{m}}\text{Tc-PYP}$ planar image and $^{99\text{m}}\text{Tc-PYP}$ SPECT image is confirmed from the $^{201}\text{Tl-Cl}$ SPECT image and dual isotope image.

In the dual isotope images, dark gray shows $^{201}\text{Tl-Cl}$ accumulation (1), light gray shows $^{201}\text{Tl-Cl}$ and $^{99\text{m}}\text{Tc-PYP}$ accumulation (2) and intermediate gray shows $^{99\text{m}}\text{Tc-PYP}$ accumulation (3).

Figure 7

$^{99\text{m}}\text{Tc-PYP}$ myocardium images and $^{201}\text{Tl-Cl}$ myocardium images of case 5

$^{99\text{m}}\text{Tc-PYP}$ strongly accumulates in the base side of the posterior wall of a ventricular septum.

$^{201}\text{Tl-Cl}$ weakly accumulates in the domain in which $^{99\text{m}}\text{Tc-PYP}$ strongly accumulates.

Figure 8

PYP accumulation rates and PYP scores of each group

PYP scores from 0 to 4+ are shown on the transverse axis with the corresponding PYP accumulation rates shown on the vertical axis. (\circ , cardiac amyloidosis group; \bullet , the other group).

We calculated the correlation coefficient of the PYP score and PYP accumulation rate ($r^2=0.69$).

Table 1

Novel quantitative cardiac amyloidosis evaluation method

List of cases of the cardiac amyloidosis group and the other group

Clinical form and clinical findings of Cases 1–13 in the cardiac amyloidosis group and Cases 14–18 in the other group

AA: AA amyloidosis (secondary amyloidosis)

AL: AL amyloidosis (primary amyloidosis)

FAP: familial amyloid polyneuropathy

SSA: senile systemic amyloidosis

EF: left ventricular ejection fraction

IVSth: thickness of interventricular septum

PWth: thickness of left ventricular posterior wall

Table 2

Myocardial scintigraphic findings, echocardiographic analysis data and serum BNP levels

LVDd: left ventricular internal dimension in diastole

LVDs: left ventricular internal dimension in systole

FS: fractional shortening

EF (Teichholz method): left ventricular ejection fraction

LVMI (g/m^2): left ventricular mass index

LAD: left atrial dimension

E: peak early diastolic left ventricular filling velocity

A: peak atrial filling velocity

E/A: peak early diastolic left ventricular filling velocity/peak atrial filling velocity ratio

DT: deceleration time

Novel quantitative cardiac amyloidosis evaluation method

IVRT: isovolumetric relaxation time

E/E': the ratio of deceleration time of early diastolic wave to mitral valve ring velocity

BNP: brain natriuretic peptide

Table 3

Odds ratios of PYP score and PYP accumulation rate

In the cardiac amyloidosis group, positive odds ratio was 1. In the other group, negative odds ratio was 2.05.

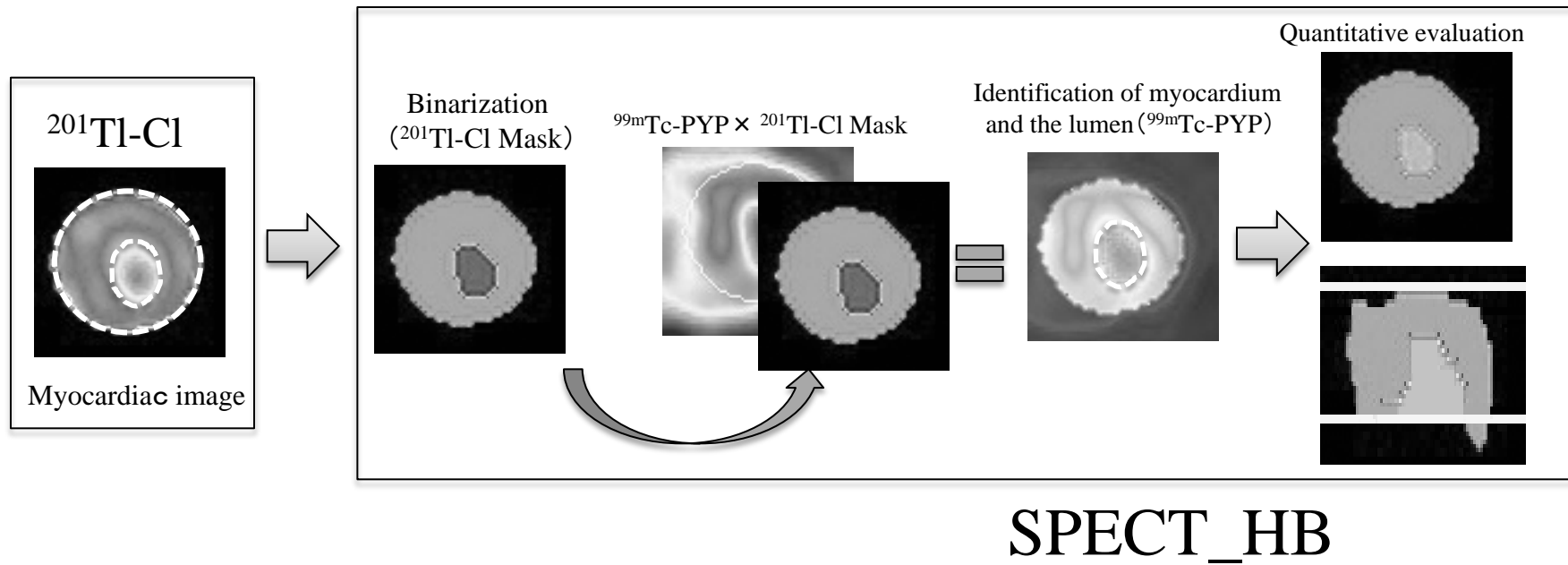


Fig.1

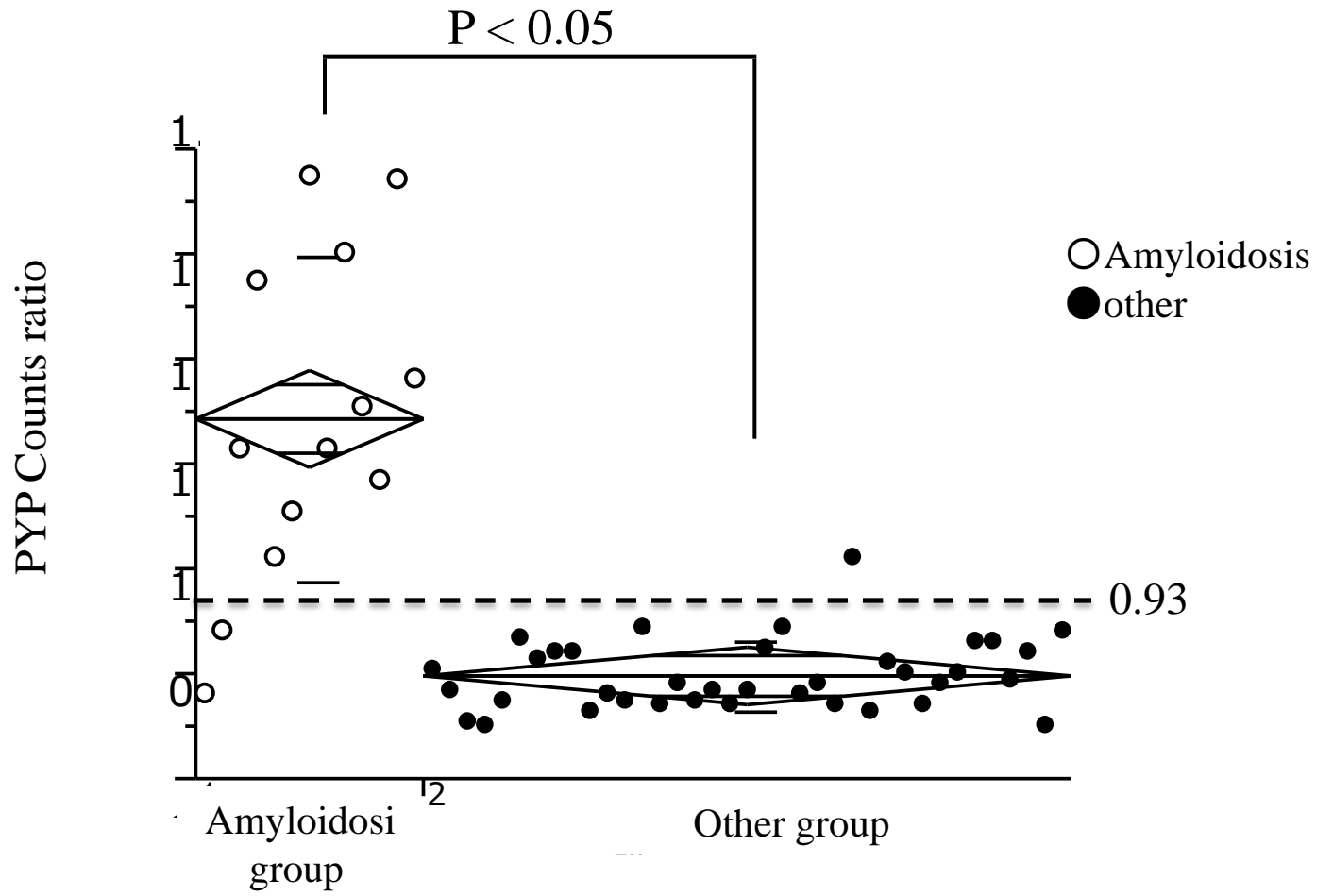


Fig.2

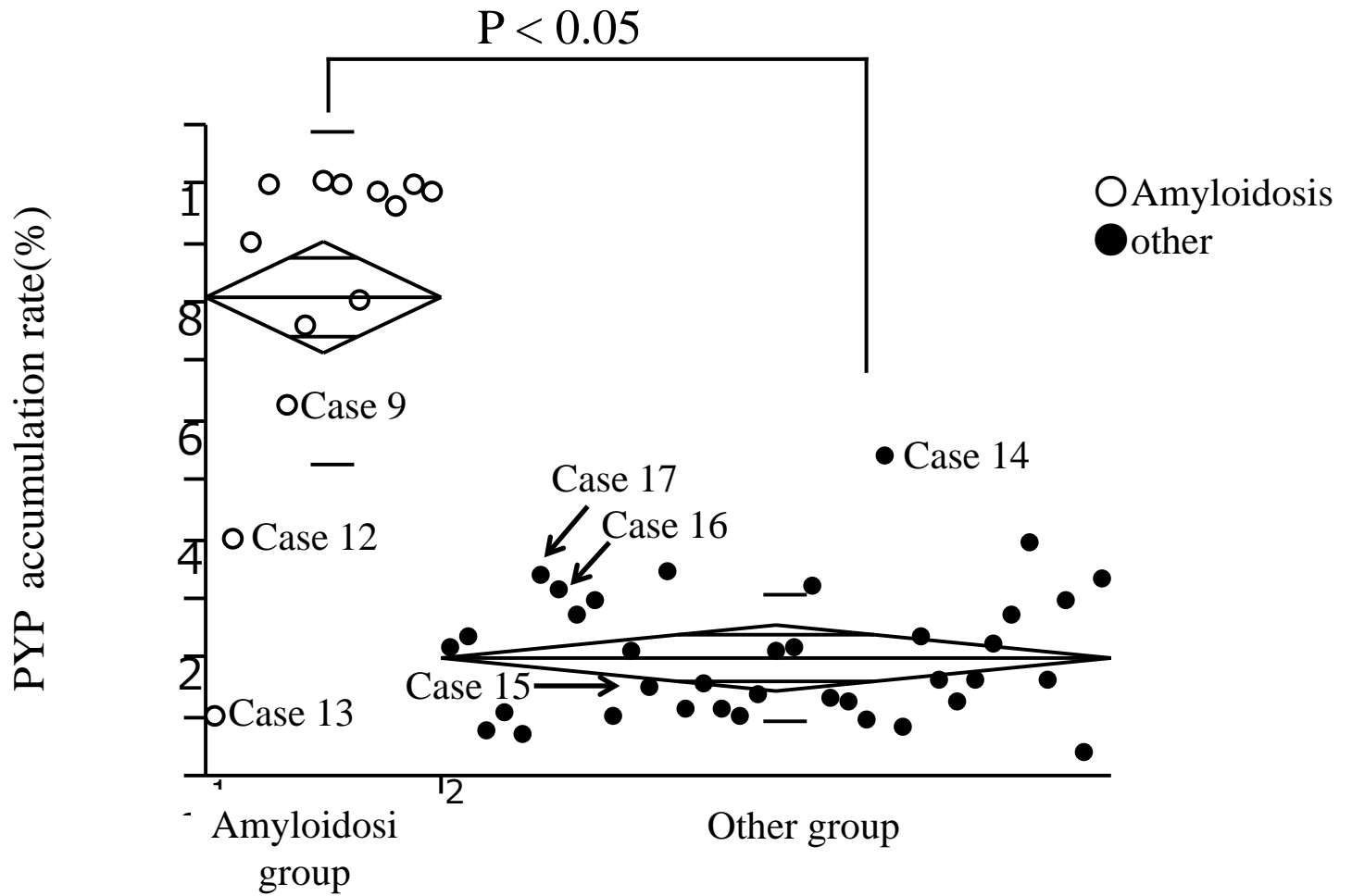


Fig.4

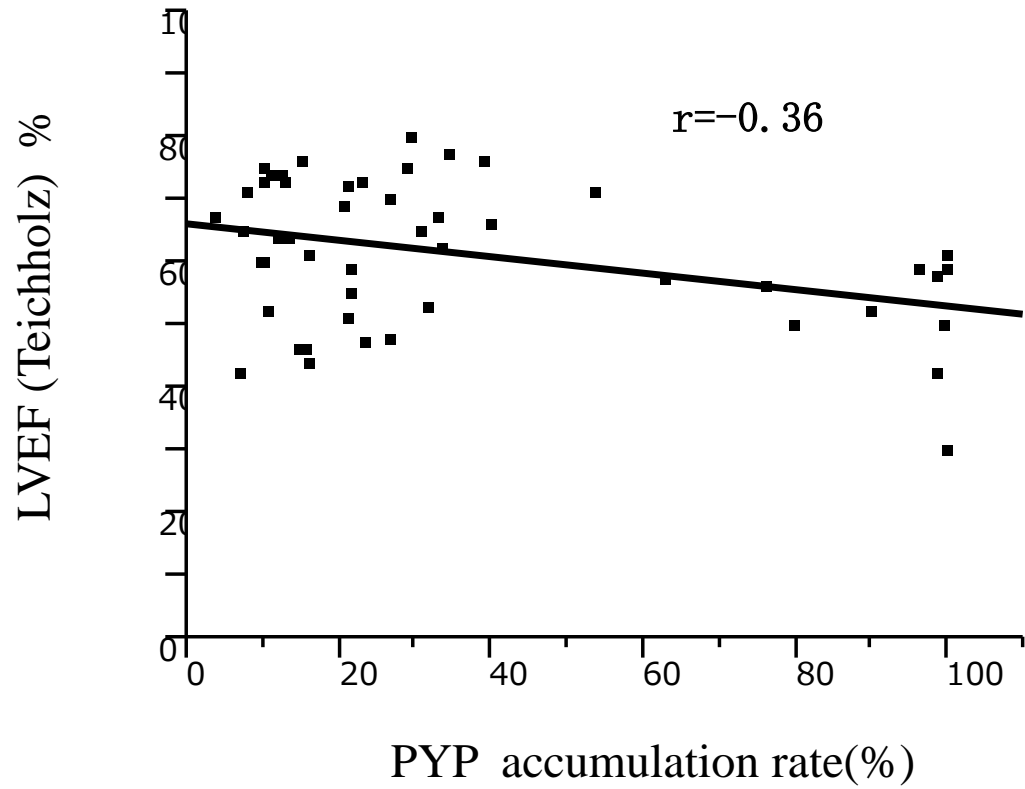


Fig.5

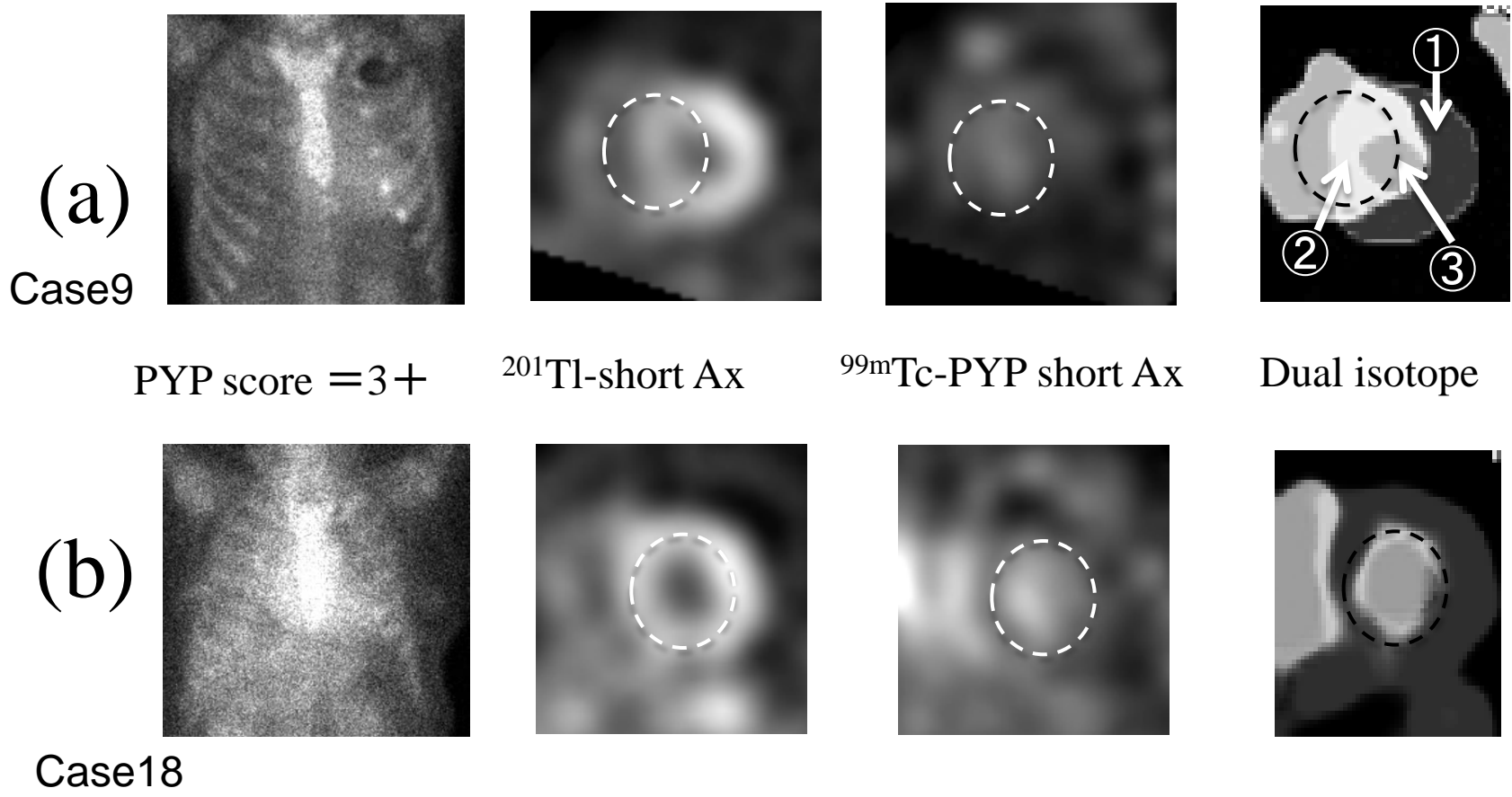


Fig.6

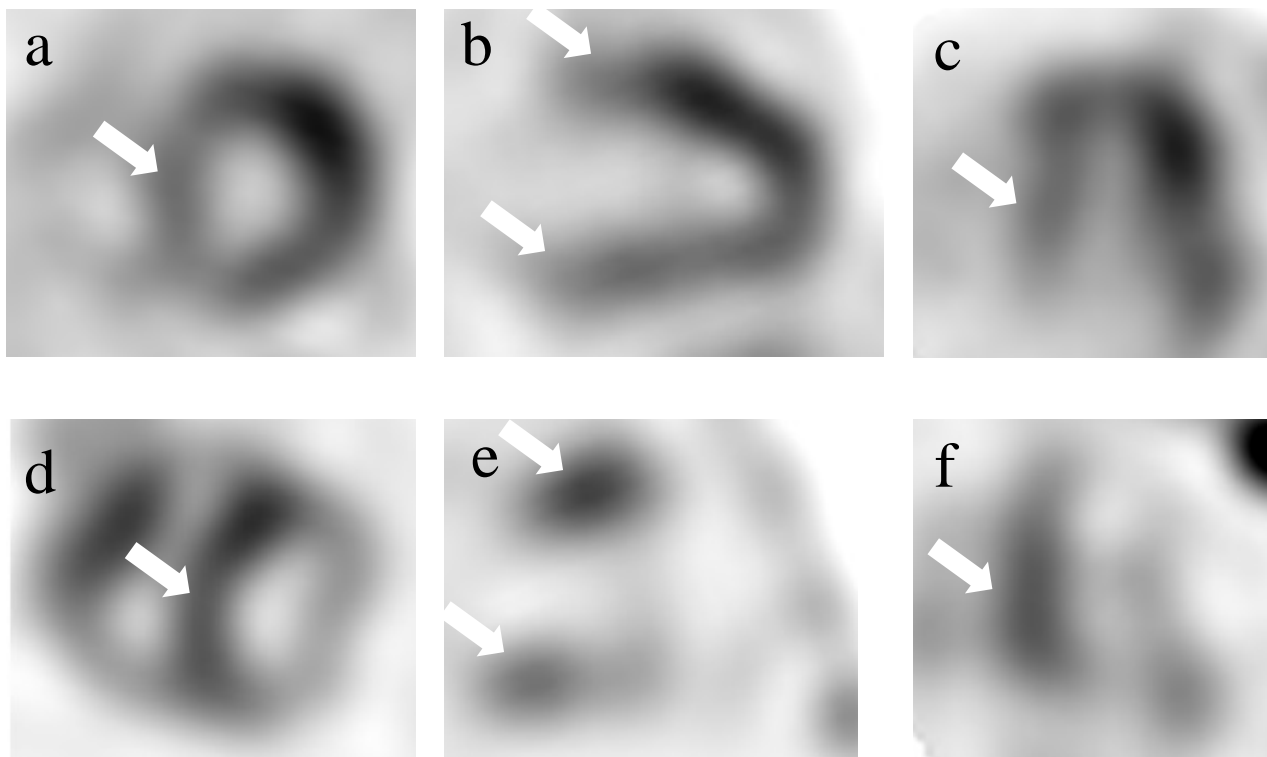


Fig.7

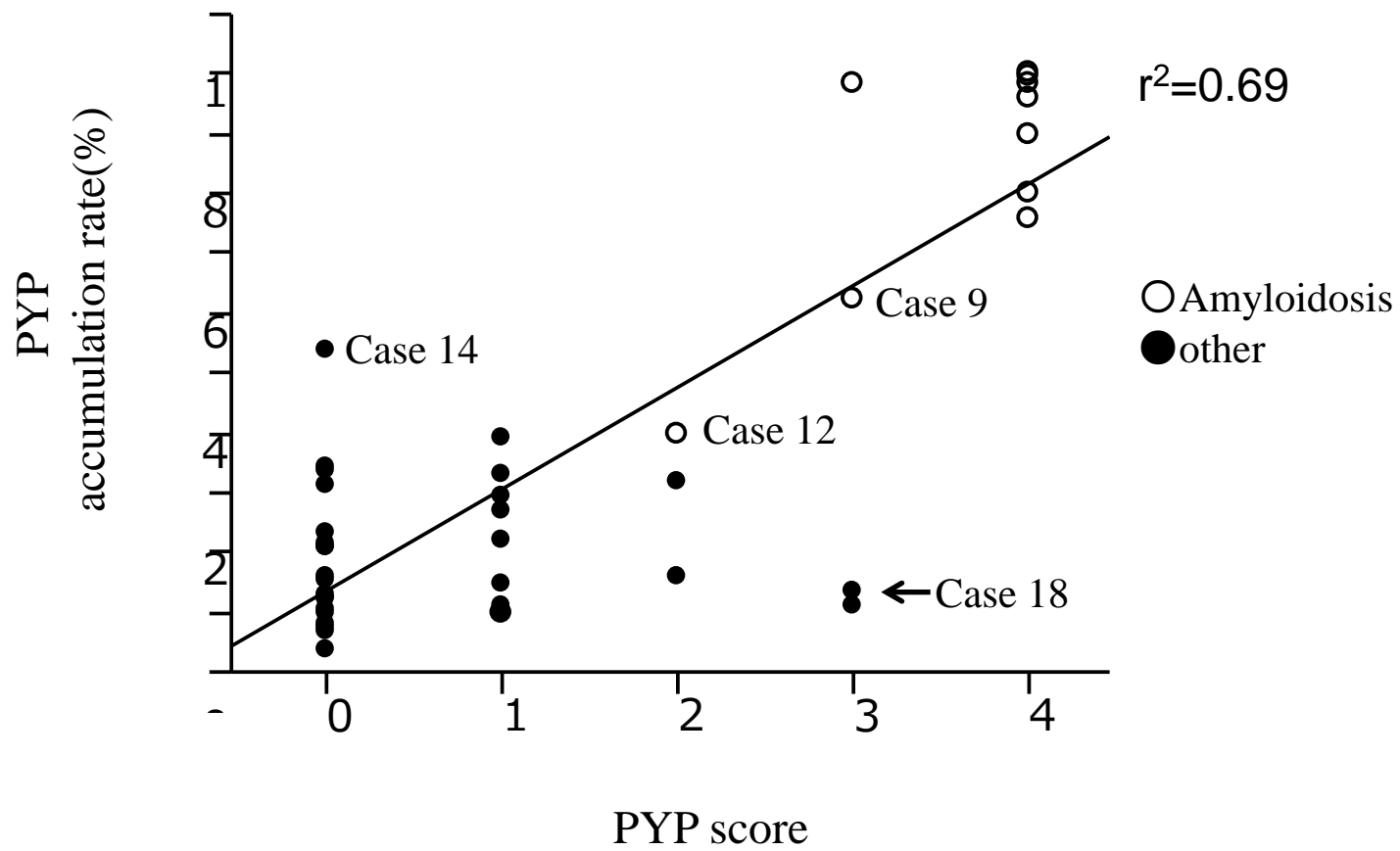


Fig.8

| Case | Age(yr) & Sex | Clinical findings | biopsy site | ^{99m} Tc-PYP uptake | | Echocardiogram | | |
|------|------------------|----------------------|--------------------------------------------|-----------------------------------------|-----------|----------------|---------------|-----------|
| | | | | PYP myocardial accumulation rate (%) | PYP score | EF(%) | IVSth (mm) | PWth (mm) |
| 1 | 46M | AL | duodenum | 98.42 | 3+ | 42 | 13 | 13 |
| 2 | 56F | FAP | myocardium | 99.87 | 4+ | 30 | 18 | 18 |
| 3 | 60F | FAP | skin ,mesopharynx | 96.11 | 4+ | 59 | 11 | 12 |
| 4 | 83F | SSA | skin,duodenum ,stomach, aorta | 98.37 | 4+ | 58 | 8 | 15 |
| 5 | 87M | SSA | skin | 79.97 | 4+ | 50 | 15 | 15 |
| 6 | 74F | FAP | skin | 99.66 | 4+ | 61 | 17 | 16 |
| 7 | 79M | SSA | myocardium ,Kidney, skin | 99.98 | 4+ | 57 | 14 | 13 |
| 8 | 90M | SSA | skin | 76.00 | 4+ | 50 | 16 | 16 |
| 9 | 53F | AA | skin | 62.59 | 3+ | 59 | 19 | 20 |
| 10 | 80M | SSA | myocardium | 99.83 | 4+ | 66 | 13 | 13 |
| *11 | 90F | SSA | gallbladder | 89.95 | 4+ | 60 | 11 | 12 |
| 12 | 78M | SSA | subcutaneous tissue, abdominal wall fat | 39.83 | 2+ | 56 | 15 | 14 |
| 13 | 81M | SSA | blood vessel | 10.06 | 1+ | 52 | 15 | 15 |
| 14 | 69F | AL | Kidney, duodenum ,stomach | 53.65 | 0 | 71 | 11 | 10 |
| 15 | 64F | AA | blood vessel | 33.09 | 1+ | 67 | 13 | 12 |
| 16 | 82F | AA | duodenum ,stomach, | 9.59 | 0 | 60 | 12 | 11 |
| 17 | 34F | AA | Kidney | 10.97 | 1+ | 74 | 8 | 8 |
| 18 | 68F | | Myocardium, skin | 13.15 | 3+ | 64 | 11 | 13 |

Table.1

*Case11:granular sparkling appearance

| | Amyloidosi group | Other group | p-Value |
|----------------------------------|--------------------|--------------------|----------|
| Number of cases | n = 13 | n = 37 | |
| Age | 73.6±14.8 | 71.8±10.9 | P = 0.41 |
| Men | 7 | 20 | |
| Female | 6 | 17 | |
| LVDd(mm) | 44.3±6.0 | 45.3±6.0 | P = 0.71 |
| LVDs(mm) | 32.0±5.4 | 29.7±6.7 | P = 0.26 |
| FS(%) | 28±5.7 | 35±7.9 | P < 0.05 |
| EF (Teichholz) % | 53.8±9.4 (n=13) | 63.8±11.0 (n=36) | P < 0.05 |
| IVSth mm | 14.2±3.0 | 11.9±2.2 | P < 0.05 |
| PWth mm | 14.7±2.3 | 11.1±1.8 | P < 0.05 |
| LV mass index(g/m ²) | 177.5±47.5 (n=11) | 135.9±42.7 (n=29) | P < 0.05 |
| LAD (mm) | 43.2±8.6 | 40.3±7.0 | P = 0.23 |
| EF (Simpson methods) % | 50.2±12.7 (n=9) | 58.7±13.8 (n=22) | P = 0.12 |
| E (cm/sec) | 76.2±21.8 | 67.2±21.3 | P = 0.19 |
| A (cm/sec) | 50.3±31.0 (n=8) | 92.6±23.7 (n=32) | P < 0.05 |
| E/A | 2.2±1.6 (n=8) | 0.72±0.28 (n=32) | P < 0.05 |
| DT (msec) | 160.8±39.5 (n=12) | 231.6±71.3 (n=35) | P < 0.05 |
| IVRT (msec) | 83.0±21.5 (n=6) | 81.2±15.1 (n=7) | P = 0.86 |
| E/E' (E/Ea) | 22.1±9.8 (n=9) | 17.8±8.4 (n=29) | P = 0.55 |
| BNP (pg/ml) | 540.7±464.3 (n=13) | 361.4±433.5 (n=36) | P = 0.11 |
| PYP accumulation rate(%) | 80.8±28.0 | 19.8±10.8 | P < 0.05 |
| PYP score | 3.4±0.9 | 0.5±0.8 | P < 0.05 |

Table.2

| | Amyloidosi group | Other group |
|------------|------------------|-------------|
| Positivity | 11 | 2 |
| Negative | 2 | 35 |

(a)PYP score

| | Amyloidos group | Other group |
|------------|-----------------|-------------|
| Positivity | 11 | 1 |
| Negative | 2 | 36 |

(b)PYP myocardial accumulation rate (%)

Table.3