

Reasons for the delays in the definitive diagnosis of lung cancer for more than one year from the recognition of abnormal chest shadows

著者	Yoshimoto Akihiro, Tsuji Hiroshi, Takazakura Eisuke, Watanabe Toshio, Haratake Joji, Kasahara Kazuo, Fuiimura Masaki, Nakao Shinji
journal or publication title	Internal Medicine
volume	41
number	2
page range	95-102
year	2002-01-01
URL	http://hdl.handle.net/2297/24309

Reasons for the Delays in the Definitive Diagnosis of Lung Cancer for More than One Year from the Recognition of Abnormal Chest Shadows

Akihiro YOSHIMOTO, Hiroshi TSUJI, Eisuke TAKAZAKURA, Toshio WATANABE*, Joji HARATAKE**, KAZUO KASAHARA***, Masaki FUJIMURA*** and Shinji NAKAO***

Abstract

Objective Primary lung cancer generally has a poor prognosis if not diagnosed at an early stage. But some lung cancers grow very slowly. In particular, adenocarcinoma is sometimes observed for years with no change of tumor size. In this study, we examined the reasons for the delays in reaching a definitive diagnosis of lung cancer.

Methods We retrospectively reviewed primary lung cancer cases between January 1995 and December 1999 and examined those whose definitive diagnoses were delayed for more than a year.

Results A total of 222 primary lung cancers were diagnosed. Of those, 19 patients (group A, 8.6%) were diagnosed after more than a year, and the other 203 (group B, 91.4%) were diagnosed within one year. The proportion of women in group A was significantly higher than that in group B ($p < 0.05$). The mean age of group A was significantly younger than that of group B ($p < 0.05$). The Brinkman Index of group A was significantly lower than that of group B ($p < 0.05$). The histologic types were significantly different between the two groups ($p < 0.05$). In group A, 18 patients (94.7%) had adenocarcinomas. Five primary reasons for the delays in group A were identified: 1) Four patients were tentatively diagnosed as inflammation or benign tumor on CT and were consequently not followed-up. 2) The chest CT shadows in 6 patients were suspected lung cancers but transbronchial lung biopsy findings did not show malignancy. 3) Four patients were tentatively diagnosed as inflammation or benign tumor on CT, but the tumors showed only very slow growth or no change at all. 4) The chest CT shadows of 2 patients were suspected lung cancer, but the patients refused to undergo video-assisted thoracic surgery (VATS) or closer examination. 5) Three patients did not consult medical facilities for a second examination.

Conclusions Many of the adenocarcinomas reviewed in

our study grew slowly or remained unchanged for years. Doctors are mainly responsible for the delays in the definitive diagnosis and should aggressively perform VATS or closer examinations without hesitation. (Internal Medicine 41: 95-102, 2002)

Key words: video-assisted thoracic surgery, slow-growing, transbronchial lung biopsy

Introduction

Primary lung cancer generally has a poor prognosis if not diagnosed at an early stage. Recently, spiral CT for the screening of peripheral lung cancer (1) and HRCT play a more efficient role than routine chest radiography in the detection of minute nodules. Once discovered, such nodules can be observed carefully and often prompt further diagnostic studies. Although the rate of benignity among resected nodules has decreased, it remains high, somewhere in the range from 20% to 40% (2). Earlier studies have investigated how the growth rate and tumor-doubling time were related to the prognosis of lung cancer patients (3-5). As a result, it was found that some of the lung cancers grew very slowly. In particular, adenocarcinoma is sometimes followed-up for years. Lung cancers that grow slowly are often difficult to distinguish from inflammatory diseases and therefore can take a long time to accurately diagnose. In this study, we examined the reasons for the delays in reaching a pathological definitive diagnosis after the recognition of abnormal chest shadows.

Patients and Methods

We retrospectively reviewed all primary lung cancer patients between January 1995 and December 1999 at Kurobe City

From the Department of Internal Medicine, *the Department of Thoracic Surgery, **the Department of Pathology, Kurobe City Hospital, Toyama and ***the Third Department of Internal Medicine, Kanazawa University, School of Medicine, Kanazawa

Received for publication March 5, 2001; Accepted for publication September 29, 2001

Reprint requests should be addressed to Dr. Akihiro Yoshimoto, the Third Department of Internal Medicine, Kanazawa University, School of Medicine, 13-1 Takaramachi, Kanazawa, Ishikawa 920-8640

Hospital (Toyama, Japan) and examined the cases whose pathological definitive diagnoses were delayed for more than a year from the initial recognition of abnormal chest shadows. To simplify the data collection for our study, the initial recognition of abnormal chest shadows was assumed to take place when the patient was notified of the shadows by his or her doctor. The definitive diagnosis was assumed to have taken place when the pathological diagnosis was made.

If a lung nodule being followed at our hospital is discovered to have grown, a chest CT is generally performed 1 month later. If the nodule does not change, CT is performed 3 months, 6 months, and 1 year after the initial CT. If the localized lung nodule on CT does not change for 2 years, the possibility of the lung cancer is extremely low and physicians do not follow-up the progress of the nodules.

We examined the following: histological type, TNM classification, whether the patient underwent curable resection, CT findings, tentative diagnosis at the first visit, whether a transbronchial lung biopsy (TBLB) was performed at the first visit, method of definitive diagnosis, tumor size on chest roentgenogram or CT at the first visit, delay to pathological diagnosis, size on CT at the time of pathological diagnosis, whether tumor size increased on CT, and the reasons for the delay in the pathological definitive diagnosis. The slice thickness used for the CT was 10 mm up to 1994, and then a thinner slice of 2 mm was introduced. Between 1995 and 1997 both the conventional 10 mm slice and the new 2 mm slice were used, and from 1998 onward the 2 mm slice has been used exclusively.

We also compared these lung cancer cases with those whose definitive diagnosis was no more than a year by sex, age, Brinkman Index, method of detection, WHO performance status, chest image findings, histology, TNM classification, and

prognosis. Survival time was defined as the period from pathological diagnosis. We also examined the rate of diagnosis by TBLB in peripheral lung cancer cases and the methods of diagnosis in mass survey cases.

The chi-square test or Fisher's exact probability test was used to compare values between the two groups. The non-paired Student's *t*-test was used to compare mean (\pm SD) values between the two groups. Survival curves were plotted using the Kaplan-Meier method and the log rank test was used to assess the significance of differences between the two groups. All tests were two-tailed, and a *p* value of <0.05 was considered statistically significant.

Results

Between January 1995 and December 1999 at our hospital, 222 primary lung cancers were diagnosed. Of those, 19 patients (group A, 8.6%) were diagnosed more than a year from the recognition of abnormal chest shadows, and the other 203 (group B, 91.4%) were diagnosed within one year.

Table 1 shows the characteristics of the groups. The proportion of women in group A, 57.9% (11 patients), was significantly higher than that in group B ($p<0.05$). The mean age of group A was 62.8 ± 11.8 (mean \pm SD) years old and significantly younger than that of group B ($p<0.05$). The Brinkman Index of group A was 359 ± 929 (mean \pm SD) and significantly lower than that of group B ($p<0.05$). The method of detection, performance status, and location of the tumor were all significantly different between the two groups.

Tables 2 and 3 show the histologic types and TNM staging. The histologic types were significantly different between the two groups ($p<0.05$). In group A, 18 patients (94.7%) were

Table 1. Characteristics of Patients of the Two Groups

	Group A (n=19)	Group B (n=203)	p Value
Gender			
man/woman	8/11 (57.9%)	137/66 (32.5%)	<0.05
Age (mean \pm SD)	62.8 ± 11.8	68.4 ± 10.5	<0.05
(range)	(40-83)	(39-90)	
Cigarette smoking			
Smoker/Non-smoker	6/13 (68.4%)	136/67 (33.0%)	<0.05
Brinkman Index	359 ± 929	720 ± 680	<0.0001
Method of detection			
Mass survey	17 (89.5%)	74 (36.5%)	
Any symptom	0 (0%)	63 (31.0%)	
Other disease	2 (10.5%)	66 (32.5%)	
Performance status			<0.05
0	18 (94.7%)	115 (56.7%)	
1	1 (5.3%)	56 (27.6%)	
2	0 (0%)	21 (10.3%)	
3-4	0 (0%)	11 (5.4%)	
Location of tumor			<0.05
Central	0 (0%)	47 (23.2%)	
Peripheral	19 (100%)	156 (76.8%)	

Reasons for the Delays in the Diagnosis of Lung Cancer

Table 2. Histologic Type and Stage of the Two Groups

	Group A (n=19)	Group B (n=203)	p Value
Histologic type			<0.05
Adenocarcinoma	18 (94.7%)	113 (55.7%)	
Squamous cell carcinoma	0 (0%)	58 (28.6%)	
Adenosquamous cell carcinoma	1 (5.3%)	4 (2.0%)	
Large cell carcinoma	0 (0%)	3 (1.5%)	
Small cell carcinoma	0 (0%)	24 (11.8%)	
Others	0 (0%)	1 (0.5%)	
Stage			N.S.
IA	8 (42.1%)	65 (32.0%)	
IB	2 (10.5%)	11 (5.4%)	
IIA	0 (0%)	9 (4.4%)	
IIB	3 (15.8%)	8 (3.9%)	
IIIA	1 (5.3%)	20 (9.9%)	
IIIB	3 (15.8%)	48 (23.6%)	
IV	2 (10.5%)	42 (20.7%)	

Table 3. Characteristics of Patients (Group A)

No	Age at definitive diagnosis	Sex	Histology	Tumor size* (mm)	TNM	Curable resection	CT findings			Survival from diagnosis (month)	Outcome
							Air broncho	Spicula	Pleural indent		
1	40	F	W/D Ad	25	T1N0M0	(+)	(+)	(-)	(-)	63	Alive
2	44	M	W/D Ad	37	T2N0M0	(+)	(-)	(+)	(+)	63	Alive
3	79	M	M/D Ad	40	T3N0M0	(+)	(-)	(+)	(-)	56	Alive
4	63	F	W/D Ad	35	T2N1M0	(+)	(+)	(-)	(+)	55	Alive
5	50	F	M/D Ad	23	T1N0M0	(+)	(+)	(-)	(+)	5 days	Dead
6	77	M	M/D Ad	30	T1N0M0	(+)	(+)	(+)	(+)	42	Dead
7	66	F	W/D Ad	20	T1N0M0	(+)	(+)	(-)	(+)	50	Alive
8	83	M	W/D Ad	40	T2N0M0	(-)	(-)	(+)	(+)	48	Alive
9	72	F	P/D Ad	18	T1N0M0	(+)	(+)	(-)	(+)	40	Alive
10	68	F	W/D Ad	37	T4N1M0	(+)	(+)	(-)	(-)	34	Alive
11	56	F	W/D Ad	8	T1N0M0	(+)	(-)	(-)	(-)	28	Alive
12	53	F	W/D Ad	9	T1N0M0	(+)	(-)	(-)	(-)	27	Alive
13	66	F	W/D Ad	27	T4N1M0	(+)	(+)	(+)	(+)	37	Dead
14	67	M	W/D Ad	27	T1N0M0	(+)	(+)	(+)	(-)	68	Alive
15	67	F	Ad	25	T4N1M0	(-)	(+)	(+)	(+)	31	Dead
16	69	M	Ad-sq	55	T2N1M0	(+)	(+)	(+)	(+)	25	Dead
17	68	F	M/D Ad	48	T2N1M1	(-)	(-)	(-)	(+)	5	Dead
18	55	M	P/D Ad	30	T4N0M1	(+)	(+)	(+)	(+)	32	Alive
19	50	M	W/D Ad	28	T1N2M0	(+)	(-)	(+)	(+)	73	Alive

W/D Ad: well differentiated adenocarcinoma, M/D Ad: moderately differentiated adenocarcinoma, P/D Ad: poorly differentiated adenocarcinoma, Ad-sq: adenosquamous cell carcinoma, Air broncho: air bronchogram, Pleural indent: pleural indentation, *Maximum tumor size at the time of definite diagnosis measured by resected specimen or on CT.

adenocarcinomas and 1 was adenosquamous cell carcinoma. Of the 18 adenocarcinomas, 11 were well differentiated, 4 were moderately differentiated, 2 were poorly differentiated, and 1 was unknown. Maximum tumor size at the definitive diagnosis ranged from 8 mm to 55 mm, and 8 patients (42.2%) had T1N0M0. Sixteen (84.2%) of the 19 patients underwent curable resection and 13 (68.4%) of the 19 were still alive in February 2001 (Table 3). Case 8 did not receive any treatment. Case 15 received video-assisted thoracic surgery (VATS). Ten KE of OK-432 were injected into the pleural space when pleu-

ral dissemination was found during the procedure, but case 15 did not receive any chemotherapy. The CT findings of group A are also shown in Table 3. Air bronchograms were found in 12 patients, spiculations were found in 10, and pleural indentations were found in 13.

The patients in group A received the following tentative diagnoses based on chest images at the first visit: lung cancer suspected in 9 patients, inflammation in 8 patients, and benign tumor in 2 patients. Ten patients received TBLB at the first visit and 9 patients did not. The definitive diagnoses were made

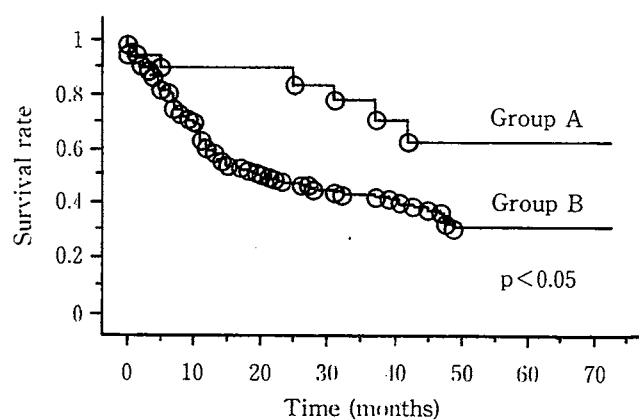
Table 4. Clinical Course of Patients from the First Visit to Definitive Diagnosis (Group A)

No	Tentative diagnosis	TBLB at the first visit	Method of definitive diagnosis	Size at the first visit (mm)	Delay (month)	Size at the definitive diagnosis (mm)	Tumor size Increase
1	Benign tumor	Not examined	TBLB	19×18	71	26×24	Yes
2	Inflammation	Examined	TBLB	21×15	58	39×37	Yes
3	Inflammation	Examined	Open	20×17	60	38×36	Yes
4	Inflammation	Not examined	TBLB	20×16	12	34×32	Yes
5	Inflammation	Examined	TBLB	18×14	15	25×23	Yes
6	Lung ca. susp	Examined	TBLB	21×18	22	30×30	Yes
7	Lung ca. susp	Examined	Open	22×21	30	22×21	No
8	Inflammation	Not examined	TBLB	18×15	108	39×24	Yes
9	Lung ca. susp	Examined	TBLB	12×12	60	22×22	Yes
10	Lung ca. susp	Examined	TBLB	36×32	54	36×32	No
11	Benign tumor	Not examined	VATS	8×8	15	8×8	No
12	Inflammation	Not examined	VATS	10×10	40	10×10	No
13	Lung ca. susp	Examined	TBLB	25×15	28	33×26	Yes
14	Inflammation	Not examined	TBLB	15×12	12	29×28	Yes
15	Lung ca. susp	Examined	TBLB	20×18	12	25×23	Yes
16	Lung ca. susp	Examined	TBLB	35×30	32	58×50	Yes
17	Lung ca. susp	Not examined	TBLB	35×20	27	45×39	Yes
18	Lung ca. susp	Not examined	TBLB	30×18	60	33×31	Yes
19	Inflammation	Not examined	TBLB	18×12	12	24×24	Yes

TBLB: transbronchial lung biopsy, Lung ca. susp: lung cancer suspected, Open: open lung biopsy, VATS: Video-assisted thoracic surgery.

by TBLB in 15 patients, by VATS in 2 patients, and by open lung biopsy in 2 patients. The tumor size was increased on CT at the definitive diagnosis in 15 patients (78.9%), but there were no changes in the tumor size from the first visit in the other 4 patients (21.1%) (Table 4). The disease did not progress in the lymph nodes during the period from the first detection of abnormal chest shadows to definite diagnosis in any of the patients. There was a significant difference between the Kaplan-Meier estimates of the survival curves between the two groups ($p < 0.05$, Fig. 1).

Table 5 shows the rate of diagnosis by TBLB in peripheral lung cancer cases. Fifteen (88.2%) of 17 patients in group A and 93 (78.0%) of 120 patients in group B were diagnosed by TBLB. Table 6 shows the methods of diagnosis in mass survey cases.

**Figure 1. Survival curves of the two groups.****Table 5. The Diagnostic Rate by TBLB in Peripheral Cases**

	Group A (n=19)	Group B (n=156)	p Value
TBLB			N.S.
Examined	17 (89.5%)	120 (76.9%)	
Not-examined	2 (10.5%)	36 (23.1%)	
TBLB examined cases	n=17	n=120	N.S.
Diagnosed	15 (88.2%)	93 (78.0%)	
Not-diagnosed	2 (11.8%)	27 (22.5%)	

TBLB: transbronchial lung biopsy.

Reasons for the Delays in the Diagnosis of Lung Cancer

Case presentation

Case 10

A 68-year-old woman had an annual chest roentgenogram examination in October 1993. The chest CT (Fig. 2A) showed an irregular mass shadow no larger than 35 mm in the left lingula. Chest CTs were repeated 7 times up to March 1998 (Fig. 2B), but the findings and size of the mass did not change.

Case 11

In a 56-year-old woman, in September 1997, a small nodular shadow with a sharp border and solid density was detected in the right middle lobe on CT (Fig. 3A). Chest CTs were repeated 3 times up to November 1998 (Fig. 3B), but the size of the mass did not change. In our hospital in 1998, many small solid-density nodules similar to those observed in this case

Table 6. The Method of Diagnoses in Mass Survey Cases

	Group A (n=17)	Group B (n=74)	p Value
			N.S.
TBLB	14 (82.3%)	47 (63.5%)	
Surgery	3 (17.6%)	13 (17.6%)	
Open lung biopsy	2	3	
VATS	1	10	
CT-guided lung biopsy	0 (0%)	4 (23.5%)	
TBB	0 (0%)	7 (9.5%)	
Sputum cytology	0 (0%)	3 (4.1%)	

TBLB: transbronchial lung biopsy, TBB: transbronchial tumor biopsy, VATS: video-assisted thoracic surgery.

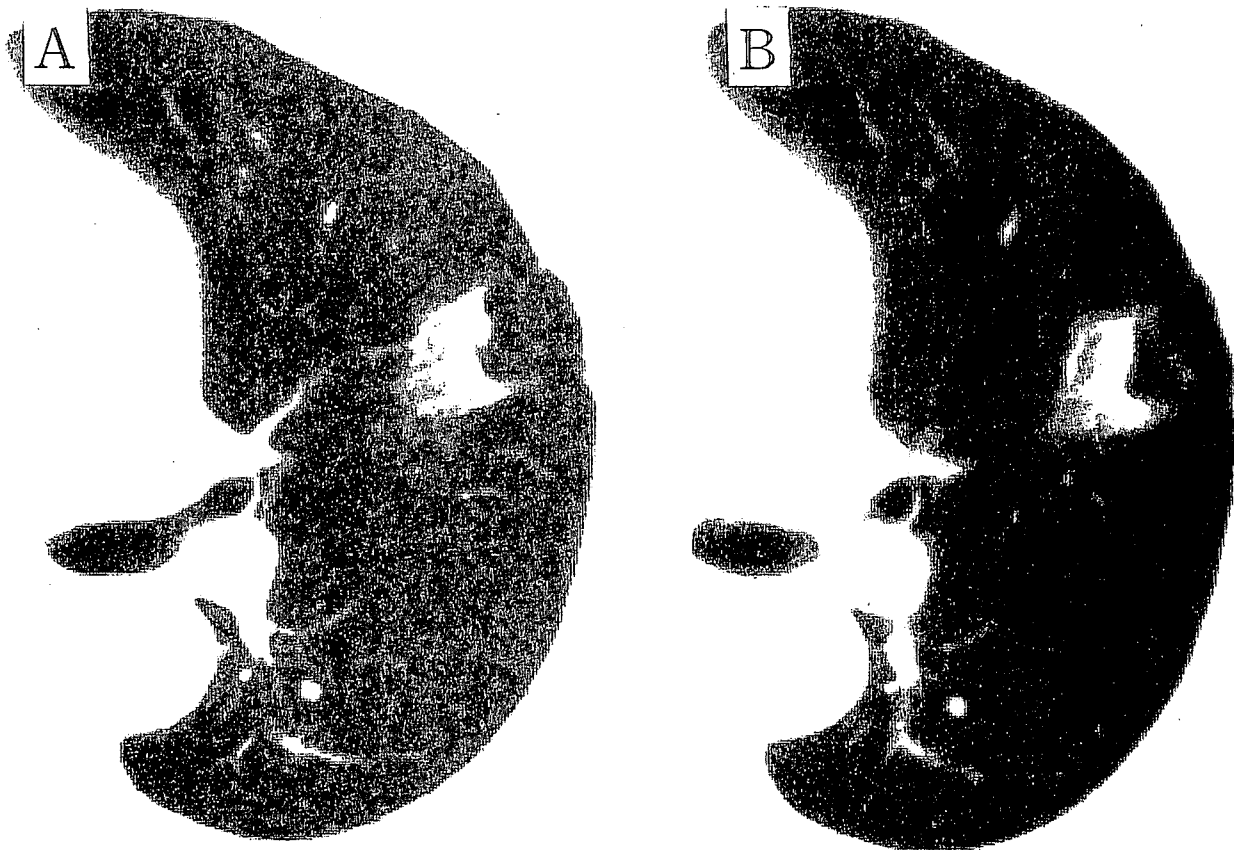


Figure 2. Case 10, a 68-year old woman. Left, A: the chest CT in October 1993 showing an irregular mass shadow no larger than 35 mm in the lingula. Right, B: the findings and size of the mass on chest CT in March 1998 showing no change.

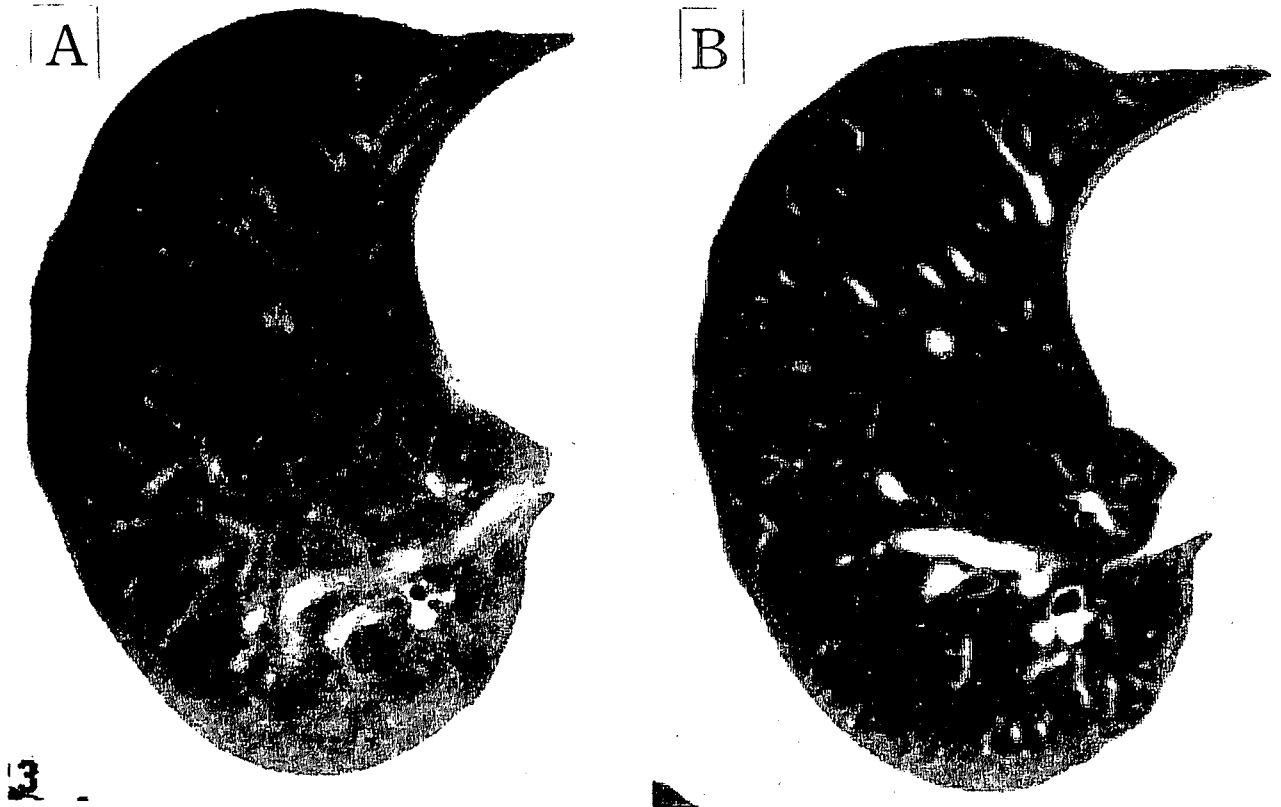

Figure 3. Case 11, a 56-year old woman. Left, A: the chest CT in September 1997 showing a small nodular shadow with a sharp border and solid-density in the right middle lobe. Right, B: the size of the mass on CT in March 1998 showing no change.

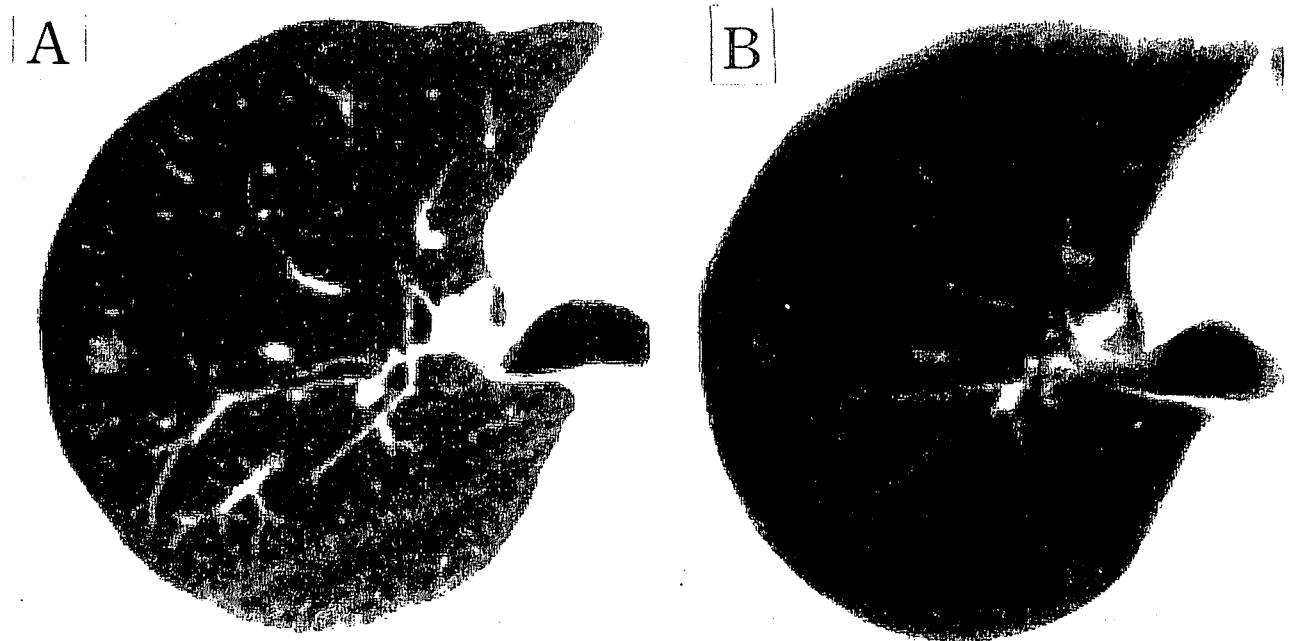
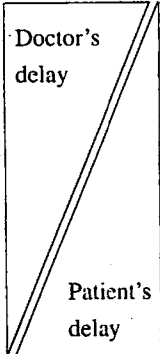


Figure 4. Case 12, a 53-year old woman. Left, A: the chest CT in October 1995 showing a small nodular shadow with ground-glass opacity in the right S2. B: the findings and size of the mass on CT in December 1998 showing no change.

Reasons for the Delays in the Diagnosis of Lung Cancer

Table 7. Reasons for the Delay in the Pathological Definitive Diagnosis, and Who Is Responsible for the Delay (Group A)

		Who is responsible?
1. Tentatively diagnosed as inflammation or benign tumor on CT and not followed-up	4 cases	
2. Suspected lung cancers on CT, but TBLB findings showed no malignancy	6 cases	
3. Tentatively diagnosed as inflammation or benign tumor on CT, but tumor showed only very slow growth or no change at all	4 cases	
4. Refused VATS or closer examination although CT findings were suspected lung cancer	2 cases	
5. Not consulted medical facilities for the second examination	3 cases	

TBLB: transbronchial lung biopsy, VATS: video-assisted thoracic surgery.

proved to be lung cancer. This prompted us to perform VATS.
Case 12

A 53-year-old woman had an annual chest roentgenogram examination in October 1995. The chest CT (Fig. 4A) showed a small nodular shadow with ground glass opacity (GGO) in the right S2. Chest CTs were repeated 8 times up to December 1998 (Fig. 4B), but the findings and size of the mass did not change. Later, in many reports small nodular shadows with GGO were proved to be cancer. This prompted us to perform VATS.

Table 7 shows the reasons for the delays in the definitive diagnoses in group A. Five main reasons were identified. 1) Four patients were tentatively diagnosed as inflammation or benign tumor on CT at the first visit and not followed-up. 2) The chest CT shadows in 6 patients were suspected lung cancers but TBLB findings did not show malignancy. Subsequently, the progress of 4 of these patients was followed-up but the other 2 of patients refused re-examination or VATS. 3) Four patients were tentatively diagnosed as inflammation or benign tumor on CT at the first visit, but the tumors showed only very slow growth or no change at all. 4) The chest CT shadows of 2 patients were suspected lung cancer, but the patients refused VATS or closer examination. 5) Three patients did not consult medical facilities for a second examination.

Discussion

Some past reports have discussed the tumor-doubling time (3–5). In a population of 237 lung cancer patients, Arai et al (3) calculated a mean tumor-doubling time of 166.3 days. Of those, 75 patients had slow-growing tumors that required more than 252.4 days to double in size. This slow-growing tumor rate of more than 252.4 days was assessed in 43% of the adenocarcinomas in their series. In a report on 107 lung cancer patients, Hayabuchi et al (4) applied the slow-growing classifi-

cation to 29 cases with masses that doubled in volume in no less than five months prior to any therapy. By these criteria, 7 (17%) of 41 squamous cell carcinomas were slow growing, in contrast to 22 (42%) of 52 adenocarcinomas.

Four of our patients (cases 7, 10, 11, 12) showed no change in tumor size (Table 4), and 8 patients (Table 3) were pathologically graded as T1N0M0. Cases 1, 9, and 12 were all observed for more than three years and none advanced pathologically beyond T1N0M0. These results suggest, first, that some adenocarcinomas grow slowly or do not change in size for some years, and second, that a good prognosis can be expected in the patients who have these slow-growing tumors. In all of our 19 patients diagnosed more than a year from the detection of shadows, the lesions did not progress in the lymph nodes before the definitive diagnosis. However, these findings cannot be generalized, and physicians should not hesitate to perform VATS even in the absence of changes of the tumor size and lymph nodes.

The delays in the diagnosis of lung cancer are an issue of clinical concern and have been the subject of other reviews (4, 6–8). Billing and Wells (6) analyzed 38 surgically treated lung cancers. In their report, the mean total delay from presentation to operation was 109 days, and although they pointed out ways to improve the efficiency of the diagnostic process, the length of the delay was not correlated with the tumor stage. The delays in the diagnosis and treatment of lung cancer have been investigated in Brazil, where two prospective studies looked at delays in the diagnosis of lung cancer from the onset of symptoms (7, 8). The time lost between the first appointment and the diagnosis was more than 90 days in 55.7% of cases (8). However, the present study is slightly different in that it focuses specifically on a subgroup in which the diagnosis was markedly delayed (more than one year).

Our study aims to clarify the reasons for the delays in the definitive diagnosis. Table 7 shows the reasons for the delays in the definitive diagnosis in those 19 patients from our study.

Most of the reasons had to do with the doctors and their techniques in performing TBLB. As the TBLB demonstrated no malignant findings, the doctors were not inclined to continue with further examination, which led to the delays in the definitive diagnosis. Though some of the nodules changed little over the most recent year of examination, apparently these nodules had grown intermittently during prior years. The diagnostic limitations of CT scanning and TBLB in potential lung cancer patients are well known.

In our 19 patients, the abnormal chest shadows were recognized by the doctors at the first visit, but the frequency of the delayed definitive diagnosis was quite high in the overall population (19 of 222 patients; 8.6%). In our study, many of the adenocarcinomas grew slowly or remained unchanged for years, and their diagnosis was markedly delayed (more than one year). Therefore, adenocarcinomas are sometimes observed in progress, and physicians hesitate to perform VATS even when the nodule sizes exceed 20 mm. Doctors are mainly responsible for the delays in the definitive diagnosis and should aggressively perform VATS or closer examinations without hesitation.

References

- 1) Kaneko M, Eguchi K, Ohmatsu H, et al. Peripheral lung cancer: screening and detection with low-dose spiral CT versus radiography. *Radiology* **201**: 798-802, 1996.
- 2) Midthun DE, Swensen SJ, Jett JR. Clinical strategies for solitary pulmonary nodule. *Annur Rev Med* **43**: 195-208, 1992.
- 3) Arai T, Kuroishi T, Saito Y, Kurita Y, Naruke T, Kaneko M. Tumor doubling time and prognosis in lung cancer patients: evaluation from chest films and clinical follow-up study. *Jpn J Clin Oncol* **24**: 199-204, 1994.
- 4) Hayabuchi N, Russell WJ, Murakami J. Slow-growing lung cancer in a fixed population sample: radiologic assessments. *Cancer* **52**: 1098-1104, 1983.
- 5) Geddes DM. The natural history of lung cancer: a review based on rates of tumour growth. *Br J Dis Chest* **73**: 1-17, 1979.
- 6) Billing JS, Wells FC. Delays in the diagnosis and surgical treatment of lung cancer. *Thorax* **51**: 903-906, 1996.
- 7) Pereira JR, Ikari FK, Minamoto H, Cassioli JC. Delay factors in the diagnosis of lung cancer: a public health problem. *Rev Paul Med* **109**: 109-112, 1991.
- 8) Silva PP, Pereira JR, Ikari FK, Minamoto H. Lung cancer and the delay in diagnosis: analysis of 300 cases. *Rev Assoc Med Bras* **38**: 145-149, 1992.