

## Embolic Stroke with a Patent Foramen Ovale and Behçet's Disease

Chiho ISHIDA, Eisuke FURUI, Yasuo SAKASHITA\* and Masahito YAMADA

### Abstract

**We report a case of a 53-year-old man with Behçet's disease (BD) and paradoxical stroke. This patient suddenly developed sensory aphasia, right oculomotor palsy, nystagmus, and left ataxic hemiparesis. MR images showed fresh embolic infarcts in the midbrain and the left parietotemporal lobe. He presented with uveitis, oral aphthous ulcers and genital ulcers. An electrocardiogram revealed no abnormalities, and a transesophageal echocardiogram disclosed a patent foramen ovale. Since venous involvement is common in BD, we suspected the presence of smaller thrombi probable in this patient. We conclude that embolic stroke is a notable complication of BD with right-to-left shunting. (Internal Medicine 44: 326–327, 2005)**

**Key words:** Behçet's disease, patent foramen ovale, embolism, cerebrovascular accident

### Case Report

Central nervous system involvement in Behçet's disease (BD) is mainly caused by chronic, recurrent vasculitis affecting small vessels. Additionally, cerebral venous thrombosis is a major complication, and cerebral arterial thrombosis is infrequently observed in central nervous system involvement of BD (1–3). However, embolic stroke with BD has never been reported. We present the first report of BD and paradoxical embolism through a patent foramen ovale (PFO).

A 53-year-old right-handed man with a 20-year history of uveitis suddenly developed right oculomotor palsy, speech impairment, and gait disturbance simultaneously on July 7, 2000, and he was admitted to a hospital. He had a high fever from July 15, and was admitted to our hospital for further examination on July 17. The patient had recurrent oral

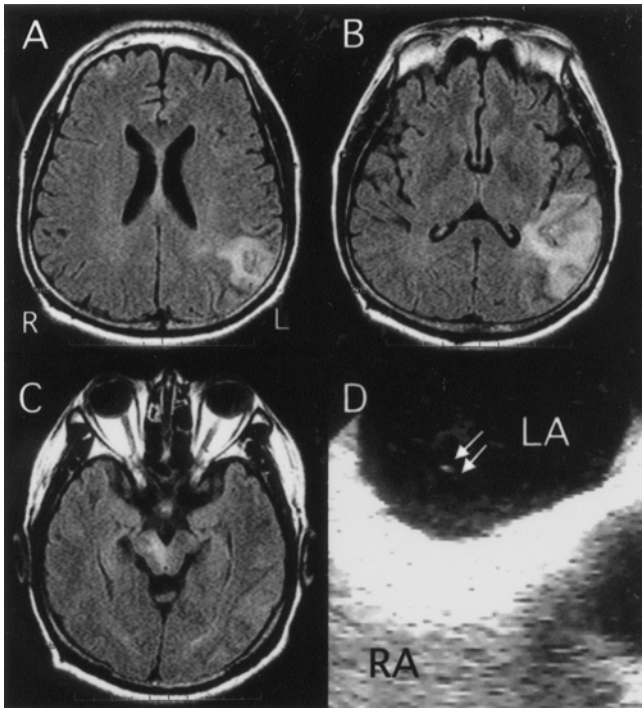
aphthous ulcers, and active genital ulcers on the scrotum, but no thrombophlebitis. Neurological examination showed sensory aphasia, right oculomotor palsy, nystagmus of the left eye at gaze to the left, central type left facial palsy, and left ataxic hemiparesis. Fluid-attenuated inversion recovery MR images showed lesions in the midbrain, the left parietotemporal lobe, and the right frontal lobe (Fig. 1A–C). The lesions of the midbrain and the left parietotemporal lobe showed hypersignal intensity in diffusion-weighted images. Cerebral angiography revealed no abnormalities. The patient was clinically diagnosed with embolic stroke and BD (1). HLA-B51 antigen was present. Laboratory data showed leukocytosis 30,100/mm<sup>3</sup>, IgG-κ benign monoclonal gammopathy, and elevated levels of CRP 34.8 mg/dl, fibrinogen 942 mg/dl, and plasmin α2 plasmin inhibitor complex 2.0 μg/ml on admission. Although the patient had a history of smoking, there were no other risk factors for stroke, such as hypertension, diabetes mellitus, hyperlipidemia, collagen disease, hyperhomocysteinemia, antiphospholipid syndrome, or any congenital disorders of the coagulation system. Electrocardiogram and transthoracic echocardiogram (TTE) showed no abnormal findings. However, transesophageal echocardiogram (TEE) with the contrast method demonstrated a right-to-left shunting through a PFO (Fig. 1D). Both the radionuclide venography (RNV) and pulmonary circulation scintigraphy revealed no thrombus in the lungs or the legs. Antibiotic therapy was beneficial for the fever. All the abnormal laboratory data, except for monoclonal gammopathy, disappeared without any administration of immunosuppressants. The neurological manifestations gradually improved, but partially remained. The genital ulcers had become scarring by the time of the patient's discharge from the hospital on August 30. He had no recurrence of stroke for 4 years under treatment with warfarin.

We determined that embolic stroke in this patient was caused by the coincidence of BD and PFO. Patients with BD, especially men, have a significantly high risk of developing systemic venous thrombosis (2, 3). In addition, patients with

From the Department of Neurology and Neurobiology of Aging, Kanazawa University Graduate School of Medical Science, Kanazawa and \*the Department of Neurology, Tonami General Hospital, Tonami

Received for publication July 7, 2004; Accepted for publication October 18, 2004

Reprint requests should be addressed to Dr. Chiho Ishida, the Department of Neurology, Noto General Hospital, 6-4 a-bu, Fujimachi-machi, Nanao 926-8610



**Figure 1.** Fluid-attenuated inversion recovery (FLAIR) MRI scan shows hyperintensity in the right frontal cortex (A) and the right paramedian portion of the midbrain (C), and heterogenous hyperintensity in the left parietotemporal lobe (A and B). A branch of the right prefrontal artery, the right paramedian arteries from the basilar artery, and the left angular artery supply those regions, respectively. Transesophageal echocardiography with the contrast method (D) reveals a shunting of a few air-microbubbles (arrows) through a patent foramen ovale into the left atrium (LA) from the right atrium (RA). RA is filled with abundant air-microbubbles which have been injected from the radial vein. RA: right atrium, LA: left atrium.

BD may have pulmonary embolism caused by thrombi from venous thrombosis (4). No venous thrombus was found with RNV and pulmonary circulation scintigraphy in our patient. However, there is the possibility of the presence of systemic venous microthrombi, which cannot be detected with RNV or pulmonary circulation scintigraphy, but can cause embolic stroke. Even with small thrombi, the clinical manifestations should be more obvious in embolic stroke than in pulmonary embolism. In the present patient, TEE with the contrast method disclosed a right-to-left shunting, while TTE did not show any abnormalities. We propose that embolic stroke is a notable complication for patients affected by BD and right-to-left shunting, and TEE with the contrast method is an important examination procedure.

Anticoagulants, antiplatelet agents, or both have been used for the preventive therapy of venous thrombosis with BD (1, 4) and of embolic stroke with a PFO (5). Warfarin appears to be effective in some patients and in our patient, although the efficacy remains controversial, requiring further investigation (1, 5).

## References

- 1) Sakane T, Takeno M, Suzuki N, Inaba G. Behçet's disease. *N Engl J Med* **341**: 1284–1291, 1999.
- 2) Ames PRJ, Steuer A, Pap A, Denman AM. Thrombosis in Behçet's disease: a retrospective survey from a single UK centre. *Rheumatology* **40**: 652–655, 2001.
- 3) Koç Y, Güllü I, Akpek G, et al. Vascular involvement in Behçet's disease. *J Rheumatol* **19**: 402–410, 1992.
- 4) Sanchez-Burson J, Corzo JE, Marengo JL, Rejon-Gieb E. Thrombolytic therapy in pulmonary embolism of Behçet's disease. *Acta Haematol* **96**: 181–183, 1996.
- 5) Alp N, Clarke N, Banning AP. How should patients with patent foramen ovale be managed? *Heart* **85**: 242–244, 2001.