

## Pulmonary Infiltrates with Eosinophilia due to Naproxen

Haruhiko OGAWA, Kazuyoshi KURASHIMA, Masanobu NAMURA,  
Hounin KANAYA, Youichi KAWAMURA, Takio OHKA, Hiroshi KURUMAYA\*,  
Masahide YASUI\*\*, Masaki FUJIMURA\*\* and Tamotsu MATSUDA\*\*

An increasing number of drugs have been implicated in the etiology of eosinophilic pneumonia characterized by the development of pulmonary infiltrates, and peripheral blood eosinophilia. Naproxen is a commonly used nonsteroidal anti-inflammatory drug which may be added to the growing list of pharmacologic agents associated with infiltrative pulmonary lesions. A case of eosinophilic pneumonia induced by Naproxen is described. The results of TBLB, a lymphocyte stimulation test, and a challenge test supported this diagnosis.

**Key words:** Drug-induced pneumonitis, Eosinophilic pneumonia, Respiratory failure, Lymphocyte stimulation test (LST), TBLB, Challenge test

### CASE REPORT

A 72-year-old woman was admitted to our hospital on January 25, 1990, because of dry cough, dyspnea on exertion, and low-grade fever. The chest X-ray on admission revealed diffuse reticuloliner shadows in the right lung field. Additional history revealed that the patient had been taking Naproxen, 300 mg daily, during the previous three wks for osteoarthritis.

The physical examination revealed the following

The physical examination revealed the following: temperature, 37.6°C; blood pressure, 110/50 not anemic nor icteric. Auscultation of the chest revealed late inspiratory fine crackles over the right whole-lung-zone. No heart murmur was noted. There was no lymphadenopathy or edema.

Abnormal laboratory studies included arterial blood gas levels while breathing room air: Po<sub>2</sub>, 51 mmHg; Pco<sub>2</sub>, 38.7 mmHg; and pH, 7.47. The white blood cell count was 14,900/ $\mu$ l with a differential of 33% segmented neutrophils, 8%

lymphocytes, 2% monocytes, and 55% eosinophils. The hemoglobin level was 10.7 g/dl with a hematocrit value of 36.0%. The erythrocyte sedimentation rate was 124 mm/h. The C-reactive protein was 23.3 mg/dl, and IgE level was 440 U/ml.

The following laboratory values were normal or negative: urine analysis, stools for ova and parasites, serum electrolytes, total protein, albumin, and mycobacterial and fungal cultures of sputum.

The ECG revealed a normal sinus rhythm.

Chest X-ray film on admission (Fig. 1) showed diffuse reticuloliner shadows in the right lung field.

Chest CT scan 7 days after admission (Fig. 2) showed diffuse interstitial shadows with partial infiltrative change in the right lung field.

Bronchoalveolar lavage (BAL) was performed using a total volume of 150ml of sterile saline solution (46.7% recovery). Differential cell analysis revealed 3.7% alveolar macrophages, 6.0% lymphocytes, 0.7% neutrophils, 89.7% eosinophils, and an increased absolute total cell count of  $13.4 \times 10^7$  cells/ml. BALF lymphocyte subsets

From The Departments of Internal Medicine, \*Pathology, Ishikawa Prefectural Central Hospital, Kanazawa and \*\*The Third Department of Internal Medicine, Kanazawa University School of Medicine, Kanazawa

Received for publication April 17, 1990; Accepted for publication August 27, 1990

Reprint requests should be addressed to Haruhiko Ogawa, MD, Third Department of Internal Medicine, Kanazawa University School of Medicine, 13-1 Takaramachi, Kanazawa 920, Japan

revealed the presence of CD4<sup>+</sup> cells (46%) and CD8<sup>+</sup> cells (20%). CD4/CD8 ratio was 2.3.

A transbronchial lung biopsy (TBLB) obtained from right S<sup>4</sup> (Fig. 3) showed alveolar septal thickening and predominant eosinophilic infiltration in the alveolus and septa.

The result of a lymphocyte stimulation test (LST) of Naproxen was not significant (344 cpm, 167%).

Regarding the clinical course, due to the suspicion of drug-induced pneumonitis, the Naproxen therapy

was discontinued and 2 days after admission she was administered prednisolone therapy, 30 mg/day. Within 10 days, the fever and cough were resolved and the white blood cell count was diminished to 7,500/ $\mu$ l with 5% eosinophils. Three wks later the chest X-ray showed marked resolution of all infiltrates (Fig. 4). Though the result of a lymphocyte stimulation test of Naproxen was negative, the patient was challenged with Naproxen,

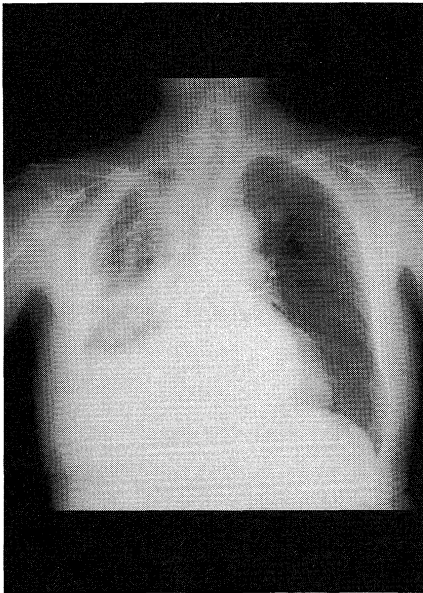


Fig. 1. Chest X-ray film on admission showing diffuse reticulolinear shadows in the right lung field.

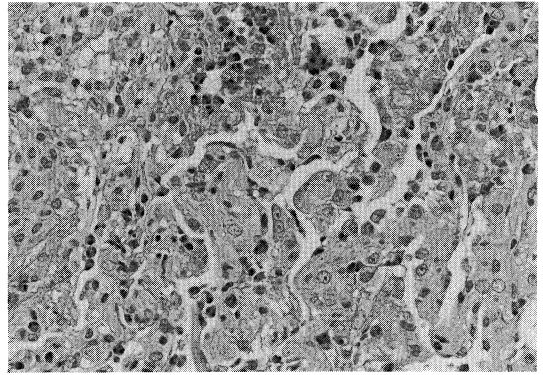


Fig. 3. Transbronchial lung biopsy obtained from right S<sup>4</sup> showing alveolar septal thickening and eosinophilic infiltration in the alveoli and septa (H&E stain, original magnification  $\times 100$ ).

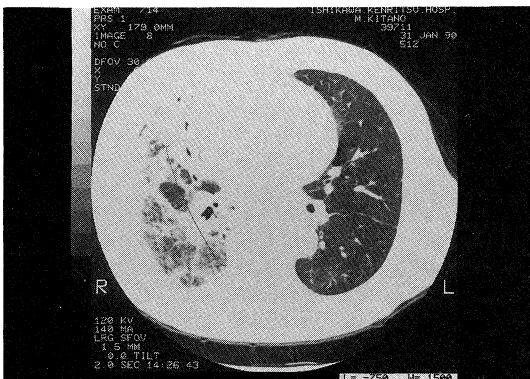


Fig. 2. Chest CT scan 7 days after admission showing diffuse interstitial shadows with partial infiltrative change in the right lung field.

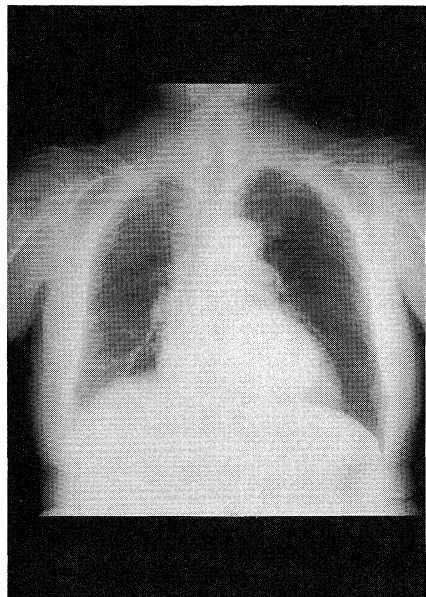


Fig. 4. Chest X-ray film 21 days after admission showing marked resolution of infiltrates.

Table 1. Laboratory findings before and after challenge.

	Before	After
WBC (/ $\mu$ l)	7,100	5,600
seg%	44	23
eos%	4	13
CRP (mg/dl)	0.5	1.3
Blood gas (room air)		
PaO <sub>2</sub> (mmHg)	87.6	79.6
PaCO <sub>2</sub> (mmHg)	41.6	43.9
Pulmonary function		
VC (ml)	1,970	2,020
FEV <sub>1.0</sub> (ml)	1,380	1,470
DLco (ml/min/mmHg)	12.56	8.59

WBC, white blood cell count; seg, segmented neutrophil; eos, eosinophils; CRP, C-reactive protein; Pao<sub>2</sub>, arterial O<sub>2</sub> tension; Paco<sub>2</sub>, arterial CO<sub>2</sub> tension; VC, vital capacity; FEV<sub>1.0</sub>, forced expiratory volume in 1 s; DLco, diffusing capacity for carbon monoxide

100 mg tablets administered every eight h, under informed consent. After 11 doses, within 96 h, the patient developed symptoms of fever and dry cough. The white blood cell count was 5,600/ $\mu$ l with 13% eosinophils (Table 1). A chest X-ray showed thickening of the minor fissure and mild peripheral infiltrates in the right lung. The Naproxen was permanently discontinued; the patient's symptoms subsided, and laboratory findings returned to normal.

### DISCUSSION

Eosinophilic pneumonia represents a clinical manifestation of an immunologic response or allergic reaction. A number of drugs have been reported to be the cause of pulmonary infiltrates (1–3), and nonsteroidal, anti-inflammatory agents have been implicated as etiologic factors for acute interstitial pneumonitis (4). However, the mechanism whereby drugs can cause pulmonary disease is not clearly understood. The following possible mechanisms were reported by Rosenow (2): 1) over dosage, 2) intolerance, 3) side effects, 4) secondary effects, 5) idiosyncrasy, or 6) allergic reactions.

The link between drugs and pulmonary damage has become more evident and the list of drugs implicated in lung injury has grown during the last decade. In a 1972 review of the subject, Rosenow

(2) cited 19 drugs associated with lung damage. Since that time, a number of additional drugs have been reported. Cooper (5) described the clinical aspects and pathogenic mechanisms of cytotoxic and non-cytotoxic drug-induced pulmonary disease.

We believe the present case represents a pulmonary hypersensitivity reaction to Naproxen manifested by fever, dry cough, exertional dyspnea, peripheral lung infiltrates, and blood eosinophilia. Upon cessation of Naproxen therapy and the use of steroid therapy, there was clinical improvement of the illness. Rechallenge with Naproxen produced similar symptoms, a similar chest roentgenogram, and eosinophilia.

The extrapulmonary complications of Naproxen are well known, but to our knowledge only six cases of Naproxen induced-lung disease have been reported (6–9).

Lymphocyte predominant alveolitis induced by other drugs (10, 11) is well known. In the present patient, the finding of BALF and TBLB revealed marked eosinophil predominancy.

It is important to be aware of the possibility of such a complication occurring in patients treated with Naproxen.

### REFERENCES

- 1) Fraser RG, Pare JAP. *Diagnosis of diseases of the Chest*. WB Saunders, Philadelphia, 1978, p.906.
- 2) Rosenow III EC. The spectrum of drug-induced pulmonary disease. *Ann Intern Med* 77: 977, 1972.
- 3) Lippmann M. Pulmonary reactions to drugs. *Med Clin North Am* 61: 1353, 1977.
- 4) Fein M. Sulindac and pneumonitis. Letter. *Ann Intern Med* 95: 245, 1981.
- 5) Cooper JAD, White DA, Matthey RA. Drug-induced pulmonary disease. *Am Rev Respir Dis* 133: 321, 1986.
- 6) Nader DA, Schillaci RF. Pulmonary infiltrates with eosinophilia due to naproxen. *Chest* 83: 280, 1983.
- 7) Buscaglia AJ, Cowden FE, Brill H. Pulmonary infiltrates associated with naproxen. Brief report. *J Am Med Assoc* 251: 65, 1984.
- 8) Londino Jr AV, Wolf GL, Calabro JJ, Perrone SJ. Naproxen and pneumonitis. Letters. *J Am Med Assoc* 252: 1853, 1984.
- 9) Adachi S, Nimura T, Monoe T, et al. A case of pneumonitis due to naproxen. *Jpn J Thorac Dis* 24: 172, 1986.
- 10) Eitensohn DB, Roberts NJ, Condemi JJ. Broncho-alveolar lavage in gold lung. *Chest* 85: 569, 1984.
- 11) Chamberlin DW, Hyland RH, Ross DJ. Diphenylhydantoin-induced lymphocytic interstitial pneumonia. *Chest* 90: 458, 1986.