

Evaluation of upper lip hypoesthesia with a trigeminal somatosensory-evoked potential following Le Fort I osteotomy in combination with mandibular osteotomy

著者	Ueki Koichiro, Nakagawa Kiyomasa, Marukawa Kohei, Shimada Mayumi, Yoshida Kan, Hashiba Yukari, Shimizu Chika, Yamamoto Etsuhide
journal or publication title	Oral Surgery, Oral Medicine, Oral Pathology, Oral Radiology, and Endodontics
volume	103
number	2
page range	169-174
year	2007-02-19
URL	http://hdl.handle.net/2297/3580

Evaluation of upper lip hypoesthesia with a trigeminal somatosensory-evoked potential following Le Fort I osteotomy in combination with mandibular osteotomy

KOICHIRO UEKI, DDS, PhD†; KIYOMASA NAKAGAWA, DDS, PhD‡; KOHEI MARUKAWA, DDS, PhD†; MAYUMI SHIMADA, DDS, PhD†; KAN YOSHIDA, DDS, PhD†; YUKARI HASHIBA, DDS#; CHIKA SHIMIZU, DDS#; ETSUhide YAMAMOTO, DDS, PhD § .

† Clinical Fellow.

Graduate Student.

‡ Associate Professor.

§ Chief Professor.

Department of Oral and Maxillofacial Surgery, Graduate School of Medicine, Kanazawa University, 13-1 Takaramachi, Kanazawa 920-8641, Japan.

Address correspondence to: Koichiro Ueki, DDS, PhD

Department of Oral and Maxillofacial Surgery, Graduate School of Medicine, Kanazawa University, 13-1 Takaramachi, Kanazawa 920-8641, Japan.

Tel: +81-76-265-2444; Fax: +81-76-234-4268

E-mail: kueki@med.kanazawa-u.ac.jp

Abstract

Purpose: The purpose of this study was to objectively evaluate hypoesthesia of the

upper lip following Le Fort I osteotomy in combination with mandibular osteotomy with trigeminal somatosensory-evoked potential (TSEP).

Subjects and Methods: The subjects consisted of 25 patients with mandibular prognathism with maxillary retrognathism mandibular prognathism with or without asymmetry, who underwent Le Fort I osteotomy in combination with sagittal split ramus osteotomy (SSRO) or intra-oral vertical ramus osteotomy (IVRO).

Trigeminal nerve hypoesthesia at the region of upper lip was assessed bilaterally by the TSEP method. The electrodes were placed exactly above the highest point of the vermilion border and on the mucosa of the upper lip. An electroencephalograph recording system (Neuropack Sigma™; Nihon Koden Corp., Tokyo, Japan) was used to analyze the potentials. Each patient was evaluated preoperatively and then postoperatively at 1 week, 2 weeks, 1 month, 3 months, 6 months and 1 year.

Results: The average measurable period and standard deviation of TSEP of the upper lip was 7.8 ± 10.7 weeks following Le Fort I osteotomy, TSEP of the lower lip was 4.6 ± 9.2 weeks in the patients who underwent SSRO with Le Fort I osteotomy, and 1.2 ± 0.4 weeks in the patients who underwent IVRO with Le Fort I osteotomy.

Conclusion: This study objectively proved that hypoesthesia could appear in the upper lips following Le Fort I osteotomy with TSEP. The measurable period for the upper lip following Le Fort I osteotomy tended to be longer than that for the lower lip in the patients who underwent SSRO and IVRO with Le Fort I osteotomy.

Key words: TSEP, upper lip, Le Fort I osteotomy

Introduction

Le Fort I osteotomy is commonly performed to correct various types of dentofacial deformities.¹⁻³ Advances in surgical techniques have reduced the number of complications related to the surgical mobilization of the maxilla, however, the sensitivity of maxilla after Le Fort I osteotomy is still unclear.

A disturbance of the sensitivity of the palatal mucosa of the premaxilla is inevitable with the down-fracture technique since the naso-palatine nerve is severed. Nevertheless, one year postoperatively a partial to total recovery of sensation to the affected area has been reported.⁴⁻⁶ It is generally considered that permanent damage to the infra-orbital nerve should be an avoidable complication. Rosenberg and Sailer found that 18 of 21 patients had a hypoesthesia of the upper lip area served by the infraorbital nerve one month postoperatively. Thus, three months postoperatively, the sensory function had virtually returned to the preoperative values and values at 6 months postoperative were attained using electrical sensimetry.⁷ It was therefore shown that permanent damage does not occur provided there is no incorrect retraction of the soft tissue.

Standard sensory testing modalities include the following: threshold of light touch perception, two-point discrimination threshold, temperature sensitivity,⁸ and trigeminal somatosensory-evoked potentials.⁹⁻¹³ The trigeminal somatosensory-evoked potential (TSEP) method is non-invasive, highly objective, and extremely reliable and it can be used to investigate the trigeminal sensory hypoesthesia of the lower lip after mandibular ramus osteotomy. However, there have been no reports regarding sensory

hypoesthesia of the upper lip following Le Fort I osteotomy using TSEP. Hypoesthesia following Le Fort I has not been objectively investigated beyond that following mandibular ramus osteotomy.

The purpose of this study was to objectively evaluate hypoesthesia of the upper lip following Le Fort I osteotomy in combination with sagittal split ramus osteotomy (SSRO) or intraoral vertical ramus osteotomy (IVRO) with TSEP.

Subjects and Methods

Subjects

The subjects comprised 25 Japanese adults (8 men, 17 women) presenting with jaw deformities diagnosed as mandibular prognathism with maxillary retrognathism and mandibular prognathism with or without bimaxillary asymmetry. At the time of orthognathic surgery, mean patient age was 23.6 years (standard deviation; 4.8 years, range; 16-34 years).

Surgery:

Of the 25 patients in this study, 16 underwent Le Fort I osteotomy and bilateral SSRO (by the Obwegeser method). Two PLLA L-type mini-plates (10×22×1.5 mm with 4 screws (2×8 mm), Fixorb[®]-MX; Takiron Co., Osaka, Japan) and two straight PLLA plates (28×4.5×1.5 mm with 4 screws (2×8 mm), Fixorb[®]-MX; Takiron Co.) were used to fix the maxilla and two PLLA mini-plates (28×4.5×1.5 mm with 4 screws

(2×8 mm), Fixorb[®]-MX; Takiron Co.) were used for bilateral internal fixation of the mandible.

Eight patients underwent Le Fort I osteotomy and IVRO without fixation to alter the occlusal cant, predominantly for correcting the asymmetry. After 1-2 weeks of MMF, elastics were placed to maintain ideal occlusion. PLLA plates were used in the same way. The other one patient underwent Le Fort I osteotomy alone.

Trigeminal nerve hypoesthesia was assessed bilaterally by the TSEP method. The methodology and values of the TSEP have been previously described in a preliminary study.¹¹⁻¹³ The method was applied to the upper lip. The electrodes were placed exactly above the highest point of the vermilion border and on the mucosa of the upper lip. An electroencephalograph recording system (Neuropack Sigma[™]; Nihon Kodan Corp., Tokyo, Japan) was used to analyze the potentials. The right and left sides were measured separately so that a total of 48 sides could be assessed. Each patient was evaluated preoperatively and then postoperatively at 1 week, 2 weeks, 1 month, 3 months, 6 months and 1 year.

Trigeminal hypoesthesia was assessed by the latency of P1 and N2 in the recorded TSEP spectra because these peaks produce an accurate figure and have a tendency of inducing a higher reproducibility among healthy volunteers. Measurable periods of TSEP were defined as those periods before the peaks of N1(N13), P1(P17), N2(N27), P2(P36) and N3(N46) that were clearly identified on early components of the TSEP wave (Fig. 2).

The measurable period was determined as the time when TSEP was first measurable postoperatively. Measurement of TSEP after surgery was continued until

TSEP became measurable.

Data were statistically analyzed using the StatView™ version 4.5 software (ABACUS Concepts, Inc., Berkeley, CA, USA). Differences between groups were analyzed using Scheffe's F test. Differences were considered significant at $P < 0.05$.

Results

There were no complications such as fracture of the proximal segments or abnormal bleeding during surgery. After surgery, no patient had a wound infection or dehiscence, bone instability or non-union, or long-term malocclusion. Facial muscle dysfunction derived from facial nerve injury was not observed.

The average measurable period and standard deviation of TSEP of the upper lip following Le Fort I osteotomy was 7.8 ± 10.7 weeks, TSEP of the lower lip was 4.6 ± 9.2 weeks in the patients who underwent SSRO with Le Fort I osteotomy, and 1.2 ± 0.4 weeks in the patients who underwent IVRO with Le Fort I osteotomy. Although, there were significant differences between these groups, the measurable period of the upper lip following Le Fort I osteotomy tended to be longer than those of the lower lip in patients who underwent SSRO and IVRO with Le Fort I osteotomy ($P=0.0508$). There were no significant differences between the right and left sides in all groups.

In 21 of 50 (42%) sides of the upper lip following Le Fort I osteotomy, TSEP was measurable within 1 week, for 28 sides (56%) within 2 weeks, 36 sides (72%) within 1 month, 39 sides (78%) within 3 months, 49 sides (98%) within 6 months and for 50 sides (100%), it was recovered within 1 year.

On the other hand, in 17 of 34 (50%) sides of the lower lip following SSRO with Le Fort I osteotomy, TSEP was measurable within 1 week, for 24 sides (70.4%) within 2 weeks, 28 sides (82.4%) within 1 month, 31 sides (91.2 %) within 3 months, 32 sides (94.1 %) within 6 months and for 33 sides (97.1%), it was recovered within 1 year. one side remained immeasurable postoperatively for 1 year.

In 14 of 16 (87.5%) sides of the lower lip following IVRO with Le Fort I osteotomy, TSEP was measurable within 1 week, for 15 sides (93.8%) within 2 weeks and for 16 sides (100%), it was recovered within 1 month.

In the within-subject comparisons, there were significant differences between pre-operation and 1 month ($P=0.00424$) in N1; between 1 month and 6 months (0.0026), 1 month and pre-operation ($P<0.0001$), and 2 weeks and pre-operation ($P=0.0006$) in P1; between pre-operation and 1 week ($P=0.0238$), 2 weeks and pre-operation ($P=0.0190$) in N2; between 1 week and 6 months ($P=0.0144$), 1 week and pre-operation ($P=0.0126$), 2 weeks and 6 months ($P=0.0260$) and 2 weeks and pre-operation ($P=0.0229$) in P2 regarding TSEP of the upper lip following Le Fort I osteotomy (Fig. 3).

On the other hand, there were significant differences between 1 week and pre-operation ($P=0.0333$), between 3 months and pre-operation ($P=0.0008$), between 6 months and pre-operation ($P=0.0017$) in N1, and between 1 month and pre-operation ($P=0.0478$), between 1 week and pre-operation ($P=0.0030$) and between 3 months and pre-operation ($P=0.0090$) in N2, and between 1 week and pre-operation ($P=0.0180$) in P2 in TSEP of lower lip following SSRO with Le Fort I osteotomy (Fig. 4).

There were no significant differences in N1, P1, N2 and P2 in TSEP of lower lip following IVRO with Le Fort I osteotomy (Fig. 5).

Discussion

The sensory innervation of the surgical area involved in Le Fort I osteotomy falls within the distribution of the second division of the trigeminal nerve. This is a distinct area of the anterior part of the nasal septum and lateral nasal wall which is served by internal nasal branches of the anterior ethmoidal nerve (from the first division of the trigeminal nerve). After emerging from the middle cranial fossa through the foramen rotundum, the maxillary nerve crosses the pterygopalatine fossa and enters the orbit through the infraorbital fissure, now called the infraorbital nerve. Having traversed the infraorbital canal, it emerges through the infraorbital foramen to supply the skin of the mid-face and the mucous membrane of the cheek and lip.¹⁴

In Le Fort I osteotomy, the three superior alveolar nerves are transected as part of the osteotomy, and the terminal labial branches of the infraorbital nerve are transected as part of the mucosal incision. After the infraorbital nerve emerges from the infraorbital foramen, it may be subjected either to direct laceration or to traction injury, as a result of the forceful use of retractors during the operation.¹⁵

Previous studies have reviewed the complications and long-term results of the Le Fort I osteotomy.^{5,6} In the early period after surgery all patients experienced decreased facial sensibility in the infraorbital nerve distribution and in the oral mucosa inferior to

the vestibular incision. Sensory recovery was reported to have occurred in most patients between 6 and 12 months after the operation. A careful review of these studies reveals that sensibility assessment was carried out using only a sharp probing technique.

Although, there has not been a study using TSEP for assessment of hypoesthesia in the upper lip after maxillary osteotomy, this method could be usefully adopted for the upper lip area as well as the lower lip. TSEP, is one of the somatosensory-evoked potentials of the peripheral nerves, and has been previously used to investigate causal factors of trigeminal sensory hypoesthesia after sagittal ramus osteotomy. The changes in potential of cerebral origin can be detected on the scalp in human subjects after electrical stimulation of the peripheral nerves. Trigeminal hypoesthesia is indicated by a prolonged detection of changes in the potential on the scalp after peripheral electrical stimulation (a latency delay) and may be induced by various causal factors such as compression or decompression injury, bone cut, fixation method, patient age, or the amount of segmental movement.¹⁶⁻¹⁹

In simple sensory test such as 2-point sensory discrimination, collection of output data depends on patient's view with their bias, even if input data such as stimulating pressure is objective. However, TSEP data is directly collected from their electroencephalography derived from cerebral cortex so that data of TSEP could be more objective and reliable. Thus, difference between objective and subjective assessment may occur. Furthermore, there may be also difference between actual return of feeling and registration of nerve conduction. Advancements in the field of neurophysiology have revealed posttraumatic change in the central nervous system.

Functional disturbance in the central nervous system after peripheral nerve injury is known as central sensitization.^{20,21} Actual return of feeling may not always occur with recovery in peripheral nerve.

In this study, hypoesthesia of both the upper and lower lip was measured in each patient so that the difference between upper and lower hypoesthesia after osteotomy could be compared, although we have reported hypoesthesia after SSRO.¹¹⁻¹³ Interestingly, the measurable period of the upper lip following Le Fort I osteotomy tended to be longer than those of the lower lip in the patients who underwent SSRO and IVRO. This may be due to the surgical technique used. We have changed the SSRO procedure from the Obwegeser Dal-Pont method to the Obwegeser method on the basis of previous data on TSEP.¹³ Therefore, the recovery period of hypoesthesia of lower lip might tend to be short in this study. It is well-known that IVRO has a lower rate of incidence of hypoesthesia after surgery.

From our results, although transit hypoesthesia of the upper lip after Le Fort I osteotomy occurred, there recovered within one year.

In general, comparing between subjects, the pre-operative latency period was significantly shorter than other post-operative periods in N1, P1, N2 and P2 following Le Fort I osteotomy. This showed that surgical invasion could induce a prolongation of the latency period for TSEP as well as after SSRO, although a measurement could be made. In IVRO, the sample number was very small and incidence rate of hypoesthesia was low so that there were therefore significant differences between pre-operative and other post-operative periods.

Regarding fixation material, although PLLA plates were used to fix the maxilla after Le Fort I osteotomy in this study, it remained unclear whether fixation material affects the hypoesthesia following osteotomy. Therefore, further investigation will be needed.

Conclusion

This study objectively shows that hypoesthesia occur in the upper lip following Le Fort I osteotomy with TSEP. The measurable period (i.e, when TSEP wave appeared firstly after surgery) of the upper lip following Le Fort I osteotomy tended to be longer than that of the lower lip in the patients who underwent SSRO and IVRO with Le Fort I osteotomy.

References

1. Proffit WR, Phillips C, Prewitt JW, Turvey TA. Stability after surgical-orthodontic correction of skeletal Class III malocclusion. 2. Maxillary advancement. *Int J Adult Orthodn Orthognath Surg* 1991; 6: 71-80.
2. Proffit WR, Turvey TA, Phillips C. Orthognath Surgery: a hierarchy of stability. *Int J Adult Orthodon Orthognath Surg* 1996; 11:191-204.
3. Bell WH, Proffit WR, White RP. *Surgical Correction of Dentofacial Deformities*. Philadelphia: Saunders, 1980; 353-359.
4. Nelson RL, Path G, Ogle RG, Waite DE, Meyer MW. Quantitation of blood flow after Le Fort I osteotomy. *J Oral Surg* 1977; 35:10-16.
5. de Jongh M, Barnard D, Birnie D. Sensory nerve morbidity following Le Fort I ostotomy. *J Maxillofac Surg* 1986; 14:10-13.
6. Kahnberg KE, Engström H. Recovery of maxillary sinus and tooth sensibility after Le Fort I osteotomy. *Br J Oral Surg* 1987; 25:68-73.
7. Rosenberg A, Sailer HF. A prospective study on change in the sensibility of the oral mucosa and the mucosa of the upper lip after Le Fort I osteotomy. *J Craniomaxillofac Surg* 1994; 22:286-293.
8. Lemke RR, Rugh JD, Van Sickels J, Bays RA, Clark GM. Neurosensory differences after wire and rigid fixation in patients with mandibular advancement. *J Oral Maxillfac Surg* 2000; 58: 1354-1359.
9. de Beukelaer JG, Smeele LE, van Ginkel FC. Is short-term neurosensory testing after removal of mandibular third molars efficacious? *Oral Surg Oral Med Oral Pathol* 1998; 85: 366-370.

10. Jones DL, Wolford LM. Intraoperative recording of trigeminal evoked potentials during orthognathic surgery. *Int J Orthod Orthognath Surg* 1990; 5: 167-174.
11. Nakagawa K, Ueki K, Matsumoto N, Takatsuka S, Yamamoto E, Ooe H. The assessment of trigeminal sensory nerve paraesthesia after bilateral sagittal split osteotomy: modified somatosensory evoked potentials recording method. *J Craniomaxillofac Surg* 1997; 25: 97-101.
12. Nakagawa K, Ueki K, Takatsuka S, Daisuke T, Yamaomoto E. Somatosensory-evoked potential to evaluate the trigeminal nerve after sagittal split osteotomy. *Oral Surg Oral Med Oral Pathol Oral Radiol Endod* 2001; 91: 146-152.
13. Nakagawa K, Ueki K, Takatsuka S, Yamamoto E. Trigeminal nerve hypesthesia after sagittal split osteotomy in setback cases: Correlation of postoperative computed tomography and long-term trigeminal somatosensory evoked potentials. *J Oral Maxillofac Surg* 2003; 61: 898-903.
14. Gray HG. *Gray's Anatomy*, 36th .Ed. Williams PL and Warwick R. Churchill Livingstone, Edinburgh 1980:1062-1066.
15. Posnick JC, Mohammed M, Al-Qattan M, Pron G. Facial sensitivity in adolescents with and without clefts 1 year after undergoing Le Fort I osteotomy. *Plast Reconstr Surg* 1994; 94:431-435.
16. August M, Marchena J, Donady J, Kaban L. Neurosensory deficit and functional impairment after sgittal split ramus ostetomy: a long-term follow-up study. *J Oral Maxillofac Surg* 1998; 56:1231-1235.

17. Blomqvist JE, Alberius P, Isaksson S. Sensibility following sagittal split osteotomy in the mandible: a prospective clinical study. *Plast Reconstr Surg* 1998; 102:325-333.
18. Westermarck A, Bystedt H, von Konow L. Inferior alveolar nerve function after mandibular osteotomies. *Br J Oral Maxillofac Surg* 1998; 36:425-428.
19. Westermarck A, Bystedt H, von Konow L. Inferior alveolar nerve function after sagittal split osteotomy of the mandible: correlation with degree of intraoperative nerve encounter and other variables in 496 operations. *Br J Oral Maxillofac Surg* 1998; 36:429-433.
20. Coderre TJ, Katz J, Vaccarino AL, Melzack R. Contribution of central neuroplasticity to pathological pain: review of clinical and experimental evidence. *Pain* 1993; 52:259-85.
21. McQuay HJ, Carroll D, Jadad AR, Glynn CJ, Jack T, Moore RA, et al. Dextromethorphan for the treatment of neuropathic pain: a double-blind randomized controlled crossover trial with integral n-of-1 design. *Pain* 1994; 59:127-33.

Figure legends

Fig.1 TSEP wave form. Measurable periods of TSEP were defined as those periods before the peaks of N1, P1, N2, P2 and N3 that were clearly identified on early components of the TSEP wave. Amplitude value (μV) and latency periods (msec) were shown in this graph.

Fig. 2 Average latency period of TSEP at the region of the upper lip following Le Fort I osteotomy

Error bar shows standard deviation.

Fig. 3 Average latency period of TSEP at the region of the lower lip after SSRO with Le Fort I osteotomy

Error bar shows the standard deviation.

Fig. 4 Average latency period of TSEP at the region of the lower lip after IVRO with Le Fort I osteotomy

Error bar shows the standard deviation.

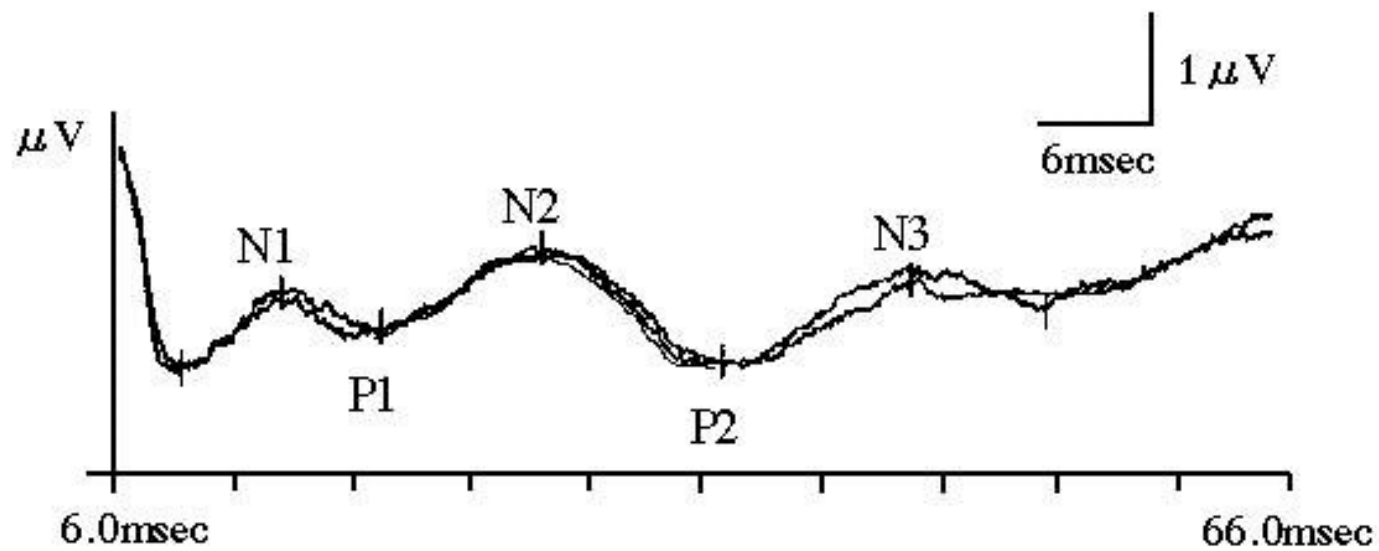


Fig.1

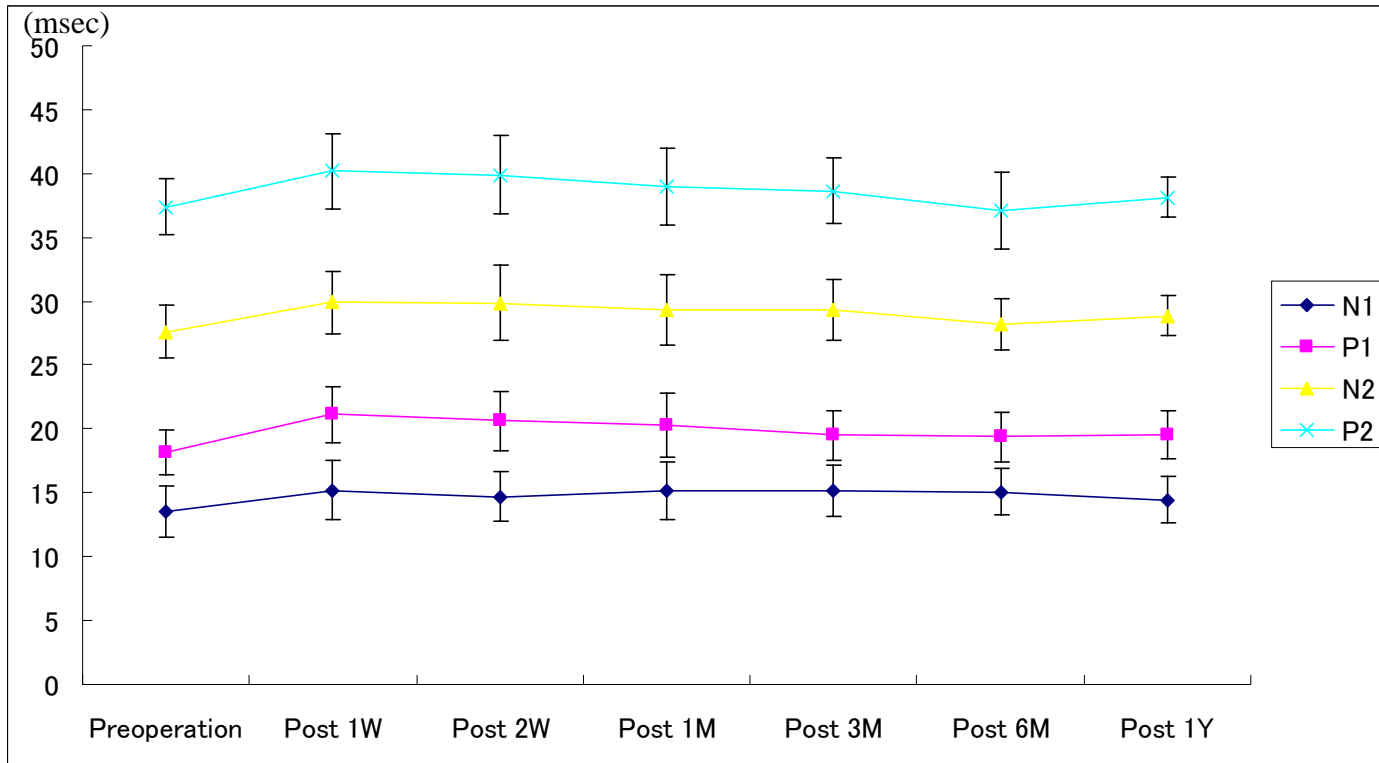


Fig. 2

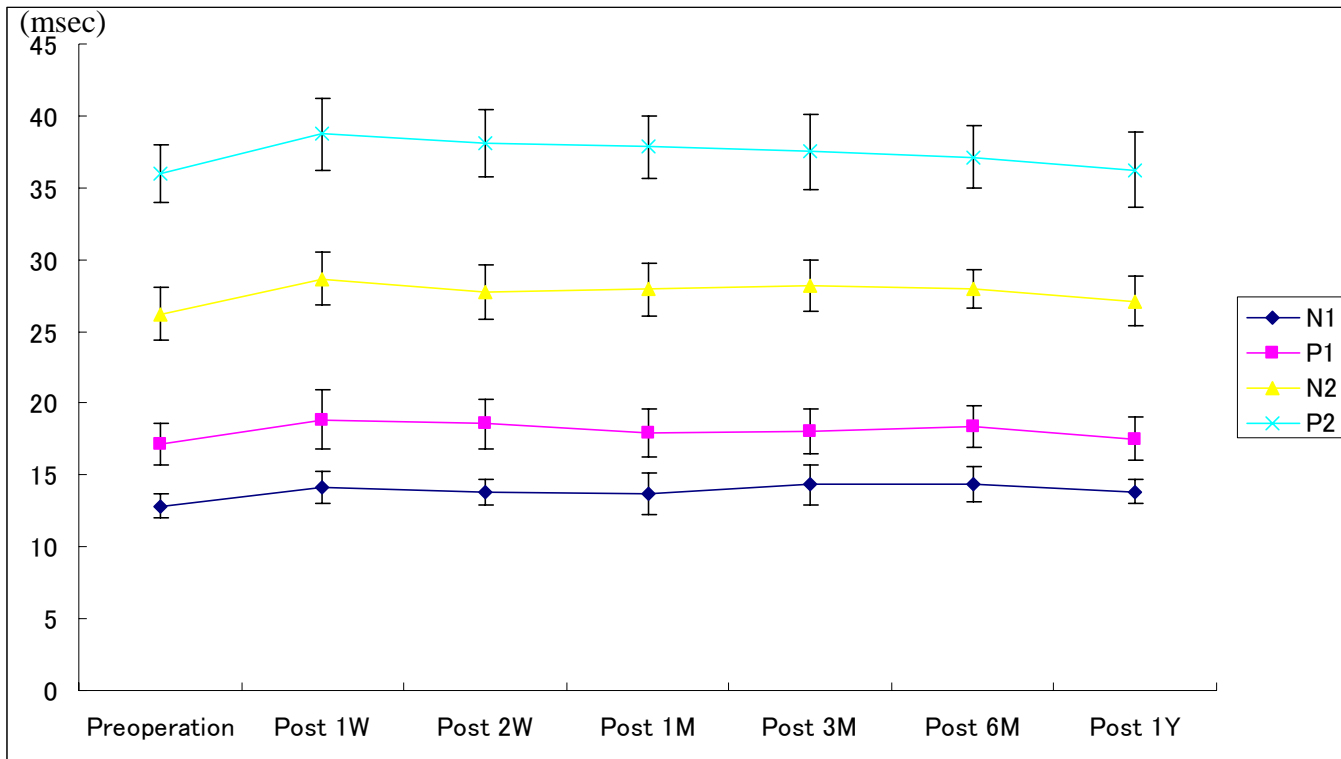


Fig. 3

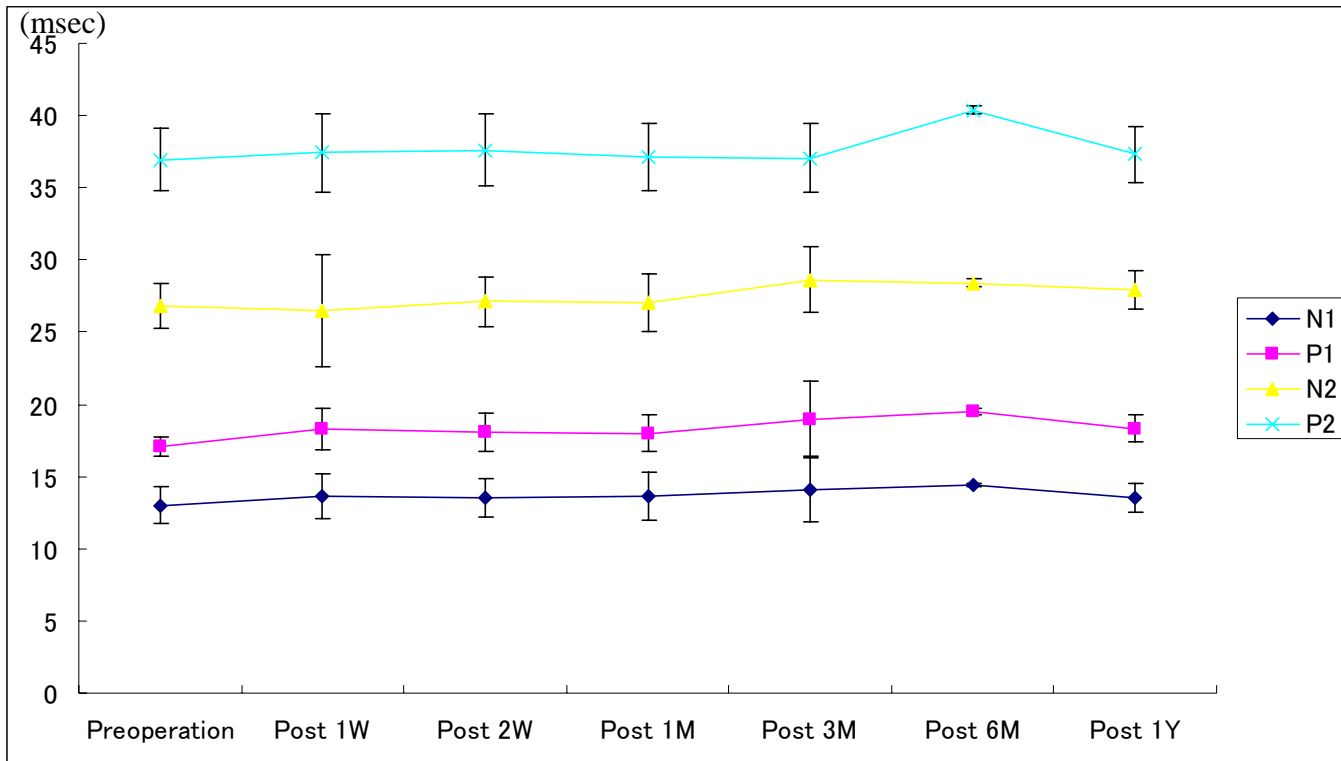


Fig. 4