

Human heme oxygenase-1 deficiency: A lesson on serendipity in the discovery of the novel disease

著者	Koizumi Shoichi
journal or publication title	Pediatrics International
volume	49
page range	125-132
year	2007-04-01
URL	http://hdl.handle.net/2297/6757

doi: 10.1111/j.1442-200X.2007.02353.x

Invited paper

Human heme oxygenase (HO) -1 deficiency

A lesson on serendipity from the discovery of the novel disease

From the presidential address of the 109th Annual Meeting of the Japan Pediatric Society

Running title: HO-1 deficiency

Shoichi Koizumi, MD, PhD

Angiogenesis and Vascular Development (Department of Pediatrics)

Kanazawa University Graduate School of Medical Science and School of Medicine

S. Koizumi, MD: Department of Pediatrics, Kanazawa University Hospital, 13-1 Takaramachi,

Kanazawa 920-8641, Japan

Phone: 81 76 265 2314, Fax: 81 76 262 1866, e-mail: skoizumi@med.kanazawa-u.ac.jp

Text pages: Reference pages: Tables: Figures: Legends:

The first case of human heme oxygenase (HO) - 1 deficiency was reported by Yachie et al. at our laboratory in 1999.^{1,2} In the present paper, I would like to review this novel disease. Our studies into HO-1 deficiency were called by us "Kanazawa version Project X". From the story of our successful discovery we have learned that serendipity is a very important spiritual factor. Serendipity is the making fortunate and unexpected discoveries by chance [from its possession by the heroes in the Persian fairy tale *The Three Princes of Serendip*].

Enzymology and molecular biology of HO

HO is the rate-limiting enzyme that adds an oxygen molecule to the porphyrin ring of heme, thereby catalyzing the oxidation of heme to biliverdin, free iron, and carbon monoxide (CO) (Figure 1). Biliverdin is subsequently metabolized to bilirubin by the enzyme biliverdin reductase. By producing bilirubin, CO, and iron/ferritin, HO plays a crucial role in humans as a defense factor against a variety of oxidative stresses.³⁻⁷

Three isoforms of HO have been identified; HO-1, HO-2, and HO-3.³ Most interestingly, HO-1 is rapidly induced in liver, spleen, endothelium, and other tissues following exposure to various oxidative and other stresses. In contrast, HO-2 is constitutively expressed and widely distributed in the body, especially in the brain and testes, at higher concentrations.

The genes for human HO-1 and HO-2 have been isolated and mapped to chromosomes 22q13.1 and 16p13.3, respectively. HO-3, which has a high degree of amino acid identity to HO-2, is not present in humans and has been isolated only from rats. The human HO-1 gene is about

14 kb long and organized into five exons encoding a 32,800 Da molecule containing 288 amino acids.³

Case presentation

Clinical studies and laboratory data relating to the first case of HO-1 deficiency have previously been described in detail.^{1,2} Briefly, the male patient was born in 1992, and from the age of 2 suffered from recurrent high fever, xanthema, and hepatomegaly. An elder sister and an elder brother are in good health, but the mother had previously had two intrauterine fetal deaths. His birth weight was 2,029 kg at a gestational age of 38 weeks. Growth retardation of -2 standard deviations was noted. A mild motor developmental delay was apparent in infancy, but his intellectual development was approximately normal. In addition to fever, rash, and hepatomegaly, arthralgia without swelling and generalized lymphadenopathy developed. The saddle nose and frontal bossing of his face looked slightly strange, but no congenital disorder such as gargoylism was detected. The lungs and heart showed no abnormalities, but asplenia was confirmed by abdominal ultrasonography and isotope image scanning.

One of the most characteristic findings in laboratory examinations was that normal clear serum was not obtained following centrifugation of peripheral blood samples, as illustrated in the original report, because of the presence of fragmented red blood cells in the blood.² Giant platelets and numerous erythroblasts were noted, and dysmorphic monocytes were also observed. There was a surface lipid layer following centrifugation of venous blood. Hematuria and proteinuria were consistently present. Severe microcytic hypochromic anemia was noted. The numbers of white

blood cells and platelets were extraordinarily increased. The CRP level was consistently high. Levels of lactate dehydrogenase and serum ferritin were remarkably increased. Marked abnormalities of the coagulation/fibrinolysis system were noted. Some adhesion molecules involved in vascular endothelial metabolism, including thrombomodulin, Von Willebrand factor, ICAM1, and selectins were also remarkably increased. Autoantibodies were not detectable by Coombs' test. The serum heme concentration was extremely high as shown in the original paper.² Although intravascular hemolysis was strongly indicated, serum bilirubin levels were consistently within the normal range; serum haptoglobin levels, in contrast, remained extremely high. Hypertriglyceridemia and hypercholesterolemia were consistently observed. Bone marrow aspiration showed no abnormal findings. As far as hemolytic diseases are concerned, examinations including hemoglobin absorbance spectrum analysis and electrophoresis for hemoglobinopathies indicated no abnormalities. Although the patient received aggressive therapeutic support, including frequent blood transfusions, he finally died of an intracranial hemorrhage at 6 years of age. The autopsy report was published by Kawashima et al.⁸

The patient's problem lists are shown in Table 1, these were (1) enhanced systemic inflammatory reactions, (2) intravascular hemolysis with erythrocyte-crushing symptom-complex, (3) marked abnormalities of the coagulation/fibrinolysis system, (4) nephropathy and systemic vascular endothelial disturbance, and (5) asplenia.

Discovery of HO-1 deficiency

What on earth was the diagnosis for the patient? A number of residents and doctors had

examined the patient and considered a diagnosis without success. Second opinions had been pursued in many laboratories, even overseas, without any light being shed on the matter.

One day, I noticed once again a contradiction in the problem list which indicated that the patient had erythrocyte-crushing symptom-complex, with resultant intravascular hemolysis, and yet there was no elevation of the serum bilirubin level and the serum haptoglobin level had not declined to zero but, on the contrary, remained consistently high. I opened my old biochemistry textbook and checked the metabolic map of heme through bilirubin. I was reminded that two enzymes were involved in the pathway, HO and biliverdin reductase, and that HO was the important rate-limiting enzyme in heme metabolism. This was indeed of great significance in enabling the project to advance to the next stage. HO-1 had fortunately already been recognized by a number of biochemists as an important defense factor against oxidative stress in humans, and because of this the gene analysis had been completed and several antibodies were already on the market. It was very fortunate that we were immediately able to prepare an antibody (antiserum) against HO-1 protein.

Immunohistochemical analysis using hepatic biopsy specimens demonstrated that, although intense HO-1 staining could be observed within Kupffer cells in control liver, no HO-1 staining was detectable in the patient's liver. Transformed lymphoblastoid cell lines (LCLs) were then established from the HO-1-deficient patient. Western immunoblotting analysis of HO-1 and HO-2 using LCLs clearly showed no HO-1 protein was produced by the patient's LCLs, even after their subjection to oxidative stress by cadmium, arsenic trioxide and hemin (Figure 2). HO-2 protein was consistently noted in both the patient's and control LCLs.²

Genetic analysis was performed immediately and revealed that the patient's HO-1 gene

was completely lacking exon 2 in the maternal allele and had a two-nucleotide deletion within exon 3 in the paternal allele. Soon after, a large genomic deletion (1730 bp) including exon 2 in its entirety, probably mediated by homologous recombination with the *Alu* repeating sequence, was defined in the patient.⁹

The paper regarding the first case of human HO-1 deficiency was published by Dr. A. Yachie as first author in the *Journal of Clinical Investigation* in 1999.² Because this is the only case in the world to date, and there have thus been no further case reports, the complete nature of the disease has not been clarified. There still remain several questions; for example, asplenia without cardiac anomalies has not previously been reported. However, the discovery of the first patient with HO-1 deficiency has addressed the physiologically crucial role of HO-1 in the human body, and highlighted an academic breakthrough in the field of defense mechanisms against various oxidative stresses.

HO-1 knockout mice

At least two strains of HO-1 knockout mice have been generated, by Poss and Tonegawa at the Massachusetts Institute of Technology^{10,11} and Yet et al. at Harvard Medical School.¹² A comparison of clinical findings in the HO-1 deficient patient and HO-1 knockout mice is shown in Table 2; pathological findings have been described elsewhere.⁵ Although there are many similarities between the two species, including prenatal death, developmental failure, iron-deficiency anemia, and chronic systemic inflammatory disorders, almost the only difference between them is the occurrence of asplenia in the human HO-1 deficient patient which contrasts with the

splenomegaly observed in the knockout mice.

Pathophysiology of human HO-1 deficiency

As illustrated in Figure 3, HO-1 deficiency results in a remarkable elevation of heme concentration and contrasting reductions in bilirubin, iron-binding ferritin, and CO. Heme is one of the strongest oxidative stress agents, and low production of bilirubin and ferritin results in breakdown of the body's defense system. Clinically, disturbances of the iron-reuse system, functional disorders of hematological cells, especially monocytes/macrophages, and renal disturbances follow. Low levels of CO production may be involved in homeostasis of the microvascular system. Extreme disturbance of this system could lead to the complex features seen in the patient.

HO-1 and monocytes/macrophages

HO-1 expression on the surface of monocytes in normal peripheral blood, but not lymphocytes, was remarkable.^{3,13,14} Monocytes from the patient with HO-1 deficiency showed remarkable morphological changes, with abnormal surface antigens including HLA-DR, CD36, and CD11b, as shown previously.^{3,14} A disturbance of phagocytic function was also observed in the patient. These findings indicate that HO-1 plays a crucial role in monocyte function, and that the HO-1 defect resulted in the severe systemic inflammation that occurred in the patient.

Recently, several subpopulations of peripheral blood monocytes have been separated in our laboratory on the basis of their expression of surface antigens such as CD14, CD16, and CCR2, their

production of cytokines such as IL-6 and TNF- α , and their functional roles in vivo.¹⁵ We demonstrated the selective expansion of a subpopulation of circulating monocytes that preferentially produced HO-1 during the acute phase of infectious diseases including Kawasaki disease and influenza virus infection.^{13,15}

A beautiful review in Trends in Immunology showed how the induction of excessive HO-1 or CO expression in normal monocytes and macrophages could suppress the proinflammatory response while, at the same time, boosting the anti-inflammatory response in the lipopolysaccharide-stimulating system (Figure 4).¹⁶ Another review described how the HO-1 molecule also plays a role in the regulation of regulatory T cell and antigen-presenting cell function via interferon- γ production (Figure 5).¹⁷

HO-1 and renal diseases

Three renal specimens from the patient were examined, two renal biopsies and a third sample obtained at autopsy.¹⁸ The tubulointerstitial damage was striking. The size of the injured area progressively increased, occupying 0.7% of the first biopsy, 17.4% of the second, and 40.2% of the autopsy sample, as described previously.¹⁸ Using immunohistochemical analysis, moderate-to-intense HO-1 expression was observed within the tubular epithelial cells in various renal diseases, but was not detected within intrinsic glomerular cells.¹⁹ HO-1 staining tended to be more intense within distal tubules than proximal tubules. It was intriguing that characteristic HO-1 staining was also noted in a patient with minimal change nephrotic syndrome in remission, in which no apparent tubular damage is usually seen. These findings indicate that renal tubular epithelial

cells are constantly exposed to various toxic stresses. Within the proximal tubules, higher degrees of HO-1 expression correlated significantly with greater degrees of proteinuria and hematuria.¹⁹

Further studies using in situ hybridization methods showed that HO-1 mRNA was readily detectable within tubular cells, and even within glomerular and Bowman's epithelial cells with lesser intensity.²⁰ Different patterns of HO-1 gene expression were also observed between proximal and distal tubules. Further experimental studies were performed to compare the patterns of oxidative stress-induced HO-1 expression between primary cultured human mesangial cells (HMC) and renal proximal tubular epithelial cells (HRPTEC).²¹ The results showed that HO-1 mRNA expression and protein production by HMC peaked earlier, at 4 h to 6 h after hemin stimulation, and that the levels of each declined rapidly compared with HRPTEC.²¹ These findings indicate that HO-1 expression is regulated in a manner that is cell-, tissue-, organ segment-, and stress antigen-specific.

HO-1 and endothelial cell injuries

Although there were no significant changes in the walls of major vessels in autopsy specimens from the patient, with no necrotic changes and no cell infiltration or fibrosis,⁸ laboratory data strongly suggested systemic vascular endothelial cell injury with massive intravascular hemolysis.² Interestingly, electron microscopic examination revealed widespread endothelial detachment and subendothelial deposits of unidentifiable material in the renal glomerular capillary loops as shown previously.² We may therefore propose that HO-1 deficiency constitutes a novel form of vasculitis or endothelial cell injury syndrome encompassing a wide variety of clinical manifestations.³ The unexpected occurrence of endothelial cell injury without major changes to the

vessels might be related to the monocyte/macrophage dysfunction in HO-1 deficiency.³

HO-1 and cardiovascular disorders

Recent advances in vascular biology have revealed that HO-1 is markedly involved in cardiovascular homeostasis and systemic vascular disease.^{23,24} Oxidative modification of low-density lipoprotein (LDL) in the subendothelial space is recognized as an early event in atherogenesis.²³ Endothelial cell dysfunction then accelerates the adherence of monocytes/macrophages and T lymphocytes to the endothelium, and macrophages become foam cells after the accumulation of lipid in combination with T cells and smooth muscle cells. The proliferation of intimal smooth muscle cells is known to be a key event in the development of advanced atherosclerosis. A large number of growth factors and cytokines participate in this process, and it is suggested that HO-1 regulates the system. HO-1 may inhibit the development of atherosclerosis via the upregulation or downregulation of specific molecules at various stages.²³ Importantly, special analysis of plasma from the HO-1-deficient patient revealed ongoing in vivo heme-catalyzed LDL oxidation.^{7,24} In addition, increased cytotoxicity induced by heme-catalyzed oxidation of LDL in the patient's lymphoblastoid cells was demonstrated.²⁴

HO-1 protects the heart.²⁵ Right ventricular dilatation and thrombus formation were reported in HO-1 knockout mice in response to hypoxia.¹² In xenograft heart transplantation experiments, such as from mouse-to-rat, only transplanted hearts able to express HO-1 survived indefinitely. Lack of the gene led to rejection in just a few days. If, however, both donor and recipient were treated with CO, the transplanted heart survived in the long-term.²⁶

HO-1 is speculated to play another important role in angiogenesis.²⁷ HO-1 knockout mice have hypoplastic arteries when compared with controls.²⁸ We need to carefully evaluate the asplenia in the patient with HO-1 deficiency. Asplenia without heart anomalies, as in the patient, might suggest a hypothesis whereby HO-1 gene expression is correlated with splenogenesis and/or splenic arteriogenesis in the fetus.

HO-1 and pulmonary disease

We have observed that HO-1 expression in lung is localized in the peribronchiolar epithelium and blood vessel endothelial cells, as well as in alveolar macrophages (unpublished data). HO-1 expression was much more intense in lung specimens from patients with secondary pulmonary hypertension than from those with congenital primary pulmonary hypertension (unpublished data). The involvement of HO-1 in respiratory conditions such as experimental bronchial asthma²⁹ and oxidant-induced lung injury in mice has been described.³⁰

Polymorphism within the HO-1 promoter region

The next thing to summarize is that the cytoprotective effect of HO-1 is associated with GT repeat polymorphism in the promoter region of the gene. A 20 to 30 GT repeat polymorphism has been described.³¹ Individuals with shorter GT repeats are known to have a reduced risk of restenosis after angioplasty.³² HO-1 gene promoter polymorphism has been shown to be associated with renal allograft function.³³ A higher frequency of pulmonary emphysematous lesions has also been noted in cigarette smokers with a longer GT repeat.³⁴ In terms of the biological mechanism

underlying these associations, *in vitro* studies of lymphoblastoid cell lines have indicated that HO-1 gene polymorphism is associated with the strength of the antiapoptotic effect of HO-1 in response to oxidant-induced stresses.³⁵

HO-1 and nervous system

Like haptoglobin, hemopexin is another plasma protein that binds heme with high affinity. Although the monocyte/macrophage protein CD163 is known to be a scavenger receptor for hemoglobin/haptoglobin,³⁶ the hemopexin-heme complex is cleared from the circulation by the low-density lipoprotein receptor-related protein (LRP)/CD91 (Figure 6).³⁷ Hemopexin is abundant in cerebrospinal fluid. In addition to its expression in macrophages, LRP/CD91 is highly expressed in several other cell types, such as neurons.³⁷ Hence, HO-1 induced after heme uptake by LRP/CD91 appears to play a key role in neurodegenerative diseases such as Alzheimer disease.³⁸ A protective effect of HO-1 in cerebral vascular impairment in rats has been reported.³⁹

HO-1 gene transfection and hemin-induced cell injury of transfected cells

Transfection of the HO-1 gene into LCLs from the patient were performed using a retroviral vector.^{3,13} Positive expression of HO-1 protein by the transfected LCLs was confirmed by flow cytometry and immunohistochemistry. However, the HO-1 expression pattern in the transfected LCLs was constitutive but not inducible, as shown physiologically. When HO-1-transfected LCLs were stimulated by different concentrations of hemin, significant inhibition of cell injury was observed in a dose-dependent manner, in contrast to untransfected LCLs from the

patient which were seriously injured.^{3,13} Inhibition of cell injury was also confirmed in our laboratory using an HO-1-transfected anchorage-dependent ECV304 cell line.⁴⁰ Among the different clones of HO-1-transfected ECV304 cells, those expressing a moderate level of HO-1 showed enhanced cell survival under oxidative stress compared with wild-type cells. In contrast, however, a representative clone expressing a high level of HO-1 exhibited enhanced cell injury, suggesting that excessive levels of HO-1 exerted a paradoxical effect on cell survival.⁴⁰ This might well be because, despite constitutive expression of the HO-1 gene in both ECV304 and patient LCL HO-1-transfected cell lines, there is no stress-inducible expression that is recognized physiologically. This suggests that consideration should be given to physiologically-recognized stress-inducible HO-1 gene expression in future gene therapy trials.

HO-1 as a “therapeutic funnel”

HO-1 has been described as a “therapeutic funnel”.¹⁶ As shown in Figure 7, a number of molecules exert their effect by “feeding through” HO-1, and induce and activate HO-1. The products of HO-1 activity, biliverdin/bilirubin, CO, and free-Fe/ferritin then provide the protective effects. Collectively, HO-1 serves as a “protective” gene by virtue of its anti-inflammatory, anti-apoptotic, and anti-proliferative actions. Clinically, HO-1 has attracted widespread attention in various fields, including cardiovascular ischemia and reperfusion injury, as well as atherosclerosis, hypertension, and systemic inflammatory, renal, and nervous disorders, as described above. Examination of PubMed shows an almost two-fold increase in the number of publications regarding HO-1 in the past few years as compared with approximately 10 years ago.

Serendipity

The discovery of the novel disease, HO-1 deficiency, was rather like the story of “Columbus’ egg” when we took a backward glance. “Columbus’ egg” means the tradition that Columbus stood a raw egg on its end on the table; a thing that looks easy once it has been done. Hemolysis, hypobilirubinemia, and hyperhaptoglobulinemia were actually the three key words that led to elucidation of the new disease. My memory is still strong of the moment we observed that the Kupffer cells of the patient showed no HO-1 staining, suggesting a novel disease. Why did no one turn their attention to HO-1 more speedily? Is there any idea how to stimulate the faculty of finding valuable or agreeable things not sought for more promptly?

Before finishing this review, I would like to think about serendipity. Recently, brain scientists have paid special attention to serendipity; the faculty of making fortunate and unexpected discoveries by chance [named after its possession by the heroes in the Persian fairy tale *The Three Princes of Serendip*.] How can we combine an unexpected chance with something that is valuable? It has been said that this depends on continuous mental exercise targeting the brain that involves at first moving into action, followed by continuous observation and daily concentration on the relevant questions. Secondly, it is very important for us to be aware of even trifling matters and, finally, not to give up, but to accept things as they are. The proverbs say “Take time by the forelock, for he is bald behind” and “Opportunity seldom knocks twice at any man’s door.” Another proverb says, “Chance finally is delivered to the person possessing superior knowledge and excellent technology.”

We have to continually think about serendipity, allowing our minds to act, observe, and

accept things, without discarding them because they are small. We will then be able to succeed in breaking through the problems, as was the case, for example, with the discovery of the novel disease, human HO-1 deficiency.

Acknowledgments

The author thanks all the members of our laboratory, especially Dr A. Yachie, chief of the special team of the Kanazawa version Project X regarding the first case of human HO-1 deficiency, and Drs N. Taniguchi, N. Okuda, K. Ota, K Ota, Y. Kasahara, Y. Niida, Y. Saikawa, T. Wada, and T. Toma. The author thanks Dr Y. Tsunematsu for providing the biopsy materials, Dr M. Suematsu for giving a monoclonal antibody against HO-1, and Dr A. Kawashima for reporting the pathologic autopsy record. This work was supported by grants-in-aid for research by the Ministry of Education, Culture, Sports, Science and Technology of Japan.

References

- 1 Koizumi S. Discovery of human heme oxygenase-1 deficiency. New aspects of the iron metabolism and defense mechanisms of vascular endothelial cell injuries against oxidative stresses. *J. Jpn. Pediatr. Soc.* 1998; 102: 1267-70. *in Japanese*
- 2 Yachie A, Niida Y, Wada T, et al. Oxidative stresses causes enhanced endothelial cell injury in human heme oxygenase-1 deficiency. *J. Clin. Invest.* 1999; 103: 129-35.
- 3 Yachie A, Kawashima A, Ohta K, Saikawa Y, Koizumi S. Human HO-1 deficiency and cardiovascular dysfunction. In: Wang R (ed). *Carbon monoxide and cardiovascular functions*. CRC Press, 2002; New York, 181-212.
- 4 Yachie A, Toma T, Shimura S, et al. Human heme oxygenase (HO)-1 deficiency and the oxidative injury of vascular endothelial cells. In: Abraham NG, Alam J, and Nath K (eds). *Heme oxygenase in biology and medicine*. Kluwer Academic/Plenum Publishers, New York, 2002; 325-34.
- 5 Maines MD. The heme oxygenase system: Update 2005. *Antioxid. Redox. Signal.* 2005; 7: 1761-6.
- 6 Morse D, Choi AMK. Heme oxygenase-1: from bench to bedside. *Am. J. Respir. Crit. Care Med.* 2005; 172: 660-70.
- 7 Balla J, Vercellotti GM, Jeney V, Yachie A, et al. Heme, heme oxygenase and ferritin in vascular endothelial cell injury. *Mol. Nutr. Food Res.* 2005; 49: 1030-43.
- 8 Kawashima A, Oda Y, Yachie A, et al. Heme oxygenase-1 deficiency : the first autopsy case.

- Hum. Pathol. 2002; 33: 125-30.
- 9 Saikawa Y, Kaneda H, Yue L, et al. Structural evidence of genomic exon-deletion mediated by *Alu-Alu* recombination in a human case with heme oxygenase-1 deficiency. Hum. Mut. 2000; 16: 178-9.
 - 10 Poss KD and Tonegawa S. Heme oxygenase 1 is required for mammalian iron reutilization. Proc. Natl. Acad. Sci. USA 1997; 94: 10919-24.
 - 11 Poss KD and Tonegawa S. Reduced stress defense in heme oxygenase 1- deficient cells. Proc. Natl. Acad. Sci. USA 1997; 94: 10925-30.
 - 12 Yet SF, Perrella MA, Layne MD, et al. Hypoxia induces severe right ventricular dilatation and infarction in heme oxygenase-1 null mice. J. Clin. Invest. 1999; 103:R23-9.
 - 13 Yachie A. Lesson from the HO-1 deficiency. J. Jpn. Pediatr. Soc. 2002; 106: 1380-9. *in Japanese*
 - 14 Yachie A, Toma T, Mizuno K, et al. Heme oxygenase –1 production by peripheral blood monocytes during acute inflammatory illnesses of children. Exp. Biol. Med. (Maywood) 2003; 228: 550-6.
 - 15 Mizuno K, Toma T, Tsukiji H, et al. Selective expansion of CD16^{high} CCR2⁻ subpopulation of circulating monocytes with preferential production of haem oxygenase (HO)-1 in response to acute inflammation. Clin. Exp. Immunol. 2005; 142: 461-70.
 - 16 Otterbein LE, Soares MP, Yamashita K, Bach FH. Heme oxygenase-1: unleashing the protective properties of heme. Trends Immunol. 2003; 24: 449-55.
 - 17 Wood KJ, and Sawitzki B. Interferon γ : a crucial role in the function of induced regulatory T cells in vivo. Trends in Immunol. 2006; www.sciencedirect.com.

- 18 Ohta K, Yachie A, Fujimoto K, et al. Tubular injury as a cardinal pathological feature in human heme oxygenase-1 deficiency. *Am. J. Kidney Dis.* 2000; 35: 863-70.
- 19 Morimoto K, Ohta K, Yachie A, et al. Cytoprotective role of heme oxygenase (HO) -1 in human kidney with various renal diseases. *Kidney Int.* 2001; 60: 1858-66.
- 20 Shimizu M, Ohta K, Yang Y, et al. Glomerular proteinuria induces heme oxygenase-1 gene expression within renal epithelial cells. *Pediatr. Res.* 2005; 58: 666-71.
- 21 Yang Y, Ohta K, Shimura M, et al. Selective protection of renal tubular epithelial cells by heme oxygenase (HO) –1 during stress-induced injury. *Kidney Int.* 2003; 64: 1302-9.
- 22 Ohta K, Yachie A. Role of heme oxygenase-1 in cardiovascular diseases: a novel target for molecular intervention? *J. Endovasc. Ther.* 2001; 8: 444-6.
- 23 Ohta K, Yachie A. Development of vascular biology over the past 10 years : Heme oxygenase-1 in cardiovascular homeostasis. *J. Endovasc. Ther.* 2004; 11 (Suppl II): 140-50.
- 24 Nagy E, Jeney V, Yachie A, et al. Oxidation of hemoglobin by lipid hydroperoxide associated with low-density lipoprotein (LDL) and increased cytotoxic effect by LDL oxidation in heme oxygenase-1 (HO-1) deficiency. *Cell. Mol. Biol.* 2005; 51: 377-85.
- 25 Choi AMK. Heme oxygenase-1 protects the heart. *Circ. Res.* 2001; 89: 105-7.
- 26 Soares MP, Lin Y, Anrather J, et al. Expression of heme oxygenase-1 can determine cardiac xenograft survival. *Nature Med.* 1998; 4: 1073-7.
- 27 Deramautd BMJM, Braunstein S, Remy P, Abraham NG. Gene transfer of human heme oxygenase into coronary endothelial cells potentially promotes angiogenesis. *J. Cell. Biochem.* 1998; 68: 121-7.

- 28 Duckers HJ, Boehm M, True AL, et al. Heme oxygenase-1 protects against vascular constriction and proliferation. *Nature Med.* 2001; 7: 693-8.
- 29 Kitada O, Kodama T, Kuribayashi K, et al. Heme oxygenase-1 (HO-1) protein induction in a mouse model of asthma. *Clin. Exp. Allergy* 2001; 31: 1470-7.
- 30 Otterbein LE, Kolls JK, Mantell LL, et al. Exogenous administration of heme oxygenase-1 by gene transfer provides protection against hyperoxia-induced lung injury. *J. Clin. Invest.* 1999; 103: 1047-54.
- 31 Kimpara T, Takeda A, Watanabe K, et al. Microsatellite polymorphism in the human heme oxygenase-1 gene promoter and its application in association studies with Alzheimer and Parkinson disease. *Hum. Genet.* 1997; 100: 145-7.
- 32 Exner M, Schillinger M, Minar E, et al. Heme oxygenase-1 gene promoter microsatellite polymorphism is associated with restenosis after percutaneous transluminal angioplasty. *J. Endovasc. Ther.* 2001; 8: 433-40.
- 33 Exner M, Boehmig GA, Schillinger M, et al. Donor heme oxygenase-1 genotype is associated with renal allograft function. *Transplantation* 2004; 77: 538-42.
- 34 Yamada N, Yamaya M, Okinaga S, et al. Microsatellite polymorphism in the heme oxygenase-1 gene promoter is associated with susceptibility to emphysema. *Am. J. Hum. Genet.* 2000; 66: 187-95.
- 35 Hirai H, Kubo H, Yamaya M, et al. Microsatellite polymorphism in heme oxygenase-1 gene promoter is associated with susceptibility to oxidant-induced apoptosis in lymphoblastoid cell lines. *Blood* 2003; 102: 1619-21.

- 36 Schaer DJ, Schaer CA, Buehler PW, et al. CD163 is the macrophage scavenger receptor for native and chemically modified hemoglobins in the absence of haptoglobin. *Blood* 2006; 107: 373-80.
- 37 Hvidberg V, Maniecki MB, Jacobsen C, Hoejrup P, Moeller HJ, Moestrup SK. Identification of the receptor scavenging hemopexin-heme complexes. *Blood* 2005; 106: 2572-9.
- 38 Takeda A, Itoyama Y, Kimpara T, et al. Heme catabolism and heme oxygenase in neurodegenerative disease. *Antioxid. Redox. Signal.* 2004; 6: 888-94.
- 39 Suzuki H, Kanamaru K, Tsunoda H, et al. Heme oxygenase-1 gene induction as an intrinsic regulation against delayed cerebral vasospasm in rats. *J. Clin. Invest.* 1999; 104: 59-66.
- 40 Maruhashi K, Kasahara Y, Ohta K, et al. Paradoxical enhancement of oxidative cell injury by overexpression of heme oxygenase-1 in an anchorage-dependent cell ECV304. *J. Cell. Biochem.* 2004; 93: 552-62.

Table 1

Problem lists of the patient

- 1) Generalized inflammation
- 2) Intravascular hemolysis with marked fragmentation of erythrocytes
- 3) Coagulation/fibrinolysis system disturbance
- 4) Retinopathy, endothelial injury
- 5) Asplenia

Non-hyperbilirubinemia ?

Hyperhaptoglobinemia ?

Table 2

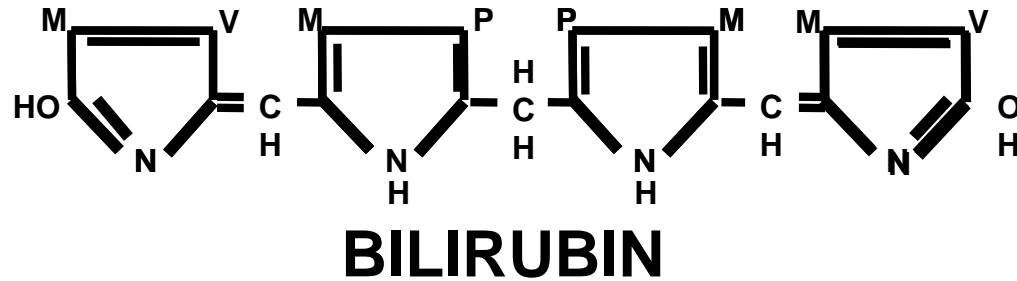
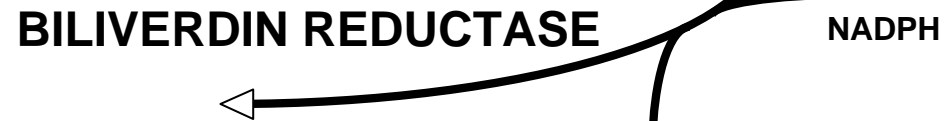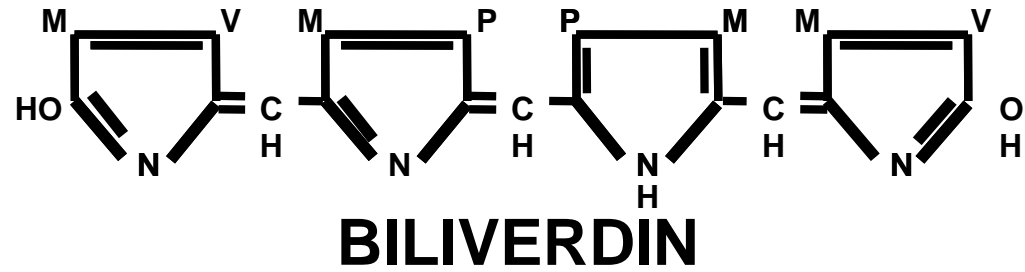
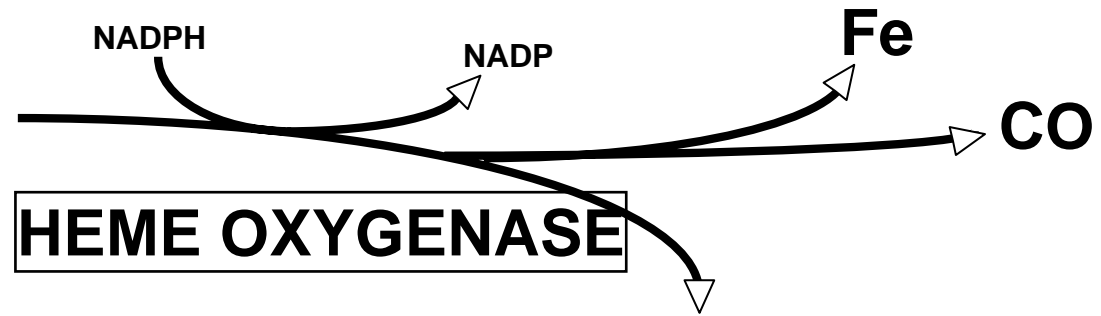
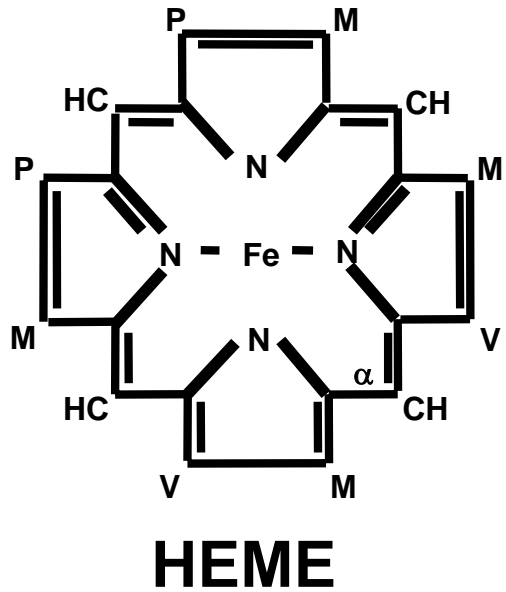
Comparison of clinical findings in the HO-1-deficient patient and HO-1 knockout mice

Finding	Human	Mice
Intrauterine death	Stillbirth, abortion	20% birth rate
Growth failure	+	+
Anemia	+	+
Fragmentation	+	Unknown
Iron-binding capacity	Increased	Increased
Ferritin	Elevated	Elevated
Iron deposition	+	+
Hepatomegaly	+	+
Splenomegaly	Asplenia	+
Lymph node swelling	+	+
Leukocytosis	+	+
Thrombocytosis	+	Unknown
Coagulation abnormality	+	Unknown
Endothelial injury	+	Unknown
Hyperlipidemia	+	Unknown

HO-1, heme oxygenase-1

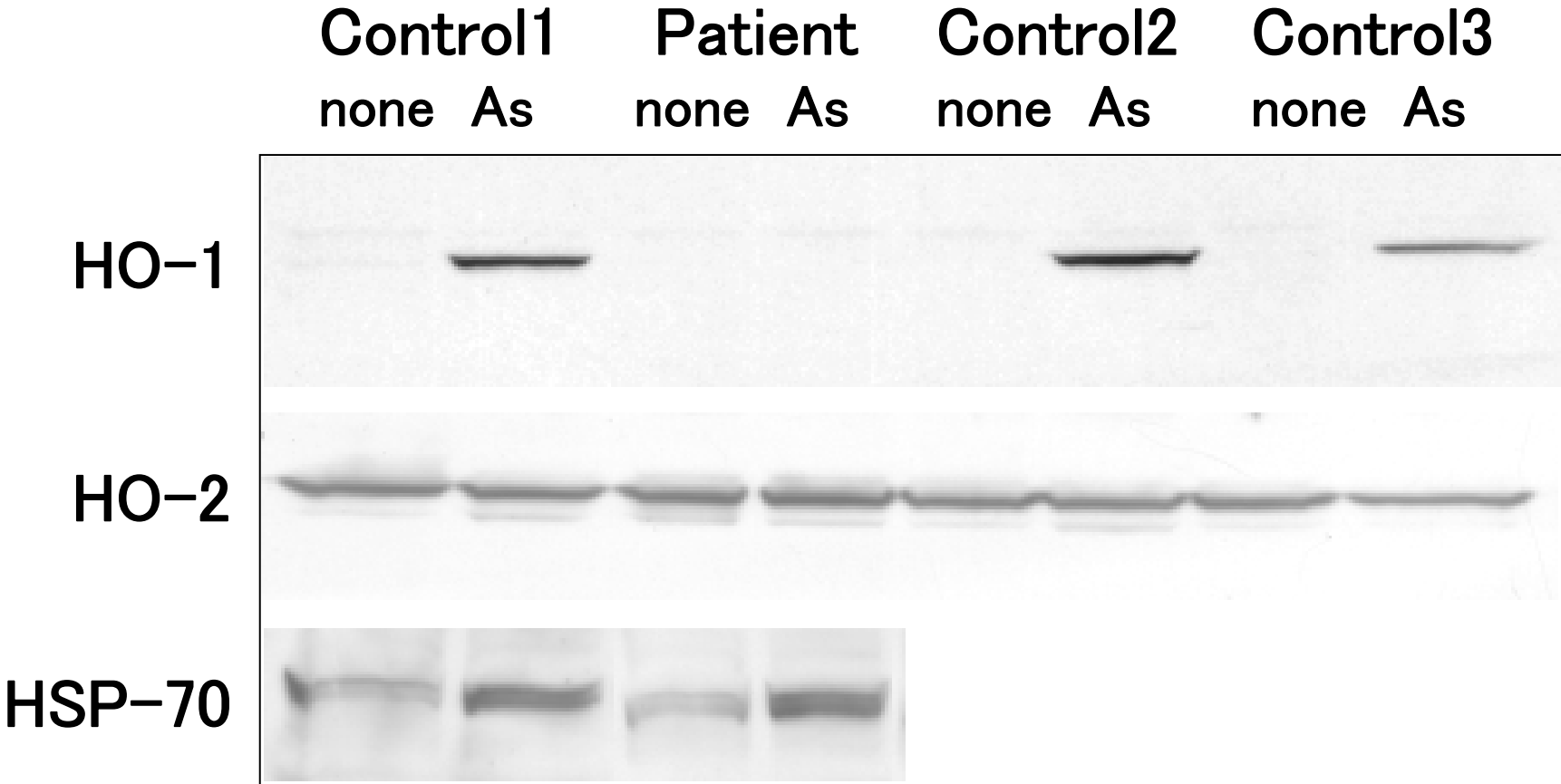
Figure legends

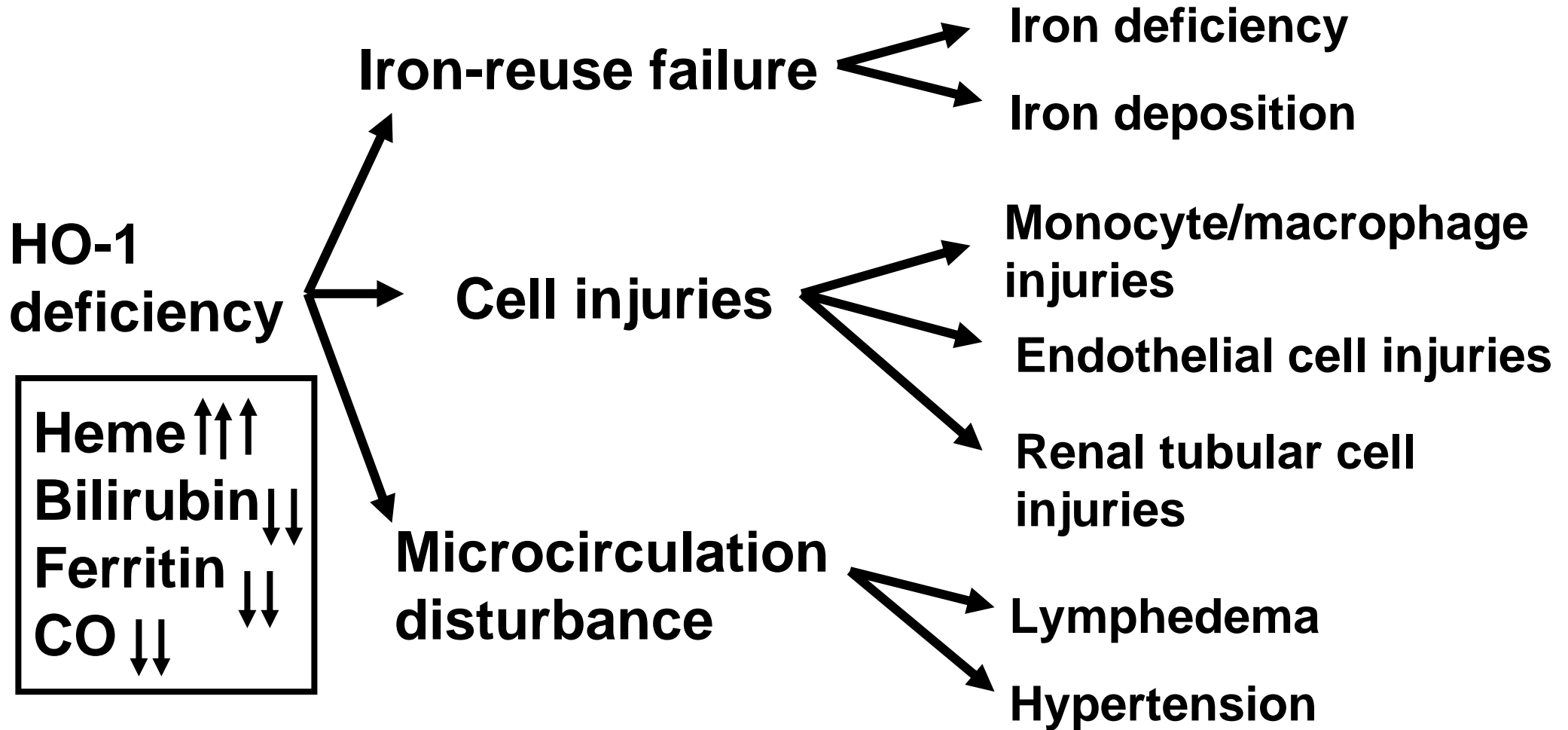
1. Metabolic map of porphyrin through bilirubin
2. Western blotting analysis using lymphoblastoid cell lines (LCLs)
3. Pathophysiology of HO-1 deficiency
4. Heme oxygenase-1 and monocytes/macrophages in pro- and anti-inflammatory systems (modified in part from Trends in Immunology 2003; 24: 449-55)
5. Heme oxygenase-1 in the system of influence of interferon- γ production by T regulatory cells on the antigen presenting cell function (modified in part from Trends in Immunology www.sciencedirect.com, 2006)
6. Overview of receptor pathways for the endocytosis of extracellular heme and hemoglobin in complex with hemopexin and haptoglobin (modified in part from Blood 2005; 106: 2572-9)
7. Heme oxygenase-1 as a “therapeutic funnel”(modified in part from Trends in Immunology 2003; 24: 449-55)



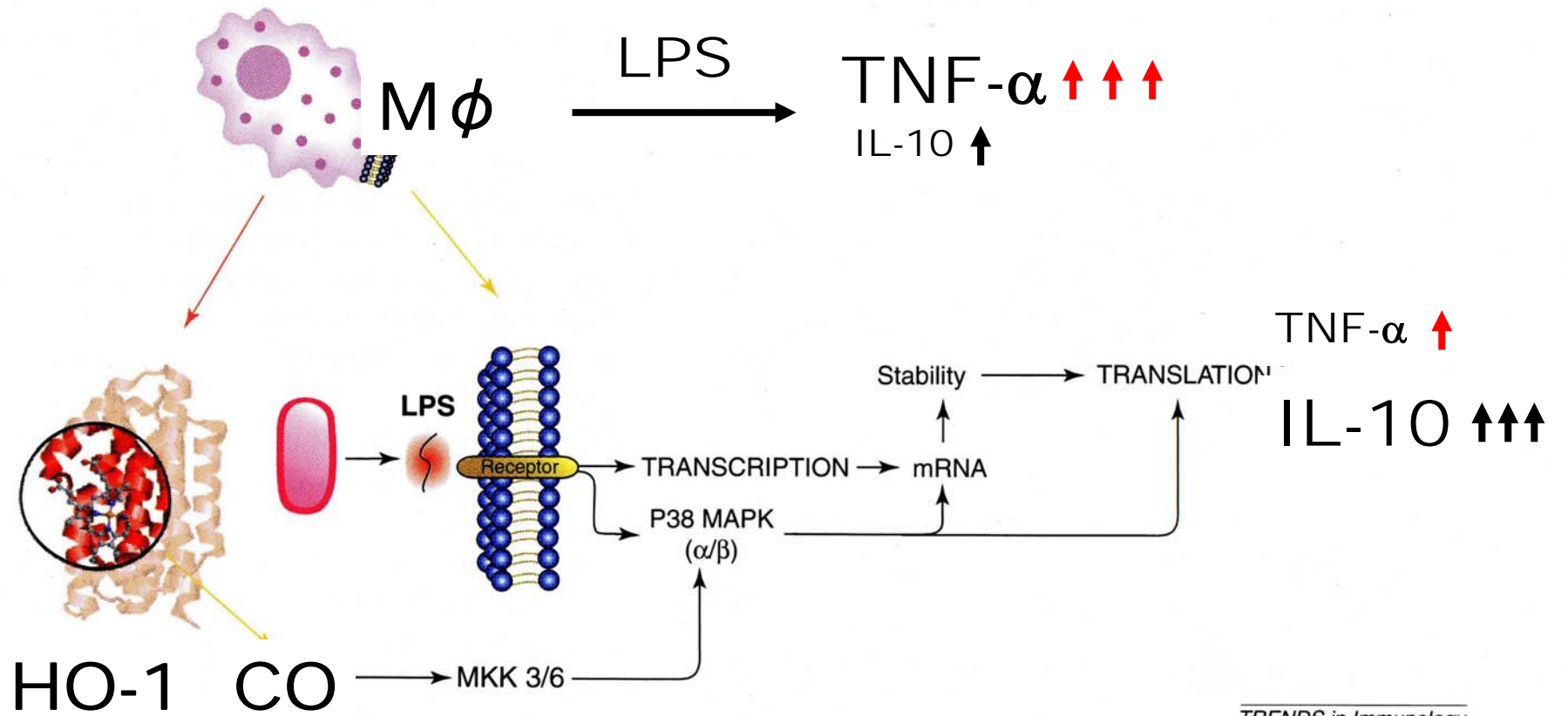
M = methyl
 V = vinyl
 P = propionic acid

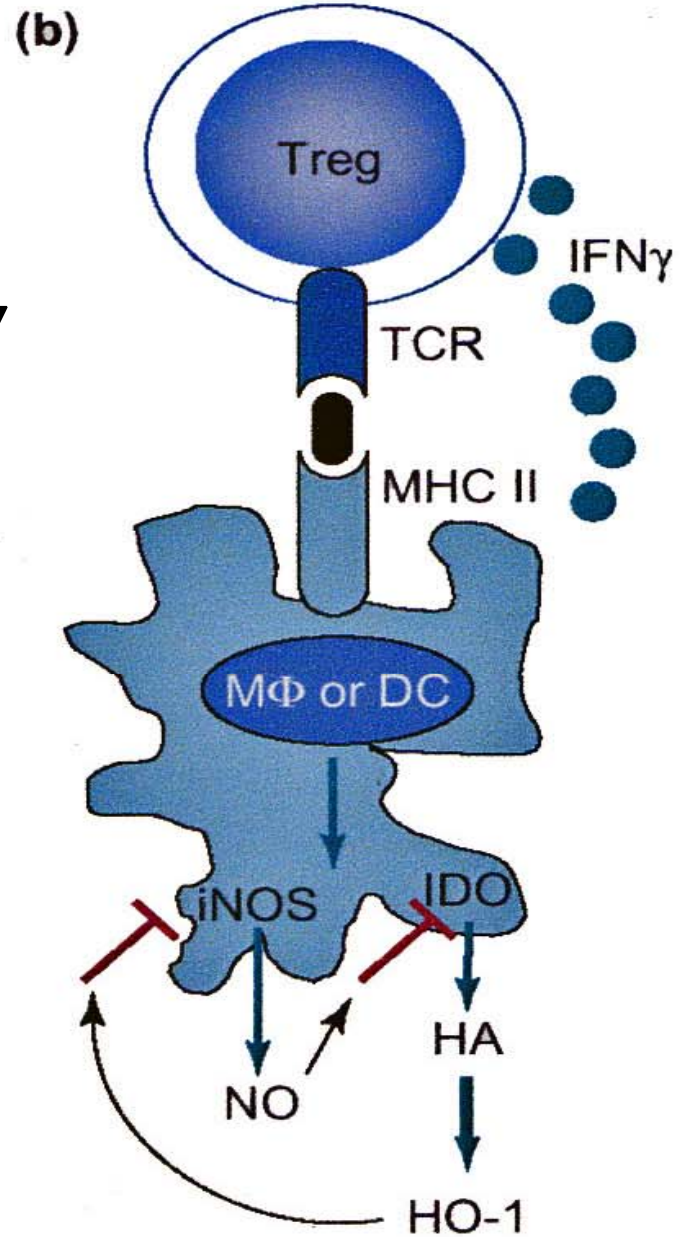
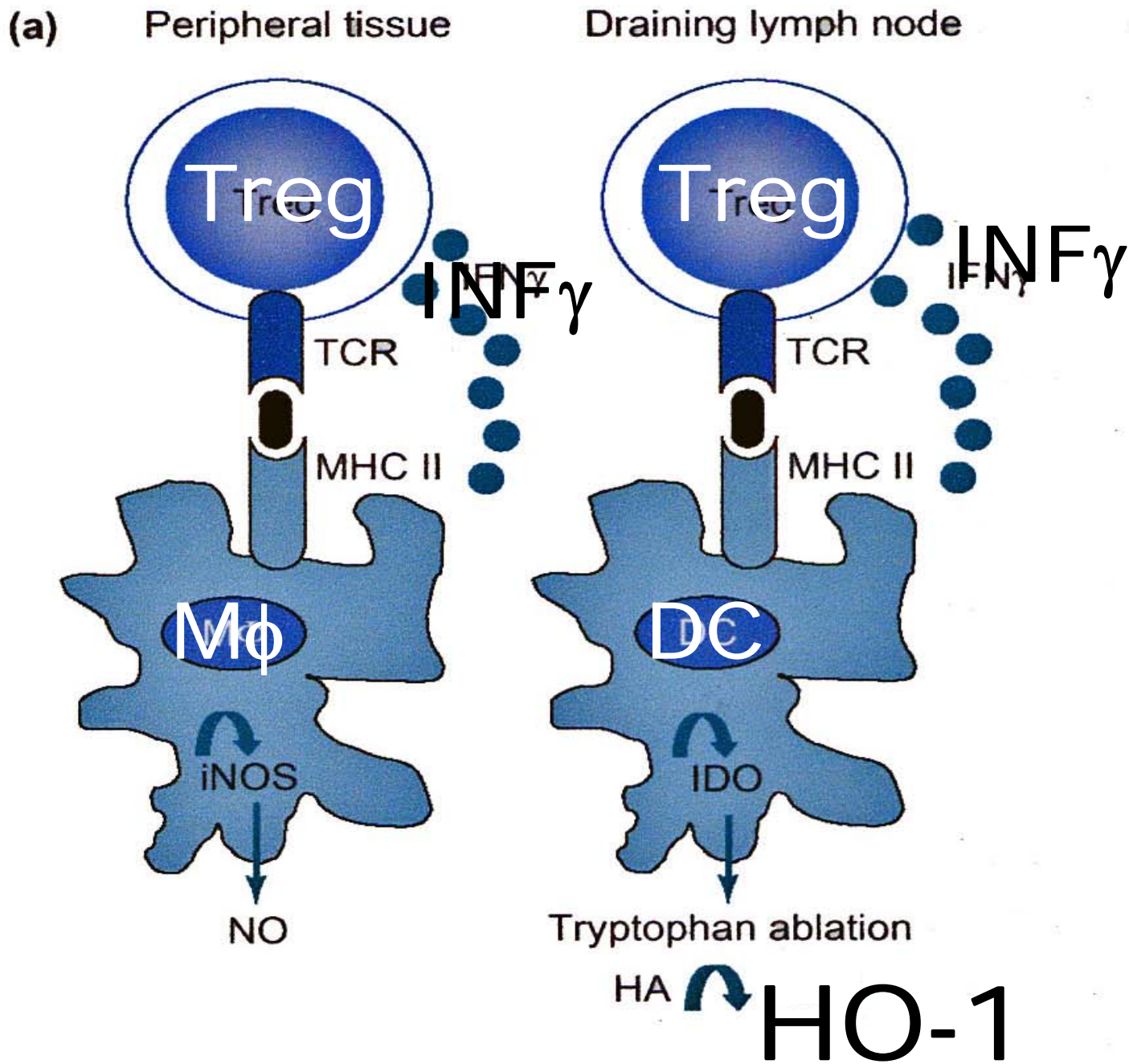
Immunoblotting Analysis (LCL)

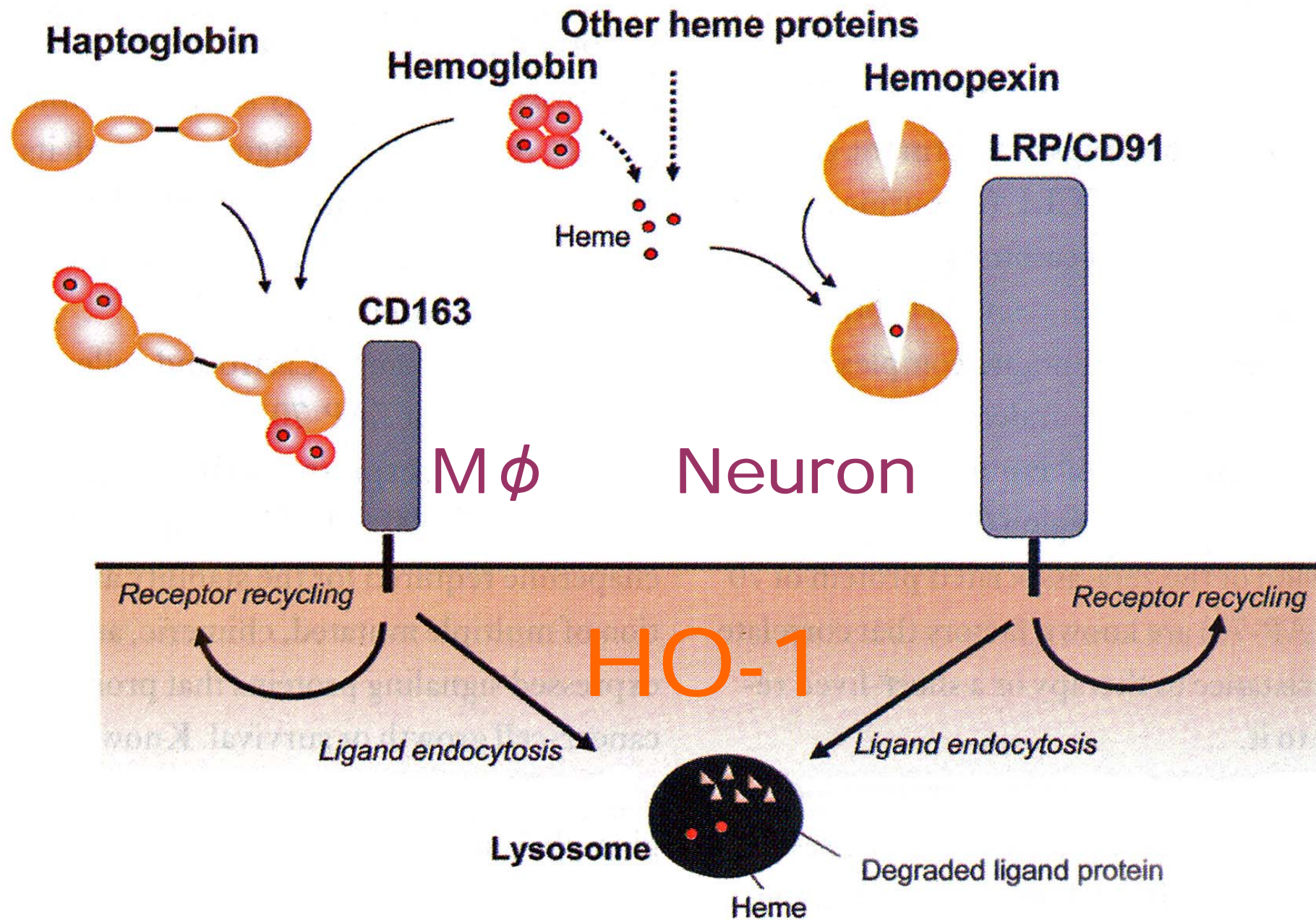




**Breakdown of
defense mechanisms**







HO-1 as a "therapeutic funnel"

