

Comparison of regional myocardial Technetium-99m-MIBI uptake between ECG-gated and ungated SPECT imaging

著者	Onoguchi Masahisa, Maruno Hirotaka, Fujinaga Tsuyoshi, Komiyama Nobuyuki, Takayama Teruhiko, Murata Hajime
journal or publication title	Journal of Nuclear Medicine Technology
volume	25
number	3
page range	181-186
year	1997-09-01
URL	http://hdl.handle.net/2297/7451

Comparison of Regional Myocardial Technetium-99m-MIBI Uptake Between ECG-Gated and Ungated SPECT Imaging

Masahisa Onoguchi, Hiroataka Maruno, Tsuyoshi Fujinaga, Nobuyuki Komiyama, Teruhiko Takayama and Hajime Murata

School of Health Sciences, Kanazawa University, Kanazawa; and Division of Nuclear Medicine and Cardiovascular Center, Toranomon Hospital, Tokyo, Japan

Technetium-99m-MIBI uptake was compared between ECG-gated and ungated SPECT images in 10 normal subjects and 10 patients with coronary artery disease to investigate the effects of wall motion on regional myocardial uptake.

Methods: Left ventricular ejection fraction (LVEF) and wall motion were evaluated using the first-pass data acquired immediately after injection of 1110 MBq ^{99m}Tc -MIBI. A transaxial ungated image was reconstructed with cumulative data during a cardiac cycle. For transaxial gated images, data during a cardiac cycle were divided into eight frames and the first seven frames were used. The lateral/septal ratios for ungated and gated images were obtained using the counts in the ROIs drawn in the lateral and the septal walls.

Results: In 10 normal subjects, the lateral/septal ratio for gated increased during end-systole. The mean of the lateral/septal ratio was significantly lower for ungated than for gated (1.025 vs. 1.077, $p < 0.05$). In patients with septal wall asynergy and a normokinetic lateral wall, the mean of the lateral/septal ratios was significantly lower for ungated than for gated (1.267 vs. 1.325, $p < 0.01$).

Conclusion: Ungated SPECT acquisition may underestimate regional myocardial uptake when myocardial wall motion is good, therefore, ECG-gated data should be acquired for accurate assessment of regional myocardial uptake of ^{99m}Tc -MIBI.

Key Words: technetium-99m-MIBI; electrocardiogram-gated SPECT imaging; regional myocardial uptake

J Nucl Med Technol 1997; 25:181-186

Using technetium-99m-methoxyisobutyl isonitrile (^{99m}Tc -MIBI) it is possible to administer a 10-15 times higher dose than with thallous chloride (^{201}Tl) because of the 140-keV photon energy and 6-hr half-life of ^{99m}Tc (1-4). We can simultaneously perform myocardial perfusion imaging and assess cardiac function (5-7). In these studies, cardiac function

was evaluated by left ventricular ejection fraction (LVEF) and wall motion using the first-pass method. For myocardial perfusion imaging, the advantages of electrocardiogram-gated (ECG-gated) SPECT has been shown with respect to high-contrast perfusion images and additional regional functional information (8-13). However, accurate assessment of regional uptake is still under investigation.

Recently we had an opportunity to compare ECG-gated ^{18}F -FDG images to ungated images in a patient with hypertrophic cardiomyopathy (HCM). The ungated images showed reduced tracer uptake in the posterolateral wall, whereas ECG-gated images showed homogeneous distribution of tracer. Echocardiography in this patient showed severe hypokinesis of the hypertrophic septal wall and hyperkinesis of the lateral wall. These findings made us consider the possibility of underestimation of the regional myocardial uptake caused by wall motion on ungated images.

The purpose of this study was to compare ^{99m}Tc -MIBI uptake between gated and ungated images and to investigate the effects of wall motion on the regional myocardial uptake in normal subjects and in patients with ischemic heart disease.

MATERIALS AND METHODS

Study Population

The study population consisted of 10 normal subjects (4 men, 6 women; mean age 33.5 ± 8.1 yr) and 10 patients (6 men, 4 women; mean age 65.5 ± 6.0 yr) with coronary artery disease. Their ECGs showed regular sinus rhythm. All patients had echocardiography, coronary angiography and contrast ventriculography for the evaluation of coronary arteries and regional wall motion. Coronary artery stenosis was shown in nine patients by coronary angiography. Wall asynergy was shown in all patients by echocardiography and contrast ventriculography. Final diagnosis was old myocardial infarction in seven patients, and coronary artery disease with angina pectoris in three patients (Table 1). Two patients had undergone percutaneous transluminal coronary angioplasty (PTCA).

For correspondence or reprints contact: Masahisa Onoguchi, School of Health Sciences, Kanazawa University, Kotatsuno 5-11-80, Kanazawa, 920, Japan.

TABLE 1
Comparison of Regional Myocardial Technetium-99m-MIBI Uptake in 10 Patients

Patient no.	Age	Sex	Diagnosis	Coronary artery stenosis	LVEF (%)	Wall motion abnormalities	^{99m} Tc-MIBI defects
1	62	F	MI (AS, Ap)	Normal	50	AS, Ap	AS, Ap
2	62	M	MI (AS)	LAD (post PTCA)	61	AS	AS
3	77	M	MI (AS)	LAD (post PTCA)	39	AS, Ap	AS, Ap
4	68	M	CAD/AP	LAD, RCA	53	AS	AS
5	63	F	MI (AS, Ap)	LAD, LCX, RCA	51	AS, Ap	AS, Ap
6	70	M	MI (AS)	LAD	48	AS	AS
7	68	F	CAD/AP	LAD, LCX, RCA	58	IP, Ap	IP, Ap
8	62	M	CAD/AP	LCX, RCA	46	IP	IP
9	55	M	MI (PL)	LCX, RCA	42	PL	PL
10	69	F	MI (IP)	RCA	36	IP	IP

CAD/AP: Coronary artery disease with angina pectoris; AS: Anteroseptal; Ap: Apex; MI: Myocardial infarction; PL: Posterolateral; IP: Inferoposterior.

Preparation of Technetium-99m-MIBI

Technetium-99m-MIBI (Daiichi Radioisotope Corp., Tokyo, Japan) was prepared from a freeze-dried kit by reconstitution with approximately 3 ml of a sterile pertechnetate solution containing 1480 MBq ^{99m}Tc.

First-Pass Imaging

Immediately after injection of 1110 MBq ^{99m}Tc-MIBI, first-pass data were acquired with a zoom of 1.00 at the anterior position using a gamma camera equipped with a low-energy slant-hole collimator (RAO 30°). A 20% energy window around the 140-keV energy peak of ^{99m}Tc was used. First-pass imaging was used to evaluate LVEF and regional wall motion. Wall motion was graded as normal, hypokinesis and akinesis/dyskinesis and was assessed in four different segments: anterior, apical, inferior and inferobasal regions.

Technetium-99m-MIBI SPECT Imaging

Technetium-99m-MIBI SPECT imaging was performed at 1 hr postinjection using a rotating gamma camera equipped with a low-energy all-purpose collimator. Thirty-two projections (30 sec per projection) were acquired over a 180°, semicircular arc extending from the 45° RAO to the 45° LPO position. All images were obtained with a 64 × 64 matrix and a zoom of

1.33. All data were prefiltered with a Hanning filter (cutoff 0.8 pixel⁻¹). The SPECT images were reconstructed by a filtered backprojection algorithm and Ramp filtering. Three sets of SPECT images were generated: (a) horizontal long axis, (b) vertical long axis and (c) short axis. No attenuation correction was performed. SPECT images were interpreted dividing the left ventricle into nine segments: anterior, anterobasal, apical, inferior, posterior, distal septum, basal septum, distal lateral wall and basal lateral wall. All studies were interpreted by visual inspection of both the tomographic slices and bull's eye maps.

Quantitative Analysis of Tracer Uptake

Transaxial images were reconstructed to analyze tracer uptake quantitatively. An ungated image was reconstructed using cumulative data during a cardiac cycle. A cardiac cycle was divided into eight frames for gated images. Quantitative analysis was performed using the first seven frames. The eighth frame was excluded to avoid error based on the variation of counts at this frame caused by heart rate fluctuation. Tracer uptake was quantitatively evaluated using the lateral/septal ratio, where lateral and septal were the means of counts in two regions of interest (ROIs) drawn in the lateral and septal walls, respectively (Fig. 1). The lateral/septal ratio was obtained at each image and by using the following formula: Mean gated =

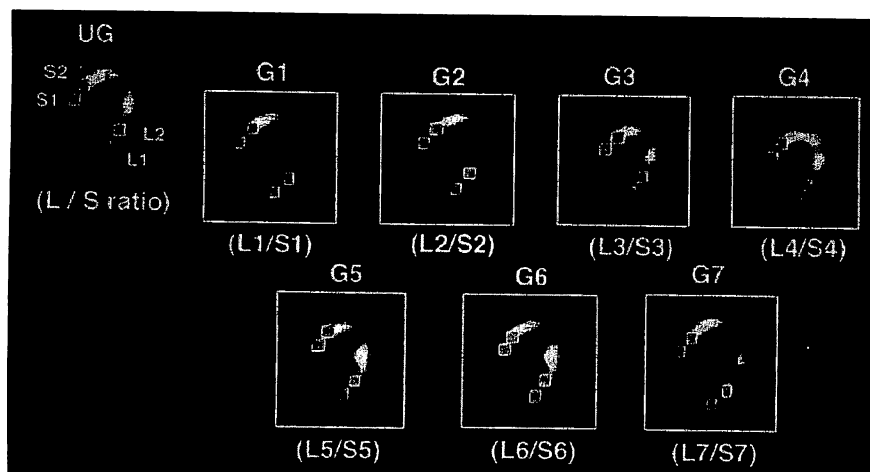


FIGURE 1. An ungated (UG) transaxial image (left) and seven gated (G) images during a cardiac cycle. Comparison of tracer uptake between ungated and gated is performed using both the mean gated and the lateral/septal (L/S) ratio at each frame, where lateral (L) and septal (S) are the means of the counts in two ROIs drawn in the lateral and septal walls, respectively.

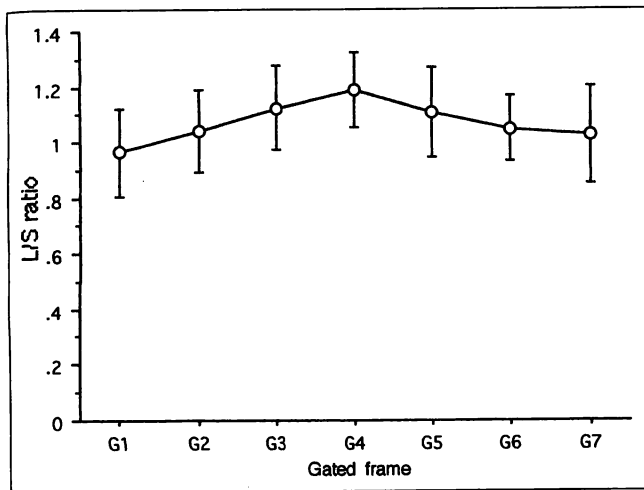


FIGURE 2. The mean lateral/septal (L/S) ratio in 10 normal subjects. It changes at each frame ranging from 0.966 ± 0.158 at the first gated frame (G1) to the maximum of 1.191 ± 0.133 at the fourth gated frame (G4).

Σ Lateral Inferior/ Σ Septal Inferior, where Inferior is 1 to 7. In addition, one of the seven gated images showing the same myocardial size as the ungated image was selected and compared to the ungated image.

Statistical Analysis

Data are presented as mean \pm s.d. Differences between gated and ungated were compared using Student's paired or unpaired Student's t-test. Statistical significance was defined as $p < 0.05$.

RESULTS

First-Pass Imaging

The results of first-pass imaging were LVEF of $61.0\% \pm 4.8\%$ in the 10 normal subjects and normokinesis of myocardial wall. The 10 patients showed LVEF of $49.1\% \pm 7.7\%$ and wall asynergy consistent with echocardiography and contrast ventriculography: the anteroseptal asynergy in six patients and the lateral or inferoposterior asynergy in four patients (Table 1).

Technetium-99m-MIBI Myocardial SPECT Imaging

Visual analysis of ^{99m}Tc -MIBI myocardial SPECT revealed perfusion abnormalities in all patients (Table 1). There was no

discrepancy between the wall motion abnormality on first-pass imaging and the perfusion abnormality on ^{99m}Tc -MIBI SPECT.

Quantitative Analysis of Tracer Uptake

Normal Subjects. The lateral/septal ratio for ungated images was 1.025 ± 0.147 in the 10 normal subjects. The lateral/septal ratio for gated images changed at each frame, ranging from 0.966 ± 0.158 at the first frame (G1) to the maximum of 1.191 ± 0.133 at the fourth frame (G4) (Fig. 2). The means of seven frames was 1.073 ± 0.068 . The mean for gated images was 1.077 ± 0.130 . The value for gated images was significantly greater than that for ungated images ($p < 0.01$) (Fig. 3A). In addition, we compared an ungated image to a gated image showing the same myocardial size as the ungated image. Of seven frames, the G2 and/or G6 frame(s) showed the same myocardial size as the ungated image. Limiting evaluation to these frames, the lateral/septal ratio was 1.090 ± 0.119 and greater than the mean for gated images (Fig. 3B). Figure 4 shows a bull's eye map and the lateral/septal ratios in two normal subjects. Compared with the gated image, the ungated image showed reduced uptake in the lateral wall, whereas the septal wall uptake for ungated was similar to that for gated. The lateral/septal ratio for ungated was lower than that for gated.

Patients. The 10 patients were categorized into two groups according to asynergic wall: (a) the septal wall asynergy group, including the anterior and anteroseptal wall asynergy; and (b) the lateral wall asynergy group, including the posterolateral and inferoposterior wall asynergy. Figure 5 shows the comparison of the lateral/septal ratio between ungated and gated in 10 patients. In six patients, who had septal wall asynergy and the normokinetic lateral wall, the lateral/septal ratios for ungated and gated were 1.267 ± 0.221 and 1.325 ± 0.235 , respectively. The value for ungated was significantly lower than that for gated ($p < 0.01$). Similarly, in the four patients who had the lateral wall asynergy, the lateral/septal ratios for ungated and gated were 0.878 ± 0.151 and 0.897 ± 0.148 , respectively. The value for ungated was significantly lower than that for gated ($p < 0.05$). The difference between the lateral/septal ratio for ungated and gated was smaller in patients with asynergy in the lateral wall than for patients with asynergy in the septal wall.

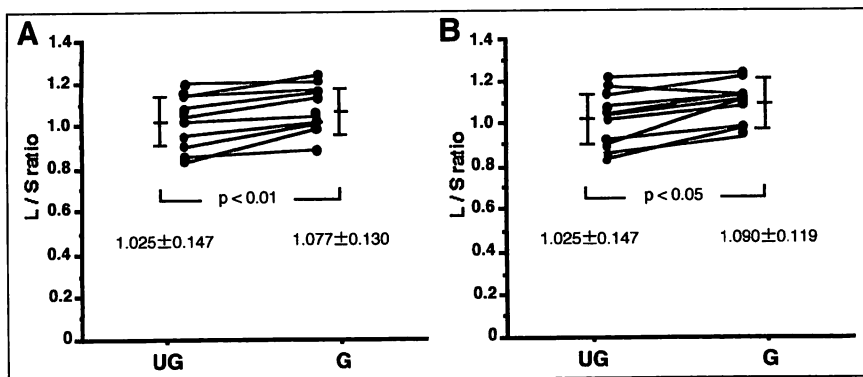


FIGURE 3. Comparison of the lateral/septal (L/S) ratio between ungated (UG) and gated (G) in 10 normal subjects. (A) The lateral/septal ratio for ungated is significantly lower than that for gated (1.025 ± 0.147 vs. 1.077 ± 0.130 , $p < 0.01$). (B) The lateral/septal ratio for ungated is significantly lower than that for a gated image showing the same myocardial size as the ungated image (1.025 ± 0.147 vs. 1.090 ± 0.119 , $p < 0.05$).

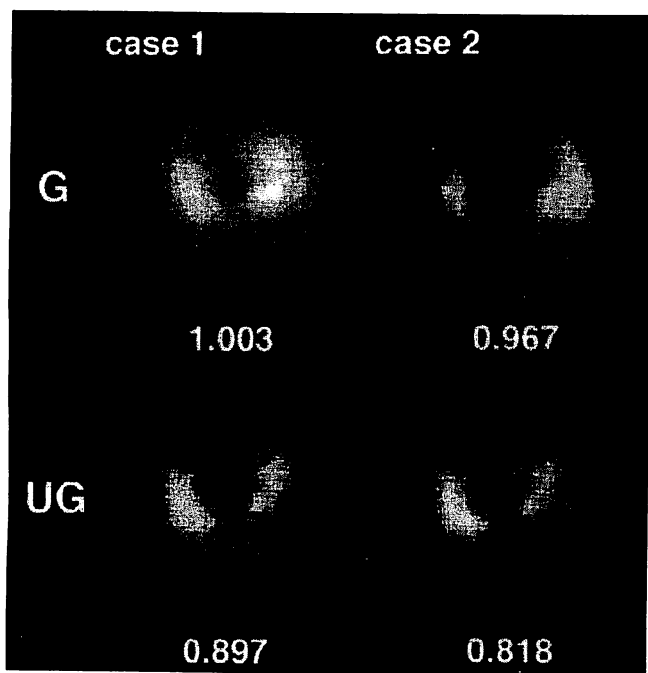


FIGURE 4. Bull's eye maps and the lateral/septal ratios in two normal subjects. The lateral wall uptake is relatively lower for ungated (UG) than for gated (G), whereas the septal wall uptake for ungated is similar to that for gated.

CASE REPORTS

Case 1

This 62-yr-old female patient's ECG showed transient ST elevation during a cholecystectomy for cholelithiasis. Although echocardiography showed severe hypokinesis of the anteroseptal wall and the apex, coronary angiography showed no abnormality. The diagnosis of myocardial infarction due to vasospasm was made. First-pass imaging showed an LVEF of 50%. For ungated imaging, the transaxial image and bull's eye map showed a perfusion defect in the apex and reduced uptake in the lateral wall. In contrast, gated imaging of the lateral wall uptake was normal (Fig. 6A). The lateral/septal ratio for ungated was lower than that for gated (0.99 vs. 1.079). The lateral wall uptake was underestimated for ungated. The lateral/septal ratio at each frame was not significantly different from that in normal subjects (Fig. 6B).

Case 2

Three months before, this 62-yr-old male patient had an anteroseptal myocardial infarction. Coronary angiography performed at 2 hr postinfarction showed complete occlusion of a branch of the left anterior descending artery. Following PTCA, it improved to a 50% stenosis. First-pass imaging showed an LVEF of 61% and mild hypokinesis of the anterior wall. Echocardiography showed hypokinesis of the septal wall and normokinesis of the lateral wall. The transaxial image and the bull's eye map showed reduced uptake in the anteroseptal wall (Fig. 7A). The lateral/septal ratio for ungated was lower than that for gated (1.269 vs. 1.330). The lateral wall uptake for ungated was underestimated. The lateral/septal ratio at each

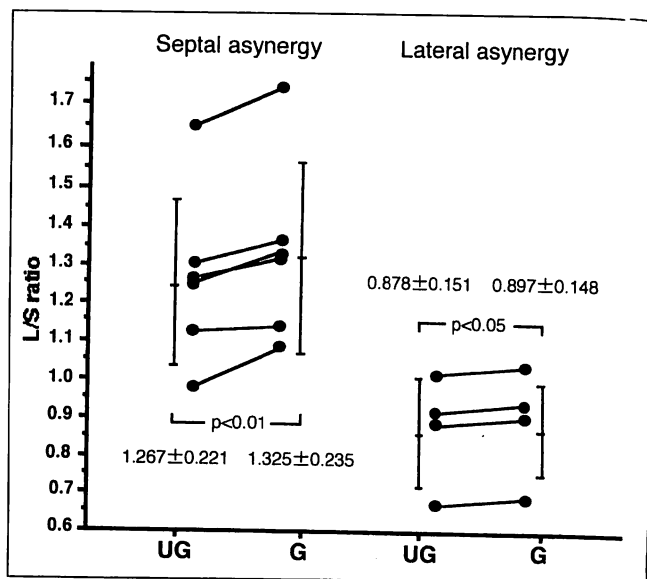


FIGURE 5. The lateral/septal (L/S) ratio for ungated (UG) and gated (G) in 10 patients. In the six patients who had septal wall asynergy and a normokinetic lateral wall, the lateral/septal ratio for ungated is significantly lower than for gated (1.267 ± 0.221 vs. 1.325 ± 0.235 , $p < 0.01$). In four patients who had lateral wall asynergy, the lateral/septal ratio for ungated is significantly lower than that for gated (0.878 ± 0.151 vs. 0.897 ± 0.148 , $p < 0.05$).

frame was considerably greater than that in normal subjects (Fig. 7B).

DISCUSSION

Thallium-201 has been widely used for the scintigraphic assessment of coronary artery disease and is generally accepted for the noninvasive evaluation of myocardial ischemia and infarction. However, it has significant disadvantages such as soft tissue attenuation and scatter caused by low-photon energy emission and a relatively long half-life (73 hr) limiting the amount of administration. Technetium-99m-MIBI has several properties including minimal lung uptake, transient liver uptake and minimal or no myocardial redistribution (1-2). Several authors reported the simultaneous assessment of myocardial perfusion imaging and cardiac function (5-7). Sporn et al. (5) demonstrated that perfusion images with ^{99m}Tc -MIBI correlated well with ^{201}Tl images during exercise and at rest, with 89% concordance in areas of ischemia or infarction and 93% in normal segments. Baillet et al. (6) reported that simultaneous assessment of wall motion and perfusion was a very sensitive procedure to assess the presence of acute myocardial infarction in its earliest stage. Villanueva-Mayer et al. (7) described the best agreement between wall motion and myocardial perfusion was seen in the inferior wall, while most of the discrepancies were found at the apex. Agreement between ^{99m}Tc -MIBI and ^{201}Tl SPECT myocardial perfusion was seen in 93% of segments.

Eisner et al. (14) developed a computer simulation of SPECT imaging to model the effects of attenuation and resolution on myocardial perfusion imaging and predicted that SPECT reconstructions of myocardial perfusion images would

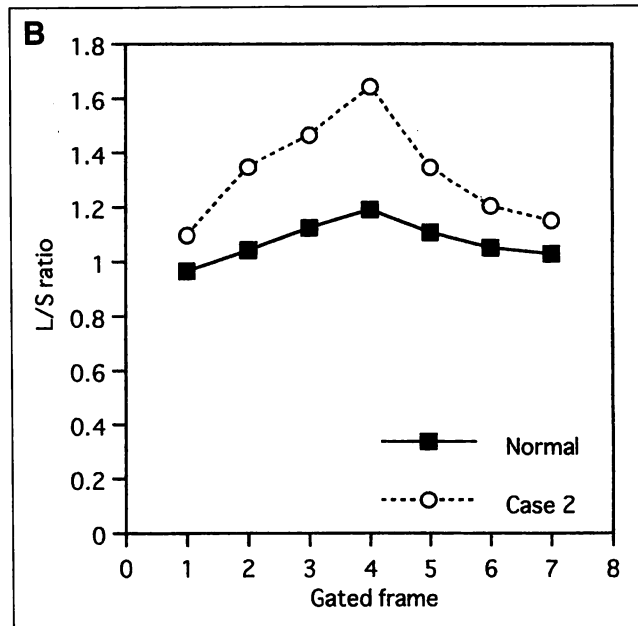
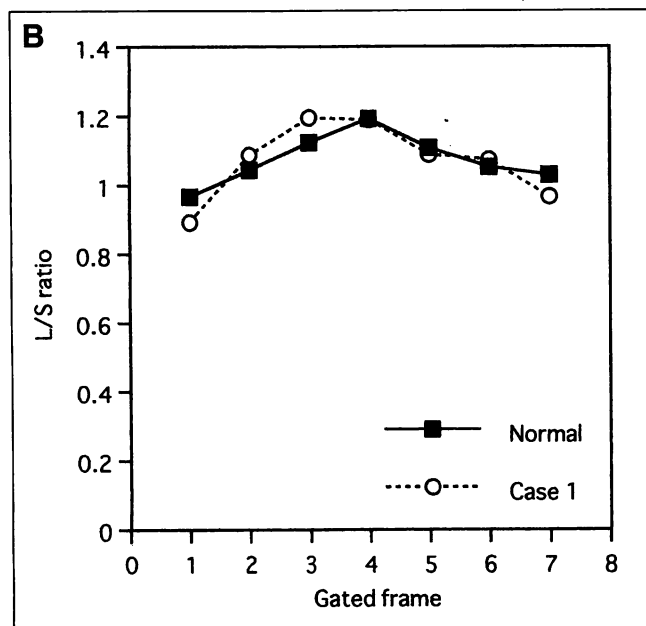
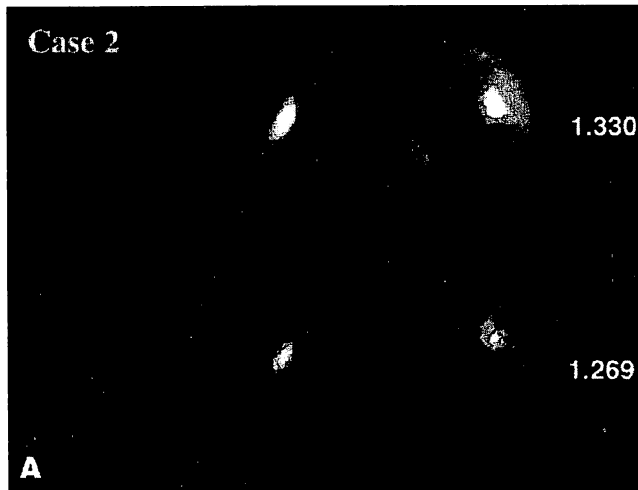
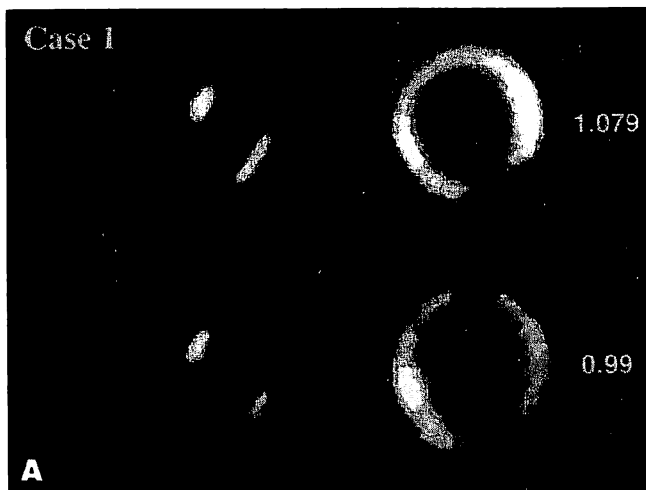

FIGURE 6. Case 1. (A) Comparison of a transaxial image and the bull's eye map between ungated (UG) and gated (G) in a 62-yr-old female patient with severe hypokinesis of the apex and septal wall, and a normokinetic lateral wall. The lateral/septal ratio for ungated is lower than that for gated (0.99 vs. 1.079). The lateral wall uptake is underestimated by ungated imaging. (B) The lateral/septal (L/S) ratio at each frame is similar to that in normal subjects.

FIGURE 7. Case 2. (A) Comparison of a transaxial image and the bull's eye map between ungated (UG) and gated (G) in a 62-yr-old male patient with a hypokinetic septal wall and a normokinetic lateral wall. The lateral/septal ratio for ungated is lower than that for gated (1.269 vs. 1.330). The lateral wall uptake is underestimated for ungated imaging. (B) The lateral/septal (L/S) ratio at each frame is greater than that in normal subjects.

be distorted with decreased counts at the apex and an asymmetry in septal-to-lateral wall counts (14). In addition, they compared ^{99m}Tc -MIBI SPECT and ^{201}Tl SPECT in a canine model of adenosine-induced vasodilation and partial coronary occlusion. Their results indicated that ^{99m}Tc -MIBI SPECT underestimated the extent and severity of transient myocardial underperfusion during adenosine stress with moderately severe partial coronary occlusion (15). In the study performed in normal dogs, they concluded that ungated and gated ^{99m}Tc -MIBI SPECT images showed similar count inhomogeneities (8). They also reported that the asymmetry in wall counts in PET, using a myocardial perfusion imaging agent similar to ^{201}Tl , differs from that found in their ^{201}Tl SPECT studies in humans, in other words increased ratio of lateral-to-septal

counts (8). Corresponding to Eisner et al., our results also showed an increased ratio of lateral-to-septal counts. We also compared tracer uptake in the septal and the lateral walls between gated and ungated. In both normal subjects and patients, the lateral/septal ratio was significantly lower for ungated than for gated. Despite similar uptake in the septal wall between ungated and gated, the lateral wall uptake was lower for ungated than for gated. This finding was observed in patients with septal wall asynergy and patients with lateral wall asynergy. Compared with the gated image, tracer uptake on the ungated image was underestimated. The underestimation was greater in septal wall asynergy than lateral wall asynergy.

The means of the lateral/septal ratios in the 10 normal subjects changed during the cardiac cycle. The maximum was

shown at the fourth frame (G4). As shown in Figure 1, the G4 frame corresponds to end-systole. The same myocardial size as the ungated image was shown at the G2 and/or G6 frame(s). It should be noted that the change of the lateral/septal ratio during a cardiac cycle includes the influence of both wall motion and the partial volume effect. Since the lateral/septal ratio for ungated was significantly lower than that for gated, it seems that the increase of the lateral/septal ratio in these frames was caused by wall motion rather than by partial volume effect. In comparison with normal subjects, the lateral/septal ratio in Case 1 showed no significant difference at each frame. In this case, the perfusion defect on the ^{99m}Tc -MIBI SPECT was limited to the apex. The lateral/septal ratio at each frame in Case 2 increased significantly compared with normal subjects. In this case, ^{99m}Tc -MIBI SPECT showed a wide perfusion defect in the anteroseptal wall. The change of the lateral/septal ratio at each frame may be helpful in evaluating wall motion following myocardial perfusion imaging.

Tracer uptake is underestimated more for ungated in patients with septal wall asynergy than for patients with lateral wall asynergy. Further studies should be performed on the effects of wall motion on regional myocardial uptake. Although our study population is limited, our results demonstrated advantages of ECG-gated SPECT.

CONCLUSION

Ungated SPECT acquisition may underestimate regional myocardial uptake when myocardial wall motion is good. Therefore, ECG-gated data should be acquired for accurate assessment of regional uptake.

ACKNOWLEDGMENT

This paper was presented at the 42nd Annual Meeting of the Society of Nuclear Medicine in Minneapolis, Minnesota on June 13, 1995.

REFERENCES

1. Wackers FJ, Berman DS, Maddahi J, et al. Technetium-99m-hexakis 2-methoxyisobutyl isonitrile: human biodistribution, dosimetry, safety and preliminary comparison to thallium-201 for myocardial perfusion imaging. *J Nucl Med* 1989;30:301-311.
2. Sinusas AJ, Beller GA, Smith WH, et al. Quantitative planar imaging with technetium-99m-methoxyisobutyl isonitrile: comparison of uptake patterns with thallium-201. *J Nucl Med* 1989;30:1456-1463.
3. Clausen M, Henze E, Schmidt A, et al. The contraction fraction (CF) in myocardial studies with technetium-99m-isonitrile(MIBI)-correlations with radionuclide ventriculography and infarct size measured by SPECT. *Eur J Nucl Med* 1989;15:661-664.
4. Leppo JA, DePuey EG, Johnson LL. A review of cardiac imaging with sestamibi and teboroxime. *J Nucl Med* 1991;32:2012-2022.
5. Sporn V, Perez Balino N, Holman BL, et al. Simultaneous measurement of ventricular function and myocardial perfusion using the technetium-99m isonitriles. *Clin Nucl Med* 1988;13:77-81.
6. Baillet GY, Mena IG, Kuperus JH, et al. Simultaneous ^{99m}Tc -MIBI angiography and myocardial perfusion imaging. *J Nucl Med* 1989;30:38-44.
7. Villanueva-Meyer J, Mena I, Narahara KA. Simultaneous assessment of left ventricular wall motion and myocardial perfusion with technetium-99m-methoxy isobutyl isonitrile at stress and rest in patients with angina: comparison with thallium-201 SPECT. *J Nucl Med* 1990;31:457-463.
8. Eisner RL, Martin SE, Leon AR, et al. Inhomogeneity of gated and ungated SPECT technetium-99m-sestamibi bull's-eyes in normal dogs: comparison with thallium-201. *J Nucl Med* 1993;34:281-287.
9. Germano G, Kiat H, Kavanagh PB, et al. Automatic quantification of ejection fraction from gated myocardial perfusion SPECT. *J Nucl Med* 1995;36:2138-2147.
10. Mannting F, Morgan-Mannting MG. Gated SPECT with technetium-99m-sestamibi for assessment of myocardial perfusion abnormalities. *J Nucl Med* 1993;34:601-608.
11. Depuey EG, Nichols K, Dobrinsky C. Left ventricular ejection fraction assessed from gated technetium-99m-sestamibi SPECT. *J Nucl Med* 1993;34:1871-1876.
12. Depuey EG, Rozanski A. Using gated technetium-99m-sestamibi SPECT to characterize fixed myocardial defects as infarct or artifact. *J Nucl Med* 1995;36:952-955.
13. Eisner RL, Schmarkey LS, Martin SE, et al. Defects on SPECT "perfusion" images can occur due to abnormal segmental contraction. *J Nucl Med* 1994;35:638-643.
14. Eisner RL, Nowak DJ, Pettigrew R, Fajman W. Fundamentals of 180-degree acquisition and reconstruction in SPECT imaging. *J Nucl Med* 1986;27:1717-1728.
15. Leon AR, Eisner RL, Martin SE, et al. Comparison of SPECT myocardial perfusion imaging with thallium-201 and technetium-99m-sestamibi in dogs. *J Am Coll Cardiol* 1992;20:1612-1625.