

Therapeutic approaches to prevent disease recurrence in uveitis

Supervisor Professor Susan Lightman

By

Ahmed Talib Kasb Al-Janabi

Institute of Ophthalmology/ University College London

PhD

December 2018

Author's declaration

I, Ahmed Talib Kasb Al-Janabi confirm that the work presented in this thesis is my own. Where information has been derived from other sources, I confirm that this has been indicated in the thesis.

Ahmed AL-JANABI

12 Dec. 18

Abstract

Uveitis is a significant cause of visual morbidity in the working-age population and has a high propensity to recur and cause damage to the ocular tissues which compromise the patient's sight and that can be irreversible. This dissertation addresses the question of how different treatment regimens influence disease recurrence, improve visual outcome and reduce the dose of concomitant immunosuppressive therapy in patients with sight-threatening ocular inflammatory conditions.

Therapeutic agents targeting specific inflammatory mediators are playing an increasingly important role in the management of non-infectious uveitis. The first study examined the role of anti-TNF α drugs and rituximab (anti-CD20) in controlling ocular inflammation in 82 patients with non-infectious, intermediate posterior and panuveitis refractory to conventional immunosuppression. Treatment with these agents achieved better disease control manifested by significant reduction in concomitant immunosuppressive therapy, substantial decrease in disease relapse rate and stability in visual acuity. Both adalimumab and infliximab have similar efficacy and corticosteroids sparing effect; however, compared to infliximab, adalimumab was better tolerated and was associated with significantly lower drug discontinuation rate (treatment failure). Behcet's patients on TNF α blockers had 75% risk reduction in disease recurrence compared non-Behcet's disease subjects which point to the central role of TNF α in Behcet disease pathogenesis. Finally, treatment with TNF α inhibitors and rituximab was effective for extended follow-up periods (5 years and beyond).

Statins used to reduce serum cholesterol and improve cardiovascular outcomes in high-risk patients was shown to have pleiotropic anti-inflammatory effects in several in-vivo and in vitro studies. The second study is a phase II, randomised, placebo-controlled trial, examined the effect of simvastatin (80 mg per day) on the amount of concomitant immunosuppressive drugs in 32 patients with non-infectious intermediate, posterior, and panuveitis, at one and two years follow-up visits. Analysing the mean prednisolone dose did not show a significant difference between the two groups. Therefore, there is no evidence to support the anti-inflammatory effect of simvastatin in uveitis. However, given the long-term exposure to corticosteroid-

based immunosuppressive therapy, these patients were found to have high serum cholesterol. Our data shows that intensive lipid lowering with simvastatin significantly decreased total cholesterol and LDL and thus reducing the risk of atherosclerotic cardiovascular diseases.

Ocular toxoplasmosis, the most common cause of infectious posterior uveitis, has drastic consequences on vision if it involves vision-sensitive structures. The third study looked retrospectively at the role of co-trimoxazole as a prophylactic agent in patients with recurrent sight-threatening disease. Prophylaxis course with co-trimoxazole treatment resulted in a substantial reduction in disease recurrence and significant improvement in vision in comparison to controls. To our knowledge, this is the first study to report improvement in visual acuity on prophylactic therapy, in a disease where no therapy, over the past two decades, was reported to achieve an increase in vision.

Impact statement

The impact of this research is particularly relevant to the management of patients with infectious and non-infectious sight-threatening uveitis, where persistent inflammation and frequent disease relapse can lead to substantial loss of vision. Infectious toxoplasmic retinochoroiditis and non-infectious intermediate posterior and panuveitis are incurable diseases with a largely unpredictable course. Classically the management of ocular toxoplasmosis involves controlling the acute inflammation with high dose corticosteroids with antiparasitic drugs and treatment usually stops after resolution of acute episode. However, after each episode there is more scarring and higher risk of vision loss even when treatment is timely instituted. In non-infectious uveitis, high dose corticosteroids along with other immunomodulatory agents are used. But unfortunately, any attempt to reduce or cease the immunosuppressive treatment often results in rebound of inflammation which can significantly further damage the ocular tissues and compromise vision, therefore higher (toxic) doses for long-term is needed.

This work has several implications in the management of patients with uveitis.

1. Patients with non-infectious uveitis particularly those with Behcet disease have an aggressive disease and at high risk of irreversible vision loss. TNF α blockers and rituximab are very useful in controlling ocular inflammation and preserve sight in uveitis recalcitrant to combination of high dose corticosteroid and immunomodulatory therapy. Treatment with anti-TNF α significantly reduced the amount of immunosuppressive drugs required by patients with non-infectious non-anterior uveitis. Behcet disease patients showed a significantly better response to TNF α blockers compared to other uveitis aetiologies, therefore these agents must be instituted early in the disease course to prevent severe visual impairment. Our data shows that adalimumab is as effective as infliximab and is better tolerated, therefore it should be first treatment option in non-infectious uveitis inadequately controlled with conventional immunosuppression. Etanercept was associated with high rate of treatment failure due to poor disease control and must be avoided in uveitis. Treatment was generally safe and well-tolerated, however due to relatively small sample further studies with larger sample are required to ascertain these results.

Finally, a therapy targeted to mediators of inflammation appears to have a superior efficacy in disease control. Thus, developing drugs that neutralize immune signalling is the future in uveitis management.

2. Simvastatin in sight-threatening uveitis trial did not show a robust anti-inflammatory effect measured by reduction in the amount of daily prednisolone dose and second-line immunosuppressive agents. Therefore, there is no need to add statin therapy to patients with ocular inflammatory diseases unless used to treat high cholesterol and improve cardiovascular outcomes in patients on high dose immunosuppressive therapy. Patients with chronic ocular inflammation which could be part of systemic disease are usually exposed to long-term corticosteroid-based immunosuppression and subsequently are at high risk of cardiovascular disease. Our result shows that just under two-thirds of patients in this study had high serum cholesterol, and intensive lipid lowering with 80 mg simvastatin achieved significant reduction in total cholesterol driven primarily by reduction in LDL-cholesterol. However, we could not establish how this relates to reduction in cardiovascular morbidity and mortality. Further studies are required to assess the risk of cardiovascular disease in patients with uveitis and high serum cholesterol.

3. Prophylactic treatment with co-trimoxazole significantly reduced the disease relapse rate and improved the vision in patients with recurrent toxoplasma retinochoroiditis compared to controls. Co-trimoxazole prophylaxis was effective and safe in the long-term management of patients with recurrent ocular toxoplasmosis. Therefore, this therapy should be widely offered to all patients with recurrent disease even when the macula is not involved since recurrent disease episode can lead to dissemination of parasite and infection of previously healthy retinal tissue. However, randomised-controlled trials with larger sample size are needed to confirm the study findings and establish the long-term safety of co-trimoxazole.

The results presented in this thesis add to the body of knowledge in this highly specialised area of sight-threatening uveitis.

Dedication

This thesis is dedicated to my mother, father, Professor Lightman and my wife Rafal.

Acknowledgments

This work in this thesis could not have been done without the kind support of Professor Lightman, who have helped me a lot throughout this work. She gave me a great privilege to be in her team and learn from her. Also, a special thanks go to my supervisor Oren Tomkins-Netzer for his unconditional support and his help with the statistics for the biologics chapter. Many thanks with great appreciation for the JP Moulton Charitable Foundation for the grant for the simvastatin study. Many thanks to Dr. Abdul-Hakim Al-Rawi who is no longer with us, nothing would have been possible without his kind help and unlimited support.

Many thanks for our patients, this work would not been possible without the enormous contributions from them. A huge thank you for both Sarah Mayhew and Hazel Lawrence, for all the help and support I have received from them. Also, thanks to my senior colleagues and great friends Lazha, Xia, Thora, Anastasia and Linda, thank you so much.

A big Thank you for Dr. Nura AL- Qassimi for the data entry for the simvastatin trial, and for being very helpful and kind all the time. Thanks to Dr. Ali Lamin who was supportive and very helpful. Thanks to Dr. Amgad Ali for his help with data collection in biologics chapter. Thanks to the library staff at the Institute of Ophthalmology (Debbie Heatlie, Debora Marletta and Desta Brooks. Many thanks for Hakim Dehbi UCL statistical services for his help with data analysis for the ocular toxoplasmosis. Also, many thanks for Dr. Gareth Ambler and Tao Ding for their help with the analysis of simvastatin in sight-threatening uveitis trial.

Table of Contents

1	Chapter One General introduction	40
1.1.1	The eye.....	41
1.1.2	Lens.....	44
1.1.3	Bruch's membrane.....	45
1.1.4	Retina	45
1.1.5	Retinal pigment epithelium (RPE)	46
1.1.6	Vitreous	47
1.2	Immunology	47
1.2.1	Basic terminology	49
1.2.2	The eye as an immune privileged site.....	49
1.3	Uveitis.....	53
1.3.1	Pathophysiology of uveitis.....	54
1.3.2	Epidemiology of uveitis	61
1.3.3	Classification of uveitis.....	63
1.3.4	The clinical course of uveitis	72
1.3.5	Symptoms of uveitis.....	72
1.3.6	Disease manifestations in uveitis	73
1.3.7	Diagnostic tools in uveitis.....	76
1.3.8	Complications of uveitis /Causes of vision loss in uveitis	84
1.3.9	Infectious causes of intraocular inflammation.....	99
1.3.10	Non-infectious (autoimmune) causes of intraocular inflammation.....	101

1.3.11	Management of uveitis.....	127
1.3.12	Therapy for uveitis	129
1.3.13	Why systemic therapy with immunosuppression appears superior to local corticosteroids treatment ?.....	133
1.3.14	Types of immunomodulatory therapy:.....	142
1.4	Aims of this thesis.....	159
2	Chapter Two Role of biological agents in patients with non-infectious intermediate, posterior and panuveitis (NIIPPU).....	160
2.1	Introduction.....	161
2.2	Role of anti-TNF α in ocular inflammation.....	163
2.2.1	VISUAL I, II and III.....	165
2.3	AIMS.....	168
2.4	Hypothesis:.....	169
2.5	Methods.....	170
2.6	Data collection	171
2.7	Definitions.....	173
2.7.1	The non-therapeutic dose of immunomodulatory agent	173
2.7.2	Relapses.....	174
2.7.3	Treatment failure.....	174
2.7.4	Disease control (remission).....	174
2.8	Inclusion criteria.....	174
2.9	Exclusion criteria.....	175
2.10	Statistical tests.....	175

2.11	RESULTS	176
2.12	Demographics.....	176
2.13	Corticosteroids dose analysis	182
2.13.1	Comparing Behcet versus non-Behcet disease patients with regards to corticosteroid dose reduction	186
2.13.2	Time to prednisolone dose less than 10 mg/day	187
2.13.3	Mean reduction in daily prednisolone dose on infliximab versus adalimumab 193	
2.14	Best corrected visual acuity	196
2.14.1	Analysing BCVA in non-Behcet disease versus Behcet disease patients.....	198
2.14.2	Causes of vision loss on biologic treatment	200
2.15	Second-line immunosuppressive agent.....	202
2.16	Disease relapse	204
2.16.1	Survival to the first disease relapse on Infliximab versus adalimumab	205
2.16.2	The relapse rate for Behcet and non-Behcet disease patients on biologics..	207
2.16.3	Disease relapses on other agents.....	211
2.17	Treatment failure.....	213
2.18	Periocular corticosteroids injections	221
2.19	Safety of biologic response modifiers.....	222
2.20	Discussion	223
2.21	Demographics.....	224
2.22	Disease control	226
2.22.1	Corticosteroids sparing	226

2.22.2	Immunomodulatory dose	235
2.22.3	Best Corrected Visual Acuity (BCVA).....	237
2.22.4	Disease relapses	240
2.23	Treatment failure.....	249
2.23.1	Switching from infliximab to adalimumab.	252
2.23.2	Is adalimumab is superior to infliximab in treating NIIPPU?	253
2.23.3	Role of adalimumab in NIIPPU	254
2.24	Safety of biologic response modifiers.....	256
2.25	Overall conclusion and the major impact of the study	258
	Limitations	260
3	Chapter Three Statins in inflammatory eye disease	262
3.1	Introduction	263
3.2	Background of statins	265
3.3	Statin's immunomodulatory effect	266
3.4	Anti-inflammatory effect of statin at the cellular level.....	269
3.5	Statin's clinical data	273
3.6	Statins in uveitis.....	273
3.7	Why simvastatin?.....	274
3.8	AIMS.....	275
3.9	Hypothesis	275
3.10	Declaration of Helsinki	276
3.11	Ethical approval	276

3.12	Funding.....	276
3.13	Methods.....	276
3.13.1	Inclusion and exclusion criteria	277
	Inclusion criteria.....	277
	Exclusion criteria.....	277
3.13.2	Patient recruitment.....	278
3.13.3	Randomisation.....	279
3.13.4	Follow-up visits	279
3.14	Statistical analysis.....	280
3.15	Primary outcome analysis.....	280
3.15.1	Outcome measures.....	281
3.16	Analysis of secondary outcomes.....	282
3.17	3.4 Exploratory analyses.....	282
3.18	Results.....	282
1.1	Enrolment	283
1.2	Allocation	283
1.3	Follow-Up	283
1.4	Primary Analysis	283
1.5	Secondary Analysis	283
3.18.1	Patients demographics and baseline characteristics	284
3.19	Primary outcome analysis.....	288
3.19.1	Time to prednisolone <10 mg per day.....	296

3.20	Secondary analysis.....	297
3.20.1	1. Prednisolone dose at 24 months.....	297
3.20.2	2. Reduction in 2 nd line immunosuppressive agents by 24 months.....	298
3.20.3	3. Disease relapses at 24 months.....	300
3.20.4	4. Blood cholesterol and lipid levels at baseline and 24 month.....	301
3.20.5	Relapse-free survival.....	305
3.20.6	CMO.....	306
3.20.7	Safety of simvastatin.....	312
3.20.8	CK.....	313
3.20.9	Liver enzymes.....	314
3.21	Exploratory analysis of visual acuity BCVA.....	317
3.22	Discussion.....	321
3.22.1	Prednisolone dose analysis.....	321
3.22.2	Second-line immunosuppressive agent.....	329
3.22.3	Disease relapse.....	330
3.22.4	Visual acuity analysis.....	330
3.22.5	Cholesterol analysis.....	331
3.22.6	Safety of simvastatin.....	334
3.23	Conclusion.....	334
4	Chapter Four Ocular toxoplasmosis and the role of long-term, low-dose trimethoprim-sulfamethoxazole prophylaxis in recurrent toxoplasmic retinochoroiditis.....	337
4.1	Background.....	338
4.2	Mode of transmission.....	338

4.3	The life cycle of toxoplasma gondii	339
4.4	Epidemiology	342
4.5	Pathogenesis of toxoplasmosis.....	345
4.6	Clinical presentation of ocular toxoplasmosis.....	347
4.7	Complications of ocular toxoplasmosis	349
4.8	Types of ocular toxoplasmosis infection.....	350
4.8.1	Congenital toxoplasmosis	350
4.8.2	Clinical features of congenital toxoplasmosis	351
4.8.3	Toxoplasmosis in the immunocompromised host.....	352
4.9	Diagnosis.....	353
4.10	Mechanisms of relapsing toxoplasmic retinochoroiditis	354
4.11	Treatment	358
4.11.1	Corticosteroids.....	363
4.12	The role of co-trimoxazole in ocular toxoplasmosis	366
4.13	Local treatments for toxoplasma retinochoroiditis	370
4.14	Treatments to reduce recurrent rates of toxoplasma retinochoroiditis	371
4.15	The rationale of intermittent co-trimoxazole treatment in toxoplasmic retinochoroiditis	372
4.16	When should we start prophylaxis?.....	372
4.17	Antibiotic prophylaxis in ocular toxoplasmosis.....	373
4.17.1	Co-trimoxazole prophylaxis in recurrent toxoplasmic retinochoroiditis.....	375
4.18	AIM.....	377
4.19	Design	377

4.20	Definition of Terms.....	378
4.21	Methods.....	379
4.22	Statistical analysis.....	381
4.23	RESULTS	382
4.23.1	Demographics.....	382
4.23.2	Location of the lesion	386
4.23.3	Best corrected visual acuity	386
4.23.4	Relapse rates.....	396
4.23.5	Multiple prophylactic courses	403
4.23.6	Safety of prophylaxis treatment.....	404
4.24	Discussion	404
4.24.1	Best Corrected Visual Acuity.....	407
4.24.2	Visual impairment	409
4.24.3	Relapses.....	410
4.24.4	Survival to first disease relapse	413
4.24.5	Explanation of current findings.....	415
4.24.6	Safety and tolerability of Co-trimoxazole.....	422
4.25	Limitations	423
4.26	Conclusion.....	423
5	Chapter Five Discussion and summary of this research, conclusions and recommendations	426
6	References	437
7	Appendices.....	481

List of figures

Figure 1-1 Cross section of the eye shows the uveal tissue. Web source	42
Figure 1-2 Colour fundus photograph shown the macular, fovea and optic nerve head. Web source https://en.wikipedia.org/wiki/Fundus_photography	45
Figure 1-3 Immune system responses in uveitis. Reproduced from a presentation by Alastair Denniston.....	60
Figure 1-4 Type of uveitis and the predominant site of inflammation (Jabs, Nussenblatt et al. 2005) (<i>SUN criteria</i>).....	64
Figure 1-5 Snowballs in the peripheral retina associated with vitreous haze. Photo courtesy of professor Lightman, Moorfields Eye Hospital.	69
Figure 1-6 Manifestations of intermediate uveitis (TOP) Severe inflammation of optic nerve head. (Bottom) snow banking. Photos courtesy of professor Lightman, Moorfields Eye Hospital.....	69
Figure 1-7 Leakage of fluorescein dye in active retinal vasculitis. Photos courtesy of Dr. Xia Moorfields Eye Hospital	74
Figure 1-8 Spectral domain OCT scan with segmentation of all the retinal layers. Web source https://academy.heidelbergengineering.com/course/view.php?id=356&utm_source=academy-teaser-en&utm_campaign=Handout_Retinal_Layers	79
Figure 1-9 CMO on fluorescein angiography shows the characteristic petaloid pattern. Source Moorfields Eye Hospital.	86
Figure 1-10 OCT scan shows CMO with cystoid changes at the fovea and sub retinal fluid in uveitis. Source Moorfields Eye Hospital.	87
Figure 1-11 Mutton fat KPs on the inner surface of the cornea in patients with sarcoid uveitis. Source Moorfields Eye Hospital	103

Figure 1-12 Focal periphlebitis (TOP) fluorescein leakage on dye test (BOTTOM) Focal periphlebitis in sarcoidosis. Source Moorfields Eye Hospital 104

Figure 1-13 Candle wax drippings (extensive periphlebitis in sarcoid associated vasculitis). Source Moorfields Eye Hospital. 104

Figure 1-14 Posterior segment finding in Behcet's disease, areas of retinitis at the fovea in both eyes. RE (left side image) superior branch retinal vein occlusion (BRVO). Source Moorfields Eye Hospital. 108

Figure 1-15 Extensive serous retinal detachment in VKH disease. Photo courtesy of professor Lightman. Source Moorfields Eye Hospital. 111

Figure 1-16 Disc hyperemia in VKH disease Photo courtesy of professor Lightman. Source Moorfields Eye Hospital. 112

Figure 1-17 Ocular manifestations in MS Optic neuritis with optic nerve head involvement. Source Moorfields Eye Hospital. 114

Figure 1-18 Focal periphlebitis in MS with fluorescein leakage on dye test. Photo courtesy of professor Lightman. Source Moorfields Eye Hospital. 114

Figure 1-19 Left eye with serpiginous choroiditis, areas of geographic atrophy are seen around the fovea. Source Moorfields Eye Hospital..... 120

Figure 1-20 Birdshot lesions in the posterior pole (Left) Birdshot disease complicated by CNV and haemorrhage at the fovea (Right). Photos are courtesy of professor Lightman. Source Moorfields Eye Hospital 122

Figure 1-21 TOP left PIC disease with active CNV, top right PIC scarring. Lower images FFA shows leakage from the CNV lesion. Photos are courtesy of Dr. Talat. Source Moorfields Eye Hospital..... 126

Figure 2-1 Snellen to LogMAR online calculator..... 172

Figure 2-2 Mean change in prednisolone dose on biologics over five years follow-up. At starting biologics, the mean daily prednisolone dose was 16.4 mg. However, on biologics the mean prednisolone dose reduced significantly from 3 months follow-up. Then mean prednisolone dose remained significantly lower compared to the baseline dose at all follow-up times. * Statistically significant, ** highly statistically significant. Please refer to table 2-6 for the mean differences and the corresponding p values. 183

Figure 2-3. Prednisolone dose at baseline (starting biologics) and last follow-up visit on biologic. There was a significant reduction in mean daily prednisolone dose on biological therapy (p-value<0.001, paired sample t-test). 184

Figure 2-4. The proportion of patients on daily prednisolone dose less than 10 mg per day. After starting biological therapy, 92% achieved daily prednisolone dose of < 10 mg by a median of 3 months 185

Figure 2-5 reduction in mean prednisolone dose in Behcet disease (BD) versus non-Behcet disease patients. 186

Figure 2-6 For all study population, the estimated mean time to prednisolone dose less than 10 mg per day, was 1.97 ± 0.30 SEM years; 95%CI 1.37-2.56. 188

Figure 2-7 Comparison between BD and none BD patients in mean time to prednisolone dose <10 mg/day shows a statistically non-significant difference between the two groups (p-value= 0.19). 189

Figure 2-8 Infliximab versus adalimumab in time to prednisolone dose under 10 mg per day. There was no statistically significant difference in time to prednisolone dose less than 10 mg per day, (p value 0.32, Log-Rank test). 190

Figure 2-9 Comparing infliximab versus adalimumab in time to prednisolone under 10 for non-Behcet. The median for infliximab was 3 months (95% 0-12); adalimumab median 3 months (95% CI 0-9), (p-value=0.45) 192

Figure 2-10 Time to prednisolone under 10 mg adalimumab versus infliximab in Behcet disease subjects. The median for infliximab was 6 months (95%CI 3-9 months), adamilumab median 3 months (95%CI 3-6) (p-value=0.42)..... 192

Figure 2-11 Analysing the mean prednisolone dose at baseline (starting biologics) shows no significant difference between infliximab and adalimumab (p-value=0.54, Mann Whitney U test, two-sided)..... 193

Figure 2-12 Analysing the mean daily prednisolone dose between infliximab and adalimumab at last follow-up visit shows no statistically significant difference (p-value=0.29, Mann Whitney U test, two-sided). Both drugs seems to have similar efficacy with regards to corticosteroid sparing. 194

Figure 2-13 Change in mean daily prednisolone dose on infliximab and adalimumab at all follow-up visits shows no statistically significant difference between the two anti TNF α agents. 195

Figure 2-14 Change in BCVA on biologics during the follow-up visits (*) statistically significant difference compared to baseline at 3, 6, 9 months and 2-year follow-up. 197

Figure 2-15 BCVA in LogMAR units at baseline, 3, 6, 9 and 1-5 years, Boxplots, there is a statistically significant improvement in vision at 3, 6, nine months and two years compared to baseline. 197

Figure 2-16 Behcet vs non-Behcet disease patients with regards to BCVA on biologics ... 199

Figure 2-17 percentage of eyes with no loss of vision, moderate vision loss and severe vision loss during follow-up periods. The proportion of eyes without vision loss rose significantly from 62.7% at baseline to 70.5% and 74.8% at 6 months and 2-year, respectively (p values = 0.004 at 6 months and 0.01 at 2-year..... 200

Figure 2-18 Change in the percentage of patients on second-line agents after 20, 40 and 60 months on biologics. Significantly lower proportion of patients receiving therapeutic dose of

second line agents after starting biologics compared to baseline. (**) highly statistically significant difference at 2 and 5 years follow-up (p-value < 0.0001) Fisher's Exact test..... 202

Figure 2-19 the proportion of eyes that flared on biologics was 42.3% (n=66). The estimated median time to first disease relapse was 5.41 years. 204

Figure 2-20 Survival from flare on adalimumab versus infliximab in all patients. No statistically significant difference between infliximab and adalimumab with regards to time to the first disease relapse (p-value =0.097, Log-Rank test)..... 205

Figure 2-21 Survival from flare infliximab versus adalimumab in non-Behcet's disease patients. there was no significant difference in time to first flare between infliximab and adalimumab (p-value= 0.42, Log-Rank test)..... 206

Figure 2-22 survival to the first disease relapse on infliximab and adalimumab. There was no significant difference in time to first flare between these two biologics (p-value =0 .58, Log-Rank test) 207

Figure 2-23 a statistically significant difference in the average number of disease relapse on biologics in Behcet versus non-Behcet disease patients, (p-value<0.001). Mann-Whitney U test, two-sided)..... 208

Figure 2-24 Kaplan Meir analysis for survival to first disease relapse for Behcet versus non-Behcet disease patient, shows a highly statistically significant difference between the two groups (p-value<0.001). 209

Figure 2-25 Cox regression analysis, which showed a highly statistically significant difference between the two groups with a hazard ratio HR of 0.25; (p-value of <0.001). ... 210

Figure 2-26 Disease relapse on etanercept. The mean time to first disease relapse was 1.82 ±0.76 SEM; 95% CI 0.32-3.33 years, estimated median time 0.82 years and IQR 0. 23-1.46 years. 211

Figure 2-27 Disease relapse on rituximab. The mean time to first disease relapse was 4.18 years. Median was not calculated due to small number of eyes with disease relapse. 212

Figure 2-28 Treatment failure on biologics. Only 28% (23 out of 82 patients) failed their first biological treatment. Estimated mean time to treatment failure was 9.44 years \pm 085; 95%CI 7.76- 11.11, the median was not calculated as it did not reach 50%. 213

Figure 2-29 comparing survival to treatment failure on infliximab and adalimumab. There was a statistically significant difference in time to treatment failure between the two biologic (p-value=0.003, Log-Rank test). Adalimumab has superior drug retention rate compared to infliximab..... 214

Figure 2-30 Cox regression analysis for treatment failure on infliximab and adalimumab. Hazard Ratio 0.35, p-value =0.004..... 215

Figure 2-31 Treatment failure for non-Behcet disease patients, a statistically significant difference between infliximab and adalimumab in time to treatment failure (p-value =0.01, Log-Rank test). 216

Figure 2-32 For Behcet disease patients there was no significant difference between infliximab and adalimumab in time to treatment failure (p-value=0.23, Log-Rank Test). 217

Figure 2-33 Survival to treatment failure in Behcet and non-Behcet disease patients. There was no significant difference in time to treatment failure between the two groups,(p-value =0. 10 Log-Rank test). 218

Figure 2-34 Survival to treatment failure on adalimumab. 220

Figure 2-35 Time to treatment failure after switching form infliximab to adalimumab. The median time to treatment failure on infliximab was1.65 years; 95% CI 1.31-1.99 years, whereas on adalimumab the median was not calculated due to very few numbers of patients who failed the treatment..... 221

Figure 2-36 comparing the number of local corticosteroid injections before and during biologics, shows a statistically significant difference, (p -value <0.001)..... 222

Figure 2-37 Trend for daily corticosteroids dose for patients with active disease, inactive disease and overall study population on adalimumab in VISUAL III study..... 228

Figure 2-38 Infliximab versus Adalimumab in the Treatment of Refractory Inflammatory Uveitis: A Multicenter Study From the French Uveitis Network (Vallet, Seve et al. 2016) .. 242

Figure 3-1 effects of statins on T cells and antigen presenting cells (Greenwood, Steinman et al. 2006)..... 268

Figure 3-2 Disease duration at baseline for patients in both treatment groups. Although patients on placebo had longer disease duration, there was no statistically significant difference between the two groups (p -value =0.21, two sample t-test, two-sided). 287

Figure 3-3 Baseline oral prednisolone dose between the placebo and the simvastatin group. There was no statistically significant difference with regards to daily oral prednisolone dose between the two groups, (p -value= 0.50, Mann-Whitney U test two-sided)..... 288

Figure 3-4 Distribution of prednisolone dose at baseline and 12 months..... 290

Figure 3-5 (0) Represents the baseline value (1) Baseline (2) Three months visit (3) six months visit(4) nine months visit (5) one year 291

Figure 3-6 Mean dose for simvastatin and placebo group from baseline up to 52 weeks. There was no significant difference between the two study arms. 293

Figure 3-7. Percentage of patients with prednisolone dose below 10mg (safety dose). There was no significant difference in proportion of patients on less than 10 mg prednisolone daily between the two groups at 3,6,9, and 12 months. (0) represents baseline where all patients were ≥ 10 mg and above (study inclusion criteria)..... 294

Figure 3-8. Scatter plot of prednisolone dose at 12 months versus baseline. At one year the majority of patients in the study have had their prednisolone dose reduced below 10 mg per day..... 294

Figure 3-9 Prednisolone analysis for patients with less than 20 mg at the initial study visit shows no significant difference in proportion of patients on less than 10 mg per day prednisolone at all follow-up visits between the two study arms. 296

Figure 3-10 Time to prednisolone dose less than 10 mg per day for simvastatin and placebo group. There was no significant difference between the two groups with regards to time to daily prednisolone dose below 10 mg (p-value = 0.87, Log-Rank test)..... 297

Figure 3-11 Proportion of patients with active disease for the simvastatin and the placebo group. There was no significant difference between the two groups at all follow-up visits. 300

Figure 3-12 CRP level at baseline. There was no statistically significant difference between the two groups 303

Figure 3-13 CRP level for placebo and simvastatin group at one-year follow-up. There was no statistically significant difference between the two groups (p-value=0.87) 304

Figure 3-14 Relapse-free survival. For all study population the overall mean survival to first relapse was 0.58 years. 305

Figure 3-15 Survival to first disease relapse for simvastatin and placebo groups. Kaplan Meier survival analysis curve did not show a statistically significant difference between the two groups, (p-value= 0.089, Log-Rank test)..... 306

Figure 3-16 Proportion of patients with CMO in simvastatin and placebo groups. There was no significant difference between the two arms at all study visits. 307

Figure 3-17 the mean total cholesterol for placebo and simvastatin groups at baseline. There was no significant difference between the two groups (p-value= 0.42 independent sample t-test)..... 308

Figure 3-18 LDL cholesterol level for simvastatin and placebo groups at baseline There was no significant difference between the two groups (p-value= 0.45 independent sample t-test) 308

Figure 3-19 HDL cholesterol level for the placebo and simvastatin groups at baseline. (p-value= 0.57, two-sample t-test) 309

Figure 3-20 Change in total cholesterol level for the placebo and simvastatin group during the first year follow-up, p-value=0.001..... 310

Figure 3-21 Change in LDL cholesterol level for the placebo and simvastatin group during the first year follow-up. One-Way Repeated measure ANOVA showed a highly statistically significant difference between the two groups, (F value =18.34, p-value<0.001)..... 311

Figure 3-22 Change in HDL cholesterol level for the placebo and simvastatin group during the first year follow-up HDL did not reveal a statistically significant difference between the two group, (p-value=0.77, F value=0.082, One-Way Repeated measure ANOVA)..... 311

Figure 3-23 Change in triglycerides level for the placebo and simvastatin group during the first year of follow-up did not show a statistically significant difference (p-value=0.14 and the F value is 2.26, One-Way Repeated measure ANOVA). 312

Figure 3-24 Creatinine kinase (CK) level at baseline for placebo and simvastatin groups, there was no statistically significant difference between the two groups (p-value=0.83).... 313

Figure 3-25 Creatinine kinase (CK) level for the placebo and the simvastatin at one year follow-up, did not show a statistically significant difference between the two groups (p-value=0.42)..... 314

Figure 3-26 Mean difference in alanine transaminase (ALT) from baseline for placebo and simvastatin groups 315

Figure 3-27 Mean difference in aspartate transaminase (AST) from baseline for placebo and simvastatin groups 316

Figure 3-28 Mean difference in serum alkaline phosphatase (ALK) from baseline for placebo and simvastatin groups	316
Figure 3-29 BCVA for the placebo and simvastatin groups at baseline	318
Figure 3-30 Trend in visual acuity over 12 months for the left eye (measured in LogMAR) shows no difference between the two study arms.	320
Figure 3-31 Trend in visual acuity over 12 months for the right eye (measured in LogMAR) shows no difference between the two study arms.	320
Figure 4-1 the lifecycle of toxoplasma gondii/ Source, Image from Sherris Medical Microbiology 1996.....	339
Figure 4-2 factors involved in tachyzoites-bradyzoites interconversion (Lyons, McLeod et al. 2002)	340
Figure 4-3 Tissue cyst in mouse brain on electronic transmission microscopy A cyst wall, B bradyzoites (Cenci-Goga, Rossitto et al. 2011). Photo by Dr. Marcello Tosti, Veterinarian, Perugia	341
Figure 4-4 Classical reactivation of ocular toxoplasmosis at the edge of a previous scar. Source Moorfields Eye Hospital	348
Figure 4-5 Toxoplasmosis scar at the macula with permanent loss of vision. Source Moorfields Eye Hospital.	349
Figure 4-6 Congenital toxoplasma infection with retinal scarring. Source Moorfields Eye Hospital.....	351
Figure 4-7 Reactivation of macular toxoplasmic retinochoroiditis lesion with subsequent loss of vision due to foveal involvement in a patient in the control group (without co-trimoxazole prophylaxis). Source Moorfields Eye Hospital.	356
Figure 4-8 Active toxoplasmic retinochoroiditis at the macula and close to the fovea. Source Moorfields Eye Hospital	360

Figure 4-9 the activity of trimethoprim and sulfamethoxazole alone and in combination on the multiplication of toxoplasma gondii (Nguyen and Stadtsbaeder 1975).....	368
Figure 4-10 Reactivation of toxoplasmosis. Photos are courtesy of professor Lightman. Source Moorfields Eye Hospital.	374
Figure 4-11 Age at first presentation for the co-trimoxazole and the control group. There was no significant difference between the two groups (p value=0.55, Mann-Whitney, two-sided test).....	383
Figure 4-12 Total follow-up time (months) for the co-trimoxazole and control groups. There was no statistically significant difference in follow-up time between the two groups (p-value = 0.81, Mann Whitney U, two-sided test).....	384
Figure 4-13 the difference in mean BCVA between the co-trimoxazole and control groups at first presentation was not statistically significant, (p-value= 0.054, Mann-Whitney U, two-sided test).	387
Figure 4-14 BCVA between the two groups at three months a statistically significant difference between the two groups (p-value = 0.046, GEE).	390
Figure 4-15 mean BCVA at one year, p-value =0.072, GEE (two-sided)	390
Figure 4-16 BCVA between co-trimoxazole and control group at last follow-up. The difference in mean BCVA at last follow-up visit was highly statistically significant (p-value=0.044) using GEE test	391
Figure 4-17 the mean BCVA at initiation and last visit on co-trimoxazole prophylaxis (p-value=0.002, Wilcoxon Signed Rank test).....	392
Figure 4-18 Mean change in BCVA from baseline.....	393
Figure 4-19 BCVA in patients with visual impairment (MVL+SVL) at initiating co-trimoxazole prophylaxis. There was a statistically significant difference in BCVA between the start and end of prophylaxis (p-value 0.018, Wilcoxon Signed Rank Test).....	395

Figure 4-20 Relapse rate per year for both groups before co-trimoxazole prophylaxis, a statistically significant difference, (p-value = 0.022, Mann Whitney U test, two-sided)..... 397

Figure 4-21 Relapse rate per year of toxoplasmic retinochoroiditis before and during Co-trimoxazole prophylaxis. A highly statistically significant difference (p-value <0.001, Wilcoxon Sign Rank test, two-sided). 398

Figure 4-22 Relapse-free survival between the control group and co-trimoxazole group Kaplan Meir survival analysis with Log-rank test for significance (p-value =0. 022) 400

Figure 4-23 Hazard curve between the control group and co-trimoxazole group, HR 0.30 (95%CI; 0.10-0.88) (p-value=0.03) 400

Figure 4-24 Disease-free survival between the control group and co-trimoxazole group. Kaplan Meir survival curves show a significant difference in disease relapses between the two groups (p-value of 0.007, Log Rank Test)..... 401

Figure 4-25 Post co-trimoxazole prophylaxis survival curves between the control group and co-trimoxazole group (p-value=0.17, Log Rank Test)..... 402

Figure 4-26 Immunomodulatory effect of co-trimoxazole (Church, Fitzgerald et al. 2015). 420

List of tables

Table 1-1 the SUN working group anatomical classification of Uveitis (Jabs, Nussenblatt et al. 2005).....	63
Table 1-2 (LEFT) Grading of anterior chamber cellular activity higher scores visible on examination indicate more severe disease. Table 1-3 (RIGHT) SUN Classification of anterior vitreous activity (Jabs, Nussenblatt et al. 2005).....	65
Table 1-4 grading anterior chamber flare (Jabs, Nussenblatt et al. 2005).....	65
Table 1-5 Blood tests in uveitis	77
Table 1-6 Disease-specific tests in uveitis.....	78
Table 1-7 Imaging studies in selected cases with uveitis.....	78
Table 1-8 Diagnostic System for Behcet Information from Behcet disease Research Committee of Japan. Behcet disease: a guide to the diagnosis of Behcet disease. Jpn J Ophthalmol. 1974;18:291-294.....	106
Table 1-9 Side effects of systemic corticosteroids therapy (Stanbury and Graham 1998) .	138
Table 1-10 Indications for initiating systemic non-corticosteroids immunomodulatory therapy (Dick, Rosenbaum et al. 2018).....	142
Table 1-11 Key features and differences between different types of TNF α agents adopted from (Pleyer and Foster 2007)	154
Table 2-1 LogMAR and Snellen equivalent for BCVA.....	172
Table 2-2 Patients demographics and anatomical type of uveitis.	177
Table 2-3. Disease aetiology.....	178
Table 2-4 First biologic drug and the corresponding number of eyes	178

Table 2-5. Demographic data for patients treated with infliximab and adalimumab	179
Table 2-6 Mean reductions of oral prednisolone dose from baseline. The result was statistically significant at three months and remained highly statistically significant from 6 months up to five years follow-up. * Statistically significant, ** highly statistically significant.	182
Table 2-7 Prednisolone dose for Behcet and non-Behcet disease patients, the reduction in mean oral prednisolone dose was consistently highly statistically (**) significant from three months until the last follow-up in Behcet patients compared to a non-Behcet disease.	187
Table 2-8 median time to prednisolone less than 10 mg per day among different biologic agents.....	190
Table 2-9 Mean prednisolone dose at all study follow-up visits for infliximab and adalimumab groups. There was no statistically significant difference between the two groups (p-value >0.05).	195
Table 2-10 Mean BCVA at baseline and subsequent follow-up visits on biologics.....	196
Table 2-11 Comparing baseline BCVA at baseline with different follow-up time points.....	198
Table 2-12 Comparing baseline BCVA (Log MAR) versus different time points (p-values), (*) statistically significant.....	199
Table 2-13 Number of eyes with or without visual impairment at baseline and subsequent visits on biologics	201
Table 2-14 Causes of vision loss on biologics. Macular scarring was the most common cause for both moderate ad severe vision loss, whereas, CMO came second to macular scarring.....	201
Table 2-15 Percentage of patients on therapeutic dose and a non-therapeutic dose of second-line agents.....	203

Table 2-16 Multivariate analysis for factors associated with treatment failure on infliximab and adalimumab.	219
Table 3-1 Simvastatin trial inclusion and exclusion criteria.....	277
Table 3-2 Primary and secondary endpoints for simvastatin trial.....	282
Table 3-3 Baseline characteristics for patients in simvastatin and placebo group.....	285
Table 3-4 Underlying diagnoses for patients on simvastatin and placebo.....	286
Table 3-5 Mean prednisolone dose at baseline and study follow-up visits shows no significant difference between the two study arms (p-value> 0.05, Mann Whitney U test).	289
Table 3-6 Mean difference of prednisolone dose for simvastatin and placebo group during first-year follow-up.....	291
Table 3-7 Trend in prednisolone dose and the percentage of patients whose dose is below 10mg over 12 months by treatment group.....	292
Table 3-8 Regression analysis for primary outcome.....	295
Table 3-9 Regression analysis for secondary outcome	298
Table 3-10. Number of patients on second-line immunosuppressive agents in both, simvastatin and placebo group at baseline.....	298
Table 3-11. The number of patients with a reduction in second-line immunosuppressive agents (IMT) The chi-square test suggests that there is weak evidence of a difference between the two groups regarding reduction in the second-line IMT.	299
Table 3-12 Number of patients with relapses by 24 months the chi-square test suggests that there is weak evidence of a difference between the two groups in disease relapses.....	301
Table 3-13. Descriptive analysis of blood cholesterol and lipid levels.....	302
Table 3-14 Liver enzyme analysis for the placebo group.....	314
Table 3-15 Liver enzymes analysis for the simvastatin group.....	315

Table 3-16 Mean BCVA for placebo and simvastatin groups at study follow-up visits.	317
Table 3-17 BCVA (Log MAR) at baseline and during trial follow-up visits for the simvastatin and the placebo group.	319
Table 3-18 Mean visual acuities over time (measured in LogMAR).....	319
Table 4-1 Systemic treatment option in ocular toxoplasmosis	362
Table 4-2 (Nguyen and Stadtsbaeder 1975).	368
Table 4-3 Baseline characteristics.....	385
Table 4-4 Mean BCVA for co-trimoxazole group and controls at baseline, three, six, twelve months and last follow-up visit.	388
Table 4-5 Mean difference in BCVA from baseline and between groups using GEE.	389
Table 4-6 Mean difference in BCVA from baseline for co-trimoxazole and control groups.	393
Table 4-7 causes of moderate and severe vision loss in eyes with recurrent toxoplasma retinochoroiditis.....	396
Table 4-8 Comparison of relapse rate per year and proportion of patients with disease relapse in co-trimoxazole and control groups.	399

List of Abbreviations

µm	Micrometre
AAU	Acute Anterior Uveitis
AC	Anterior chamber
ACAID	Anterior chamber associated immune deviation
ACE	Angiotensin converting enzyme
AMD	Age related macular degeneration
ANA	Antinuclear antibody
ANCA	Anti-neutrophil cytoplasmic antibody
Anti-ds DNA	Anti-double strand DNA
APC	Antigen presenting cells
APMPPE	Acute posterior multifocal placoid pigment epitheliopathy
ARN	Acute retinal necrosis
AS	Ankylosing spondylitis
AZA	Azathioprine
BBB	Blood brain barrier
BCVA	Best corrected visual acuity
BD	Behcet's disease
BM	Bruch's membrane
BRB	Blood retinal barrier
BRVO	Branch retinal vein occlusion
BSCR	Birdshot chorioretinopathy
CAM	Cell adhesion molecules
CD4	Cluster of differentiation 4 (glycoprotein marker on T cells)
CF	Counting fingers
CI	Confidence intervals
CK	Creatinine kinase
CMO	Cystoid macular oedema
CMV	Cytomegalovirus
CNS	Central nervous system

CNVM	Choroidal neovascular membrane
Co-trimoxazole	Combination of trimethoprim and sulfamethoxazole
COX	cyclooxygenase
CRAO	Central retinal artery occlusion
CRT	Central retinal thickness
CRVO	Central retinal vein occlusion
CS	Corticosteroids
CSF	Cerebrospinal fluid
CT	Computerized tomography
D	Dioptre
DH	Delayed hypersensitivity
DM	Diabetes mellitus
DMO	Diabetic macular oedema
DNA	Deoxyribonucleic acid
EAU	Experimental autoimmune uveoretinitis
ELISA	Enzyme linked immunosorbent assay
ERG	Electroretinogram
ERM	Epiretinal membrane
ESR	Erythrocytes sedimentation rate
EUA	Experimental autoimmune uveitis
Fab	Antigen-binding fragment
FAF	Fundus autofluorescence
FBC	Full blood count
Fc	Fragment crystallisable
FDA	Food and drug administration
FFA	Fundus fluorescein angiography
GEE	Generalized estimating equation
GPA	Granulomatosis with polyangiitis
Hb	Haemoglobin
HBA1c	Haemoglobin A 1c
HDL	High density lipoprotein
HIV	Human immune deficiency virus
HLA- B27	Human leukocyte antigen B 27

HM	Hand motion
HMG-CoA	Hydroxymethylglutaryl Co A
HR	Hazard Ratio
HSV	Herpes simplex virus
HTLV1	Human T cell lymphotropic virus 1
ICAM	Inter cellular adhesion molecules
ICG	Indocyanine Green angiography
Ig	Immunoglobulin
IgG	Immunoglobulin
IL	Interleukin
IL-1 β	Interleukin- 1 Beta
IMT	Immunomodulatory therapy
INF	Interferon
IOL	Intraocular lens
IOP	Intraocular pressure
IQR	Interquartile range
IU	Intermediate uveitis
IVTA	Intravitreal triamcinolone acetonide
JIA	juvenile idiopathic arthritis
K	Potassium
KP	Keratic precipitate
LDL	Low density lipoprotein
LFA-1	Leukocyte function associated antigen 1
LFT	Liver function test
LogMAR	Logarithm of the Minimal Angle of Resolution
mAb	Monoclonal antibody
MFC	Multifocal choroiditis
MHC	Major histocompatibility complex
ml	Millilitre
MMF	Mycophenolate mofetil
mmHg	Millimetre of mercury
MMP	Metalloproteinases
MR	Magnetic resonance imaging

MS	Multiple sclerosis
MUST	Multicentre Uveitis Steroid Treatment Trial
MXT	Methotrexate
Na	Sodium
Nd:YAG	Neodymium-doped yttrium aluminium garnet laser
NF-Kb	Nuclear Factor Kappa Beta
NIIPPU	Non-infectious intermediate, posterior and panuveitis
nm	Nanometre
NPL	No perception of light
NSAID	Non-steroidal anti-inflammatory drugs
NV	Neovascularization
OCT	Optical coherence tomography
OCT A	OCT Angiography
OFI	Orbital floor injection
PCO	Posterior capsular opacification
PCR	Polymerase chain reaction
PG	Prostaglandin
PIC	Punctate inner choroidopathy
PL	Perception of light
PMN	Polymorphonuclear cells
POHS	Presumed ocular histoplasmosis
POINT	PeriOcular versus INTravitreal corticosteroids for uveitic macular oedema
PS	Posterior synechiae
PU	Panuveitis
PUK	Peripheral ulcerative keratitis
Ras	Family of related proteins belongs to small GTPase and are involved in cellular signal transduction
RBC	Red blood cells
RD	Retinal detachment
RF	Rheumatoid factor
Rho	A protein involved in termination of transcription
RNA	Ribonucleic acid

RPE	Retinal pigment epithelium
SD	Standard deviation
SE	Standard error
SEM	Standard Error of the Mean
SITE	Systemic Immunosuppression Therapy for Eye disease
SLE	Systemic lupus erythematosus
SO	Sympathetic ophthalmia
SUN	Standardization of uveitis nomenclature
T reg	T regulatory cells
TB	Tuberculosis
TGF β	Transforming growth factor Beta
Th	T helper cells
TNF α	Tumour necrosis factor alpha
TNFR	Tumour Necrosis Factor Receptor
TRC	Toxoplasma retinochoroiditis
UCL	University College London
UK	United Kingdom
US	United states
VA	Visual Acuity
VDRL	Venereal disease Research Laboratory
VEGF	Vascular endothelial growth factor
VH	Vitreous haemorrhage
VKH	Vogt Koyanagi Harada
WBC	White blood cells

1 Chapter One General introduction

1.1.1 The eye

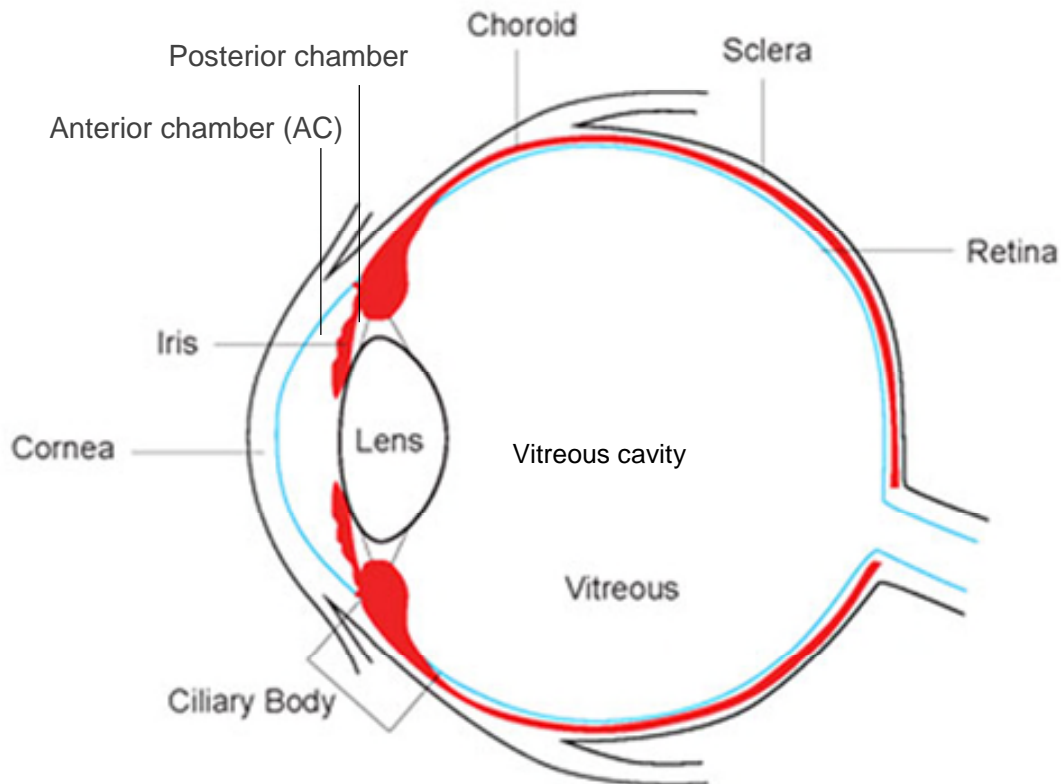
The eyeball or globe is a spherical structure but not a perfect sphere because the corneal radius of curvature (8 mm) is less than that of the sclera (12 mm). The anteroposterior diameter of the eye is 23-25 mm and an average transverse diameter of 24 mm.

The eye contains three compartments; the anterior chamber, posterior chamber and the vitreous cavity. The anterior chamber is the space between the cornea and the iris, and it is filled with aqueous fluid. It has an average volume of 200 μ L and measures 3 mm in depth. The posterior chamber is the space between the iris and the anterior surface of the lens and also contains aqueous but with a much smaller volume (60 μ L). The vitreous cavity is the largest compartment, which forms two-thirds of the total eye volume (5-6 mL) and encloses the vitreous gel. Figure 1-1.

The eyeball consists of three concentric layers. The external (outermost) one is composed of the transparent cornea anteriorly, and opaque sclera posteriorly and these are composed of collagen fibres and protect the intraocular structures. The middle layer is the uvea, and it consists of (anterior to posterior), iris, ciliary body and choroid. The innermost layer is the retina, which is the photosensitive layer that contains the photoreceptors and the neuronal cells and networks. The retina is responsible for processing the visual signals which are then transmitted to the brain via the optic nerve (American Academy of 2017).

Figure 1-1 Cross section of the eye shows the uveal tissue. Web source

<https://www.foresteyesurgery.com.au/blog/?post=spring-2016-gp-newsletter>



1.1.1.1 Anatomy of the uvea

Uvea is a Latin origin from the word *uva*, which means grape, as the eye, peeled of sclera, would appear as a darkly pigmented, densely lobulated structure, hanging from optic nerve which represent the stalk. The uveal tract is the middle layer, highly vascular, pigmented tissue of the eye, Figure.1-1 and it provides nourishments and support to the underlying structure. The uvea is composed of three distinct portions:

- A. Iris
- B. Ciliary body and
- C. Choroid (Foster and Vitale 2002).

1.1.1.1.1 Iris

The iris is the most anterior extension of the uveal tract, and it is composed of blood vessels and connective tissue. It has melanocyte and pigmented cells which give the iris its unique colour. The iris acts as a diaphragm to control the amount of light entering the eye by changing the pupil size. When the eye is dilated (mydriasis) the iris is pulled into ridges and folds; while during pupil constriction (miosis) it assumes a relatively smooth anterior surface. The diaphragm splits the anterior segment of the eye into anterior and posterior chambers. The iris stroma is made from blood vessels and connective tissue. The blood vessels within the iris follow a radial course toward the centre of the pupil. These blood vessels have a non-fenestrated endothelium and are surrounded by a basement membrane, associated pericytes. The posterior surface is composed of densely pigmented cells which are continuous with the non-pigmented epithelium of the ciliary body whence it continues with the neurosensory retina (Wright, Spiegel et al. 2013). The iris dilator muscle lies parallel and anterior to the posterior pigmented epithelium whereas the sphincter muscles assume a circular fashion and rest at the pupillary border.

1.1.1.2 Ciliary body

The ciliary body is triangular in cross-section with its apex directed posteriorly toward the ora serrata, while its base gives rise to the iris. The ciliary body inserts to the scleral spur via its longitudinal muscle fibres, and this represents the only attachment of the ciliary body to the sclera. The two principal functions of the ciliary body are lens accommodation and aqueous humour production. Its body measures 6-7 mm in width and consists of two parts:

A. The pars plana is avascular, smooth and pigmented zone of 4 mm wide. The lack of blood vessels makes this part a suitable site for accessing the vitreous cavity when applying intravitreal injections and performing vitreoretinal surgeries.

B. The pars plicata is the heavily vascularized portion of the ciliary body and consists of the ciliary processes which give rise to the zonular fibres that hold the lens in position and control the changes in the shape of the intraocular lens during accommodation. The blood supply is through the anterior and long posterior ciliary

arteries which fuse to form the arterial plexus that supplies the iris in addition to the ciliary body (American Academy of 2017).

1.1.1.3 Choroid

The choroid is the largest and most posterior portion of the uvea; it is vital for health and normal function of the outer retina through providing nourishment and oxygen. The choroid is located between the retinal pigment epithelium (RPE) and the sclera, and it's composed of blood vessels, melanocytes, fibroblasts and supporting collagenous and elastic connective tissue. Also, immunocompetent cells reside within the choroid. (Nickla and Wallman 2010). It measures on average 0.25 mm in thickness and consists of three layers from inside (Zierhut, Pavesio et al. 2016).

1. The choriocapillaris
2. A middle layer of small blood vessels (Sattler's layer)
3. An outer layer of large blood vessels (Haller's layer) (Albert and Jakobiec).

The choriocapillaris forms a single plane and lies beneath the RPE. These capillaries have an extremely thin wall and lots of fenestrations mainly on their retinal facing surface. The middle and outer layers of the choroid have larger diameter blood vessels, are not fenestrated, and resemble small arteries elsewhere. The blood supply of the choroid is derived from the long and short posterior ciliary arteries and perforating anterior ciliary arteries. The choroid drains to the superior and inferior ophthalmic veins via the vortex veins which are 4-6 in number. Within the choroid, the oxygen concentration of the venous blood is only 2% - 3% lower than that of the arterial blood owing to fast blood circulation (American Academy of 2017).

1.1.2 Lens

The lens is a biconcave structure, situated behind the iris and the posterior chamber. It contributes to 20 D (dioptr) of the total refractive power of the eye (60 D). The lens is 9-10 mm in diameter and 6 mm in depth in the adult. The lens is composed of fibres and epithelial cells which lies beneath the anterior and equatorial capsule. The lamina (lens capsule) encloses the whole lens, and it lacks innervation and vascularisation (American Academy of 2017).

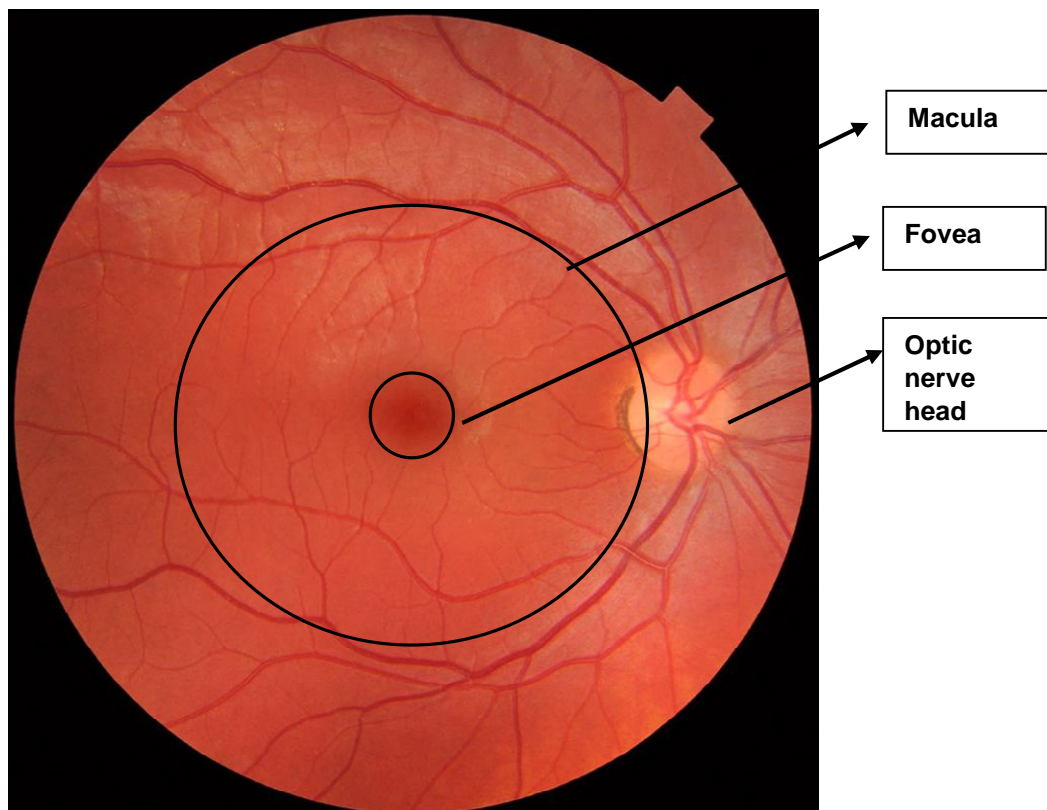
1.1.3 Bruch's membrane

Bruch's membrane is a lamina (sheet), consisting of a series of connective tissues that are highly permeable to small molecules such as fluorescein. It results from the fusion of the basal laminae of the retinal pigment epithelium (RPE) and the choriocapillaris of the choroid. It runs from the margin of the optic nerve to the ora serrata, which lies at the far retinal periphery and it represents the junction between the retina and pars plana (ciliary body) (American Academy of 2017).

1.1.4 Retina

The fundus oculi or (ocular fundus) includes the retina and its vessels, optic nerve head or (optic disc). The macula, 5-6 mm in diameter, lies between the temporal vascular arcades or histologically the area which has two or more layers of ganglion cells. At its centre lies the fovea, a concave central depression measures approximately 1.5 mm in diameter, the fovea is rich in cones and responsible for the highest visual acuity and colour perceptions. Figure 1-2. (Orth, Fine et al. 1977).

Figure 1-2 Colour fundus photograph shown the macular, fovea and optic nerve head. Web source https://en.wikipedia.org/wiki/Fundus_photography



The retina is thin and transparent and consists of 10 layers on a cross section. From the inner (close to the vitreous) to the outer (close to the RPE):

1. Internal limiting membrane
2. Nerve fibre layer
3. Ganglion cells layer
4. Inner plexiform layer
5. Inner nuclear layer
6. Outer plexiform layer
7. Outer nuclear layer
8. External limiting membrane
9. Rods and cones inner and outer segments.
10. RPE

The central retinal artery supplies the inner portion of the retina. A cilioretinal artery can branch from the ciliary circulation to supply the macula in around 18%-32% of eyes. The retinal blood vessels resemble cerebral blood vessels and maintain the inner blood-retinal barrier. This physiologic barrier is made of a single layer of non-fenestrated endothelial cells, whose tight junctions are impermeable even to tiny substances, such as fluorescein. A basal lamina covers the outer surface of the endothelium. An interrupted layer of pericytes is situated within the basement membrane (American Academy of 2017).

1.1.5 Retinal pigment epithelium (RPE)

The RPE consists of a monolayer of hexagonal cells that extends from the optic disc anteriorly to the ora serrata, where it fuses with the pigmented epithelium of the ciliary body. The main functions are:

1. Vitamin A metabolism and regeneration of the visual pigments
2. Maintenance of the outer blood-retinal barrier
3. Phagocytosis of the photoreceptors outer segments
4. Absorption of light to reduce scatter and
5. Heat exchange

The apices of the RPE have multiple villous processes that surround the outer segments of the photoreceptors. Adjacent RPEs are firmly attached by chains of lateral and intercellular, junctional complexes, and these are; the zonulae occludentes, consist of fused plasma membranes, and zonulae adherentes. These are important in providing structural stability and maintaining the outer blood-retinal barrier. The separation of the RPE from the neurosensory retina is called a retinal detachment (American Academy of 2017).

1.1.6 Vitreous

The vitreous fills four-fifths of the volume of the globe. It's transparent and serves an important function to the metabolism of intraocular structure (lens, retina and ciliary body). Its volume is close to 4 ml and its 99% water, but due to the presence of hyaluronic acid and mucopolysaccharide the vitreous assumes a gel-like structure. On a histological level, the vitreous is formed of mainly collagen type 2 fibres and cells (hyalocytes). The function of these cells is unknown. The vitreous adheres firmly to the peripheral retina (where it forms the vitreous base), around the optic nerve and along the blood vessels. The vitreous liquefies with age and separates from the retina to form posterior vitreous detachment, and this may exert a traction on the retina and leading to rhegmatogenous retinal detachment (American Academy of 2017).

1.2 Immunology

The immune system is a result of a complex interaction between different types of cells and molecules aiming to clear a threat such as offending pathogen, toxic materials, cellular debris and malignant cells, to protect the organism. It has two main components, the innate immunity which is non-specific and consists of physical barriers such as (skin and mucous membrane), phagocytes (cells that engulf and destroy foreign antigens), and humoral factors such as complement system. The second part of the immune system is antigen-specific and is called adaptive immune response. It consists of T and B lymphocytes and a smaller population of B cells that have the characteristics of memory cells. These systems are closely related and connect via a particular form of proteins named Toll-like receptors (TLRs) present on phagocytic cells, which interact with the antigen presenting cell to initiate the adaptive immune response (Nussenblatt and Whitcup 2010).

The intercellular communication is largely mediated via the secretion of cytokines. Cytokines are soluble polypeptides, manufactured and released by cells to serve as a tool for intercellular signalling and communication and these include; chemokines, interleukins, interferons, lymphokines and tumour necrosis factors. Cytokines are secreted by both resident and effector immune cells and act locally as well as remotely to help with recruitment of leukocytes, changes in vascular permeability and enhancing the adaptive immune response. Chemokines are chemotactic cytokines that induce a directional movement (chemotaxis) in the nearby responsive cell. Lymphocytes and macrophages, among other cells, produce cytokines and these cytokines can either accelerate or decelerate the immune responses. There are two types of cytokines, either pro-inflammatory such as (IL-1, 2, 3, 4, 6, 8, 12, 17, TNF α and INF γ), or anti-inflammatory cytokines (IL-4, IL-10, TGF β , and INF γ). However, some such as INF γ can act as inducer and suppressor of the immune reactions depending on the medium where the cytokine is present.

These cytokines are classified into different groups based on their origin, action and target cells. For example, growth factors are cytokines mediating immune cell proliferation and differentiation and the terms interleukins and lymphokines are used for cytokines thought to mediate intercellular communication among lymphocytes and other leukocytes. Most cytokines have many sources and targets, and an activated macrophage in an inflammatory site secretes different cytokines such as growth factors, interleukins, interferons and chemokines. T lymphocytes are the classic cytokines producing cells of adaptive immunity. Macrophages, mast cells and neutrophils produce a wide range of cytokines when stimulated. The interaction between different cytokines is complex and eliminating one molecule may have unpredictable outcomes. The classic example is the monoclonal antibody against TNF α which results in substantial suppression of the immune system but increases the susceptibility to multiple sclerosis as well. Generally, cytokines modulate the immune responses and the function of most leukocytes, and therefore, they function as mediators and amplifiers of inflammation (American Academy of 2017).

1.2.1 Basic terminology

Immune response: is the process of removing an offending stimulus

Inflammation is the clinically evident immune response which is triggered by immunity (innate or adaptive). Inflammation results from a consequence of molecular and cellular events leading to five cardinal manifestations: pain, hyperaemia, oedema, heat and loss of function. These signs are produced by two physiological responses within a tissue: cellular recruitment and altered vascular permeability. The following pathophysiological findings are typical of inflammation:

- Effector cell infiltration releases biochemical factors and molecules (inflammatory mediators) such as, cytokines (interleukins and chemokines) and lipid mediators (prostaglandins and platelet-activating factors)
- Production of oxygen metabolites (superoxide and nitrogen radicals)
- The release of granule products and catalytic enzymes such as collagenases and elastases
- Activation of plasma-derived enzyme systems (complement component and fibrin)

(Delves, Martin et al. 2017)

1.2.2 The eye as an immune privileged site

The eye is an immune privileged site, which means that the healthy eye is hidden from the immune system by the blood-ocular barriers including blood-retinal barriers but when retinal antigens are exposed to the immune system, an inflammatory response will ensue. Activated T cells become adherent to retinal blood vessels and extravasate into the tissues by expressing degrading enzymes. Once they recognise retinal antigens, a surge of cytokines including chemokines is produced to recruit more inflammatory cells which in turn magnify the inflammatory cascade and increase tissue damage. These inflammatory cells include leukocytes/monocytes, granulocytes, natural killers, natural killers T cells and gamma delta ($\gamma\delta$) T cells (Caspi 2006).

To minimise damage, the classical immune response arc has been modified in specific tissue sites and organs such as the eye. In these sites, regional immunity is described

which can affect all three phases of immune arc (afferent, processing and effector) and it differs between various tissues. These regional differences are attributed to differences in the immunological microenvironment. For example in the eye these can be subdivided to;

- Conjunctiva,
- Anterior chamber, anterior uvea (iris, ciliary body),
- Retina, retinal pigment epithelium and choriocapillaris and
- Choroid.

1.2.2.1 Immune responses of the conjunctiva, anterior chamber, anterior uvea, and vitreous

The conjunctiva is composed of an epithelial layer and a connective tissue called the substantia propria. It is well vascularized with blood and lymphatics which drain to preauricular and submandibular lymph nodes. The conjunctiva homes many cells that serve as potential antigen presenting cells such as Langerhans cells, macrophages and dendritic cells. The conjunctiva is also densely populated with potential effector cells, mainly mast cells. All antibody isotypes are present but IgA dominates.

Several specific anatomical features of the anterior chamber AC govern local immunity. The AC is a fluid-filled cavity with circulating aqueous humour, which serves as a unique medium for intercellular communication between different resident ocular tissue cells (iris, ciliary body, corneal endothelium). The aqueous only contains between 0.1% - 1.0% of total serum proteins compared to serum. The blood-ocular barrier is formed by the tight junctions between pigmented and non-pigmented cells of the ciliary body, functions to exclude immune cells. Therefore, B lymphocytes, eosinophils and neutrophils are usually absent, and very low IgG and complement proteins are present in the aqueous humour under normal condition. The eye has no lymphatics, therefore, immune processing is unlikely to occur locally. Clearance of soluble particles relies on aqueous humour draining channels (trabecular meshwork endothelial cells and macrophages).

The vitreous shares similar properties to the anterior chamber but with few exceptions. Charged protein substances can electrostatically bind to the vitreous gel,

therefore, the vitreous may serve as a depot for foreign antigens and scaffolding for leukocytes. Additionally, because the vitreous contains type II collagen, it may harbour potential autoantigens as well.

These unique microenvironments in the eye have influenced the immune responses to a great extent and led to the notion of the immune privilege of the eye which means that the eye and its antigens are being ignored or *tolerated* by the immune system. This notion came from the fact that tumour implants or allografts survived better within an immunologically privileged site compared to other locations, such as the skin, where a similar implant is rapidly rejected. This unique immune system in the eye is essential, because a relatively mild degree of inflammation in the skin, which is harmless, would cause severe loss of vision if it occurs in the eye. Similarly, an antigen presented to a lymphatic vessel would mount a different immune response to one shown in the blood with an excellent immune response in the former (Nussenblatt and Whitcup 2010).

In the eye, the best-studied model of immune privilege is called the *anterior-chamber associated immune deviation* (ACAID). This term refers to the ability of the anterior chamber AC of the eye to retain foreign antigens for a long time compared to other tissues such as the skin where an intense inflammatory reaction is inevitable. This phenomenon aims to limit the harmful consequences that may arise from the immune responses and interferes with the physiological function of the eye (Streilein 1993). This function is particularly important to preserve the eye from the damage inflicted by the inflammatory response or its consequences. It is an active rather than a passive process and is mediated by immunoregulatory cytokines such as TGF- β 2. However, it is to blame for the enhanced growth of intraocular tumours (Nussenblatt and Whitcup 2010).

Macrophages process the antigen in the AC when these antigens are present in the anterior uvea. The antigen-stimulated TGF- β 2 exposed macrophages migrate through the aqueous channels to the venous circulation to the spleen. Within the spleen, there will be activation of not only helper T cells and B cells but also CD8+ T regulatory cells (T regs). These T regs alter the function of CD4+ cells and downregulate CD4+ delayed hypersensitivity (DH) lymphocytes and selectively reduce the production of

complement-fixing antibodies, thus, limiting the reaction to the specific antigen at all body sites. Therefore, ACAID represents an attenuated effector arc.

Additionally, the eye is further protected from severe inflammation by another mechanism termed effector blockade, where Th1, cytotoxic lymphocytes, natural killer cells and complement components seem to be less efficient in the anterior uvea than somewhere else. One of the most important and known mechanisms involved is the Fas ligand (FasL or CD 95). FasL is expressed on the iris and corneal endothelium and is a potent inducer of programmed cell death of lymphocytes expressing the Fas receptor. Interestingly, ACAID and effector blockade can be overcome by a significant immune reaction. Following an attack of ocular inflammation, these mechanisms can only be partially restored, therefore possibly reducing the immune protection of the eye (Sugita, Ng et al. 2006, Niederkorn 2007, Foster and Vitale 2013).

Moreover, the retinal circulation is secured by inner blood-retinal barrier (tight junctions between adjacent endothelial cells of retinal blood vessels), whereas tight junctions between RPE cells form the outer blood-retinal barrier (between the choroid and the retina). Lightman and Greenwood in experimental autoimmune uveoretinitis have shown that loss of the integrity of blood-retinal barrier is accompanied by lymphocytic infiltration into the retina (Greenwood, Howes et al. 1994). The presence of inflammatory inhibitors in the eye milieu, which could be either soluble or membrane-bound, also help reducing the immune response. A programmed cell death, is another mechanism adopted by the eye to destroy the invading pathogens or cells without inflammation. Lastly, the adoption of immune tolerance to limit the damage to the ocular tissue and preserve sight (Ferguson, Green et al. 2002).

1.2.2.2 Immune responses in the eye

Under normal condition, the choroid and the retina lack well-developed lymphatics and there are no neutrophils or eosinophils in the choroid, but a considerable number of mast cells are present around the arteriole with low numbers of lymphocytes. Moreover, RPE cells display a complement regulatory protein (CD46) on its basolateral surface which may protect against complement activation in the underlying choroid (Vogt, Barnum et al. 2006). Additionally, effector cells are usually absent in the retina and the choroid, however macrophages and dendritic cells play as APCs in

the choroid, similarly, in the retina, microglia (cells derived from the bone marrow and similar to dendritic cells) are potential APCs. These cells are widespread and present in all retinal layers and can undergo morphological changes and migrate in response to different stimuli (Detrick and Hooks 2010).

Under inflammatory conditions, ocular resident cells such as Langerhans cells in the cornea, RPE, Müller cells and also vascular endothelial cells can play a significant role in the immune responses within the eye. These cells can behave like immune cells and participate in immune-mediated events, and the best example is RPE cells which can act like an APC. There are many features in common between the RPE and macrophages which make these cells an active participant in the local immune response. RPE cells can migrate and engulf unwanted material; they also secrete IL-6, a cytokine that is capable of inducing intraocular inflammation when injected into the eye (Planck, Dang et al. 1992). Furthermore, RPE cells can express MHC class II antigen in addition to MHC class I when activated (Chan, Detrick et al. 1986). Müller cells have a significant impact on T cell proliferation within the eye (Caspi, Roberge et al. 1987). Furthermore, large numbers of T and B lymphocytes, neutrophils and macrophages infiltrate the choroid, choriocapillaris and retina with the RPE and different cell types in the retina and choroid secreting various cytokines which participate in subsequent immune response (Vogt, Barnum et al. 2006). But not all microglia are derived from tissue resident cells and cells invading the eye play also a key role in inflammation.

1.3 Uveitis

Uveitis is a term that refers to inflammation of the uveal tract. But the inflammation is not only limited to the uvea but can also involve other ocular structures such as, the retina, vitreous, optic nerve, and sclera is usually common in uveitis. There are over 30 different disease entities under the term uveitis and they all manifest with intraocular inflammation. Uveitides are grouped by the anatomic class (anterior, intermediate, posterior and pan-uveitis). Also, uveitis is classified according to the aetiology to infectious and non-infectious (autoimmune). The latter could be part of a systemic disease or limited to the eye.

Because uveitis is commonly associated with systemic disease, a careful and detailed history and review of systems is an essential first step in identifying the cause. Then a comprehensive exam of the eye and associated organ system is performed to characterise the type of inflammation encountered. The location of intraocular inflammation with respect to ocular anatomy along with information gathered from history and clinical examination help direct the investigational studies needed. Differentiating infectious from the non-infectious cause is a critical first step since corticosteroid only treatment can lead to harmful consequences when infection is the cause. Also, reaching the right diagnosis is essential to guide the choice of therapy and long-term disease management (Jabs 2017).

1.3.1 Pathophysiology of uveitis

Autoimmune uveitis is heterogeneous, with different diseases and diverse clinical presentations, in which the eye could be the only involved organ, or the eye is affected by a systemic condition. Uveitis can be due to systemic autoimmune diseases such as sarcoidosis, Behcet's and Vogt Koyanagi-Harada, or infections such as toxoplasmosis or syphilis (Ooi, Galatowicz et al. 2006). Because of the complexity of the disease process in uveitis, the exact pathological mechanism is not fully understood. However, experimental autoimmune uveitis (EAU) in mice, in which a retinal soluble antigen and interphotoreceptor retinoid-binding protein is injected to create an immune response has helped to understand some of the immune mechanisms in ocular inflammation (Caspi 2011). The key elements of the immune system in uveitis are as follow:

1.3.1.1 T cells

Uveitis is regarded as a T cell-mediated disease. When premature T cells leave the bone marrow and enter the thymus, these cells undergo maturation and differentiation. During this process, T cells are educated to ignore self-protein (antigens) and to combat foreign antigens in the body. However, in certain situations, these cells will react to own body tissue and cause inflammation (Caspi 2011). Several subsets of CD4+ T cells such as Th1, Th2, and Th17 are involved in autoimmune uveitis, and these cells differ in phenotypical appearance and function. These cells secrete

different cytokines and chemokines, for example, Th17 secretes IL-17 and $\text{INF}\gamma$. Despite having different biological roles to fight against microorganisms, these T-cells are also implicated in several autoimmune diseases such as rheumatoid arthritis, multiple sclerosis and uveitis (Jager and Kuchroo 2010) (Damsker, Hansen et al. 2010). Another subtype of T cells is T regulatory cells which are involved in suppressing the immune system reactions via their ability to produce IL10 and TFG- β and downregulate both CD4 and CD8 mediated inflammatory responses, Figure1.3 (page 60) (Piccirillo 2008).

T cells produce different pro-inflammatory cytokines and these have an essential role in autoimmune uveitis. $\text{TNF}\alpha$, which is produced by T cells among other inflammatory cells (macrophage, monocytes, and NK), is regarded as a key effector cytokine in uveitis pathogenesis. This cytokine up-regulates adhesion molecules and facilitates more leukocyte infiltration and activation. It also extends the survival of dendritic cells and macrophages (Dick, Forrester et al. 2004). Another key pro-inflammatory cytokine is $\text{INF}\gamma$ (Nussenblatt 1991). $\text{INF}\gamma$ upregulates dendritic cells and macrophages by mediating delayed hypersensitivity immune response. These cells secrete $\text{TNF}\alpha$ and IL-12 which further promote T helper cells development (Yoshida, Koide et al. 1994, Gordon 2003).

Therefore, treatment aiming at blocking adhesion molecules or eliminating certain leukocytes will interfere with the recruitment of inflammatory cells from the peripheral blood into the eye which results in better control of inflammation or even disease remission (Lightman, Taylor et al. 2015). However, such treatment is not curative, but only helps improving disease activity, and once treatment is stopped, the disease recurs. This is due to the presence of autoreactive T cells and disruption of the immune tolerance (Caspi 2011).

Also, non-immune ocular parenchymal cells such RPE, retinal Müller cells, iris and ciliary body epithelium can produce a wide array of inflammatory mediators and cytokines which help with the recruitment of innate effector cells such as natural killer cells, monocytes, neutrophils, dendritic cells and macrophages among other cells. Neutrophils are very efficient effectors of innate immunity. They are classified as resting or activated depending on their secretory and cell membrane activity. Their

recruitment by innate immune response occurs rapidly via two mechanisms. Firstly, cell adhesion molecules (CAMs) on both leukocytes and vascular endothelium mainly in the postcapillary venules, facilitate the adhesion between neutrophils and vascular endothelium. Secondly, the chemotactic factors which direct the transmigration of the neutrophils through the endothelium and the surrounding extracellular matrix. The activation of vascular endothelial cells is triggered by different innate immune stimuli such as lipopolysaccharides (LPS), physical injury, thrombin, histamine, and leukotriene release. Neutrophil rolling is a process by which neutrophils bind loosely and irreversibly to non-activated endothelial cells (Abbas, Lichtman et al. 2014).

Delayed hypersensitivity represents the typical pathway of the adaptive immune mechanism. A primed DH CD4⁺ T cells enter the site of inflammation and re-stimulated by MHC class II APCs leading to their full activation and with the resultant secretion of different mediators to recruit other immune cells. Experimental and histological studies in man revealed different subtypes of DH T cells; their differentiation is based on the spectrum of different cytokines they produce. These subtypes of DH CD4⁺ cells will set different types of immune reactions. These cells differentiate to Th1 and Th2; Th1-mediated DH lymphocytes are thought to be involved in several intraocular inflammatory diseases such as, acute anterior uveitis, sarcoidosis, intermediate uveitis, sympathetic ophthalmia, Vogt-Koyanagi-Harada syndrome, birdshot disease as well as orbital diseases such as acute thyroid orbitopathy and giant cell arteritis (Boyd, Young et al. 2001).

1.3.1.2 Cell adhesion molecules

Cell adhesion molecules (CAMs) are cell-surface glycoproteins which are responsible for cellular communication, and the interaction between cells and their environment. These molecules are overexpressed in inflammation and primarily found on the vascular endothelium and surrounding tissue to allow for recruitment of more inflammatory cells. Therefore, they play an essential role in the development of inflammation due to their ability to direct leukocytes to sites of inflammation (Bevilacqua, Stengelin et al. 1989, Luscinskas, Brock et al. 1989). Further, they are responsible for interactions between lymphocytes and APC necessary for lymphocyte activation.

CAMs can be divided into three groups based on the structural differences, namely:

1. Selectins especially L-, E- and P-selectin,
2. Integrins especially, leukocytes function-associated antigen 1 (LFA-1) and macrophage-1 antigen (Mac-1)
3. Immunoglobulin gene superfamily especially intercellular adhesion molecule 1 (ICAM-1) and 2 (ICAM-2) (Mulligan, Varani et al. 1991).
4. Very Late Antigen 4 (VLA-4) (integrin $\alpha 4\beta 1$) is expressed on cell surface of neutrophils, T and B cells, monocytes, natural killers. It promotes an inflammatory response by recruiting inflammatory cells. In MS VLA-4 (particularly $\alpha 4$ integrin) allowed cells to penetrate through the blood brain barrier and it's expression was positively correlate with disease severity (Sheremata, Minagar et al. 2005).

The primary events in cellular adhesion are mediated mainly by members of the selectins family and occur within minutes of stimulation. L-selectin is expressed on non-activated neutrophils and mediates a weak bond to the endothelial cell by binding to specific selectin ligands. When endothelial cell become activated upon exposure to triggering stimuli, it will further express the other two selectins (E and P) by which a more stable interaction is maintained and is called (adhesion). Subsequently, other factors, such as platelet-activated factor and various cytokines can induce overexpression of β integrin which makes the adhesion even firmer to allow for the transvascular migration (Springer 1994).

Subsequently, with the help of various chemotactic factors, transmigration of neutrophils across the endothelial barriers and extracellular matrix occur towards the site of inflammation. Chemotactic factors are short-range signalling molecules that diffuse maximally at the source and reduced in concentration at target cells. Neutrophils have receptors for these molecules, and upon stimulation, neutrophils undergo membrane modification that enables migration in the direction of highest level. The activation of neutrophils starts when adhesion takes place and then reach a full activated state upon interacting with injured tissue or site of infection (Abbas, Lichtman et al. 2014).

1.3.1.3 T regulatory cells

T regulatory cells (T reg) express CD8+ and were considered to be the only cells with immune regulatory function. More recently, CD4+, CD25+ and Foxp3 T lymphocytes have also been known to have a regulatory role. These cells operate by releasing TGF β that can alter or inhibit the function of other effector T cells. T regulatory cells might be necessary as a potential therapeutic option, because they may provide a tool to induce tolerance of self-antigens (Abbas, Lichtman et al. 2014).

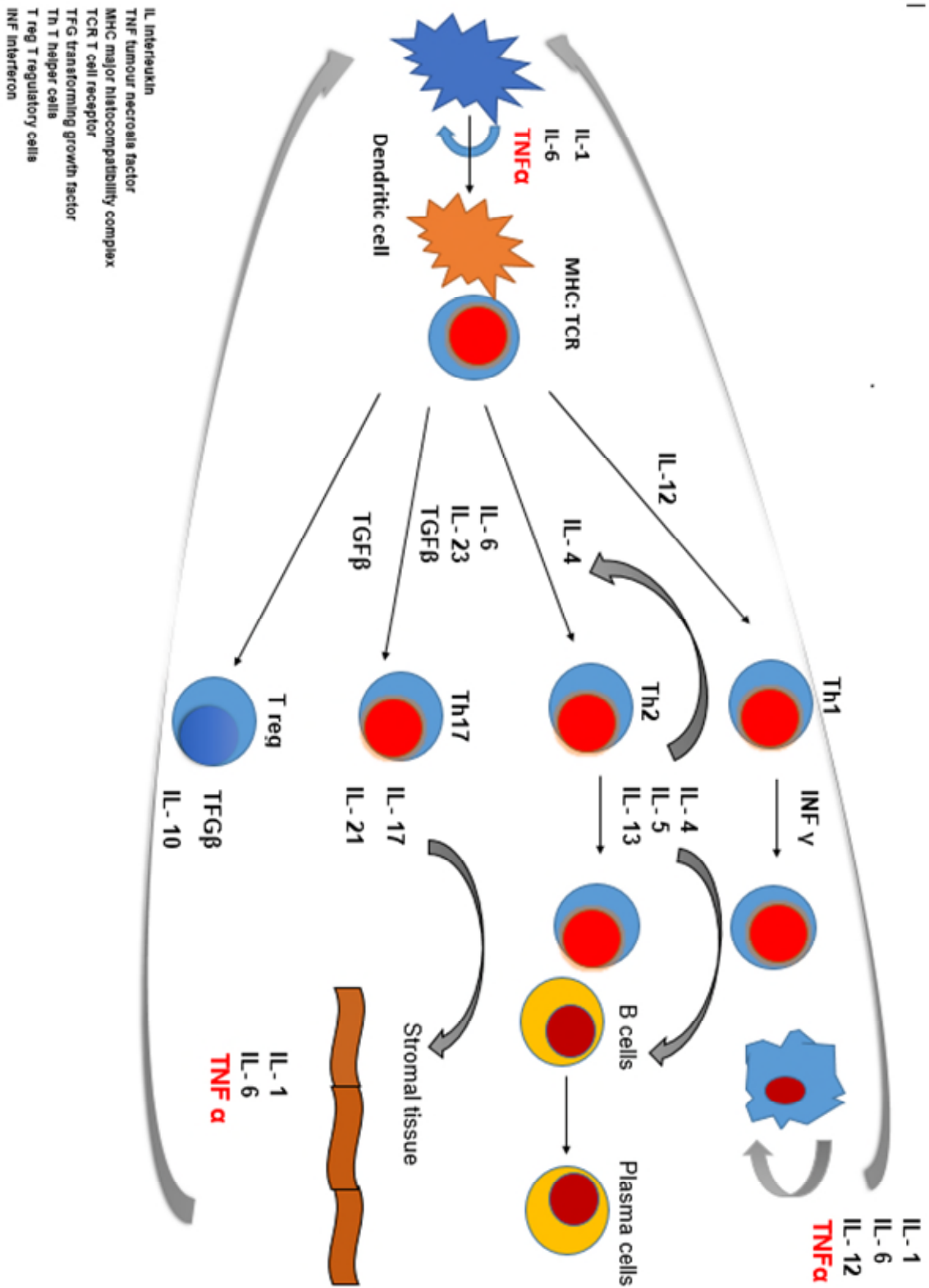
1.3.1.4 Cytokines and their role in ocular inflammation

Although the pathogenesis of uveitis is not entirely understood, cytokines seem to play a vital role in mediating ocular inflammation, particularly IL-2, TNF α and Th-1 mediators (INF γ and IL-12). In experimental autoimmune uveoretinitis (EAU), a model of uveitis achieved by immunisation of mice with specific retinal antigens supports the role of cytokines in the development of intraocular inflammation. The inflammation produced in EAU gives a picture similar to sympathetic ophthalmia and panuveitis in humans. Various cytokines play different roles in inflammatory response. TNF α , for example, exacerbates the inflammation whereas, administration of IL-10 seems to be protective against inflammation and the level of these cytokines correlates with disease activity (Dick, Forrester et al. 2004).

IL-2, IL-6 and INF γ are heavily involved in intraocular inflammation. IL-2 is one of the most crucial cytokines in human immune reactions because it stimulates the growth of lymphocytes and exacerbates the immune responses. Another cytokine is INF- γ which does not only modulate the immune responses but also has a great propensity to induce the expression of major histocompatibility complexes (MHC) on cells which further amplify the immune reactions. Seminal work by Foxman and colleagues showed a very high expression of IL-1, IL-6 and TNF α in an experimental autoimmune uveoretinitis. Interestingly cytokines were also highly expressed in an eye without inflammation (Foxman, Zhang et al. 2002). High level of proinflammatory cytokines namely, IL-2 and INF γ , were found in ocular tissues infiltrated by T cells (Levy-Clarke, Jabs et al. 2014). Likewise, high levels of TNF α and IL-6 were detected in aqueous and serum samples of patients with ocular inflammatory disease and their levels seem to correlate to disease relapse and inflammatory activity (Santos Lacomba, Marcos

Martin et al. 2001). Finally, other cytokines such as TGF β may act by downregulating the immune responses and participate in immune tolerance and anterior chamber-acquired immune deviation ACAID.

Figure 1-3 Immune system responses in uveitis. Reproduced from a presentation by Alastair Denniston



1.3.2 Epidemiology of uveitis

Uveitis embraces a wide range of pathology with an incidence estimated at 38-200 per 100,000 in the Western world (Sangwan 2010). (Rychwalski, Cruz et al. 1997). It can be associated with an underlying systemic disease, though most cases remain idiopathic.

There is an increased incidence of uveitis; a recent population-based study in the US reported three-fold increment in the incidence of uveitis compared to the previous studies, which was especially true in older age group (Gritz and Wong 2004). The same study reported a significantly higher prevalence of uveitis in females compared to males. Non-infectious uveitis constitutes more than 90% of cases of uveitis (Thorne, Suhler et al. 2016). Studies from the US and Europe have shown an annual incidence of uveitis to be between 14 and 22.4 per 100,000 population, and the prevalence is between 38-270 cases per 100,000 population (Darrell, Wagener et al. 1962, Baarsma 1992, Tran, Auer et al. 1994). These figures peak at 30-50 years of age and then drop (Durrani, Meads et al. 2004). There are geographical variations in the incidence and prevalence of uveitis. For example, in India, uveitis prevalence was higher than those reported in the US and Europe, 730 per 100,000 inhabitants (Dandona, Dandona et al. 2000), which might reflect ethnic variations between these different populations or an increase in infectious causes such as, TB.

Anterior uveitis is the most common type of uveitis; it is reported between (52-91%) in the US (McCannel, Holland et al. 1996, Rodriguez, Calonge et al. 1996). In Europe, the figures were almost similar (Smit, Baarsma et al. 1993, Paivonsalo-Hietanen, Vaahtoranta-Lehtonen et al. 1994). In these studies, posterior uveitis was the second most common type (5-26%). However, the figures for anterior, posterior and panuveitis can vary in range and this reflects the difference in the study population between the tertiary referral centres and community based general practices. The etiological factors can also play a role in this, for example, a study from South America reported panuveitis as being the most common type (37%) followed by posterior uveitis (34%) and anterior uveitis is the least common (19%) (Rathinam and Cunningham 2000). This variation could be attributed to the fact that *Toxoplasmosis* related ocular inflammation is the most frequent cause of uveitis in that area.

Uveitis is regarded as the fifth most common cause of vision loss especially among the working age group in the developed world, and around 10-15% of all causes of vision loss and 20% of legal blindness is attributed to uveitis (Durrani, Tehrani et al. 2004). Because it affects all age groups including children, it tends to have a more profound impact on vision than age-related diseases (Jabs 2017). Uveitis mainly affects the younger age group, and its related complications can have devastating consequences on their vision and dependency (Tomkins-Netzer, Talat et al. 2014), which has a potential negative impact on patient's quality of life (Fabiani, Vitale et al. 2017).

Uveitis is the major cause of vision loss in the younger population. A retrospective study of 315 consecutive patients (with a mean age of 48 years) in a tertiary centre with mean follow-up duration of three-years found that visual impairment ($VA \leq 6/18$) was reported in 70% of patients, with subgroup (55%) having severe vision loss ($VA \leq 6/60$) (Durrani, Tehrani et al. 2004). The same study described a higher rate of vision loss in patients with panuveitis (85%), and the most common causes were CMO and cataract with 50% of patients having bilateral vision loss. The poor prognostic factors were panuveitis and bilateral disease, increase duration of vision loss and Indian/Pakistani ethnic background.

1.3.3 Classification of uveitis

The range of inflammatory processes in uveitis usually associate with and respect the anatomical boundaries. For example, anterior uveitis is restricted to the iris and ciliary body (synonyms: anterior uveitis, iridocyclitis and anterior segment intraocular inflammation), whereas, posterior inflammation is usually confined to the choroid (synonyms: choroiditis, chorioretinitis and posterior segment intraocular inflammation). However, certain diseases cross these boundaries such as intermediate uveitis, where the disease locus predominantly involves the posterior ciliary body and the anterior peripheral retina. Moreover, the involvement of other ocular structures such as the optic nerve, sclera and retina is common in different types of posterior segment inflammation (Forrester 2007).

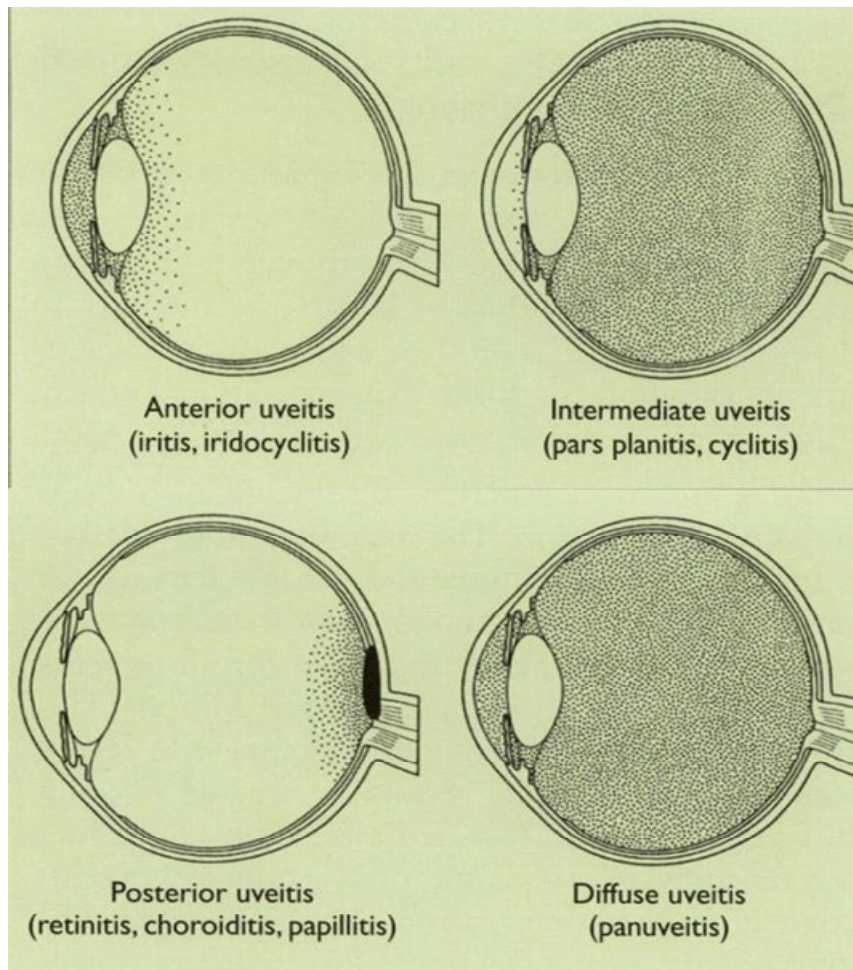
1.3.3.1 Anatomical classification

Different classification systems exist, however, the Standardization of Uveitis Nomenclature (SUN) is the most popular and commonly used one (Jabs, Nussenblatt et al. 2005). The SUN group classifies uveitis depending on the anatomical location of inflammation within the eye. Please refer to Table 1-1 and Figure 1-4. Uveitis can also be classified according to the clinical course into acute, chronic, or recurrent.

Table 1-1 the SUN working group anatomical classification of Uveitis (Jabs, Nussenblatt et al. 2005).

Type of uveitis	The primary site of inflammation	Includes
Anterior Uveitis	Anterior chamber	Iritis Iridocyclitis Anterior cyclitis
Intermediate uveitis	Vitreous	Pars planitis Posterior cyclitis Hyalitis
Poster uveitis	Retina or choroid	Focal, multifocal or diffuse choroiditis Chorioretinitis Retinochoroiditis Retinitis/ Neuroretinitis
Panuveitis	Anterior chamber, vitreous and retina or choroid	

Figure 1-4 Type of uveitis and the predominant site of inflammation (Jabs, Nussenblatt et al. 2005) (*SUN criteria*)



SUN grading of anterior chamber cells, anterior vitreous cells and anterior chamber flare are displayed in (Table 1-2), (Table 1-3) and (Table 1-4), respectively.

Table 1-2 (LEFT) Grading of anterior chamber cellular activity higher scores visible on examination indicate more severe disease. Table 1-3 (RIGHT) SUN Classification of anterior vitreous activity (Jabs, Nussenblatt et al. 2005).

Grade	Number of vitreous cells
0	No cells
0.5+	1-10
1+	11-20
2+	21-30
3+	31-100
4+	>101

Grade	Number of AC cells
0	<1
0.5+	1-5
1+	6-15
2+	16-25
3+	26-50
4+	>50

Table 1-4 grading anterior chamber flare (Jabs, Nussenblatt et al. 2005)

Grade	Anterior chamber flare
0	None
1+	Faint
2+	Moderate (iris and lens details clear)
3+	Marked (iris and lens details hazy)
4+	Intense (fibrin or plastic aqueous)

1.3.3.1.1 Anterior uveitis

Anterior uveitis is when the anterior chamber of the eye is the primary site of inflammation (inflammation of the iris and ciliary body); it is the most common type of uveitis, up to 60% of all uveitis cases (Rothova, Buitenhuis et al. 1992, Mercanti, Parolini et al. 2001, Singh, Gupta et al. 2004). Anterior uveitis can be a single acute episode or a chronic disease. It can also be localised to the eye or be part of a systemic condition such as juvenile idiopathic arthritis or sarcoidosis or ankylosing spondylitis. Most cases of anterior uveitis manifest as a single attack and are usually idiopathic. These episodes usually present with pain, redness and photophobia.

Nevertheless, anterior uveitis can present in different ways from a white eye with a low-grade inflammation to a red and painful eye. Other causes of non-infectious anterior uveitis include HLA-B27 associated uveitis which may present with recurrent episodes of anterior uveitis alternating between the two eyes. JIA-associated chronic anterior uveitis is a well-recognised cause of anterior uveitis in childhood, and it is usually asymptomatic with a high risk of cataract and glaucoma and carries poor prognosis if left untreated (Nussenblatt, Whitcup et al. 1996).

On examination cells in the anterior chamber and retroental space (behind the lens) are often noted when there is spill over. Inflammatory process originating in the cornea is called keratouveitis while if it is arising in the sclera and involves the uvea it is called sclerouveitis. Also, inflammatory deposits of the corneal endothelium (keratic precipitates) are frequently present in addition to posterior synechia, which represents an area of adhesion between the iris and the lens behind. These are commonly noted in severe and chronic disease. Hypopyon (pus accumulation in the anterior chamber) is another sign of severe active disease in an eye with HLA B-27 associated uveitis or Behcet disease (Foster and Vitale 2013).

Acute anterior uveitis is usually associated with a decrease in intraocular pressure (IOP). However, it could be associated with an increase in IOP and in these cases one should suspect a viral aetiology such as herpes viruses, Fuch's heterochromic cyclitis or Posner-Schlossman syndrome. Besides, there may be mechanical causes behind the rise in IOP such as clogging of the trabecular meshwork with inflammatory cells, debris or even progressive synechial closure and pupil block. Iris pigment defects are typically found in virus causes of anterior uveitis leading to patches of iris atrophy (Foster and Vitale 2013).

Treatment of acute episode is usually with topical corticosteroid drops and dilating agents such as cyclopentolate to relief ciliary body spasm, reduce pain and prevent the formation of posterior synechiae. Systemic immunosuppressive therapy is instituted in chronic disease poorly responsive to topical treatment or when anterior uveitis is part of chronic systemic condition, such as JIA.

1.3.3.1.2 Intermediate Uveitis

The Uveitis Study Group first coined the term intermediate uveitis (IU) in 1987 for a subset of uveitis where the vitreous is the primary site of inflammation, particularly the vitreous base overlying the ciliary body, peripheral retina and pars plana. In intermediate uveitis, there is no chorioretinal inflammation or scarring, but there might be a mild degree of anterior chamber inflammation. Intermediate uveitis accounts for 15% of all uveitis cases (Bloch-Michel and Nussenblatt 1987).

Aggregation of inflammatory cells in the vitreous are called snowballs. Whereas snow banking represents inflammatory exudate accumulation on the inferior pars plana and it may reflect a more aggressive disease process. Retinal vasculitis is frequently associated with IU, and it commonly involves peripheral retinal veins. Intermediate uveitis can be associated with different types of systemic diseases such as sarcoidosis, multiple sclerosis, inflammatory bowel diseases and lymphoma. Whereas TB, syphilis, toxoplasmosis, Whipple's disease, brucellosis, Lyme disease, toxocariasis and human T cells lymphotropic virus type 1 (HTLV1) are well recognised infectious aetiologies (Foster and Vitale 2013).

Pars planitis

According to the SUN group, the term pars planitis is used when there is no underlying cause (whether infectious or systemic disease) for the inflammation, in the presence of snow banking and snowballs (Jabs, Nussenblatt et al. 2005). The prevalence of IU varies considerably in the literature with a higher incidence in the Western world. Pars planitis is found in 68% of cases of intermediate uveitis, and it mostly affects children and young adults in their second decade of life (Foster and Vitale 2013). However, it may reach up to 90% of intermediate uveitis cases. The most frequent symptoms of intermediate uveitis are blurred vision and floaters. Children may present with significant anterior uveitis with pain and photophobia (light sensitivity). IU is bilateral disease in 80% of cases but with asymmetrical presentation (Donaldson, Pulido et al. 2007) (Bonfioli, Damico et al. 2005).

On examination, vitritis is a universal finding when there is active disease. Also, snowballs, pars plana exudate, peripheral retinal periphlebitis and sheathing of the vessels are seen. Histologically, snowballs consist of lymphocytes, macrophages,

epithelioid cells and multinucleated giant cells which makes these aggregates as solitary vitreous granulomas. Another feature of this disease is snowbank formation which appears as a white exudate and usually present in the inferior retina. Snowbanks frequently extend to the pars plana, but it is not present in all patients. They consist of collapsed vitreous, membranous fibroglial cells, collagen and inflammatory cells (Jain, Ferrante et al. 2005). Figures 1-5 and 1-6.

Figure 1-5 Snowballs in the peripheral retina associated with vitreous haze. Photo courtesy of professor Lightman, Moorfields Eye Hospital.

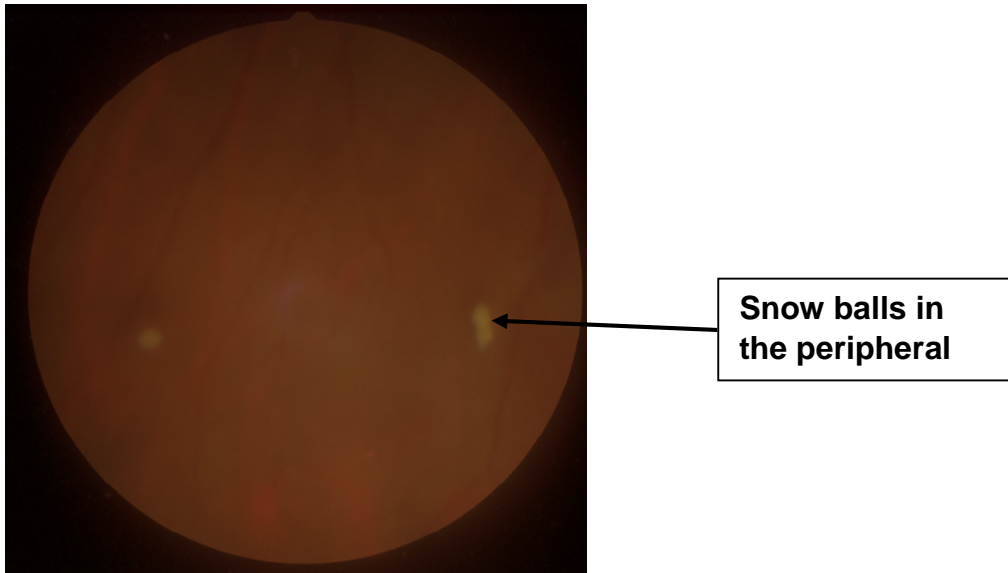
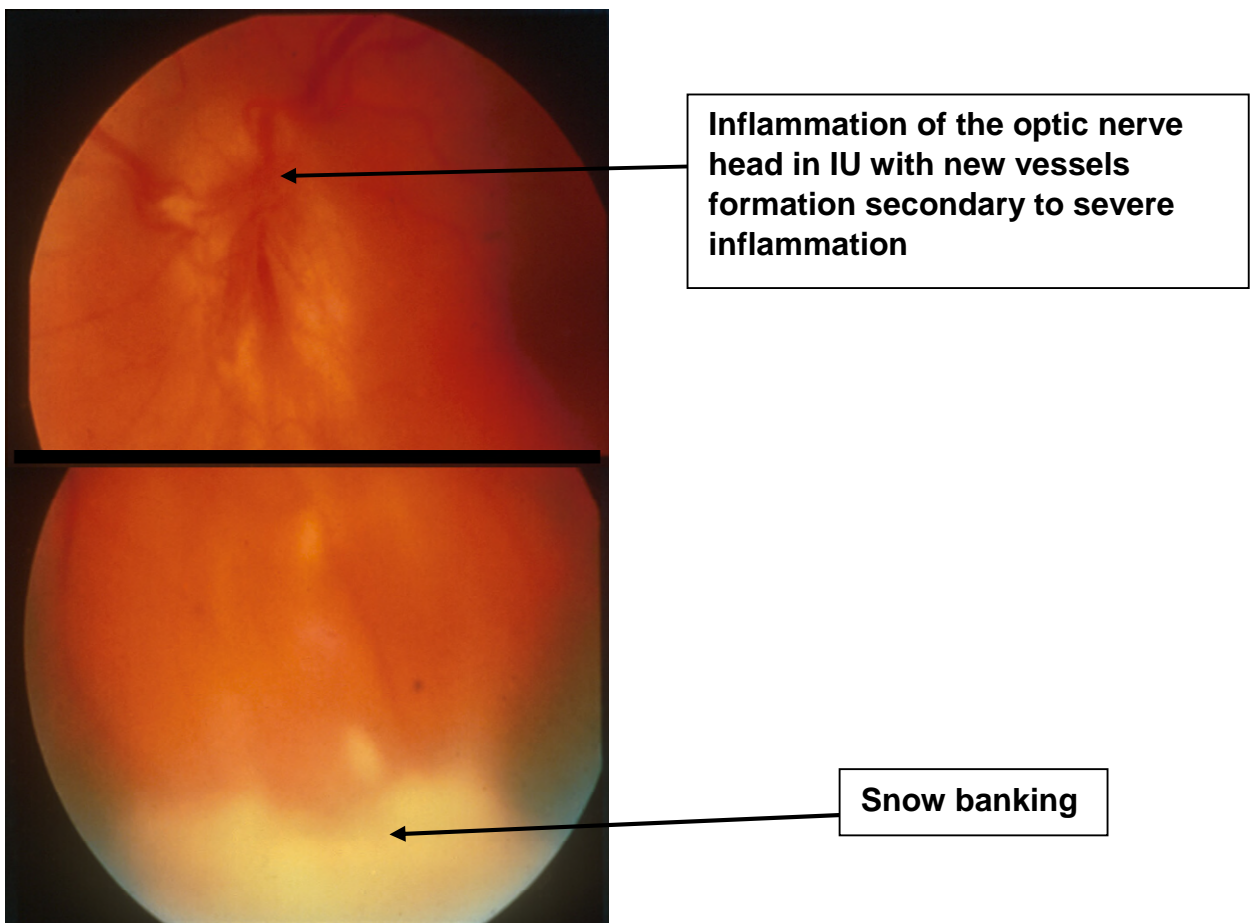


Figure 1-6 Manifestations of intermediate uveitis (TOP) Severe inflammation of optic nerve head. (Bottom) snow banking. Photos courtesy of professor Lightman, Moorfields Eye Hospital.



Intermediate uveitis is associated with several sight-threatening complications. Cystoid macular oedema (CMO) is the leading cause of vision loss in IU and develops in 50% of patients. CMO becomes chronic and resistant to treatment in around 10% of cases. The other frequent cause of visual impairment is the formation of epiretinal membranes (ERM) in 36%, followed by cataract, mainly posterior subcapsular cataract in 30% of patients (Donaldson, Pulido et al. 2007). Ischaemia from retinal periphlebitis along with angiogenic signals from the inflammation can lead to neovascularization along the inferior snow banking or the optic nerve head in 10% of patients which lead to vitreous haemorrhage (VH) commonly in children. Figure1-6 (Lauer, Smith et al. 2002).

Additionally, these neovascular complexes may contract causing tractional and rhegmatogenous retinal detachment in 10% of patients. Similarly, Liquefaction and collapse of vitreous due to a state of chronic inflammation also lead to posterior vitreous detachment. The detached posterior vitreous exerts traction on the retina leading to the formation of holes in the retina which predispose to rhegmatogenous retinal detachment (Kerkhoff, Lamberts et al. 2003). Additionally, vitreous traction along with vitritis may contribute to the development of chronic macular oedema and ERM. The latter represents a fibrocellular proliferation which causes wrinkling of the inner surface of the retina and distortion of central vision (Gandorfer, Rohleder et al. 2002). Finally, other causes may develop especially with chronic disease and have a profound impact on vision such as vitreous opacification, uveitic glaucoma and cyclitic membrane (Hughes and Dick 2003).

The diagnosis of pars planitis is made with reference to the classical clinical findings. Laboratory workup is important to exclude other causes of intermediate uveitis such as sarcoidosis, Lyme disease, and syphilis. These tests include serum angiotensin-converting enzyme inhibitors (ACE), chest X-ray, Lyme antibody titers, and syphilis serology. Fluorescein angiography is helpful to document leakage from the disc, peripheral retinal veins and signs of cystoid macular oedema (American Academy of 2017).

Pars planitis is a sight-threatening disease and treatment can take many years, but if the CMO is brought under control by sufficient immunosuppression, the visual prognosis can be good, with approximately 75% of patients retaining good vision

(6/12) or better after ten years (Donaldson, Pulido et al. 2007). The first line of therapy consists of corticosteroids (oral, periocular). Periocular corticosteroids (triamcinolone or methylprednisolone) can be given via the orbital floor route or sub-Tenon injection. These can be repeated every six weeks; however, glaucoma patients should be monitored closely for corticosteroid-induced high intraocular pressure. Intravitreal triamcinolone injections should be reserved for recalcitrant cases (Leder, Jabs et al. 2011). Systemic corticosteroids are preferred in bilateral disease. If high doses for a long time are needed, immunomodulatory therapy should be instituted. Systemic Immunosuppression Therapy for Eye disease (SITE) reported 70%-80% of patients achieving long-term disease remission with cyclosporine, azathioprine and mycophenolate mofetil. TNF α blockers should be avoided in MS-associated IU due to the risk of disease exacerbation. Pars plana vitrectomy is considered to treat disease complications such as retinal detachment and vitreous haemorrhage or if there is significant vitreous debris (American Academy of 2017).

1.3.3.1.3 Posterior uveitis

Posterior uveitis refers to an inflammatory process involving the posterior structures of the eye (retina, RPE and the choroid) and inflammatory cells are seen throughout the vitreous cavity. The optic nerve is also frequently involved in this setting. This subset of uveitis carries a high risk of permanent loss of vision and is often associated with systemic disease. The reported percentage of posterior uveitis varies hugely in the literature, and this variation is due to the differences in aetiology, ethnic background and geographic location, but it generally ranges from 5 to 20% (Zierhut, Pavesio et al. 2016).

The most common presentation with posterior uveitis is visual distortion, floaters and or disturbances in the visual fields. When posterior uveitis is associated with a significant amount of vitritis, the possible infectious causes are endogenous endophthalmitis (bacterial, fungal), *toxoplasmosis*, *toxocara*, human T cell lymphotropic virus 1 (HTLV1), syphilis, Whipple's disease and Lyme disease. The non-infectious aetiologies include sarcoidosis, Behcet disease, immune recovery uveitis and lymphoma. Vitreous haemorrhage, due to retinal neovascularization, could be due to TB or occlusive vasculitis, while the absence of vitreous inflammation could point to ocular histoplasmosis syndrome.

Retinal infiltrates occur in many infectious causes such as bacterial and fungal endophthalmitis, acute retinal necrosis (ARN) due to herpes or CMV viruses and non-infectious cause such as Behcet disease. On the other hand, choroidal infiltrates which appear as multifocal creamy lesions underneath the retina are the most common, non-specific findings, in posterior uveitis. The possible causes are either infectious causes such as TB or non-infectious such as sarcoidosis, Vogt Koyanagi Harada (VKH), sympathetic ophthalmia (SO), serpiginous choroiditis, multifocal choroiditis, birdshot disease, punctate inner choroidopathy (PIC) and acute posterior multifocal placoid pigment epitheliopathy (APMPPE) (Foster and Vitale 2013).

1.3.3.1.4 Panuveitis

In panuveitis, the inflammation is diffuse throughout the eye. The inflammatory activity is seen across all the eye (anterior chamber, vitreous, retina and choroid). There are many systemic infectious or non-infectious diseases that can produce diffuse intraocular inflammation. Panuveitis is idiopathic when no cause was identified.

1.3.4 The clinical course of uveitis

The course of uveitis can be acute, chronic or recurrent. Acute uveitis is usually used to describe episodes of uveitis with sudden onset and limited duration, generally less than three months duration (SUN criteria). Chronic uveitis is persistent, with relapse occurring within three months after treatment discontinuation. Recurrent uveitis refers to repeated episodes of inflammation separated by inactivity without treatment that last for three months or more (American Academy of 2017).

1.3.5 Symptoms of uveitis

The symptoms of uveitis depend on the anatomical location of inflammation, the speed of the disease onset (acute, chronic or recurrent), duration (limited or persistent) and associated complications. For example, acute onset anterior uveitis is commonly associated with pain, redness, photophobia and blurred vision. The pain is due to spasm of the ciliary body, and it may radiate to the side of the face (area supplied by trigeminal nerve). Redness and light sensitivity usually occur when the inflammation affects the iris, cornea and ciliary body. Chronic anterior uveitis in patients with JIA is

usually asymptomatic, and vision loss may develop as a result of calcific band keratopathy, cataract, glaucoma or cystoid macular oedema (Foster and Vitale 2013).

Intermediate uveitis commonly causes floaters which are produced by vitreous cells or debris casting shadows on the retina. Visual impairment can also result from vitreous opacities in the visual axis or more commonly from CMO. Patients with posterior uveitis may present with painless loss of vision, floaters, photopsia (flashes of light), metamorphopsia (straight lines appear wavy), scotoma (blind area in the field of vision), or impaired night vision (nyctalopia) or a combination of these symptoms.

Loss of vision can occur either due to the primary pathology, such as retinitis and or choroiditis directly involving the macula, or secondary complications, such as CMO, ERM, retinal ischaemia and or neovascularization. Finally, loss of vision may occur due to refractive error due to the forward (hyperopic) or backward (myopic) shift of the macula associated with macular oedema, hypotony or change in lens position (American Academy of 2017).

1.3.6 Disease manifestations in uveitis

1.3.6.1 Retinal vascular disease in uveitis

There is a spectrum of abnormal vascular disease in patients with uveitis which includes retinal vasculitis, retinal Ischaemia and neovascularization. Many ocular and systemic disorders can present with retinal vasculitis, and these include systemic lupus erythematosus (SLE), Behcet disease, MS, ocular TB and sarcoidosis among others. Retinal vasculitis appear frequently in patients with posterior segment involvement, and it can lead to arterial and venous occlusion with subsequent ischaemia. Fundus Fluorescein angiography (FFA) is the best method to diagnose retinal vasculitis by demonstrating leakage of fluorescein dye from inflamed retinal vessels.

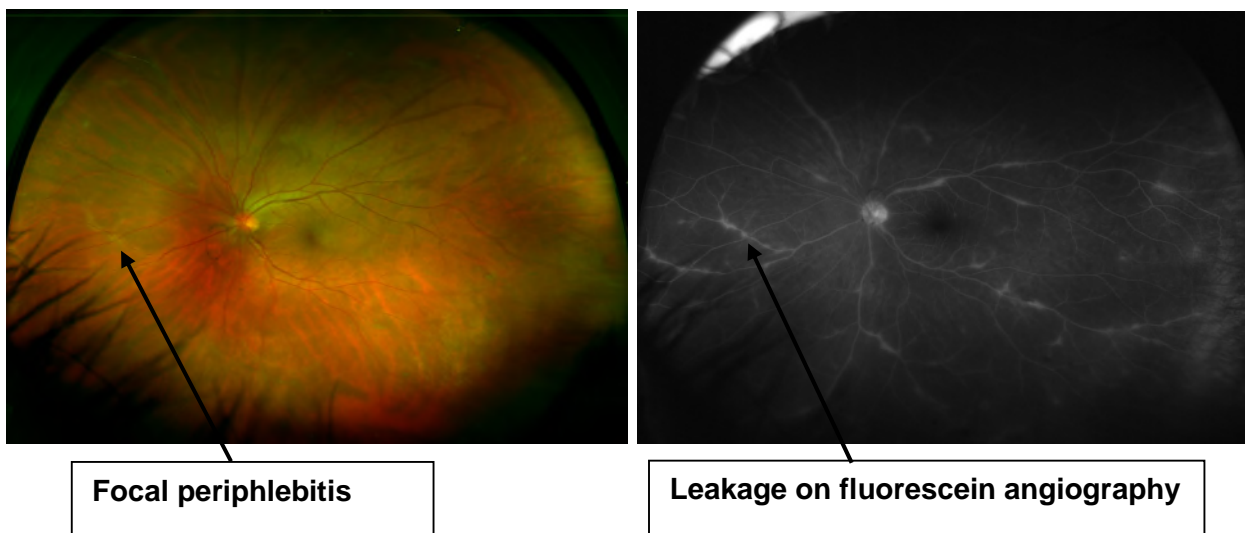
1.3.6.1.1 Retinal vasculitis

Retinal vasculitis is defined as retinal vascular changes associated with ocular inflammation. Vascular changes include perivascular sheathing and vascular leakage or occlusion on fluorescein angiography. It can present as an idiopathic isolated

condition or as a sequelae of infective, autoimmune or malignant process, or commonly in association with systemic inflammatory disease (Abu El-Asrar, Herborg et al. 2005). Behcet's disease (BD) and SLE retinopathy and classic examples of retinal vasculitis leading to occlusive events. Also, Granulomatosis with polyangiitis (GPA) previously known as Wegener's disease, sarcoidosis and polyarteritis nodosa can lead to occlusive vasculitis resulting in ischaemia to the retina (El-Asrar, Herborg et al. 2010, Rosenbaum, Sibley et al. 2016).

The diagnosis of retinal vasculitis is made clinically and FFA helps in confirming the diagnosis. When disease is active, exudates will accumulate around the vessel walls and form a white sheathing or cuffing of these vessels and dye leaks on FFA. Figure 1-7. Based on data obtained from pathological specimens the best term to describe these lesions would be perivasculitis and in most cases its periphlebitis. In MS patients, autopsy data showed that there is a lymphoplasmacytic infiltration around the retinal veins (Arnold, Pepose et al. 1984). In sarcoidosis, on histological study, the perivascular sheathing corresponded to the nodular epithelioid cells proliferation around retinal veins (Gass and Olson 1976).

Figure 1-7 Leakage of fluorescein dye in active retinal vasculitis. Photos courtesy of Dr. Xia Moorfields Eye Hospital



Histopathological examination of Behcet's disease affected eyes showed T lymphocytes infiltrated the vascular, perivascular and the surrounding space and these cells surface markers were positive for CD4 and IL-2 (Charteris, Champ et al. 1992). Similarly, lymphocytic infiltration of retinal vessels was also reported in pars planitis and Birdshot disease (Pederson, Kenyon et al. 1978, Gaudio, Kaye et al. 2002). There is another type of occlusive retinal vasculitis where the occlusion is mediated by microthrombus, and the intraocular inflammation is usually not a feature such as SLE, GPA and polyarteritis nodosa (Graham, Spalton et al. 1985, Au and O'day 2004).

Retinal vasculitis can affect the vision in several ways. Firstly, the inflamed vessels leak fluid leading to swelling of the retina, exudation and CMO formation. As mentioned earlier CMO is the most common cause of vision loss among uveitis patients. Secondly, it can lead to branch or central retinal artery occlusion which can have a devastating impact on visual outcome (Hsu, Kerrison et al. 2001, Saatci, Kocak et al. 2001, Iida, Spaide et al. 2002). Similarly, occlusive perivasculitis can lead to intraretinal haemorrhages and haemorrhagic infarction (El-Asrar, Herbort et al. 2010). Thirdly, vasculitis may result in macular ischaemia and significant visual loss (Bentley, Stanford et al. 1993, Palmer, Stanford et al. 1996). Finally, the late consequences represented by ischaemic-driven neovascularization which results in recurrent vitreous haemorrhage, traction retinal detachment, rubeosis and neovascular glaucoma. These late complications lead to loss of the eye function (Salmon, Ursell et al. 2000, Saatci, Kocak et al. 2001, Valentincic, Kraut et al. 2007).

The other important aspect is retinal vasculitis associated necrotising retinitis which follows infection with toxoplasmosis and herpes viruses. In toxoplasmosis, there is a characteristic form of vasculitis namely, Kyrieleis arteriolitis where the exudates accumulate around the retinal arteries whether adjacent to the focal area of retinitis or elsewhere in the retina (Theodossiadis, Kokolakis et al. 1995). Retinal ischaemia due to retinal vascular occlusion manifests as defects in the visual field.

1.3.7 Diagnostic tools in uveitis

1.3.7.1 Biomicroscopic examination

Clinical examination using a slit lamp is the gold standard technique used in the diagnosis of uveitis. A slit-lamp examination allows for the viewing of the anterior segment of the eye, which includes the cornea, AC and iris in detail. It also helps with the grading of the anterior chamber activity including, inflammatory cells and flare and assessing for the presence or absence of keratic precipitates, hypopyon and vitritis (Busacca 1957).

The corneal signs include KP, which are collections of inflammatory cells on the corneal endothelium (back surface of the cornea) and band keratopathy (calcium deposits on the anterior corneal surface) in long-standing disease. To measure the cellular activity in the anterior chamber, the SUN group recommends a field of 1×1 mm high power, and full intensity beam at 45-60 degree in a dark room (Jabs, Nussenblatt et al. 2005). A similar technique applies to the grading of anterior chamber flare. Iris involvement may present as either iris nodules, posterior or anterior synechiae or iris stromal atrophy in herpetic uveitis. These signs not only help with the assessment of disease severity but also in the differential diagnosis.

The National Institute of Health grading system for the vitreous haze could be superior to cell count with regards to disease activity. This method utilises standard photographs with clinical disease activity to determine the level of vitreous haze (Nussenblatt, Palestine et al. 1985). Additional signs in the vitreous are snowballs opacities which are common in sarcoidosis and intermediate uveitis and snow banking which is fluffy appearance over the pars plana. Vitreous strands also develop in these cases.

Further, slit lamp examination (with the aid of lenses) allow binocular visualisation of the posterior segment of the eye to assess the type, location, size of the lesions in the vitreous body, retina and choroid. Also, it gives an insight into the status of the optic nerve, retinal thickness (CMO) and alterations in retinal vasculature such as vascular occlusion, sheathing and neovascularization (Rutnin 1967). Posterior segment signs are retinal or choroidal inflammatory infiltrates, sheathing of blood vessels, retinal

detachment (exudative, tractional and rhegmatogenous), retinal pigment atrophy, atrophy or swelling of the retina, choroid, or the optic nerve, preretinal and subretinal fibrosis and retinal or choroidal neovascularization (American Academy of 2017).

1.3.7.2 Laboratory investigations

The laboratory tests usually follow a detailed history, review of systems and physical examination. Then a list of differential diagnosis is reached based on the findings from history and examination. To search for a possible cause for patients presenting with uveitis commonly requires laboratory investigation and a multidisciplinary approach (Perez, Chavala et al. 2004, Herbort, Cimino et al. 2005). However, at its heart lies the differentiation between infective, neoplastic and inflammatory (autoimmune) process because the treatment is entirely different. For example, immunosuppressive therapy in infectious aetiology can have devastating outcomes (El-Asrar, Herbort et al. 2010). Therefore, ruling out infectious causes in the uveitis setting cannot be overemphasised before initiating immunosuppressive drugs. In other words, laboratory tests are used to help with confirming or excluding a diagnosis for a list of differential diagnoses. Please refer to Tables 1-5,6,7.

Table 1-5 Blood tests in uveitis

General blood tests
FBC (WBC,RBC,Hb,HCT,MCV,MCH,platelet,,neutrophils,lymphocytes,monocytes, eosinophils ,basophils)
Biochemistry and serum electrolytes (Na, K, Chloride, Bicarbonate)
Erythrocytes sedimentation rate
C- reactive protein
Urea & creatinine
Liver function test (Alanine transaminase, aspartate transaminase, alkaline phosphatase)
Total protein, albumin and bilirubin
Serum cholesterol (LDL,HDL, triglycerides)
Blood sugar and HbA1c
Urinalysis

Table 1-6 Disease-specific tests in uveitis

Disease-specific tests
Venereal disease Research Laboratory (VDRL) and fluorescent treponemal absorption antibody test (FTA-ABS)
Gamma interferon release assays for tuberculosis (Q Gold quantiferon test)
Angiotensin Converting Enzyme (ACE)
Lyme disease serology
Toxocara serology
Toxoplasma serology
Bartonella henselae (Cat scratch disease) serology
Human immunodeficiency virus Human T cell lymphoma virus HTLV-1 Cytomegalovirus, Herpes simplex, herpes zoster, varicella zoster, West Nile virus serology
Polymerase Chain Reaction (PCR) to identify pathogens in samples obtained from ocular fluid (Aqueous and vitreous)
Rheumatoid factor
Antinuclear antibody (ANA)
Anti-ds DNA
Antineutrophil cytoplasmic antibody(ANCA)
Antiphospholipid antibodies (Lupus anticoagulant and anticardiolipin antibodies)
Human Leukocyte antigen testing (HLA B27, HLA A 29, HLA B51, and HLA DR3)
Cerebrospinal fluid analysis

Table 1-7 Imaging studies in selected cases with uveitis

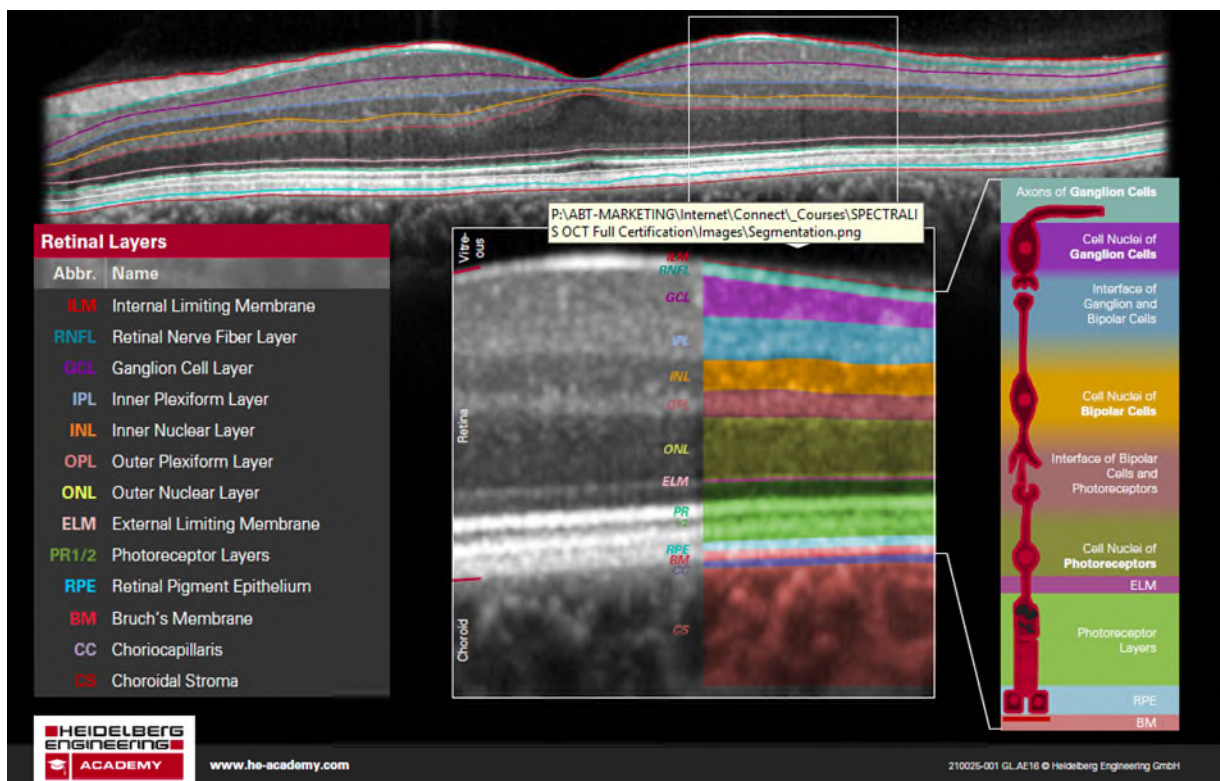
Imaging
Chest X-ray
Chest CT scanning
MRI

1.3.7.3 Imaging modalities in uveitis

1.3.7.3.1 Optical Coherence Tomography

The Optical Coherence Tomography (OCT) era began in 1991 (Huang, Swanson et al. 1991) and has revolutionised the field of ophthalmology ever since. OCT is non-invasive cross-sectional in-vivo imaging of the ocular structure. It uses laser light and coherence interferometry to identify differences in tissue reflectivity and in real-time plots images that are comparable to the histological structure of the retina. Figure 1-8 (Hassenstein and Meyer 2009). In uveitis practice, OCT is routinely performed to assess and monitor for CMO, vitreoretinal interface and inflammatory-mediated structural complications in the posterior segment of the eye.

Figure 1-8 Spectral domain OCT scan with segmentation of all the retinal layers. Web source https://academy.heidelbergengineering.com/course/view.php?id=356&utm_source=academy-teaser-en&utm_campaign=Handout_Retinal_Layers



The first generation of the OCT was time-domain, but this was replaced by Spectral Domain OCT (SD-OCT). This technology relies on a spectrometer with a high-speed camera and utilises low-coherence interferometry to detect the reflected light and analyses the information using a Fourier transformation (mathematical formula to

simultaneously measure all the echoes of light). This faster technology with higher axial resolution (1-3 μ m) has provided more details with regards to retinal structures and pathologies (Kiernan, Mieler et al. 2010). The underlying choroid can also be captured by the Enhanced Depth Imaging technique (EDI) (Margolis and Spaide 2009). This imaging modality is beneficial in assessing the choroid in Vogt-Koyanagi-Harada disease (VKH), where there is an increase in choroidal thickness.

Macular oedema, the most common cause of visual loss in uveitis, can be seen on OCT in three patterns: Cystoid macular oedema, diffuse type macular oedema and macular oedema with serous retinal detachment (Markomichelakis, Halkiadakis et al. 2004). OCT has a superior sensitivity (96%) and specificity (100%) in detecting CMO compared to fluorescein angiography (Antcliff, Stanford et al. 2000). Moreover, OCT scan gives quantitative and qualitative data with regards to macular thickness and volume which is essential in monitoring response to therapy. Further, an epiretinal membrane which causes reduced vision and distortion can also be demonstrated by OCT (Tran, de Smet et al. 2008).

OCT scan has several more advantages in uveitic eyes. It can depict the RPE and outer retina changes particularly photoreceptors inner/outer segment junction and shows disturbances to these structures which have been found to correlate to visual function (Zhou, Jiang et al. 2015). Also, it detects choroidal neovascular membrane (CNV), a sight-threatening complication that arises when the RPE/Bruch's membrane complex is compromised. Several inflammatory conditions are associated with CNV, such as multifocal choroiditis (MFC), punctate inner choroidopathy (PIC) and VKH. However, FFA remains the gold standard technique in demonstrating these membranes since inflammatory CNVs are not always associated with fluid (Kotsolis, Killian et al. 2010). Moreover, OCT differentiates between the intraretinal and subretinal fluid accumulation. The latter is common in VKH where non-rhegmatogenous retinal detachment is typical (Rao 2007). Finally, epiretinal membrane and or vitreomacular traction are readily visible on OCT, and these can aggravate uveitic CMO. OCT is important in these scenarios, because the management of these complications is more surgical than medical. OCT helps with diagnosing uveitis related posterior pole complications as well as excludes and other pathologies that may worsen uveitic CMO.

1.3.7.3.2 OCT Angiography

OCT angiography (OCTA) is an innovative technology for imaging retinal blood vessels without the need for an injection of contrast agent. OCTA plots images of the capillary networks by analysing the light reflected from static and moving targets (blood) on sequential scans (Wang 2010). OCTA provides high-resolution images of vascular complexes at different levels and this can be of particular importance in situations where blood and stain mask vascular alterations.

This modality can show secondary vascular complications of uveitis, it mainly confirms the presence of abnormal neovascularization (CNV) in a non-invasive way and when these vessels appeared equivocal on FA and ICG. For example, OCTA was able to show the different origin of these abnormal vessels. In infectious pathologies such as ocular toxoplasmosis, the source of these vessels was the outer retina, contrasting MFC and PIC where these vessels arise from the choriocapillaris layer of the choroid. There are several shortcomings with this technology. First, this modality is unable to differentiate between active and inactive neovascular lesions. Also, the images generated are subject to artefacts manifesting as projections of superficial vessels on the deep layers, and these are the major limitation at the time being. OCTA is a highly active area of research and with continuous improvements OCTA would help reveal vascular changes in uveitis and aid with their management (Hassan, Agarwal et al. 2016).

1.3.7.3.3 Fundus fluorescein angiography FFA

Angiographic testing of the posterior segment of the eye is essential in diagnosing certain inflammatory conditions such as retinal vasculitis and CMO. Also, it is useful in assessing the extent and severity of vascular disease. Fluorescein can emit light of longer wavelength upon stimulation of light with a short wavelength. Fluorescein angiography uses fluorescein sodium, a natural dye, injected intravenously and it is water soluble; 70-85% is protein bound, and the remaining is free, and this free portion is responsible for the absorption of light at 490nm and re-emitting it between (520-530nm).

FFA is a very sensitive measure when assessing the retinal circulation and blood vessels. There are patterns which can give insight regarding the underlying pathology. For example, fluorescein dye can leak through disrupted barriers and give rise to leakage or staining of the vessel walls in subjects with vasculitis. It also aids with documenting the areas of occlusive vasculopathy and retinal ischaemia by showing vascular non-perfusion (capillary drop-out) or abnormal vascular growth (neovascularization) whether of retinal or choroidal origin. Finally, increased transmission from the choroid through areas of RPE atrophy (window defect) gives a hyperfluorescent signal. However, it provides limited information on the choroidal layer because the wavelength of fluorescein is blocked by the RPE layer (Kanski and Bowling 2011).

1.3.7.3.4 Indocyanine Green Angiography

Indocyanine Green Angiography (ICG) fluoresces at a longer wavelength (830 μ m) in the infrared spectrum, and therefore readily access the RPE layer and allows better visualisation of the underlying choroid. The other differentiating feature is that ICG is completely protein bound (Baker 1966) hence, only large defects in retinal vessels would allow ICG leakage (Lim and Flower 1995). However, the fenestrations of the choriocapillaris allow ICG to leak slowly (Guex-Crosier and Herbort 1997). Areas of choroidal non-perfusion due to inflammatory foci appear as decreased fluorescence while areas of increased fluorescein can demonstrate areas of leakage from large choroidal vessels (Tugal-Tutkun, Herbort et al. 2010).

1.3.7.3.5 Fundus autofluorescence (FAF)

Autofluorescence is the ability to fluoresce without using stains. Lipofuscin accumulates in the RPE cells as result of phagocytosis of the outer segments of the photoreceptors, and it contains a wide range of fluorophores with an excitation spectrum from 300-600nm and emission spectrum from 480 to 800 nm. Clinically autofluorescence detects the distribution of lipofuscin within the RPE and therefore it can accurately measure the health and function of the retinal pigment epithelium (Delori, Dorey et al. 1995).

Over accumulation of lipofuscin within the RPE, and hence hyperautofluorescence indicates oxidative cellular damage, whereas hypoautofluorescence indicates loss of RPE cells and subsequently photoreceptors (Schmitz-Valckenberg, Holz et al. 2008).

Fundus autofluorescence FAF has many applications in posterior uveitis and could be a sensitive measure of disease activity and progression which can guide the treatment with immunomodulatory therapy. For example, FAF is regarded as a reliable indicator of disease activity in serpiginous choroiditis and shows RPE involvement more than the angiography. In the acute stage, FA showed hyperautofluorescence which then followed by hypoautofluorescence due to scarring (Piccolino, Grosso et al. 2009). Further studies showed that FAF helps to distinguish serpiginous choroiditis from tuberculosis-associated serpiginous-like choroiditis. The latter appeared as a varied pattern of hypo and hyper autofluorescence which is different from the homogenous, continuous hypofluorescence in serpiginous choroiditis (Yeh, Forooghian et al. 2010). In VKH fundus autofluorescence revealed many hypofluorescence dots secondary to RPE atrophy and these develop in areas of previous serous retinal detachment. (Ayata, Dođru et al. 2009).

In multifocal choroiditis and panuveitis syndrome which is characterised by small round chorioretinal scars, FAF showed a widespread involvement of the RPE which was not evident by other imaging techniques (Haen and Spaide 2008). These dots were mainly clustered around the optic nerve and in the macula region, and they outnumbered the visible scars on clinical examination. Interestingly, later on, these spots have increased both in size and number and progressed to scarring. Moreover, in the same study, CNV was visible as a hyperautofluorescence margin. In Birdshot chorioretinopathy (BSCR) hypoautofluorescence dots were associated with visible lesions of advanced disease. Finally, significant foveal hypoautofluorescence corresponds to reduction in visual acuity in patients with white dot syndromes (Yeh, Forooghian et al. 2010).

1.3.7.3.6 Electroretinography

Electroretinography can help with the aid of visual field testing to monitor disease progression in Birdshot uveitis. It also helps excluding masquerade of uveitis such as retinitis pigmentosa and autoimmune retinopathy (American Academy of 2017).

1.3.7.3.7 Ultrasound scan

Ultrasound scans are usually used when there is a poor view of the ocular fundus, due to the excellent penetration of ultrasonic waves. It shows vitreous opacities, choroidal thickening, retinal detachment, ciliary body detachment and cyclitic membranes. Moreover, US helps rule out intraocular foreign bodies, especially if media opacities obscure a good view of the posterior segment. Finally, ultrasound is very useful in diagnosing posterior scleritis (American Academy of 2017).

1.3.8 Complications of uveitis /Causes of vision loss in uveitis

Uveitis can affect the vision in different ways. A study by Tomkins-Netzer and co-workers showed that intermediate, posterior or panuveitis carry the worst visual outcome. The study showed that posterior signs of uveitis such as vitreous haze or development of new inflammatory chorioretinal lesions are more closely related to vision loss than anterior segment signs (increasing in anterior chamber cells). The most common causes of vision loss are cystoid macular oedema (CMO), macular scarring and retinal detachment (Tomkins-Netzer, Talat et al. 2014). Other reasons are optic neuropathy, retinal vasculitis with or without ischemia, phthisis bulbi, hypotony, (Daniel, Pistilli et al. 2012), band keratopathy and glaucoma (Foster, Kothari et al. 2016).

1.3.8.1 Cystoid Macular Oedema CMO

Uveitic CMO, represents a serious and common cause of vision loss in uveitis, occurs in around 40% of eyes with non-infectious intermediate, posterior and panuveitis (Rothova, Suttorp-van Schulten et al. 1996). CMO refers to the accumulation of intraretinal fluid in the foveal region with subsequent increase in retinal thickness. The MUST trial reported a significant association between a central retinal thickness of $\geq 240 \mu\text{m}$ and worse visual outcome in patients with uveitis (Taylor, Lightman et al. 2012). Several proinflammatory cytokines during active intraocular inflammation can lead to the formation of CMO. For example, VEGF and IL-6 appear to mediate CMO by causing retinal vascular leakage and RPE dysfunction (Rothova 2007). Vitreomacular traction can also cause CMO, but to a lesser extent.

This complication carries a negative impact on patients' vision and quality of life. It has been reported that CMO is responsible for 40-50% of cases of irreversible vision loss among patients with uveitis (Lardenoye, van Kooij et al. 2006). The paper defines legal blindness as vision $\leq 6/60$, and visual impairment is visual acuity of $\leq 6/18$ but better than $6/60$ on Snellen visual acuity chart. In this cross-sectional study on 529 patients, panuveitis and intermediate uveitis had the highest frequency of CMO compared to other uveitis entity. CMO associated with panuveitis was responsible for 59% of cases of visual impairment or blindness, and CMO in intermediate uveitis accounted for 85% of these cases. The authors pointed out that specific forms of uveitis tend to be associated with a higher frequency of CMO (over 50% of cases) compared to other types. Sarcoidosis, for example, is associated with CMO in 59% of cases, Behcet disease 63%, and Birdshot chorioretinopathy in 100% of patients, while, HLA-B27 associated anterior uveitis is least frequently associated with CMO, and CMO only occurs in about 12%.

Other factors associated with increased risk of CMO are age and cataract surgery. In a retrospective study, Kooji et al. reported a 3.8 fold increase risk of CMO in patients over 50 years of age compared to younger patients (Van Kooij, Probst et al. 2008). Cataract surgery has been described to increase the risk of CMO in patients with uveitis, and the risk was higher in eyes with active inflammation within three months before the surgery compared to non-inflamed eyes (Bélair, Kim et al. 2009).

The clinical symptoms of CMO can vary, but generally, it leads to a reduction in central visual acuity and mainly reading difficulty. Other symptoms include metamorphopsia (straight lines appear wavy), reduced colour perception and central or paracentral scotoma. A special consideration should be paid to young patients with ocular inflammation, where there is a substantial amount of CMO but with normal or near-normal visual acuity (Bischoff 1999). Recent studies have shown that reading function and contrast sensitivity are superior to distant visual acuity when assessing visual impairment in patients with inflammatory CMO (Kiss, Barisani-Asenbauer et al. 2006). Long-standing or inadequately treated CMO lead to permanent vision loss and a central scotoma in the field of vision due to damage to the photoreceptors (scarring) (Bischoff 1999).

The exact pathophysiological mechanism behind the development of inflammatory CMO is still not clear. However, studies have shown that various inflammatory mediators such as, prostaglandins, IL-1, IL-2 and IL-10, interferon gamma, and TNF α induce breakdown of the blood-retinal barrier that leads to leakage of fluid from the vessels into retinal tissue manifesting as extracellular oedema (Wakefield and Lloyd 1992, Rotsos and Moschos 2008). Similarly, vascular endothelial growth factor (VEGF) is also involved in the pathogenesis of CMO. Fine et al. reported increased levels of VEGF in aqueous humour of uveitis patients with CMO (Fine, Baffi et al. 2001).

Because fundoscopy is not always a reliable method in diagnosing CMO, fluorescein angiography was the most commonly used method to detect the presence of CMO which manifests as a petaloid-like pattern. Figure 1-9. Nonetheless, being an invasive method with several side effects, fluorescein angiography has mainly been replaced by newer technology. OCT is now the gold standard technique for diagnosing CMO because it allows for detection of the distribution of the fluid and quantification of retinal thickness, non-invasively and can be easily repeated. Figure 1-10. These data are essential for follow-up and during the assessment of a patient's response to treatment (Tran, de Smet et al. 2008). Moreover, OCT was able to detect ERM another inner retinal pathology in around 40% of uveitic macular oedema (Markomichelakis, Halkiadakis et al. 2004).

Figure 1-9 CMO on fluorescein angiography shows the characteristic petaloid pattern. Source Moorfields Eye Hospital.

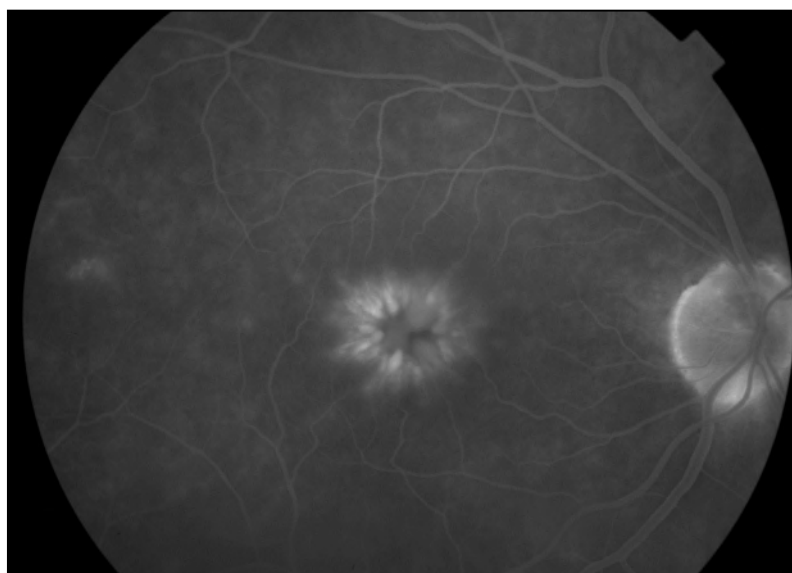
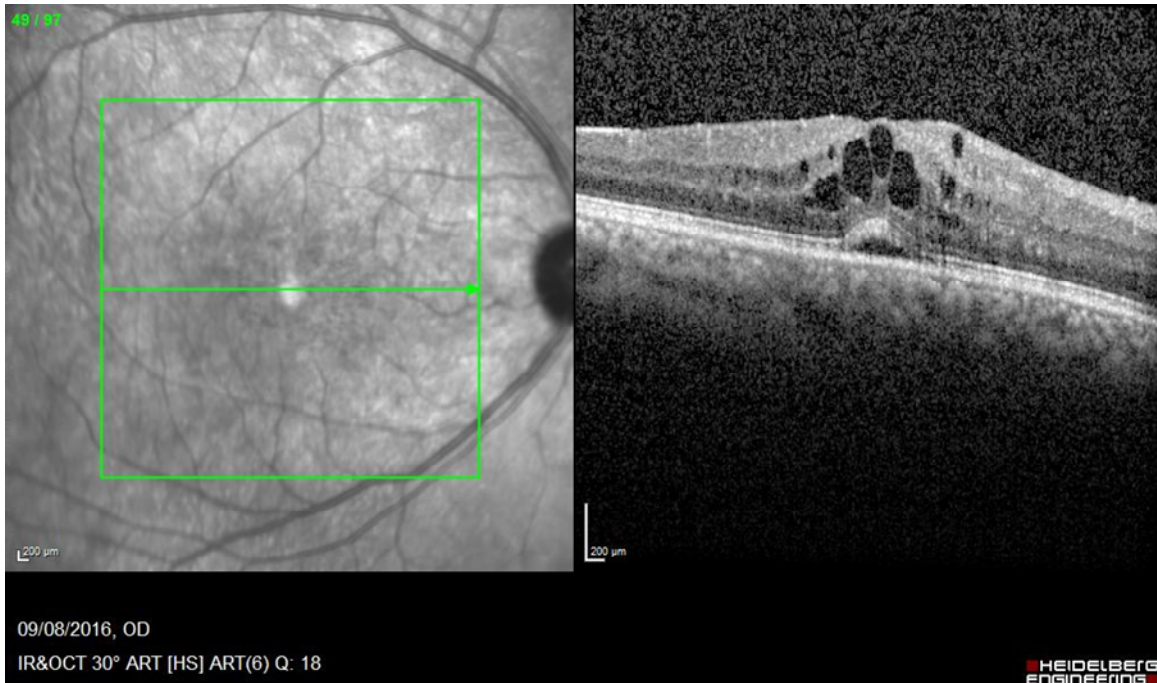

Figure 1-10 OCT scan shows CMO with cystoid changes at the fovea and sub retinal fluid in uveitis. Source Moorfields Eye Hospital.



However, fluorescein angiography cannot be entirely replaced by OCT. FFA may show early perifoveal vascular leakage before cystic spaces become evident on OCT. Furthermore, FFA is more sensitive in detecting vascular inflammation which results in an early breakdown of the blood-retinal barrier, even before CMO is overt. This can occur early in inflammation when there is still efficient mechanisms responsible for fluid absorption (Kempen, Sugar et al. 2013).

1.3.8.2 Cataract

Cataract is a common complication in uveitic patients: it can result from chronic inflammation or its treatment particularly the use of corticosteroids whether local or systemic. The incidence of cataract varies, and in many forms of uveitis such as JIA, pars planitis and Fuch's uveitis it can reach up to 50% of patients (Hooper, Rao et al. 1990). Pathologically, the changes in the lens are seen first in the anterior subcapsular epithelium, lens equator or in the posterior subcapsular region (Spencer 1985). The areas of anterior lens changes are commonly seen in association with posterior synechiae (adherence between the posterior iris and anterior lens capsule).

Inflammation in the posterior chamber produces changes in the equatorial region of the lens which forces the lens epithelium to migrate posteriorly with disruption of the subjacent cortical fibres. When these fibres lose their tight junctions, they begin to lyse and liquefy predisposing to clinical opacities. A posterior subcapsular cataract develops when the posteriorly migrated epithelial cells undergo degeneration and hyperplasia, commonly associated with the appearance of hypertrophied “bladder” cells. This type of cataract appear more localised, and it is frequently associated with corticosteroid use (Greiner and Chylack 1979). A posterior subcapsular cataract is the most common type in uveitis and can have a profound effect on vision due to its proximity to the nodal point of the eye.

The exact mechanisms by which intraocular inflammation causes cataract is unknown. However lenticular changes due to posterior synechia can result from local hypoxia and accumulation of toxic metabolites secondary to local alteration of aqueous outflow. Additionally, inflammatory products such as phospholipase A and lysosomal enzymes, have been shown to damage lens fibres membranes leading to cataract formation (Secchi 1982). Other inflammatory products such as oxygen free radicals and immune complex deposition on the lens capsule, may also result in inflammatory lens damage (Fisher 1981, Marak Jr, Rao et al. 1985).

The mechanism by which corticosteroid causes posterior subcapsular cataract is also unknown. However, alteration in cellular metabolism and electrolyte balance seem to contribute to the development of cataract. Clinical studies have shown that the risk of cataract increases with the higher frequency of topical steroids drops and longer duration of use (Williamson, Paterson et al. 1969). The incidence is higher in patients treated with higher oral corticosteroid doses compared to smaller doses < 10 mg/ day (Giles, Mason et al. 1962). In this series, the incidence of cataract formation in patients on systemic corticosteroids for four years reached 56%. However, other authors have suggested that steroids can trigger the formation of cataract regardless of the total dose, treatment duration, or even the age of the patient (Skalka and Prchal 1980). The authors claimed that the formation of cataract varies among individuals and the exposure to corticosteroids by itself is more important than the dose or duration of the exposure.

The most likely explanation for the development of cataract is the interplay of multiple factors involved in ocular inflammation and its treatment. Therefore, the aim of treating the inflamed eye should be directed to minimise the inflammation with the least dose of corticosteroid possible to lessen the risk of cataract, which is not always possible (Hooper, Rao et al. 1990).

The typical clinical manifestations of cataract are glare and vision loss. The diagnosis of cataract is by slit lamp examination which reveals the lens opacities in addition to any pigment deposition on the anterior lens capsule. However, in the presence of posterior synechia which restricts pupillary mobility, the assessment of the lens can be somewhat challenging. Treatment is mainly indicated to surgically remove the visually significant cataract when there is a good prospect for improvement in visual acuity or when the cataract precludes the proper assessment of patients with posterior segment disease.

The previously held misconception regarding the unfortunate outcome of cataract surgery in uveitis was true before the advent of corticosteroids. The operation on these inflamed eyes have resulted in catastrophic consequences. Previous attempts to remove the cataract in an eye with inflammation that is difficult to control have resulted in a high incidence of severe complications such as intraocular haemorrhage, choroidal detachment, exacerbation of inflammation postoperatively leading to pupillary membrane formation and glaucoma or ciliary body detachment and phthisis (Hooper, Rao et al. 1990). The recent advances in surgical techniques with the introduction of phacoemulsification, the development of high quality ophthalmic viscosurgical devices and foldable, biocompatible intraocular lens (Chee, Ti et al. 1999, Abela-Formanek, Amon et al. 2002) have resulted in better surgical outcomes and less postoperative inflammation. However, uveitic eyes are at higher risk of early capsular opacification, lens deposits, synechia, iris atrophy, cystoid macular oedema, epiretinal membrane, retinal detachment and even phthisis (Hooper, Rao et al. 1990).

It is of paramount importance to achieve full control of intraocular inflammation before, during and after the surgery (Becker and Davis 2008) and the operation should be performed when the inflammation is under control for a minimum of three months (Foster and Rashid 2003). However, this is not always possible, therefore a minimum anterior chamber activity $<+1$ cellular activity is acceptable, but those patients need a

prophylactic therapy for one week before the surgery to be tapered after that. Also, periocular corticosteroid injection may be used when a severe postoperative inflammatory response is anticipated (Sharief, Lightman et al. 2018).

Postoperative complications after cataract surgery are common in patients with uveitis, with CMO being the most common and distressing complication in patients with chronic uveitis. A study by Sharief and associates showed that 27% of uveitic patients showing CMO post cataract surgery and this occurring in 28.4% of patients with IU. Importantly, patients with a history of preoperative CMO have a 2.5 fold increase in the risk of CMO post cataract surgery (Sharief, Lightman et al. 2018). Other authors reported an incidence of 21.3% for CMO, and this came after posterior capsular opacification and posterior synechiae) (Ram, Gupta et al. 2010). It is agreed that lower incidence of postoperative CMO occurs when uveitis is under control for at least three months before the surgery and corticosteroids are used perioperatively.

Cataract surgery is consistently reported to cause exacerbations in various types of intraocular inflammation with a peak incidence of 1-6 months after surgery. Macular oedema and recurrence of inflammation have been reported in up to 50% of patients with pars planitis and VKH, and inflammatory deposits on the intraocular lens (IOL) in one-third of cases (Ganesh, Babu et al. 2004, Ganesh, Babu et al. 2004). Different strategies are aiming to reduce the risk of relapses after cataract surgery, and local corticosteroid injection and or frequent topical corticosteroid therapy being the most commonly used (McColgin and Heier 2000). Reactivation of ocular toxoplasmosis was reported following cataract extraction. Despite the improvement in visual acuity after cataract removal, the authors reported a 36% of disease reactivation within four months after the surgery (Bosch-Driessen, Plaisier et al. 2002). Therefore, a prophylactic treatment before the surgery is recommended especially when the patient is at high risk of vision loss in recurrent ocular toxoplasmosis (scars near the optic disc or the fovea).

Posterior capsular opacification (PCO) is one of the most common long-term postoperative complications, ranging between 20-30% of cases (Ram, Gupta et al. 2010). Others reported an even higher incidence of PCO reaching up to 81% of cases (Rauz, Stavrou et al. 2000). PCO is a form of postoperative inflammatory reaction to the artificial lens which occurs in a higher rate in patients with uveitis (Abela-Formanek,

Amon et al. 2002). Also, younger patients are more susceptible to this complication, which can be visually significant and requiring Nd: YAG laser posterior capsulotomy.

1.3.8.3 Glaucoma

Uveitic glaucoma is a common and often serious complication in uveitis. The prevalence of glaucoma in uveitis patients varies, but it has been reported between 10-30% (Panek, Holland et al. 1990, Neri, Azuara-Blanco et al. 2004). Specific types of uveitis are associated with high frequency of IOP elevation such as Posner Schlossman syndrome (100%) and Fuch's cyclitis. However, intraocular pressure (IOP) elevation was reported to be as high as 42% of patients (Herbert, Viswanathan et al. 2004). Secondary ocular hypertension is the preferred term initially, but when glaucomatous optic nerve head damage and visual fields abnormalities ensue, it is labelled as glaucoma.

Several important factors lead to elevation of the IOP. Firstly, the type of uveitis, high IOP tends to occur more frequently in anterior segment inflammation compared to posterior segment (Panek, Holland et al. 1990). Secondly, the severity and chronicity of the inflammation also play a significant role in this regard, glaucoma is more prevalent in patients with the longer duration of inflammation, in other words in poorly controlled inflammation (Neri, Azuara-Blanco et al. 2004). Finally, the type of the treatment used, the risk is higher with local treatment compared to systemic one. MUST trial have shown that more patient in fluocinolone acetonide implant group (65%) had an increase in IOP ≥ 10 mmHg versus only 24% in those with systemic immunosuppressive therapy (p -value < 0.001). Consequently, glaucomatous optic nerve damage occurred in 23% and 6% in implant and systemic therapy group, respectively, (p -value <0.001). The study concluded that implant received eye had a 4-fold increase in the risk of high IOP and optic nerve damage, over two-year follow-up (Friedman, Holbrook et al. 2013).

Mechanical factors in the anterior chamber such as posterior synechiae are more frequently associated with elevated intraocular pressure (Neri, Azuara-Blanco et al. 2004). In acute inflammatory attacks in uveitis, there is a natural tendency for a reduction in IOP. However, in many cases with chronic uveitis, this low IOP is outweighed by increased resistance to aqueous outflow which leads to an increase in

IOP. Angle-closure is caused by pupillary block either by the complete seclusion of the pupil by the posterior synechiae and forward movement of the iris-lens diaphragm, or neovascularization of the angle. Angle closure occur more commonly due to peripheral anterior synechiae.

Open angle is a common finding and the rise in IOP is mainly due to strong corticosteroid use. The potency and frequency of corticosteroids used to treat ocular inflammation and subject's susceptibility to corticosteroids contribute significantly to IOP rise. For example, dexamethasone sodium 0.1% and prednisolone acetate 1% have a more profound effect on IOP elevation than rimexolone 1% and fluorometholone 0.1% (Foster, Alter et al. 1996). The proposed mechanism by which steroids increase IOP is by altering the extracellular matrix in the trabecular meshwork (Sheppard, Comstock et al. 2016).

Other causes which can also lead to glaucoma in uveitis are inflammation of trabecular meshwork, pigment deposition in the draining structures and ischaemia of trabecular meshwork secondary to reduced aqueous production during episodes of acute uveitis (Johnson 1996). Finally, flare in the anterior chamber due to leakage of proteins from inflamed ciliary body and iris vessels is inversely correlated to the outflow facility (Ladas, Yu et al. 2001).

Adequate management of active uveitis is a crucial issue when treating uveitic glaucoma. The initial management is medical; however, a large proportion of uveitic eyes require surgery to reduce the IOP and prevent permanent damage to the optic nerve head. The surgical options include trabeculectomy and aqueous shunts (Friedman, Holbrook et al. 2013).

1.3.8.4 Retinal and choroidal neovascularization

Retinal neovascularization is an uncommon but severe complication of intraocular inflammation. This term refers to the excessive growth of abnormal vascular complexes in the pre-retinal space leading to fibrous tissue formation which predisposes to tractional retinal detachment. These abnormal vessels arise as a compensatory mechanism to microvascular damage and ischaemia (Sapieha et al., 2010). The reported prevalence is 0.77%, and incidence is 0.33 with a higher risk in

intermediate, posterior and panuveitis especially when there is accompanying retinal vascular sheathing and occlusion (Patel et al., 2016). Chronic inflammation lead to vascular occlusion and ischemia with subsequent upregulation of several proinflammatory cytokines such as, TNF α , IL-1 β , IL-6 and IL-8 in addition to environment-rich VEGF form ischaemic retina (Curnow and Murray, 2006, Dorrell et al., 2007, Adamis and Berman, 2008, Sapieha et al., 2010).

As mentioned earlier retinal vaso-occlusive diseases such as Behcet's disease, SLE (Vine, 1992) and presumed ocular TB (Eales disease) (Biswas et al., 2002) are frequently associated with neovascularization. Other conditions that can also be associated with retinal neovascularization are intermediate uveitis, toxoplasma retinochoroiditis, sarcoidosis and retinal vasculitis of various aetiologies (Kalina et al., 1990, Rodriguez et al., 2015, Miyao et al., 1999).

The presence of retinal neovascularization due to uveitis does not always require laser treatment. Some cases of sarcoid panuveitis, for instance, may exhibit retinal neovascularization on the optic disc without retinal vascular closure and respond well to immunosuppressive therapy and corticosteroids alone. Therefore, treatment should be directed first to reduce the inflammation. If there is extensive retinal ischaemia angiographically then scatter laser photocoagulation is the therapeutic option of choice to minimise the angiogenic drive. Also, a dramatic response of these abnormal vessels to anti-VEGF treatment is commonly reported (Gulati, Forooghian et al. 2011). Initially better control of inflammation reduces the risk of neovascularization. However, later in disease course when there is extensive retinal ischemia and upregulation of VEGF, treatment with laser photocoagulation and anti-VEGF therapy become the superior alternative.

Choroidal neovascular membrane (CNV) refers to the abnormal growth of vascular complexes from the choroid into the neurosensory retina, through damaged RPE and Bruch's membrane complex. These pathological blood vessels tend to involve the macula and leak fluid resulting in serous retinal detachment and scar formation with loss of central vision (Penn 2008). It has a high prevalence in eyes with posterior or panuveitis such as MFC, PIC, VKH and ocular histoplasmosis syndrome (Baxter, Pistilli et al. 2013).

The pathogenesis of CNV is multifactorial but a state of chronic inflammation and activated leukocytes that promote angiogenesis, are key issues in the development of CNV (Dhingra, Kelly et al. 2010). The secretion of inflammatory mediators such as TNF α and IL-1 help degrade the RPE and Bruch's membrane complex along with upregulation of angiogenic factors such as VEGF, promote CNV complexes growth and development (Crane, Wallace et al. 2000, Bian, Elner et al. 2007, Cha, Bae et al. 2007). The new vascular tufts of CNV may invade and perforate Bruch's membrane (BM) or grow through defects within inflammatory disturbed BM and reside underneath the RPE layer (type 1) or beneath the neurosensory retina (type 2). In contrast to patients with neovascular AMD, CNV in uveitic patients tend to be smaller and type 2 in most patients (Grossniklaus, Miskala et al. 2005).

A study by Reddy et al. examined the differences between inflammatory and non-inflammatory CNV membranes found that inflammatory CNV was associated with higher number of macrophages and lymphocytes than the non-inflammatory membranes in AMD (Reddy, Zamora et al. 1995). Also, the study hypothesised that transforming growth factor beta1 and basic fibroblast growth factor (both secreted from macrophages that invaded the retina in response to the death of the RPE) play a key role in CNV development. TGF β -1 is chemotactic for lymphocytes among other immune cells and induces the transformation of the RPE into fibroblasts. Basic fibroblast growth factor binds to extracellular matrix and induces angiogenesis with the help of lymphocytes, by stimulating vascular endothelial proliferation in choroidal choriocapillaris.

The Systemic Immunosuppressive for Eye disease (SITE) study has shown that CNV is rarely found in anterior or intermediate uveitis but it is more common in eyes with posterior and panuveitis. Among 4041 eyes with posterior and panuveitis at baseline only 2% had CNV, and of these 2364 CNV free eyes initially, the two years cumulative incidence for CNV development was 2.7%. The same study has identified several risk factors for CNV and these include: the presence of active inflammation, pre-retinal neovascularization and history of prior CNV in the contralateral eye.

All patients with intraocular inflammation especially those with intermediate, posterior and panuveitis (NIIPPU) are at risk of CNV development. However, certain diseases are associated with higher risks than others. PIC, for example, is associated with a

high risk of CNV development with as many as 69% of patients having CNV and with 34% of patients having bilateral involvement. In 75% of patients, CNV developed within the first year from onset of symptoms (Gerstenblith, Thorne et al. 2007). Similarly, VKH may also be complicated by CNV and subretinal fibrosis in 15% and 40% of patients, respectively. The risk of CNV development was higher with the longer disease duration (Lertsumitkul, Whitcup et al. 1999). In line with these results in a study from the University of Southern California on 116 eyes of VKH, CNV was present in 9% of patients. The affected eyes have had frequent and severe attacks of anterior and vitreous inflammation before the emergence of CNV and poorer visual outcome after that (Moorthy, Chong et al. 1993). Similar findings were reported by another group (Read, Rechodouni et al. 2001). Serpiginous choroidopathy has also been associated with either active CNV development (13%) or disciform macular scarring (13%) in 14 of 53 patients (Blumenkranz, Gass et al. 1982). CNV was also reported in patients with sarcoidosis and Behcet disease (Michelson, Michelson et al. 1980, Gragoudas and Regan 1981). Interestingly, CNV may be an early manifestation of intraocular inflammation. A review of 58 cases with idiopathic CNV showed that four have subsequently been diagnosed with uveitis (Machida, Fujiwara et al. 2008). Furthermore, a case has been reported with bilateral peripapillary CNV who later developed serpiginous choroiditis (Lee, Suhler et al. 2003).

CNV could also complicate the course of infectious diseases such as ocular toxoplasmosis. CNV was documented at the edge of an inactive scar in a review of 21 patients affected by toxoplasmosis and CNV in an otherwise healthy eye (Atmaca, Simsek et al. 2006).

Therefore, it seems prudent to control the inflammation in posterior uveitis to try and eliminate the risk of CNV. Additionally, laser treatment aimed at the non-perfused area is necessary to decrease the angiogenic drive that would promote CNV development.

The symptoms of CNV can vary, for example, peripheral CNV is asymptomatic whereas, foveal involving CNV presents with a reduced central vision. Patients with CNV usually presents with metamorphopsia caused by retinal distortion due to retinal pigment epithelial detachment, subretinal fluid or cystoid macular oedema. Scotoma due to adjacent haemorrhage has also been documented in these CNV membranes.

CNV membrane appears on fundoscopy as a greenish-grey sub-retinal lesion. More commonly intra-retinal and sub-retinal fluid, blood or fibrosis, may be the only sign.

The diagnosis of CNV is usually made with fluorescein angiography. Typically the CNV has a central hyperfluorescence that increases with time, and it may show leakage of dye into the surrounding subretinal space. ICG may show mid-phase hyperfluorescence and late leakage. FFA helps to distinguish between CNV and new sites of active inflammation in some uveitis entities such as serpiginous choroiditis. OCT visualises CNV as hyperreflective layer anterior to RPE (Giovannini, Amato et al. 1999). FA is superior to OCT when evaluating inflammatory CNV, Kotsolis and colleagues reported that 95% of patients with MFC had leakage on FA consistent with type 2 CNV, whereas only 53% showed subretinal fluid or intraretinal cystic spaces on OCT (Kotsolis, Killian et al. 2010).

Treatment of inflammatory CNV should be directed toward controlling inflammation as well as targeting the membrane to ablate it. Focal laser photocoagulation of extrafoveal CNV may be useful. In subfoveal and juxtafoveal location the treatment consists primarily of anti-VEGF therapy. However, increasing the dose of immunosuppressive medication including corticosteroid and a second-line immunosuppressive agent(s) should be sought when these membranes arise in the presence of active intraocular inflammation, and in their recurrence, or inadequate response to anti-VEGF agents. Results of one study showed 2-3 injections are usually sufficient to improve vision and reduce the CNV size (Doctor, Bhat et al. 2009). Submacular surgery has a favourable outcome in uveitis because these membranes are mostly of type 2 (Olsen, Capone et al. 1996). However, the risks involved are much greater than those with intravitreal anti-VEGF injections, and therefore, this has largely stopped.

1.3.8.5 Hypotony

Acute inflammation of the ciliary body may cause hyposecretion of the aqueous and low IOP. This reduction is reversible with the control of inflammation. Chronic inflammation may lead to ciliary body damage and with atrophy of ciliary processes resulting in permanent hypotony. Chronic hypotony is defined as IOP < 5 mmHg for at least one month and is usually associated with serous choroidal detachment which

may require surgical drainage. Removal of inflammatory membranes that are causing traction on the ciliary body (cyclitic membrane) may help reverse hypotony if the ciliary body processes are still intact. However, when there is damage to these process vitrectomy and injecting silicone oil may help increase the IOP and preserve the ocular anatomy. Some of these patients may experience a substantial visual improvement, but it's transient because half of them will redevelop hypotony and need reinjecting with silicone oil several times per year (De Smet, Gunning et al. 2005, Kapur, Birnbaum et al. 2010).

1.3.8.6 Epiretinal membrane ERM

Epiretinal membrane (macular pucker), refers to a fibrocellular proliferation at the vitreoretinal interface above the internal limiting membrane (Cheung, Tan et al. 2016). It can be classified on its severity into cellophane maculopathy in the early stage or premacular fibrosis in the advanced stage. The latter appears when the initial membrane thickens and contracts, becoming more opaque, and can cause vision impairment in up to 80% of patients and appears as retinal folds and traction lines with vascular tortuosity (Stevenson, Ponce et al. 2016).

ERM can occur in many conditions including proliferative retinopathies, ocular inflammatory diseases, non-proliferative retinal vascular disorders, after vitreous haemorrhage, after blunt and penetrating ocular injuries, in association with rhegmatogenous retinal detachment, after retinal photocoagulation, and idiopathic in otherwise healthy eyes. In all of the previously mentioned causes, the membrane is avascular except the one associated with proliferative retinopathies (Kenyon, Pederson et al. 1975).

Different cell types have been reported to cause epiretinal membranes, however, fibrous astrocytes are the most commonly involved cells in eyes with pars planitis (Kenyon, Pederson et al. 1975). Other cells derived from the RPE are also believed to be involved in the formation of epiretinal membrane especially in cases with proliferative vitreoretinopathy following rhegmatogenous retinal detachment (Clarkson, Green et al. 1977). Other cells types include fibroblast, myofibroblast, hyalocytes, macrophages and inflammatory cells (Green, Kenyon et al. 1979).

These membranes usually exert traction on the retina beneath and cause deformation of the retinal architecture (Watanabe, Arimoto et al. 2009). The visual acuity can be reduced when these membranes cover or distort the fovea or causing tractional detachment of the macula. (Kampik, Kenyon et al. 2005). Initially, the patient is asymptomatic, however, when the membrane progresses patients usually present with mild impairment of central visual acuity, metamorphopsia (straight lines appear wavy) and micropsia (objects appear smaller due to stretching of the photoreceptors cell layer) (Kempen, Altaweel et al. 2010).

ERM is a prevalent complication in uveitis, with over 40% of patients showing evidence of ERM on imaging in at least one eye. It is most commonly associated with intermediate uveitis, posterior and panuveitis with 57% and 43% respectively, followed by anterior uveitis 28% (Nicholson, Zhou et al. 2014). Epiretinal membrane is a frequent complication and cause of vision loss among uveitic patients particularly those with intermediate uveitis (Malinowski, Pulido et al. 1993). A study by Tomkins and co-workers reported that ERM was the third most common cause of moderate vision loss (6/15-6/36) among uveitis patients after chronic CMO and macular scarring (Tomkins-Netzer, Talat et al. 2014). Also, in the same study, ERM has been reported to cause severe vision loss ($VA \leq 6/60$) in 1% of cases.

The diagnosis of ERM can be made clinically when examining the posterior fundus, it appears a thin transparent membrane overlying the macula. Amsler charts (patients looks at a square with parallel crossing lines and appreciate any deformities in these straight lines) are useful in monitoring these. OCT is more sensitive in detecting ERM, on OCT, ERM appears as a hyperreflective band on the inner surface of the retina and causes increased retinal thickness. OCT can also visualize secondary complications related to ERM such as macular oedema secondary to foveal traction, macular detachment or the presence of vitreomacular traction (Stevenson, Ponce et al. 2016).

Visually significant membranes can be treated surgically with pars plana vitrectomy and internal limiting membrane peel with favourable outcomes in the vast majority of patients (de Bustros, Rice et al. 1988, Dev, Mieler et al. 1999).

1.3.8.7 Retinal detachment RD

Retinal detachment refers to the separation of the neurosensory retina from the underlying retinal pigment epithelium. There are several types of retinal detachment depending on the aetiology namely serous RD, rhegmatogenous RD and tractional RD. Serous retinal detachment occurs in many infective or autoimmune ocular conditions. VKH and posterior scleritis, for example, are usually associated with serous retinal detachment. Rhegmatogenous retinal detachment (RRD) occurs in 3% of patients with uveitis with panuveitis and infectious uveitis being the most common entities associated with RRD. However, pars planitis and posterior uveitis can also lead to tractional rhegmatogenous retinal detachment. Usually, eyes presenting with RRD still have active uveitis, and at diagnosis up to 30% of uveitic patients with RRD also have proliferative vitreoretinopathy (PVR). This percentage is significantly higher than those presenting with RRD but without uveitis. Surgical repair is often challenging and is complicated by pre-existing PVR, vitreous membranes and poor view. Viral retinitis is frequently associated with a retinal detachment that resists barrier lasers due to the presence of large posterior breaks and may benefit from vitrectomy and silicone oil tamponade (Kerckhoff, Lamberts et al. 2003).

1.3.8.8 Phthisis bulbi

Phthisis bulbi is an end-stage disease when the eye becomes shrunken, non-functional with disorganisation of the eyeball contents. It can result from severe, uncontrolled complicated inflammation among other causes such as injury. Treatment is usually by enucleation and prosthesis (Kanski and Bowling 2011).

1.3.9 Infectious causes of intraocular inflammation

Bacterial, fungal, protozoan and viruses all can cause uveitis.

1. Tuberculosis
- 2. Toxoplasmosis**
3. Syphilis
4. Borreliosis (Lyme disease)
5. Toxocara
6. Herpes viruses (Simplex, Zoster, Cytomegalovirus (CMV))

7. Bartonella (cat scratch disease)
8. Candidiasis

Apart from toxoplasmosis, all the other infectious aetiologies are out of the scope of this research and therefore will not be discussed.

1.3.9.1 Toxoplasmosis

Ocular toxoplasmosis is the leading cause of infectious posterior uveitis worldwide and a significant cause of visual impairment and blindness (Bosch-Driessen, Berendschot et al. 2002). Toxoplasma retinochoroiditis (TRC) is a potentially blinding disease, with legal blindness in at least one eye in 24% of patients in a large series of patients with ocular toxoplasmosis. Recurrences are the hallmark of this disease and recurrence rate can be as high as 79 % in patients followed-up for more than five years (Bosch-Driessen, Berendschot et al. 2002).

The specific age at onset of toxoplasmosis remains unknown since most patients with acute eye disease at presentation have already had inactive retinal scars. These acute episodes present with photosensitivity, floaters and reduced vision to a variable degree. These disease occurrences usually resolve in 6-8 weeks leaving a chorioretinal scar behind and may be associated with chronic complications such as persistent vitreous opacities and epiretinal membrane. However, permanent visual loss occurs if the disease involves the vision-critical structures such as the fovea and the optic nerve (Kim, Scott et al. 2013). The lifetime risk of symptomatic TRC varies considerably in the literature and depends on the geographic location. In the UK it's estimated to occur in 18 per 100,000 natives (95% CI confidence interval 18.8 -25.2), but it can be as high as 382 of 100,000 people born in West Africa (95% CI 99-664) (Gilbert, Dunn et al. 1999).

1.3.10 Non-infectious (autoimmune) causes of intraocular inflammation

1.3.10.1 Diseases with ocular and systemic involvement

1.3.10.1.1 Sarcoidosis

Sarcoidosis is a granulomatous disease of unknown aetiology it affects multiple systems but with more frequent respiratory manifestations (90%) (Sharma 1984). Other areas that are frequently involved are lymph nodes, skin, CNS and joints. Ocular manifestations may present in 50% of patients with a systemic disease, with uveitis being the most common ocular presentation (Crick, Hoyle et al. 1961, Rothova, Alberts et al. 1989). In a large series, it was reported that 10% of all uveitis patients had sarcoidosis. The primary histological lesion in sarcoidosis consists of non-caseating granuloma without evidence of infection or foreign body.

Sarcoidosis affects all ethnic groups and has a worldwide distribution, with a highest prevalence in Northern European countries (40 cases per 100,000 inhabitants) (Fernandez Fabrellas 2007, Deubelbeiss, Gemperli et al. 2010). In the US the disease is 20 times more common among African Americans than their white counterparts (Hunter and Foster 1999). Sarcoidosis affects both sexes, but it is slightly more common in females than males (Jabs and Johns 1986). The peak disease onset occurs between 20-50 years. In a recent review sarcoidosis was reported frequently in patients over 60 years old, and later onset disease tends to have more ocular manifestations and less systemic and chest x-ray findings compared to younger patients.

There is no identified causative agent responsible for this disease at present, and many environmental, infectious and genetic factors have been described. However, molecular studies of histological samples suggest a mycobacterial aetiology with propionibacteria as the offending microbe. Also, genetic susceptibility is another possibility since sarcoidosis tends to occur in families; siblings of patients have a fivefold increased risk of disease development.

Studies have shown that in sarcoidosis there is an increase in the number of activated T cells (CD4), immunoglobulin and IgG-secreting cells along with a reduction in the number of CD8 cells which lead to increased CD4/CD8 ratio.

There are several clinical courses in sarcoidosis. Systemic onset is usually associated with anterior uveitis in young patients and resolves spontaneously within two years. Another form of acute sarcoidosis is the Löfgren syndrome, presenting with erythema nodosum, joint involvement with fever, bilateral hilar lymphadenopathy and acute anterior uveitis. This form is very susceptible to systemic corticosteroids and has an excellent long-term prognosis. Heerfordt disease (uveoparotid fever) is featured by uveitis, parotitis and facial nerve palsy (Obenauf, Shaw et al. 1978). Chronic sarcoidosis has a gradual onset and persists for more than two years, and requires extended corticosteroids therapy (Jabs and Johns 1986).

Sarcoidosis affects the eye and its adnexa in 25%-80% of patients (Bonfioli and Orefice 2005), with anterior uveitis whether acute or chronic being the most common presentation (occurring in two-thirds of patients with ocular sarcoidosis). Typical findings include mutton fat KPs, Figure 1-11, Koeppe and Busacca nodules on the iris and white aggregates of cells in the inferior vitreous. Extensive posterior synechiae and iris bombe may develop leading to secondary glaucoma, and this usually carries a poor prognosis and lead to profound vision loss. Likewise, chronic posterior segment disease tends to lead to a poor visual outcome (Dana, Merayo-Llives et al. 1996).

Posterior segment involvement occurs in up to 20% of patients with ocular sarcoidosis. Vitreous snowballs are common and may be associated with cellular infiltration into the vitreous and form linear strands (string of pearls). Nodular granulomas on the optic nerve, retina and choroid, perivascular sheathing appearing as linear or segmental periphlebitis are also common. Periphlebitis is focal fluffy white cuffing of retinal veins, it is a common feature in sarcoidosis, present in 67% of patients and is associated with focal leakage of fluorescein (Graham, Stanford et al. 1989). Figure 1-12. Irregular nodular granulomas can occur along the course of venules (called candle wax drippings) (Kanski and Bowling 2011). Figure 1-13. Sarcoidosis can lead to vascular occlusion such as, branch or less commonly central retinal vein occlusion, together with peripheral capillary dropout, which may result in retinal neovascularization and subsequent vitreous haemorrhage. CMO is frequently seen (Steahly 1988).

Sarcoidosis should be suspected in all patients with ocular inflammation since it has different presentations. Chest radiographs abnormalities mainly hilar lymphadenopathy are present in 90% of patients. High resolution computed

tomography (CT) is superior to chest X-ray, and it is the imaging modality of choice when there is a high clinical suspicion of sarcoidosis in the presence of a normal chest x-ray. Serum ACE and lysozyme enzymes help in the diagnosis as they reflect total body granuloma content. Finally, obtaining a tissue specimen is the gold standard diagnostic tool (Kanski and Bowling 2011).

The mainstay treatment for ocular disease in sarcoidosis is corticosteroid, and these are either topical, or periocular or systemic. Systemic corticosteroid are usually required for sight-threatening posterior segment disease. Local steroids are useful for the ocular disease but will leave the systemic disease uncontrolled. Sarcoid is generally responsive to corticosteroids but patients require long-term corticosteroid-sparing agents such as methotrexate, azathioprine mycophenolate mofetil or cyclosporine to minimize the systemic side effect of corticosteroids. Lately, TNF α blockers are being increasingly used to treat sarcoid resistant uveitis.

Figure 1-11 Mutton fat KPs on the inner surface of the cornea in patients with sarcoid uveitis.
Source Moorfields Eye Hospital

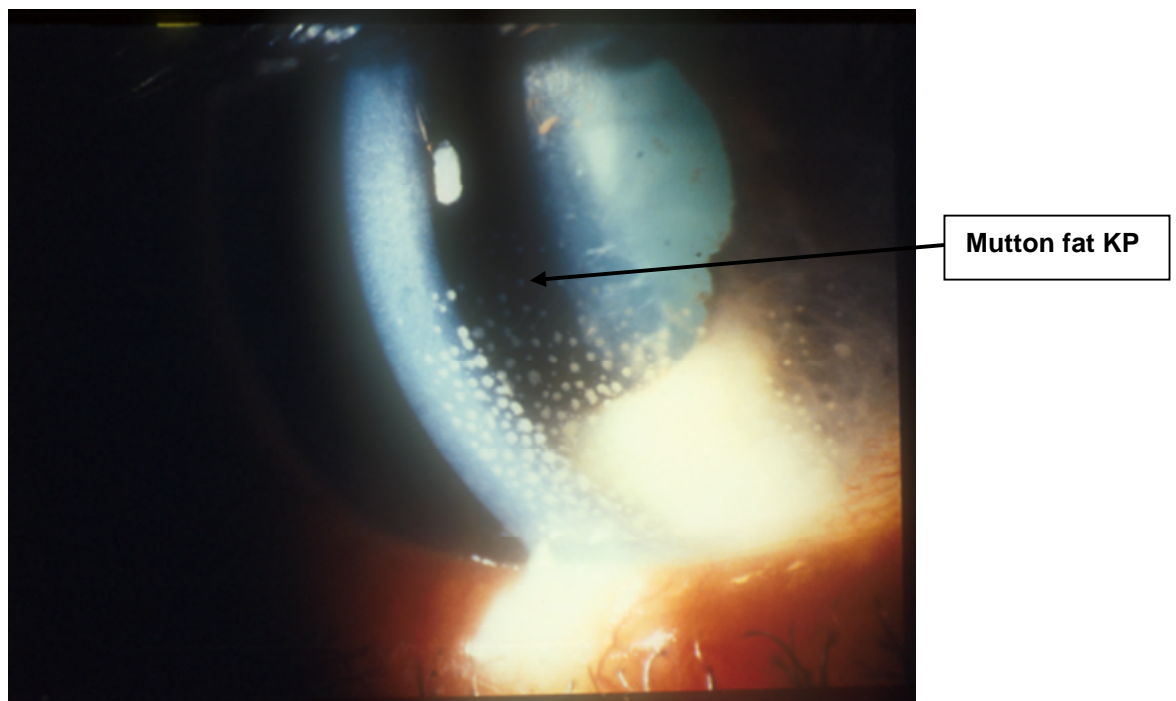


Figure 1-12 Focal periphlebitis (TOP) fluorescein leakage on dye test (BOTTOM) Focal periphlebitis in sarcoidosis. Source Moorfields Eye Hospital

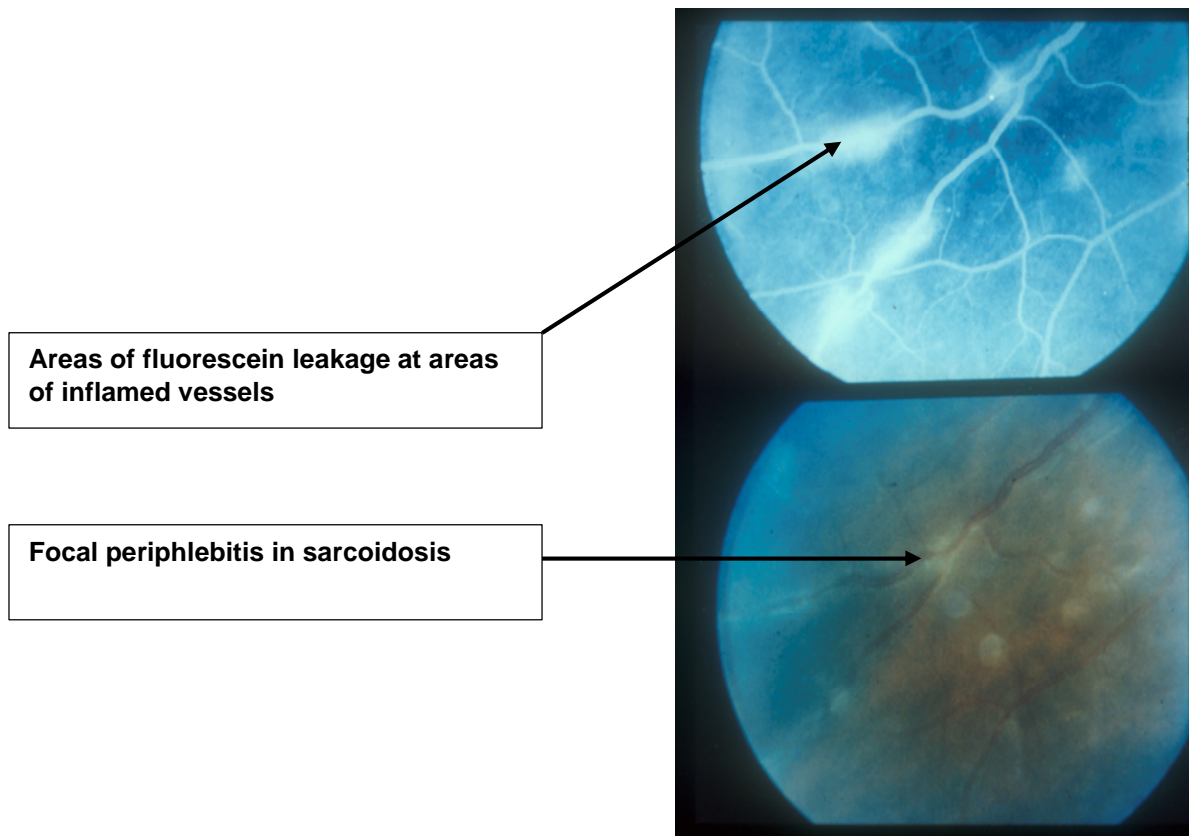
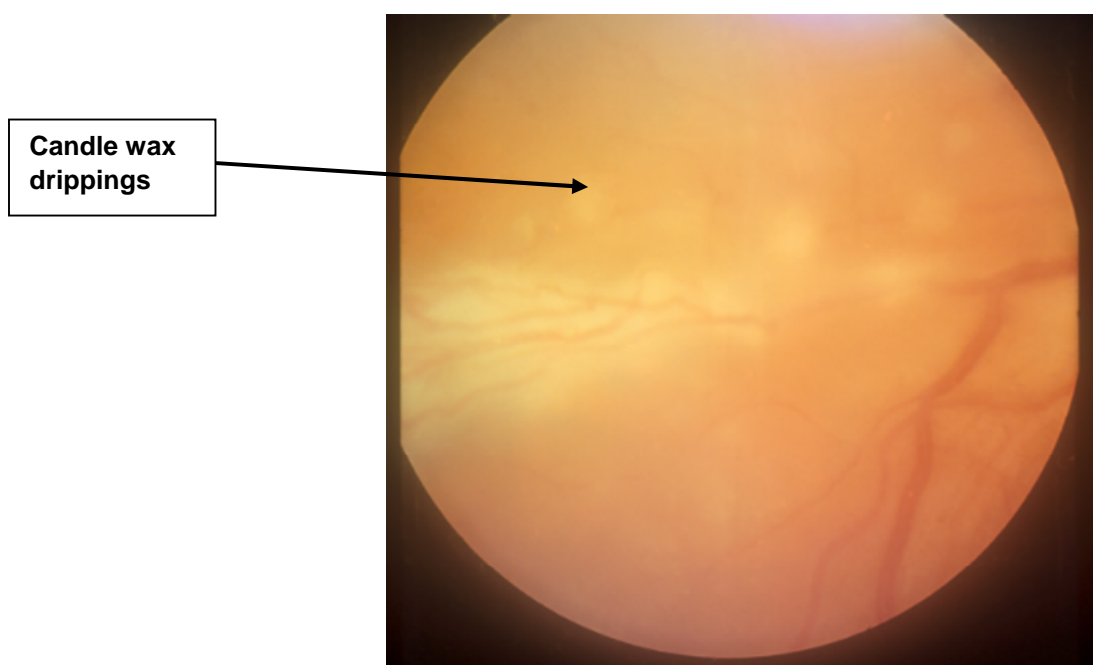


Figure 1-13 Candle wax drippings (extensive periphlebitis in sarcoid associated vasculitis). Source Moorfields Eye Hospital.



1.3.10.1.2 Behcet's disease

Behcet disease (BD) is a chronic relapsing multisystemic inflammatory disorder of unknown aetiology. This disease is characterised by occlusive vasculitis and affects young to middle age individuals, particularly men. Patients classically present with a triad of recurrent oral and genital aphthous ulcers, skin lesions (folliculitis, erythema nodosum), and uveitis. Other disease manifestations include arthritis, gastrointestinal and neurological (Esatoglu, Kutlubay et al. 2017).

It has a worldwide distribution, however, the prevalence of BD has a geographical variation. Behcet disease is more prevalent in the Mediterranean basin and the Far East. It is estimated to be as high as 80-300 cases per 100,000 in Turkey and 8-10 cases per 100,000 in Japan whereas in the US it is estimated at 0.4 cases per 100,000 inhabitants (Evereklioglu 2005). It is characterised, in part, by uveitis which affects both anterior and posterior segments of the eye, it is bilateral in 86% of patients (Namba, Goto et al. 2015). The typical age of onset is between 25-35 years; however, it has been reported that BD also develops as early as 10-15 years (Tugal-Tutkun, Onal et al. 2004).

BD has a strong association with the HLA-B51 gene, but this is not diagnostic. The International Study Group for Behcet disease proposed the diagnostic criteria for BD in 1990. The diagnosis requires recurrent oral ulceration as a main symptom, as well as two of the following symptoms (genital ulceration, eye lesions, skin lesions and a positive pathergy test) (Wechsler and Davatchi 1990). Similarly, the Behcet Disease Research Committee Japan has defined disease criteria into major and minor. Based on this classification, patients will be categorised as having complete, incomplete Behcet or being disease suspect. Please see Table. 1-8 below. (Suzuki Kurokawa and Suzuki 2004).

Table 1-8 Diagnostic System for Behcet Information from Behcet disease Research Committee of Japan. Behcet disease: a guide to the diagnosis of Behcet disease. Jpn J Ophthalmol. 1974;18:291-294

Diagnostic System for Behcet's disease
<p>Major criteria</p> <ul style="list-style-type: none"> • Recurrent oral aphthous ulcer • Skin lesions(erythema nodosum, acneiform pustules, folliculitis) • Recurrent genital ulcers • Ocular inflammatory disease <p>Minor criteria</p> <ul style="list-style-type: none"> • Arthritis • Gastrointestinal ulceration • Epididymitis • Systemic vasculitis or associated complications • Neuropsychiatric symptoms <p>Types of Behcet disease</p> <ul style="list-style-type: none"> • Complete (4 major criteria) • Incomplete (3 major criteria) • Suspect (2 major criteria with no ocular involvement) • Possible (1 major criterion)

1.3.10.1.2.1 Clinical manifestations

In general, inflammatory eye disease develops after oral ulceration, which is the most frequent finding in BD, and it is present in around 70% of patients in Japan (Namba, Goto et al. 2015). Patient suffers from recurrent painful mucosal ulcers which appear on the lips, tongues and palate and have a white base with an erythematous rim. These ulcers reappear every 5-10 days and last for about 7-10 days. Skin lesions include recurrent erythema nodosum (which could be tender), acne vulgaris or folliculitis (frequently appears on the upper chest or face). Around 40% of patient develop a positive pathergy test (a sterile pustule at the site of needle prick or venepuncture but it is not pathognomonic for Behcet disease. Genital ulcers leave scars and may occur even without acute symptoms (Evereklioglu 2005).

Systemic vasculitis develops in 25% of patients and it could involve any artery or vein in the body. Systemic vasculitis can be complicated by arterial occlusion or aneurysm, and venous occlusion, varices and thrombosis. Gastrointestinal ulceration is also frequent, and pulmonary involvement can present as aneurismal dilation of the pulmonary artery. Arthritis develops in 50% of patients, with the knee being the most commonly affected joint. Neuro-Behcet is the most serious among all other presentations and may occur in 10% of patients, but this increase to 30% in those with ocular involvement. Neuro-Behcet mainly involves the motor control, and it may also present as a headache due to widespread cerebral vasculitis. The mortality rate is 10% in patients with neuro-Behcet, but the introduction of immunomodulatory therapy had led to a lower mortality rate. Neuro-ophthalmic involvement includes cranial nerve palsies, central scotoma and visual field defects caused by papilitis or papilledema which is caused by increased intracranial pressure secondary to superior sagittal sinus thrombosis or other sinuses (Evereklioglu 2005).

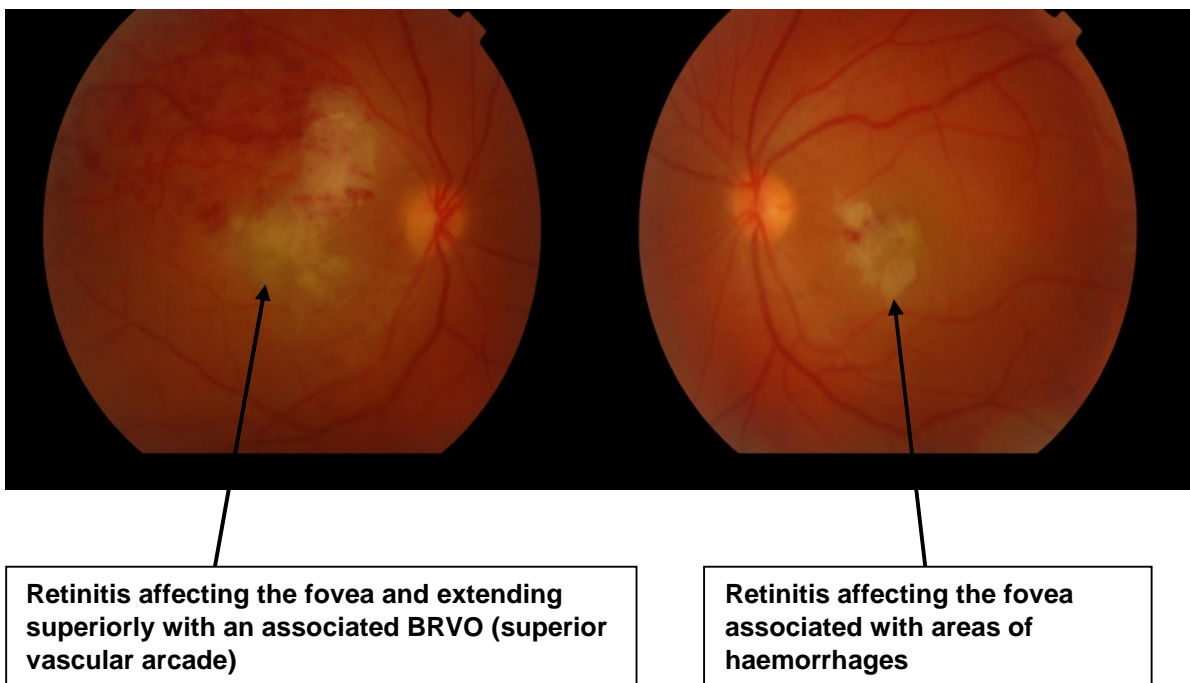
1.3.10.1.2.2 Ocular manifestation

Ocular manifestations occur in 70% of patients with Behcet disease. They bear severe consequences because they result in permanent damage to the ocular tissue. Because of the aggressive and recurrent nature of these relapses (Verity, Wallace et al. 2003), severe vision loss can occur in 25% of patients. Men tend to be affected more than women and have a more aggressive disease course (Tugal-Tutkun, Onal et al. 2004), and a higher risk of sight loss (Kitaichi, Miyazaki et al. 2007). The intraocular inflammation is necrotising non-granulomatous occlusive vasculitis which can involve any or all portions of the uveal tract (Holland, O'Connor et al. 1996).

Anterior uveitis in Behcet disease includes recurrent iridocyclitis with or without hypopyon. The hypopyon is transient and occurs in 25% of patients. The frequent symptoms are redness, light sensitivity and blurred vision. The hypopyon can shift with patients head movement, and severe episodes of inflammation can lead to the development of anterior and posterior synechia, with angle closure glaucoma. The course of BD is of explosive nature, and can develop over a few hours (Kitaichi, Miyazaki et al. 2007).

Behcet disease has a high propensity to involve the posterior segment of the eye, and can be extremely sight-threatening (Atmaca 1989). The two most commonly encountered complications are branch retinal vein occlusion (BRVO) with ischaemia and CMO. BRVO is a significant factor for visual morbidity ($P < 0.001$) (Graham, Stanford et al. 1989, Okada 2000, Sakane and Takeno 2000). Behcet disease associated posterior and panuveitis are the most significant risk factors for sight loss. Visual impairment in one or both eyes occur in a high proportion of patients (82%) and legal blindness ($VA < 6/60$) is reported in about 25% of cases (Kaçmaz, Kempen et al. 2008). In addition to branch retinal vein occlusion (BRVO), a branch retinal artery occlusion or combination of both can develop, and vascular sheathing with vitritis, retinitis with retinal haemorrhages (Namba, Goto et al. 2015). BRVO was documented in 64% of patients with ocular BD and severe vision loss was significantly associated with BRVO at the macula. Intraretinal infiltrates are a unique finding in Behcet's eye disease (33%), and they appear as white deep retinal infiltrate in the absence of infection (Graham, Stanford et al. 1989), and are usually associated with adjacent retinal haemorrhages (El-Asrar, Herbort et al. 2010). Figure 1-14.

Figure 1-14 Posterior segment finding in Behcet's disease, areas of retinitis at the fovea in both eyes. RE (left side image) superior branch retinal vein occlusion (BRVO). Source Moorfields Eye Hospital.



The increased frequency of ocular attacks showed a significant negative correlation with the final visual acuity (Takeuchi, Kezuka et al. 2014). The three main factors that lead to poor visual outcome are; an average of three or more relapses per year, exudates within the retinal vascular arcade, and dense vitreous opacities (Takeuchi, Hokama et al. 2005). Similar findings reported in another study, where poor final visual outcomes were associated with recurrent ocular attacks, which were observed in 54% of patients over ten years follow-up (Kaburaki, Araki et al. 2010). In the latter study, the main reason for poor vision was ischemic retinochoroidal atrophy at the macula.

Retinal ischaemia due to occlusive vasculitis can lead to neovascularization of the retina and the iris with resultant vitreous haemorrhage and neovascular glaucoma. Following recurrent attacks of retinal vasculitis and closure of retinal vessels, these vessels will appear white and sclerotic. Finally, the optic nerve is involved in 25% of patients in the form of papillitis. However, progressive optic atrophy ensues after repeated attacks of occlusive vasculitis affecting arterioles around the optic nerve head (O'Connor 1982).

Disease complications such as vitreous haemorrhage, retinal detachment, retinal or optic disc neovascularization often require complex medical and surgical management, and they have a significant impact on the final visual acuity. The presence of posterior synechia, hypotony, persistent disease activity and increased ocular pressure are poor prognostic factors for final visual acuity (Kaçmaz, Kempen et al. 2008).

Therefore, the aim of treating Behcet patients is to achieve rapid control of ocular inflammation and prevent future disease relapses to help preserve vision (Hatemi, Silman et al. 2008). To this aim, early treatment with corticosteroids and a second-line immunosuppressive agent is warranted. Classical treatment involves a combination of corticosteroids and second line immunosuppressive agent such as azathioprine and cyclosporine, but with variable response.

The diagnosis is clinical and based on the international criteria. Laboratory testing for inflammatory markers, HLA typing and the pathergy test are of little diagnostic value. FFA reveals diffuse retinal vascular leakage, occlusion and dilation of involved vessels

which stain late in the angiogram. Also, disc leakage, macular oedema, areas of capillary non-perfusion and neovascularization can be shown on the angiogram (Atmaca 1989). Faint vascular leakage can precede disease activity and may help with adjusting the therapy and aborting an inflammatory attack. OCT shows structural alterations such as macular oedema and disruption of retinal layers in response to vascular occlusion and ischaemia.

Several clinical and laboratory data suggest a crucial role for TNF α in Behcet disease pathogenesis. For example, there are increased levels of TNF α , TNF α soluble receptors, TNF α producing cells in the peripheral blood of patients with active Behcet disease, and the levels of TNF α , IL2, 6 and 8 correlates with disease activity (Turan, Gallati et al. 1997, Evereklioglu, Er et al. 2002). Ocular fluid samples from patients with active Behcet disease showed increased levels of several pro-inflammatory cytokines, such as interferon- γ , (IL-2, -6 and -17), and TNF α , whereas, in anti-TNF α treated patients these inflammatory markers were undetected (Sugita, Kawazoe et al. 2012). Additionally, the authors reported that active CD4+T cells were producing a large amount of TNF α and IL-17 before infliximab, while failed to do so after infliximab therapy. Moreover, Th17 cells exposed to infliximab significantly failed to produce IL-17. The authors believed that TNF α blockers effectively suppress the differentiation of the effector T cells, particularly T helper 17, in Behcet disease related uveitis.

The efficacy and safety of anti-TNF α agents have been reported in the treatment of refractory cases of Behcet disease (Hatemi, Silman et al. 2008) (Vitale, Emmi et al. 2017). However, due to the accumulating evidence regarding the superior efficacy of anti-TNF α in Behcet disease patients, recently, an expert panel recommended TNF α blockers as first, or second-line treatment, in Behcet uveitis (Levy-Clarke, Jabs et al. 2014).

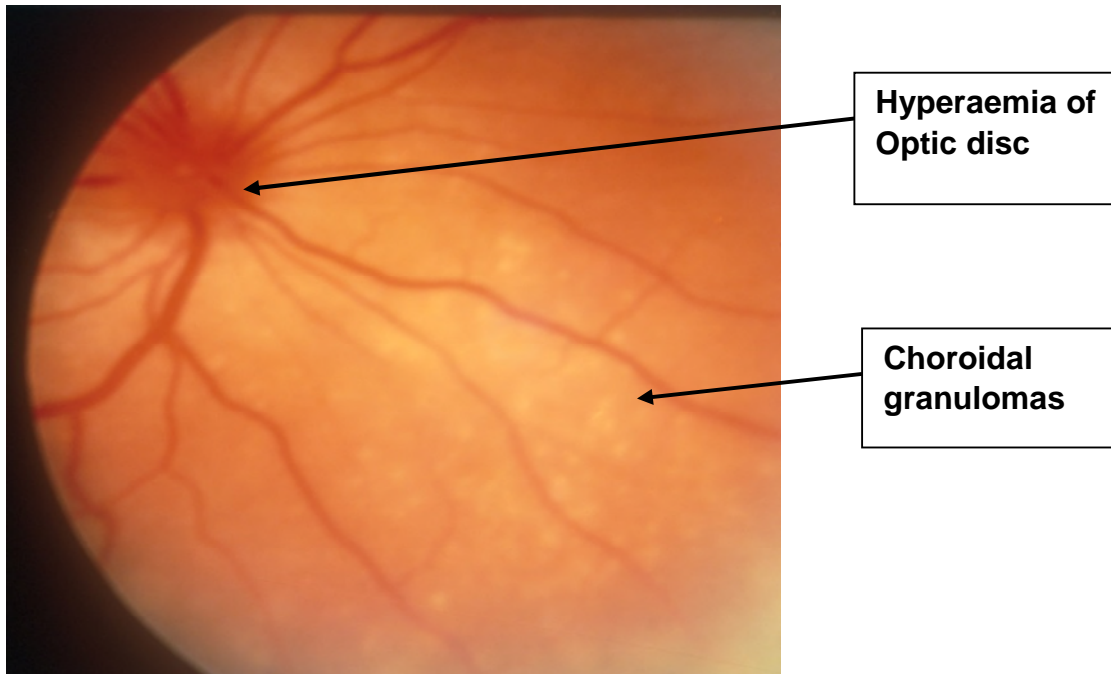
1.3.10.1.3 Vogt-Koyanagi-Harada disease (VKH)

VKH is an idiopathic inflammatory disease when an autoimmune reaction, triggered by genetic factors, is set against the melanocytes. The ocular presentation is of bilateral granulomatous panuveitis combined with exudative retinal detachment, Figure 1-15, and hyperaemic optic discs, Figure 1-16. There are extraocular signs associated with this disease such as auditory, meningeal and cutaneous manifestations. The CNS signs include headache, signs of meningeal irritation and rarely focal neurological signs with CSF pleocytosis (abnormal increase in CSF lymphocytes). The auditory signs include tinnitus and hearing loss. The cutaneous manifestations may develop during the chronic phase of the disease, and they include vitiligo, alopecia and poliosis (whiting of the eyelashes, eyebrows and scalp hair). High dose corticosteroid is initially used, then a second-line immunosuppressive agent is added. However, a chronic recurrent course may develop after the acute attack resulting in loss of melanocytes and a characteristics sunset glow fundus appearance. With recurrent inflammation, there is a high risk of ocular complications including cataract, glaucoma, CNV, and subretinal fibrosis (Moorthy, Inomata et al. 1995).

Figure 1-15 Extensive serous retinal detachment in VKH disease. Photo courtesy of professor Lightman. Source Moorfields Eye Hospital.

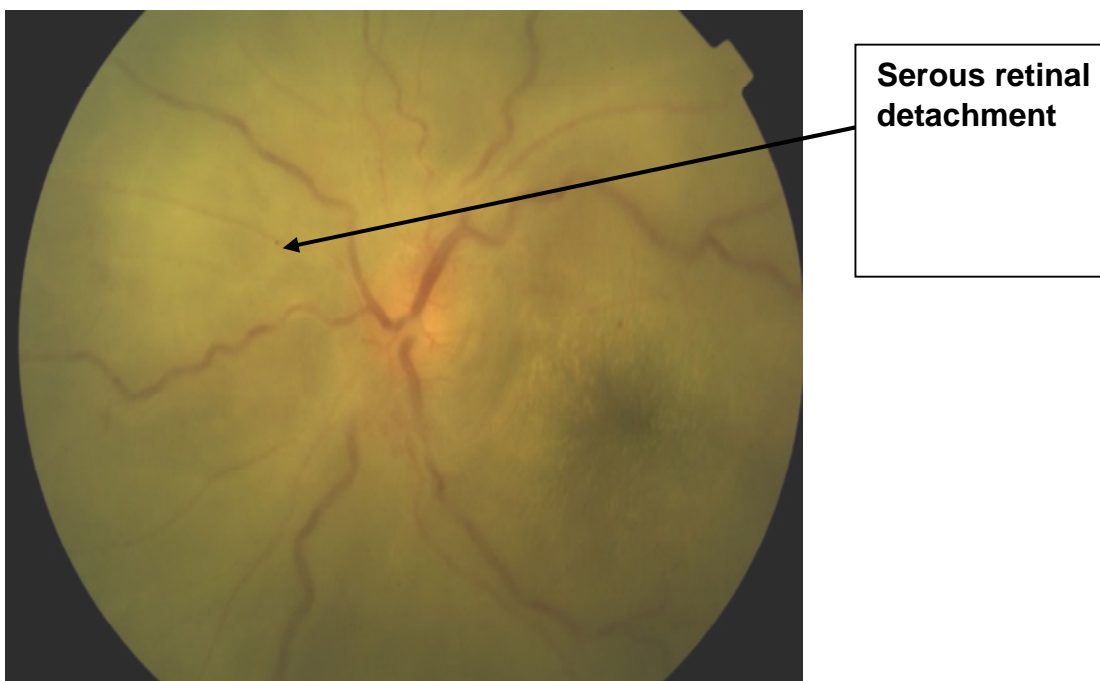

Figure 1-16 Disc hyperemia in VKH disease Photo courtesy of professor Lightman. Source Moorfields Eye Hospital.



1.3.10.1.4 Multiple sclerosis (MS)

Multiple sclerosis is a chronic inflammatory disease of the central nervous system, with more than 2 million people being affected worldwide; It is three times more common in females compared to males (Reich, Lucchinetti et al. 2018). The disease is characterised by recurrent episodes of neurological disability which could be partially or wholly reversible with episodes usually lasting between few days to several weeks. The typical presentation of the disease includes optic neuritis resulting in monocular vision loss, limb weakness and sensory disturbance due to transverse myelitis, ataxia due to cerebellar lesions or double vision due to brainstem dysfunction. However, after 10-20 years a progressive clinical course ensues in many patients leading to the impairment of the mobility and cognition. 15% have a progressive course at the disease onset (Brownlee, Hardy et al. 2017).

The diagnosis of MS is based on demonstration of plaque-like sclerotic lesions that are disseminated in time and space. The documentation of the evolution of this disease over-time was made possible by the advent of modern technologies such as MRI and immunohistochemistry. The MS lesions can involve any part in the CNS.

However, it's more easily identified in the white matter region as areas of demyelination and inflammation. The tissue damage in MS is a consequence of a complex and dynamic interaction between the immune system, glia (myelin synthesising cells (oligodendrocytes and their precursors, astrocytes and microglia) and neurons (Reich, Lucchinetti et al. 2018).

Helper CD4+ and Cytotoxic CD8+ T cells have both been identified in MS lesions (Lassmann 2014), and drugs that restrict the access of T cells to the CNS have reduced the development of new MS lesions (Reich, Lucchinetti et al. 2018). B-cells are also implicated in the pathogenesis of MS and antibody depleting B cells was successful in reducing new MS lesions and clinical disease activity. The role of B cells in MS lesion can be attributed to a particular type of antibody production (oligoclonal band). Moreover, other functions of B cells such as antigen presentation to T helper cells and cytokines production can also contribute to the formation of MS lesions. Finally, blood-borne macrophages are implicated in disease pathogenesis. Macrophages reach CNS to engulf myelin debris and inflammatory by-products in inflammatory sites (Michel, Touil et al. 2015, Reich, Lucchinetti et al. 2018).

Another factor in MS development is abnormal vascular permeability. In experimental autoimmune encephalitis EAE (an animal model of demyelination similar to MS) the first step in disease development was vascular leakage (Maggi, Macri et al. 2014) a similar finding reported in humans with MS (Absinta, Nair et al. 2015).

The ocular manifestations of MS patients may be the first presenting sign of this disease. These include anterior uveitis, intermediate uveitis (snowballs), retinitis, periphlebitis and optic neuritis, Figure 1-17 (Engell and Andersen 1982, Arnold, Pepose et al. 1984, Graham, Francis et al. 1989, Vine 1992, Towler and Lightman 2000). Retinal periphlebitis is the most common ocular manifestation in MS patients with a prevalence of 11.5 %. Figure 1-18. These lesions can progress to vascular occlusion, ischaemia and neovascularization (Towler and Lightman 2000). The presence of retinal vascular sheathing is a strong predictor to future MS development with a relative risk of 14.4 (Lightman, McDonald et al. 1987).

Figure 1-17 Ocular manifestations in MS Optic neuritis with optic nerve head involvement.
Source Moorfields Eye Hospital.

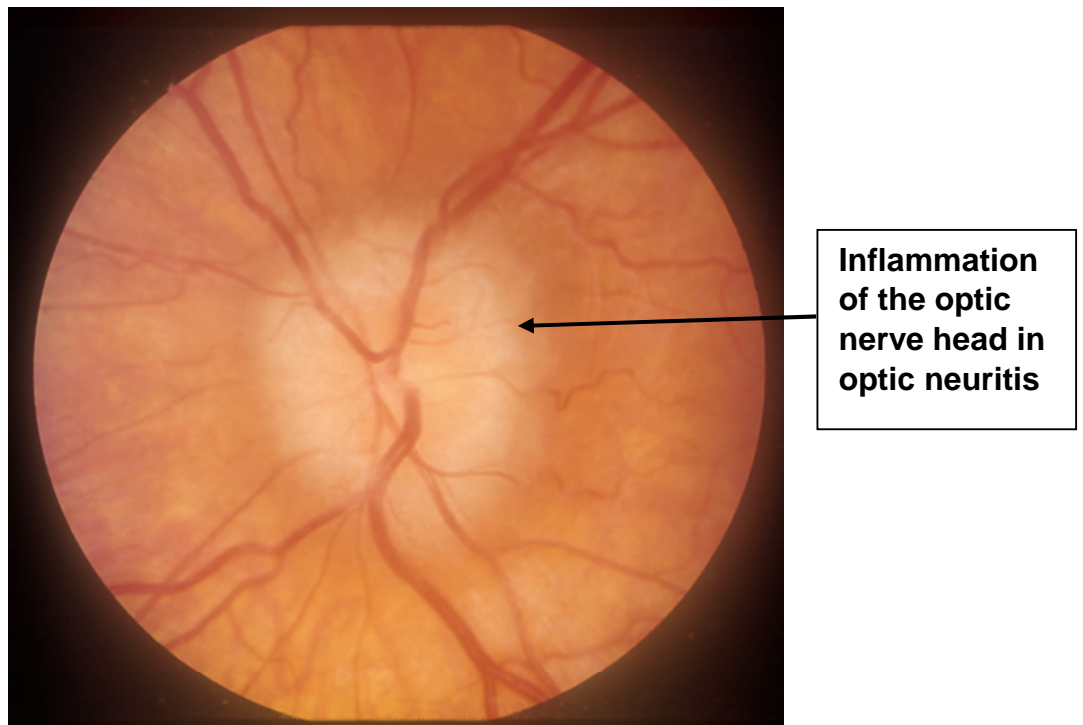
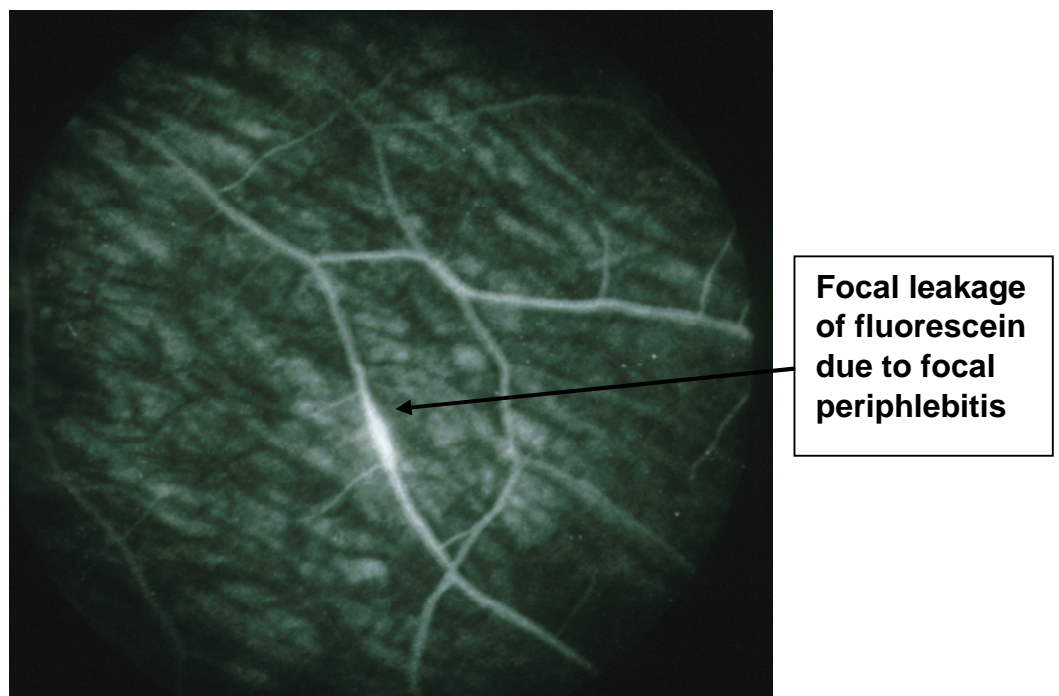


Figure 1-18 Focal periphlebitis in MS with fluorescein leakage on dye test. Photo courtesy of professor Lightman. Source Moorfields Eye Hospital.



1.3.10.1.5 Granulomatosis with polyangiitis (Wegner's granulomatosis)

GPA is a granulomatous necrotising vasculitis affects the upper and lower respiratory tract primarily. If untreated it carries a high risk of mortality. The definitive diagnosis can be made by demonstrating inflammation and necrosis of small and medium vessels with granuloma formation (Haynes, Fishman et al. 1977). Laboratory tests help to confirm the diagnosis and may reveal increased ESR, positive rheumatoid factor and c ANCA (antineutrophil cytoplasmic antibody) being the most sensitive and specific test to confirm the disease (Jayne, Gaskin et al. 1995). The eye is commonly involved and up to 60% of affected patients present with orbital inflammation, retinal vasculitis and ischemic optic neuropathy. Anterior segment findings include scleritis, episcleritis, conjunctivitis and peripheral ulcerative keratitis (Haynes, Fishman et al. 1977).

1.3.10.1.6 Idiopathic retinal vasculitis

Retinal vasculitis is an inflammatory disorder of the retinal blood vessels, and it is usually associated with inflammation of the uveal tract and the vitreous. It could be idiopathic or more commonly associated with infections such as TB, toxoplasmosis and viral retinitis. Other causes that lead to retinal vasculitis include neoplastic and inflammatory disorders such as, MS. Systemic vasculitis such as Behcet disease, and sarcoidosis can present with retinal vasculitis. Ocular inflammatory disease such as Birdshot chorioretinopathy, IU and panuveitis also present with retinal vasculitis (Palmer, Zaman et al. 1995). In this section will discuss primary (idiopathic) retinal vasculitis. Primary retinal vasculitis by definition is not associated with systemic vasculitis or systemic inflammation. It is much less frequent than secondary retinal vasculitis due to Birdshot and other causes, and most commonly seen in young adults with women more affected than men. Because the retinal capillaries are frequently involved with the loss of the integrity of endothelial tight junctions there will be leakage of fluid and CMO with subsequent loss of vision. Macular oedema was documented in 60% of patients with idiopathic retinal vasculitis (Graham, Stanford et al. 1989).

Inflammation usually causes perivascular sheathing, and this represents an inflammatory cell infiltration in the perivascular space. Diffuse capillary leakage and CMO are also signs of active disease on FFA. Subsequently, perivascular scarring develops following active disease, and this is evident by a clearer and smoother outline

of perivascular sheathing and usually accompanied by atrophy of the RPE and outer retinal layers and scarring. Some patients will develop vessel shutdown and ischaemia. The presence of retinal and disc neovascularization increases the risk of recurrent vitreous haemorrhage, retinal detachment and neovascular glaucoma (Jones and Jones 2012).

The diagnosis of retinal vasculitis is made by fundoscopic examination which shows retinal vascular sheathing and leakage which is confirmed by fluorescein angiography. Sheathing of the retinal vessels was the most common finding in association with isolated retinal vasculitis. Vitritis usually accompanies retinal vasculitis and sometimes anterior uveitis is also present. Retinal ischaemia, neovascularization and vitreous haemorrhage are well-recognised complications of this disease.

Although primary retinal vasculitis is apparently a disease that is confined to the eye, there is evidence to support a systemic vasculitic process is also implicated and these patients are at a significant risk of systemic morbidity. A study by Plamer and co-authors found that approximately half of the patients diagnosed with idiopathic retinal vasculitis developed systemic diseases subsequently, with a high frequency of coronary heart disease, myocardial infarctions and cerebrovascular accidents. The cardiovascular disease had occurred in subjects with idiopathic retinal vasculitis despite lacking other risk factors, such as diabetes, hypertension and dyslipidaemia. Similarly, a significant proportion of patients with leakage only retinal vasculitis developed multiple sclerosis and other undetermined neurological diseases (Palmer, Zaman et al. 1995).

The visual prognosis is mainly dependent on whether the disease causes vascular occlusion or not, and if it does, heavy immunosuppression is warranted. In the majority of patients, corticosteroid treatment alone was insufficient for disease control, and corticosteroid-sparing agent was required. Therefore, long-term disease control with the introduction of second-line immunosuppressive agents, is necessary. There is no consensus on which agent is preferred, however, azathioprine was proven effective in these patients. Visual acuity has improved or been maintained in 64% of patients, and the number of relapses reduced on azathioprine. However, the corticosteroids sparing effect was partial (Greenwood, Stanford et al. 1998).

1.3.10.1.7 Polyarteritis nodosa

Polyarteritis nodosa is an idiopathic form of necrotising vasculitis that involves mainly medium-sized arteries with a tendency to form microaneurysms. In contrast to, Wegener's granulomatosis, the lungs are not affected, and this disease does not cause granulomatous inflammation. It is associated with hepatitis B virus infection in some patient (personal communication with professor Lightman). The ocular features include retinal vasculitis, non-granulomatous uveitis, scleritis and PUK (Akova, Jabbur et al. 1993).

1.3.10.1.8 Seronegative Spondyloarthropathy

Human cells express a cell surface glycoprotein called major histocompatibility complex (Human leukocyte antigen). This cell surface marker plays an essential immunological function because it controls the binding capacity of APC and thus the subsequent stimulation of T lymphocytes. There are six different families of HLA:

MHC class I: HLA -A, -B, -C

MHC class II: HLA-DR, -DP, DQ

Spondyloarthropathies are a group of chronic inflammatory disorders strongly associated with HLA-B27. They include reactive arthritis, ankylosing spondylitis, psoriatic arthritis, and inflammatory bowel disease (Crohn's disease and ulcerative colitis) (Braun and Sieper 2007), ankylosing spondylitis being the most common. The pathogenesis of this autoimmune condition remains unknown. However, many cases of reactive arthritis and anterior uveitis follow gram-negative bacillary dysentery or chlamydial infection which raises the possibility of bacterial lipopolysaccharide-induced immune reaction. Another speculation is that chronic intracellular chlamydial infection triggers an adaptive immune response with CD4+ T lymphocytes that indirectly damage the eye while trying to eliminate the microorganism. Another hypothesis is the presence of molecular mimicry between the bacterial antigen and some amino acid sequences of HLA-B27. Studies analysing the ocular fluids of HLA-B27 patients suggest that a CD4+ Th1 mediated delayed hypersensitivity reaction possibly responding to bacteria-derived antigens is responsible for this disease. Conversely, the endogenous autoantigens of the anterior uvea (perhaps melanin

associated antigen, type I collagen, or myelin-associated protein) may be involved in this disease process. HLA association only describes patients at risk but is not a diagnostic marker, and the clinical diagnosis is as reliable as the association with HLA (Levinson 2005).

1.3.10.2 HLA-B-27 associated uveitis

HLA-B27 is frequently associated with acute anterior uveitis, and it mainly affects young adults in their second and third decade of life, with males being affected more than females in a 2:1 ratio and men tend to have more severe disease (Braun and Sieper 2007). Up to 50 % of patients with recurrent episodes of AAU have the HLA-B27 gene (Brewerton, Hart et al. 1973, Russell, Lentle et al. 1979, Rothova, van Veenendaal et al. 1987).

HLA-B27 associated uveitis classically presents with acute, unilateral anterior uveitis that usually develops in one eye but can have a bilateral asymmetrical presentation. The inflammation can be more intense than the one seen in idiopathic anterior uveitis and can lead to fibrinous reaction and hypopyon. Sometimes the inflammation becomes chronic leading to vision-threatening complications such as cystoid macular oedema, cataract, and glaucoma. They are usually treated with short courses of topical steroids and cycloplegics and respond well (Rothova, van Veenendaal et al. 1987). Patients have generally 1-2 attacks per year which usually takes about six weeks to resolve, but can last up to three months (personal communication with professor Lightman).

Ankylosing spondylitis is present in 1 per 1000-2000 of the white population. It can affect both sexes, but males tend to have a more severe disease. In some patients, the eye manifestations predate the joint disease. It typically presents with lower back pain associated with morning stiffness, large joint inflammatory disease and enthesitis (sites where tendons attach to the bones). A lumbosacral X-ray is helpful to diagnose sacroiliitis manifesting as sclerosis and obliteration of joint space and a sclerosed spine giving a characteristic “bamboo spine appearance”. MRI scan is superior now in diagnosing joint manifestations. HLA-B27 occurs in approximately 90% of patients and the reported prevalence of anterior uveitis in patients with ankylosing spondylitis range

from 30-40% (Wyngaarden and Smith 1992, Nussenblatt, Whitcup et al. 1996, Gran and Skomsvoll 1997).

Although patients usually present with frequent attacks of acute anterior uveitis, HLA-B27 associated disease can cause severe sight-threatening posterior segment inflammation in 17% of patients, such as severe diffuse vitritis, papillitis (inflammation of the optic nerve), and retinal vasculitis. Cystoid macular oedema and epiretinal membrane were the most common causes of visual impairment in these patients, and these patients often require aggressive systemic immunosuppressive therapy to preserve sight (Rodriguez, Akova et al. 1994).

Inflammatory bowel disease is commonly associated with seronegative-spondyloarthritis and is HLA-B27 positive (Rankin, Watts et al. 1979). Similarly, posterior segment inflammatory manifestations such as severe bilateral neuroretinitis, retinal vasculitis, ischemic optic neuropathy, optic neuritis and pars planitis have been described in patients with inflammatory bowel disease (Heuer, Gager et al. 1982, Sedwick, Klingele et al. 1984, Duker, Brown et al. 1987).

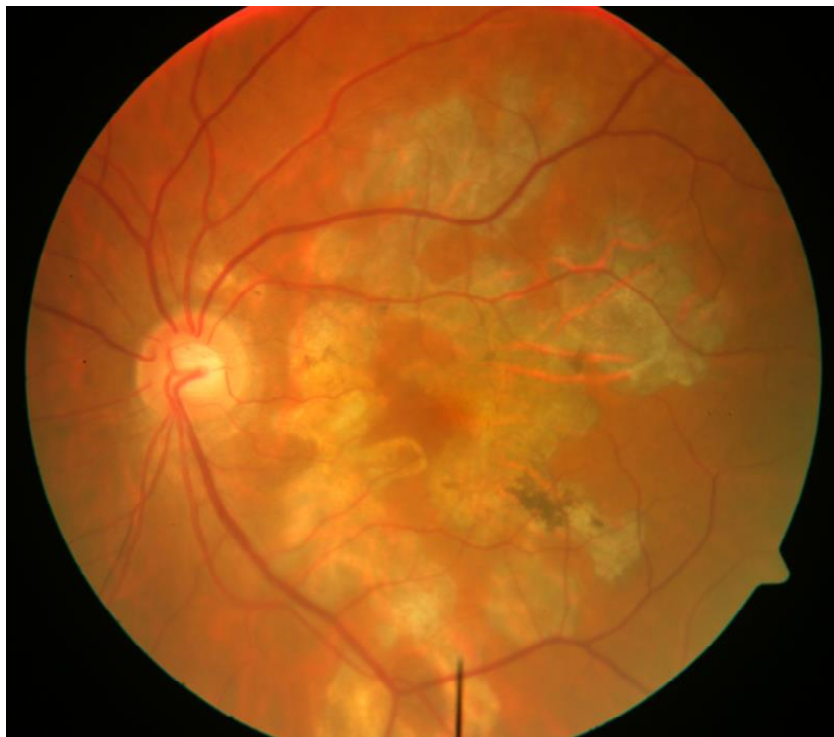1.3.10.2.1 Systemic lupus erythematosus (SLE)

SLE is multisystem connective tissue disease of unknown aetiology. Heart, kidney, CNS and skin can be involved in this disease. The most common ocular features are dry eye disease. However, it can cause ischaemic occlusive vasculitis without significant ocular inflammation (Dammacco 2017).

1.3.10.2.2 Serpiginous choroiditis

Serpiginous choroiditis (geographic or helicoid choroidopathy) is a chronic progressive inflammatory condition occurring equally in adult women and men in their second to seventh decades of life. It is a rare disease of unknown aetiology but 50% of patients have associated systemic tuberculosis and in the other half of patients, no evidence of TB could be found. An immune-mediated process with occlusive vasculitis is thought to play a part in the disease pathophysiology. In those without TB treatment is with immunosuppressive therapy. Serpiginous choroiditis is not associated usually with others types of systemic or infectious disease (Gupta, Gupta et al. 2003). Figure 1-19.

Figure 1-19 Left eye with serpiginous choroiditis, areas of geographic atrophy are seen around the fovea. Source Moorfields Eye Hospital.



Serpiginous choroiditis usually advances with multiple relapses, and new lesions tend to develop at the edge of previous scars (interval between attacks is months to several years), leaving atrophic retinal, RPE and choroid behind along with subretinal fibrosis and RPE hyperplasia (hyperpigmentation). Therefore, over a disease course, the scarring enlarges unpredictably and results in loss of vision (Jones and Jones 2012). The visual prognosis is guarded and 38% will have a poor visual acuity (between 6/60 and counting fingers) (Christmas, Oh et al. 2002). Patients usually present with painless, visual field defects (paracentral scotoma) and reduced central vision. On examination, there is often a quiet anterior chamber and minimum vitreous involvement, but the striking abnormality is the presence of pseudopodial or geographic lesions emanating from the optic nerve at the posterior segment of the eye which is usually bilateral. Active lesions appear as grey-whitish lesions at the level of RPE. CNV develops in one quarter of patients. The disease course is progressive with centrifugal extension with a notable asymmetry between the two eyes.

The diagnosis is clinical, and there are several tests help documenting disease activity. Fluorescein angiography shows blockage of the normal choroidal background early in the angiogram and staining of the active border later in the angiogram. Opposite to early hyperfluorescence and late leakage later on in case of CNV. ICG shows hypofluorescence of the lesion throughout all phases of the angiogram. Fundus autofluorescence is a sensitive tool for detecting damage to the RPE and documenting the disease course. For instance, hypoautofluorescence relates closely to areas of inactive disease, while hyperautofluorescence features area of active pathology. Finally, OCT shows increased reflectivity of the outer retinal layer, RPE layer also appears disrupted on OCT when the disease is active. Eventually, atrophy of both the retina and the RPE occur when the disease quiescences (Bansal, Gupta et al. 2012).

Excluding serpiginous-like choroiditis (TB related) is imperative. Therefore, patients need a tuberculin skin test, or interferon-gamma assay and chest x-ray to exclude TB infection (Gupta, Gupta et al. 2003). Also, other entities such as sarcoidosis, syphilis and herpetic choroiditis may give a similar clinical picture (Khanamiri and Rao 2013).

Corticosteroids are given systemically, periocularly and intravitreally to treat vision-threatening disease, but are often ineffective and even the addition of systemic immunosuppressive therapy can be insufficient. Cyclosporine alone has been used successfully in a small number of cases. Similarly, azathioprine as part of triple therapy (corticosteroids, cyclosporine and azathioprine) can help with disease control (Hooper and Kaplan 1991). Long-term treatment is required as most patients relapse when these drugs are tapered. Cytotoxic therapy with cyclophosphamide and chlorambucil have been reported to induce disease remission (Akpek, Jabs et al. 2002). Alternatively, injection of a steroid implant into the vitreous can be used in patients intolerant to systemic therapy.

1.3.10.2.3 Masquerade

Retinal detachment and Lymphoma. These subjects are beyond the scope of this thesis.

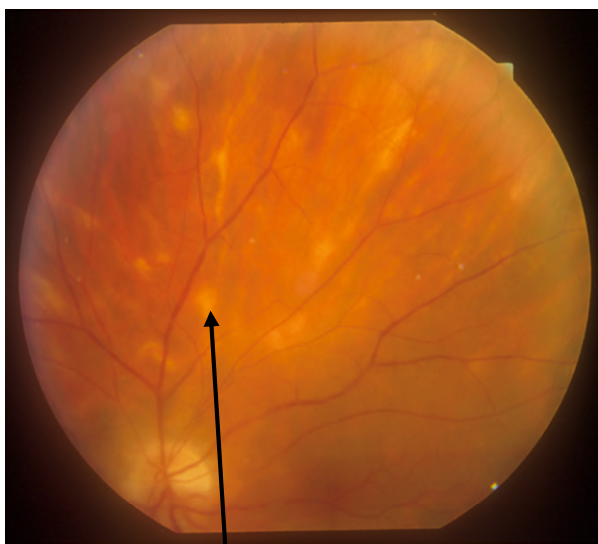1.3.10.3 Disease with ocular involvement only

1.3.10.3.1 Birdshot chorioretinopathy BSCR

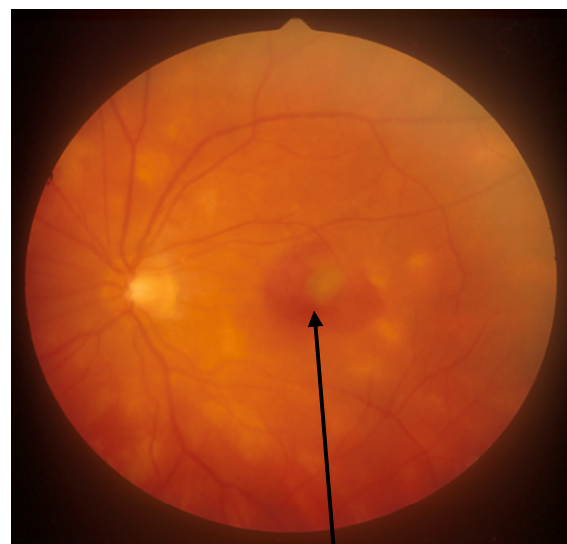
Birdshot chorioretinopathy is bilateral posterior uveitis of unknown aetiology (Shao, Menezo et al. 2014). It commonly affects people of Northern European descent, and it is strongly associated with the HLA-A29 gene with a sensitivity of 96% and specificity of 93% (224 times increase in relative risk) (Levinson, Brezin et al. 2006). It affects people past their fourth decade of life and represents 6-8 % of cases with posterior uveitis. It is a progressive disease leading to retinal dysfunction (Shah, Levinson et al. 2005, Levinson, Brezin et al. 2006).

The presenting symptoms include blurred vision, floaters, night blindness and impaired colour perception. Because of widespread retinal dysfunction, visual complaints are usually out of the proportion to the measured Snellen acuity (Levinson, Monnet et al. 2009). Minimal anterior segment activity is noticed, however, vitritis is a common finding. Fundoscopy reveals a characteristic multiple creamy coloured oval lesions distributed throughout the posterior pole in a fashion similar to Birdshot pellets. Figure 1-20, (Shah, Levinson et al. 2005). Retinal vasculitis, CMO are sight-threatening complications of this disease, while, optic atrophy and ERM are late complications of this disease (Thorne, Jabs et al. 2005).

Figure 1-20 Birdshot lesions in the posterior pole (Left) Birdshot disease complicated by CNV and haemorrhage at the fovea (Right). Photos are courtesy of professor Lightman. Source Moorfields Eye Hospital



Creamy white lesions in Birdshot disease



Subfoveal CNV lesion in Birdshot disease

There are still gaps in our knowledge regarding the definitive immune mechanism involved in Birdshot disease. However, studies have shown that it is a T cell-driven disease particularly Th-17 which secrete IL-17. Also, several immune mediators known to promote Th17 such as IL-21, IL-23 and TGF β 1 were upregulated in treatment naïve Birdshot patients (Kuiper, Mutis et al. 2011, Yang and Foster 2013).

Different tools help with the diagnosis of Birdshot. ICG is more sensitive in characterising the Birdshot lesions compared to FFA which is of limited value especially in the early stages of the disease (Papadia and Herbort 2013). However, FFA is good at showing retinal vasculitis and CMO which are reported as being the most common cause of vision loss in these patients (Taylor, Lightman et al. 2012). Furthermore, in patients with BSCR disease progressive thinning of the outer retina on OCT scan corresponds to the loss of vision (Papadia, Jeannin et al. 2012). Electrodiagnostic studies and visual field testing are more sensitive measures to detect disease progression. ERG shows a decrease in scotopic b wave amplitude in early disease. However, delayed 30Hz flicker implicit time appears the most sensitive measure of disease activity and response to treatment (Holder, Robson et al. 2005, Kiss, Ahmed et al. 2005, Gordon, Monnet et al. 2007). Treatment relies on systemic corticosteroids, but BSCR is not fully responsive to corticosteroid alone and early initiation of immunomodulatory therapy is warranted. Long-term immunosuppressive treatment is also essential given the chronic disease course (Kiss, Ahmed et al. 2005, Tomkins-Netzer, Taylor et al. 2014).

1.3.10.3.2 Multifocal choroiditis (MFC) and panuveitis

MFC is an idiopathic inflammatory disease of unknown aetiology affecting young, myopic females. This disease involves the retina, choroid and the vitreous with asymmetrical presentation between the two eyes. Symptoms include floaters, flashing lights (photopsia), reduced vision and enlargement of the physiological blind spot. Ophthalmic exam reveals the presence of multiple white-yellow dots which appear as punched-out, atrophic lesions (50-200 μ m) around the optic disc, mid-periphery of the retina and anterior to the equator. Acute lesions appear creamy and become atrophic with a variable degree of hyperpigmentation with time. There is a degree of anterior segment and vitreous inflammation (Dreyer and Gass 1984) which excludes other entities such as, PIC and ocular histoplasmosis syndrome (Essex, Wong et al. 2013).

Structural complications can be present at the time of diagnosis, and these include cataract, CMO, ERM and CNV. These complications can also develop during the disease course and are responsible for vision impairment in these patients (Kedhar, Thorne et al. 2007). Vision loss can occur in up to 70% of patients, and most commonly due to the development of CNV which affects about one-third of eyes (Dreyer and Gass 1984, Brown, Folk et al. 1996).

The diagnosis is that of exclusion since many ocular diseases can mimic MFC such as TB, sarcoidosis, syphilis, but it is usually made clinically with the aid of imaging modalities. Fluorescein angiography shows hypofluorescence early and staining late in acute active lesions. While atrophic lesions show early hyperfluorescence which fades with time. CNV and macular oedema show early hyperfluorescence and late leakage. ICG often shows multiple hypofluorescent lesion corresponding to active choroiditis, and they cluster around the optic nerve (Slakter, Giovannini et al. 1997) which explains the enlarged blind spot on a visual field test. On OCT these lesions appear as sub RPE deposits with overlying disruption of the outer retina (Spaide, Goldberg et al. 2013). Fundus autofluorescence (FAF) may show numerous punctate hypofluorescence spots that correspond to areas of chorioretinal atrophy. Active lesions display hyperautofluorescence spots that vanish after treatment. Therefore, FAF can be used to monitor response to treatment (Yeh, Forooghian et al. 2010).

Without treatment, the visual prognosis is generally poor, with irreversible vision loss occurring in 75% of patients due to the complications that result from chronic and recurrent inflammation. Treatment with systemic and periocular steroids can help with disease control especially with CMO and even regression of CNV complex in some patients. Due to the chronic and recurrent nature of the inflammation corticosteroid-sparing agents are usually needed (Michel, Ekong et al. 2002). This treatment has succeeded not only in controlling the inflammation but also in reducing the risks of posterior pole complication (CMO, ERM and CNV) with 83% to 92% reduction in the risk of severe vision loss ($\geq 6/60$) in the affected eye (Kedhar, Thorne et al. 2007). Therefore, treatment with immunosuppressive drugs appears very effective in preventing disease complications and sight loss (Michel, Ekong et al. 2002).

1.3.10.3.3 Punctate Inner Choroidopathy (PIC)

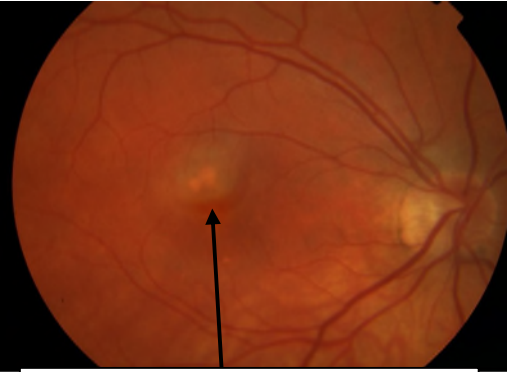
PIC is idiopathic posterior uveitis that was first reported by Watzke in 1984 (Watzke, Packer et al. 1984). In his series, the disease was described as small yellow lesions at the posterior pole in young myopic females Figure 1-21. Patients usually present with blurred central vision, paracentral scotoma and flashing lights. These lesions heal with atrophic scars and are commonly complicated by a choroidal neovascular membrane.

Some authors claimed that PIC and MFC are two spectra of one disease because both are idiopathic inflammatory disorders which occur predominantly in young myopic and white women (Spaide, Goldberg et al. 2013). However, these are two different entities for several reasons. Firstly, PIC presents at a younger age compared to MFC (29 versus 45 years, respectively). Secondly, compared to MFC, PIC lesions are smaller and rarely extend beyond the mid-periphery of the retina and are never associated with vitritis. Thirdly, PIC lesions progress to atrophic scars with a halo of pigmentation around them, and they appear deeper and more punched out than MFC. Finally, with the exception of CNV, PIC patients tend to have much less structural complications such as cataract, CMO and ERM than those with MFC. A difference, undeniably attributed to the presence of chronic intraocular inflammation in MFC (Kedhar, Thorne et al. 2007).

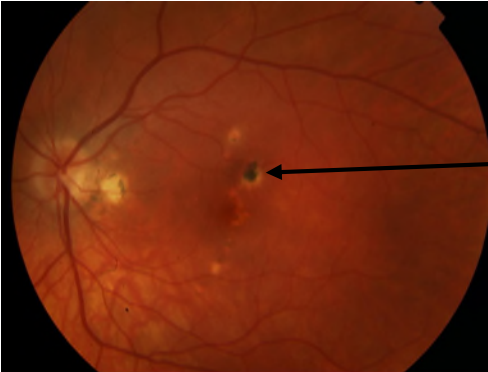
Fluorescein angiography shows early hypofluorescence and late staining in active lesions. When early hyperfluorescence is seen one should suspect a CNV. CNV is the most common sight threatening complication and as high as 69% and 75% of patients develop CNV (Gerstenblith, Thorne et al. 2007, Patel, Birnbaum et al. 2011).

Visual prognosis is good when there is no CNV and scarring at the fovea. Treatment options include corticosteroids either periocular or systemic with the addition of corticosteroid-sparing agents when there are acute lesions threaten the fovea. The primary treatment of active CNV lesions is intravitreal injections with anti-VEGF (Leung, Moradi et al. 2014).

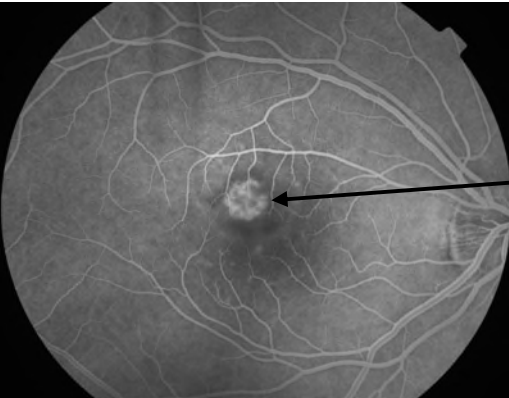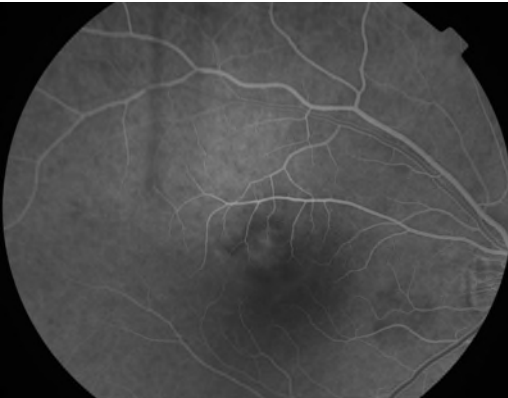
Figure 1-21 TOP left PIC disease with active CNV, top right PIC scarring. Lower images FFA shows leakage from the CNV lesion. Photos are courtesy of Dr. Talat. Source Moorfields Eye Hospital.



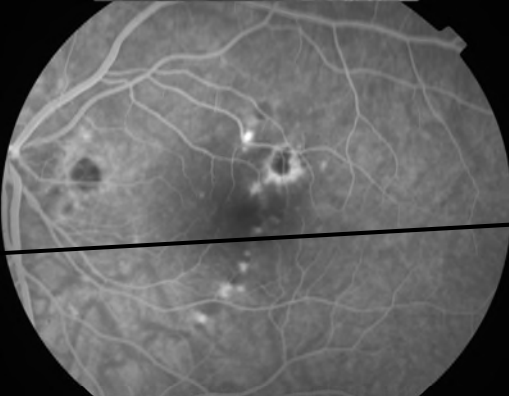
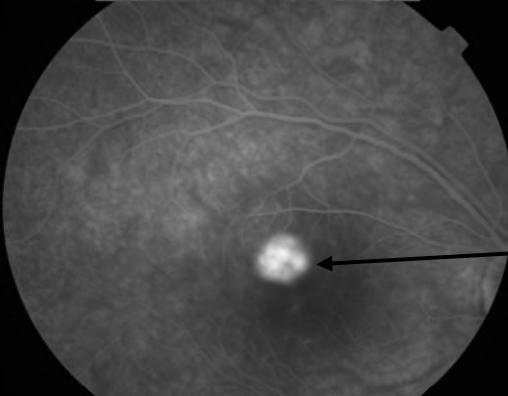
PIC lesion complicated by CNV



Atrophic PIC lesion with hyperpigmentation



Fluorescein angiography shows the CNV complex



Fluorescein angiography shows late leakage from the CNV membrane

1.3.10.3.4 Non-infectious posterior, intermediate and panuveitis

Non-infectious posterior, intermediate and panuveitis are a heterogeneous group of ocular inflammatory conditions, uncommon, autoimmune in nature, commonly associated with systemic inflammatory diseases. These diseases collectively responsible for 19% to 40% of non-infectious uveitis cases, with a worldwide prevalence of 38/100,000 people. These disorders could be isolated to the eye or associated with systemic disease such as Behcet disease, VKH, sarcoidosis. They carry a significant risk of sight loss (Jabs, Nussenblatt et al. 2005). These diseases are largely unpredictable mandating frequent health care visits, periodic checking and expensive medication. Recent reports estimated that patients with these uveitides have a 10-fold increased risk of blindness or low vision compared to the normal population (Engelhard, Patel et al. 2015, Dick, Tundia et al. 2016). Therefore, early and successful long-term control of inflammatory activity appears to play a key role in reducing the risk of ocular complication and preventing sight loss. Corticosteroid represents the first-line treatment because they achieve rapid control of inflammation in these sight-threatening conditions. However, their long-term use is limited by their wide range of side effects, therefore patients usually receive immunomodulatory or biologic therapy to achieve control of inflammation and a reduced dose of corticosteroid.

1.3.11 Management of uveitis

The control of inflammation and preventing the visual loss which can result from the cumulative damage to ocular structures remains the most critical step in the management of uveitis. In the majority of cases, inflammation in uveitis is idiopathic, and the mainstay of treatment is corticosteroid with an additional immunosuppressive agent(s) if required. High dose corticosteroid is used initially to achieve rapid control of the inflammation but are not suitable for long-term therapy due to well-known side effects. On the other hand, lower doses of corticosteroids ≤ 7.5 mg per day are often ineffective for long-term disease control, and therefore, immunosuppressive agents should be instituted early in disease management (Jabs 2017). Corticosteroid and corticosteroid-sparing immunosuppressive drugs are used to treat the vast majority of patients with non-infectious uveitis (intermediate, posterior and panuveitis), in addition

to cases of JIA-associated anterior uveitis. Clinical data suggest superior visual outcome lower sight-threatening complications are attained with immunosuppressive agents.

“If many cures are suggested for a disease, it means that the disease is incurable”

Anton Chekhov.

Treatment of non-infectious uveitis is driven mainly by the anatomical class of uveitis, disease course and natural history. For example, topical corticosteroids are the treatment of choice in anterior uveitis; intermediate uveitis is managed initially by regional corticosteroids, and systemic therapy is introduced in bilateral, chronic disease with transient or no response to local treatment; systemic immunosuppression is usually instituted in posterior and panuveitis. Disease course on the other hand influences treatment, with diseases of chronic relapsing nature such as Behcet’s disease, sarcoidosis, VKH and Birdshot chorioretinopathy being better managed with long-term systemic immunosuppressive therapy to control the inflammation. Therefore, non-infectious chronic uveitis mandates long-term treatment to suppress the inflammation. Conversely, HLA-B27-associated uveitis which presents with recurrent attacks, is typically treated only with local corticosteroids drops during the acute attack (Jabs 2017).

The decision to treat uveitis always balances the risk and benefits of therapy, and not all patients require treatment. For example, Fuch’s chronic anterior uveitis does not respond to treatment and treatment is typically not given. Similarly, a quarter of patients with pars planitis have mild disease, with good vision and no complications; therefore, they do not require treatment (Raja, Jabs et al. 1999). Nonetheless, when treatment is needed the aim is to achieve complete suppression of inflammation (grade 0 inflammation) in SUN criteria (Jabs, Nussenblatt et al. 2005) for anterior and intermediate uveitis to reduce the risk of sight loss. Posterior chorioretinal diseases usually require multimodal imaging including fundus autofluorescence, which has shown good agreement with disease activity, to judge response to treatment and resolution of inflammation (Jabs 2017).

1.3.11.1 Why long-term control of inflammation is better?

Studies from JIA associated uveitis show that any inflammation doubles the risk of visual impairment (VA<6/18) and triples the risk of blindness (VA≤6/60). Also, the more severe the inflammation, the higher the risk of vision loss (Thorne, Woreta et al. 2007). Likewise, the results from the SITE study indicate that active uveitis in Behcet's disease patients is associated with a 2.5 fold risk of visual impairment and 2.7 fold risk of blindness (Kaçmaz, Kempen et al. 2008). The use of immunosuppressive therapy reduced the risk of ocular complications and blindness in JIA-associated uveitis patients (Thorne, Woreta et al. 2007).

Long-term disease control appears superior to short courses of corticosteroids used to manage ocular complications. For example, in Birdshot disease the use of intermittent immunosuppressive therapy to control complications such as CMO is not sufficient to prevent visual deterioration, because the chronic inflammatory status in Birdshot leads to progressive decline in retinal function even when VA is normal. Only repeat electroretinograms, and visual field tests show signs of retinal involvement and the visual acuity measurements remain normal until late in the disease course (Oh, Christmas et al. 2002). Therefore, the optimum treatment in patients with uveitis should aim for no inflammation in the eye, and this should be sustained for an extended period to avoid complications and loss of sight.

1.3.12 Therapy for uveitis

1.3.12.1 Non-steroidal anti-inflammatory drug NSAID

NSAIDs are used to treat mild inflammatory joint disease. They act by blocking the cyclooxygenase (COX) pathway and hence inhibit the synthesis of prostaglandins (PG). There are two COX pathways, COX1 which is present in most tissues and COX 2 which is upregulated during inflammation. NSAID are either nonselective and inhibits both COX 1 and 2, or selective (blocking only COX2 pathway). The most common side effects associated with their use are gastrointestinal disturbances such as nausea, vomiting and peptic ulceration. Also, in severe cases NSAID can lead to renal dysfunction and fluid retention.

NSAIDs is the first-line treatment for scleritis, particularly indomethacin and flurbiprofen but the success rate varies between subjects (Sainz de la Maza, Jabbur et al. 1994, Jabs, Mudun et al. 2000). Interestingly, patients with HLA-B27 associated uveitis using systemic NSAIDs have been shown to have fewer flare-ups, and those patients needed fewer corticosteroids (any form) or other immunosuppressive agents to control their inflammation (Teasley, Christen et al. 2007). There are recommendations to use these medicines as adjuncts to corticosteroids in patients with inflammatory bowel disease and uveitis or juvenile idiopathic arthritis JIA-associated chronic anterior uveitis (Olson, Lindsley et al. 1988, Soukiasian, Foster et al. 1994).

However, these medications are not routinely used by ophthalmologists for patients with intraocular inflammation, since their efficacy is inferior to corticosteroids and are not ideal when rapid control of inflammation is desired to decrease ocular tissue damage. Moreover, the addition of NSAID to steroids will increase the risk of gastrointestinal side effects especially peptic ulcer disease. Finally, topical formulas of NSAID can produce local irritation to the ocular surface resulting in a burning sensation and conjunctival hyperaemia and corneal melt (not uncommon but serious complication). As a result, the use of NSAID is limited to a mild form of episcleritis and scleritis and to reduce the risk of inflammation post cataract surgery (Kim, Flach et al. 2010).

1.3.12.2 Corticosteroid (steroids)

Corticosteroid, has revolutionised the treatment of ocular inflammation since their first use by Gordon and Mc Lean in 1950. Corticosteroids achieve their anti-inflammatory and immunosuppressive effects via several mechanisms (Fauci 1978, Nussenblatt, Whitcup et al. 1996): Firstly, while it increases the neutrophil populations in the bone marrow, it decreases the adherence of neutrophils and macrophages to vascular endothelium thereby, reducing the number of inflammatory cells reaching the sites of inflammation. Secondly, it causes lymphocytopenia through redistributing the lymphocytes, mainly T cells from the intravascular to the extravascular compartment such as the spleen, bone marrow and lymph nodes. Moreover, at higher doses it reduces the antibody production from B cells.

In addition, corticosteroids cause a reduction in the number of circulating eosinophils, monocytes and basophil and inhibits the bactericidal activity of macrophages and monocytes. Moreover, it stabilises the cell membrane of mast cells and eosinophils and prevents the degranulation and subsequent release of their inflammatory cytokines such as histamine and bradykinin. More importantly, corticosteroid inhibits the transcription of essential inflammatory cytokines necessary for chronic inflammation such as IL-1 $\text{INF}\alpha$ granulocyte macrophage colony-stimulating factor (GM-CSF), among other inflammatory cytokines. Finally, corticosteroid stabilises capillaries and reduces their permeability and dilation in response to inflammation (Rhen and Cidlowski 2005).

Corticosteroids, have been widely used in the management of uveitis and were given via different routes orally, topically and periocular administration. Also, intravenous corticosteroid therapy has been advocated in severe sight-threatening conditions such as Behcet, VKH and sympathetic ophthalmia. Oral corticosteroids generally preferred for posterior segment disease. The topical route can achieve higher concentrations in the aqueous compared to systemically administered corticosteroids due to the blood-ocular barriers (Leopold and Maylath 1952).

1.3.12.2.1 Topical corticosteroid therapy

Topical corticosteroids drops are used primarily to treat inflammation in the anterior chamber. There are different types of topical corticosteroids, and these vary in their potency and ocular tissue concentration. Recent work looked at the penetration of different corticosteroid compounds and their efficacy, have found that prednisolone acetate 1% and dexamethasone alcohol 0.5% have a higher concentration in the AC and maximal anti-inflammatory effects (Awan, Agarwal et al. 2009). Therefore these drops have been used to treat severe AC inflammation whether isolated or in association with posterior, IU or panuveitis. Some authors have postulated that these drops may be of benefit in treating vitritis or CMO in aphakic or pseudophakic patient (Lee, Bajwa et al. 2014). Nevertheless, Weijtens et al. reported that the penetration of dexamethasone drops into the vitreous after repeated installation was negligible (Weijtens, Schoemaker et al. 2002). Less potent topical steroids such as rimexolone and loteprednol may be used to treat mild inflammation and in steroid-responders, owing to their minimum effect on IOP elevation (Foster, Kothari et al. 2016).

1.3.12.2.2 Periorcular corticosteroid administration

Periocular corticosteroid therapy is preferred when the patient has a unilateral disease, unresponsive or poorly compliant to systemic treatment or for pregnant patients. Examples are methylprednisolone sodium succinate 40 mg/mL (Depo-Medrol) or triamcinolone acetonide-10–40 mg/mL suspension (Kenalog). Excluding any infectious aetiology, is a must, before commencing this treatment approach. Also, a special attention should be paid to patients known to have high IOP with corticosteroid therapy or those with necrotising scleritis. The choice of using local therapy also depends on the patient's preference. These agents can be used as adjuncts, but they cannot replace immunomodulatory therapy in patients with sight-threatening disease (Foster, Kothari et al. 2016).

Local corticosteroids are delivered by two techniques, either by orbital floor route using a 27 gauge needle, or sub-Tenon injection with 25 gauge needle. Both are equal in terms of efficacy and side effects (cataract formation and increase in IOP). These techniques are associated with increased risk of periorbital haemorrhage and penetration of the globe. Also, dropping of the upper eyelid is one of the complications related to the sub-Tenon approach, while orbital fat prolapse occurs with orbital floor injection (Foster, Kothari et al. 2016).

1.3.12.2.3 Intravitreal steroid injection

Intraocular steroid injections are used to control the inflammation in patients with non-infectious intraocular inflammation complicated by cystoid macular oedema and vitritis. It is the preferred treatment modality in patients with unilateral disease, severe disease, intolerant or unresponsive to systemic corticosteroids/immunosuppressive agents or periorbital steroids. The bioavailability of intravitreal corticosteroids injections is 100%, as these injections bypass all the ocular barriers and achieve a higher therapeutic concentration to the site of inflammation which helps with rapid disease control. Another advantage of Intravitreal therapy is the elimination of the side effects of systemic corticosteroid. They are effective in reducing the amount of CMO and improve the visual acuity in patients with non-infectious uveitis (Kok, Lau et al. 2005).

However, some intraocular corticosteroid implants have a limited duration of action. Therefore, patients often need repeated injections to control the inflammation (Foster, Kothari et al. 2016). There are different steroid formulations used for intravitreal injections. Triamcinolone acetonide is commonly used at a dose ranging from 2 to 4 mg per 0.1 ml and lasts up to 3 months. A sustained release device such as, (Ozurdex) which is a biodegradable dexamethasone implant (0.7 mg) or Retisert, fluocinolone acetonide (0.59 mg), usually lasts longer, generally 3-6 months and 2.5 years, respectively.

Recently, the POINT trial compared the effect of triamcinolone (Intravitreal or orbital floor injection) with the Intravitreal steroid implant (ozurdex) for the treatment of uveitic macular oedema. All treatment modalities were effective in reducing the amount of fluid at the macula. However, the intravitreal treatment groups achieved a significantly better reduction in CMO and improvement in BCVA compared to periorbital treatment. The risk of an increase in IOP was higher in the intravitreal treated groups, but no difference was seen between IVTA and ozurdex with regards to IOP elevation (Thorne, Sugar et al. 2018).

Cataract and increased intraocular pressure are the main side effects associated with local corticosteroid injections and the risk increases with repeated doses or longer duration of action (Thompson 2006, Haghjou, Soheilian et al. 2011). Also, other complications such as injury to the eye, bleeding, infection, trauma to the lens, and sterile endophthalmitis due to the accumulation of drug crystal in the anterior chamber, in case of triamcinolone, have been reported. The Multicentre Uveitis Steroid Treatment Trial (MUST) reported a four-fold increase in IOP rise and glaucomatous optic nerve damage in implant treated patients compared to those on systemic treatment (Friedman, Holbrook et al. 2013). Thus, patients need to be monitored closely for the rise in IOP, and a low threshold for surgical intervention for glaucoma is warranted.

1.3.13 Why systemic therapy with immunosuppression appears superior to local corticosteroids treatment ?

There are several treatment options for patients with non-infectious uveitis. Initially, corticosteroids can be given orally or administered locally into the eye, and then there

is the option of combining corticosteroid with other immunomodulatory therapy. Traditionally, corticosteroid-sparing agents, such as tacrolimus, cyclosporine, azathioprine, mycophenolate mofetil (MMF), methotrexate, chlorambucil, and cyclophosphamide have all been used to control the inflammation in uveitis patients (Jabs, Rosenbaum et al. 2000). To answer the question of whether systemic, or local therapy, is superior, a Multicentre Uveitis Steroids Treatment (MUST) trial began over seven years ago.

1.3.13.1 MUST TRIAL

The MUST Trial was a comparative effectiveness randomised trial, comparing the efficacy of systemic corticosteroids with or without immunosuppressive medication to the local corticosteroid implant (fluocinolone acetonide, Retisert®) among patients with active non-infectious IU, posterior or panuveitis (Kempen, Altaweel et al. 2010). At 54 months follow-up, the study showed similar visual acuity outcomes in the two groups. Regarding the uveitis activity, there was a statistically significant difference favouring implant therapy from 6 months through 54 months, but the difference was not statistically significant after that (Kempen, Altaweel et al. 2017).

The 7-year results from MUST trial (obtained from approximately 70% of uveitic eyes in each treatment group who initially participated in the trial) favour systemic treatment with regards to better long-term visual acuity outcomes. Despite a significant initial improvement in vision at six months in the implant group, with longer follow-up (7 years) patients on systemic therapy achieved better BCVA, (p -value= 0.045 and 0.006, at 6 and seven years, respectively). The mean change in visual acuity from baseline was 7.2 (95%CI, 2.1-12) letters more on systemic therapy. The proportion of patients with legal blindness decreased from baseline by 1% in the systemic therapy group while in the local therapy group the proportion increased by 8%. The disparity in BCVA was attributed mainly to more irreversible chorioretinal scarring in implant given patients (52% in implant versus 31% in systemically treated patients, (CI 2%-39%), (p -value=0.02). Glaucoma did not differ significantly as a cause of severe vision loss between the two groups. With regards to macular oedema, there was a statistically significant difference at 6 months (favour implant), but at 72 months the

data shows that systemic therapy is superior to the corticosteroid implant (fewer eyes with CMO on systemic treatment).

More uveitis reactivation occurred in eyes treated by local therapy, which have resulted in a decline in visual acuity from irreversible chorioretinal damage, whereas, patients on systemic treatment enjoyed more stable disease control. The authors speculated that scheduled replacement of the implants (re-implantations) might have had a better outcome. However, this approach would have several impracticalities. Firstly, the duration of the effect of the implant varies, and most groups replaced the original implant only when disease relapsed. Secondly, the frequent ocular side effects from the first implant may restrict or even prevent the re-implantation in some cases. Finally, more medical and surgical interventions were required in the implant group to maintain favourable vision (Kempen, Altaweel et al. 2017).

Systemic treatment is the preferred initial treatment in patients with bilateral disease. Because the risk of complications from the local therapy is higher in these patients (Kempen, Altaweel et al. 2015). Besides, the high cost for implants in this cohort (Sugar, Holbrook et al. 2014). Approximately two-thirds of eyes on systemic therapy in the MUST trial required one or two adjunctive corticosteroid injections for uveitic CMO (Kempen, Altaweel et al. 2015).

Although, superior control of inflammation initially with implant group, cataracts, ocular hypertension, glaucoma and glaucoma filtration surgery were higher in the implant group. At seven years, 45% of eyes in the implant group underwent glaucoma filtration surgery compared to only 12% in the systemic therapy group. Similarly, 90% of eyes in the implant group had cataract surgery versus 50% of patients in the systemic treatment arm.

The MUST study demonstrated that local therapy with fluocinolone acetonide (retisert) was associated with an 81% increase risk in the odds of blindness compared to systemic therapy. This disparity appeared to be due to the retinal damage from relapse of uveitis before re-implantation (Kempen, Altaweel et al. 2017). Therefore, with each relapse, there was cumulative damage to the eye, and even with some initial recovery with local treatment, the long-term visual outcome was inferior to that of systemic therapy (Jabs 2017).

Finally, there was no significant increase in the risk of systemic side effects with systemic therapy for a minimum of 7 years follow-up. MUST study has shown that systemic therapy proved safe and effective for long-term disease control (up to 7 years follow-up). There was no increase in the risk of side effects with systemic therapy compared to regional treatment and the only statistically significant difference was more antibiotic use for infections for the systemic treatment group compared to the implant group (Kempen, Altaweel et al. 2017). Importantly, the authors reported that systemic therapy was well-tolerated by the majority of patients, who continued low dose corticosteroids for many years. In agreement with this, the Systemic Treatment for Eye Disease Cohort Study (SITE) study also reported that on long-term the systemic treatment approach with antimetabolites and calcineurin inhibitors is safe (Gangaputra, Newcomb et al. 2009, Pasadhika, Kempen et al. 2009, Daniel, Thorne et al. 2010).

In summary, systemic immunosuppressive therapy in non-infectious intermediate, posterior and panuveitis is a better initial treatment option as multiple relapses occur with local treatment. The use of local treatment is reserved for patients intolerant to systemic treatment or when such treatment is ineffective (Jabs 2017).

1.3.13.1.1 Systemic corticosteroid therapy

Corticosteroids are invaluable in the rapid control of inflammation, and they should be used in acute management but are not suitable at higher doses for long-term therapy. In sarcoid associated uveitis, for example, studies have shown that oral corticosteroid therapy is associated with a 93% reduction in the odds of visual impairment (Dana, Merayo-Llives et al. 1996). Prednisolone is the most commonly used drug, and the starting dose is 1-2 mg/kg per day tapered gradually over the next 2-4 weeks. Alternatively, a pulse of 1 gm methylprednisolone daily for three days can be used initially followed by oral corticosteroids for sight-threatening conditions.

Low dose corticosteroid therapy can help to maintain disease control in patients with sight-threatening uveitis. However, if the patient requires long-term corticosteroid therapy, the target dose is <7.5 mg per day. Systematic reviews of studies in rheumatoid arthritis patients showed no increased risk of corticosteroid side effects at this dose over the course of months to years. However, there is an increase in

cardiovascular morbidity and mortality with large cumulative doses of prednisolone (risk is seen at doses of prednisolone at 5 mg per day for 22 years or 7.5 mg for 15 years) (Jabs 2017). Therefore, in patients receiving long-term corticosteroid treatment, subsequent reduction of corticosteroid dose should be made with successively smaller decrements to minimise the risk of disease relapse and corticosteroid withdrawal.

A steroid-sparing agent should be initiated if higher doses of corticosteroids are needed to achieve control of inflammation, and this generally occurs in patients with chronic sight-threatening uveitis, especially when associated with systemic inflammation. Special consideration to gastric protection should be given due to the high-risk of peptic ulcer disease. Also, Dual Energy X-ray bone scans (DEXA) should be requested for high-risk patients along with supplementing their diet with calcium and vitamin D tablets (Foster, Kothari et al. 2016). Besides, regular checks for blood sugar levels and body weight.

Corticosteroids have a wide range of side effects as they can adversely affect almost any organ in the human body (Lee, Bajwa et al. 2014). Systemic side effects of corticosteroid are given in Table 1-9.

Table 1-9 Side effects of systemic corticosteroids therapy (Stanbury and Graham 1998)

<p>Dermatological</p> <ol style="list-style-type: none">1. Corticosteroids cause skin fragility.2. Increase body hair3. Easy bruising, facial erythema, increased sweating,4. Acne, striae and delayed wound healing. Therefore, care must be exercised to avoid injury.
<p>Haematological</p> <ol style="list-style-type: none">1. Corticosteroids increase total white blood cells count, particularly PMN (Neutrophils),2. Decrease lymphocyte population, mainly T cells. B cells and immunoglobulin production is also reduced with corticosteroid use.3. Reduce monocytes and eosinophils.4. Corticosteroid enhances blood coagulation.
<p>Fluid and electrolytes</p> <ol style="list-style-type: none">1. The use of corticosteroids is associated with water and sodium retention, thus increase blood pressure, which can lead to the development of heart failure.2. CS is associated with loss of potassium.

Endocrine

1. Corticosteroids are notoriously known to cause Cushing's syndrome (moon face, central obesity and increase fat content at the back of the neck). However, subject's susceptibility to CS is variable with some having cushingoid features on 15 mg per day, while for others higher doses can lead to Cushing's syndrome. Additionally, weight gain is a common side effect of CS.
2. Corticosteroids increase gluconeogenesis and blood glucose by 10-20% while decrease sensitivity to insulin. Patients must have their blood sugar checked every visit since one-fifth of patients may develop 'steroid induced diabetes' which may necessitate the initiation of hypoglycemic medications. This form of diabetes is reversible once corticosteroid treatment is discontinued. Diabetes is not a contraindication to CS therapy, however, patients should be aware of the fact that their blood sugar control is likely to deteriorate.
3. Interestingly hypophyseal pituitary adrenal axis can be suppressed even with a small amount of CS. Treatment for two or more weeks above physiological levels (greater than prednisolone 7.5 mg/ day), will cause impairment of endogenous corticosteroids synthesis which could be overt in acute stress such as trauma or surgery. Therefore, patients must not stop their CS suddenly.
4. Sex hormones are usually reduced on CS therapy. Sex hormones (estrogen and progesterone) play an important role in bone metabolism and they are co-factors in the development of corticosteroid-induced osteoporosis. Corticosteroids increase serum lipids both total cholesterol and triglycerides.

Pregnancy and lactation

1. CS has been reported to increase the risk of cleft lip and palate in animals. Intrauterine growth retardation in humans has also been reported. CS is secreted in breast milk in small amounts which can lead to an adrenal suppression in an infant.
2. CS inhibits growth, the mechanism is fully known, however, it may involve both, reduction in growth hormone production and direct inhibition on bone and connective tissue. Low doses of CS (below 10-15 mg) on alternating days did not lead to a significant growth retardation (unlike other side effects). However, at such low doses, the efficacy of CS in controlling the ocular inflammatory disease is lost.

Musculoskeletal

1. After a few years of CS treatment, patients will have an increased risk of osteoporosis and fracture. Patients given CS have an increased incidence of fracture (between 10% and 20%). The highest rate of bone loss occurred within the first 6 months of CS treatment and the rate of bone loss continued as long as CS is administered. Therefore, patients undergoing long-term CS therapy should have their bone mineral density checked annually using dual energy X-ray absorptiometry.
2. Osteonecrosis, formerly known avascular necrosis is a serious complication of CS and affects between 5 to 25% of patients and seldom seen in the first six months. The risk increases with time and dose of corticosteroid. The head of the femur is commonly involved; however all large joints could be affected. The earliest symptoms are joint pain and stiffness, and these should raise the alarm for this dreadful complication.
3. CS reduces muscle protein production and increase protein catabolism leading to loss of muscle bulk and weakness and in advanced cases 'steroid myopathy' develops (mainly in proximal muscles). This side effect may persist even after stopping CS therapy.

Behavioural changes

1. The most common side effects are euphoria, mood swings and depression.
2. CS can worsen pre-existing psychiatric problems and, even previously stable personalities can experience severe depression and become suicidal (Carpenter and Gruen 1982).
3. Sleep disturbances and insomnia are well-recognized complications.
4. Psychosis usually occurs after two weeks at doses greater than 40 mg prednisolone per day.

Infection

1. CS increase susceptibility to infections and also infections may be masked or present in an atypical way and advances to septicemia in patients on CS therapy.
2. Reactivation of latent TB and varicella infection (shingles).

Gastrointestinal

The three main GI side effects are;

1. Peptic ulcer disease,
2. Candidiasis and
3. Pancreatitis.

Therefore, for practical reasons patients on corticosteroids are prescribed prophylactic treatment with H2 receptor blocker or proton pump inhibitor, such as omeprazole.

1.3.13.2 Immunomodulatory therapy for uveitis

Immunomodulatory treatment (IMT) can offer uveitis patients a corticosteroid-sparing effect with more therapeutic efficacy. Because these agents act by targeting one or

more aspects of the immune response two agents from different classes can be used simultaneously. The main indications for starting IMT therapy are shown in table.1-10.

Table 1-10 Indications for initiating systemic non-corticosteroids immunomodulatory therapy (Dick, Rosenbaum et al. 2018).

Ocular indications	Therapeutic indications
<ul style="list-style-type: none"> • An acute sight-threatening disease that severe enough to compromise vision, increase in vitreous haze of 2 or more on SUN criteria, or relapse of CMO • Chronic and persistent inflammation • Presence of exudative retinal detachment • Posterior and macular involvement • Binocular sight-threatening disease 	<ul style="list-style-type: none"> • Failure to respond to periocular corticosteroids injections or topical corticosteroids. • Active uveitis while on higher doses of systemic corticosteroids, such as 30 mg per day or more • Relapse of uveitis after reducing the daily corticosteroids to ≤ 10 mg • Corticosteroids intolerance. • Need for corticosteroid-sparing effect.
<p>Certain diseases such as JIA when there are poor prognostic factors for vision loss such as reduced visual acuity at presentation, posterior segment involvement, the presence of uveitis complication (cataract, glaucoma, synechiae and ocular hypotony)</p>	

1.3.14 Types of immunomodulatory therapy:

1.3.14.1 Antimetabolite: (methotrexate, azathioprine and mycophenolate mofetil)

Antimetabolites act by inhibiting nucleotide and DNA synthesis thus suppresses rapidly proliferating cells, such as lymphocytes.

Azathioprine

Azathioprine is a synthetic, purine analogue. Its mechanism of action is poorly understood. However, it's thought that one of its active metabolites, the 6-thioguanine nucleotides, has a similar structure to guanine and binds to DNA leading to its fragmentation (Derijks and Hommes 2006, Patel, Swerlick et al. 2006). This effect is marked in T lymphocytes since these cells rely on the de novo synthesis of purine for DNA replication (Tiede, Fritz et al. 2003). Thiopurine methyltransferase (TPMT) enzyme testing is essential before starting azathioprine therapy since patients deficit with this enzyme, which is involved in azathioprine metabolism, are prone to develop life-threatening severe bone-marrow toxicity (Sayani, Prosser et al. 2005).

The dose of azathioprine is 1mg/kg up to 2.5 -4 mg/kg per day (Jabs, Rosenbaum et al. 2000). The side effects commonly associated with azathioprine use are gastrointestinal upset such as loss of appetite, nausea, and diarrhoea. Other side effects are fatigue and bone marrow suppression (leukopenia, thrombocytopenia, and anaemia). Nevertheless, azathioprine is well tolerated in patients with ocular inflammatory diseases (Tamesis, Rodriguez et al. 1996).

Mycophenolate mofetil (MMF) (CellCept®)

MMF is a prodrug of mycophenolic acid, and it is widely used in treating ocular inflammation. MMF has two main mechanisms of action; firstly, it selectively inhibits the proliferation T and B lymphocytes so that it suppresses cell-mediated immune responses and antibody production. This action mediated by reversible blocking of enzyme inosine 5 monophosphate dehydrogenase involved in the biosynthesis of purine (Allison 2005). The second mechanism of action is repressing the glycosylation and the expression of adhesion molecules, thereby reducing the number of inflammatory cells reaching the site of inflammation (Allison, Kowalski et al. 1993). MMF also reduces NO synthesised by activated macrophages, and therefore, reduces tissue destruction (Senda, DeLustro et al. 1995).

MMF was initially used to prevent graft rejection in organ transplantation (Cho, Danovitch et al. 1995). Then it was used to treat various autoimmune disease, such as SLE and Crohn's disease (Adu, Cross et al. 2001, Miehsler, Reinisch et al. 2001).

The first published reports for the use of CellCept in ocular inflammation have reported success in a small cohort of patients (Kilmartin, Forrester et al. 1998, Larkin and Lightman 1999, Lau, Comer et al. 2003). The control of ocular inflammation with MMF and reduction of steroid dose ≤ 10 mg per day was achieved in 82% of patients' with chronic non-infectious uveitis (Thorne, Jabs et al. 2005). Analysing data from six different studies on 241 patients with chronic recalcitrant uveitis showed stability or improvement in visual acuity, improved inflammatory parameters and reduction in the number of disease relapses in most patients (Pato, Muñoz-Fernández et al. 2011).

The most common adverse reactions associated with MMF use, are gastrointestinal upset, leukopenia and increased risk of opportunistic infection (Behrend 2001). Also, there is an increased risk of lymphoma and other malignancies with an observed percentage of 0.4 to 1% of patients on MMF. There was a slightly higher incidence of non-melanoma skin cancer (1.6 - 4 %) (Group 1995, Keown, Häyry et al. 1996). Contrary to this, in a comprehensive review, MMF was not associated with increased cancer risk or mortality (Kempen, Gangaputra et al. 2008, Kempen, Daniel et al. 2009). The recommended daily dose in inflammatory ocular disease is 1 to 3 gm per day.

Methotrexate

Methotrexate is a folic acid analogue that inhibits dihydrofolate reductase enzyme. It inhibits purine synthesis and thereby inhibits the synthesis of DNA, RNA and other proteins genes. However, other mechanisms such as suppression of the activity and the synthesis of inflammatory cytokines and adhesion molecules have also been reported (Segal, Mozes et al. 1989, Cronstein 1996, Johnston, Gudjonsson et al. 2005). Therefore oral supplements with folic acid are essential to limit drug toxicity. Methotrexate dose ranges between 7.5- 25 mg weekly, with folic acid 1 mg daily.

Among all other antimetabolites, methotrexate is the most extensively used agent in ocular inflammatory disease, and it has a long-term efficacy and safety profile both in children and adults. The lower cost and convenience of use (once weekly administration) has positioned this drug to be a first-line steroid-sparing agent for many systemic and ocular inflammatory disease. The main side effects associated with

methotrexate use are gastrointestinal upset, bone marrow suppression, liver toxicity and pulmonary fibrosis (Foster, Kothari et al. 2016).

The SITE study (a large retrospective study on 639 eyes in the US, between 1979 and 2007) examining the efficacy of methotrexate in ocular inflammatory disease reported that methotrexate has a moderate effectiveness in controlling the ocular inflammation and achieving a corticosteroid-sparing effect (prednisolone \leq 10 mg/d) (Gangaputra, Newcomb et al. 2009). In the SITE study, methotrexate was discontinued by 52% of patients, and side effects were responsible for 16%, and these occurred early in the treatment course. By one year, methotrexate was discontinued due to lack of efficacy in 15.5% of patients. Some authors suggested that methotrexate may have better efficacy in some ocular inflammatory conditions such as JIA (Foeldvari and Wierk 2005), and non-JIA uveitis in childhood. Intravitreal methotrexate at 400 micrograms in 0.1 ml was successful in improving vision and reducing the amount of CMO in some patients with uveitis (Taylor, Habet-Wilner et al. 2009, Taylor, Banker et al. 2013).

To conclude, methotrexate has modest efficacy in ocular inflammation. Compared to anterior uveitis, control of inflammation and corticosteroid-sparing success occurred less frequently in IU, posterior and panuveitis. Methotrexate therapy was well-tolerated by most patients, and the risk of severe side effects was little.

1.3.14.2 Calcineurin inhibitors (T cells inhibitors): cyclosporine A, tacrolimus and sirolimus.

Calcineurin inhibitors act by suppressing T-cell signalling, activity and growth.

Cyclosporine is the most commonly used agent in this class at doses ranging from 1-5 mg per kg per day. Cyclosporine suppresses antigen triggered T lymphocytes and inhibits the expression of pro-inflammatory lymphokines, particularly IL-2, which is essential for proliferation and maturation of T lymphocytes and amplifies immune reactions. Cyclosporine also inhibits INF- γ which is necessary for activation of macrophages (Kacmaz, Kempen et al. 2010).

The analysis of data regarding the efficacy of cyclosporine CsA in non-infectious posterior intermediate and panuveitis showed varying results concerning drug efficacy. A study examined the effect of cyclosporine in 56 subjects with posterior,

intermediate and panuveitis treated with either oral corticosteroid or cyclosporine, did not show differences between the two groups regarding improvement in visual acuity or level of inflammation. The inflammation was controlled in approximately 50% of patients in each group. The efficacy of cyclosporine was not superior to corticosteroids, however, hypertension and increased creatinine were higher in the CsA group (Nussenblatt, Palestine et al. 1991). In the same study patients who failed each drug alone gained additional improvement in disease control when used a combination of both. However, this was Sandimmune where the bioavailability of cyclosporine in this formulation was poor.

Doses between 151-250 mg are successful in controlling ocular inflammation. Major side effects include bone marrow suppression, renal toxicity, hypertension, hyperlipidemia, gum hypertrophy, hirsutism, and haemorrhage (Foster, Kothari et al. 2016). In the SITE study, drug-related toxicity on cyclosporine was reported in 10.7% of patients, with renal toxicity and hypertension being the most common side effects. Interestingly, subjects > 55 years of age were three times more likely to develop drug-toxicity compared to younger subjects (Kacmaz, Kempen et al. 2010).

Tacrolimus

Tacrolimus is a natural metabolite of the bacterium *Streptomyces tsukubaensis*. The dose of tacrolimus ranged from 0.05 to 0.2 mg/kg per day. Both tacrolimus and cyclosporine have a similar action in modulating the immune system, but tacrolimus has a more potent immunosuppressive effect. Both drugs modulate the activity of CD+4 T cells via the suppression of interleukin 2 (IL-2) production (Peters, Fitton et al. 1993) an action that is relevant to treating non-infectious uveitis which is a T cell-mediated disease. However, in non-infectious uveitis tacrolimus has similar efficacy to cyclosporine, and was better tolerated. A study compared the effectiveness of tacrolimus and cyclosporine in posterior uveitis did not find any differences in visual acuity and improvement in ocular inflammation. However, the side effects of cyclosporine were higher (hypertension and increase cholesterol levels) (Murphy, Greiner et al. 2005).

1.3.14.3 Alkylating agents: chlorambucil and cyclophosphamide

1. Chlorambucil 0.15 mg/kg per day
2. Cyclophosphamide 1 mg/kg per day

These are more potent immunomodulatory agents and are usually reserved for uveitis unresponsive to other immune suppressive therapies, and are rarely used now. Cyclophosphamide has a cytotoxic effect on rapidly dividing cells by alkylating nucleotide bases within the DNA and inducing damage to its structure, thereby interfering with DNA replication. Cyclophosphamide used as cancer chemotherapy and for inducing remission in autoimmune diseases such as GPA, polyarteritis nodosa and kidney disease associated with systemic lupus erythematosus (Durrani, Papaliadis et al. 2004). It can be given as an intravenous infusion and orally. However, it is associated with a variety of toxic side effects including sterile haemorrhagic cystitis, bladder carcinoma, other secondary malignancies, bone marrow suppression and sterility. Therefore, weekly blood tests monitoring is warranted to screen for drug toxicity and severe bone marrow suppression (Foster, Kothari et al. 2016).

Studies looking at the effect of chlorambucil in Behcet's disease, sympathetic ophthalmia, serpiginous choroiditis and other uveitides showed improvement in inflammation and stability or improvement in visual acuity (Pato, Muñoz-Fernández et al. 2011). Cyclophosphamide did not appear useful in Behcet disease (Ozyazgan, Yurdakul et al. 1992). However, it was effective in controlling other intraocular inflammatory conditions such as serpiginous choroiditis, none had disease recurrence while on therapy, and most patients (7 out of 9) achieved prolonged drug-free remission from 15 to 96 months (Akpek, Jabs et al. 2002). The side effects reported were: transient bone marrow suppression, nausea, fatigue, and bladder cancer in one patient. Another study looked at the effect of cyclophosphamide in patients with ocular inflammatory conditions mainly related to rheumatoid arthritis, and systemic lupus erythematosus showed favourable outcome (Durrani, Papaliadis et al. 2004). The vision was maintained in 66% of patients and improved in 21%, and cyclophosphamide achieved corticosteroid-sparing effect in all patients. However, due to severe systemic toxicities, these agents are not used currently for ocular inflammation.

1.3.14.4 Biologics

A biologic is a therapeutic medical product formed by biological processes, and this involves a recombinant DNA. Biologics fall into three main categories.

1. Monoclonal antibodies such as, infliximab and adalimumab are known to target $\text{TNF}\alpha$, rituximab against CD20, which is primarily found on the surface of B cells. The suffix *-mab* refers to all monoclonal antibody while the prefix can be anything. *lim* in *adalimumab* relates to the immune system, *u* is for a human. The *xi* in *Infliximab* and *rituximab*, is for chimeric (both human and mouse portions). The *tu* in *rituximab* is for a miscellaneous *tumour* since rituximab was initially used against B cells, non-Hodgkin's lymphoma.
2. Fusion proteins of a known receptor added to an immunoglobulin segment, an example is etanercept which is a TNF receptor attached to IgG1 (Fc)
3. Signalling molecules reproduced via biosynthesis. An example is an interferon.

With regards to targeting cells and signals, biological agents can deplete cells, e.g. Rituximab anti-CD20, inhibit or modulate function. A biologic agent can also interfere with signalling molecules (cytokines) in two ways, either inhibit function, e.g. infliximab and adalimumab or utilise function, e.g. interferon.

1.3.14.4.1 TNF α and its role in immune responses

TNF α is a potent proinflammatory cytokine that is mainly produced by macrophages and activated T cells. Other retinal cells also participate in TNF α syntheses such as microglia, REP, and Müller cells. TNF α is a protein that composed of three identical polypeptide units. It is present in two forms, transmembrane and soluble. When TNF α is synthesized its membrane-bound, however, matrix metalloproteinases (MMP) results in proteolytic cleavage and releases the soluble forms. These two forms will interact with two types of receptors TNFR1 (p55) and TNFR2 (p75). It was proposed that p55 receptor is implicated in pro-apoptotic and inflammatory pathways, whereas p75 is involved in cellular proliferation (Rodrigues, Farah et al. 2009). These receptors are found on the surface of most body cells. Once the TNF α interacts with the receptors it initiates a complex intracellular transduction cascade. The outcome of this interaction depends on many factors including cell and receptor types. TNF receptors can also present in a soluble form to neutralize TNF, so they act as a natural inhibitors (Pleyer and Foster 2007).

Classically, TNF α plays a crucial role in the induction and maintenance of an inflammatory response. TNF α induces proliferation and activation of T cells and macrophages and upregulates several inflammatory cytokines. Further, TNF α upregulates the expression of adhesion molecules such as E-selectin and ICAM (Mulligan, Varani et al. 1991). However, biological roles of TNF α is complex and TNF can also serve as a mediator of immune regulation. For example, TNF α is implicated in apoptosis of tumour cells, suppression of autoreactive T lymphocytes, and is a main cytokine involved in granuloma formation thereby helps containing infectious pathogens such as mycobacteria.

TNF α is a pleiotropic cytokine that can mediate a wide variety of immune reactions. These different functions of TNF α can be explained by the type of the receptor stimulated by TNF α . For example, TNFRp55 is necessary for the inflammatory reaction in autoimmune diseases, whereas TNFRp75 mediates normal lymphoid development and immune regulatory functions of TNF α (Kollias 2005). Alternately, the timing, quantity of TNF α in a specific environment can have a significant influence on its biological role (Kollias, Douni et al. 1999).

The role of TNF as a key pro-inflammatory cytokine and has been extensively studied in experimental autoimmune uveoretinitis (EAU). EAU is a CD4+Th1 mediated autoimmune reaction against the soluble retinal antigens. This immune response is mediated by infiltration of antigen-specific T cells and macrophages, and lead to severe inflammation. The administration of TNF α worsens disease activity while blocking TNF α resulted in suppression of inflammation. Moreover, the neutralisation of TNF α activity with TNFp55 fusion protein, inhibits Th1 activity, suppresses the activity of macrophages and limits tissue damage. Additionally, blocking TNF α in the retina resulted in a shift in T cell responses from Th1 to Th2, which implies an immunomodulatory effect (Dick, Forrester et al. 2004).

1.3.14.5 Biologic response modifiers (biologics)

Biologic response modifiers are recombinant proteins or antibodies that aim to target the inflammatory mediators such as, cytokines/chemokines or their receptors. They help reduce the inflammation and achieve better disease control. There are different classes of biologics, including anti TNF agents, anti-IL agents, anti B cell agents, interferons, anti-vascular endothelial growth factor and antibodies against specific IL receptors (Levy-Clarke, Jabs et al. 2014) The two extensively studied agents in the field of ocular inflammatory disease are infliximab and adalimumab, both are anti-TNF α monoclonal antibodies (Bhatt, Tucker et al. 2016) (Lee, Bajwa et al. 2014).

The 5 TNF α blockers are:

1.3.14.5.1 Etanercept (*Enbrel*®)

Etanercept is a fusion protein that neutralises the activity of TNF α and TNF β (Lymphotoxin α) by binding to soluble and transmembrane TNF. It consists of an extracellular ligand-binding portion of TNFRp75 attached to Fc domain of human IgG1.

Etanercept is commonly used at a dose between 20-50 mg once or twice weekly (Zhou 2005). It has been used successfully to treat joint disease in rheumatoid arthritis, but its efficacy in uveitis patients is not seen (Foster, Tufail et al. 2003, Schmeling and Horneff 2005). In a randomised controlled trial on 20 patients with recurrent uveitis, there was no difference in the rate of disease recurrences or visual acuity between

etanercept and placebo (Foster, Tufail et al. 2003). Similarly, Smith and co-authors showed no therapeutic benefits with etanercept in patients with JIA related chronic anterior uveitis (Smith, Thompson et al. 2005) Furthermore there were reports of uveitis and scleritis occurring on etanercept (Lim, Fraunfelder et al. 2007) (Gaujoux-Viala, Giampietro et al. 2012). Therefore, etanercept is not suitable for non-infectious uveitis.

The effect of etanercept in ocular inflammation was less impressive when compared to other anti-TNF α agents, such as infliximab and adalimumab. The differences in molecular structure between these agents might explain the reduced efficacy of etanercept. Firstly, etanercept is a fusion protein whereas infliximab is a monoclonal antibody. Secondly, unlike infliximab, etanercept makes unstable complexes with TNF α and dissociates quickly leaving active biologic forms of TNF α behind, thus, its effect in neutralizing TNF α is transient. Thirdly, one receptor binding site on TNF α molecules remains open even in the abundance of etanercept. Therefore, theoretically, TNF α molecule has still one active site. Finally, the interaction between etanercept and transmembrane TNF α is inconsistent and therefore etanercept blocks the soluble form of TNF α molecule only while infliximab and adalimumab block both forms (transmembrane and soluble). Thus, etanercept may have a small effect on signalling pathway via TNFRp75 (Pleyer and Foster 2007).

1.3.14.5.2 Infliximab (*Remicade*)

Infliximab is a chimeric monoclonal antibody (Calabrese 2003). The antigen binding (Fab domain) is of mouse origin whereas the (FC portion) is of human origin. It neutralises the action of TNF α by binding to its soluble and transmembrane forms. Once infliximab binds to both types of TNF α , it forms stable complexes preventing the interaction of TNF α and its receptors hence counteracting its biological action (Scallon, Cai et al. 2002). Further, Infliximab, as well as adalimumab, can destroy cells that continually express transmembrane TNF α , by complement-mediated cytotoxicity. Also, they have the ability to activate the complement-dependent cytotoxicity and induce lysis of activated T cells and macrophages via the membrane attack complex through the classical pathway (Mitoma, Horiuchi et al. 2008).

The serum half-life of infliximab is approximately 9.5 days which is longer than etanercept (4.25 days). Infliximab has FDA approval for rheumatoid arthritis, Crohn's disease, ulcerative colitis, ankylosing spondylitis and psoriasis in adults (Levy-Clarke, Jabs et al. 2014). The commonly used dose is 5-20 mg /kg given as an intravenous infusion at 0, 2, and six then every eight weeks. It is recommended as a combination therapy with methotrexate to reduce antibody formation (Lee, Bajwa et al. 2014, Levy-Clarke, Jabs et al. 2014).

Since infliximab has a mouse portion within its structure, there is a potential for the development of human anti-chimeric antibodies (HACA), and these can reduce the efficacy of the treatment after repeated infusions. It is not possible to check for these antibodies while a patient is on therapy because infliximab in serum counteracts the test results (Maini, Breedveld et al. 1998). Therefore, these can only be tested after stopping the treatment. Maini and co-workers showed that concomitant administration of low-dose methotrexate reduced the percentage of HACA from 53% in patients with infliximab alone, to 0% when used with methotrexate. Clinical trials have shown that approximately 10% of patients on infliximab were antibody positive and were more prone to develop allergic reactions *Remicade® (infliximab) leaflet*.

In non-infectious uveitis, there is an increasing body of evidence regarding the efficacy of infliximab in treating ocular manifestations of Behcet's disease and juvenile idiopathic arthritis resistant to other immune modulatory agents (Galor, Perez et al. 2006, Al Rashidi, Al Fawaz et al. 2013).

1.3.14.5.3 Adalimumab (Humira®)

Adalimumab is the first fully humanised IgG1 antibody that neutralises TNF α . It acts like infliximab, by binding to soluble and transmembrane TNF α (Weinblatt, Keystone et al. 2003). Adalimumab is delivered by subcutaneous injection at doses of 40 mg every other week or even weekly if necessary aiming for better control of the disease activity. The mean half-life is approximately two weeks, ranging from 10 to 20 days Table 1-11 (Diaz-Llopis, Garcia-Delpech et al. 2008, Levy-Clarke, Jabs et al. 2014).

Adalimumab is FDA approved for treating rheumatoid arthritis, ulcerative colitis, psoriatic arthritis, ankylosing spondylitis, Crohn's disease and plaque psoriasis in

adults and recently has been approved to treat uveitis in the US. It was used for ocular inflammation secondary to sarcoidosis, JIA and Behcet's disease (Callejas-Rubio, Ortego-Centeno et al. 2006, Vazquez-Cobian, Flynn et al. 2006, Mushtaq, Saeed et al. 2007). Because of subcutaneous administration, adalimumab has a more stable delivery and is conveniently administered by patients at home, whereas, infliximab is given by intravenous infusion in hospitals. Please see Table 1-11.

Since Adalimumab is fully humanised, it appears less immunogenic than infliximab and theoretically it is associated with less production of Ab and have a better safety profile. However, there is still a potential for the development of anti-adalimumab antibodies, and these were responsible for the enhanced clearance of adalimumab. The concurrent therapy with methotrexate led to decreased adalimumab clearance by 29 % and 44 % after single and multiple dosing, respectively (Tabrizi, Tseng et al. 2006).

Adalimumab was successful in patients with non-infectious uveitis who failed multiple drug therapy. A higher success rate was reported in paediatric patients with JIA associated uveitis with 88% responding to treatment; the response was defined either one or two relapses less than before adalimumab (Biester, Deuter et al. 2007). Vazquez-Cobian et al. reported reduced inflammation in 80% of patients (9 JIA and five idiopathic uveitis) for an average of 18 months on adalimumab therapy (Vazquez-Cobian, Flynn et al. 2006).

1.3.14.5.4 Vedolizumab

Vedolizumab is a monoclonal antibody that binds to $\alpha 4\beta 7$ integrin on T helper lymphocytes, and used mainly in inflammatory bowel disease at doses of 300mg at 0, 2, 4 weeks then every 8 weeks. BNF.NICE.org.UK.

1.3.14.5.5 Golimumab

Golimumab is another fully humanised monoclonal antibody IgG1 anti-TNF α . It has identical amino acid sequences in both heavy and light chains to infliximab, but unlike infliximab, it's fully humanised. Golimumab is given subcutaneously at a dose of 50 mg once a month; however, the treatment can be increased to 100 mg in unresponsive or patients over 100 kg body weight (Cada, Levien et al. 2009).

1.3.14.5.6 Daclizumab (IL-2 inhibitor)

Daclizumab is a humanised monoclonal antibody works by binding to CD25, the alpha subunit of the IL-2 receptor of T cells. The dose is 1-2 mg/kg/IV. A randomised placebo-controlled trial looked at the effect of Daclizumab in Behcet's patients found that Daclizumab lacked efficacy in disease control and corticosteroid-sparing effect (Buggage, Levy-Clarke et al. 2007). The authors reported that the placebo group had less relapses in ocular inflammation, and more significant reduction in immunosuppressive medication compared to daclizumab. This drug was withdrawn later from the market due to reports of drug-induced autoimmune fulminant hepatopathy and encephalitis (Perez-Miralles 2018).

Table 1-11 Key features and differences between different types of TNF α agents adopted from (Pleyer and Foster 2007)

Characteristics	Infliximab	Adalimumab	Etanercept
Type of the drug	Monoclonal ab Chimeric	Monoclonal ab Fully humanised	Fusion protein
TNF α interaction TNF α and drug binding Membrane TNF α Blockage	High-affinity stable Good	High-affinity stable Good	Unstable Poor
Administration			
Route	Intravenous	Subcutaneous	Subcutaneous
Periodicity	0,2,6 then 6 weekly	Weekly to 2 – weekly	Twice a week to weekly
dose	3, 5 or 10 mg/kg	20 mg/week to 40 mg/2-weekly	25 mg biweekly, 50 mg /week
Half-life	10 days	14 days	4 days
Side effects Tuberculosis risk Lymphoma Demyelination Autoantibodies /anti-drug antibodies	High Increased Reported Common	High Increased Reported Common (less than infliximab)	low Increased Reported Common (rare)

1.3.14.5.7 Side effects of anti-TNF α agents

Anti-TNF agents are well-tolerated. However, they can cause several adverse events, and these include increased risk of infection, development of autoimmune diseases while on therapy, and immune-mediated resistance to treatment. These antibodies can be immunogenic (perceived as foreign bodies leading to immune reaction) resulting in immune reactions against them shortly after their administration (Presta 2006). The spectrum of this immune reaction ranges from local inflammation at the site of injection, flu-like symptoms, pyrexia to acute anaphylaxis which could be life-threatening (Chung 2008).

Infection is one of the most important and serious side-effect associated with anti-TNF α use. Treatment with biologics will cause a state of acquired immunodeficiency which predisposes patients to different types of opportunistic bacterial, fungal, and viral infections. Reactivation of latent TB is a well-recognised complication of infliximab therapy (Accorinti, Pirraglia et al. 2007), and severe infection with fatal sepsis have also been reported (Singh, Wells et al. 2010, Levy-Clarke, Jabs et al. 2014). The predisposition for latent TB reactivation illuminates the fact that TNF plays a fundamental role in immunity and protective granulomas that contain *Mycobacterium tuberculosis* (Keane 2005). In line with this, in Denmark, it has been reported that anti-TNF drugs increase the risk of TB reactivation four-fold compared to the general population (Nordgaard-Lassen, Dahlerup et al. 2011).

Albeit, TNF α antagonists vary in their risk of TB reactivation. A survey of all adverse events reported with TNF α over a span of 4 years found 129 per 100,000 infliximab-given patients in comparison to 60 per 100,000 for etanercept (p-value <0.001) (Wallis and Ehlers 2005). This variation in the risk of TB reactivation reflects the differences in efficacy between anti-TNF α agents. Infliximab neutralises all biologically active TNF α . Further, infliximab was shown to induce apoptosis of monocytes and T cells specifically active against mycobacterial antigens (Wallis and Ehlers 2005). For this reason, the patient's tuberculosis (TB) status should be checked before the commencement of any anti-TNF agent.

TNF α inhibitors have been associated with the development of new or worsening of pre-existing demyelinating disease, particularly multiple sclerosis MS (van Oosten,

Barkhof et al. 1996, 1999). Therefore, great caution should be exercised in patients with intermediate uveitis since some may have, or develop MS (Cunningham and Zierhut 2010). Interestingly, higher levels of TNF α in CSF of patients with active MS lesions was shown, and the trial of anti-TNF α in animal studies showed reduced disease activity (Selmaj, Raine et al. 1991). These findings highlight the dual effect of TNF α in neuronal disease (Akassoglou, Probert et al. 1997).

Also, cardiac adverse events including congestive heart failure and angina have been reported with anti-TNF α use. (Hansel, Kropshofer et al. 2010). Moreover, the use of anti-TNF is associated with the development of antinuclear and anti-double-strand DNA antibodies which can be a sign of SLE-like syndrome (Ramos-Casals, Brito-Zeron et al. 2007). However, the development of lupus-like syndrome and musculoskeletal symptoms is rare, and these generally disappear after discontinuation of the therapy (Haraoui and Keystone 2006). A lupus-like illness was documented in some patients who developed polyarthropathy and were positive for anti-ds DNA Ab (Suhler, Smith et al. 2009). Other rare autoimmune diseases reported with TNF α blockers are sarcoidosis, inflammatory bowel disease, psoriasis and anterior scleritis (Levy-Clarke, Jabs et al. 2014).

Finally, because TNF α plays an important role in CD8 lymphocytes function, which participate in the destruction of tumour cells, there is a potential risk for malignancy in patients on TNF α blockers. Some patients developed fatal solid tumours on Infliximab, but the causal relationship was unclear (Suhler, Smith et al. 2009). Also, lymphoma development in the paediatric population was reported with the use of infliximab (de Vries, van Oijen et al. 2008). However, Kempton and co-authors in their critical review and analysis on large observational studies have refuted this notion. Nonetheless, they have reported that TNF α blockers may allow the pre-existing malignancy to grow faster but their use do not induce cancer (Kempen, Gangaputra et al. 2008). In line with these results, a meta-analysis on 29,423 patients on biologics reported that the risk of malignancy was similar in comparison to other disease-modifying anti-rheumatic drugs and placebo, with only (0.72%) developing malignancy (Lopez-Olivo, Tayar et al. 2012). However, biologics were reported to increase the risk of lymphoma by 2-3 fold a risk that is higher infliximab compared to etanercept (Mariette, Tubach et al. 2010).

TNF α blockers are associated with increased risk of treatment failure, which can be partly attributed to the immunogenicity of anti-TNF α agents and development of antidrug antibody (de Vries, Wolbink et al. 2007, Bartelds, Krieckaert et al. 2011). While the incidence of anti-drug antibody increases with the longer duration, these antibodies can shorten the clinical response time and increase the risk of infusion reactions and subsequent discontinuation of the treatment (Plasencia, Pascual-Salcedo et al. 2012). A meta-analysis of 856 patients with autoimmune inflammatory diseases, the antibodies against infliximab and adalimumab reduced drug response by 68%, nevertheless, the simultaneous use of methotrexate or azathioprine decreased the frequency by almost 50% (Garces, Demengeot et al. 2013).

Contraindications to use of anti-TNF α agents include evidence of active infection, previous lymphoproliferative disorders, moderate to severe heart failure, chronic hepatitis B and C, pneumonitis and presence of any demyelinating disorder (Levy-Clarke, Jabs et al. 2014). Therefore, before initiating anti-TNF α blockers, baseline laboratory screening including complete blood count, liver function tests, renal function tests and electrolytes, screening for tuberculosis and hepatitis C and B viruses are performed.

The anti-TNF α blockers are only approved for systemic administration. There are several, pilot studies on the use of infliximab via the intravitreal route to treat uveitis, CMO and macular degeneration. However, it was toxic on the retina, and this was documented by a decline in electroretinogram amplitude, worsening in microperimetry and even the development of de novo uveitis (Giganti, Beer et al. 2010).

1.3.14.6 Interferon α (INF α)

Interferon is a cytokine that is secreted by virus-infected cells to help these cells in resisting viral infections, by causing degradation of viral messenger RNA and inhibition of protein synthesis. INF α has antiviral, antiproliferative and immunomodulatory effects. The most common side effects are flu-like symptoms, leukopenia, thyroid hormone dysregulation and alopecia. There are two different recombinant human INF- α s (INF- α 2a and INF- α 2b). They differ in 1 amino acid only (Foster and Finter 1998) (Lin and Young 2014). INF- α alters the immune responses towards Th1 stimulating the activity of cytotoxic cells and natural killers and increases the expression of MHC

class I antigen on lymphocytes and antigen presenting cells (Belardelli and Gresser 1996, Belardelli, Ferrantini et al. 2002). All of these mechanisms might help in clearing the offending antigen such as viruses (Kötter, Günaydin et al. 2004). Additionally, other immunosuppressive effects of INF- α include interfering with the adhesion of T cells to vascular endothelium, reduction of the ability of neutrophils to phagocytose and free-radicals formation, and reduction of IL-8 secretion by endothelial cells (Kötter, Günaydin et al. 2004). These actions are relevant to patients with Behcet's disease who have hyperactive neutrophils (Accardo-Palumbo, Triolo et al. 2000). Therefore, the most common uveitis being treated with INF α is Behcet's disease. Analysis of data combined from several clinical trials on 215 Behcet's disease patients with ocular disease showed that 75% of patients achieved complete remission, 19% partial remission, 0.5% remained stable, and only 4% deteriorated (Kötter, Günaydin et al. 2004). The same study reported a higher rate of remission with INF- α 2a than INF- α 2b, the figures were 91% and 6%, respectively.

1.3.14.7 Anti CD 20 antibody Rituximab

Another important biological agent is rituximab which is a chimeric monoclonal antibody directed against the CD20 protein. The CD20 molecule is present on mature B cells but is not expressed on pre-B lymphocytes or plasma cells. Rituximab acts on CD20 by two main mechanisms: antibody-dependent cell mediated cytotoxicity, and complement-mediated lysis and apoptosis. Transient depletion of B cells for about 6 - 9 months, follows the administration of rituximab (Lee, Bajwa et al. 2014, Bhatt, Tucker et al. 2016).

In ophthalmology, this therapy was tested and proved efficacious in ocular inflammatory conditions such as cicatricial pemphigoid, scleritis associated antineutrophil cytoplasmic antibody vasculitis, peripheral ulcerative keratitis and granulomatosis with polyangiitis (Kurz, Suhler et al. 2009).

There is a small number of studies in the ophthalmic literature regarding the use of rituximab in uveitis. Eight patients with JIA-related uveitis, and failed anti-TNF α , had rituximab. Rituximab reduced the level of inflammation and the concomitant use of steroids for a follow-up time of 15 months. 7 out of 8 achieved clinical remission

(Miserocchi, Pontikaki et al. 2011). Rituximab achieved clinical remission in 10 patients who had ophthalmic manifestations of GPA, six of those patients either had recalcitrant scleritis or had granulomas compressing the optic nerve head or both (Taylor, Salama et al. 2009). A case report study describes one patient with chronic anterior uveitis who failed all the immunosuppressive therapy but responded well to rituximab (Tappeiner, Heinz et al. 2007). However, infusion reactions were as high as 35% and to minimise this risk some authors advocated the use of methylprednisolone and antihistamine with paracetamol before and during the infusion (Taylor, Salama et al. 2009).

1.4 Aims of this thesis

This thesis looked at different therapies in two distinct areas in ocular inflammation (non-infectious and infectious), where the recurrent inflammation or its complications have a significant risk of vision loss. The research was undertaken to find better ways to improve disease control, visual outcomes in patients with recurrent uveitis, particularly those with intermediate, posterior and panuveitis, and those with recurrent toxoplasma retinochoroiditis. Firstly, the role of biologic agents in disease control and corticosteroid dose in patients with intermediate, posterior and panuveitis. Specifically, disease control and corticosteroid dose on different biologics, and the long-term efficacy of these agents with regards to visual function and disease relapse rate. Secondly, examining the immunomodulatory effect of high dose simvastatin on oral corticosteroid dose in patients with intermediate, posterior and panuveitis. Finally, the role of co-trimoxazole as a chemoprophylactic agent in patients with recurrent toxoplasmic retinochoroiditis.

Adopting a therapeutic strategy aims to prevent or significantly reduce the risk of disease recurrence in patients with sight-threatening uveitis may lead to superior outcomes compared to treating the inflammatory attacks only. We hypothesise that this strategy minimises the concomitant dose of immunosuppressive therapy, and improves long-term visual outcomes in patients with sight-threatening diseases.

2 Chapter Two Role of biological agents in patients with non-infectious intermediate, posterior and panuveitis (NIIPPU)

2.1 Introduction

Commonly, the treatment of non-infectious uveitis starts with corticosteroids (topical, or systemic). However, patients with non-infectious intermediate, posterior and panuveitis (NIIUPPU) require heavy systemic immunosuppression to achieve disease control and prevent future relapses. A study by Tomkins-Netzer and co-workers showed that approximately half of the patients needed systemic corticosteroid to control their inflammation (525 out of 1076 patients), and around 60% of patients required a dose higher than 40 mg per day, and approximately 25% of patients had one or more second-line agent to control their inflammation (Tomkins-Netzer, Talat et al. 2014).

Corticosteroid-based immunosuppression is required for a long-term. However, if the patient requires daily prednisolone dose more than 10 mg to control ocular inflammation, a corticosteroid-sparing agent is added to help reduce concomitant corticosteroid dose while maintaining disease control. Also, second-line agents are introduced if corticosteroids are poorly tolerated, or the underlying disease will likely need a long-term treatment such as Birdshot, VKH and Behcet disease, (Martel, Esterberg et al. 2012). Lastly, second-line immunosuppressive agent(s) may help with disease control in corticosteroid unresponsive cases.

In NIIUPPU lower doses of corticosteroids are usually ineffective, therefore, patients require long-term high dose to control disease manifestations. For example, in Birdshot disease high dose oral corticosteroid is used to treat macular oedema and when the dose drops below 15 mg daily, CMO usually recurs. Since too high corticosteroid dose for long-term control is required, a second-line agent is imperative. The concomitant immunosuppression in Birdshot patients resulted in an 83% reduction in risk of macular oedema (Thorne, Jabs et al. 2005). Therefore, prolonged immunosuppression in Birdshot disease is warranted, and studies have shown that long-term treatment reverses visual field loss and the retinal damage seen on optical coherence tomography (Forooghian, Gulati et al. 2010).

Similarly, in multifocal choroiditis (MFC) and panuveitis, treatment with corticosteroid alone required doses higher than 10 mg/day to maintain disease control and reduce the risk of ocular complications such as CMO and CNV. Lower doses (safer) of

corticosteroid were ineffective in controlling disease manifestations. Therefore, treatment with corticosteroid-sparing, second-line immunosuppressive drugs is necessary to reduce the risk of ocular complications and vision loss. A study by Thorne and co-workers have shown that immunosuppressive second-line drugs decreased the risk of CMO and CNV by 83% and blindness by 92% (Thorne, Wittenberg et al. 2006). Studies in late-stage VKH confirm the superior results of systemic immunosuppression in reducing the risk of ocular complications evident by 67% and 92% reduction in the risk of visual impairment and blindness, respectively (Bykhovskaya, Thorne et al. 2005). In the SITE study, complete suppression of inflammation decreased the risk CNV by 50% compared to eyes with active uveitis. The presence of minimally active disease carries the same risk of CNV as the active one (Baxter, Pistilli et al. 2013). Therefore, a significant portion of patients with NIIPPU will start immunomodulatory therapy.

However, in the SITE study (large study in the US looked at the effectiveness of different IMT in uveitis) the corticosteroids-sparing (prednisolone \leq 10 mg per day) was only achieved in 36% of patients on cyclosporine at 1-year follow-up. Similarly, in patients with posterior and panuveitis, on methotrexate, corticosteroid dose dropped to a safe level in only 21% and 39%, at 6 and 12 months follow-up, respectively. Likewise, only 47% and 55% of patients on azathioprine and mycophenolate, respectively, managed to reach safe doses of prednisolone at or before one year follow-up.

Recently, the safe dose of daily prednisolone dropped to \leq 7.5 mg, and the previous cut-off dose of \leq 10 mg is not safe for long-term disease control. Therefore, even after the addition of second-line agents, a significant proportion of patients are still on relatively high dose of corticosteroid. Moreover, some agents require several months to show full effect which prolong the time to reduce the corticosteroids. For example, methotrexate requires several months before reaching its full therapeutic effect, and patients needed high doses corticosteroids to keep disease under control. Also, treatment with second-line immunosuppressive agents can be ineffective in controlling ocular inflammation (patients would normally wait for three months before switching to another agent and disease is managed solely by corticosteroids). Alternatively, IMT may be poorly tolerated due to side effect or development of systemic toxicities. At this

stage biologic agents can be considered. A biologic is a therapeutic drug manufactured by a biological process that involves a recombinant DNA technology. The term biologics or biologic response modifiers will be used in this chapter to refer to infliximab, adalimumab, etanercept, rituximab, and vedolizumab.

2.2 Role of anti-TNF α in ocular inflammation

Research has led to a better understanding of the pathophysiological mechanisms in uveitis particularly the role of different cytokines in inflammation. But because ocular inflammatory diseases are heterogeneous and have varying immune response, one therapeutic agent might not have a similar efficacy across different diseases. For example, TNF α seems to play a more significant role in inflammatory response in Behcet disease compared to other uveitides, and therefore Behcet patients respond better to TNF α blockers. Therefore, a more targeted therapy toward the mediators of inflammation is now in development and use, and this will create more opportunities for patients with sight-threatening ocular inflammation.

The advent of agents that interfere with TNF α , whether a monoclonal antibody or a soluble receptor form, was a significant development in the treatment of autoimmune disease. Because of the unprecedented success of these agents in conditions such as rheumatoid arthritis and Crohn's disease. TNF α is a potent, pro-inflammatory cytokine that is primarily produced by activated monocytes and macrophages. Other cells such as T helper cells, neutrophils, mast cells, eosinophils, RPE, microglia, Müller cells, and activated endothelial cells can also contribute to the production of TNF α (Levy-Clarke, Jabs et al. 2014). It is hypothesised that activated cells release cytokines that activate transcription factors in the nucleus, which leads to the formation of the transmembrane form of TNF α which in turn binds to TNF α receptor-1.

TNF α promotes the inflammation in several ways. TNF α induces the production of potent inflammatory cytokines such as IL-1, IL-6 and chemokines (O'Shea, Ma et al. 2002). Moreover, it induces overexpression of adhesion molecules, and increases the adherence of neutrophils among other inflammatory cells to vascular endothelium and makes them more sensitive to IL-1 and IL-6 (Eigler, Sinha et al. 1997, Heiligenhaus, Thureau et al. 2010). In addition to secretion of effector molecules, TNF α enhances the

inflammation by promoting the secretion of growth factors, proliferation factors, immunoglobulins, and metalloproteinases (Levy-Clarke, Jabs et al. 2014).

Experimental studies showed that there is considerable evidence regarding the role of TNF α in inducing retinal damage, particularly apoptosis of retinal cells (Dick, Forrester et al. 2004, Robinson, Ho et al. 2011). The inhibition of TNF α has led to a demonstrable benefit in Experimental Autoimmune Uveitis (EAU) due to a reduction in T cell polarisation, INF γ production and lowering the levels of cellular activation, which led to less target organ damage (Dick, McMenamin et al. 1996).

In autoimmune diseases, TNF α has been reported to be over-expressed in rheumatoid arthritis, multiple sclerosis and other autoimmune disorders, of particular interest, is the ability of TNF α to cause erosive arthritis and synovial tissue proliferation even in the absence of lymphocytes (Kollias, Douni et al. 1999, Owens, Wekerle et al. 2001).

In uveitis, TNF α plays a crucial role in ocular inflammatory diseases. Higher levels of TNF α were reported in serum and aqueous humour of patients with active uveitis compared to controls and higher levels of TNF α were associated with recurrent disease relapse (Santos Lacomba, Marcos Martin et al. 2001). Blocking TNF α in patients with posterior segment intraocular inflammation resulted in shifting of CD4 cytokine profile in peripheral blood, from pro-inflammatory to anti-inflammatory and this was associated with significant improvement in visual acuity (Greiner, Murphy et al. 2004). However, there is evidence that TNF α has a dual mechanism, it down-regulates and up-regulates the immune system. For example, MS patients treated with anti-TNF α showed worsening disease activity and increased demyelination (Kollias, Douni et al. 1999). Further, blocking the TNF α have enhanced production of other antibodies such as anti-DNA, nuclear antibodies and anticardiolipin antibodies, resulting in drug-induced lupus (O'Shea, Ma et al. 2002).

The use of biologics namely infliximab began in rheumatology with unprecedented success in controlling systemic inflammatory diseases (Weinblatt, Keystone et al. 2003). Several cohort studies and case reports have demonstrated the efficacy of these agents in non-infectious ocular diseases (Ohno, Nakamura et al. 2004, Sfikakis, Kaklamanis et al. 2004) (Tugal-Tutkun, Mudun et al. 2005). Recently, biologics are being prescribed more frequently in ocular inflammatory disease, and the two most

extensively studied biologics are infliximab and adalimumab. The efficacy of infliximab was tested in several ocular inflammatory conditions (Behcet panuveitis and vasculitis, JIA and HLA-B27 associated uveitis, scleritis and Birdshot chorioretinopathy).

2.2.1 VISUAL I, II and III

Recently, two randomised controlled trials (VISUAL I & II) reported better disease control with adalimumab compared to placebo which led to its approval in non-infectious uveitis (Jaffe, Dick et al. 2016, Nguyen, Merrill et al. 2016). However, the design of these studies does not relate to the clinical practice since patients on second-line agents had to stop their treatment before enrolling into these trials. Also, these studies did not report the long-term corticosteroids sparing effect of adalimumab because corticosteroids were tapered in a relatively short period of time to challenge the disease and assess the time to relapse on adalimumab (defined as treatment failure). Moreover, these studies have relatively short follow-up time, and therefore, the long-term efficacy of adalimumab remains to be proven.

The VISUAL-I and II studies are landmark trials examined the effect of adalimumab versus placebo in patients with active (VISUAL-I) (Jaffe, Dick et al. 2016) and inactive (VISUAL-II) (Nguyen, Merrill et al. 2016) non-infectious intermediate, posterior and panuveitis whom inflammation was controlled on systemic steroids before enrolment. The aim of the VISUAL I study was to achieve quiescence in eyes with active disease whereas, in the VISUAL II, the purpose was to assess the ability of adalimumab to maintain disease quiescence. Both trials reported a significant improvement of median time to treatment failure on adalimumab compared to placebo. Treatment with adalimumab significantly reduced the risk of treatment failure by 50% and 43%, in the VISUAL I and the VISUAL II, respectively.

VISUAL-1 study included patients with active disease, the primary endpoint was time to treatment failure which was defined as new chorioretinal inflammatory foci, new vascular inflammatory lesion, increase in anterior chamber cells grade and or vitreous haze grade and change in vision. The results showed a significant improvement in time to treatment failure in the adalimumab group compared to the placebo group. Patients on adalimumab had few treatment failures compared to placebo group, HR 0.5 95% CI, 0.36-0.70; p-value <0.001. Adalimumab reduced the risk of treatment

failure by 50%, the median time to treatment failure was 13 weeks and 24 weeks for the placebo and adalimumab group, respectively. Also, the secondary endpoints (increasing in vitreous haze and anterior chamber cells, and worsening in visual acuity) were significantly less frequent in adalimumab group compared to placebo (p-value \leq 0.01).

In VISUAL I vitreous haze (primary endpoint), was the most common cause of treatment failure (36%) in the placebo group. Conversely, in the adalimumab group, the vitreous haze was significantly the least frequent cause for treatment failure (15%), whereas, increase in anterior chamber activity was the most common. In subgroup analysis, the efficacy of adalimumab versus placebo was only significant in patients with idiopathic uveitis and patients without a history of second-line agent use prior adalimumab treatment. Patients with Birdshot disease or those who used second-line agent prior commencing adalimumab showed the least favourable response to adalimumab treatment.

The VISUAL II study, recruited patients with an inactive disease for at least 28 days before enrolment, and on higher than the recommended dose of corticosteroids (10-30 mg prednisolone). The aim was to assess corticosteroid-sparing effect of adalimumab while maintaining disease quiescence (preventing uveitis relapse). The primary endpoint was time to treatment failure, which encompassed four different elements of inflammation (vitreous haze, AC cells, new inflammatory chorioretinal or vascular lesions, and change in best corrected visual acuity) to examine the efficacy of adalimumab across different aspects of ocular inflammation.

Treatment failure rates were 55% and 39% in the placebo and the adalimumab groups, respectively. The median time to treatment failure was not estimated for the adalimumab group because more than half of the subjects in the adalimumab group did not relapse, therefore, it was estimated to be over 18 months, while median time to treatment failure in the placebo group was 8.3 months. The 40th percentile for treatment failure were 4.8 and 10.2 months in the placebo and the adalimumab groups, respectively, hazard ratio HR 0.57%, CI 0.39%-0.84%, (p-value 0.004). Adalimumab resulted in a 43% risk reduction in treatment failure compared to the placebo. Therefore, adalimumab almost halved the risk of treatment failure and doubled the time to failure in patients with non-infectious intermediate, posterior and

panuveitis. The study reported a similar risk of adverse events between the two groups.

Interestingly, in the VISUAL II trial, the difference in visual acuity between the two groups was not only the largest, but also the only significant difference among other endpoints (AC activity, vitreous haze, new chorioretinal and new vascular lesions). Time to treatment failure due to drop in visual acuity has significantly improved in adalimumab-treated patients compared to placebo HR 0.33% (95%CI 0.16-0.70%) p-value= 0.002.

Nonetheless, there are several issues with VISUAL studies that need careful consideration.

Systemic corticosteroids were the primary therapy used to control the inflammation in these studies, and patients had to undergo a mandatory taper of prednisolone dose to zero within 15 weeks in the VISUAL I and 20 weeks in the VISUAL II study. In the VISUAL I study at day 0 (starting biologics) all patients had 60 mg prednisolone. This approach substantially contradicts the clinical practice in uveitis for two reasons. Firstly, treatment with corticosteroids (prescribed as needed) usually undergo a slow taper and then the dose is adjusted in accordance with inflammatory activity (Jabs, Rosenbaum et al. 2000). Secondly, even with a gradual taper of corticosteroid, it is not uncommon to keep patients on a low dose of corticosteroids for more-extended periods to maintain disease control. Furthermore, in the VISUAL I study, because patients had a burst of high dose oral prednisolone at the time of starting biologics, time to disease activity (in both arms) might have been influenced, in other words, time to treatment failure might be confounded by the high prednisolone dose initially.

Moreover, patients in VISUAL I and II had to stop their second-line immunomodulatory therapy before starting treatment. Also, both studies excluded patients on two second-line immunosuppressive agents at baseline which might have a selection bias since patients with more aggressive disease, which require two IMT, were excluded. In clinical practice, most patients with sight-threatening uveitis would have been on an immunosuppressive corticosteroid-sparing agent(s) before trying biologics and treatment on a second-line agent is maintained for at least 6 to 12 months before being gradually tapered if the disease remains well-controlled. By stopping the second-line

agent prior treatment with adalimumab, these studies did not assess the efficacy of adalimumab on the concomitant use of second-line immunomodulatory therapy, which is commonly used in uveitis treatment. Therefore, the application of these results in the real world is quite challenging. Also, these studies did not report the response to biologics in different uveitis aetiologies, as there is well-recognised heterogeneity within NIIUPPU groups. Finally, both trials have had a relatively short follow-up time in a chronic disease, and increase in inflammatory activity was a sign for treatment failure, which meant that the patient is no longer in the trial. Therefore, the real assessment of long-term effects of adalimumab in non-infectious intermediate, posterior and panuveitis was not applicable.

Recently the VISUAL III, a phase 3 open-label study, (it is an extension from the previous VISUAL studies), ascertained the efficacy and safety of adalimumab in patients with non-infectious posterior intermediate and panuveitis with active or inactive disease (Suhler, Adán et al. 2018). At 78 weeks, adalimumab achieved disease quiescence, improved visual acuity and reduced corticosteroid dose in patients with active disease, while those with inactive disease continued to have disease quiescence, stable vision and the vast majority (93%) of those patients were corticosteroids free at week 78.

2.3 AIMS

Recently, two prospective randomised double-masked trials (VISUAL-I and VISUAL-II) demonstrated the effectiveness of adalimumab in patients with non-infectious intermediate, posterior and panuveitis, which has led to the FDA approval for adalimumab in these patients when treatment with corticosteroids is insufficient for disease control. However, these studies do not correlate to standard clinical practice, because patients in these studies had to undergo mandatory corticosteroid reduction in a considerably short period. Also, it excluded the second-line immunosuppressive agents from the analysis. Therefore, these trials did not give an insight into the corticosteroids and second-line immunosuppressive agent sparing, nor did they analyse the response to biological agents in different diseases aetiology such as Behcet's disease, since non-infectious intermediate, posterior and panuveitis is a group of heterogeneous disorders with well-recognised differences in pathological immune response.

Moreover, in addition to adalimumab, which is licensed for uveitis after the VISUAL I and II trials, infliximab has also been proven effective non-infectious uveitis in many retrospective and prospective open-label studies. Both are effective in disease control and corticosteroids sparing, and there is no clear evidence on which one has a better disease control and superior drug-retention rate. Therefore, comparing their effect is of great interest for uveitis specialist, because a direct comparison between several biologics reported inconsistent results. Similarly, studies have reported varying responses to biologic treatment. For example, rituximab was reported to have a minor effect on disease control, while etanercept increases the risk of uveitis. Finally, the question remains with regards to their long-term efficacy, particularly their ability in maintaining disease control while sparing corticosteroids dose and allowing the reduction of other immunosuppressive agents.

The study aimed to assess long-term treatment outcomes on biologics in patients with non-infectious intermediate, posterior and panuveitis refractory to conventional immunomodulatory therapy. In particular, this work will look at the corticosteroids-sparing effect of biologics, dose of second-line immunosuppressive agents, best corrected visual acuity, the number of disease relapses pre and post biologics and time to treatment failure (stopping biologics due to poor disease control or development of side effect). Also, the impact of disease aetiology (especially Behcet disease), and anatomical location on treatment outcome will be analysed.

2.4 Hypothesis:

Biologic response modifiers help reduces the dose of corticosteroids and second-line immunosuppressive medications required by patients with sight-threatening non-infectious uveitis and preserve sight.

The primary endpoints that relate to this question

Corticosteroid dose and second-line immunosuppressive drug levels (therapeutic dose or below therapeutic dose) at baseline, 3, 6, 9 and 12 months, then at 2, 3, 4 and five years. Finally, the effect of biologic treatment on the best corrected visual acuity in LogMAR units at these time points.

Null hypothesis: The mean differences in prednisolone dose would be unchanged following treatment with biologic response modifiers.

Alternative hypothesis: Prednisolone dose will change significantly following treatment with biologic agents.

What will be the primary statistical analysis of that endpoint?

Different statistical methods were employed, and these were based on the question to answer and the type of data being analysed. Please see the statistical section below.

Secondary (exploratory analyses)

1. Comparing disease control and corticosteroid-sparing on adalimumab and infliximab.
2. Time to prednisolone dose less than 10 mg per day.
3. Time to treatment failure on biologics, (time to stopping or switching to another biologic due to poor disease control or development of side effect, with direct comparison between adalimumab and infliximab.
4. Effect of biologics on Behcet versus non-Behcet disease patients with regards to disease relapse and safe corticosteroid dose.
5. Report the safety of biologics in uveitis patients.

2.5 Methods

This is a retrospective study aiming to examine the effect of biologics on patients with non-infectious, non-anterior uveitis. Ethical approval for this project was obtained from the Department of Research and Development at Moorfields Eye Hospital (MEH) under (ROAD16039) (Visual loss in uveitis). Patients with a history of non-infectious uveitis presented to MEH from May 1995 to June 2018 were identified by searching the database for the following terms; biologics and Humira, infliximab, adalimumab, rituximab, TNF α , anti-TNF alpha in any context within the letter body on OpenEyes system). This search was performed by the data management division at MEH on OpenEyes software (Electronic database for Moorfields patients). Uveitis has been classified according to the Standardization of Uveitis Nomenclature (SUN) Working Group criteria (Jabs, Nussenblatt et al. 2005). Chest radiographs, Mantoux and/or

Quantiferon tests were performed for all patients to ensure no current TB infection. Also, patients were screened for malignancy and present infection prior starting biologic response modifiers.

2.6 Data collection

Data were obtained retrospectively from medical records and included patient demographics (age, gender, and ethnic background), age at first presentation, eye involved and whether the patient has a unilateral or bilateral disease, systemic association, anatomical location of the uveitis (Intermediate, posterior or panuveitis) and disease aetiology (if known). The number of disease relapses before biologic treatment, time of initiation of biologics, type of biologics, indication for the biologics treatment (ocular versus systemic), time of stopping or switching to another biological agent and reason. The number of flares during treatment with biologics and time of first disease relapse were recorded for relapse-free survival analysis along with the date of first and last visit. Corticosteroid dose, and type and dose of second-line immunosuppressive agent, best corrected visual acuity were recorded for each patient in the study at time of presentation, starting biologics (baseline), 3 months, 6, 9 months, 1, 2, 3, 4 and five years, and at last follow-up visit or last visit on biologics if it was stopped. The BCVA, was recorded at each pre-specified time points in Snellen format (pinhole or manifest refraction), and this was collected and transferred to the logarithm of the minimal angle of resolution (LogMAR) for statistical analysis. Visual acuity at last follow-up visits was recorded and classified into moderate vision loss (MVL) $VA \geq 6/15$ and $< 6/60$, severe vision loss (SVL) defined as $\geq 6/60$, and the cause of vision loss was recorded. For Snellen visual acuity outside the values presented in Table 2-1, the LogMAR equivalents were obtained from an online website, Figure 2-1

Table 2-1 LogMAR and Snellen equivalent for BCVA

LogMAR	Snellen Equivalent
1.0	6/60
0.9	6/48
0.8	6/38
0.7	6/30
0.6	6/24
0.5	6/19
0.4	6/15
0.3	6/12
0.2	6/9.5
0.1	6/7.5
0.0	6/6
-0.1	6/5
-0.2	6/4
-0.3	6/3

Figure 2-1 Snellen to LogMAR online calculator

Web address <http://www.myvisiontest.com/logmar.php>

Snellen - logMAR Visual Acuity Calculator

[« Back to MyVisionTest](#)

1/60 Snellen acuity converted to logMAR is: 1.7781512503836

Convert Snellen to logMAR

Snellen numerator:

Snellen denominator:

Convert logMAR to Snellen

logMAR:

Usage: In addition to interactive use of the calculator, links to the calculator may contain either logMAR or Snellen values that will be automatic value, you may provide just a denominator (sd), or both a numerator (sn) and denominator. If only a denominator is provided, the numerator is as

The initial survey from Jan 2001- August 2016 at MEH revealed 898 patients, (the run date was 12/08/2016). After manually surveying all patients we identified 329 who had no biologics given and 569 who had biologics treatment. From those on biologics 165 and 118 patients had biologics for corneal/scleral and orbital disease, respectively. Of the remaining 286 patients, 4 had biologics for lymphoma and others were given biologics for other illnesses such as haemolytic anaemia. The remaining 280 patients had their biologics for uveitis. We reviewed patients with uveitis again and those with anterior uveitis (188 patients) or inadequate data (10 patients) were excluded, and only 82 patients (200 eyes) were eligible for analysis.

2.7 Definitions

2.7.1 The non-therapeutic dose of immunomodulatory agent

Non-therapeutic dose for each of the second-line immunosuppressive agent is shown below:

- Azathioprine <150 mg per day
- Methotrexate <10 mg per week
- Mycophenolate mofetil <1000 mg per day
- Cyclosporine < 3 mg per kg per day
- Tacrolimus < 3 mg per day.

Because biologics (perceived as foreign antigens) can trigger an immune reaction, sometimes a lower than optimal dose of second-line immunosuppressive agent is used with them. This aims to reduce the risk of development of anti-drug (biologic) antibodies which helps prolong drug efficacy and also reduces the risk of occurrence drug reactions and other auto immune diseases while on biological therapy. In these situations and after achieving disease control mainly by biologic agent the IMT dose is significantly reduced but not completely stopped. The IMT is not taken primarily to achieve an immune modulation due to lower than recommended doses. Therefore, a lower than the usually recommended dose of IMT is used to help prolong drug efficacy and these doses are regarded as non-therapeutic as shown above. However, an immunosuppressive effect cannot be ruled out even with lower doses of IMT.

2.7.2 Relapses

Relapses are defined as new ocular inflammation or worsening of pre-existing inflammation necessitating treatment intensification, as per previous study (Vallet, Seve et al. 2016).

1. Increase in disease activity (one step or more according to the sun criteria) (AC activity, vitreous activity with or without CMO or chorioretinal or vascular lesions. New area(s) of retinitis in patients diagnosed with Behcet disease or
2. Recurrence of CMO or worsening of preexisting one (increases in central retinal thickness)
3. Reduction in visual acuity that cannot be explained by any cause other than inflammation.
4. Increase or initiation of oral/topical periocular or intravenous corticosteroids (methylprednisolone) administration.
5. Addition of another immunosuppressive agent or increasing the dose after being on a maintenance dose.

2.7.3 Treatment failure

1. Inadequate or poor response to treatment (persistent disease activity and or frequent flare-ups that requires an increase in corticosteroid dose or use of periocular steroids injection) that ultimately resulted in stopping or change to another biologic agent.
2. Development of allergic reactions.
3. Treatment-related side effects (demyelination).

2.7.4 Disease control (remission)

Disease control was defined as disease quiescence for at least three months (time to first relapse \geq 3 months after starting biologics).

2.8 Inclusion criteria

1. Patients with non-infectious intermediate, posterior and panuveitis.
2. At least three months of follow-up.

3. Treatment with biologics was primarily indicated for ocular disease, and patients with uveitis who have had their biologic treatment for inflammatory bowel or joint disease were also included.
4. No age limit for patient selection

2.9 Exclusion criteria

1. Patients with infectious uveitis
2. Biologics indicated for anterior uveitis, corneal disease, orbital pathology or scleritis.
3. Treatment stopped early (less than three months). Early discontinue of treatment due to funding issues or allergic reaction or reactivation of miliary TB (1 case).

2.10 Statistical tests

Descriptive statistics were used including sample size, percentages, and standard errors. Assessment for normality of distribution was performed using graphical methods and Shapiro-Wilk test. Continuous data are presented as means \pm standard error of the mean (SEM). Non-continuous data are presented in median and interquartile range (IQR). The accepted level of significance for all tests was $\alpha \leq 0.05$. The Kaplan-Meier estimator was used to examine survival from the recurrence of ocular inflammation, treatment failure and achieving a prednisolone dose of 10 mg per day with log-rank (Mantel-Cox) to compare the survival analysis curves.

Generalised estimated equation (GEE) was used to compare the change in mean BCVA and the number of flare-ups per year throughout the follow-up time, adjusting for the time of follow-up and correlations between the two eyes of the same patient. Repeated measure ANOVA and Bonferroni adjusted for type I errors as post hoc analysis (after rejecting the null hypothesis) was used to analyse change in dose of prednisolone over time.

Chi-square and Fisher's exact tests to compare the proportion of patients who had a therapeutic versus nontherapeutic dose of the second-line immunosuppressive agent. Multivariate analysis and odds ratio (OR) with 95% confidence interval (CI) for treatment failure was calculated using Cox regression model while adjusting for

correlation between the two eyes of the same patient and accounting for the variable follow-up. Only factors with a significance level of at least 0.1 on univariate analysis were included in the multivariate model. SPSS (Version 24, IBM, USA) was used for analysis.

2.11 RESULTS

2.12 Demographics

This study included 82 patients (32 females and 50 males), 76% of patients were white. Age at the time of diagnosis was 33.9 ± 1.7 SEM years (range 4.4 - 69.5 years), 74 patients (90%) had bilateral uveitis whereas, a unilateral disease was observed in only eight patients (10%), 156 eyes were included (80 right), 42 diagnosed as intermediate uveitis, 31 posterior uveitis and 83 with panuveitis. In 116 out of 156 eyes (74.3%), uveitis was associated with a specific systemic disease such as, Behcet disease and HLA B-27 spondyloarthritis among others, whereas in the remaining (25.7%), the diagnosis was idiopathic uveitis in 32 eyes (20.5%), and 8 (5.2%) had a known ocular disease without known systemic involvement namely; PIC, MFC, Birdshot and idiopathic serpiginous choroidopathy. Table 2-2 summarises the demographic information regarding eyes treated with all biologic agents, and Table 2-3 displays disease aetiologies

Mean follow-up duration was 8.67 years \pm 5.54 SD, range from 0.79 - 26.1 years. Average age at starting biologics (baseline) was 37.8 ± 1.8 years (range 5.5-69.9 years). The median follow-up after initiation of biologics was 4.30 years, IQR 1.67-6.26 years. The mean length of follow-up after baseline was 5.1 ± 0.49 SE years (388 eye-years). For 29 patients (35.4%) follow-up was longer than five years, mean follow-up was 8.56 ± 0.58 SEM (range 5.09-16.61 years). The first biologic agent was infliximab in 76 eyes; adalimumab in 60 eyes; etanercept in 4 eyes; rituximab in 14 eyes and vedolizumab in 2 eyes Table 2-4. The mean duration of treatment with infliximab was 3.09 ± 0.38 SEM years, and for the adalimumab, the mean treatment duration was 3.08 ± 0.34 years. Table 2-5 includes demographic data for those only on infliximab and adalimumab.

Table 2-2 Patients demographics and anatomical type of uveitis.

Patient's demographics	Number (%)
Female	32 (39.02)
Right eye	80 (51.28)
Ethnicity	
White	53 (64.6)
Asian	11 (13.4)
African	1 (1.3)
Others	17 (20.7)
Age at baseline, years, mean \pm SEM	37.8 \pm 1.8
Prednisolone dose at base line, mg/day, mean \pm SEM	16.4 \pm 1.7
Anatomic type of uveitis	
Intermediate uveitis	42 (26.9)
Posterior uveitis	31 (19.9)
Panuveitis	83 (53.2)
Second-line immunosuppressive drugs	
None	24 (29.25%)
Mycophenolate	28 (34.25%)
Methotrexate	19 (23%)
Azathioprine	6 (7.5%)
Tacrolimus	2 (2.5%)
Cyclosporine	3 (3.5%)

Table 2-3. Disease aetiology

Disease aetiology	Number of eyes (%)
Behcet disease	51 (32.7)
Vasculitis	8 (5.1)
HLA-B27 related uveitis	25 (16.0)
Vogt Koyanagi Harada syndrome	6 (3.8)
Sarcoidosis	8 (5.1)
Systemic lupus erythematosus	3 (1.9)
Serpiginous choroiditis	2 (1.3)
Takayasu vasculitis	1 (0.6)
Punctate inner choroidopathy	2 (1.3)
Rheumatoid arthritis	4 (2.6)
Multifocal choroiditis	2 (1.3)
Idiopathic uveitis	32 (20.5)
Juvenile idiopathic arthritis	6 (3.8)
Blau syndrome	2 (1.3)
Birdshot chorioretinopathy	2 (1.3)
Multiple sclerosis related uveitis	2 (1.3)

Table 2-4 First biologic drug and the corresponding number of eyes

First biologic drug	Number of eyes (%)
Infliximab	76 (48.7)
Adalimumab	60 (38.5)
Etanercept	4 (2.6)
Rituximab	14 (9.0)
Vedolizumab	2 (1.3)

Table 2-5. Demographic data for patients treated with infliximab and adalimumab

	INFLIXIMAB	ADALIMUMAB	P-value
Number of eyes	76 EYES 39 patients	60 EYES 31 Patients	
Age years± SEM	35.02± 2.43	37.46± 2.66	0.5*
Gender	Females 14 (35.9%)	Females 14 (45%)	
Treatment duration	3.08 ± 0.53	3.08± 0.34	
Disease aetiology			
Behcet disease	18 (46)	8 (26)	
Idiopathic uveitis	7 (18)	8 (26)	
HLA B 27	4 (11)	7 (23)	
Rheumatoid arthritis	1 (2.5)	1 (2.5)	
Sarcoidosis	2 (5)	2 (5)	
JIA	0	3 (10)	
PIC	0	1 (2.5)	
Birdshot	0	1 (2.5)	
MFC	1 (2.5)	0	
Blau syndrome	1 (2.5)	0	
Serpiginous chroiditis	2 (5)	0	
Idiopathic vasculitis	1 (2.5)	0	
VKH	3 (7)	0	
Anatomical location			
Intermediate	7	10	
Posterior	8	3	
Panuveitis	24	18	
BCVA	0.44±0.07	0.44±0.07	
Corticosteroid dose	15.57±2.30	17.78± 2.86 mg	0.39 **
Second line agent			
MMF	11	11	
CYC	1	1	
TAC	1	2	
MXT	11	11	
AZA	5	3	
None	1	3	
<p>MMF(mycophenolate mofetil), CYC (cyclosporine), TAC (tacrolimus), MXT (methotrexate), and AZA (azathioprine). MFC (multifocal choroiditis), VKH (Vogt Koyanagi Harada disease), JIA (Juvenile idiopathic arthritis).</p> <p>*independent t test ** Mann Whitney</p>			

For non-Bechet disease cohort, the study included 56 patients (105) eyes. The mean age at first presentation was 34.07 ± 2.38 SEM years, range from 4.38- 69.55 years, the median was 36 years, and IQR was 19-48 years. The mean follow-up duration was 9.45 ± 0.78 years, the median follow-up time was 8.09 years, IQR 4.72-13.85 years, and range from 1.34 to 26.10 years. There were 31 males (55.4%) and 25 females (44.6%). The anatomical location of uveitis was as follows; 24 patients (42.9%) had panuveitis, 11 patients (19.6%) had posterior uveitis and intermediate uveitis in 21 patients (37.5%). With regards to patients' ethnicity 34 patients (61%) were white, eight patients were Asian/Indian (14%), one patient (2%) was African and 13 patients (23%) ethnicity was not stated. Mean corticosteroid dose at starting biologics was $14.69 \text{ mg} \pm 2.00$ SEM, median 10 mg, and IQR 3.25-20 mg. Mean best-corrected visual acuity (BCVA) at presentation was 0.40 LogMAR unit ± 0.05 SEM, median 0.17 LogMAR unit, (IQR 00.0-0.47).

For Behcet's disease cohort, the study included 26 patients (51) eyes. The mean age at first presentation was 33.46 ± 1.59 (SEM) years, range from 20- 50 years, the median was 33 years, IQR 28- 40 years. The mean follow-up duration was 7.09 ± 0.84 years, the median follow-up time was six years, IQR 3.50-10.67 years, and range from 0.89 to 15.69 years. There were 20 males (77%) and six females (33%), with a male to female ratio of approximately 3:1. The anatomical location of uveitis was as follows; 19 patients (73%) had panuveitis, six patients (23%) had posterior uveitis and intermediate uveitis in one patient (4%). With regards to patient's ethnicity, 19 patients (73%) were white, three patients were Asian (12%), and four patients (15%) the ethnicity was not stated. Mean corticosteroid dose at starting biologics was $18.55 \text{ mg} \pm 2.84$ SEM, median 15 mg (IQR 10-20 mg). Mean best-corrected visual acuity (BCVA) at presentation was 0.38 LogMAR unit ± 0.56 SD, median 0.17 LogMAR unit, (IQR 00.0-0.60).

Eyes with posterior uveitis constitute 19.9% of the total number of eyes included in the study. The different disease aetiologies presented with posterior uveitis include vasculitis, multifocal choroiditis MFC, systemic lupus erythematosus (SLE), punctate inner choroidopathy (PIC), serpiginous choroiditis, Takayasu arteritis, Birdshot disease and Behcet patients (6). 42 eyes (22) patients had intermediate uveitis (26.9%), the most common diagnosis was idiopathic intermediate uveitis (pars planitis) in 9 patients, followed closely by seronegative spondyloarthritis 6 patients

(ankylosing spondylitis, psoriasis and ulcerative colitis) and 1 patient with each of the following (Behcet disease, sarcoidosis, ANCA+ vasculitis and JIA), one patient had initially intermediate uveitis and developed multiple sclerosis later on, and two patients had rheumatoid arthritis. Most patients with seronegative spondyloarthropathy and rheumatoid arthritis had their biologic treatment started for their systemic disease.

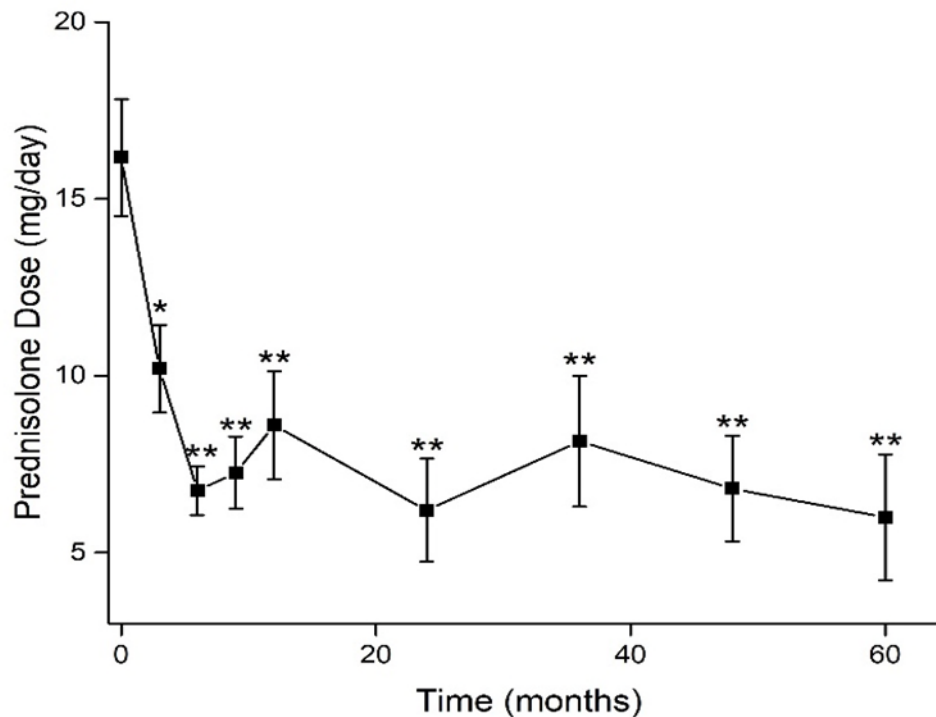
2.13 Corticosteroids dose analysis

The average prednisolone dose for all the study population at baseline was 16.4 ± 1.7 SEM mg/day. The mean reduction of oral prednisolone dose from baseline and over the five years period of follow-up was analysed using One-Way repeated measure ANOVA with Greenhouse- Geisser correction for significance. Mean corticosteroid dose reduced by six months to 6.48 ± 0.69 SEM mg/day ($p < 0.001$), and remained stable for up to five years follow-up. Figure 2-2. The mean prednisolone dose, at five years on biologics, stayed stable at 6.25 ± 2.0 SEM. There was a significant difference in mean prednisolone dose between the baseline (time starting biologic treatment) and all the other time points (3, 6, nine months, and 1-5 years), using Post hoc testing (pairwise comparisons). The mean difference in oral prednisolone dose between baseline and three months was 2.61 (p-value were 0.019), then the difference became highly statistically significant, from 6 months onwards with mean difference ranging from 6.1 to 8 mg, the corresponding p-values range between < 0.001 and 0.005, Table 2-6.

Table 2-6 Mean reductions of oral prednisolone dose from baseline. The result was statistically significant at three months and remained highly statistically significant from 6 months up to five years follow-up. * Statistically significant, ** highly statistically significant.

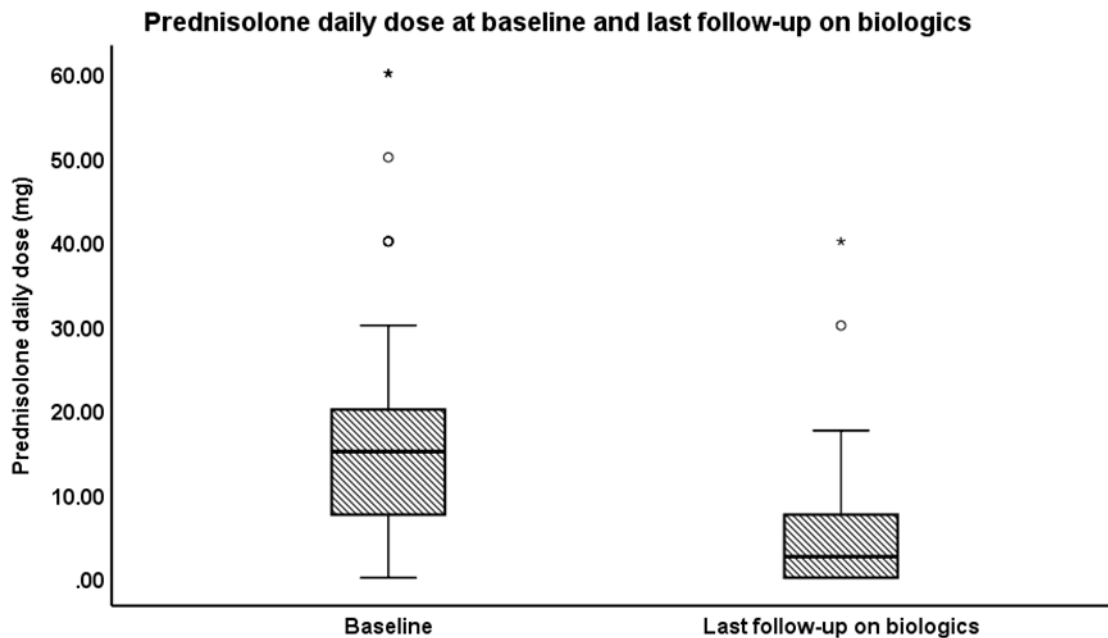
Baseline vs	Mean difference	Standard Error	P-value
Three months	2.615*	1.073	*.019
Six months	7.052*	1.451	** .000
Nine months	6.469*	1.992	** .002
One year	7.698*	1.759	** .000
Two years	7.969*	1.819	** .000
Three years	6.385*	1.956	** .002
Four years	6.177*	1.793	** .001
Five years	6.698*	2.252	** .005

Figure 2-2 Mean change in prednisolone dose on biologics over five years follow-up. At starting biologics, the mean daily prednisolone dose was 16.4 mg. However, on biologics the mean prednisolone dose reduced significantly from 3 months follow-up. Then mean prednisolone dose remained significantly lower compared to the baseline dose at all follow-up times. * Statistically significant, ** highly statistically significant. Please refer to table 2-6 for the mean differences and the corresponding p values.



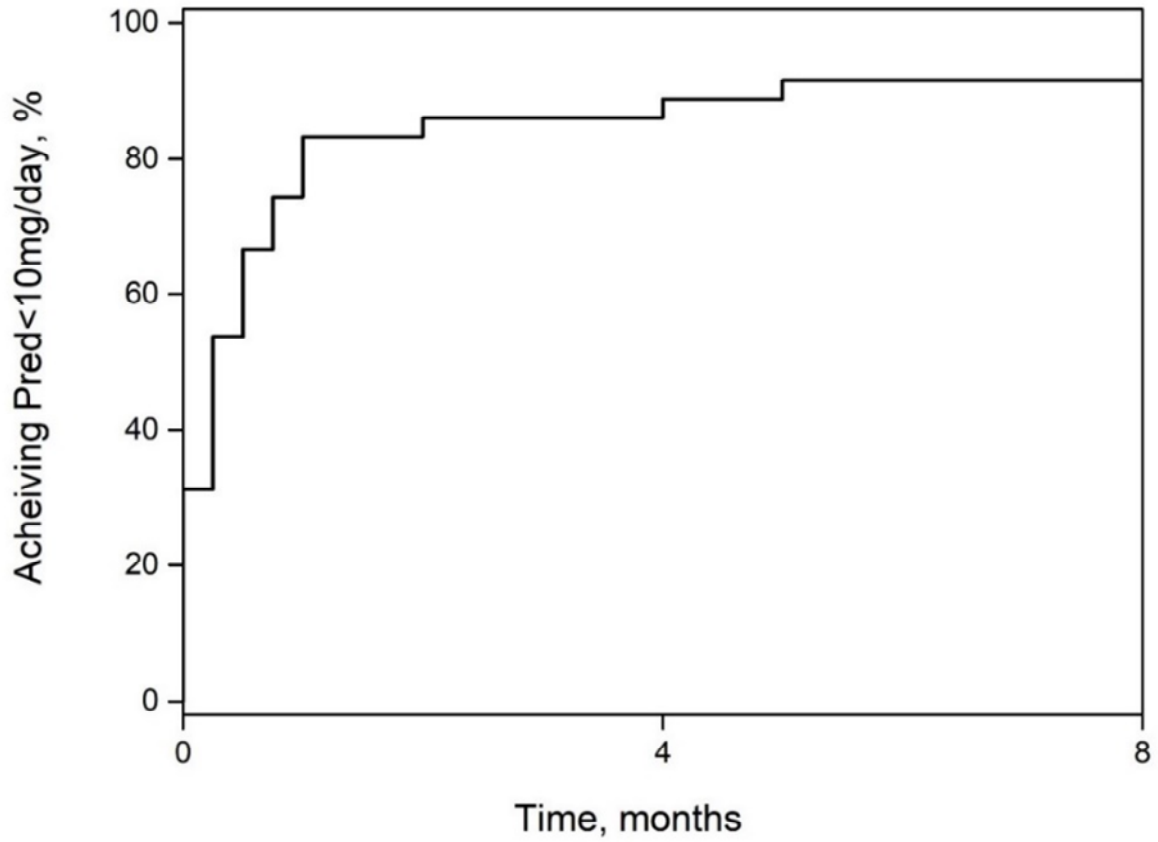
When comparing the dose of prednisolone at three months' with all other time points, there was still a statistically significant difference. However, this effect was lost from 6 months onwards (there was no statistically significant difference between mean prednisolone dose at 6 and nine months up to 5 years follow-up. Between the nine months and one year, there was a statistically significant difference between mean prednisolone doses; however, this was only marginally significant (p-value 0.043). Similarly, there was a substantial difference between two and four years follow-up (p-value =0.037) but not at any other time points. Finally, at last follow-up visit on biologics mean prednisolone dose was 4.91 ± 0.76 SEM, comparing the mean reduction of oral prednisolone dose from baseline (initiation of biologics) and last visit on biologics showed a highly statistically significant difference, with a mean difference of 11.38 ± 1.74 SEM; (95% CI 7.90 - 14.85), (p-value<0.001, paired sample t-test), Figure 2-3.

Figure 2-3. Prednisolone dose at baseline (starting biologics) and last follow-up visit on biologic. There was a significant reduction in mean daily prednisolone dose on biological therapy (p-value<0.001, paired sample t-test).



Moreover, among those with follow-up longer than five years, prednisolone dose remained stable and the mean daily prednisolone dose at ten years was 5.8 ± 3.07 SE mg/day and 4.14 ± 1.01 mg at last visit on biologics. Not only was the dose of prednisolone reduced, but also the proportion of patients on less than 10 mg prednisolone per day was also significantly reduced, with 92% of patients achieved a daily prednisolone dose of less than 10 mg by a median of 3 months, Figure 2-4, interquartile range IQR 0-9 months. The proportion of patients on daily prednisolone dose of < 10 mg per day at three and six months were 52.4% and 63.4%, respectively. At the time of starting biologics, 72% of patients had daily prednisolone dose of 10 mg and above, whereas at last follow-up visit on biologics the proportion of patients on ≥ 10 mg prednisolone dropped to only 18.7%, (p-value <0.001, McNemar, two-sided test).

Figure 2-4. The proportion of patients on daily prednisolone dose less than 10 mg per day. After starting biological therapy, 92% achieved daily prednisolone dose of < 10 mg by a median of 3 months



2.13.1 Comparing Behcet versus non-Behcet disease patients with regards to corticosteroid dose reduction

The analysis of daily oral prednisolone dose in Behcet disease (BD) shows, from three months onwards, a highly statistically significant reduction in oral prednisolone dose which was persistent across all study visits. Whereas, for non-Behcet disease patients, the initial decrease in oral prednisolone dose was less impressive (marginally significant) and also a non-significant difference of prednisolone dose compared to baseline was recorded at one and three years follow-up, Figure 2-5 and Table 2-7.

Figure 2-5 reduction in mean prednisolone dose in Behcet disease (BD) versus non-Behcet disease patients.

(Top) Non-Behcet. There was a statistically significant (*) reduction in mean daily prednisolone dose at three months on biologics. But the reduction became none significant compared to baseline at one and three years follow-up.

(Bottom) BD showed a higher baseline prednisolone dose compared to other diseases. However, a superior corticosteroid sparing was achieved on biologics, and the reduction in mean prednisolone dose was highly statistically significant (**) at all follow-up visits. Also, the mean prednisolone was less than 5 mg/ day at last follow-up. Please refer to table 2-7 for corresponding p values.

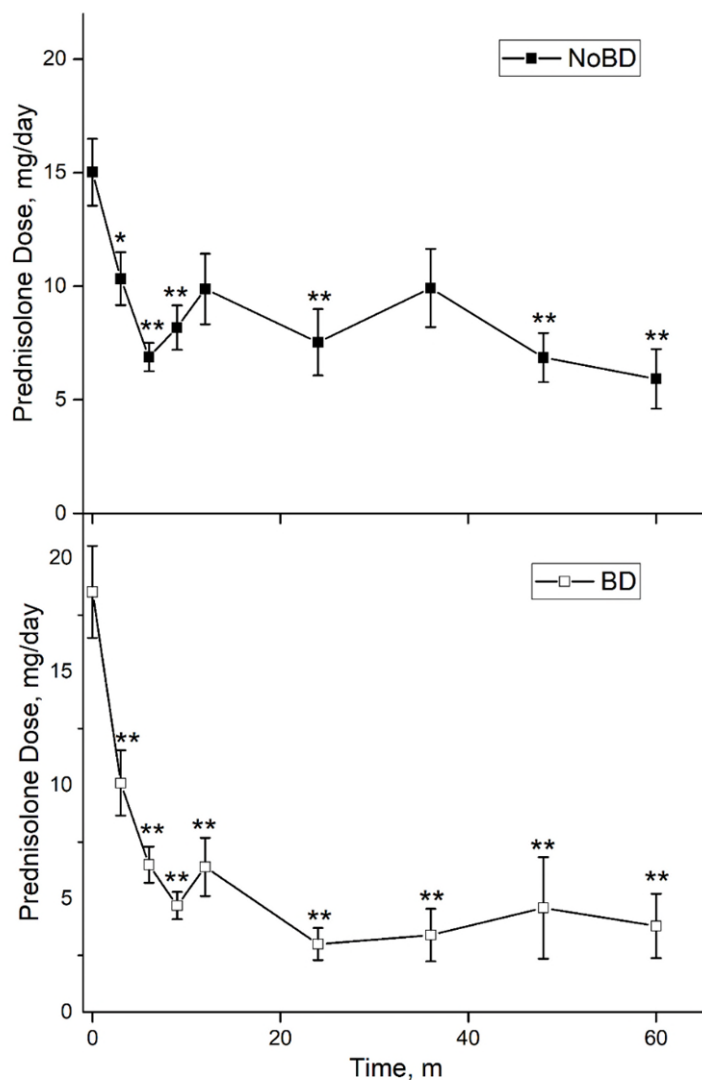


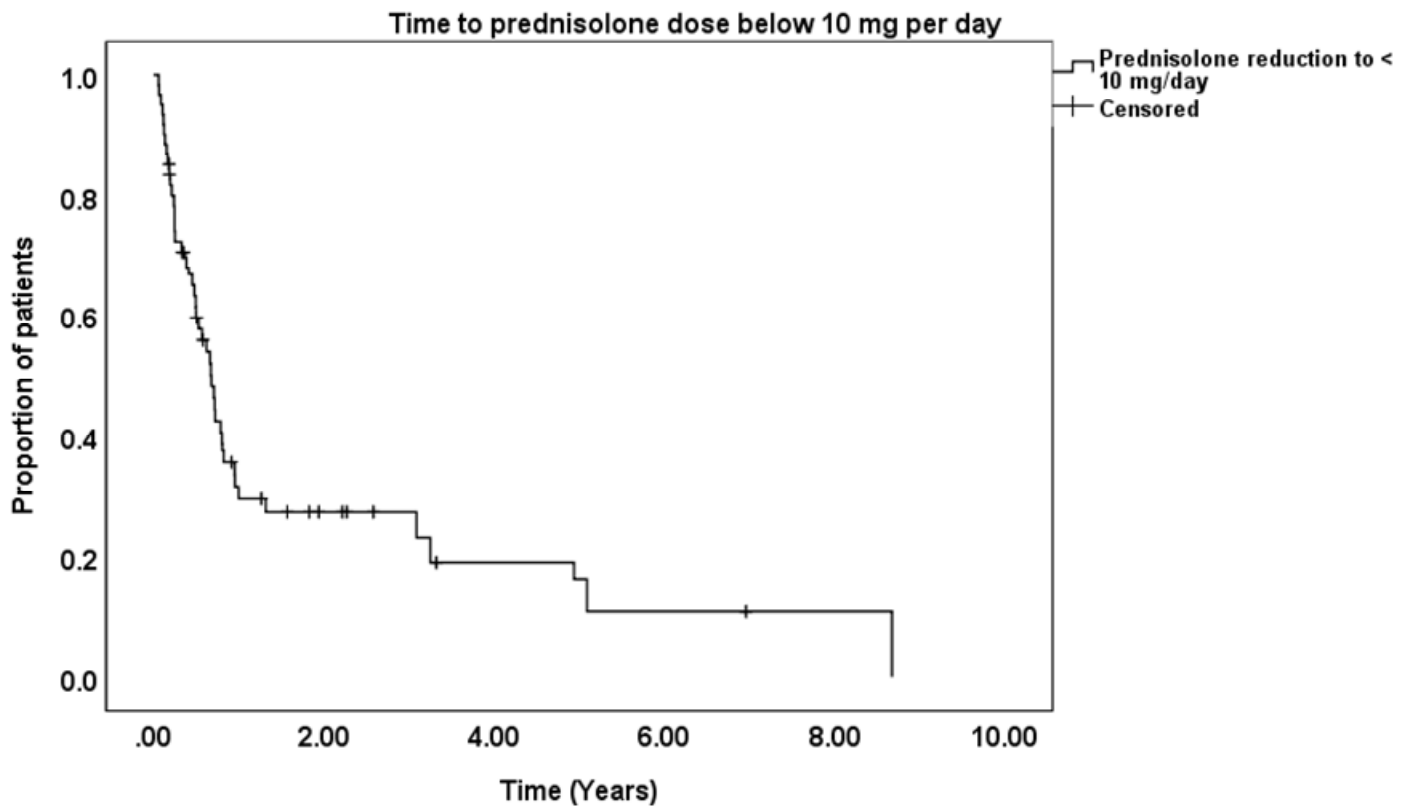
Table 2-7 Prednisolone dose for Behcet and non-Behcet disease patients, the reduction in mean oral prednisolone dose was consistently highly statistically (**) significant from three months until the last follow-up in Behcet patients compared to a non-Behcet disease.

Comparing prednisolone at baseline versus other follow-up visits		
TIME (Months)	Behcet disease (P-value)	Non-Behcet disease (P-value)
Three months	** 0.001	*0.03
Six months	**<0.0001	**<0.0001
Nine months	**<0.0001	**0.005
12 months	**<0.0001	0.12
24 months	**<0.0001	**0.001
36 months	**<0.0001	0.08
48 months	**<0.0001	**<0.0001
60 months	**<0.0001	**<0.0001
* Statistically significant, ** highly statistically significant		

2.13.2 Time to prednisolone dose less than 10 mg/day

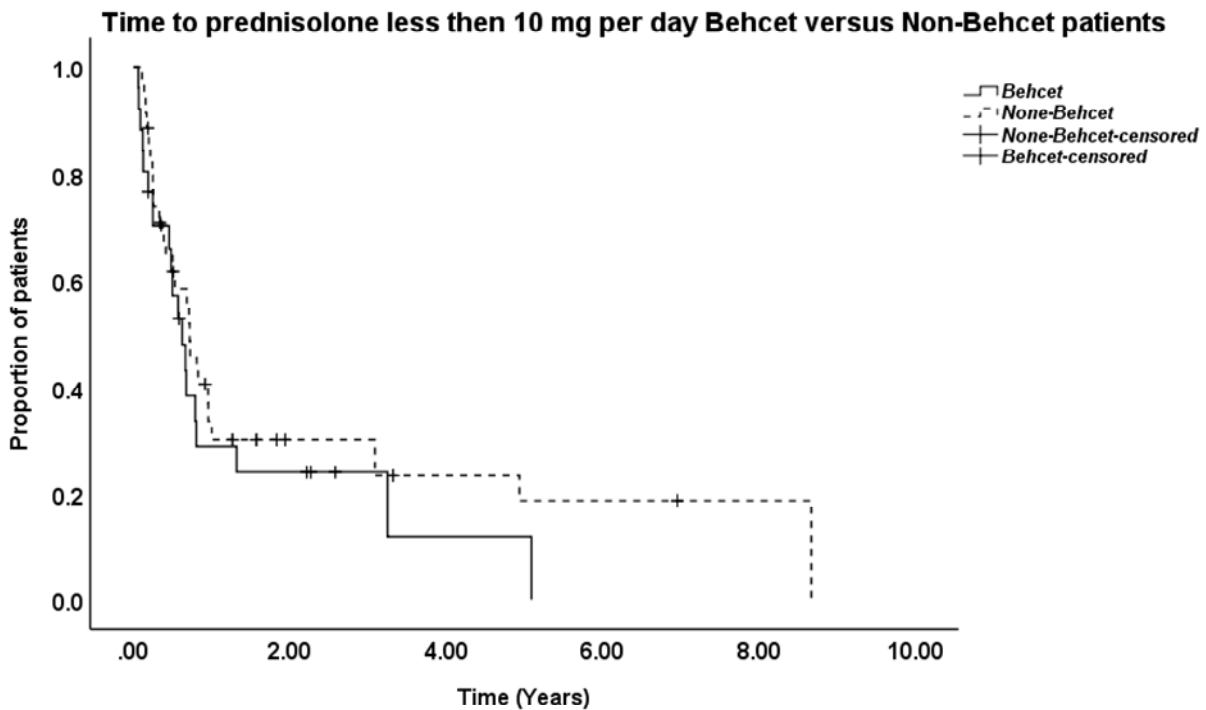
We analysed the time to prednisolone dose < 10 mg per day, this analysis included 55 patients (those whose prednisolone dose was below 10 mg (23 patients) or unknown (4 patients) at time of starting biologics were excluded). Out of 55 patients, 22 have a diagnosis of Behcet disease, and 33 patients were non-Behcet disease patients. On biologics, 47 out of 55 patients (85%) achieved a daily prednisolone dose less than 10 mg at an estimated mean of 1.59 ± 0.36 SEM years; 95%CI 0.88 - 2.30 median time was 0.52 ± 0.10 ; 95%CI 0.32-0.73 years. Figure 2-6.

Figure 2-6 For all study population, the estimated mean time to prednisolone dose less than 10 mg per day, was 1.97 ± 0.30 SEM years; 95%CI 1.37-2.56.



The estimated mean time to prednisolone < 10 mg per day for the non-Behcet disease patients was 1.99 ± 0.54 years; 95% CI 0.92 - 3.05, median time 0.67 ± 0.12 SEM; 95% CI 0.43 - 0.92. For Behcet disease patients the estimated mean time was 1.02 ± 0.34 ; 95%CI 0.35-1.69, median time is 0.49 ± 0.22 SEM; 95%CI 0.06-0.93. Although the mean time for Behcet patients is almost half than those with non-Behcet disease patients, a comparison between the two groups did not show a statistically significant difference in time to prednisolone to less than 10 mg per day, (p -value =0.19, Log Rank, Mantel-cox, Test), Figure 2-7.

Figure 2-7 Comparison between BD and none BD patients in mean time to prednisolone dose <10 mg/day shows a statistically non-significant difference between the two groups (p-value= 0.19).



Analysing data from 70 patients, 39 (47.7%) on infliximab and 31 (37.8%) on adalimumab. The median time to prednisolone dose of less than 10 mg daily for the infliximab group was six months versus three months for the adalimumab group, but it was non-significant (p-value 0.32), Log-Rank test, Figure 2-8. The estimated mean for the infliximab group was $13.60 \pm 5.55\text{SEM}$, 95%CI 2.71- 24.48, median 6.34 ± 0.99 months, while for the adalimumab group the estimated mean was 7.78 ± 2.21 , 95%CI 3.44- 12.11, estimated median 3.02 months. Patients on rituximab achieved a safe dose of prednisolone (<10mg/day) by nine months. The numbers for etanercept and vedolizumab, were 6 and three months, respectively, however, the number of cases was relatively small compared to other biologics. Time to prednisolone <10 mg/day on different biologics is displayed in Table 2-8.

Figure 2-8 Infliximab versus adalimumab in time to prednisolone dose under 10 mg per day. There was no statistically significant difference in time to prednisolone dose less than 10 mg per day, (p value 0.32, Log-Rank test).

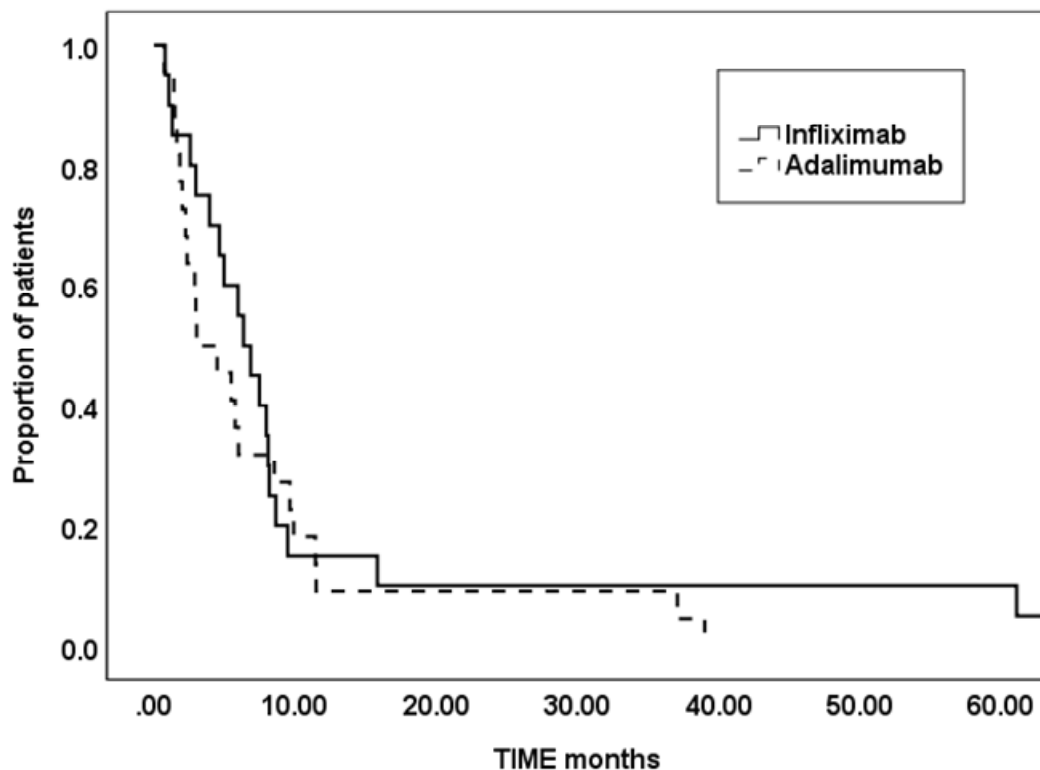


Table 2-8 median time to prednisolone less than 10 mg per day among different biologic agents.

Time to prednisolone <10mg/day, months,	Median (95% CI)
Infliximab	6.0 (3.37-8.63)
Adalimumab	3.0 (1.77-4.23)
Etanercept*	6.0
Rituximab	9.0 (0.68-17.32)
Vedolizumab*	3.0
CI- confidence interval	
* Few cases, unable to generate 95% CI.	

For non-Behcet disease patients, the median time for prednisolone dose less than 10 mg per day on infliximab was three months (95%CI 0-12), and for adalimumab, the median was three months (95%CI 0-9). There was no statistically significant difference in median time to prednisolone dose less than 10 mg per day between these two biologics, (p-value= 0.45). Figure 2-9. Similarly, for Behcet disease patients the median for infliximab was six months and for adalimumab was three months, but there was no statistically significant difference between these two biologics (p-value= 0.42). Figure 2-10.

Figure 2-9 Comparing infliximab versus adalimumab in time to prednisolone under 10 for non-Behcet. The median for infliximab was 3 months (95% 0-12); adalimumab median 3 months (95% CI 0-9), (p-value=0.45)

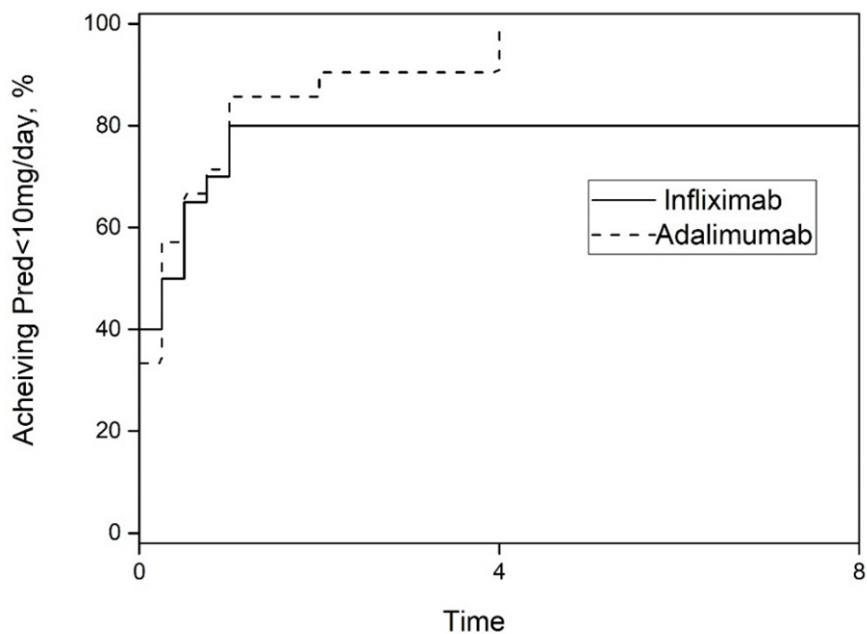
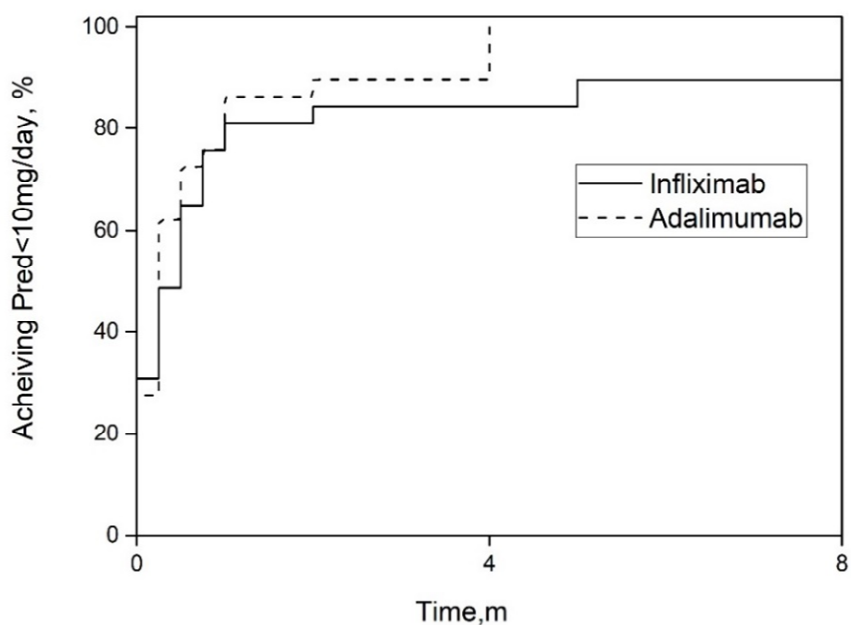


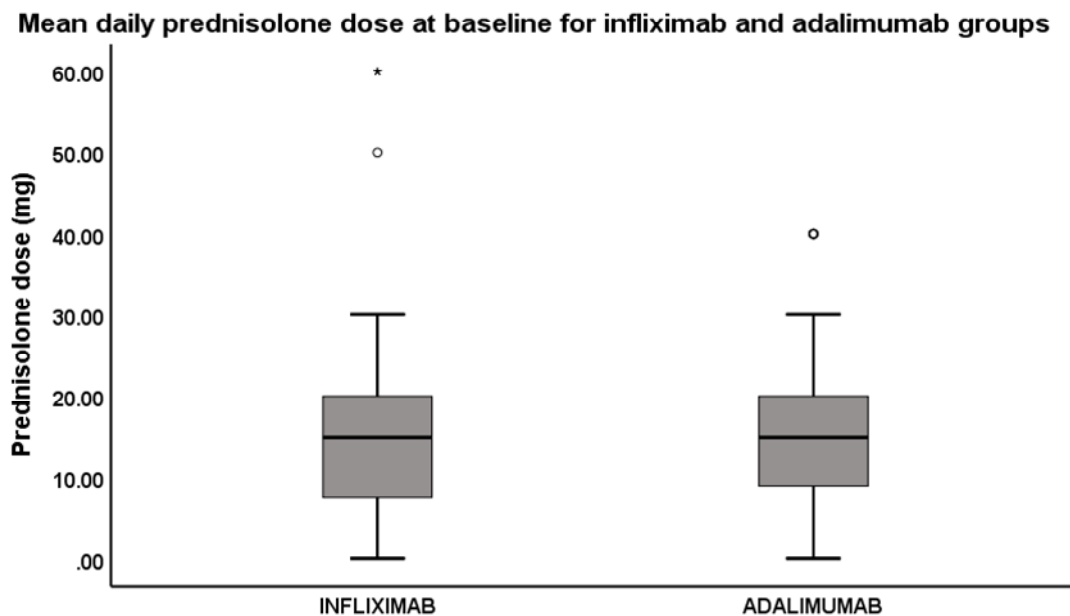
Figure 2-10 Time to prednisolone under 10 mg adalimumab versus infliximab in Behcet disease subjects. The median for infliximab was 6 months (95%CI 3-9 months), adamilumab median 3 months (95%CI 3-6) (p-value=0.42)



2.13.3 Mean reduction in daily prednisolone dose on infliximab versus adalimumab

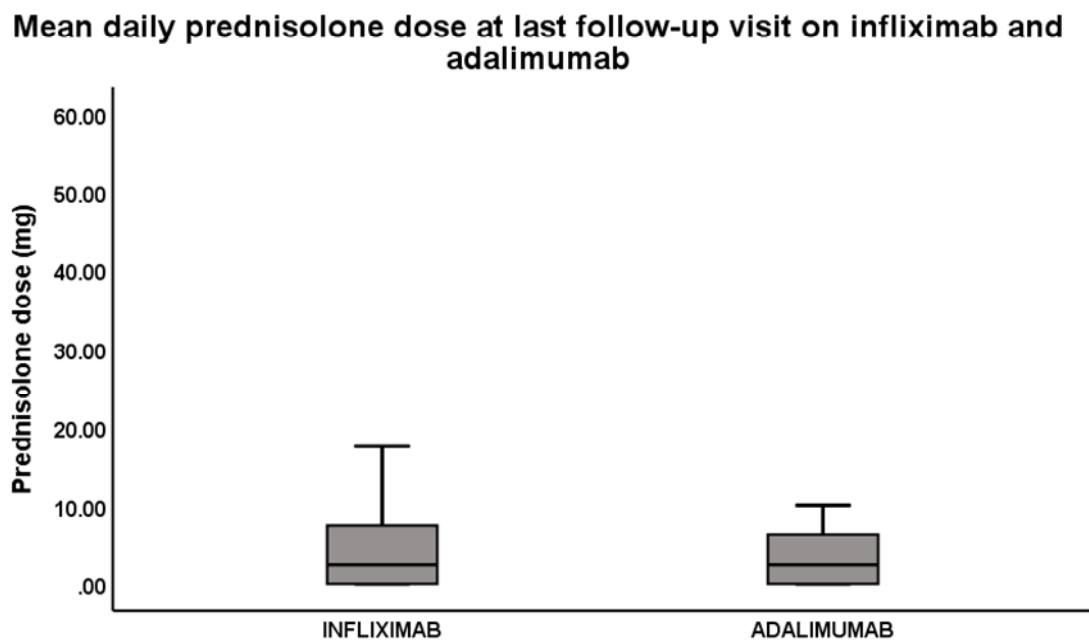
The third analysis compared the mean dose of corticosteroids on both infliximab and adalimumab at baseline and subsequent follow-up visits on biologics. This analysis included 70 patients (39 on infliximab and 31 on adalimumab). The mean prednisolone dose at baseline for patients on infliximab was 15.57 ± 2.30 SEM and for adalimumab group was 17.78 ± 2.86 mg. There was no significant difference in mean prednisolone dose between the two biologics at baseline (p -value=0.54, Mann Whitney U test, two-sided). Figure 2-11.

Figure 2-11 Analysing the mean prednisolone dose at baseline (starting biologics) shows no significant difference between infliximab and adalimumab (p -value=0.54, Mann Whitney U test, two-sided).



At last follow-up visit on biologics the mean prednisolone dose for infliximab group was 4.57 ± 0.78 mg, and for the adalimumab group, it was 3.29 ± 0.71 mg. There was no significant difference between these two biologics at last visit, (p-value =0.29, Mann Whitney U test, two-sided). Figure 2-12.

Figure 2-12 Analysing the mean daily prednisolone dose between infliximab and adalimumab at last follow-up visit shows no statistically significant difference (p-value=0.29, Mann Whitney U test, two-sided). Both drugs seems to have similar efficacy with regards to corticosteroid sparing.

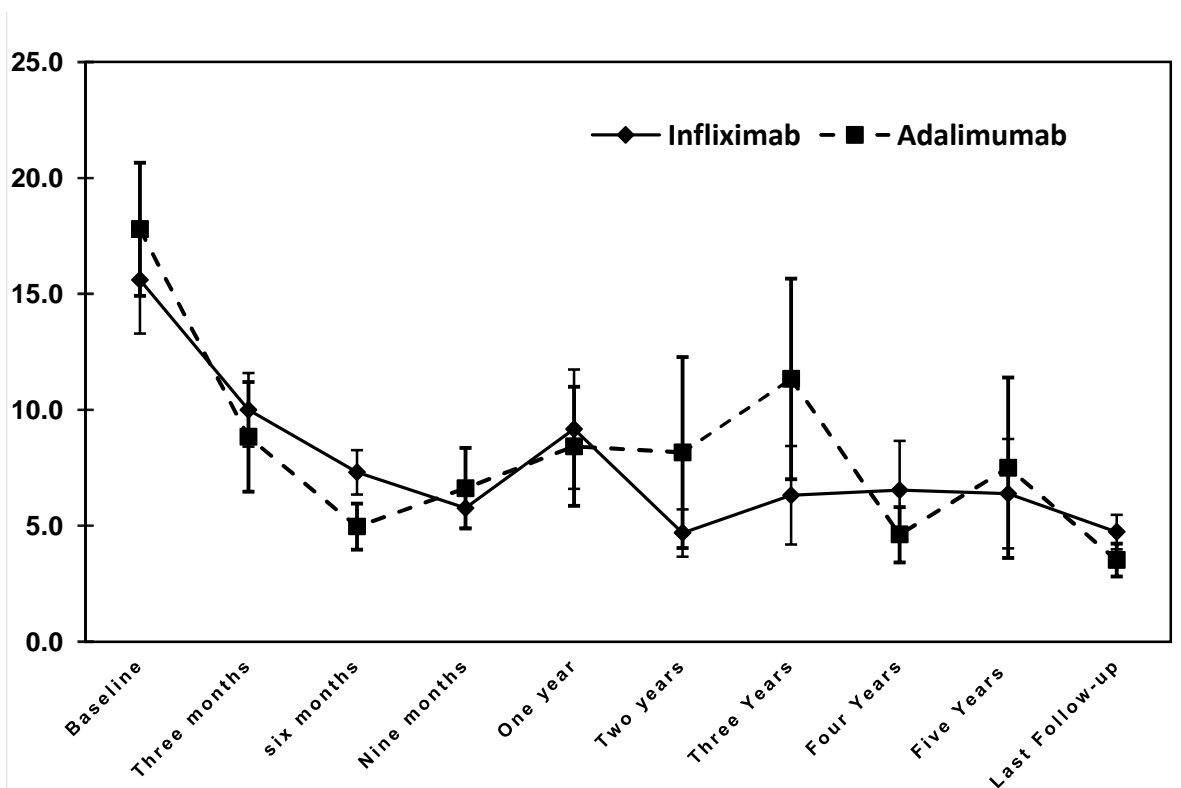


Similarly, there was no statistically significant difference between these two biologics at all follow-up visit. Please see table 2-9 and Figure 2-13.

Table 2-9 Mean prednisolone dose at all study follow-up visits for infliximab and adalimumab groups. There was no statistically significant difference between the two groups (p-value >0.05).

Mean prednisolone dose (mg)					P-value
	Infliximab	±SE	Adalimumab	±SE	
Baseline	15.6	2.3	17.8	2.9	0.547
Three months	10.6	1.6	8.8	2.4	0.071
Six months	7.3	1.0	5.0	1.0	0.110
Nine months	5.8	0.9	6.6	1.7	0.906
One year	9.2	2.6	8.4	2.6	0.656
Two years	4.7	1.0	8.2	4.1	0.963
Three Years	6.3	2.1	11.3	4.3	0.375
Four Years	6.5	2.1	4.6	1.2	0.653
Five Years	6.4	2.4	7.5	3.9	0.799
Last Follow-up	4.7	0.7	3.5	0.7	0.297

Figure 2-13 Change in mean daily prednisolone dose on infliximab and adalimumab at all follow-up visits shows no statistically significant difference between the two anti TNFα agents.



2.14 Best corrected visual acuity

Best corrected visual acuity at baseline was 0.5 ± 0.05 LogMAR, improving significantly to 0.4 ± 0.05 LogMAR at six months ($p=0.006$, Generalized Estimating Equation **GEE**), Table 2-10, and remaining unchanged for the remainder of 60 months follow-up, Figures 2-14, 2-15. While statistically significant the improvement is not clinically significant, therefore BCVA was regarded as stable. Among those with follow-up longer than five years, BCVA remained stable and was found to be 0.3 ± 0.09 LogMAR at ten years.

From 4 years follow-up vision showed a decline toward baseline visual acuity, and at five years the mean visual acuity was 0.5 LogMAR, which is similar to baseline vision. However, there were only 48 eyes at five years follow-up, of which 19 eyes (40%) had a visual impairment and this dropped to only 12 at five years, and the vision in 7 eyes improved. Therefore, the decline in vision was transient and attributed to either development of cataract or a relapse of the inflammatory condition.

Table 2-10 Mean BCVA at baseline and subsequent follow-up visits on biologics

BCVA (LogMAR)	Mean	± Standard error	Minimum	Maximum
Baseline	0.5	0.05	-0.07	2.9
Three months	0.4	0.05	-0.18	2.9
Six months	0.4	0.05	-0.17	2.9
Nine months	0.4	0.05	-0.18	2.9
One year	0.4	0.06	-0.09	2.9
Two years	0.4	0.07	-0.17	2.9
Three years	0.4	0.07	-0.17	2.9
Four years	0.4	0.08	-0.07	2.9
Five years	0.5	0.11	-0.07	2.9
Last Follow-up	0.4	0.05	-0.22	2.9

Figure 2-14 Change in BCVA on biologics during the follow-up visits (*) statistically significant difference compared to baseline at 3, 6, 9 months and 2-year follow-up.

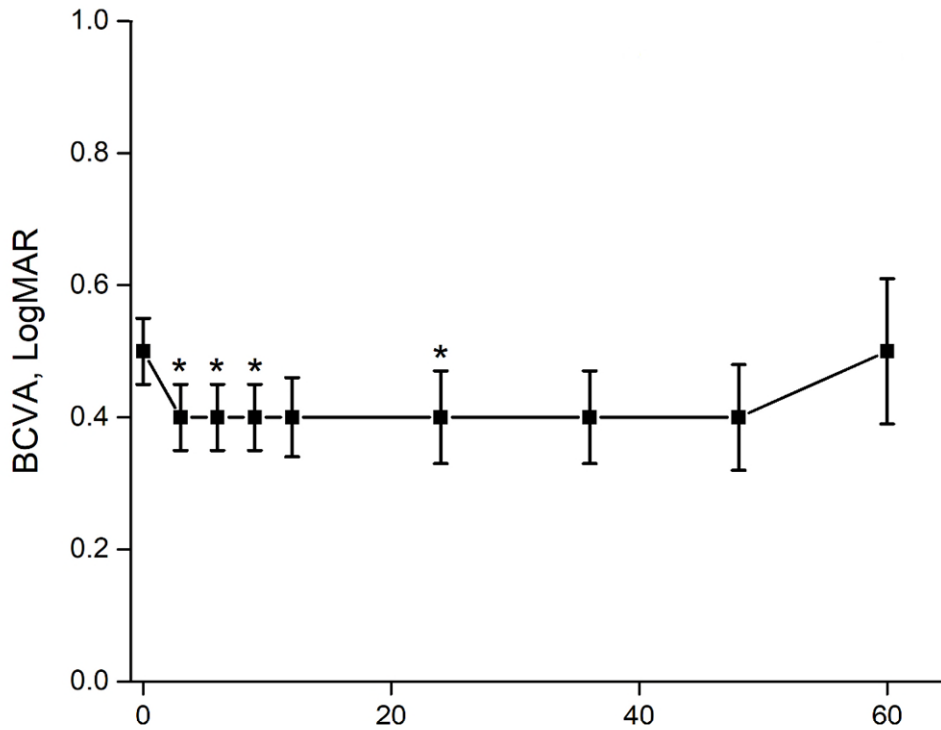
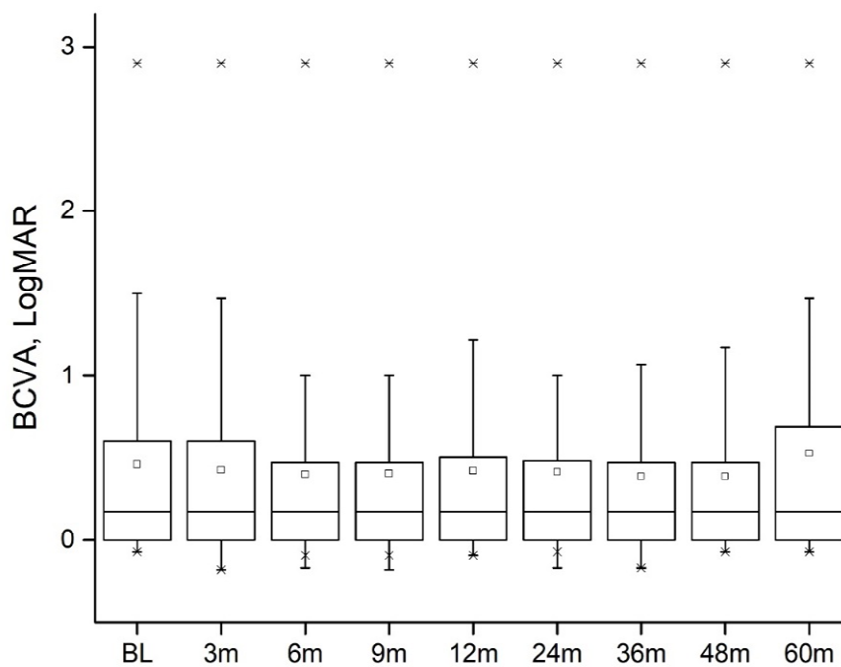


Figure 2-15 BCVA in LogMAR units at baseline, 3, 6, 9 and 1-5 years, Boxplots, there is a statistically significant improvement in vision at 3, 6, nine months and two years compared to baseline.



Baseline visual acuity compared to subsequent follow-up visits are displayed in table 2-11.

Table 2-11 Comparing baseline BCVA at baseline with different follow-up time points.

Follow-up visits (Months)	BCVA (GEE**) P-value
Three months	*0.02
Six months	*0.006
Nine months	*0.02
12 months	0.1
24 months	*0.048
36 months	0.184
48 months	0.51
60 months	0.53
** GEE Generalized Estimating Equation BCVA Best Corrected visual acuity * Statistically significant	

2.14.1 Analysing BCVA in non-Behcet disease versus Behcet disease patients.

The analysis of BCVA in non-Behcet disease patients shows a statistically significant improvement at six months compared to baseline. The BCVA remained stable afterwards, and the mean difference in BCVA at the following study visits remained stable (non-significant difference) compared to baseline. Behcet disease, on the other hand, had a sustained improvement within the first two years follow-up, a statistically significant improvement at nine months and two years. However, the mean BCVA increased after two years follow-up, but with wider confidence intervals the difference from baseline was non-significant. Table 2-12 and Figure 2-16.

Table 2-12 Comparing baseline BCVA (Log MAR) versus different time points (p-values), (*) statistically significant.

TIME (Months)	Behcet's disease	Non-Behcet disease
Three months	0.076	0.1
Six months	0.12	*0.02
Nine months	*0.04	0.07
12 months	0.21	0.17
24 months	*0.04	0.14
36 months	0.43	0.28
48 months	0.19	0.78
60 months	0.53	0.63

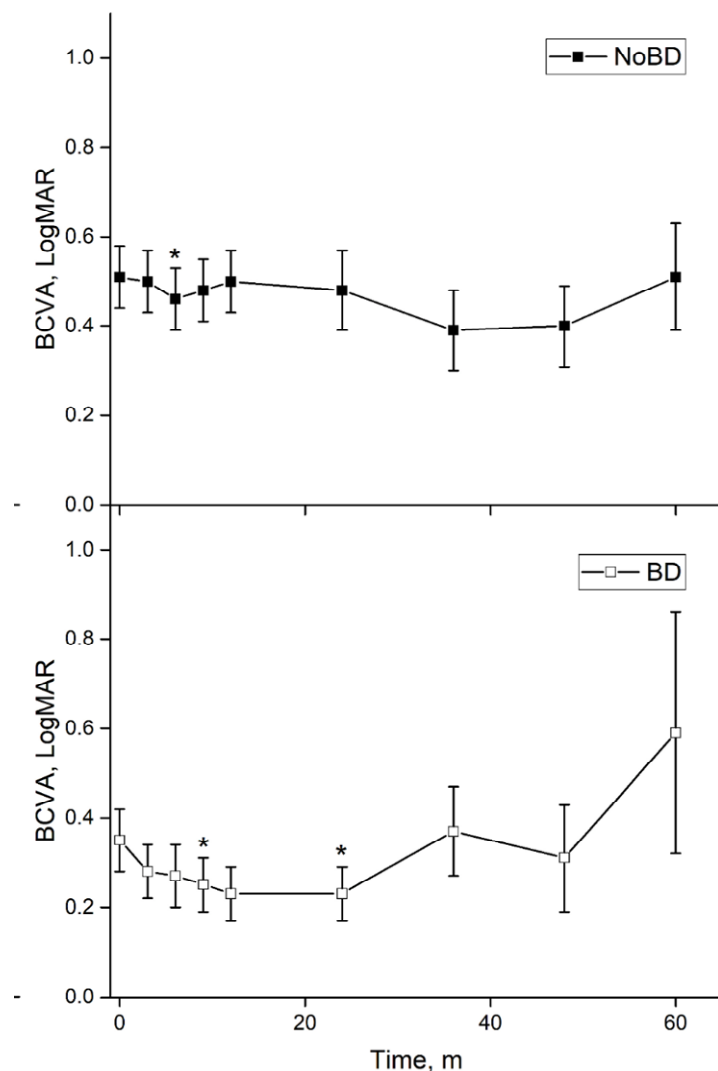
Figure 2-16 Behcet vs non-Behcet disease patients with regards to BCVA on biologics

(TOP)

None BD, BCVA shows a statistically significant difference at 6 months only.

(Bottom)

BD patients, BCVA shows a statistically significant difference at 9 and 2-year follow up compared to baseline. At 5-year there was no significant difference in BCVA compared to baseline. The wide CI reflects the variability in BCVA and small number of subjects (the analysis included only 8 eyes with only 3 have visual impairment).



2.14.2 Causes of vision loss on biologic treatment

At baseline 94 eyes (62.7%) avoided vision loss (BCVA<6/12), 31 eyes (20.7%) had moderate vision loss, and 25 eyes (16.7%) had severe vision loss. At months six, nine and 24 a significantly greater percent of eyes avoided vision loss (70.5%, p=0.004; 68.4%, p=0.4; 74.8%, p=0.01, respectively, Figure 2-17. There was no difference in the rates of vision loss at all other time points. At the final follow-up, 20 eyes had MVL, 45% caused by macular scarring and 26 eyes had SVL, 42.4% caused by macular scarring. The number of eyes with moderate vision loss, severe vision loss and no vision loss along with the total number of eyes at all follow-up visits are displayed in table 2-13.

Figure 2-17 percentage of eyes with no loss of vision, moderate vision loss and severe vision loss during follow-up periods. The proportion of eyes without vision loss rose significantly from 62.7% at baseline to 70.5% and 74.8% at 6 months and 2-year, respectively (p values = 0.004 at 6 months and 0.01 at 2-year.

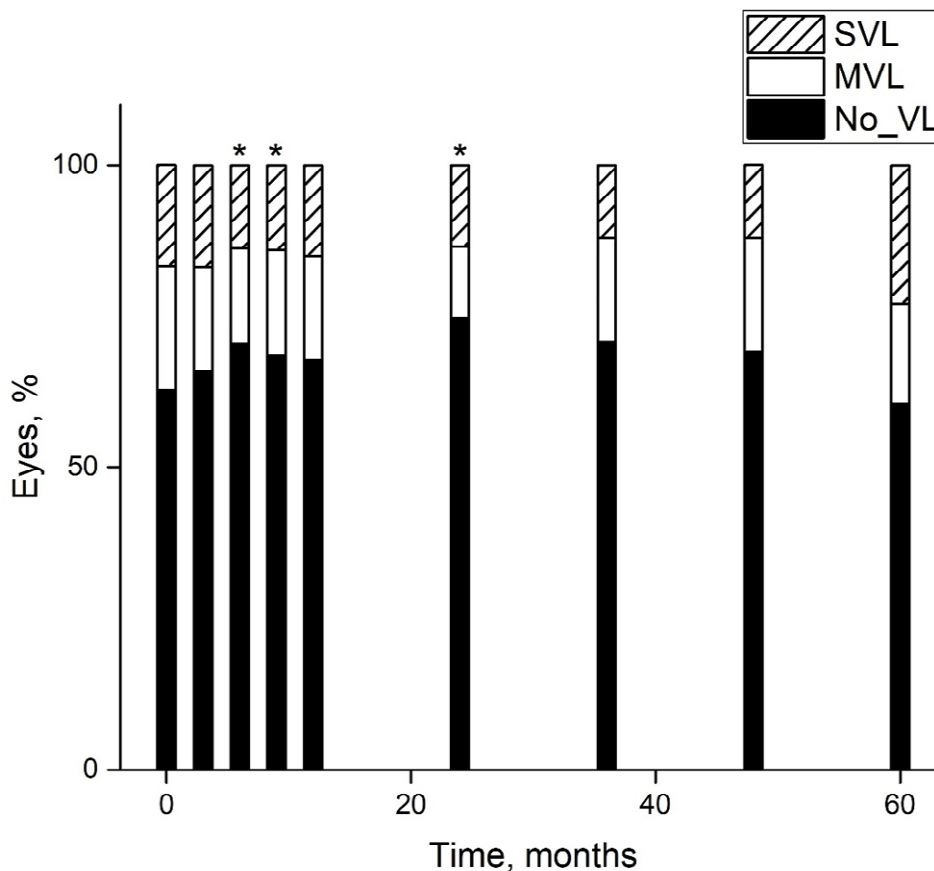


Table 2-13 Number of eyes with or without visual impairment at baseline and subsequent visits on biologics

Time	MVL (n=)	SVL (n=)	No visual impairment	Total (n=)
Baseline	31	25	94	150
Three-months	26	25	98	149
Six-months	23	20	103	146
Nine-months	24	19	93	136
One year	23	20	90	133
Two years	14	16	89	119
Three years	13	9	53	75
Four years	11	7	40	58
Five years	8	11	29	48
Last follow-up	23	25	108	156
MVL moderate vision loss (6/15 >BCVA <6/60) SVL severe vision loss (BCVA ≥ 6/60)				

Macular scarring was the most common cause of irreversible moderate and severe vision loss followed by chronic or recalcitrant CMO. Table 2-14.

Table 2-14 Causes of vision loss on biologics. Macular scarring was the most common cause for both moderate and severe vision loss, whereas, CMO came second to macular scarring.

Causes of vision loss	MVL, n (%)	SVL, n (%)
Macular Scarring	9 (45)	11 (42.4)
ERM*	1 (5)	0 (0)
Amblyopia	1 (5)	0 (0)
RD**	2 (10)	5 (19.2)
CMO***	5 (25)	7 (26.9)
Macular ischaemia	1 (5)	0 (0)
Optic neuropathy	1 (5)	2 (7.7)
Phthisis	0	1 (3.8)
Total	20 (100%)	26 (100%)
MVL moderate vision loss. SVL severe vision loss *ERM epiretinal membrane. **RD retinal detachment. ***CMO cystoid macular oedema		

2.15 Second-line immunosuppressive agent

At baseline 58 out of 82 patients (70.73%) were receiving 2nd-line immunosuppressive treatment, 28 treated with mycophenolate mofetil, 19 treated with methotrexate, six treated with azathioprine, 3 with cyclosporine and 2 with tacrolimus. Of those, 56 (97%) were receiving treatment at a therapeutic dose. By 12 months follow-up 67% were still receiving therapeutic doses of 2nd-line agents, the remainder (33%) had either stopped treatment or reduced to a non-therapeutic dose ($p < 0.0001$, Fisher's Exact test). By 24 and 60 months follow-up 45% and 62% respectively, had either stopped 2nd-line treatment or reduced to a non-therapeutic dose ($p < 0.0001$). Figure 2-18 and table 2-15.

Figure 2-18 Change in the percentage of patients on second-line agents after 20, 40 and 60 months on biologics. Significantly lower proportion of patients receiving therapeutic dose of second line agents after starting biologics compared to baseline. () highly statistically significant difference at 2 and 5 years follow-up (p -value < 0.0001) Fisher's Exact test.**

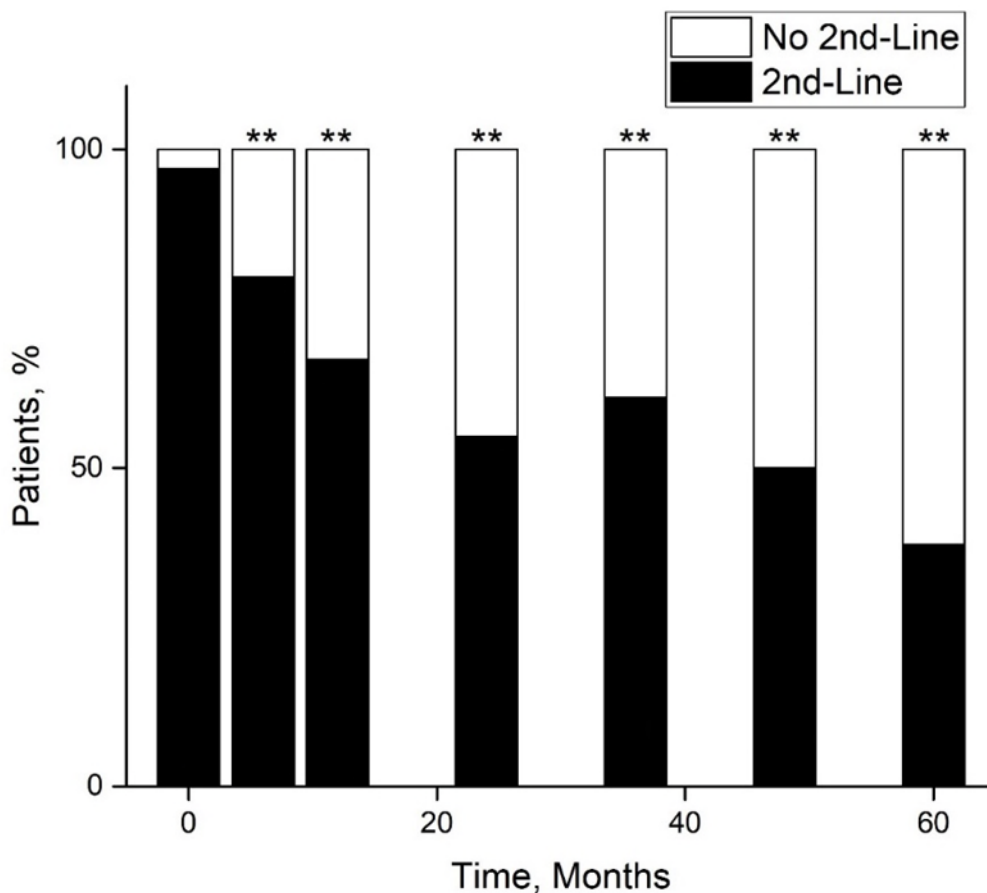


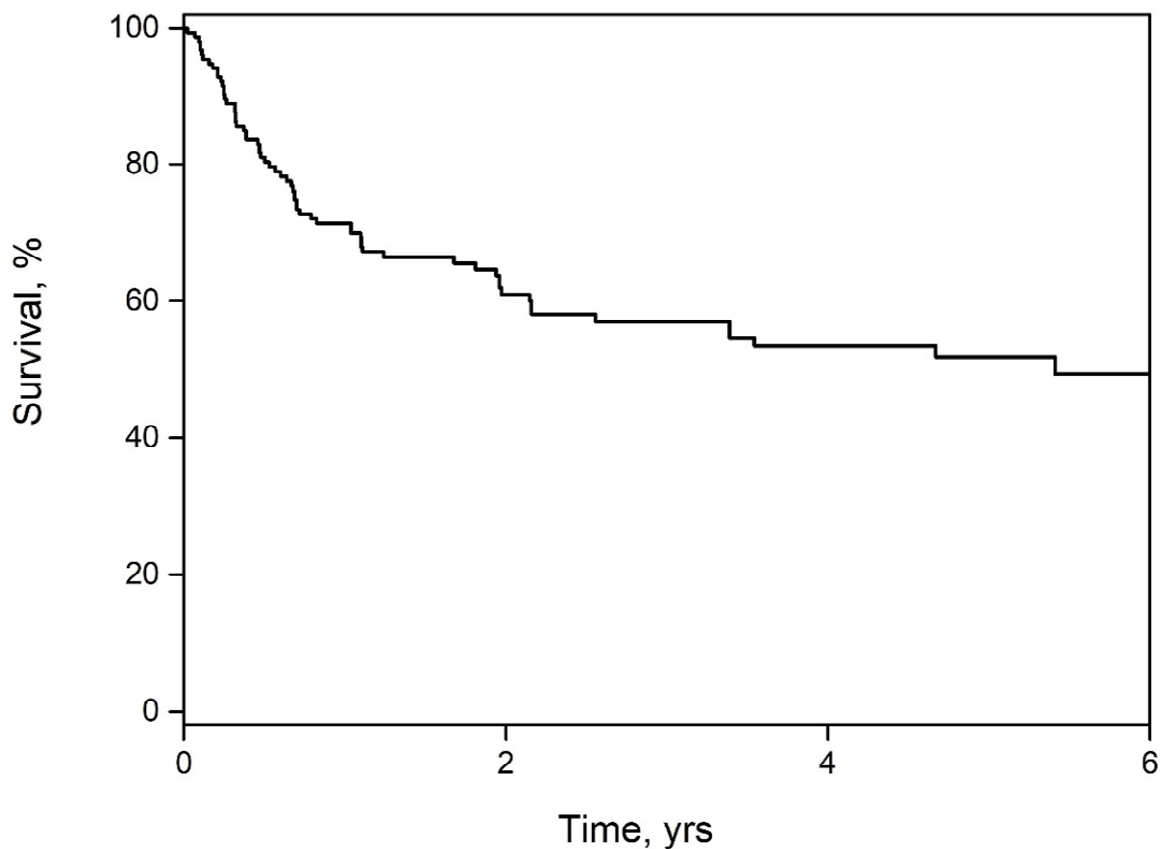
Table 2-15 Percentage of patients on therapeutic dose and a non-therapeutic dose of second-line agents.

Time	Percentage of patients on therapeutic dose IMT	percentage of patients on non-therapeutic dose IMT	Number of patients on Therapeutic IMT	Total	P-value (Fisher's Exact test)
Six months	0.80	0.20	44	55	0.03
One year	0.67	0.33	34	51	0.0001
Two years	0.55	0.45	23	42	0.0001
Three years	0.61	0.39	14	23	0.0001
Four years	0.50	0.50	9	18	0.0001
Five years	0.38	0.62	5	13	0.0001

2.16 Disease relapse

Before baseline (starting biologics) eyes had an average of 4.6 ± 0.32 flares (1.8 ± 0.14 flares/year), while after baseline this reduced to an average of 1.6 ± 0.22 flares (0.6 ± 0.08 flares/year, $p < 0.0001$, **GEE**). 42.3% of eyes ($n=66$) had flares after baseline at an estimated median time to the first relapse of 5.41 years; 95% CI 2.16-5.41, Kaplan Meir, the mean time to disease relapse was 7.08 ± 0.55 SEM years; 95% CI 5.99-8.16. Figure 2-19. Disease control (remission) (defined as ≥ 3 months of no disease activity after starting biologics) was achieved in 87.18% (136 out of 156 eyes).

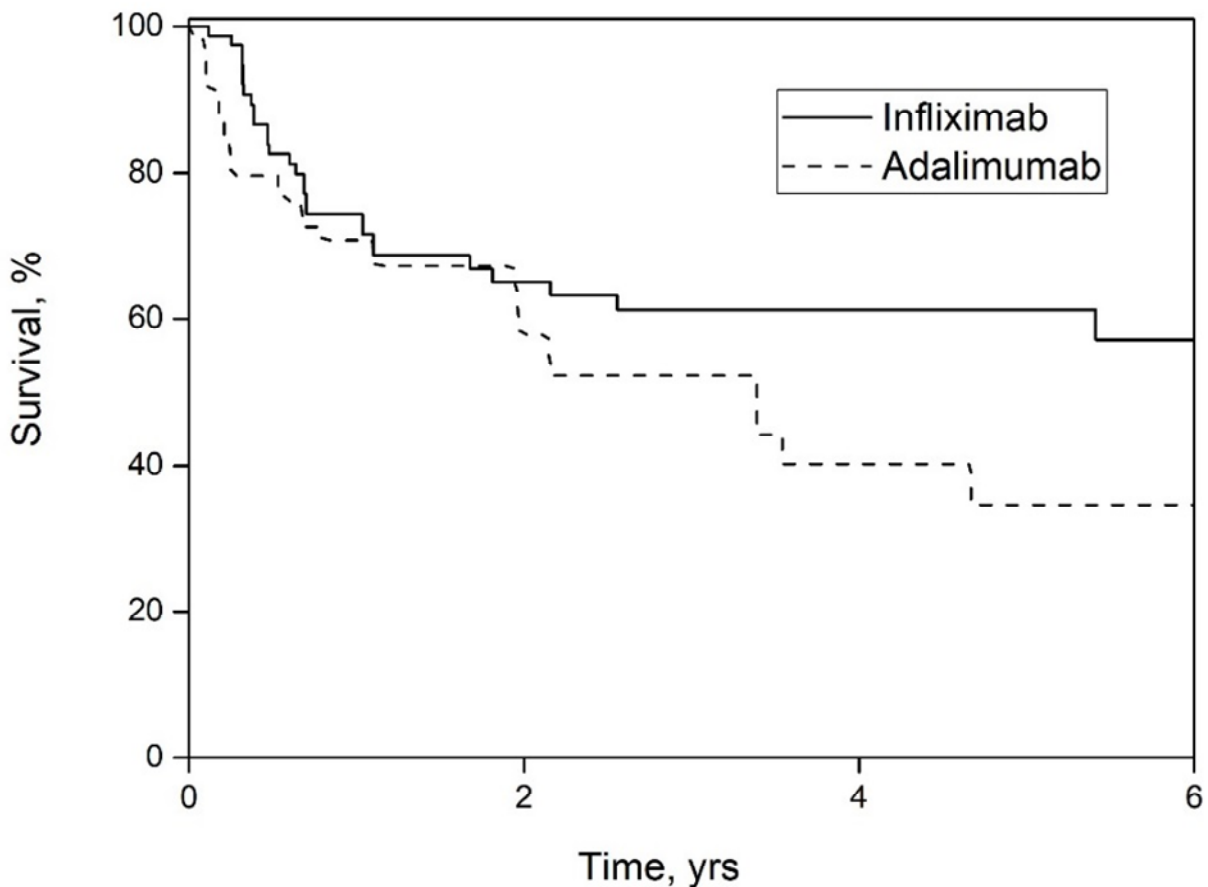
Figure 2-19 the proportion of eyes that flared on biologics was 42.3% ($n=66$). The estimated median time to first disease relapse was 5.41 years.



2.16.1 Survival to the first disease relapse on Infliximab versus adalimumab

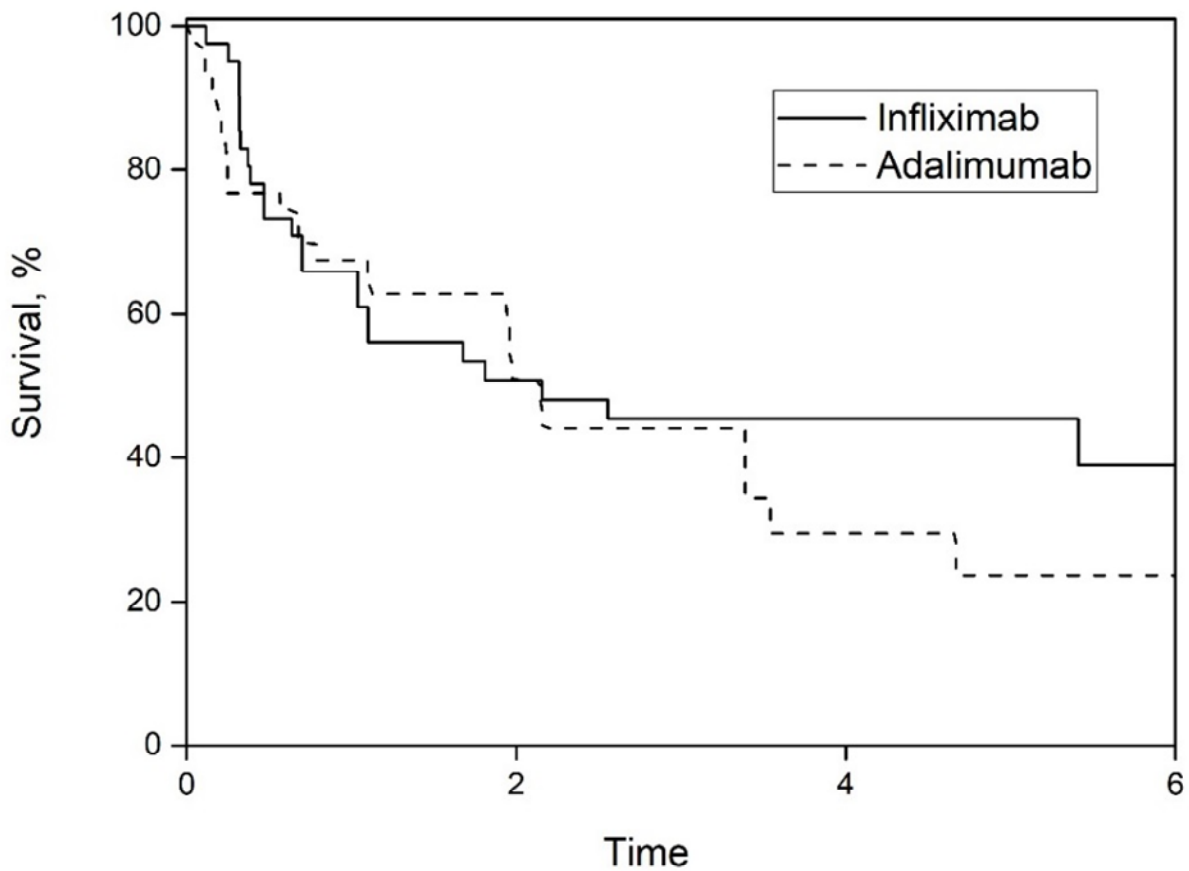
Time to the first flare for all patients on infliximab and adalimumab was analysed. The mean time to first disease relapse on infliximab was 8.02 ± 0.76 ; 95%CI 6.53-9.51, while on adalimumab the mean time to first flare 4.06 ± 0.55 SEM years; 95%CI 2.98-5.14, there was no statistically significant difference between the two biologics in terms of time to first flare, (p -value= 0.097, Log-Rank test). Figure 2-20.

Figure 2-20 Survival from flare on adalimumab versus infliximab in all patients. No statistically significant difference between infliximab and adalimumab with regards to time to the first disease relapse (p -value =0.097, Log-Rank test).



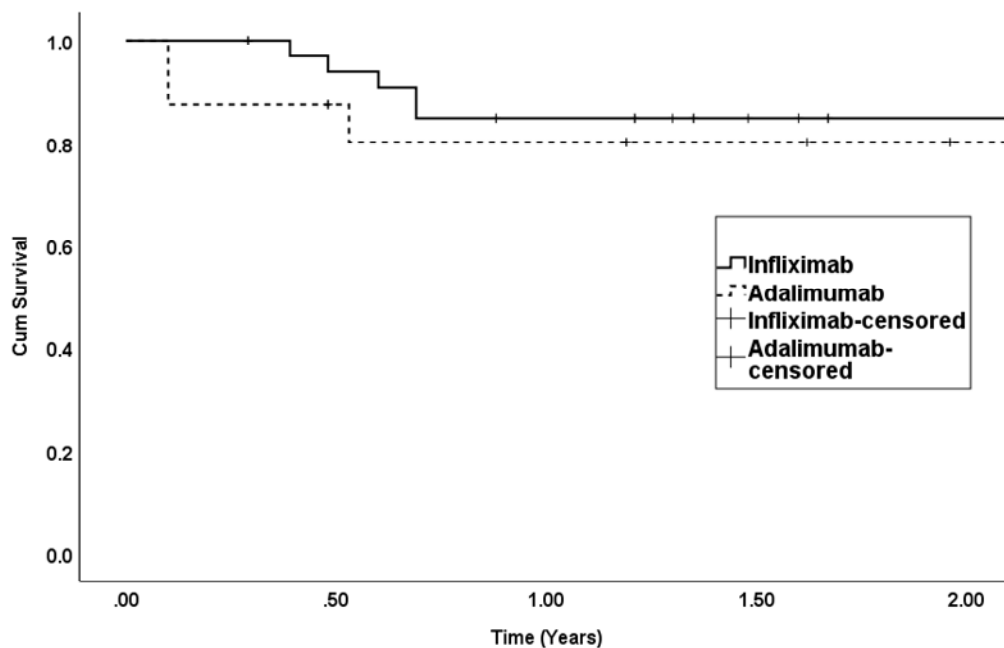
With regards to time to first relapse for non-Behcet patients, there was no significant difference in time to first flare between infliximab and adalimumab (p-value= 0.42, Log-Rank test). Figure 2-21. The mean time to first flare for patients on infliximab was $5.9 \pm 0.99\text{SEM}$; 95%CI 3.96 -7.85 years and for adalimumab, the mean time to first flare $2.81 \pm 0.4\text{SEM}$; 95% CI 2.02-3.59 years.

Figure 2-21 Survival from flare infliximab versus adalimumab in non-Behcet's disease patients. there was no significant difference in time to first flare between infliximab and adalimumab (p-value= 0.42, Log-Rank test).



With regards to Behcet disease patients, 51 eyes were included 35 on infliximab and 16 on adalimumab. Only eight eyes developed disease relapse on anti TNF α agents. For the infliximab group, the mean time to first disease flare was 9.19 ± 0.63 SEM; 95%CI 7.94-10.43 years and for the adalimumab group, it was 6.90 ± 0.85 SEM; 95%CI 5.23-8.57. There was no significant difference in time to first flare between these two biologics (p-value =0 .58, Log-Rank test). Figure 2-22.

Figure 2-22 survival to the first disease relapse on infliximab and adalimumab. There was no significant difference in time to first flare between these two biologics (p-value =0 .58, Log-Rank test)



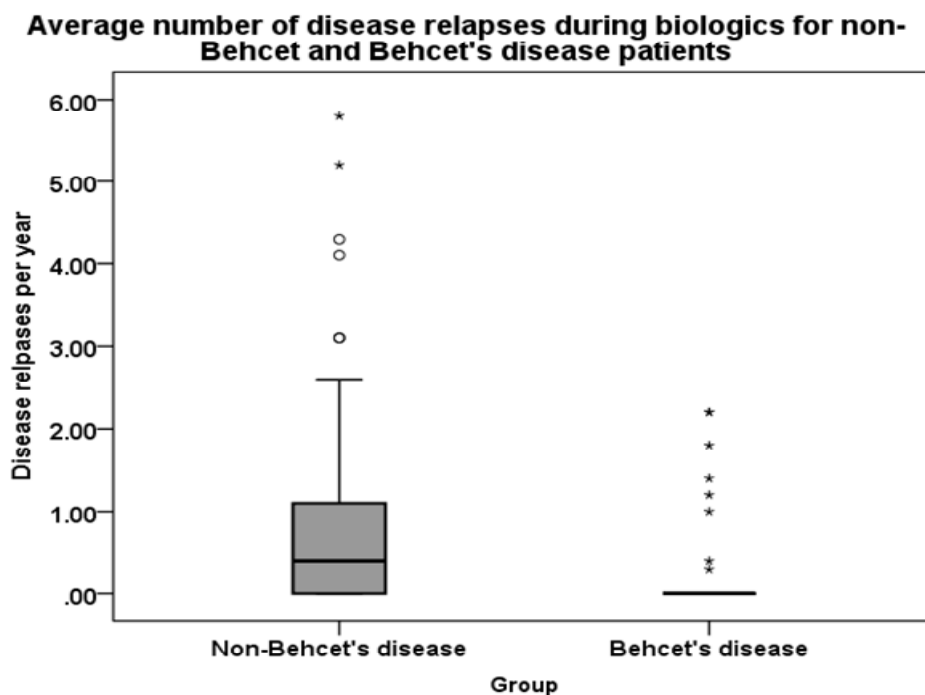
2.16.2 The relapse rate for Behcet and non-Behcet disease patients on biologics

Another analysis involved 51 eyes of Behcet's disease patients regarding the number of disease relapse pre and post biologics. Before biologics 49 eyes (96%) have had disease relapse, on biologics the percentages of eyes with disease relapse dropped to only eight eyes (15.6%), mean time to disease relapse 0.44 ± 0.08 SE years, from 0.10 to 0.69 years, median 0.50 years, IQR 0.17-0.66 years. Before biologics the mean number of disease relapse per year was 1.89 ± 0.25 SE, 95%CI 1.37-2.40. During treatment with biologics the mean number of disease relapse per year dropped significantly to 0.21 ± 0.08 SE, 95%CI 0.05-0.37 (p-value <0.001, Wilcoxon Signed

Rank Test, two-sided). The rate of disease relapse decreased by nine folds on biologic treatment.

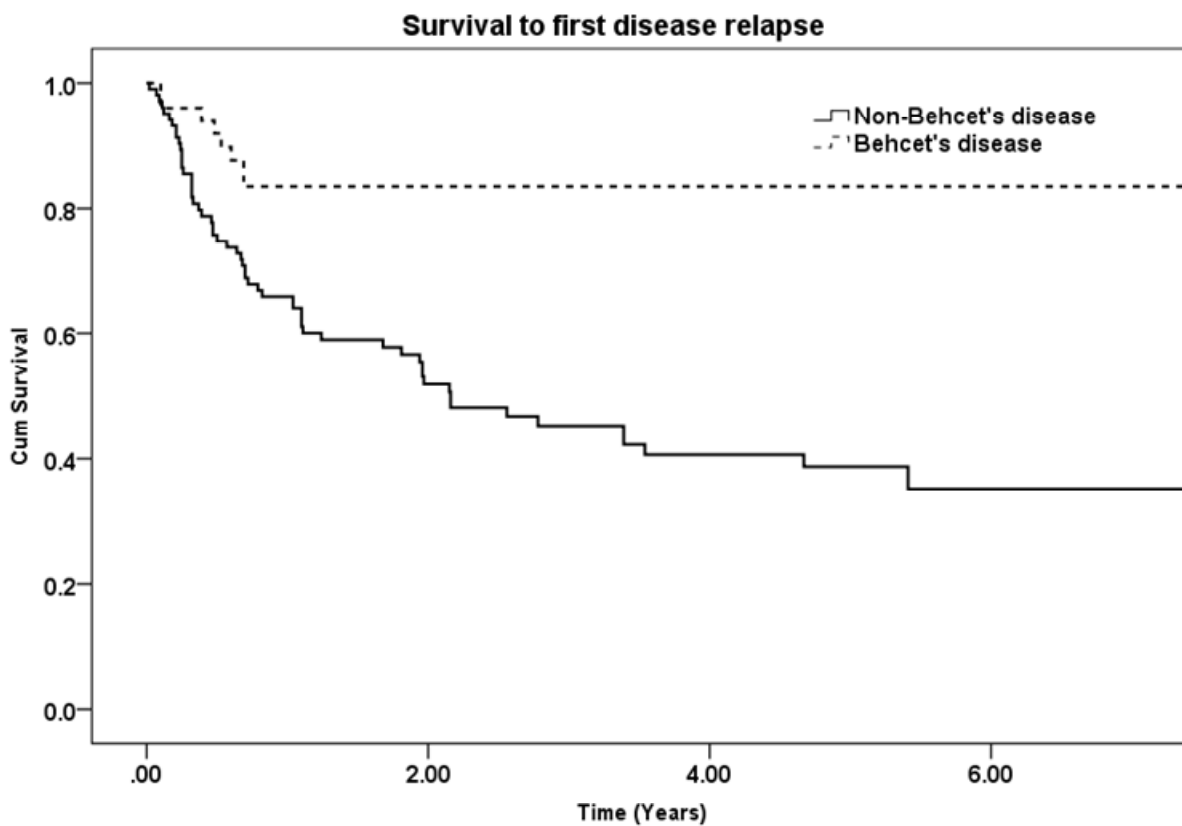
For non-Behcet disease patient, the analysis included 105 eyes, the average number of disease relapses before starting biologics was 1.8 ± 0.16 SE, median 1.38, IQR 0.60-2.52, reduced significantly on biologics to 0.76 ± 0.11 SE, median 0.40, IQR 0-1.10. There was a significant reduction in the mean number of disease relapse per year, (p-value <0.001 , Wilcoxon Signed Rank Test, two-sided). During biologics 58 eyes (55%) develop disease relapse, mean time to first disease relapse was 1.11 ± 0.15 , median 0.67, IQR 0.25-1.84 years. Before biologics there was no significant difference in the average number of disease flares per year in Behcet and non-Behcet disease patients (p-value=0.81, Mann Whitney U Test, two-sided). However, after starting biologics, the mean number of disease relapse per year was significantly less in Behcet disease patients. There was a statistically significant difference between the two groups in the average number of relapses per year, (p-value <0.001 , Mann-Whitney U test, two-sided). Figure 2-23.

Figure 2-23 a statistically significant difference in the average number of disease relapse on biologics in Behcet versus non-Behcet disease patients, (p-value <0.001). Mann-Whitney U test, two-sided).



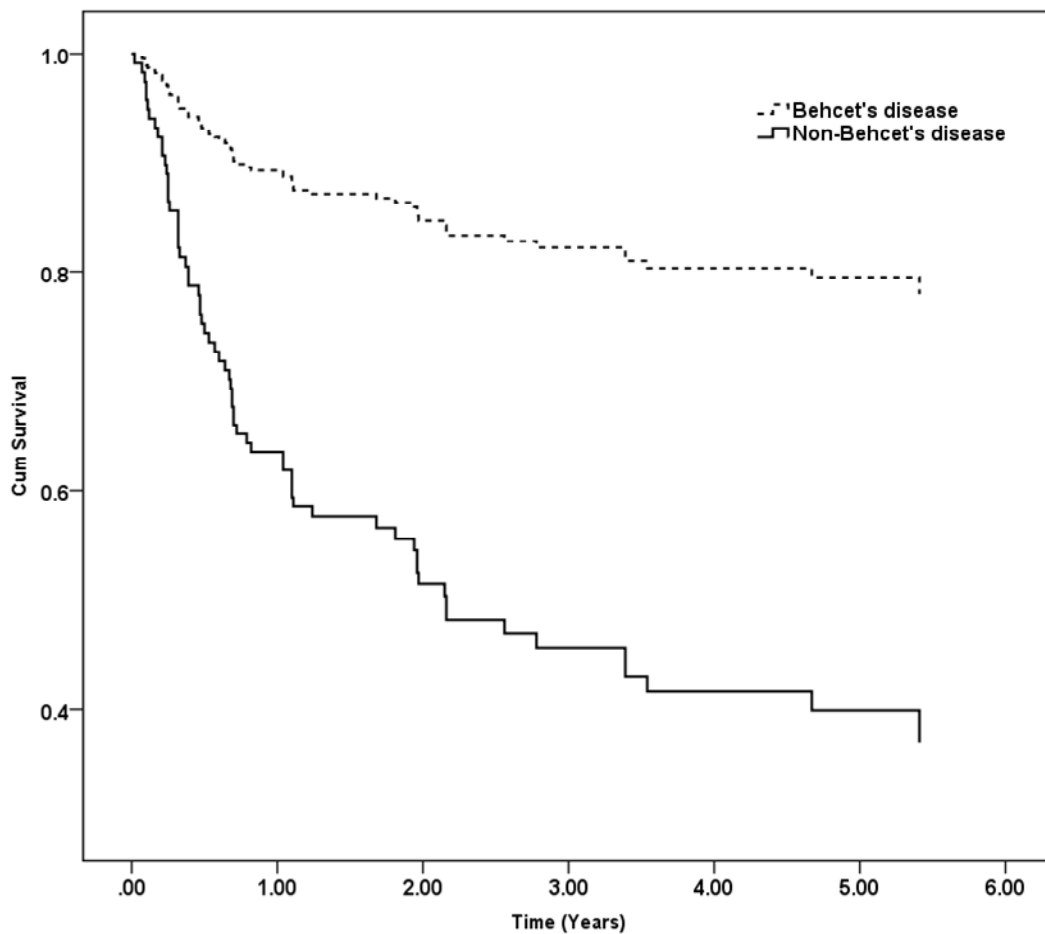
For non-Behcet disease patients, the mean time to the first flare was 5.53 ± 0.64 SEM years, 95%CI 4.27-6.80 median 2.16 ± 0.56 years, 95% CI 1.04-3.27 years. While Behcet disease patients had a mean survival time to first disease relapse of 9.02 ± 0.55 years, 95%CI 7.94 -10.10 years, median time could not be calculated due to the small number of eyes with disease relapse on biologics (<50%). Kaplan Meir survival analysis shows a highly statistically significant difference between the two groups (p-value<0.001, Log-Rank test). Figure 2-24.

Figure 2-24 Kaplan Meir analysis for survival to first disease relapse for Behcet versus non-Behcet disease patient, shows a highly statistically significant difference between the two groups (p-value<0.001).



To assess for the size of the difference between time to first disease relapse on biologics between Behcet disease and non-Behcet disease patients, we performed a Cox regression analysis, which showed a highly statistically significant difference between the two groups with a hazard ratio HR of 0.25; (p-value of <0.001; 95%CI 0.11-0.52). A 75% relative risk reduction for disease relapse on biologics treatment for Behcet disease patients compared to other uveitides. Figure 2-25.

Figure 2-25 Cox regression analysis, which showed a highly statistically significant difference between the two groups with a hazard ratio HR of 0.25; (p-value of <0.001).

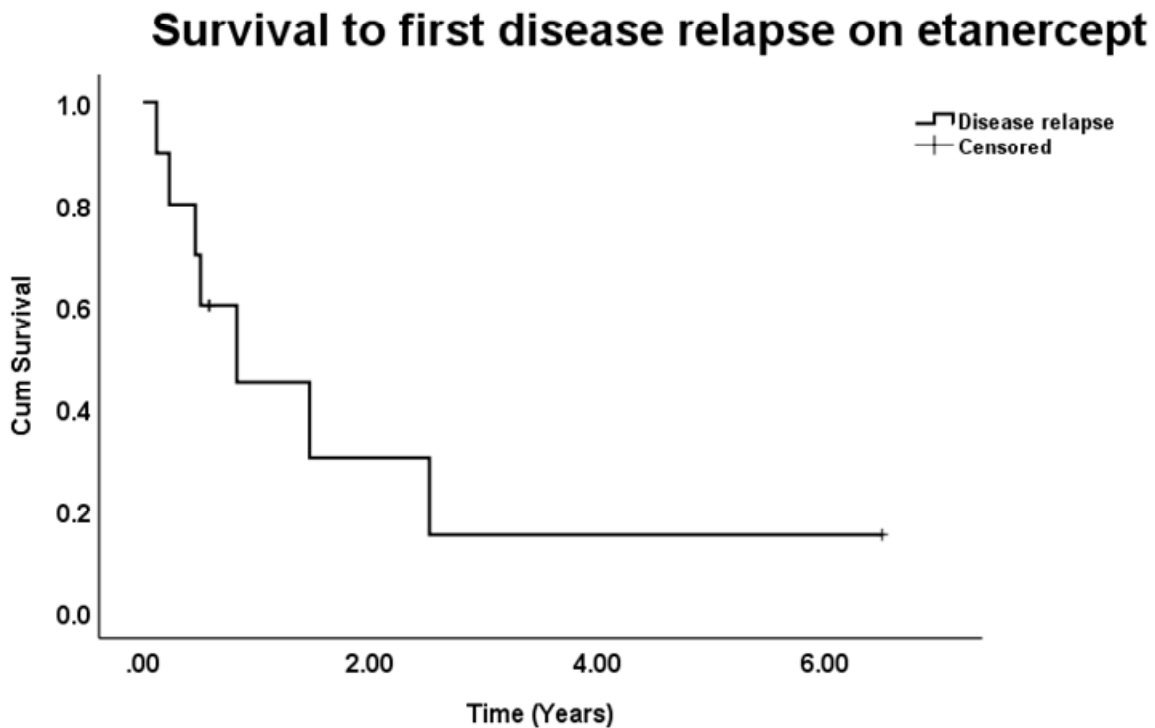


2.16.3 Disease relapses on other agents

2.16.3.1 Etanercept

With regards to etanercept 7 out of 10 eyes developed disease relapse and two of these seven eyes did not have uveitis prior commencing etanercept. The mean time to first disease relapse was 1.82 ± 0.76 SEM; 95% CI 0.32-3.33 years, estimated median time 0.82 years and IQR 0.23-1.46 years. Figure 2-26.

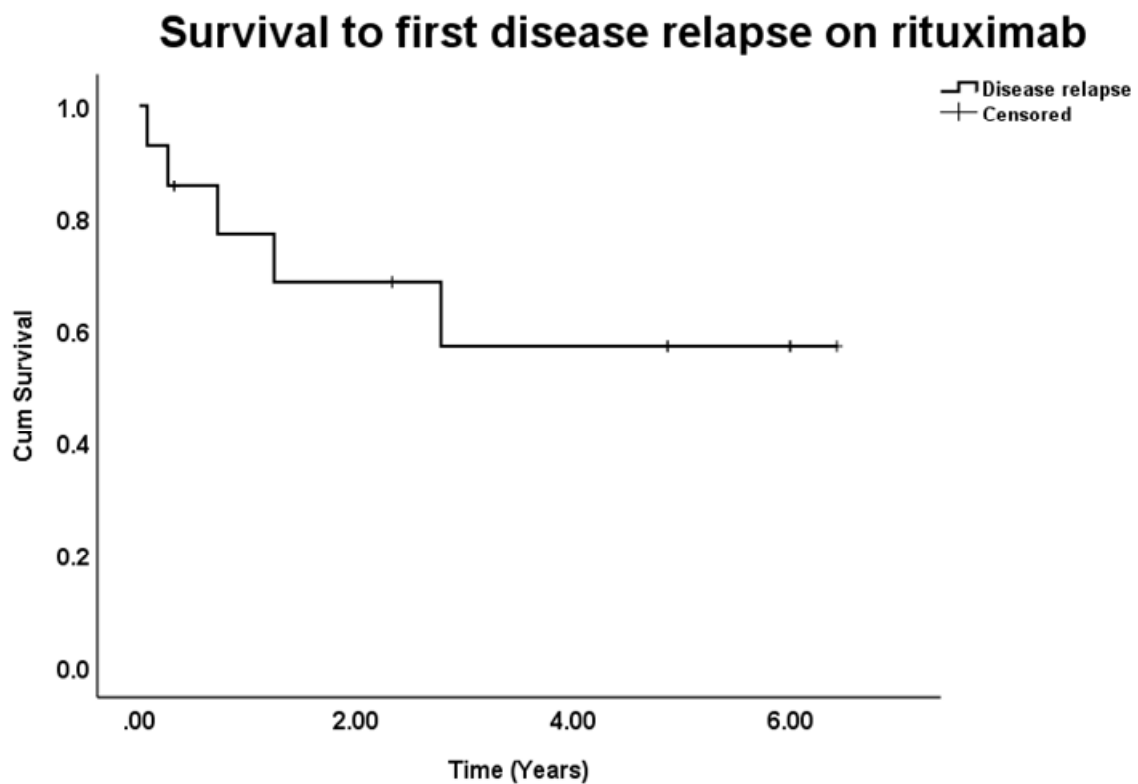
Figure 2-26 Disease relapse on etanercept. The mean time to first disease relapse was 1.82 ± 0.76 SEM; 95% CI 0.32-3.33 years, estimated median time 0.82 years and IQR 0.23-1.46 years.



2.16.3.2 Rituximab

The mean time to first disease relapse on rituximab was 4.18 ± 0.78 ; 95% CI 2.64-5.71. Median was not calculated. Only five patients out of 14 (35.7%) have had disease relapse on rituximab. Figure 2-27.

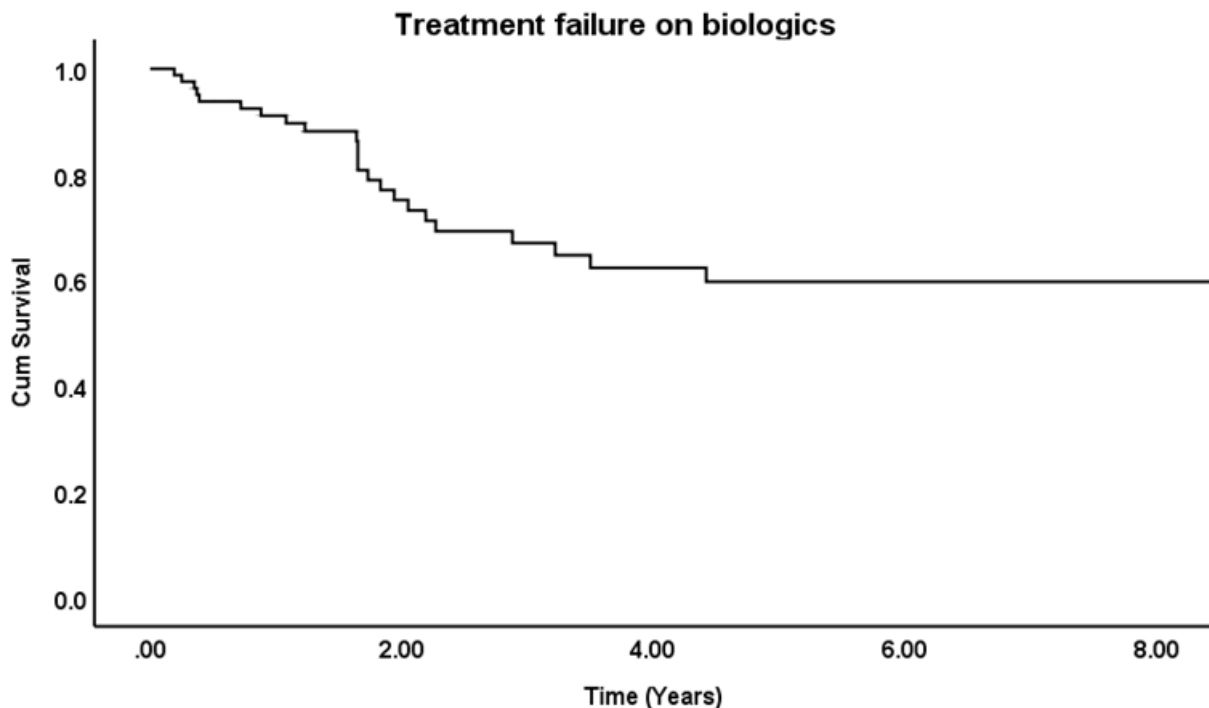
Figure 2-27 Disease relapse on rituximab. The mean time to first disease relapse was 4.18 years. Median was not calculated due to small number of eyes with disease relapse.



2.17 Treatment failure

Among 82 patients, treatment with biologics failed (stopping or switching to another biologic due to inadequate or poor response to treatment, or drug-related side effects) in 23 patients (28%). The median to treatment failure was 1.65 years, IQR 0.72-2.19, range 0.19-4.42 years, mean time to treatment failure was 1.65 ± 0.16 SEM years. Kaplan Meir analysis shows an estimated mean to treatment failure of 9.44 years ± 0.85 ; 95%CI 7.76- 11.11, the median was not calculated as it did not reach 50%. Figure 2-28.

Figure 2-28 Treatment failure on biologics. Only 28% (23 out of 82 patients) failed their first biological treatment. Estimated mean time to treatment failure was 9.44 years ± 0.85 ; 95%CI 7.76- 11.11, the median was not calculated as it did not reach 50%.



2.17.1.1 Treatment failure on different biologics

Out of 76 eyes treated with infliximab 32 (42%) failed treatment at a mean time of 1.38 ± 0.16 SEM years, median 1.64 years, whereas for eyes treated with adalimumab (n=60) only 10 (16.7%) failed treatment, the mean time was 2.54 ± 0.42 years, median 2.27 years and for etanercept (n=4) all eyes failed treatment, the average time to treatment failure was 1.58 ± 0.20 , median 1.58. Finally, with rituximab, no treatment failure was noted.

Due to small numbers for eyes on etanercept (n=4) we have only analysed time to treatment failure between infliximab and adalimumab. This analysis involved a total of 136 eyes (76 on infliximab and 60 on adalimumab). For all patients, 32 (42.1%) developed treatment failure in the infliximab group versus only 10 (16.7%) patients in the adalimumab group. Significantly fewer patients failed treatment with adalimumab compared to infliximab (p=0.001, Chi-Square test, test value 10.16).

Kaplan Meir analysis shows that infliximab-treated group had a mean time to treatment failure of 7.54 ± 0.87 SEM; 95%CI 5.83-09.25, median 3.22 years and for adalimumab the mean time to treatment failure 9.31 ± 0.80 ; 95%CI 7.70-10.92. There was a significant difference between infliximab and adalimumab (p-value = 0.003, Log-Rank Test). Figure 2-29. Cox regression analysis shows a Hazard Ratio of 0.35, (p-value= 0.004; 95%CI 0.17-0.72). Figure 2-30.

Figure 2-29 comparing survival to treatment failure on infliximab and adalimumab. There was a statistically significant difference in time to treatment failure between the two biologic (p-value=0.003, Log-Rank test). Adalimumab has superior drug retention rate compared to infliximab

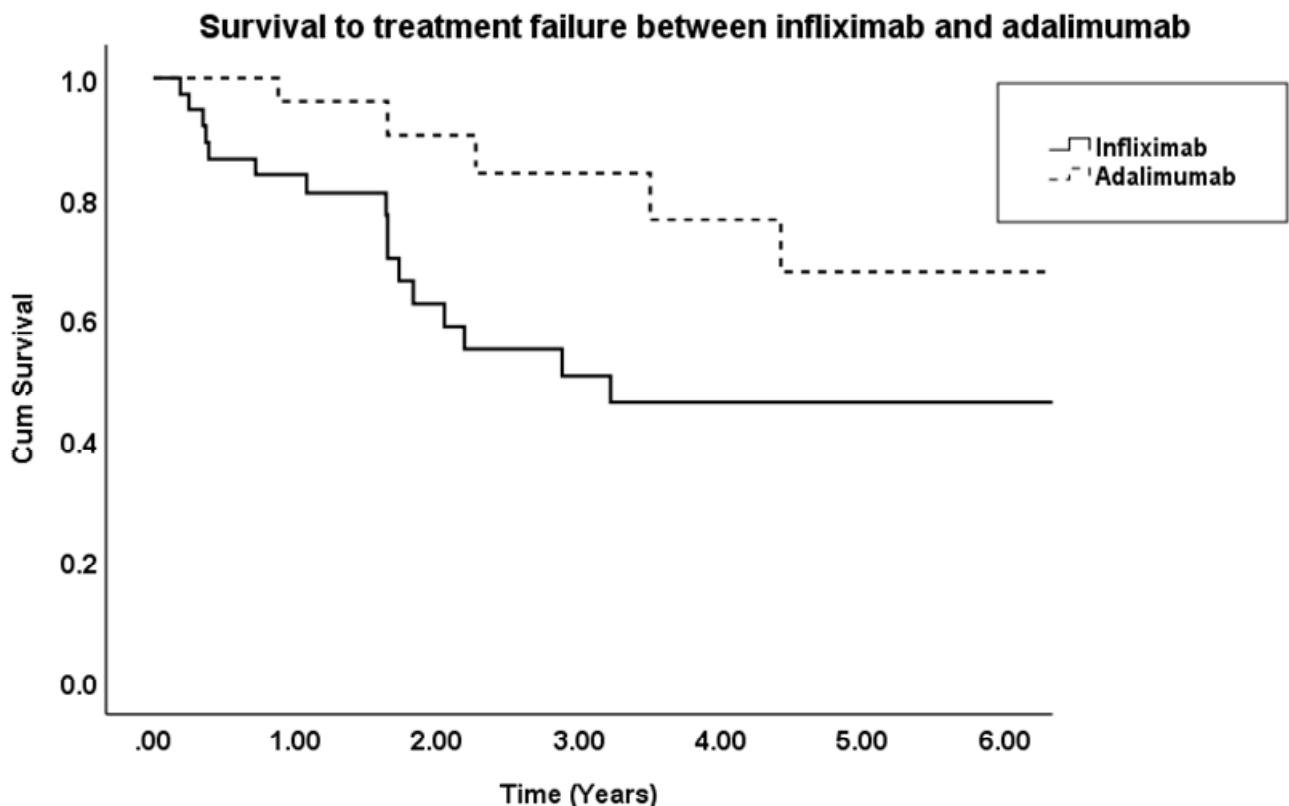
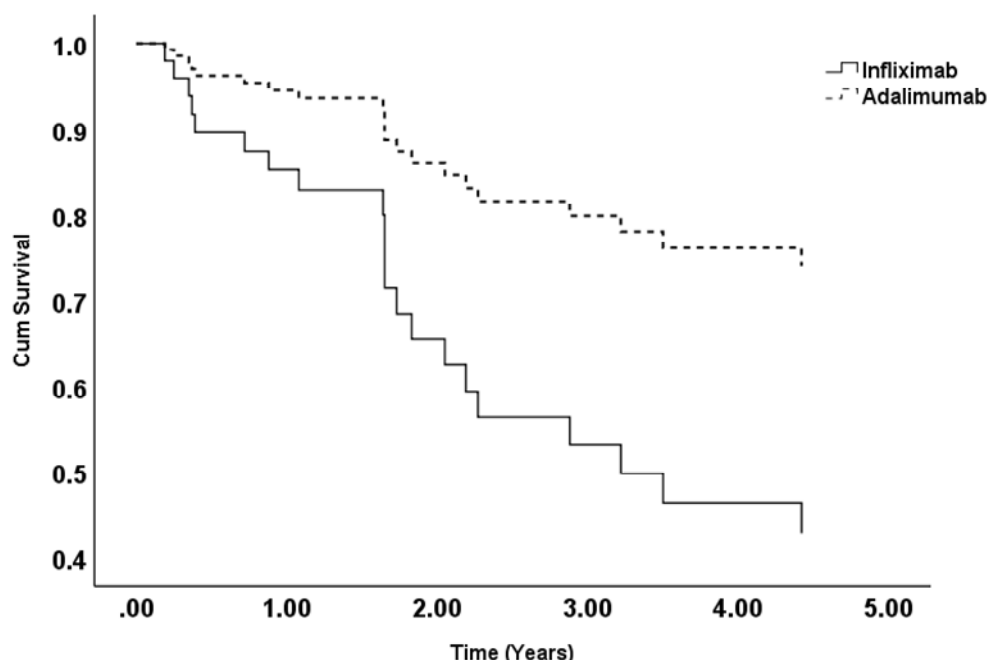


Figure 2-30 Cox regression analysis for treatment failure on infliximab and adalimumab. Hazard Ratio 0.35, p-value =0.004.

Cox Proportional-Hazards analysis for treatment failure on infliximab versus adalimumab

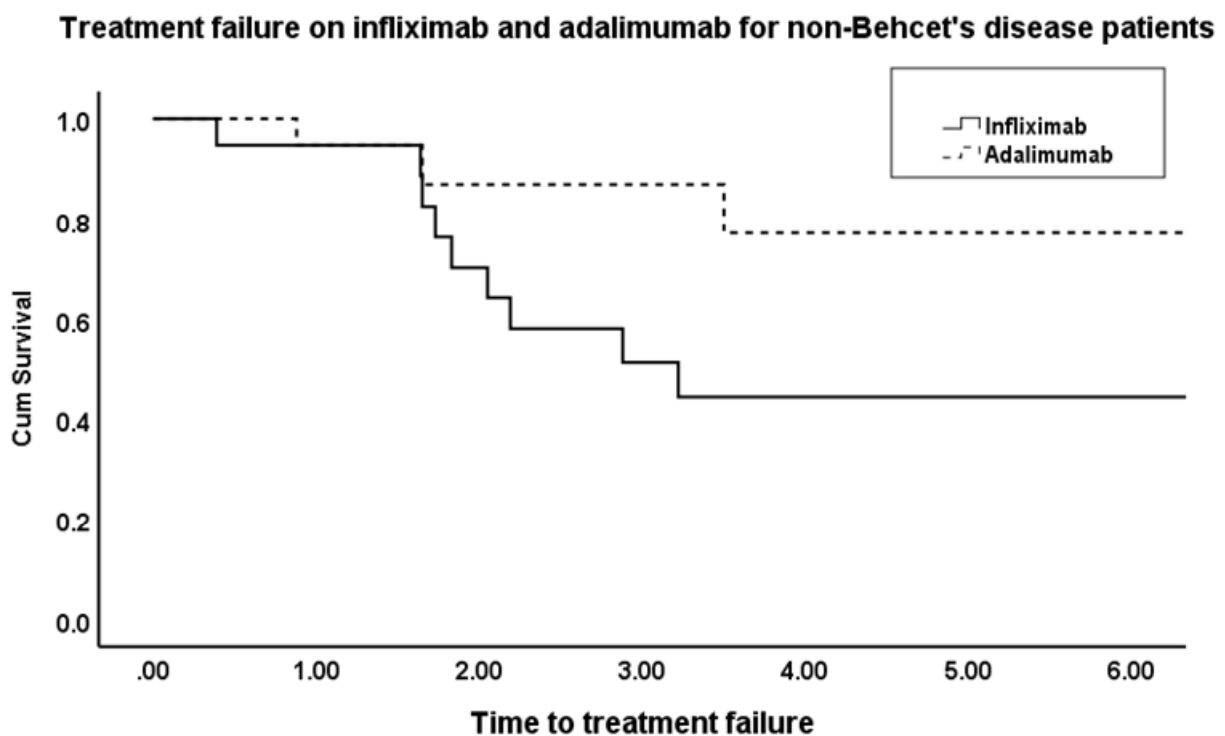


2.17.1.2 Treatment failure with Behcet versus non-Behcet disease

Subgroup analysis performed for non-Behcet’s disease patients (56 patients) and (85) eyes on either infliximab (n=41) or adalimumab (n=44). 18 eyes out of 41 (44%) on infliximab had treatment failure, the mean time to treatment failure on infliximab was 1.95 ± 0.18 years, median 1.83 years IQR (1.64-1.83). Whereas, for those treated with adalimumab only 6 out of 44 (13.6%) have failed treatment with a mean time to treatment failure of 2.01 ± 0.49 years, median 1.65 and IQR (0.88-3.50). A highly statistically significant difference in the proportion of patients who experienced treatment failure on infliximab compared to adalimumab (p-value = 0.002, Chi-square test, two-sided, test value 9.95). For non-Behcet disease patients, mean time to treatment failure on infliximab was 7.57 ± 1.10 SEM; 95% CI 5.40-9.75, median 3.22 ± 0.66 SEM; 95%CI 1.91-4.53 whereas for adalimumab mean time to treatment failure was 10.06 ± 0.84 SEM; 95% CI 8.41-11.72, median was not calculated due to

small number of eyes who failed treatment. Kaplan Meir analysis shows a statistically significant difference between these two biologics with regards to time to treatment failure (p-value =0.01, Log-Rank test), Figure 2-31.

Figure 2-31 Treatment failure for non-Behcet disease patients, a statistically significant difference between infliximab and adalimumab in time to treatment failure (p-value =0.01, Log-Rank test).

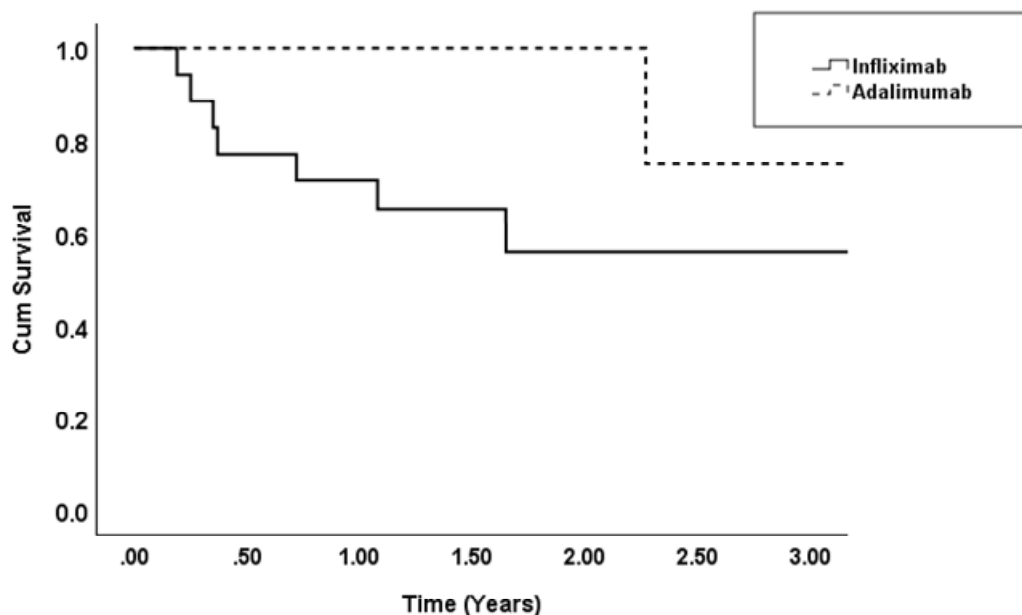


For Behcet disease patients (n=51 eyes), 35 eyes treated with infliximab and 16 treated with adalimumab. For the infliximab group, 14 patients out of 35 (40%) failed treatment, mean 0.65 ± 0.13 SEM, median 0.37, IQR 0.25-1.08 years. 4 out of 16 (25%) failed therapy on adalimumab with a mean of 3.34 ± 0.62 , median 3.34, IQR (2.27-4.42) years. One patient was due to poor disease control and one due to demyelinating disease. There was no statistically significant difference in the proportion of eyes with Behcet disease who failed treatment on either infliximab or adalimumab (p-value =0.38, Fisher's Exact test, two-sided).

Kaplan Meir analysis, an estimated mean time to treatment failure for infliximab-treated patients was 6.32 ± 0.91 SEM; 95%CI 4.53-8.11, and for the adalimumab, the estimated mean time was 3.88 ± 0.38 ; 95%CI 3.13-4.62. There was no significant difference between infliximab and adalimumab in time to treatment failure (p -value=0.23, Log-Rank Test). Figure 2-32.

Figure 2-32 For Behcet disease patients there was no significant difference between infliximab and adalimumab in time to treatment failure (p -value=0.23, Log-Rank Test).

Survival to treatment failure on infliximab and adalimumab for Behcet's disease patients

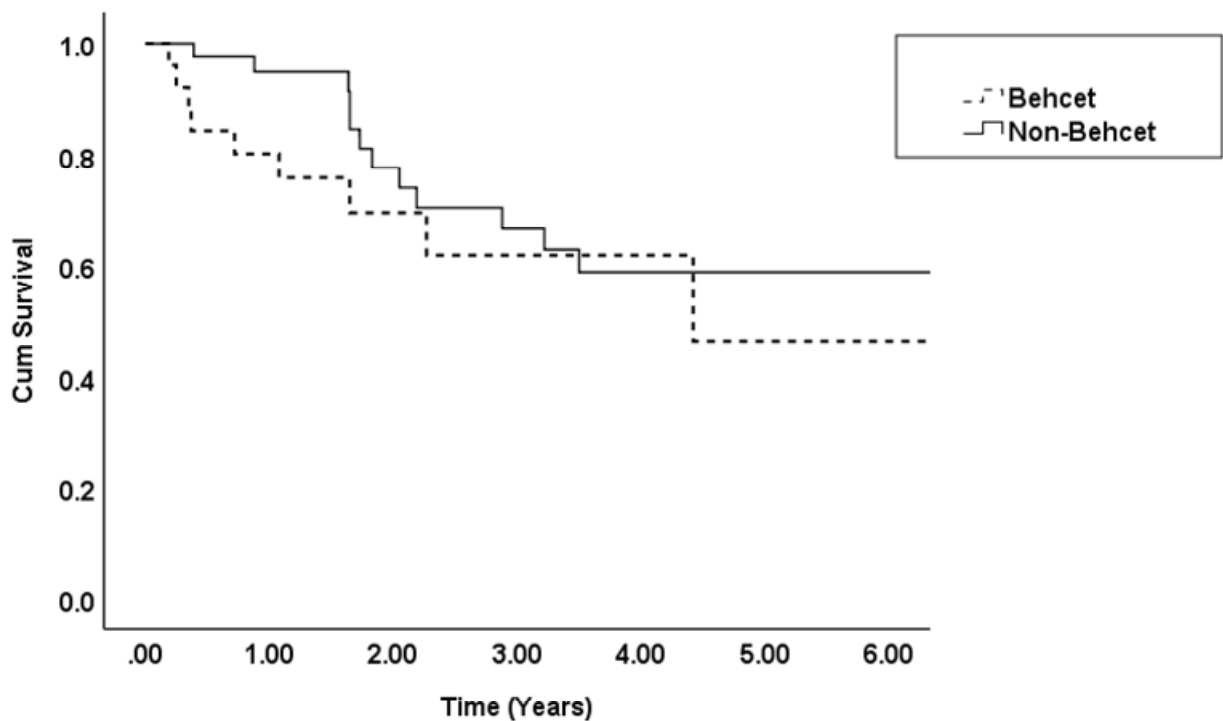


Comparing Behcet and non-Behcet disease patients with regards to treatment failure. A total of 136 eyes were analysed (85 eyes with non-Behcet diseases and 51 eyes with Behcet disease). Although only 18 patients (35.3%) with Behcet disease have failed treatment with anti-TNF α in patients versus 24 patients (28.2%) in non-Behcet disease group, there was no significant difference in the proportion of eyes who failed the therapy in both groups (p -value=0.38, test value 0.74, Chi-Square, two-sided). The estimated mean time to treatment failure for non-Behcet disease patients was 9.39 ± 0.81 SEM; 95% CI 7.79-10.99 and for Behcet disease patients mean time to treatment failure was 6.05 ± 0.87 ; 95% CI 4.34-7.77. There was no significant difference in time

to treatment failure between Behcet and non-Behcet disease patients, Kaplan Meir survival analysis, (p-value =0.10, Log-Rank test). Figure 2-33.

Figure 2-33 Survival to treatment failure in Behcet and non-Behcet disease patients. There was no significant difference in time to treatment failure between the two groups,(p-value =0. 10 Log-Rank test).

Survival to treatment failure for Behcet's and non-Behcet's disease patients



For eyes treated with infliximab and adalimumab, we conducted a multivariate analysis, using the Cox Linear Regression model examining factors related to treatment failure (Table 2-16). Treatment with infliximab and younger age were borderline significant risk factors for treatment failure in univariate analysis. However, when analysed together no risk factors were identified as related to an increased risk of treatment failure.

Table 2-16 Multivariate analysis for factors associated with treatment failure on infliximab and adalimumab.

	Crude OR	95% CI	P-value	Refined OR	95% CI	p-value
Male gender	0.6	(0.3-1.2)	0.6			
Laterality	1.1	(0.56-2.18)	0.78			
Anatomical type of Uveitis*	0.75	(0.33-1.69)	0.48			
Treatment with adalimumab	0.5	(0.23-1.06)	0.07	0.4	(0.18-0.89)	0.03
Age at beginning of biologics, years	0.98	(0.96-1.00)	0.09	0.97	(0.95-0.996)	0.03
Treatment for systemic disease	1.91	(0.96-3.81)	0.07	3.22	(1.46-7.07)	0.004
Corticosteroid dose at end of follow-up, mg	1.03	(0.96-1.11)	0.41			
Treatment with 2 nd -line immunosuppression	0.97	(0.44-2.16)	0.94			
Aetiology	1.0	(0.0 - 2997)	0.406			
OR odds ratio CI Confidence interval *Reference set as IU						

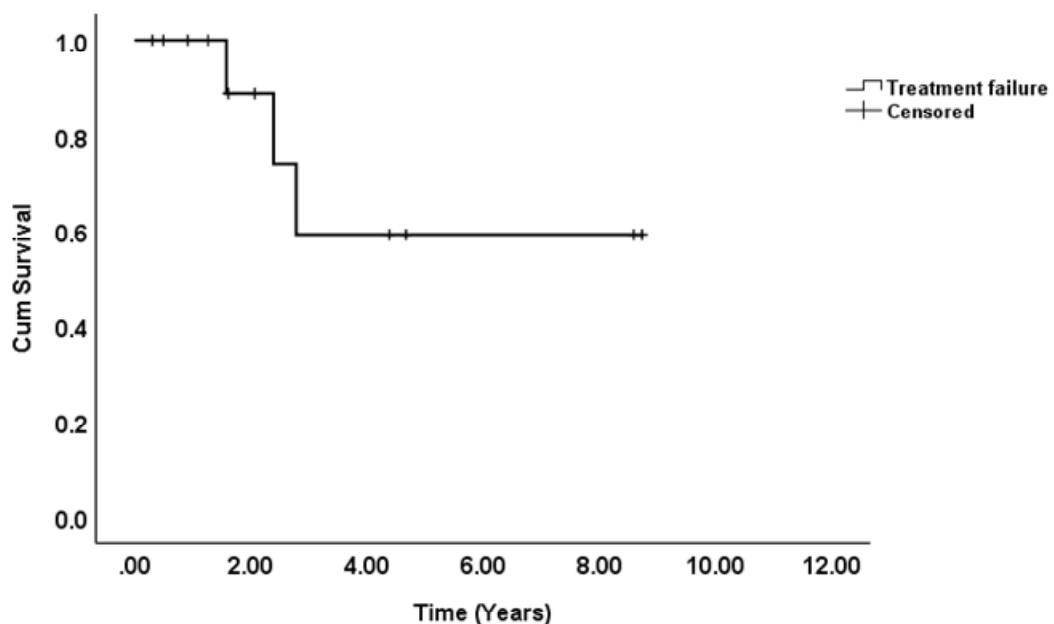
2.17.1.3 Switching between infliximab and adalimumab

Thirteen patients (26 eyes) treated initially with infliximab have switched to adalimumab. Among eyes that failed treatment with a 1st-line biologic agent (n=37), 32 switched to an alternative biologic agent, 26 to adalimumab, 6 to infliximab, 6 to etanercept 2 to tocilizumab and 2 to golimumab. Of these eyes treatment failed (Inadequate or poor response to treatment, allergic reactions or drug-related side effects) in 6 eyes treated with etanercept (100%), 2 eyes treated with golimumab (100%), 2 eyes treated with tocilizumab (100%), 5 eyes treated with infliximab (83.33%) and 4 eyes treated with adalimumab (25%).

A total of 26 eyes (13 patients) who had failed treatment with infliximab switched to adalimumab the causes were poor disease control and infliximab related side effects (itching). Treatment failure on adalimumab was only recorded in 3 patients (6 eyes) (23%). Kaplan Meir analysis shows an estimate mean of 6.12 ± 0.83 SEM; 95%CI 4.49-7.76 years, the median time was not calculated. Figure 2-34. The reason for treatment failure was poor disease control. Eight patients (61.5%) did not stop their adalimumab treatment until their last follow-up visit, and two patients (15%) discontinued treatment due to disease control.

Figure 2-34 Survival to treatment failure on adalimumab.

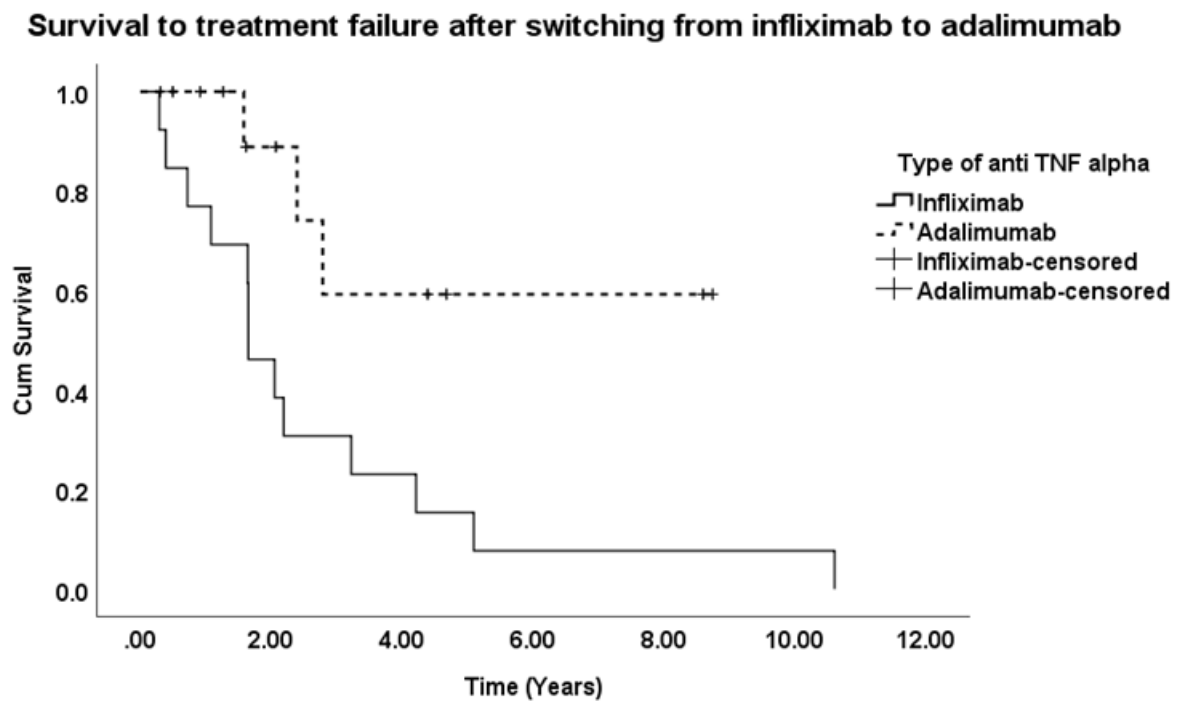
Survival to treatment failure on adalimumab for patients previously on infliximab



Kaplan Meir analysis shows a median time to treatment failure on infliximab of 1.65 ± 0.17 SEM years; 95% CI 1.31-1.99 years, whereas on adalimumab the median was not calculated due to very few numbers of patients who failed the treatment. The mean survival time on infliximab was 2.68 ± 0.53 SEM; 95%CI 1.63-3.72, while on adalimumab the mean survival time was 6.12 ± 0.83 ; 95%CI 4.49-7.76. There was a highly statically significant difference in mean survival time to treatment failure (p -value <0.001 , Log-Rank test). Figure 2-35. The mean time on infliximab was 1.78 ± 0.13 SEM years, median 1.65 years and on adalimumab, the mean time was 2.25 ± 0.35 ,

the median was 2.39 years. A paired t-test for time to treatment failure for patients who failed both drugs was not statistically significant (p-value 0.43, paired t-test, two-sided).

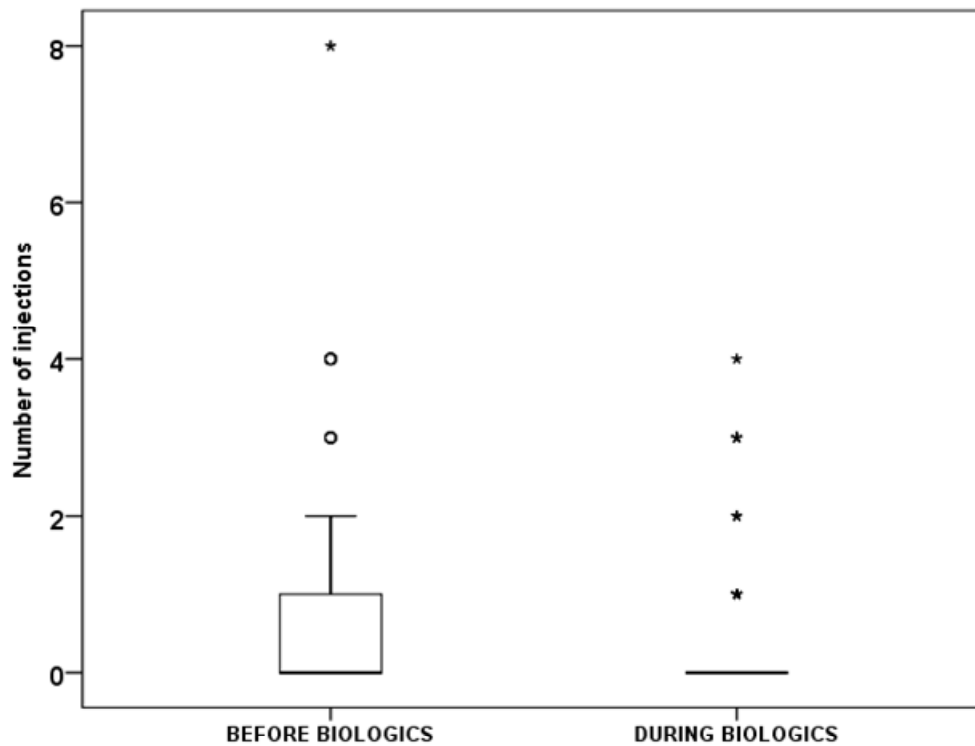
Figure 2-35 Time to treatment failure after switching from infliximab to adalimumab. The median time to treatment failure on infliximab was 1.65 years; 95% CI 1.31-1.99 years, whereas on adalimumab the median was not calculated due to very few numbers of patients who failed the treatment.



2.18 Periocular corticosteroids injections

The mean of periocular steroids injections before biologics was 0.68 ± 1.2 SD, range from 0 to 8 injections; (95% CI 0.49- 0.87), and after commencing biologic treatment this dropped to a mean of 0.24 ± 0.74 SD, (95%CI 0.12-0.35), range from 0 to 4 injections, a statistically significant difference (p-value <0.001, Wilcoxon Signed Rank Test, two-sided). Figure 2-36.

Figure 2-36 comparing the number of local corticosteroid injections before and during biologics, shows a statistically significant difference, (p-value<0.001).



2.19 Safety of biologic response modifiers

Concerning the safety of biologics in our cohort, biologics were safe and well tolerated by the majority of patients. While no serious infection was reported in patients on biologics treatment, one patient had miliary TB after treatment with biologics, and it was stopped after one month, this patient was excluded from the analysis due to very short follow-up time on biologics. However, no case of TB reactivation was recorded (0%) for all the 82 patients during the treatment period. With regards to malignancy on biologics treatment, only two female patients have had breast cancer (2.5%). The demyelinating disease was reported in 2 patients (2.5%) one male and one female, after 4.4 and 2.5 years of adalimumab and infliximab treatment, respectively. Both were initially diagnosed with Behcet disease. Finally, one patient had liver cirrhosis (1.2%)

Treatment discontinuation due to adverse drug-reaction was documented in 5 out of 82 patients (6%), one had severe anaphylaxis, two had allergic reactions, and itching and facial swelling was reported in the last two patients. None had heart failure or lupus-like autoimmune disease.

2.20 Discussion

Non-infectious ocular inflammatory diseases in the form of intermediate, posterior and panuveitis (NIIPPU) have chronic courses and a high tendency to relapse. The persisting nature of these uveitides increases the risk of sight-loss subsequent to cumulative damage to ocular structures. The structures critical to vision in the eye can be directly involved with inflammation in conditions such as multifocal choroiditis and serpiginous choroiditis, and the vision may also deteriorate due to secondary complications of inflammation such as cystoid macular oedema and choroidal neovascular membrane (Tomkins-Netzer, Talat et al. 2014). Therefore, treatment of NIIPPU aims to control inflammatory episode and a long-term course is necessary to reduce the risk of future relapse and maintain the vision. However, due to the chronic nature of the inflammation, varied response to treatment and drug-related side effects, the management of these uveitides can be quite challenging.

Treatment involves local and or systemic corticosteroids with or without second-line immunosuppressive agent(s). The exact mechanisms through which diseases respond to treatment remain unclear. Corticosteroid, the cornerstone drug in treating uveitis, is not ideal for long-term disease control due to myriad side effects which are both dose and time-dependent. Corticosteroid-sparing second-line immunosuppressive agent(s), on the other hand, are not always successful, and a significant proportion of patients will fail this treatment due to either lack of efficacy or side effects. Biologics are the third-line agents, and are increasingly being used to treat ocular inflammation. Biologics were used to help with disease control when moderate corticosteroids dose +/- 2nd line agent have failed to do so due to inadequate response to treatment, frequent recurrent disease relapse or intolerance to these drugs.

This work was undertaken to explore the effects of different biologics on long-term disease control, looking specifically at their corticosteroids-sparing effect, ability to reduce the dose of the second-line immunosuppressive agent and maintain vision. Also, we explored the rate of disease recurrence and treatment failure on different types of biologics and among patients with various diseases (Behcet versus non-Behcet disease). The analysis of long-term control of ocular inflammatory disorders

on biologics and the effect of these drugs on concomitant immunomodulatory therapy will help improve treatment outcomes in patients with uveitis.

This study is a retrospective study on patients with non-infectious uveitis refractory to conventional treatment. In this research, we measured the reduction in daily corticosteroid dose and second-line immunosuppressive agents. Also, we assessed the long-term visual acuity outcomes on biologics. Moreover, the number of disease relapses were measured to assess disease control with respect to different types of biologics. We have found that biologics have a significant corticosteroid-sparing effect, and this occurred early in treatment course (from three months onwards). Treatment with biologic response modifiers maintained visual acuity and improved long-term disease control. Interestingly, Behcet disease patients have a more favourable response to biologic treatment compared to non-Behcet disease patients, this was confirmed by the substantial reduction in the number of disease relapses on biologics in Behcet disease compared to other uveitis aetiologies. Comparing different anti-TNF α drugs shows that adalimumab has superior drug retention rate compared to infliximab, and was better tolerated.

2.21 Demographics

Our study shows that the mean age at the time of diagnosis was 34 years. However, all age groups could be affected and the youngest age recorded in this study was 4.5 years for a patient with a congenital granulomatous disease and panuveitis (Blau syndrome; dermatitis, arthritis and uveitis). In almost three-quarters of uveitic eyes (74.3%) there was an association with systemic disease and this figure is close to a previous report (Fabiani, Vitale et al. 2018). The most common presentation was bilateral disease in 90% of patients, and the most common diagnosis was Behcet disease. The proportions for males and females are 68% and 32%, respectively. There is a high male to female ratio in this study compared to other studies. Because our data was skewed by the larger number of patients with Behcet disease, which affects more males than females. Also, because of the aggressive nature of this condition and relatively quick positive response to biologic therapy compared to other ocular inflammatory diseases, there is a low threshold to start biologic treatment in Behcet disease compared to other disease aetiologies.

With regards to the anatomical location of inflammation, most of our patients presented with panuveitis 53% followed by intermediate uveitis 27% and posterior uveitis 20%. Panuveitis is the second most common type of uveitis after anterior uveitis. Also, specific disease aetiologies that most commonly present with panuveitis such as, Behcet disease, idiopathic panuveitis, sarcoidosis, VKH and Blau syndrome, make collectively over 63% of our data set. Most Behcet patients in our study presented with panuveitis (73%) followed by posterior uveitis 23% and only one patient had Behcet disease related intermediate uveitis 4%.

More than two-thirds of patients had a second-line IMT, and the most commonly used drug was mycophenolate mofetil (MMF) followed by methotrexate. Several reports support the efficacy of MMF in uveitis particularly the relative faster action and superior safety profile in comparison to other agents. MXT, on the other hand, has been widely used in ocular inflammatory disease with variable response rate. Other less prescribed drugs were calcineurin inhibitors (cyclosporine and tacrolimus), these agents are usually effective in uveitis however they are associated with significant side effects, mainly renal toxicity.

All patients included in our study have an aggressive form of uveitis whether the inflammation is only in the eye, or (most commonly) the ocular inflammation is part of systemic disease such as systemic vasculitis which includes; Behcet disease, ANCA associated vasculitis, Takayasu's arteritis and systemic lupus erythematosus with posterior segment involvement. Other systemic diseases with ocular involvement were Vogt-Koyanagi Harada disease and sarcoidosis. The ocular diseases without known systemic association are punctate inner choroidopathy, multifocal choroiditis, serpiginous choroiditis and Birdshot chorioretinopathy. These uveitis entities usually have a significant risk of vision loss directly from inflammation that damages the retina and underlying choroid or from secondary complications namely choroidal neovascular membrane and cystoid macular oedema. Therefore, long-term immunosuppression is needed to achieve disease quiescence and preserve sight.

In biologic response modifiers naïve patients, there were five different types of biologics used. Anti-TNF α drugs were the most commonly used agents (infliximab followed by adalimumab). These agents have been used widely in treating non-infectious ocular inflammatory diseases. Only two patients treated with etanercept and

the indication was systemic joint disease due to either psoriatic or seronegative arthritis. Etanercept has been proven effective in rheumatic joint disease but not in uveitis. Therefore, when patients usually placed on etanercept and develop uveitis that does not respond to treatment or become recurrent, the ophthalmologist usually requests stopping etanercept and switching to another biologic, since etanercept was associated with a high incidence of uveitis, both patients had their etanercept stopped and switched to another agent due to poor control of ocular inflammation. Rituximab was mainly used for ANCA+ve vasculitis and granulomatosis with polyangiitis. Two patients had SLE and one had Takayasu arteritis were also treated with rituximab. Similarly, rituximab was used for one patient with MS and one with intermediate uveitis. Finally, one patient had ulcerative colitis and intermediate uveitis and was placed on vedolizumab.

2.22 Disease control

The principal aim in treating uveitis is to achieve disease quiescence because as previously mentioned when the inflammation is not controlled the risk of vision loss is high due to damage to the ocular tissue directly from the inflammation or its secondary complications. On biologics, patients with refractory uveitis have achieved better long-term disease control, and this was evident by the substantial reduction of daily corticosteroid dose and immunosuppressive drugs, stability of visual acuity, and significantly lower rates of disease relapses/year.

2.22.1 Corticosteroids sparing

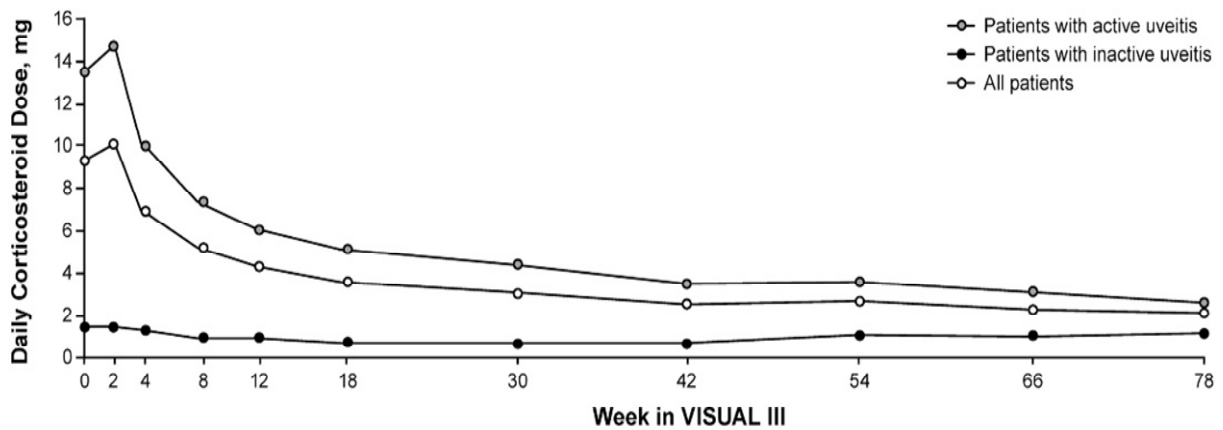
Treatment with adequate corticosteroid-sparing agents, while maintaining disease under control is one of the key aims in the management of non-infectious uveitis (Suhler, Adán et al. 2018). Our results show that biologics have a significant corticosteroid-sparing effect, with more than 60% reduction of daily corticosteroid dose at six months. Moreover, patients treated with biologics continued to reduce their oral corticosteroid dose, and disease control was maintained on lower doses for extended follow-up time. In the present study, the average daily dose of corticosteroids at the time of starting biologics was relatively high (16.4mg/day). The mean prednisolone dose was reduced significantly from three months on biologics, (p-value= 0.019) and the difference became highly statistically significant from 6 months up to 5 years

follow-up (p-value<0.0001). The mean prednisolone dose reduced to 6.5 mg at six months, then the prednisolone dose remained stable at 4.14 mg at five years follow-up. Moreover, for patients with longer than five years follow-up, prednisolone dose remained low and was 5.8 ± 3.07 mg/day at ten years follow-up.

Similarly, the French Uveitis Network multicentre study reported a significant corticosteroid-sparing effect with biologics. At starting biologics, the median daily prednisolone dose was 20 mg/day which dropped to 10 mg and 7 mg per day at six and 12 months, respectively (both p-values <0.0001). There was a 50% reduction in the amount of corticosteroid used at six months. These results were concordant with the published literature (Suhler, Smith et al. 2005, Díaz-Llopis, Salom et al. 2012, Dobner, Max et al. 2012, Suhler, Lowder et al. 2013, Kruh, Yang et al. 2014). Interestingly, our study has shown that patients on Adalimumab achieved a prednisolone dose of less than 10 mg per day at a median of 3 months which was shorter than patients on infliximab six months, but it was not significant.

Equivalently, the trend for the mean reduction in corticosteroid dose in patients with active disease in the VISUAL III was similar to our results. VISUAL III trial reported a mean corticosteroid dose at the time of starting adalimumab treatment of 13.6 mg which was reduced to 6.1 mg/day at three months and to 2.6 mg at week 78 (1.5 years) (Suhler, Adán et al. 2018). Patients with inactive disease continued on a low dose of corticosteroid throughout the trial. Figure 2-37. However, corticosteroid dose at baseline was slightly less than what was reported in our study. This is because some patients who entered the VISUAL III study had adalimumab treatment under the VISUAL I and II trials, whereas the majority of patients in our study were biologic-naïve. Also, in contrast to VISUAL III, our study included different biologics such as infliximab etanercept and rituximab, in addition to adalimumab.

Figure 2-37 Trend for daily corticosteroids dose for patients with active disease, inactive disease and overall study population on adalimumab in VISUAL III study.



n, as observed											
active:	237	237	232	229	224	218	209	198	190	181	173
inactive:	128	128	127	121	119	118	117	116	112	108	104
all patients:	365	365	359	350	343	336	326	314	302	289	277

2.22.1.1 Corticosteroid-sparing in Behcet versus non-Behcet disease patients

In BD uveitis, treatment aims to abort the acute inflammatory attack and prevent subsequent recurrences. Therefore, high dose corticosteroid-based immunomodulatory therapy must be promptly initiated in patients with sight-threatening Behcet uveitis involving the posterior segment to minimise the risk of severe vision loss (Zierhut, Abu El-Asrar et al. 2014). However, conventional immunosuppression is not always successful in treating ocular manifestations of BD. High dose oral corticosteroids, are classically used in treating acute attacks of BD. However, there are concerns that the disease is becoming corticosteroid resistant (Benezra and Cohen 1986). More importantly was that the long-term treatment with corticosteroids failed to prevent vision loss in BD patients (Chajek and Fainaru 1975). On the other hand, colchicine which is the first-line treatment for BD disease in Japan, is only useful in mild cases with mucocutaneous manifestations, and its clinical efficacy was not established in all BD patients particularly in controlling the ocular disease (Matsumura and Mizushima 1975).

Treatment results with other conventional immunosuppressive agents in ocular Behcet were inconsistent. Azathioprine, for example, was found initially useful in preserving the visual acuity in patients with established disease and was also effective in controlling other systemic manifestations such as oral, genital ulcers and arthritis (Yazici, Pazarli et al. 1990). However, approximately a quarter of patients (22%) on azathioprine developed a relapse of uveitis (Yazici, Pazarli et al. 1990). The same study reported that azathioprine was ineffective in restoring visual acuity. Another study described different responses with azathioprine among patients with Behcet disease with complete response in only 51 % of patients (Saadoun, Wechsler et al. 2010).

Similarly, a study evaluating the effect of azathioprine in different etiologies of retinal vasculitis (mostly idiopathic retinal vasculitis and Behcet disease associated vasculitis) found that a higher proportion of Behcet disease patients required an increase in their corticosteroid dose compared to the rest of the group (45% versus 24%) (Greenwood, Stanford et al. 1998). The increment was primarily driven by disease progression despite being on azathioprine. Systemic corticosteroid increased in 45% and remained unchanged in 27%, therefore 77% of patients on azathioprine remained on high corticosteroid dose. Half of patients in this study developed lymphopenia on azathioprine therapy and about a quarter of patients required an additional immunosuppressive agent (most commonly, cyclosporine) due to insufficient disease control with a combination of corticosteroid and azathioprine therapy. Therefore, azathioprine was insufficient to achieve a satisfactory corticosteroid-sparing effect in this cohort of patients.

Cyclosporine, on the other hand, was reported to have limited success in Behcet disease and was only effective in BD uveitis at higher doses (10 mg/kg) (Nussenblatt, Palestine et al. 1985). However, at such high dose renal toxicity was inevitable and when lower (safer) doses were adopted, the drug efficacy was compromised (BenEzra, Cohen et al. 1988). Subsequent studies have shown that a combined regimen of low-dose cyclosporine and steroids are more effective in controlling disease activity than each drug alone (Whitcup, Salvo et al. 1994). A combination of cyclosporine and azathioprine was also successful, however, patients needed to continue on therapeutic doses of cyclosporine as disease recurrences were inevitable

at lower doses (Foster, C.S., Baer, J.C. and Raizman, M.B., 1991). Moreover, cyclosporine has been reported to increase the risk of neurotoxicity and accelerate the development of central nervous system disease in Behcet patients (Kotake, Higashi et al. 1999). Finally, a rebound phenomenon has been noticed in patients on cyclosporine when the drug was stopped abruptly (Hayasaka, Kawamoto et al. 1994). Therefore, immune suppressive drugs in BD are not always successful in inducing disease remission and preventing further relapses. Alkylating agents such as chlorambucil and cyclophosphamides were found useful in the treatment of BD, but they carry a significant risk of systemic complications (Zierhut, Abu El-Asrar et al. 2014) and are not used now.

In the era of biologic treatment, trials have confirmed the efficacy of infliximab in achieving rapid and long-term disease control (Zierhut, Abu El-Asrar et al. 2014). Infliximab has shown an impressive suppressive effect on the acute attack (Namba, Goto et al. 2015) and was successful in reducing the number of severe attacks (Ohno, Nakamura et al. 2004). The European league against Rheumatism has recommended the use of azathioprine with corticosteroids as first-line treatment for ocular BD and cyclosporine and infliximab are second-line treatment. Recently, an expert panel in the US recommended anti-TNF α therapy (infliximab or adalimumab) as first-line or as a second-line corticosteroid sparing-agent in BD uveitis (Levy-Clarke, Jabs et al. 2014).

In our study comparing Behcet and non-Behcet disease patients with regards to corticosteroid-sparing on biologics have revealed exciting results. Firstly, Behcet patients have started biologics with slightly higher doses of oral prednisolone compared to non-Behcet disease patients despite being on conventional immunosuppressive therapy. Secondly, treatment with biologics in Behcet disease patients showed a substantial and faster reduction in mean daily prednisolone dose early on, from three months onwards, compared to non-Behcet patients. Moreover, in Behcet disease patients, the differences in mean corticosteroids compared to baseline remained highly statistically significant at all follow-up times. Additionally, in Behcet patients, the mean prednisolone dose reached below 5 mg per day after 20 months follow-up and remained stable at a low level throughout the study visit until five years follow-up.

In non-Behcet disease subjects, the reduction in daily oral prednisolone dose was only statistically significant at 3, 6 and nine months and the difference became non-significant at one year and three years follow-up. Also, non-Behcet disease patients had spikes of high doses of oral prednisolone approaching the 10 mg per day threshold. Moreover, although the mean daily oral prednisolone dose was significantly reduced at 4 and five years follow-up compared to baseline, the daily dose remained above 5 mg per day at all follow-up times. These differences between Behcet and non-Behcet patients imply better disease control on biologics for patients with Behcet disease, evidenced by less corticosteroid needed for Behcet disease patients.

In accordance with our data, Accorinti and associates, in a prospective trial reported a significant reduction in the daily corticosteroid dose required by Behcet disease patients after approximately two years follow-up. The corticosteroids dose on infliximab treatment reduced from 24 mg per day to 8.9 mg, ($p < 0.001$) (Accorinti, Pirraglia et al. 2007). However, this study included only 12 patients. Recently, Martín-Varillas et al. reported a successful corticosteroid-sparing on adalimumab in 65 BD patients, mean prednisolone dose dropped from approximately 25 mg/d to less than 5 mg/d after two years follow-up ($p\text{-value} < 0.01$) (Martín-Varillas, Calvo-Río et al. 2018).

Achieving a safe prednisolone dose (less 10 mg per day) is one of the key aims of therapy in uveitis, and the faster the time to bring prednisolone below this threshold the less the risk of side effects. As per the recommendations of an expert panel in the US on the use of immunosuppressive therapy in chronic non-infectious uveitis (Jabs, Rosenbaum et al. 2000), a safe corticosteroid dose is 10 mg/day or less. But less than 7.5 mg is now recommended by many uveitis specialists. This threshold is regarded safe for long-term disease control because the rate of side effects associated with it, is low.

The systemic immunosuppressive therapy for eye disease SITE study reported that only 20 to 40% of patients on second-line (corticosteroid-sparing) immunosuppressive agents, were able to reduce their daily corticosteroids below 10 mg per day at 6 months (discussed below in more details) (Gangaputra, Newcomb et al. 2009, Pasadhika, Kempen et al. 2009, Kacmaz, Kempen et al. 2010). Our data show that at six months more than 63% of patients on biologics achieved a safe daily corticosteroid dose (below 10 mg). A similar finding was reported by another study where over 60 %

of patients on anti-TNF α drugs were able to reduce their daily corticosteroid dose below 10 mg (Martel, Esterberg et al. 2012). These figures are higher compared to the SITE study suggesting that biologics have a superior corticosteroid-sparing effect.

In the SITE study, patients with intermediate, posterior and panuveitis have shown less favorable response to methotrexate, compared to those with anterior uveitis. Methotrexate achieved better control of ocular inflammation (55.6%) and corticosteroid-sparing (46.1%) in patients with anterior uveitis, while at six months, methotrexate achieved sustained control of inflammation (\geq 28 days) in only 38.6% of patients with posterior/panuveitis and 47.4% in those with IU. Moreover, even lower proportion of these patients had their corticosteroid dose reduced to a safe level, (20.7%) in posterior/panuveitis and (41.3%) for those with IU. The corticosteroid-sparing effect continued to increase in patients with anterior uveitis (62.6%), intermediate uveitis (68.8%), and posterior/panuveitis (39.1%) at or before 1-year. However, many months were required to achieve these objectives (Gangaputra, Newcomb et al. 2009).

Similarly, cyclosporine in the SITE study, achieved corticosteroid-sparing success in only 22.1% at six months and 36.1% at one year. Concerning the anatomical type of uveitis, corticosteroid-sparing was 28.5% in patients with anterior uveitis, 24.1% in patients with IU, and only 16.2% among those with posterior/panuveitis. Sustained control of inflammation on cyclosporine (no inflammatory activity in two-visits spanning over 28 days period) was only achieved in 33.4% and 52% of patients at six and twelve months, respectively. With regards to the type of uveitis, complete and sustained control of inflammation was achieved by six months in 30.4% of patients with anterior and 39.3% among those with IU. The figure for posterior/panuveitis was even lower (29.2%).

By contrast, in patients with intermediate, posterior and panuveitis our data shows that a significant proportion of patients (92%) had their oral prednisolone dose reduced to a safe level (<10 mg per day) by a median of three months. Over 75% of patients have reached a safe corticosteroid level before ten months of follow-up. The proportion of patients on less than 10 mg prednisolone increased significantly from 28% at baseline to 72.7% at five years follow-up. Biologics not only help significantly reduce daily oral corticosteroid dose but do that in a relatively short time. For the entire cohort, the

average time to reach this therapeutic target was three months, 95%CI 1.28-4.72. With adalimumab, this target was achieved at an average of 3 months, which was lower than that of infliximab, six months, however, the difference was non-significant. With regards to disease aetiology (Behcet versus non-Behcet disease patients), comparing the efficacy of infliximab and adalimumab did not show a significant difference in time to prednisolone dose less than 10 mg per day. Therefore, both infliximab and adalimumab have similar corticosteroid-sparing success.

In most patients oral corticosteroid dose was tapered down in a very similar fashion. After initial control of inflammation with high dose corticosteroid such as, 80 or 60 mg for a week, patients usually instructed to start reducing the dose by 10 mg every week and then at 30 or 20 mg per day the dose will be further reduced by 5 mg every week till reaching 15 or 10 mg per day. If the ocular inflammation is under control a further slow taper of corticosteroid dose to reduce the dose below 10 mg per day or even stop it entirely after good disease control for several months. But, if the disease relapses then a re-increase of corticosteroids dose is employed to try quickly to bring the disease under control again. Most uveitis experts follow this protocol and the main drive for this is the disease activity, and it would not be affected by the type of biologic.

We have compared the time to prednisolone dose below 10 mg per day for Behcet and non-Behcet disease patients. The mean time to the safe threshold was lower for Behcet disease patients compared to non-Behcet disease (1.02 versus 1.99 years) but was not statistically significant (p -value=0.19). However, after starting biologics, Behcet disease patients had lower mean prednisolone dose compared to non-Behcet patients due to a significantly lower rate of disease relapses on biologics in Behcet in comparison to non-Behcet patients.

With regards to the type of biologic therapy, there was no statistically significant difference in mean time to prednisolone dose below 10 mg per day between infliximab and adalimumab (p -value= 0.32). However, the mean time was more 50% less in patients receiving adalimumab compared to those on infliximab (2.32 versus 1.03 years).

With regards to corticosteroid-sparing between infliximab and adalimumab, there was no significant difference in mean prednisolone dose at last follow-up (p -value =0.29).

Similarly, analysing the mean prednisolone dose between these two anti-TNF α blockers at all follow-up time points did not reveal a statistically significant difference (p-value > 0.05). Another analysis with regards to time to daily prednisolone dose less than 10 mg showed no statistically significant difference between infliximab and adalimumab, and the two drugs had similar corticosteroid sparing efficacy in ocular inflammatory diseases.

Fabiani and co-authors in their study reported that both infliximab and adalimumab have similar efficacy with regards to visual acuity, the number of disease relapses and second-line immunosuppressive sparing. However, the study reported superior corticosteroid-sparing with infliximab compared to adalimumab (Fabiani, Vitale et al. 2018). In their study at last follow-up visit, the mean daily corticosteroid dose was significantly higher in the adalimumab-treated group versus infliximab (p-value=0.008). Nonetheless, this may be due to a shorter follow-up period in the adalimumab group (2 years for those on adalimumab versus five years for patients on infliximab). Moreover, there was an imbalance in group size between these two biologics (62% of patients on adalimumab versus 38% on infliximab), and patients in the adalimumab group had higher disease relapses before biologic treatment compared to those on infliximab, which may reflect a more aggressive disease course in that group. After starting adalimumab the frequency of disease recurrence was lower in adalimumab administered patients compared to infliximab, 84.2% reduction in disease relapses on adalimumab versus 66.7% on infliximab but was not statistically significant (p-value=0.09).

Finally, with regards to local corticosteroids which are used as an adjunct for disease control in patients with NIIPPU, our data show that treatment with biologics has significantly reduced the number of periocular corticosteroids injection required (p-value <0.001) owing to the better disease control on biologics.

There was a significant and consistent reduction in mean prednisolone dose early on with biologics. Furthermore, significantly more patients achieved a safe corticosteroid level within the first years of biologic therapy. More importantly, our data show that the corticosteroid-sparing effect of biologics was maintained during an extended follow-up period. Contrary to the previously held perception that biologic agents lose their efficacy due to the development of anti-drug antibodies, this study shows a sustained

efficacy of biologics up to 5 years follow-up. Moreover, patients with ten years follow-up on biologics have continued on a low dose of prednisolone, and this decline in corticosteroid dose reflects good disease control.

2.22.2 Immunomodulatory dose

Second-line immunosuppressive agents are routinely used in organ transplantation to reduce the risk of graft rejection and in systemic autoimmune disease reduce the concomitant corticosteroid dose. In uveitis, they are commonly used as corticosteroid-sparing agents, however, their use in uveitis is off-label (Suhler, Adán et al. 2018).

For non-alkylating conventional immunosuppressive therapy (antimetabolites and calcineurin inhibitors), the SITE cohort study, showed that these agents were able to achieve control of inflammation in 52%-73% of patients at 12 months depending on specific agent used, with cyclosporine appearing the least successful whereas, mycophenolate was associated with the highest success rate (73%). However, as previously discussed, their corticosteroid sparing-effect was less pronounced and a prednisolone dose < 10 mg per day occurred only in 36-58% of patients at one-year follow-up. Cyclosporine was the least effective with corticosteroid-sparing, with only 36% of patients achieving this compared to 58% in patients taking methotrexate. However, methotrexate and azathioprine appeared to be the least tolerated drugs and they were associated with a high discontinuation rate due to side effects (Jabs 2017).

Mycophenolate mofetil was found effective in controlling the inflammation in posterior uveitis and reducing the daily prednisolone dose below 10 mg at 2 years follow-up; however, 77% needed higher doses (>2 gm daily), and 21% of patients needed another second-line agent to control their disease activity with only 11% were able to stop prednisolone (Goldberg, Lyu et al. 2014). This study only included patients with multifocal choroiditis which is known to have a favourable response to conventional immunosuppression.

Our findings confirms the results of the previous open-label studies on biologics, where treatment with biologics enabled a significant proportion of patients to reduce the dose or even stop their immunomodulatory therapy while maintaining disease under control in patients with corticosteroid-resistant uveitis (Díaz-Llopis, Salom et al. 2012, Suhler,

Lowder et al. 2013). Our study has demonstrated that the proportion of patients receiving a therapeutic dose of the second-line immunosuppressive agent at the time of starting biologics reduced significantly at one-year follow-up. At baseline (initiation of biologics) 70.73% of patients were receiving second-line immunosuppressive agent(s), and the vast majority of patients (97%) were using therapeutic doses. These include mycophenolate mofetil, methotrexate, cyclosporine, azathioprine and tacrolimus. The proportion of patients on therapeutic doses dropped to 67% and 55% at one and two years, respectively. In other words, the proportion of patients who stopped or dropped their second-line agent below therapeutic level rose from 3% at baseline to 45% and 62% at 2 and five years follow-up, respectively (P-value < 0.0001). This remarkable reduction in the number of patients on therapeutic doses of the second-line immunosuppressive agent was coupled with a substantial reduction of concomitant corticosteroids due to better disease control on biologics.

VISUAL III reported a 26% reduction in dose of immunomodulatory therapy (IMT) in patients with active disease and 15% reduction in dose of IMT in patients with inactive disease. Almost half of the patients (47%) with active disease managed to reduce their dose of immunosuppressive treatment by $\geq 50\%$ while in those with inactive disease only 13% have managed to reduce $\geq 50\%$ of their initial immunosuppressive dose. It is difficult to compare these results to our data since in VISUAL III study reported IMT as a combination of corticosteroids and second-line immunosuppressive agents. Also, we have used a cut off for therapeutic and non-therapeutic doses of IMT while in VISUAL III, the reduction was compared to the baseline dose.

Biologic response modifiers are highly effective in treating ocular inflammatory conditions, and have a remarkable corticosteroid-sparing effect. It also appears that these agents have a greater ability to reduce the concomitant daily corticosteroid dose compared to other second-line immunosuppressive drugs and achieve this faster (Martel, Esterberg et al. 2012). Moreover, we have demonstrated that biologic response modifiers also reduce significantly the amount of IMT therapy needed for patients with refractory uveitis.

Because of their superior efficacy and better disease control compared to conventional agents, it would be reasonable to conclude that these agents should be the preferred initial option in patients with NIIPPU. This will not only improve treatment outcomes

but will also reduce significantly the risk of side effects associated with conventional immunotherapy especially when higher doses or more than one IMT agent is used to control ocular inflammation.

2.22.3 Best Corrected Visual Acuity (BCVA)

Benezra et al. reported that visual acuity is regarded as, the best single determinant of disease activity in uveitic eyes (Benezra, Forrester et al. 1991). Similarly, in the VISUAL II study, the most significant parameter of increased inflammatory activity was deterioration in vision in placebo given patients. Therefore, the objective of immunosuppressive treatment in uveitis is to maintain a patient's vision. Although VA does not reflect the entire spectrum of the disease, it is a very sensitive measure to the change in ocular inflammatory status.

Vision in uveitic eyes can be affected in several ways. For example, vitritis which is a common manifestation in most forms of non-anterior uveitis can reduce the vision, especially when inflammatory cells and debris get deposited in the vitreous cavity and obscure the visual axis. Moreover, uveitis related complications such as CMO, choroidal neovascularization are visually threatening and can damage the vision permanently if left untreated due to macular scarring. Furthermore, long-term complications such as retinal ischaemia, cataract, and glaucoma can also lead to significant visual impairment (Tomkins-Netzer, Talat et al. 2014). These complications are prevalent and usually result from poor disease control or side effects of disease treatment (corticosteroids particularly/topically or systemically). Therefore, proper disease control is crucial in maintaining vision in patients with uveitis since it could prevent the development of sight-threatening complications.

Our results show an initial and significant improvement in BCVA during the first year on biologics. There was an initial improvement in BCVA from 0.5 ± 0.05 LogMAR at baseline to 0.4 ± 0.05 LogMAR at three months ($p=0.005$), and BCVA remained stable for the entire follow-up period of 5 years, even in those patients with longer follow-up (10 years) the BCVA remained stable (0.3 ± 0.09) LogMAR. There was a statistically significant improvement in BCVA at 3, 6, nine months and two years follow-up compared to baseline. However, at 1, 3, 4 and five years the results did not show a statistically significant difference. The stability of BCVA reflects the long-term efficacy

of biological agents in controlling ocular inflammatory conditions that would damage structures critical to vision if left poorly controlled. Alternatively, the better control of inflammation on biologic agents reduced the risk of secondary ocular complications that would usually occur in poorly treated uveitis and would compromise the vision such as CMO, glaucoma and cataract.

The mean improvement in BCVA was 0.1 LogMAR at six months follow-up, although it was statistically significant, from the clinical point of view, the improvement was less than one line on the visual acuity chart, and therefore BCVA was considered stable.

Since corticosteroids are quicker to control inflammation compared to other immunosuppressive agents including biologics, patients with sight-threatening inflammation would initially be placed on a high dose corticosteroids (oral or parenteral) to achieve a rapid anti-inflammatory response to rescue vision. The main aim to start biologic treatment was to achieve a corticosteroid-sparing while maintaining disease quiescence.

Our results have shown an initial improvement in vision after commencing biologic treatment, and this may represent an additional disease control on biologics in patients already taking corticosteroids and second-line agents. However, we cannot disregard the fact that some patients have started biologic treatment with active uveitis despite being on high dose corticosteroids with or without second-line agents. But, treatment with biologics has achieved better control of inflammation which translated in improved vision.

Our data shows stability of best-corrected visual acuity (BCVA) on biologic agents in this high-risk group of patients and this represents an agreement with the three VISUAL studies. Likewise, the French Uveitis group reported stability in BCVA after initial improvement at 1 and two years follow up (Vallet, Seve et al. 2016). Our data has shown that the visual acuity remained stable for longer follow-up times (5 years). These results are consistent with VISUAL trials I, II and III, where treatment with biologics led to a significant reduction in the risk of disease recurrence or worsening in BCVA in patients with non-infectious uveitis.

For both Behcet and non-Behcet disease patients, BCVA showed similar trends, however, a wider confidence interval in patients with Behcet disease reflects the greater differences in BVCA within Behcet disease subjects compared to non-Behcet disease patients. For example, patients could have a very low vision (at counting finger level) or normal visual acuity, and this occurs because Behcet disease usually presents with necrotizing occlusive vasculitis and if it involves the posterior pole of the eye (optic nerve and the fovea), ischaemia and permanent structural damage will ensue and the vision remains poor even when adequate control of inflammation is established with biologics. In non-Behcet patients, the BCVA was less variable, and the vision is usually reduced due to increase inflammatory activity in the vitreous or most commonly cystoid macular oedema and both are reversible. Therefore, visual improvement is not uncommon in those entities when the disease is well-controlled.

Moderate vision loss was defined as BCVA < 6/15 whereas severe vision loss is $\leq 6/60$ (SUN criteria). The most common cause for moderate and severe vision loss was macular scarring followed closely by cystoid macular oedema. Retinal detachment was the third most common cause of severe vision loss. Other causes of vision loss are optic neuropathy, ERM, macular ischaemia. The inflammation and ischaemia lead to damage of photoreceptors cell layer and retinal pigment epithelium. Also, the persistent fluid at the macula in the form of CMO or subretinal fluid interferes with the normal physiological function of the retina and leads to loss of photoreceptors. The RPE and outer retinal structures are closely related in both anatomy and function and damage to one layer will result in loss of the other leading to scarring and atrophy.

Macular scarring was the most common cause of both, moderate and severe vision loss, and this depends on the density and the extent of scarring at the fovea. The denser and closer the scar to the fovea the more severe the vision loss is. In contrast to previously reported figures, where CMO was accounting for 41% of causes of vision loss (Rothova, Suttorp-van Schulten et al. 1996). Our study shows that chronic CMO was responsible for 25% of both moderate and severe vision loss. Due to better disease control on biologic response modifiers, CMO was less frequent cause of vision loss. An earlier study showed that TNF α plays a key role in the pathogenesis of CMO and high TNF α levels led to perpetuation of CMO (Markomichelakis, Theodossiadis et al. 2004). One of the possible mechanisms is that TNF α induces vascular leakage at

the fovea either directly or via the up-regulation of other pro-inflammatory cytokines. Anti-TNF α was shown to have antiangiogenic properties and treatment with infliximab induced vascular regression in psoriatic arthritis associated inflammation. Infliximab significantly reduced the expression of VEGF and its receptors which are produced in response to TNF α . But it upregulated angiopoietin 2 which is responsible for vascular stability (Canete, Pablos et al. 2004).

A retinal detachment causes twice as many patients to have severe vision loss compared to moderate vision loss, (19% versus 10%). This depends on the extent of the detachment and the amount retinal damage even after surgical repair.

Additionally, at baseline (at the time of starting biologics) almost two-thirds of patients (62.7%) 94 eyes did not have a visual impairment. Patients not only maintained good vision but some have their vision improved on biologic response modifiers. The percentage of patients without visual impairment rose to 70.5% and 74.8% at six and 24 months on biologics. The increased number of eyes achieving vision better than 6/12 from baseline was statistically significant at six months (p-value 0.004) and two years (p-value 0.01) and remained stable afterwards. Therefore, treatment with biological agents not only maintained the vision in the vast number of patients, but also significantly improved the vision in eyes with visual impairment (VA <6/12).

VA will continue to be used as a marker for inflammatory activity and as a reliable indicator of disease control. Any deterioration in visual function has substantial long-term consequences on patients ability to lead a normal life, and it can affect their mobility and productivity (Tomkins-Netzer, Talat et al. 2014). The long-lasting favourable visual outcome demonstrated in the present study supports the efficacy of these agents in disease control and maintaining the visual function in patients at high risk of vision loss.

2.22.4 Disease relapses

One of the essential features of non-infectious intermediate, posterior and panuveitis is recurrent disease relapse, and these recurrences can cause damage and scarring to the ocular tissue which could lead to irreversible loss of sight. Therefore, treatment usually aims not only at controlling the acute disease episode but also reducing the

risk of future relapses. Thus, long-term disease control is a crucial issue in uveitis management.

Our study shows that before beginning treatment with biologics, patients with non-infectious posterior, intermediate and panuveitis have had recurrent disease relapses, with an average of two relapses per year, despite being placed on relatively high daily dose corticosteroids and second-line immunosuppressive agents. The mean number of disease relapses before biologics was 4.6 flares and the average disease relapse per year was 1.8, whereas after biologics these figures significantly dropped to 1.6 on average, with a mean rate of disease relapses of 0.6 per year of (p-value <0.0001).

Treatment with biologics resulted in a significant reduction (four-fold) in the rate of disease relapse per year in all patients. Only 42% of eyes had a relapse of uveitis after starting biologics and more than half of eyes in our study did not develop a disease recurrence throughout the follow-up time which spans over five year period.

Before biologics, the relapse rate was high, and disease was not under control. Interestingly, biologics did not only significantly reduce the rate of disease relapse, but they also extended the mean time to first disease relapse in the 42% of eyes that had a recurrence of uveitis after starting biologics, the median time to the first relapse was 5.4 years. The significant reduction in disease relapse on biologics paralleled the substantial decrease in concomitant daily corticosteroid dose, which reflects the potency of this class of immunosuppressive drugs in disease control in uveitis. On these grounds, treatment with biologics seems superior to conventional immunosuppressive agents with regards to preventing disease relapses.

In the French Study Group, event-free survival (defined as no disease relapse, treatment failure or serious side-effects), at six months, 12 months and 24 months were 90%, 70% and 59%, respectively. With longer treatment duration, there was a trend for increase in drug-related treatment failure of any cause (Vallet, Seve et al. 2016). The comparison between infliximab and adalimumab in the French study Group revealed similar drug efficacies and event-free survival, however the graphs show data in favour of adalimumab. The event-free survival and cumulative incidence of serious side effect were better in the adalimumab group compared to infliximab, and these approximate statistical significance (p-value = 0.08). Figure 2-38 B & C.

Figure 2-38 Infliximab versus Adalimumab in the Treatment of Refractory Inflammatory Uveitis: A Multicenter Study From the French Uveitis Network (Vallet, Seve et al. 2016)

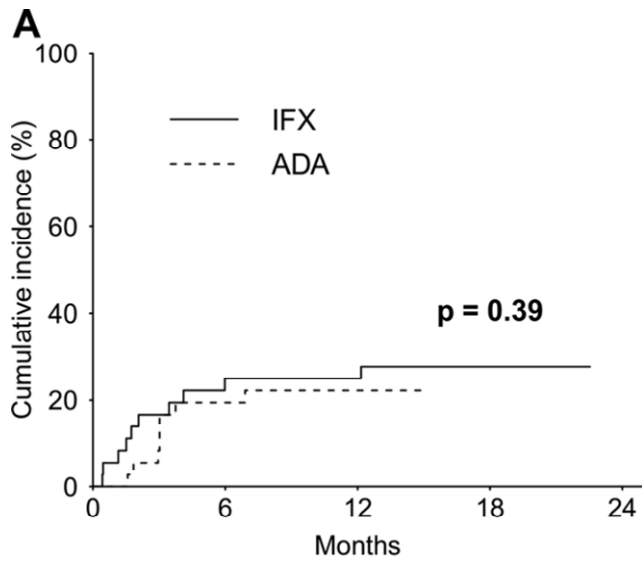


Figure A (Cumulative incidence of complete response to treatment) shows no difference between infliximab and adalimumab. Therefore both are equally effective in achieving disease

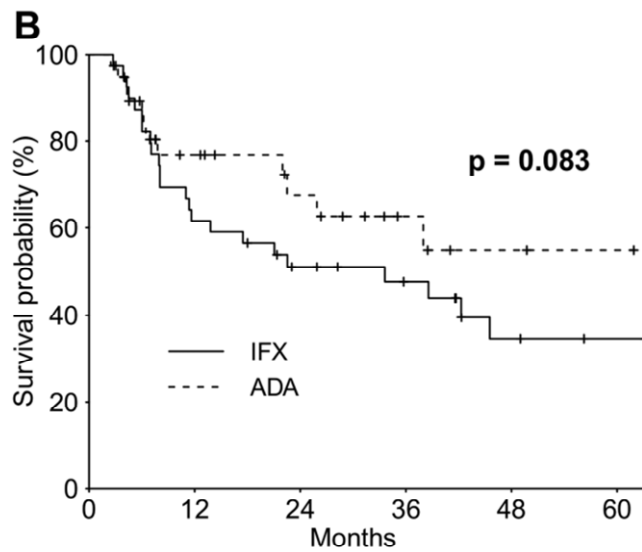


Figure B (Cumulative incidence of event-free survival*) shows a difference between infliximab and adalimumab, however, was not statistically significant.

*Event-free survival (survival without relapse, serious side effect or treatment failure due to any other cause)

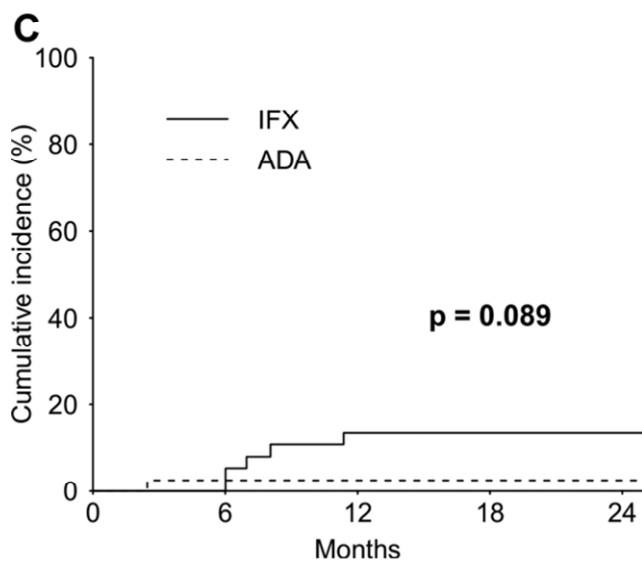


Figure C (Cumulative incidence of serious side effects) shows a difference between infliximab and adalimumab but was not significant. Therefore Adalimumab is better tolerated and associated with less risk of serious adverse events compared to infliximab.

2.22.4.1 Relapse rate on biologics among different diseases (Behcet versus non-Behcet disease).

In Behcet disease there is a pronounced T cell-mediated inflammation which can result in significant damage to the ocular structures and vision. Studies have shown that TNF α is upregulated in patients with Behcet disease and high levels were associated with disease relapse (Turan, Gallati et al. 1997) (Santos Lacomba, Marcos Martin et al. 2001, Evereklioglu, Er et al. 2002). Others have also shown a central role of TNF α in disease pathogenesis. We performed a separate analysis comparing Behcet versus non-Behcet disease patients with regards to survival to first disease relapse.

Before the initiation of biologics, there was no significant difference between Behcet and non-Behcet disease patients with regards to the rate of disease relapse per year. Nonetheless, after starting biologics, Behcet disease patients experienced significantly lower rates of disease relapse compared to non-Behcet disease subjects (p-value<0.001).

For Behcet disease patients the mean survival time to first disease relapse was more than eight years versus 2.5 years in non-Behcet patients, a highly statistically significant difference between the two groups (p-value<0.001). There was a dramatic decrease in the number of disease relapses among patients with Behcet disease after starting biologic therapy. Also, our data show that biologic therapy has reduced the risk of disease recurrence by 75% in BD compared to other patients. Behcet disease patients showed a very favourable response to treatment with biologics compared to non-Behcet disease subjects. Similar findings were reported by the French Uveitis group, where Behcet disease increases the likelihood of response to biologics (infliximab and adalimumab) (Vallet, Seve et al. 2016). In this study, univariate analysis showed that BD was associated with a three-fold increase in the rate of complete response to anti TNF α (p-value=0.004), with both Infliximab and adalimumab having equivalent efficacy.

This superior sensitivity to anti-TNF α drugs for Behcet disease patients compared to non-Behcet disease may be due the crucial role of TNF α in the pathogenesis of Behcet disease as shown in previous studies where high levels of TNF α were present in the ocular fluid of BD patients and no inflammatory cytokines were detected in the ocular

fluids in BD patients treated with TNF α . The authors concluded that anti-TNF α agents block the differentiation of effector T cells particularly Th17 (Sugita, Kawazoe et al. 2012). In non-Behcet disease patients, other inflammatory mediators might also be involved in the inflammatory cascades and to a greater extent. Therefore, blocking only TNF α does not achieve full control of inflammation in non-Behcet patients.

In agreement with our study, Takeuchi et al. reported a significant decrease in the frequency of ocular attacks per year after treatment with infliximab in 164 patients with Behcet disease-associated uveitis (5.3 ± 3.0 to 1.0 ± 0.3 ; $p < 0.05$) and improvement in visual acuity after treatment. Uveitis relapsed in 59.1% of all patients after infliximab therapy, and about 80% of relapses occurred within the first year of treatment (Takeuchi, Kezuka et al. 2014). On infliximab therapy, the majority of these relapses (69%) needed only topical corticosteroids to control disease activity which implies a milder form of disease recurrence compared to patients without biologics therapy. Alternatively, shortening of the interval between infusions in addition to topical corticosteroids was enough to control these flare-ups in 22%, and only 7% and 2% required an increased dose of infliximab and treatment with systemic immunomodulatory therapy, respectively, to control the attacks.

In the above study, the mean duration from treatment with infliximab to the first relapse was 8.5 ± 7.1 months (ranging from 1 month to 2 years), and 93% of patients were receiving systemic immunosuppressive drugs at baseline, and this decreased to 62% after initiation of therapy. In the same study, the percentage of patients receiving cyclosporine reduced from 44.5% to 25.6%, and for those with corticosteroids the proportion decreased from 39.66 to 29.3%. Since some ophthalmologists advocate the concomitant use of immunosuppressive drugs with infliximab to reduce the risk of autoantibody formation, it is difficult to assess with accuracy the actual sparing effect of infliximab on the second-line immunosuppressive agents (Takeuchi, Kezuka et al. 2014).

In Takeuchi et al. study, the data show a reduction in the rate of relapse of BD uveitis on biologics, but the proportion of patients who relapsed on treatment was relatively high (59.1%) compared to our findings, where only (15.6%) of eyes with BD had a relapse of uveitis. One of the reasons is that infliximab was the only anti-TNF α agent used whereas our study has also included patients on adalimumab which may have

better efficacy in controlling BD uveitis. Also, there was a noticeable variation in the amount and type of concomitant immunosuppressive therapy in Takeuchi et al. study. For example, colchicine was the most commonly used drug in a significant proportion before and during infliximab therapy. It is known that colchicine, has poor efficacy in controlling ocular manifestations of Behcet disease. Moreover, a small number of patients were placed on corticosteroids before (39%) and during infliximab therapy (29%), and few patients had IMT. Concomitant use of corticosteroids and immunosuppressive drugs enhances the response to anti-TNF α drugs (infliximab and adalimumab) (Vallet, Seve et al. 2016). Therefore, less response to biologics was encountered in the Takeuchi et al study compared to our findings and other reported figures in the literature (Vallet, Seve et al. 2016).

Infliximab was extensively studied in ocular manifestations of Behcet disease namely, retinal vasculitis and panuveitis and retinitis. When compared to corticosteroids or cyclosporine, infliximab demonstrated superior efficacy in disease control and a significant reduction in the number of disease relapse. A single infliximab infusion versus corticosteroids in Behcet disease panuveitis resulted in faster resolution of inflammation, macular oedema and retinitis compared to corticosteroid (Markomichelakis, Delicha et al. 2010). Another study was comparing the effect of Infliximab versus cyclosporine in refractory Behcet disease uveoretinitis, and found better efficacy with infliximab after six months follow-up. The number of disease relapses was significantly lower in the infliximab group compared to the cyclosporine group (p -value <0.005) (Yamada, Sugita et al. 2010). Moreover, both studies reported a better safety profile for infliximab compared to corticosteroids or cyclosporine.

Similarly, Tabbara et al. reported a significant decrease in inflammation and ocular complications and improvement in vision in 43 Behcet patients treated with infliximab compared to patients on conventional treatment. Better disease control with a significant reduction in the number of disease relapse was achieved in the infliximab group compared to the conventional therapy (prednisolone with cyclosporine or azathioprine and methotrexate) (p -value <0.0001). Also, the visual acuity was significantly better in infliximab treated patients compared to conventional therapy at two-year follow-up (p -value =0.0059) (Tabbara and Al-Hemidan 2008).

Interestingly, infliximab was successful in treating retinal neovascular membranes not associated with capillary drop-out but driven primarily by inflammation. These membranes regressed after eight months of treatment, with a complete resolution of ocular inflammation (Giansanti, Barbera et al. 2004). Also, infliximab was effective in treating chronic, resistant CMO in Behcet patient without clinically evident ocular inflammation (Markomichelakis, Theodossiadis et al. 2004).

Okada et al. studied 63 patients with ocular Behcet treated with infliximab prospectively, and 69% of patients showed full improvement, 23% had partial improvement, and only 8% showed no improvement. The mean number of ocular attacks reduced from 2.66 at baseline to 0.44 during the first six months after starting infliximab. The 92% improvement whether complete or partial was paralleled with improvement in visual acuity (Okada, Goto et al. 2012). Golimumab in 17 Behcet patients with systemic and ocular manifestations showed 94% of patients had their disease quiescent with better results when combined with other immunomodulatory therapy at three months (Vitale et al., 2017a).

A meta-analysis of anti-TNF α agents in 369 patients with Behcet disease, reported a very high clinical response rate with >90% improvement in all disease manifestations (mucocutaneous, ocular, gastrointestinal and central nervous system) in patients inadequately controlled with conventional immunosuppressive agents (Arida, Fragiadaki et al. 2011). The same study also reported that combination therapy of infliximab with azathioprine with or without cyclosporine resulted in superior efficacy compared to monotherapy with infliximab alone. The combination of infliximab and cyclosporine was superior to all other drugs in achieving long-term ocular remission in Behcet disease uveitis. In the same review, improvement rates in patients with ocular Behcet were 89% and 100% for those treated with infliximab and adalimumab, respectively. The study reported that adalimumab achieved better disease control in Behcet disease patients compared to infliximab. However, the number of patients treated in the infliximab group was much higher than that of adalimumab, 262 versus 16 patients.

Another study by Niccoli and co-authors, in Behcet patients with posterior and panuveitis, reported complete remission in 75% (9 out of 12 patients) after 12 months follow-up. The number of recurrences decreased from 40 attacks before infliximab to

only five after cessation of therapy (Niccoli, Nannini et al. 2007). However, the effect of biologics was not sustained, and patients needed to continue on these medications. Accorinti and associates observed that some patients who had stopped or delayed their therapy because of infections, had developed relapses after a mean time of 16.5 days, which were worse than during initiation of infliximab therapy (Accorinti, Pirraglia et al. 2007).

Several studies on repeated infliximab infusions to prevent ocular relapses in Behcet disease reported stability in visual acuity, and reduction in immunosuppressive therapy (Ohno, Nakamura et al. 2004, Sfikakis, Kaklamanis et al. 2004) (Tugal-Tutkun, Mudun et al. 2005). A quick and impressive improvement in visual acuity after 24 hours of infliximab initiation was reported, unless permanent damage to the eye has occurred before treatment (Arida, Fragiadaki et al. 2011). Fabiani and associates reported that Behcet patients (40 patients 70 eyes) treated with infliximab had their visual acuity improved, and a corticosteroid-sparing effect was achieved in most patients $p < 0.0001$. The study also reported that there were no differences in drug survival between those with concomitant second-line immunosuppressive agents or not after ten years follow-up (Fabiani, Sota et al. 2017). Quality of life also significantly improved in patients with Behcet disease after infliximab therapy. This paralleled improvement in inflammatory activity demonstrated by a reduction in numbers of uveitis flares and improvement in extraocular disease manifestations (Sakai, Watanabe et al. 2013). Similarly, infliximab therapy was effective in controlling the inflammation, resolving the CMO and improvement in visual acuity (Al Rashidi, Al Fawaz et al. 2013).

A study reported that infliximab treatment resulted in good response in 76.7% (56 out of 73) of Behcet disease patients and the concomitant use of azathioprine at the start of treatment with infliximab was significantly associated with achieving a good response (D'Angelo, Leccese et al. 2015). Similarly, treatment with infliximab resulted in significant reduction in or complete cessation of systemic immunosuppressive agents in Behcet associated uveitis, and all patients achieved remission, with 73.7% of patients not requiring systemic corticosteroids. All patients achieved complete remission and 5 out of these 19 patients achieved drug-free remission with a mean duration of 24.6 ± 5.5 months (Al Rashidi, Al Fawaz et al. 2013). Treatment was safe, and 94.7% continued treatment with infliximab without significant adverse events. The same study reported detectable titres of autoimmune antibodies (ANA and anti-

dsDNA) but without clinical disease in 53% of patients and only one patient developed a severe infusion reaction.

Stopping infliximab infusions after achieving long-term complete remission was achieved in 9 out of 15 patients with the interval from drug initiation to treatment withdrawal ranging from 22 to 87 months (mean of 55.7 ± 22.8 months). Four patients developed a flare after cessation of infliximab therapy with an interval ranging between 3 to 10 months (mean of 6.3 ± 2.9 months), and had to restart infliximab therapy (Al Rashidi, Al Fawaz et al. 2013).

The efficacy of Infliximab in sarcoidosis patients, with severe ocular involvement, has been reported in several case series studies (Levy-Clarke, Jabs et al. 2014). Similarly, adalimumab has also been used to treat severe sight threatening posterior segment sarcoidosis. Of 26 (41 eyes) sarcoid patients refractory to treatment, 85% achieved improvement in the ocular inflammatory signs while the remaining were stable at one year (Erckens, Mostard et al. 2012). Conversely, etanercept in sarcoidosis not only failed to control the ocular inflammation or achieve corticosteroid-sparing at six months when compared to placebo, but it also induced a granulomatous reaction in the setting of sarcoidosis and enhanced the development of sarcoid-like granulomas. Therefore, an expert panel recommended against the use of etanercept in sarcoid patients (Erckens, Mostard et al. 2012). Etanercept is inferior to both infliximab and adalimumab in treating ocular inflammatory diseases. One of the possible mechanisms is the molecular structure of etanercept which is composed of fusion protein that neutralizes only soluble TNF α , unlike infliximab and adalimumab where both forms of TNF α (soluble and transmembrane) are effectively blocked. Please refer to page 151 first paragraph for other mechanisms.

2.22.4.2 Time to first relapse on different biologics

Comparing the efficacy of adalimumab and infliximab in relation to time to disease relapse has shown no significant difference. Similarly, subgroup analysis for patients with Behcet and non-Behcet disease separately did not show a statistically significant difference in time to first disease relapse for patients on infliximab or adalimumab. Fabiani and associates also reported recently similar efficacy between these two

biologics in controlling disease relapses in patients with non-infectious intermediate, posterior and panuveitis (Fabiani, Vitale et al. 2018). Conversely, diagnosis (Behcet versus non-Behcet) has a significant impact on time to first disease relapse under biologics treatment, with better survival time from disease recurrence in Behcet disease subjects. However, the type of anti-TNF α agent did not show any difference.

As previously shown, the results of our small cohort of patients treated with etanercept suggest it is associated with a worse outcome in uveitis control. Analysing ten eyes with different disease aetiologies on etanercept showed a high rate of disease relapses (70%). Furthermore, two eyes without prior uveitis developed uveitis during etanercept therapy, which was commenced for systemic autoimmune disease. Treatment with rituximab, on the other hand, was effective for uveitis, and disease control was achieved in approximately 65% of patients.

2.23 Treatment failure

Generally, biologics were effective and well-tolerated by most patients. Treatment failure as previously defined as stopping of biologic treatment or switching to different biologic due to lack of efficacy or treatment-related side-effects occurred in only 28% of patients. Median time to treatment failure was approximately 1.65 years. Among patients who failed their first biologic, the vast majority (86.5%) were switched to another biologic agent (either same or different class). The most common reasons were poor efficacy or drug-related side effects such as infusion reactions or rarely demyelination. The reasons for treatment failure on infliximab were drug-related allergic reactions and inadequate response to treatment, while all patients on etanercept failed treatment due to poor disease response.

Our data show that a significantly higher proportion of patients failed treatment with infliximab (42%) compared to adalimumab (17%) (p-value = 0.001). Survival analysis shows a significant difference in time to treatment failure between these two biologics (p-value = 0.003). In all patients, the drug retention rate was significantly higher on adalimumab compared to infliximab. Treatment with adalimumab was associated with a significantly lower risk of treatment failure compared to infliximab, a relative risk reduction of treatment failure of 65% on adalimumab in comparison to infliximab (p-value = 0.004).

Subgroup analysis in non-Behect disease patients shows similar trends with a significantly higher proportion of patients failing infliximab treatment compared to adalimumab. Survival analysis displays a significant difference in time to treatment failure on infliximab versus adalimumab (p-value = 0.01). The data confirm that drug retention rate was significantly better for patients receiving adalimumab compared to those on infliximab therapy. Similarly, in Behcet disease, a higher proportion of patients failed treatment with infliximab compared to adalimumab. However, the results were not significant (p-value 0.23), and this may be due to the imbalance in the number of patients on the biologics, with a higher number of patients on infliximab compared to adalimumab. Comparing treatment failure on infliximab and adalimumab in Behcet versus non-Behect disease revealed a non-significant difference (p =0.10). Therefore, treatment failure was primarily due to the type of biologic used (infliximab versus adalimumab), and disease aetiology was not that significant in the development of treatment failure.

In contrast, Fabiani and associates reported similar drug retention rate between adalimumab and infliximab in 80 Behcet disease patients out of 107 (74%) patients (subgroup analysis) (log-Rank p-value= 0.07). Likewise, analysing all study populations (108 patients) did not show a statistically significant difference in drug discontinuation rate between these two biologics (p-value=0.22) (Fabiani, Vitale et al. 2018). These results contradict our finding where infliximab was associated with a significantly higher drug discontinuation rate. This divergence could be due to different groups of patients included in the studies since the vast majority of patients in Fabiani et al. study were Behcet disease patients, and it was not clear from the above study whether patients with non-Behect disease will behave in a similar way to those with Behcet with regards to drug retention rate. Additionally, a shorter duration of follow-up in patients on adalimumab compared to infliximab might have played a role in these results. However, in the above study, a trend toward significance, with regards to drug-retention, was observed in favour of infliximab among Behcet patients (p-value 0.07). The key message from this trial is that these biologics remained effective for long follow-up time, and this applies to whether treatment was given intravenously or subcutaneously (infliximab or adalimumab).

Our results showed that adalimumab is superior to infliximab with regards to treatment failure in uveitis. There was a significantly shorter time to treatment failure with infliximab compared to adalimumab. This may be because unlike adalimumab, infliximab is a chimeric molecule which might possess a higher risk in triggering an immune reaction that causes drug allergy, or infliximab loses its efficacy due to the development of antidrug antibodies. VISUAL I trial reported very low immunogenicity of adalimumab.

It has been reported that anti-TNF α drugs lose their efficacy owing to the development of antidrug antibody which is responsible for increasing drug failure rates after multiple infusions (Maini, Breedveld et al. 1998). Nonetheless, our data show that treatment was effective for extended follow-up times and was continued by the majority of patients (72%) at the five-year follow-up. Similarly, two studies have reported excellent long-term retention rates with infliximab in Behcet disease patients approaching up to 75% at five-year follow-up (Cantarini, Talarico et al. 2017, Fabiani, Sota et al. 2017). In Behcet disease patients the retention rate of adalimumab at 1 and four years follow-up were 76.9 % and 63.5%, respectively, among 54 patients and 82 eyes (Fabiani, Sota et al. 2018). On the other hand, the retention rate on infliximab was reported to be 89% at one year and 47% at ten years (Fabiani, Sota et al. 2017). Likewise, a study comparing the retention rate between adalimumab and infliximab showed these rates to be 65% in adalimumab group versus 75% in infliximab group at 5-year follow-up assessment in 64 Behcet disease patients (Cantarini, Talarico et al. 2017).

To determine factors related to treatment failure, a multivariate logistic regression analysis was conducted only on patients treated with infliximab and adalimumab because the number of eyes on other biologics were insufficient for the analysis. The results showed that adalimumab was associated with a significantly lower rate of treatment failure, odds ratio for treatment failure on adalimumab was 0.4 (95%CI 0.18-0.89, $p=0.03$). On the other hand, biologic agents given for systemic disease are three times more likely to lead to treatment failure compared to the ocular disease alone, odds ratio (OR) of 3.22 (1.46-7.07, $p=0.004$). Finally, for each year increase in age the risk of treatment failure was reduced by 3%.

In the multivariate analysis in our study, gender, anatomical location of uveitis, aetiology of uveitis, laterality, treatment with corticosteroids or IMT did not have a

significant association with treatment failure. Fabiani et al in their study reported similar findings, and they also reported that whether biologics were used alone or in combination with other immunosuppressive agents, there was no statistically significant effect on the long-term effectiveness of adalimumab and infliximab (Fabiani, Vitale et al. 2018). Furthermore, in Fabiani and associates study treatment with adalimumab and infliximab in biologic-naïve patients or previously switched from other biologics did not have a statistically significant difference on drug discontinuation rate.

2.23.1 Switching from infliximab to adalimumab.

Among those who initially failed infliximab (13 patients) who switched to adalimumab, the majority were due to allergic reactions (itching) and a minority due to inadequate response to treatment. Those patients had a favourable response to adalimumab, and only three patients (23%) failed the second biologic, and this was due to inadequate response to treatment. There was a significant improvement in mean survival time to treatment failure on switching to the second biologic (adalimumab) (p -value <0.001).

Those who switched from infliximab to adalimumab had an improved treatment success rate and less than a quarter of patients had to stop adalimumab due to an inadequate response, and none had drug-related allergic reactions. Almost two-thirds (61.5%) continued their treatment on adalimumab till last follow up visits and (15.5%) stopped treatment due to disease control. Adalimumab was effective and well-tolerated by over 75% of these patients.

Several studies have reported successful switching from infliximab to adalimumab. In ankylosing spondylitis and psoriatic arthritis anti-TNF α agents were associated with high drug persistence rate and switching to another agent due to lack of efficacy or adverse reactions can be a valid option. However, this study was for only six months of follow-up (Fabbroni, Cantarini et al. 2014).

With regards to the efficacy of anti-TNF α in biologic-naïve patients, Fabiani et al. reported a better drug survival when infliximab was employed as a first biologic and claimed that BD patients are more likely to have better results, if they were biologics naïve (Fabiani, Sota et al. 2017). In contrast, Vallet and co-workers reported equivocal

results between infliximab and adalimumab whether used as first or second agents (Vallet, Seve et al. 2016).

Our data shows that adalimumab was still effective in patients previously treated with infliximab. Similarly, several studies in Behcet patients showed continued disease control upon successful transition from infliximab to adalimumab in patients who were previously controlled on infliximab and flared-up after stopping treatment (Van Laar, Missotten et al. 2007), or had to stop infliximab due to development of an allergic reaction (Takase, Ohno et al. 2011) or switched during disease remission (Mushtaq, Saeed et al. 2007). In Takase et al. study adalimumab induced fast clinical remission in Behcet patients. Similarly, other studies have reported similar efficacy between infliximab and adalimumab. However, adalimumab was better tolerated and was associated with less adverse reactions (Martel, Esterberg et al. 2012). Likewise, Bhatt and co-authors, reported that allergic reactions at the injection site were the most commonly reported side effects on adalimumab (Bhatt, Tucker et al. 2016). Adalimumab appears to have a superior safety profile, and seems better tolerated compared to infliximab in patients with refractory ocular inflammatory diseases. In agreement with this Takase and Ohno reported that adalimumab was shown to be more effective and associated with fewer hypersensitivity reactions in Behcet disease patients switched from infliximab to adalimumab (Takase, Ohno et al. 2011).

Finally, our analysis shows that all patients failed treatment with etanercept. Etanercept was reported to be useful for the mucocutaneous manifestations of Behcet disease, but, was less effective in controlling other systemic manifestations (Melikoglu, Fresko et al. 2005), and better control of systemic disease was achieved after switching to infliximab (Estrach, Mpofu et al. 2002).

2.23.2 Is adalimumab is superior to infliximab in treating NIIPPU?

Studies comparing the efficacy of infliximab and adalimumab reported conflicting results. Adalimumab was reported superior to infliximab, and it was better in maintaining disease remission over three years in a comparative cohort study on anti-TNF α in sight-threatening uveitis in childhood (Simonini, Taddio et al. 2011). However, the French Uveitis group reported that adalimumab is equivalent to infliximab regarding the efficacy in patients with non-infectious refractory uveitis (Vallet, Seve et

al. 2016). In the French Uveitis group, the overall response rose significantly with both anti-TNF α drugs from 87% at six months to 93 and 95%, at 1 and two years, respectively. The median time to treatment response was two months among complete responders, and the response rate was 97% in the infliximab group and 95% in the adalimumab group.

Two studies compared the efficacy of both infliximab and adalimumab in chronic anterior uveitis in children. The first study reported a superior long-term remission with adalimumab compared to infliximab in childhood chronic anterior uveitis (Simonini, Taddio et al. 2011). However, both drugs were similar in time to achieve disease remission and discontinuation of corticosteroid. The second study reported a significantly higher remission rates with adalimumab in comparison to infliximab at one year, in JIA associated uveitis (67.5 % versus 42%, p-value= 0.025) (Zannin, Birolo et al. 2013).

2.23.3 Role of adalimumab in NIIPPU

Adalimumab In a retrospective study in patients with chronic uveitis refractory to treatment was effective in controlling the inflammation in 35% of patients who were refractory to previous treatment with etanercept and infliximab (Tynjälä et al., 2008). However, this was conducted on patients with JIA-related chronic anterior uveitis. Factors that have a favourable response were: younger age and shorter disease duration. Adalimumab was given in a prospective pilot study on 19 treatment-resistant uveitic patients, half of them diagnosed with idiopathic intermediate/panuveitis and the remaining were either Behcet' patient, Vogt Koyanagi Harada disease or Birdshot chorioretinopathy. Adalimumab controlled inflammation in 63% of patients, and after one year there was a complete resolution of CMO in 55% of patients. Adalimumab led to an improvement in their visual acuity and achieved better control of inflammation with a 50% reduction of the concomitant immunomodulatory therapy from baseline (Diaz-Llopis, Garcia-Delpech et al. 2008). However, in this study, the authors used a single numeric grading system from 0 to 9 for each drug (apart from mycophenolate 0-7). The dose of each drug is given a score on the scale and if two drugs were used a combined score is given. We have used a simplified approach by categorising the dose of each drug into therapeutic and non-therapeutic dose based on pre-specified

cut-off values for each drug. Also, this study included a small number of patients and had a relatively short duration of follow-up (1 year). Around 42% had at least one disease relapse during the follow-up period which was treated with periocular corticosteroids.

Likewise, Martel and co-workers in a retrospective case series of non-infectious uveitis reported that a combination of corticosteroid-sparing effect (daily prednisolone ≤ 10 mg) and sustained inflammatory control was achieved on adalimumab in 38% and 57% of patients at 3 and 12 months respectively (Martel, Esterberg et al. 2012). The figures for infliximab were 33% and 61% at 3 and 12 months, respectively. However, half of the patients included in this study were diagnosed with anterior uveitis. Also, the median follow-up was shorter in adalimumab 0.9 years versus 1.2 years in the infliximab group. Moreover, the authors did not stop the immunomodulatory therapy as a precautionary measure against the development of anti-biologic antibody.

Similarly, adalimumab in an open-label non-comparative prospective trial in 31 with non-infectious uveitis refractory to treatment, demonstrated clinical improvement in 68% of patients at ten weeks, and 12 patients (39%) had sustained response after one year (Suhler, Lowder et al. 2013). However, shorter duration of follow-up is unlikely to reveal the full treatment efficacy. Longer follow-up is better in demonstrating the drug resistance which was claimed to be a reason for treatment failure.

A multicentre prospective study of 131 patients with refractory uveitis (39 JIA, 16 pars planitis, 13 Behcet and 27 idiopathic uveitis) intolerant or failed to respond to prednisolone and at least one IMT received reported significant reduction in the anterior and posterior chamber inflammation, improvement in VA and reduction in the immunosuppression load on adalimumab 40 mg every two weeks. There was a significant reduction in corticosteroid dose (Díaz-Llopis, Salom et al. 2012). Those patients who had lost response to infliximab and etanercept have responded to adalimumab. Forty-four patients (33.6%) had chronic anterior uveitis, nine patients (6.9%) had intermediate uveitis, five patients (3.8%) had posterior uveitis, and 57 patients (43.5%) had panuveitis. The remaining 16 patients had combined anterior and intermediate uveitis ($n = 9$) or combined posterior and intermediate uveitis ($n = 7$). There was a marked decrease in intraocular inflammation after six months, and 50 patient (38%) experienced reactivation of uveitis

When adalimumab was given to 10 patients with refractory uveitis of different aetiologies, all patients responded to treatment by showing improvement in intraocular inflammation and visual acuity. There was a significantly lower percentage of relapses 20%, and this may be due to the fact that treatment with methotrexate was maintained throughout the follow-up period which has a synergistic effect on reducing the relapses rate (Callejas-Rubio, Sánchez-Cano et al. 2008). Treatment with methotrexate was maintained in 80% of patients. In this series-most of the patients had panuveitis.

Adalimumab is licensed in the United States for the treatment of non-infectious uveitis, intermediate uveitis, posterior and panuveitis in adult patients. In Europe, adalimumab is indicated for the treatment of non-infectious uveitis in patients who have demonstrated an inadequate response to corticosteroids, patients who need corticosteroid-sparing, or in whom the treatment with corticosteroids was not appropriate (Dick, Rosenbaum et al. 2018).

The efficacy of adalimumab as a combination therapy with methotrexate in JIA associated anterior uveitis showed superior reduction in treatment failure and delay in time to treatment failure compared to methotrexate alone (Hazard ratio 0.25: 95%CI, 0.12-0.49; $P < 0.0001$). Also, there was significant corticosteroids sparing with combination therapy ($P=0.02$) (Ramanan, Dick et al. 2017). Another study reported that the co-administration of disease modifying anti-rheumatoid drugs (DMARDs) did not affect the clinical efficacy of adalimumab, in 100 Behcet patients. Adalimumab was reported as effective and induced a good clinical response in 81 patients with a mean time of 7 ± 3 weeks. 30% relapsed after 22 months ± 1.5 month. At two years 67/100 were still using adalimumab, There was a significant difference in the number of flare-ups treatment discontinuation at 24 months (Vitale, Emmi et al. 2017).

2.24 Safety of biologic response modifiers

Our data shows that biologics were well tolerated by most patients with low rates of severe infection and demyelinating disease. Adalimumab was better tolerated than infliximab, and there were significantly fewer treatment failures due to adverse drug reaction on adalimumab compared to infliximab. The French Uveitis Group reported that infliximab was associated with a higher rate of serious adverse events compared to adalimumab (16% versus 6%) including more infections, hypersensitivity reactions,

autoimmune disease and neoplasia (Vallet, Seve et al. 2016). In the previous study factors associated with severe adverse events were older age, and those with greater than five flares before starting biologics. The higher frequencies in autoimmune diseases and allergic reactions could be explained by the fact that infliximab is more immunogenic than adalimumab due to the mouse portion within its structure. However, the two drugs were similar concerning serious side effects (Vallet, Seve et al. 2016).

Interestingly, biologics were reported to have a superior safety profile compared to other immunomodulatory therapy. Abásolo and associates in their 10-year follow-up study reported that systemic treatment was suspended in over 50% of cases with non-infectious uveitis. The three most common causes of treatment discontinuation were adequate clinical response to treatment, followed by lack of efficacy and lastly treatment-related side effects. Not surprising, this paper reported that combination therapy was associated with higher rates of drug discontinuation owing to clinical efficacy compared to monotherapy. The discontinuation rate due to adverse reactions was the lowest among TNF α blockers compared to other immunomodulatory agents (cyclosporine, methotrexate and azathioprine). Finally, the drug discontinuation rate due to adverse drug reactions was highest with cyclosporine followed by azathioprine. Also, the combination with azathioprine and another non-biologic agent such as cyclosporine was associated with a higher rate of adverse drug reactions which had led to discontinuation of the treatment (Abásolo, Rosales et al. 2016).

For patients with intermediate uveitis, MRI and neurological assessment would be important to exclude a demyelinating disease especially MS. However, MS may develop years after treatment with biologics, one patient in our study had been diagnosed with intermediate uveitis initially and was treated with biologic then had a diagnosis of both Behcet disease and MS. Anti-TNF alpha agent was stopped, and the patient commenced an interferon treatment.

The VISUAL III trial on long-term efficacy and safety of adalimumab reported a low incidence of adverse events. The most common were infections particularly reactivation of latent TB (3.8%), malignancies were reported in 2.9%, with non-melanoma skin cancer being the most commonly encountered cancer followed by solid organ cancer such as, rectal and pancreatic, and breast cancer. The incidence of demyelinating disorders was low (1.2%). Liver disorder and liver failure were

reported in 2.4% of patients. Finally, A study on 315 patients with AS using adalimumab for 24 weeks reported that there were no cases of reactivation of latent TB, exacerbation of congestive heart failure, demyelinating disease or onset of malignancies (van der Heijde, Pangan et al. 2008).

2.25 Overall conclusion and the major impact of the study

In our study, the majority of patients with non-infectious, non-anterior uveitis refractory to conventional immunosuppression (were not controlled with multiple drugs, including prednisolone, and one or two second-line agents) responded favourably to biologic therapy. There was a marked reduction in the annual rate of disease relapse, and this better disease control on biologics allowed the dose of other immunosuppressive drugs to be significantly lowered.

In accordance with previously published data, this study shows that treatment with biologics achieved a significant and consistent reduction in mean daily corticosteroid dose early on. There was a significant reduction in the daily prednisolone dosage after three months on biologics. Also, the percentage of patients on corticosteroids dose \leq 10 mg (safe threshold) increased remarkably. Similarly, a significantly less proportion of patients either stopped second-line agent(s) or dropped below the therapeutic dose. Our data also shows that the reduction in dose of immunosuppressive therapy was maintained for prolonged follow-up period (5 years and beyond). Therefore, biologic agents are still effective for extended follow-up time, contrarily to the previously held perception that biologic agents lose their efficacy with time.

With regards to anti-TNF α drugs, our study proves the fact that etanercept has poor efficacy in controlling ocular inflammatory diseases and should be avoided in these conditions. Conversely, both infliximab and adalimumab are effective in ocular inflammatory diseases. Our data shows that they both have similar corticosteroid-sparing action, but treatment failure due to drug-related allergic reactions was significantly higher in infliximab-treated patients. This might be attributed to the molecular differences between these two anti-TNF α (adalimumab is fully humanised whereas infliximab contains a mouse protein, and therefore is more likely to induce an immune reaction). Examining factors related to poor response to infliximab and

adalimumab shows that treatment for systemic disease was associated with three times increase in risk of treatment failure compared to ocular disease alone.

Importantly, in the current study, Behcet disease patients with ocular involvement are more sensitive to TNF α blockers compared to other disease etiologies. Behcet disease patients treated with biologics had significantly lower rate of disease. In subjects with Behcet disease, biologic treatment reduced the risk of uveitis recurrence by 75% compared to non-Behcet's patients. This interesting finding may be attributed to the central role of TNF α in Behcet disease pathogenesis. Therefore, BD patients should be offered a biologic treatment early on in disease course.

Finally, with regards to safety of biologics, malignancy rates were meager in our study, and only two patients developed demyelinating disease. None of the patients in this study developed lupus-like disease which could be explained by the fact that the majority of patients were taking immunosuppressive agents in addition to their biologic treatment. Although, in the current study biologic treatment was safe and well tolerated by the majority of patients, it is difficult to ascertain these findings due to small sample size. A randomised-controlled trials are needed to provide evidence regarding the safety and efficacy of biologics in large number of patients.

Implications and recommendations

- Biologics (excluding etanercept) should be used to treat patients with non-infectious intermediate, posterior and panuveitis managed on high dose corticosteroids and second-line immunosuppressive agents.
- Adalimumab has a superior safety profile and also easily administered by patients, therefore, it should be the initial preferred choice for patients with refractory non-infectious uveitis. Switching to a different biologic is a valid option and patients switched from infliximab to adalimumab had good response and treatment was well tolerated.
- Behcet disease patients with vital organ involvement (including the eye) must start anti TNF α therapy as soon as possible to achieve rapid disease control and reduce the risk of severe visual impairment.
- Looking at treatment failure rates in patients on biologics with and without IMT.

Limitations

The study is retrospective in nature, and patients in this cohort do not represent patients with ocular inflammatory diseases. The data were collected in a tertiary care centre thus a referral bias might exist because it is more likely to encounter more severe cases and patients who are doing well and their uveitis is well-controlled are unlikely to get referred. Also, patients had variable follow-ups and there was incomplete data for some patients. Moreover, there were small number of patients on some biologics such as rituximab and vedolimumab. Finally, the inherent heterogeneity of uveitis makes studying therapeutic agents challenging Therefore, our results must be interpreted with caution.

3 Chapter Three Statins in inflammatory eye disease

3.1 Introduction

Treatment with oral corticosteroid is essential in controlling the inflammation in almost all forms of sight-threatening uveitis. This treatment is not curative, but suppresses the inflammation and herein reducing the ocular tissue damage. After achieving successful control of inflammation with high dose corticosteroid, treatment then aims to keep the inflammatory drive under control with the lower effective dose possible and patients commonly adhere to therapy for an extended period.

One of the challenges in uveitis management is that there are no means in differentiating treatment-induced disease remission from disease quiescence on immunosuppressive therapy. Therefore, slow withdrawal of treatment with close monitoring for any signs of increase inflammatory activity is the only clinical management approach currently available. When the disease relapses, which is inevitable in most forms of non-infectious IU, posterior and panuveitis, corticosteroid dose is then increased to a higher dose to re-establish disease control. Therefore, uveitis management usually involves long-term treatment with systemic corticosteroids and or second-line immunosuppressive agents (corticosteroid-sparing), until the disease goes into remission.

However, the use of these agents is a double-edged sword; significant toxicity can counteract their beneficial effect. The toxicity of corticosteroids is dose-dependent and even with lower doses the toxicity is minimised but not eliminated. Higher doses are associated with significant increase in the risk of death from all-causes and particularly from cardiovascular disease (del Rincón, Battafarano et al. 2014). Corticosteroids are known to cause dyslipidaemia and increase the risk of cardiovascular morbidity and mortality. Thus, second-line immunosuppressive agents are added primarily to achieve corticosteroids sparing effect. Nonetheless, second-line immunosuppressive therapy requires several weeks to months to achieve a full effect which leads to delay in reduction of corticosteroid dose to a safe level. Moreover, agents such as cyclosporine have also cardiovascular risks including hyperlipidaemia and hypertension (Murphy, Greiner et al. 2005). Consequently, immunosuppressed uveitic patients are at higher risk of developing cardiovascular diseases.

Research is always attempting to discover a safer and more effective treatment option. Statins, which are classically prescribed to reduce serum cholesterol levels and improve clinical outcomes in patients with cardiovascular disease, have been shown to have pleiotropic immunomodulatory effects in several studies. There is an increasing body of evidence with regards to the efficacy of statins as immunomodulatory agents in many in vitro and in vivo studies. In animal models of uveoretinitis statins have shown a good response and decreased score of ocular inflammatory markers. Moreover, two observational studies have shown a protective effect of statins against the development of uveitis. Given the relatively low side effect profile of statins, when compared to other immunosuppressive medications (Smeeth, Douglas et al. 2009), statins seem suitable option for treating ocular inflammatory diseases due to their immunomodulatory effect, relative safety profile and ease of administration.

If the anticipated effect of simvastatin on the daily corticosteroid dose required to control the intraocular inflammation is equivalent to its impact on disease progression in the multiple sclerosis study, the detection limit of change in mean dose of corticosteroids was set at 2.5 mg. The smallest difference that we want to detect should match the smallest effect that would be of a real practical significance. However, is a 2.5mg reduction in daily dose of prednisolone of any clinical and practical significance? (In other words) Is the effect size of simvastatin of 2.5 mg reduction is big enough to be of any clinical importance? The answer to this question comes from studies in rheumatoid arthritis which have shown that cardiovascular disease and mortality increase with increasing daily and cumulative doses of prednisolone. The study by Del Rincon and associates on a large cohort of patients with rheumatoid arthritis have shown that the exposure to corticosteroids is associated with a dose-dependent increase in death from all causes. After the threshold of 8 mg per day, the number of fatalities increases in a dose-dependent manner with a hazard ratio of 1.07 per each mg of prednisolone per day (95%CI; 1.05-1.08) (del Rincón, Battafarano et al. 2014). The previous study also reported a safe threshold for the cumulative dose of corticosteroids to be 40 gm and doses higher than 40 are associated with a significant increase in the risk of death. For example, patients on 5 mg daily prednisolone dose, would reach this threshold (40gm) in approximately 22 years whereas those exposed to 10 mg a day would be at significant risk faster (11

years). Since uveitis is a chronic disease and it is associated with systemic inflammation in 30% of cases such as, with sarcoidosis and Behcet's disease, these durations of exposure are easily reached. Therefore, as small as, a 2.5 mg reduction of daily prednisolone dose, would be clinically significant with regards to the decrease in risk of all-cause mortality and death due to cardiovascular disease. Moreover, simvastatin would offer an additional benefit by reducing the LDL cholesterol and improve the cardiovascular outcomes in patient with ocular inflammatory disease exposed to the toxic effect of immunosuppressive therapy. This chapter will examine alternative approach aiming at using simvastatin to reduce corticosteroid requirement by patients with non-infectious uveitis.

3.2 Background of statins

Statins, also known as 3-hydroxy-3-methylglutaryl coenzyme A (HMG-CoA) reductase inhibitors, have long been used for controlling blood cholesterol levels and reducing the risk of cardiovascular morbidity and mortality. While their mechanism of action in vascular disease is established, the evidence is accumulating regarding alternative immunomodulatory roles that may enhance their cardiovascular effect, as well as play a role in treating inflammatory disorders (Jain and Ridker 2005).

Statins were discovered in the early 1970s from *Penicillium citrinium* cultures (Endo, Kuroda et al. 1976). Further research showed that these molecules strongly inhibit the rate-limiting enzyme in cholesterol biosynthesis, HMG-CoA reductase, which is responsible for the conversion of HMG-CoA to L-mevalonate and finally to farnesyl pyrophosphate (FPP, is the precursor for cholesterol synthesis). Because statins have higher affinity to the binding site of this enzyme, they inhibit endogenous cholesterol synthesis (Istvan and Deisenhofer 2001). This blocking of cholesterol synthesis leads to overexpression of low-density lipoprotein (LDL) receptors on hepatocytes in the liver which leads to enhanced clearance of LDL from the circulation (Goldstein and Brown 1990) (Graaf, Richel et al. 2004).

Another product of the L-mevalonate pathway is geranylgeranylpyrophosphate (GGPP), which is synthesised from FPP. FPP and GGPP are both essential isoprenoids and serve as lipid attachments for various intracellular proteins such as

small guanosine triphosphatases (GTPases) which are thought to have an immunomodulatory effect by acting as adjuncts for different intracellular signalling processes. GTPases are critical regulators in various biological function within the cell, such as gene transcription, and adhesion. Furthermore, they serve as essential biochemicals for actin cytoskeleton which mediates a variety of essential biological functions, such as, cellular movement and division (Hall 1998).

3.3 Statin's immunomodulatory effect

While statins are commonly used for cardiovascular disease to lower blood cholesterol levels, studies have demonstrated they may have additional effect irrespective of this (Sacks, Pfeffer et al. 1996). Endothelial function studies (Jarvisalo, Toikka et al. 1999) as well as clinical trials from organ transplantation (Kobashigawa, Katznelson et al. 1995) and stroke prevention (Sever, Dahlof et al. 2004), support their additional immunomodulatory effect unrelated to lowering cholesterol (Jain and Ridker 2005).

Statin has been shown to maintain the endothelial function in coronary arteries and increase myocardial perfusion in porcine hypercholesterolemia model which was unrelated to their lipid-lowering effect (Wilson, Simari et al. 2001). They were also found to reduce the incidence of cardiac and renal graft rejection rates in patients, increase survival and lower incidence of vasculopathy after one year of pravastatin treatment, a member of statin family, (Katznelson, Wilkinson et al. 1996) (Kobashigawa, Katznelson et al. 1995). Leading to a recommendation to give cardiac transplant patient statins irrespective of their blood cholesterol levels, (Kittleson and Kobashigawa 2013) (Jain and Ridker 2005).

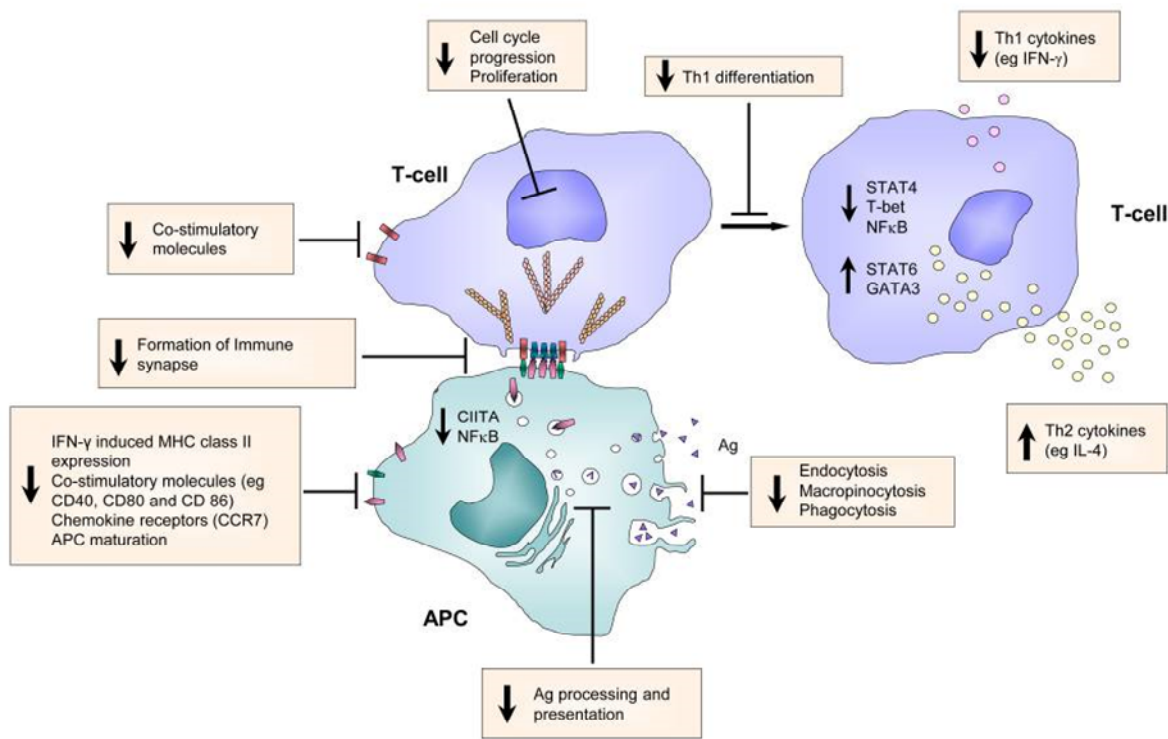
Early evidence of immune suppressive effects of statin comes from studies on C-reactive protein CRP in patients with myocardial infarction. CRP is a systemic inflammatory biomarker, and individuals with elevated serum CRP levels >3 mg/L have an increased risk of cardiovascular events. Statins resulted in a reduction of CRP levels in those patients, independently, of their cholesterol level (Musial, Undas et al. 2001, Albert, Glynn et al. 2003). This has found support in their effect in what are regarded as more classic inflammatory conditions, such as, multiple sclerosis and rheumatoid arthritis, demonstrating their role as inhibitors of the production of several

pro-inflammatory cytokines, tumour necrosis factor α (TNF α), interleukin 1 β (IL-1 β), IL-6 and IL-8 (Nagashima, Okazaki et al. 2006).

Statins have different actions on immune system. There is a mounting body of evidence regarding the efficacy of statins in suppressing the immune system in experimental autoimmune disease with exciting results. However, the influence of statin on the immune pathway and the relation to improving clinical outcome is poorly understood (Greenwood, Steinman et al. 2006).

The immunomodulatory effect of statins is exerted either directly on cells, such as interfering with T lymphocyte proliferation (Chakrabarti and Engleman 1991, Cuthbert and Lipsky 1991), inhibiting the expression of co-stimulatory molecules CD80 and CD86 on B cells (Youssef, Stuve et al. 2002). Or through inhibition of cellular interactions and signalling molecules such as tumour necrosis factor α (TNF- α) (Sadeghi, Tiglio et al. 2001), a potent pro-inflammatory cytokine that induces apoptosis of retinal cells (Robinson, Ho et al. 2011). By influencing the cytokine balance from pro-inflammatory to anti-inflammatory, statins modulate the immune response and achieve an immunosuppressive effect (Youssef, Stuve et al. 2002) (Kwak, Mulhaupt et al. 2000). Additionally, statins block the intercellular adhesion molecule 1 (ICAM1) pathway which is responsible for the interaction between the vascular endothelium and lymphocytes, therefore statins interfere with transvascular migration of lymphocytes (Yoshida, Sawada et al. 2001), thereby reducing the number of lymphocytes reaching the sites of inflammation. For a description of statin immunomodulatory pathways, please refer to figure 3-1.

Figure 3-1 effects of statins on T cells and antigen presenting cells (Greenwood, Steinman et al. 2006)



APC antigen presenting cells
 STAT4 signal transducer and activator of transcription 4
 GATA3 GATA binding protein 3
 Th2 T helper

3.4 Anti-inflammatory effect of statin at the cellular level

The cholesterol synthesis pathway and protein prenylation produce many intermediate compounds called isoprenoids which are involved in posttranslational modification of essential proteins such as, Ras Rac Rho. Statins reduce the availability of these intermediate metabolites and thus interfere with the activity of key signalling molecules necessary for immune cell function among other cells. Experiments conducted in vitro and animal models suggest that statins modulate the immune system through alterations in cell surface molecules, cellular interactions, signalling proteins and nuclear factor expression and function (Jain and Ridker 2005). Statins effect on the prenylated proteins modulates the immune pathway in several ways:

1. Statins interfere with leukocytes motility.
2. Statins interfere with antigen uptake, processing and presentation.
3. Leukocytes activation proliferation and function is affected by statin therapy. HMG-CoA reductase inhibitors interfere with T lymphocytes proliferation by blocking essential biological compounds necessary their differentiation (Chakrabarti and Engleman 1991, Cuthbert and Lipsky 1991). Statins used in experimental autoimmune uveoretinitis significantly suppressed lymphocytes proliferation and the production of INF γ , statins resulted in 77% and 87% reduction in INF γ in rats treated with atorvastatin and lovastatin, respectively in comparison to control group (Kohno, Sakai et al. 2007).

Similarly, statin administered in vivo, inhibited the induction of T helper1 cell-mediated autoimmune disease and shifted the cytokine profile of T cells from T helper 1 (pro-inflammatory) to T helper 2 (anti-inflammatory) (Youssef, Stuve et al. 2002) (Aktas, Waiczies et al. 2003, Nath, Giri et al. 2004). Nonetheless, this finding was not universal, and some studies have shown that lovastatin and simvastatin have a significant suppression on Th1 cells but no effect on Th2 cytokines (Greenwood, Steinman et al. 2006).

4. Statins inhibit the production of pro inflammatory cytokines. Pahan et al. found that in vitro treatment of macrophages and CNS resident APC (microglia and

astrocytes) with lovastatin, resulted in reduced expression of pro-inflammatory cytokines such as TNF α , INF γ , IL1 β and IL6 from macrophages and antigen presenting cells APC in vitro (Pahan, Sheikh et al. 1997). Lovastatin inhibited transcription factor T-bet (molecules present in Th1 and is a master switch for INF γ synthesis). Moreover, statins inhibition of Nuclear Factor-kB, which controls the translation of various pro-inflammatory cytokines, resulted in an anti-inflammatory effect on APC by inhibiting TNF α synthesis and induce the expression of IL-10 (Nath, Giri et al. 2004).

TNF α , a potent pro-inflammatory cytokine, has been shown to induce retinal vascular tortuosity in addition to functional and structural alterations in retinal blood vessels and structures. The most important of which was the induction of apoptosis of retinal ganglion cells, Inner nuclear layer and inner plexiform layer. A novel study demonstrated that fluvastatin counteracts the effects of TNF α in experimental rat model, where, fluvastatin showed a protective effect on retinal microvessels with reversal of retinal damage at the ganglion cell layer and also it has the ability to suppress VEGF-A expression in the retina of TNF α injected rats (Robinson, Ho et al. 2011). Similarly, simvastatin exerted a protective effect on retinal ganglion cells after ischaemia reperfusion model, and the effect is mediated by its ability to modulate apoptotic pathways (Ko, Chen et al. 2011).

Statins not only have an antiproliferative effect on lymphocytes but it also alters the function of T cells and APC. This inhibition of key pro-inflammatory molecules might benefit patients with autoimmune disease. Sing et al. have found that lovastatin inhibited mononuclear cells infiltrating the brain and it improved the clinical signs of EAE. Simvastatin, lovastatin and mevastatin inhibited in a dose-dependent manner the proliferation of peripheral blood mononuclear cells in patients with multiple sclerosis (Neuhaus, Strasser-Fuchs et al. 2002).

Statins affect the synthesis of isoprenoids and subsequently the small GTPases activity among other prenylated proteins. However, not all of these proteins are not beneficial and some can act as inhibitors of inflammation and blocking these can have an adverse effect and result in pro-inflammatory action instead. There

are reports of pro-inflammatory responses after using statins. A paradoxical effect of statin was reported where statins had upregulated the secretion of INF gamma and IL-12 production (Neuhaus, Strasser-Fuchs et al. 2002).

5. MHC Class II expression. T cells mediate many autoimmune diseases and statins were found to inhibit the expression of MHC type II molecules by APC in response to INF gamma, and stopped antigen presentation to T cells. Kawk et al. have found that atorvastatin inhibits the expression of MHC II molecules more than lovastatin and pravastatin (Kwak et al., 2000). MHC plays an essential role in the pathogenesis of autoimmune diseases such as multiple sclerosis, rheumatoid arthritis and SLE. (Bottazzo, Pujol-Borrell et al. 1983). The transactivator CIITA mediates the activation of MHC class II, and statins inhibit the inducible promotor I of the transactivator CIITA (Steimle, Siegrist et al. 1994). However, mature and professional APC are mostly unaffected by this inhibition (Greenwood, Steinman et al. 2006).

Another alternative theory is that statin may affect the expression of MHC II in a cholesterol-dependent manner via altering the integrity of cell membrane lipid structure which serves as a platform for the accumulation of signalling proteins. Simvastatin was found to disturb these microdomains and affecting their function (Kuipers, Biesta et al. 2005) (Greenwood, Steinman et al. 2006). However these data were not confirmed in vivo, and T cell content of cholesterol remained unchanged when exposed to atorvastatin (Dunn, Youssef et al. 2006).

6. The expression of co-stimulatory molecules (CD40, CD80 and DC86). These molecules are necessary for adequate T cells response and usually accompany MHC class II APC. Simvastatin and atorvastatin inhibited cytokine-induced maturation of these molecules which resulted in a marked decrease in proliferation of T cells. All of these actions are cytokine mediated. This action is particularly relevant to SLE where atorvastatin was found to inhibit the expression of MHC II and B cells expression of co-stimulatory molecules CD 80 and CD86 needed for T-cell activation (Greenwood, Steinman et al. 2006) (Sadeghi, Tiglio et al. 2001).

7. Leukocytes adhesion to vascular endothelium and transvascular migration lies at the heart of the pathogenesis of autoimmune disease. BRB normally restricts the movement of lymphocytes into the retina, while, in ocular inflammation, there is a massive increase in cellular migration across the BRB. Experimental studies have shown that increase permeability of the BRB followed lymphocytic infiltration into the retina, and the penetration occurred via the cytoplasm of endothelial cells whereas the RPE allowed for a minimal inflammatory cells infiltration despite massive infiltration to the adjacent choroid (Greenwood, Howes et al. 1994). On the contrary, the RPE cell layer was found to be involved in inflammatory cell migration into the retina via the ICAM-1 (Devine, Lightman et al. 1996).

Under inflammatory condition vascular endothelial cells express abundance of Vascular Cell Adhesion Molecule-1 (VCAM1) and Intercellular Adhesion Molecules (ICAM;CD54) which interact with Lymphocyte Function-associated Antigen (LFA1) to facilitate leucocytes movement from the bloodstream to the vessel wall, particularly, monocytes and T-lymphocytes (Male, Rahman et al. 1994) (Cybulsky and Gimbrone 1991) (Wang, Sica et al. 1991, Yla-Herttuala, Lipton et al. 1991). The integrity of BRB is compromised in ocular inflammatory disease in response to pro-inflammatory cytokines, mainly the IL-1 beta which leads to increase permeability and tissue oedema. Also, the infiltration of leukocytes into the retina leads to changes in blood vessels (Bamforth, Lightman et al. 1997).

Statins downregulate the expression of adhesion molecules on leukocytes and endothelial cells (Greenwood, Steinman et al. 2006). Numerous studies showed statin's inhibitory effect on lymphocytes migration via inhibition of Rho prenylation (Etienne, Adamson et al. 1998). A functional Rho GTPase is a critical step in transmigration of leukocytes (Adamson, Paterson et al. 1992). Because isoprenoid phosphates is one of the downstream products in mevalonic acid metabolism, (Greenwood, Walters et al. 2003), thus by blocking its synthesis, statins has been shown to alter this interaction and abort lymphocytes adhesion and activation and significantly reduce the number of

infiltrating leukocytes into the retina (Weitz-Schmidt, Welzenbach et al. 2001, Miyaki, Matsubara et al. 2009) (Aikawa, Rabkin et al. 2001) (Crisby, Nordin-Fredriksson et al. 2001). Gegg and colleagues have shown that Lovastatin suppressed leukocytes infiltration into the retina and reduced retinal vascular leakage in an acute mouse model of autoimmune retinal disease. Also, in the same study Lovastatin resulted in decrease synthesis of $\text{INF}\gamma$ and IL-10. Statins vary in their immunomodulatory effect, for example, atorvastatin appears less efficacious in retinal inflammatory disease while lovastatin demonstrated a better outcome (Gegg, Harry et al. 2005).

3.5 Statin's clinical data

Clinical studies in multiple sclerosis (MS) patients showed a positive effect from simvastatin on brain atrophy, suggesting these drugs cross the blood-brain barrier and can play a role in controlling inflammatory diseases. (Chataway, Schuerer et al. 2014) In rheumatoid arthritis, statins have a potential benefit in controlling disease activity manifesting as improvement in disease activity scores and reducing the numbers of tender and swollen joints (McCarey, McInnes et al. 2004). Ocular involvement is frequent in many systemic autoimmune conditions and statins may offer an additional treatment approach to such patients. A double-masked placebo-controlled trial of 40 mg atorvastatin in 116 patients with rheumatoid arthritis for six months showed a clinically apparent improvement in disease activity (McCarey, McInnes et al. 2004). Similar results were reported on 38 patients and for one year of follow-up by another group (Sarabi, Saeidi et al. 2016). Abud-Mendoza et al. conducted a short-term simvastatin 80 mg on three patients with SLE for eight days and found a significant reduction in proteinuria levels (Abud-Mendoza, de la Fuente et al. 2003).

3.6 Statins in uveitis

Statins have been shown to have many anti-inflammatory and immunomodulatory effects, specifically their ability to reduce key inflammatory cytokines such as IL-6, IL8 and $\text{TNF } \alpha$, as well as prevent leukocyte adhesion to vascular endothelium (Musial, Undas et al. 2001, Yoshida, Sawada et al. 2001). The role of statins has been extensively studied in a mouse model of experimental autoimmune uveoretinitis, where it was found that they reduce the clinical and histological scores of inflammation

and inhibit T lymphocyte recruitment into the retina (Kohno, Sakai et al. 2007). Treatment with statins also resulted in improved vascular stability in a rodent model of lipopolysaccharide-induced liver microvascular dysfunction (La Mura, Pasarin et al. 2013).

In a retrospective population-based study, the use of statins was found to have a protective effect on uveitis development, throughout two years (Borkar, Tham et al. 2015). The study identified 108 incident cases of uveitis with an incidence of 19% among statin users, compared to 30% in patients not treated with statins. Another study also reported a twofold reduction in the risk of ocular inflammatory disease in male patients who used statins, compared to a control group, over five years (Yunker, McGwin et al. 2013). Although these findings did not reach statistical significance, the risk reduction was higher with longer duration of statin use. These studies suggest that statins have potential benefits in patients with ocular inflammatory disease.

3.7 Why simvastatin?

Simvastatin proved useful in different areas such as brain ischemia, neurodegeneration and traumatic brain injury. This effect is mediated partly by improving microcirculation and neural protection (Leeper, Ardehali et al. 2007, Lewandowski, Sinski et al. 2010). Studies have also shown that simvastatin has better penetration of the blood-brain barrier BBB and a superior immunomodulatory effect compared to other statins (van der Most, Dolga et al. 2009).

Moreover, simvastatin has a unique ability to suppress the activity of inflammatory cells. Jameel and co-workers showed that simvastatin significantly reduced the intracellular expression of INF γ from CD4 $^{+}$ T cells in vitro, (p -value=0.01) to levels comparable to those achieved by conventional immunosuppression (dexamethasone, cyclosporine A, mycophenolate and rapamycin). Simvastatin showed an excellent inhibitory effect compared to atorvastatin and lovastatin. Nevertheless, all of these statins reduced IL17 production ($p < 0.05$) (Jameel, Ooi et al. 2013).

In an ischaemia reperfusion model of retinal injury in rat, simvastatin showed a protective effect on the retina which was mediated via the attenuation of the expression of TNF α and Nuclear Factor-KB induced by ischaemia/reperfusion and

prevented apoptosis of cells in retinal ganglion layer and inner nuclear layer (Zhang, Zhang et al. 2015). Simvastatin also upregulated the anti-apoptotic protein Bcl-2 and down-regulated the pro-apoptotic one (Bax). Therefore, simvastatin could protect retinal cells from ischaemic damage and maintain retinal integrity and function in various retinal diseases that involve inflammation and ischaemia, particularly uveitis.

A fascinating study compared the ability of three statins (simvastatin, lovastatin and pravastatin) regarding crossing blood-brain barrier and their ability to alter genes expression in mice. Simvastatin, which is lipophilic compound was able to cross the blood-brain barrier and discovered in the cerebral cortex of mice in vivo. Furthermore, when compared to lovastatin and pravastatin, simvastatin showed a most significant effect on gene expression. Simvastatin was able to alter 23 additional genes, and these genes are involved in cell growth, signalling and trafficking. Of particular importance was the expression of genes involved in apoptotic pathways, which could be a fundamental contributor to immunosuppression (Johnson-Anuna, Eckert et al. 2005). Blood-brain barrier and blood-retinal barriers demonstrated similar transport and permeation characteristics (Steuer, Jaworski et al. 2005). Therefore, simvastatin might be able to exert a local immunomodulatory effect in ocular tissue.

3.8 AIMS

The effect of simvastatin as immunosuppressive agents was assessed by measuring the reduction of daily oral corticosteroid dose required by patients with non-infectious posterior, intermediate or panuveitis uveitis at one and two years follow-up, besides, the safety and tolerability of simvastatin. We have undertaken this study to explore whether simvastatin has an anti-inflammatory effect in ocular inflammatory disease in humans, which would allow for a reduction in concomitant immunosuppressive therapy. This would be of great importance in uveitis management given the minimum side effects of statins compared to conventional immunosuppressive agents.

3.9 Hypothesis

Simvastatin can achieve a 2.5mg mean reduction in the daily amount of oral prednisolone dose in patients with sight-threatening non-infectious intermediate,

posterior and panuveitis. Also, statin will help in additional reduction/discontinuation of second-line immunosuppressive agents.

3.10 Declaration of Helsinki

The study protocol conformed to the tenets of the Declaration of Helsinki and was approved by the Ethics Committee of Bloomsbury London, UK, and local research and development department. This study was carried per Good Clinical Practice (GCP) guidelines.

3.11 Ethical approval

We obtained the ethical approval for the trial on 11 February 2015.

Study title: “Can simvastatin significantly reduce the amount of immunosuppressive medications required by patients with sight-threatening uveitis? A phase IIb, single site, randomised, placebo-controlled, double-masked trial.

REC reference: 15/LO/0084. **Protocol number:** 14/0172

EudraCT number: 2014-003119-13. **IRAS project ID:** 156966

3.12 Funding

The J P Moulton Charitable Foundation funded this study.

3.13 Methods

Simvastatin in sight-threatening uveitis is a randomised, placebo-controlled, double-masked trial in patients with intermediate, posterior and panuveitis in the UK, who require systemic prednisolone at 10 mg per day or above to control intraocular inflammation with or without a second line immunosuppressive agent. The study site is Moorfields Eye Hospital, London. The study will compare the effect of simvastatin 80mg once daily on disease control and immunosuppression treatment for two years' follow-up. Patients on standard therapy will be assigned randomly to receive either Simvastatin or Placebo (1:1). All patients were followed-up every three months for one year, and some continued for two years follow-up.

3.13.1 Inclusion and exclusion criteria

Please see Table 3-1.

Table 3-1 Simvastatin trial inclusion and exclusion criteria

Inclusion criteria
1. Patients must be >18 years and under 80 years.
2. Having non-infectious intermediate, posterior or panuveitis.
3. Patients on systemic steroids±2 nd line immunosuppressive agent.
4. The study included both sexes; however, women need proper counselling about adequate contraception.
Exclusion criteria
1. Patient without systemic disease *
2. Patients who may become pregnant or if they are breastfeeding.
3. Patients are concomitantly taking Ciclosporin, fibrates, amiodarone, amlodipine, verapamil, CYP3A4 inhibitors (itraconazole, ketoconazole), erythromycin, telithromycin, diltiazem or anticoagulants. Because these agents decrease the liver metabolism and by this, there will be a more circulating level of simvastatin and a higher risk of side effects.
4. Current use of statin
5. A family history of hereditary muscle disease.
6. Active liver disease.
7. Severe renal insufficiency.
8. Persistently elevated serum transaminases.
9. Allergy to simvastatin or placebo.
10. Lactose intolerance.
11. Active involvement in other medical trials
*Initially patients with a systemic disease were excluded from recruitment to prevent the drive of systemic disease from affecting the treatment of ocular conditions. However, since the trial medication is systemically administered is expected to have an ocular as well as systemic effect. Also, that amendment was necessary to allow us to include more patients in the trial.

3.13.2 Patient recruitment

The patient's recruitment started once the "Open to recruit letter" was obtained from the sponsor of the trial University College London (UCL) in September 2015. Trial candidates were selected from the pool of patients under the care of one consultant (SL) at Moorfields Eye Hospital. Eligibility for the trial was assessed before each clinic by going through the patient's notes for the diagnosis and daily corticosteroid dose, and patients with a dose of fewer than 10 mg per day and anterior uveitis patients or having exclusion criteria were excluded. After identifying possible recruits trial was offered for suitable patients and a patient's information sheet (PIS) was given at their clinic visit. Few days' later patients were contacted to see if they are willing to participate in the trial.

Those who accepted the trial were assessed at the Clinical Research Facility (CRF) at Moorfields Eye Hospital for the baseline visit (screening). A detailed medical history, along with recording current medications was performed to check if the patient meets eligibility criteria before a signed consent form was obtained. Initially, we had difficulty in recruiting patients for the trial, because of the negative press reports regarding statins at the time starting the trial, there was a risk of not meeting our recruitment target of 50 patients. Following a statistical approval, the sample size was amended from 50 initially to 33 patients, and this had slightly reduced the statistical power, from 90% to 80%, but this is still an accepted power for most trials.

At the baseline visit vital signs were recorded (blood pressure and pulse rate), weight and height, then the best corrected visual acuity (BCVA) was measured, slit-lamp exam, intraocular pressure check and dilated fundus examination were all performed for both eyes for each patient. An OCT scan was done to measure the central retinal thickness and document the presence of cystoid macular oedema. Finally blood tests including full blood count, blood chemistry, LFT, urea and electrolytes, cholesterol and triglyceride, and baseline CK enzyme level and urine pregnancy test in females of childbearing age. At the end of the screening visit, patients were given study numbers from 1 to 35 with an emergency contact card. The study coordinator (AJ) organised the study follow-up appointments for each patient, and patients were contacted to attend their scheduled study visits.

3.13.3 Randomisation

An online software package (Sealed Envelopes) was used for the randomisation process. The study coordinator entered the trial number, and an allocated treatment code was generated after confirming that the patient meets all the inclusion criteria and does not meet any of the exclusion criteria. The code generated corresponds to a list of codes in the pharmacy and depending on the code the trial pharmacist dispenses either simvastatin tablets or placebo (identical dummy tablets).

3.13.4 Follow-up visits

Follow-up visits were conducted every three months +/- two weeks as per the trial protocol. There was a total of 9 visits for each patient throughout the two-year follow-up period. In the subsequent visits, patients were specifically asked regarding any symptoms of myopathy such as muscle and joint pain and signs of neuropathy and whether or not there was any health issues, especially hospitalisations. All adverse events were recorded at each visit in patient's notes and were logged in the adverse events log and the Case Report Form (CRF) and trial master file. Serious adverse events were reported to the sponsor within 24 hours of site notification.

The concomitant medications were reviewed and recorded with their doses in the patient's treatment records. Patients hand in their trial medication which was counted by a dedicated pharmacist to check for drug compliance. At each visit, BCVA was recorded for each eye separately and then dilating drops were installed before sending patients for Spectralis OCT scan. Shortly afterwards patients were called into the clinic for slit lamp examination to assess the ocular inflammatory status and record the degree of inflammation based on the SUN criteria. Also, treatment would be adjusted based on the level of ocular inflammation or side-effect. Finally, a new IMP would be prescribed and given to the patient.

A blood test request was made at each follow-up visit, and these include full blood count, blood chemistry and electrolytes, Liver enzymes, blood urea and creatinine, serum lipids and cholesterol and CK enzyme level. Also, a urine test for pregnancy was performed for all females in child-bearing age group. All were documented at each

visit in case report forms, and special attention was made for CK level and renal function tests to monitor for any signs of rhabdomyolysis.

3.14 Statistical analysis

Our analysis falls in the category of the two-sample *t*-test, and in our sample size calculation, the minimum change of 2.5 mg corticosteroids daily was set a difference between the two groups. Previous data in MS patients has demonstrated that simvastatin has achieved a 43% improvement in disease control and the rate of brain atrophy. If this translates into a reduction in the corticosteroid dose at 12 months follow-up the difference between the two groups needs to be at least 2.5 mg to be detectable. A 2.5mg difference between the two groups is regarded clinically significant at 12 months follow-up. The standard deviation of the reduction in the corticosteroids dose estimated to be 2.5 mg using a two-sided 5% significance level and 80% power. It is calculated that 16 patients per arm are required. To allow for a possible 10% drop out, a total sample size of 36 patients was required.

The power calculation of the study was based on expert opinion of minimal reduction of 2.5 mg of corticosteroid with 2.5 mg SD. Finally, the power to be achieved initially was 90% was based on 50 subjects with 25 in each arm placebo and active. However getting patients into the trial was challenging. Therefore, we have settled for 80% power based on 36 patients. The statistical package used to obtain the required sample size was Stata (version 13.1).

3.15 Primary outcome analysis

The full analysis population included all subjects who met the study eligibility criteria and were subsequently randomised to one of the two groups. All patients were included in this analysis regardless as to whether they were compliant with the treatment or have been withdrawn from the trial for whatever reason. Therefore, the analysis was an intention to treat analysis. The analysis was adjusted for variables include disease duration before randomisation and baseline corticosteroid dose.

The primary outcome is the reduction in the amount of prednisolone dose at 12 months. The analysis was performed using the Mann-Whitney U test, followed by linear regression analysis to take into account other potential confounding factors such

as disease duration before randomisation. A non-parametric test was used (Mann-Whitney test to compare the reduction in mean prednisolone dose between the two groups).

Descriptive summaries of the primary outcome were produced. This was restricted to patients without missing measurements at baseline and 12 months. Continuous variables were summarized based on their distribution. Those approximate normal distribution were presented by mean SD and range. Those where non-normally distributed were presented in median, interquartile range and data range. Normality was assessed using graphical methods, histograms and normal probability plots. Categorical variables are summarized by the frequency of patients in each category and the percentage of patient in each category with each treatment group.

3.15.1 Outcome measures

The primary outcome is prednisolone dose measured at 12 months. Table 3-2. The primary statistical analyses will estimate the difference in mean prednisolone dose between patients randomised to simvastatin and placebo by intention to treat at 12 months. Group difference estimates and corresponding confidence intervals will be reported.

Initially, prednisolone dose at 12 months will be described for each treatment group using means and standard deviations. Also, plots will be produced that show dosing over time (every three months) for each group and the percentage of patients whose dose is under 10mg (safe dose).

Table 3-2 Primary and secondary endpoints for simvastatin trial.

Primary end-point:
1. Mean reduction in prednisolone achieved at one-year follow-up visit is
Secondary End-points:
1. Mean reduction in prednisolone achieved at two years follow up visit is.
2. Number and doses of second-line agents by the end of two years.
3. The number of disease relapses by the end of two years.
4. Blood cholesterol and lipid levels at 24 months as compared to baseline.
5. Safety and tolerability of simvastatin.

3.16 Analysis of secondary outcomes

There are four secondary outcomes

1. Dose at 24 months: This will be analysed using the same approach as that used to analyse the primary outcome.
2. Immunosuppressive agents by 24 months: This will be analysed using a chi-squared test. The use of survival analysis (e.g. time to reduction) will also be considered.
3. Disease relapses by 24 months: This will be analysed using a chi-squared test.
4. Blood cholesterol and lipids at 24 months: This will analysed descriptively.

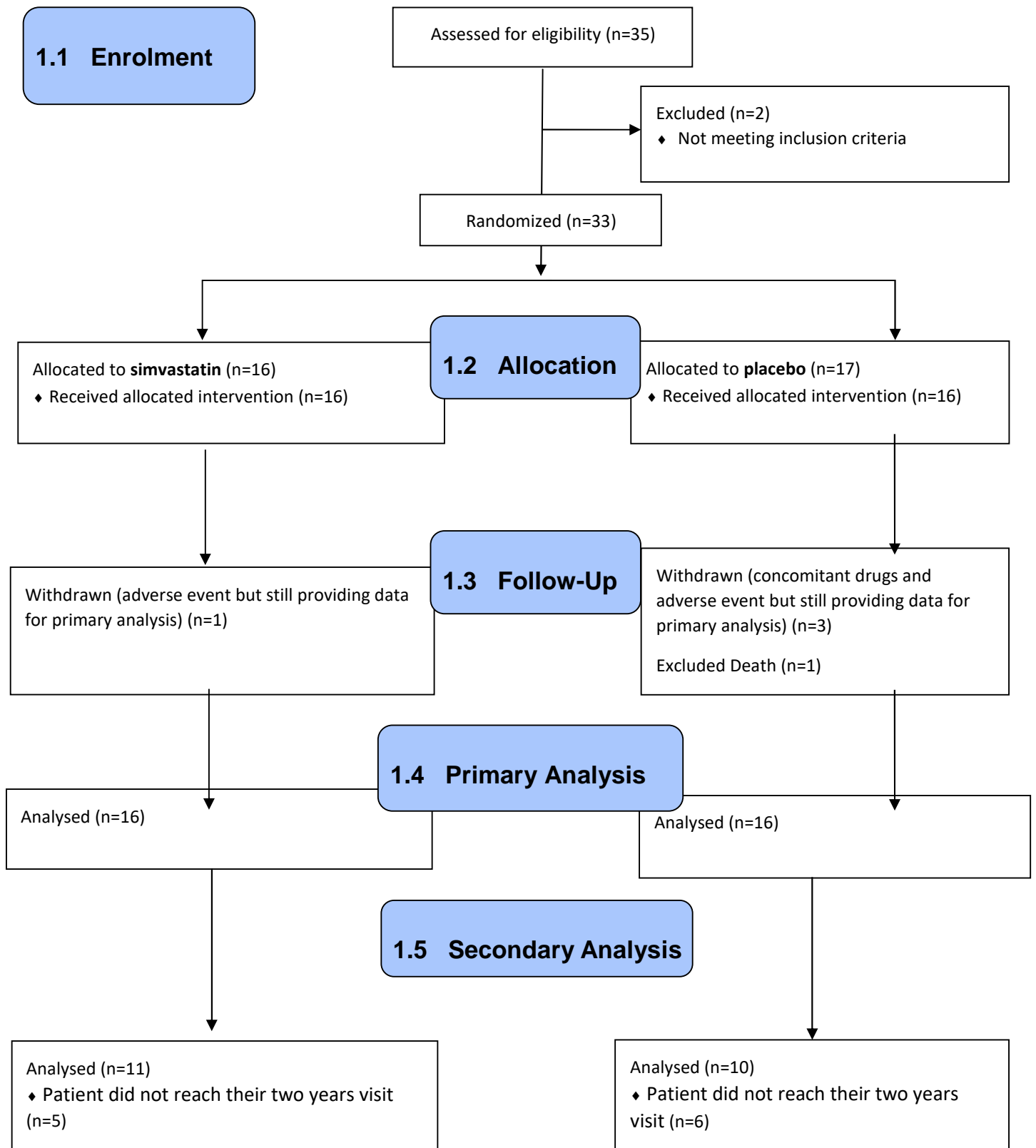
3.17 3.4 Exploratory analyses

Visual characteristics were recorded every three months. Changes in visual acuity over time will be described.

3.18 Results

Outline of the study follows in accordance with CONSORT flow diagram. From September 2015 till July 2018, 35 patients were screened for the trial, and 32 were analysed.

CONSORT Flow Diagram



3.18.1 Patients demographics and baseline characteristics

In total, 35 patients were screened of which 33 were randomized to one of the two trial arms. Sixteen were randomised to simvastatin group, and 17 were randomised to the placebo group. All of the patients received allocated interventions. One patient in the placebo group died due to a sickle cell crisis before the primary endpoint and therefore was excluded from the analysis. One patient in the simvastatin group withdrew from the study due to an adverse event however still provided data for primary analysis. Three patients in the placebo group were withdrawn from the study, one due to a concomitant drug that was exclusion criteria, the other two patients were due to adverse reactions but provided data for the primary analysis. Therefore, the intention-to-treat (ITT) analysis was performed for the primary outcome. For secondary outcome, five patients and six patients were excluded from simvastatin and placebo group, respectively (did not reach their secondary endpoint).

A total of 32 patients were analysed in this study. An equal number of patients were present in both groups, 16 patients in the placebo and 16 in the simvastatin group. The majority of patients were female (20 patients, 62.5%) and 12 were males (37.5%), there were equal numbers of males and females in each group (10 females and six males). Twenty-eight patients (87.5%) had bilateral disease at presentation. 14 patients (43.75%) intermediate uveitis, 12 patients (37.5%) had panuveitis, and six patients (18.75%) posterior uveitis. The mean age at the time of study entry for all patients was 46.92 ± 1.71 (SEM) (range 27- 67 years). For the placebo group, mean age at study entry was 48.86 ± 2.81 , median 45.23 (range 27-67 years), while for the simvastatin group the mean age at study entry was 44.98 ± 1.92 , median age 45.51 (range 30.75-58.43). There was no statistically significant difference in age at first study visit between the two groups (p-value = 0.26; 95% CI -3.08-10.84, two samples t-test, two-sided). Characteristics of the study population at presentation are summarised in Table 3-3.

Table 3-3 Baseline characteristics for patients in simvastatin and placebo group

Baseline criteria	Simvastatin	Placebo	P-value
Age (years) Mean ± SEM	44.98±1.92	48.86±2.81	0.26 Independent sample t-test
Ethnicity, n (%)	White British 9 (56.25) Black 4 (25) Asian 3 (18.75)	White British 10 (62.5) Black 4 (25) Asian 2 (12.5)	0.88 Chi- Square
Gender, n (%)	10 females (62.5) 6 males (37.5)	10 females (62.5) 6 males (37.5)	1.0 Chi-Square test
Duration of uveitis (years)	7.22 ±1.20	11.26 ± 2.32	0.13 two sample t test
Laterality, n (%)	Unilateral 3 (18.75) Bilateral 13 (81.25)	Unilateral 1 (6.25) Bilateral 15 (93.75)	0.60 Fishers Exact
Anatomical location, n (%) Intermediate uveitis Posterior uveitis Panuveitis	8 (50) 3 (18.75) 5 (31.25)	6 (37.5) 3 (18.75) 7 (43.75)	0.73 Chi- Square test
Associated systemic disease, n (%)	No 9 (56.25) Yes 7 (43.75)	No 13 (81.25) Yes 3 (18.75)	0.25 Fisher's Exact test
Prednisolone dose Mean±SEM	15.0±2.17	16.71±2.36	0.50 Mann Whitney U test
BCVA (LogMAR) Mean±SEM	0.40±0.09	0.44±0.10	0.89, Mann- Whitney U test

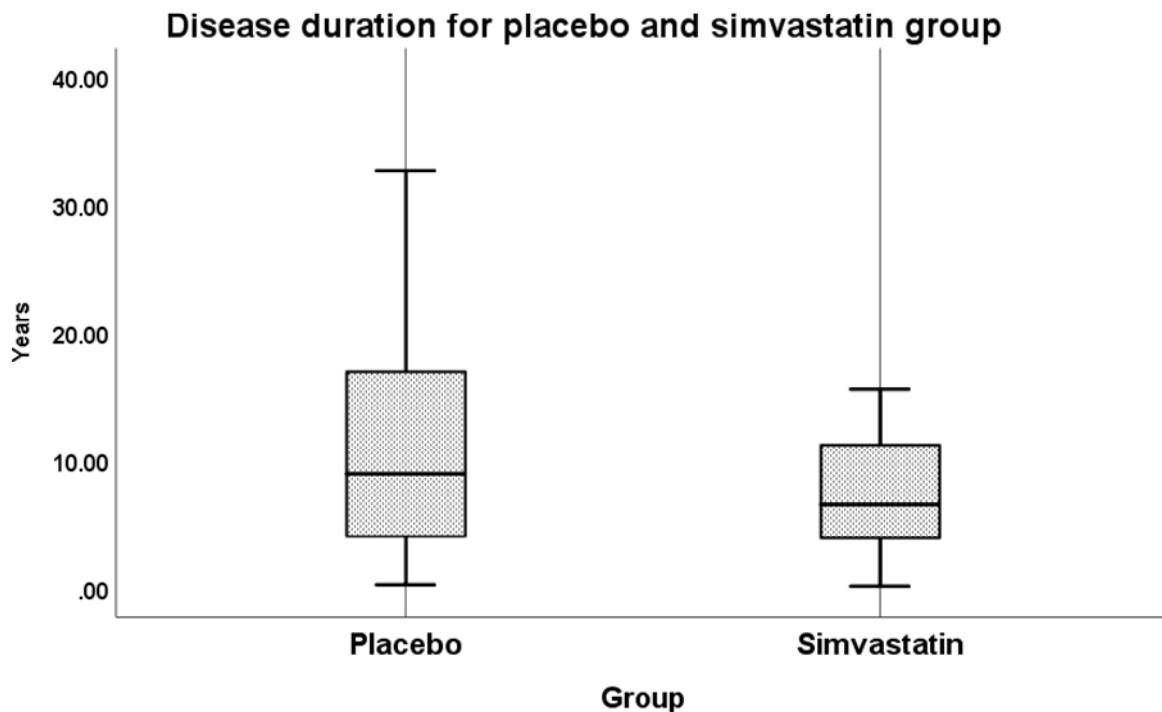
The most common disease aetiology in this study was idiopathic intermediate uveitis 12 patients (37.5%), followed by idiopathic panuveitis eight patients (25%). Other disease aetiologies are listed in Table 3-4. The baseline characteristics are generally balanced for the simvastatin and placebo groups. The disease duration is higher for the placebo group because two patients in the placebo group reported disease duration greater than 20 years and one patient who reported disease duration greater than 30 years.

Table 3-4 Underlying diagnoses for patients on simvastatin and placebo

Underlying diagnosis	Simvastatin	Placebo
HLA-B27 arthritis*, n (%)	2 (12.5)	0
Sarcoidosis, n (%)	1 (6.25)	1 (6.25)
Idiopathic panuveitis, n (%)	3 (18.75)	5 (31.25)
Idiopathic intermediate uveitis (Pars planitis), n (%)	5 (31.25)	6 (37.5)
Behcet's disease, n (%)	0	1 (6.25)
**ANCA +VE occlusive Retinal vasculitis, n (%)	1 (6.25)	1 (6.25)
Acute multifocal placoid pigment epitheliopathy, n (%)	0	1 (6.25)
Idiopathic inflammatory disc swelling, n (%)	0	1 (6.25)
Serpiginous choroiditis, n (%)	1 (6.25)	0
Punctate inner choroidopathy (PIC) disease, n (%)	2 (12.5)	0
Multiple Sclerosis (MS) related intermediate uveitis, n (%)	1 (6.25)	0
*HLA Human leukocyte antigen **ANCA antineutrophil cytoplasmic antibody (+ve) Positive		

At first presentation, the mean disease duration for all the study population was 8.49 ± 1.12 years, median 6.72 years, (range 0.15 - 24.27 years). The mean disease duration for the placebo group was 9.90± 1.8 SEM years; (95%CI 5.92 – 13.89), median 8.94 (range 0.27-24.27), whereas for the simvastatin group the mean disease duration was 7.07; (95%CI 4.48-9.66), median 5.70 (range 0.15-15.58). There was no significant difference in disease duration between the two groups (p-value =0.21; 95%CI -1.71- 7.83, two sample t-test, two-sided). Figure 3-2.

Figure 3-2 Disease duration at baseline for patients in both treatment groups. Although patients on placebo had longer disease duration, there was no statistically significant difference between the two groups (p-value =0.21, two sample t-test, two-sided).



For the all the study group mean body weight at baseline was 92.2 ± 3.46 . For the simvastatin group; the mean weight was 93.24 ± 5.48 kg and at one year 92.75 ± 5.41 . There was no statically significant difference between baseline and one-year follow-up visit, ($p= 0.68$ value; 95%CI -2.00 - 2.98, paired sample t-test, two-sided). The mean body weight for the placebo group at baseline was 91.19 ± 4.41 , by one-year follow-up the mean body weight was 90.99 ± 4.19 . Similarly, there was no significant difference between baseline and one-year follow-up (p -value =0.86; 95%CI -2.21-2.61, paired sample t-test. Between groups at one-year, there was no significant difference between the two treatment groups (p -value= 0.79, independent sample t-test, two-sided).

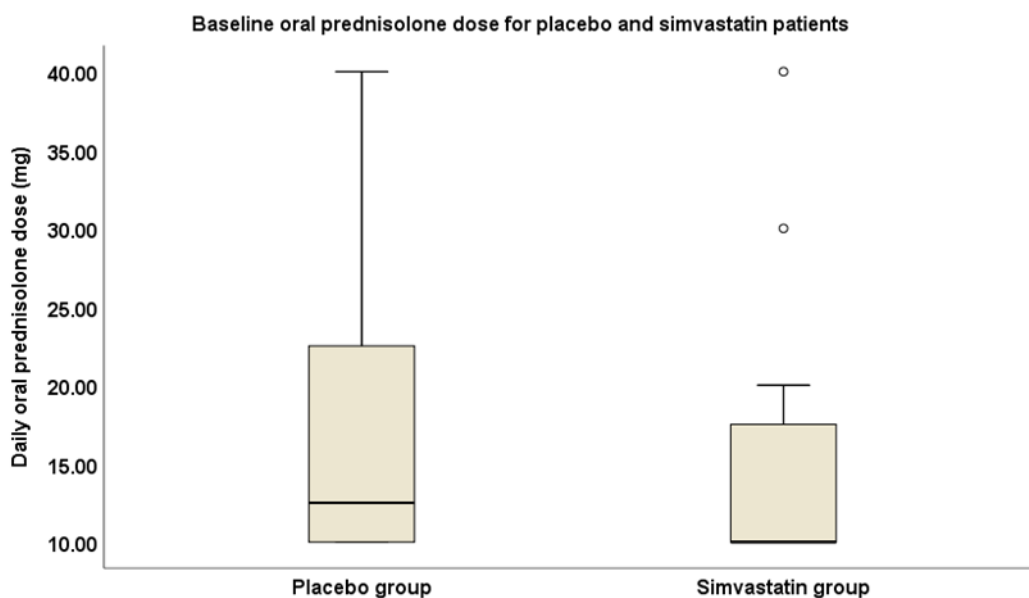
For all patients in the study, the mean systolic blood pressure at baseline was 130.2 ± 2.52 mmHg and the diastolic blood pressure was 82.25 ± 1.67 . For the simvastatin arm, the mean systolic blood pressure at baseline 131.56 ± 3.40 , and at one year 125.06 ± 3.29 , (p -value =0.19; CI -3.72-16.72, paired sample t-test, two-sided), while diastolic

pressure at baseline 83.87 ± 2.07 , and at one year 79.93 ± 2.07 , (p -value=0.10; 95%CI -0.95-8.83, paired t-test, two-sided). There was no significant difference in mean systolic and diastolic blood pressure for the simvastatin group at one-year. For the placebo group, the mean systolic blood pressure at baseline was 128.87 ± 3.80 , and diastolic blood pressure was 80.62 ± 2.63 . At one year follow-up, the mean systolic blood pressure was 127.93 ± 3.90 , and diastolic blood pressure was 79.25 ± 2.05 . Likewise, there was no statistically significant difference for systolic and diastolic blood pressure at one-year compared to baseline, (p -value 0.82;95%CI -7.79-9.66, paired t-test, two-sided) and (p -value= 0.62; 95%CI -4.41-7.16, paired t-test, two-sided) for the systolic and diastolic blood pressure, respectively.

3.19 Primary outcome analysis

The number of patients included in the primary analysis was 32 (16 from each arm). The mean prednisolone dose at baseline was 15 mg (SD 8.7), range 10 – 40 mg, the median was 10 mg for patients in the simvastatin group and 16.7mg (SD 9.5), median 12.5, range 10-40 mg for patients in placebo group. There was no statistically significant difference with regards to daily oral prednisolone dose between the two groups, (p -value 0.50) Mann-Whitney U test, two-sided). Figure 3-3.

Figure 3-3 Baseline oral prednisolone dose between the placebo and the simvastatin group. There was no statistically significant difference with regards to daily oral prednisolone dose between the two groups, (p -value= 0.50, Mann-Whitney U test two-sided).



Also, during all other follow-up visits, there was no statistically significant difference between the two arms. Table 3-5.

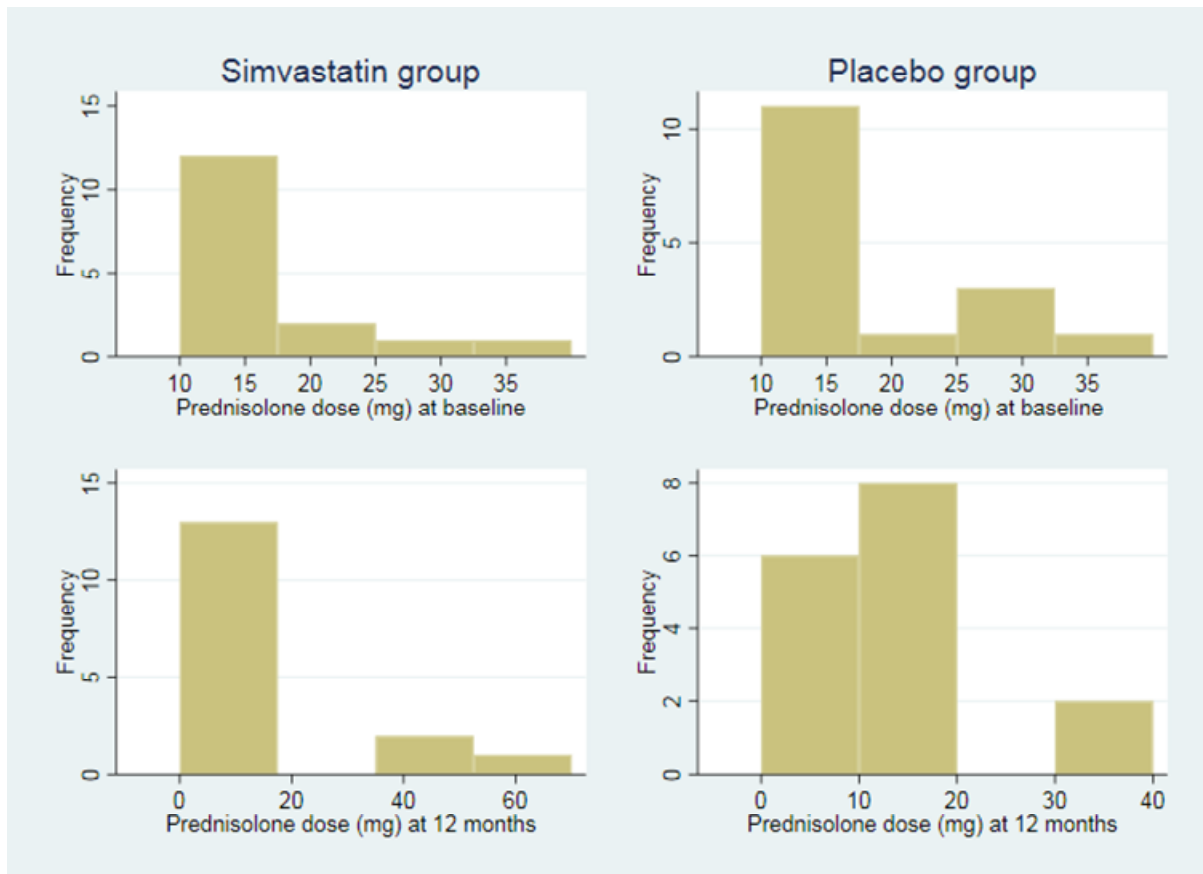
Table 3-5 Mean prednisolone dose at baseline and study follow-up visits shows no significant difference between the two study arms (p-value> 0.05, Mann Whitney U test).

Mean prednisolone dose					
Week	GROUP	Mean	± (SD) Std. Deviation	N	P-value Mann- Whitney
0	Placebo	16.71	9.47	16	0.50
	Simvastatin	15.00	8.70	16	
	Total	15.85	8.99	32	
12	Placebo	15.84	11.37	16	0.25
	Simvastatin	12.65	10.93	16	
	Total	14.25	11.09	32	
24	Placebo	20.09	23.57	16	0.64
	Simvastatin	16.09	16.32	16	
	Total	18.09	20.05	32	
38	Placebo	14.09	17.87	16	0.65
	Simvastatin	8.75	3.97	16	
	Total	11.42	13.02	32	
52	Placebo	12.39	11.16	16	0.75
	Simvastatin	16.15	19.58	16	
	Total	14.27	15.79	32	

The mean prednisolone dose at 12 months was 16.2 mg (SD 19.6) for patients in the simvastatin group and 12.4 mg (SD 11.2) for patients in the placebo group. The histogram for the mean prednisolone dose at baseline and 12 months for both groups is displayed in Figure 3-4. In Figure 3-4, the two plots on the left side present the distribution of prednisolone dose at baseline and 12 months, respectively, for simvastatin group; the two plots on the right side present the distribution of prednisolone dose at baseline and 12 months, respectively, for the placebo group. It

can be seen from the plot that the dose range for most of the patients included in the trial is 0-20 mg.

Figure 3-4 Distribution of prednisolone dose at baseline and 12 months



The number of patients on 10 mg daily prednisolone and above were 16 in each arm (100%) (Study inclusion criteria). By three months the percentage of patients still on 10 mg prednisolone and above decreased to 62.5% (10 patients) in the placebo group and 56.3 % (9 patients) in the simvastatin group, but was not statistically significant, (p-value =0.71, Chi-Square test). By six months, there were equal numbers in both groups of patients' receiving ≥ 10 mg prednisolone, (62.5%, ten patients) (p-value=1.0, Chi-Square test). By nine months the proportion of patients on 10 mg prednisolone and above was (56.3%, nine patients) and (62.5%, ten patients) in the placebo and simvastatin arms respectively, (p-value 0.71, Chi-Square test). At the one-year follow-up visit, these figures were 62.5% in the placebo and 50% in the simvastatin arm (p-value=0.47, Chi-Square test, two-sided).

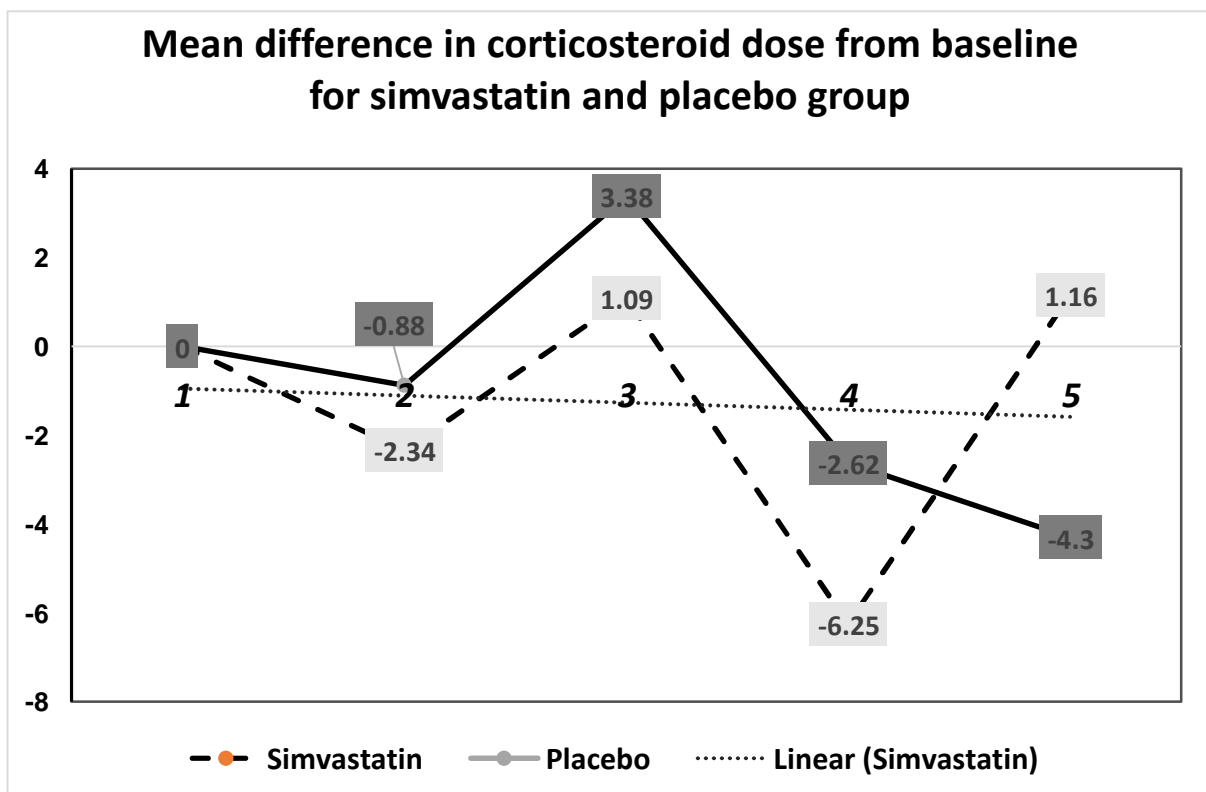
The mean differences of oral prednisolone from baseline were calculated for placebo and simvastatin group. There was a trend of reduction in daily oral prednisolone dose in the simvastatin group, but it was not significant. Table 3-6 and Figure 3-5.

Table 3-6 Mean difference of prednisolone dose for simvastatin and placebo group during first-year follow-up.

Group	*Mean difference At visit 2 (SD)	*Mean difference At visit 3 (SD)	*Mean difference At visit 4 (SD)	*Mean difference At visit 5 (SD)
Simvastatin	-2.34 10.62	1.09 16.7	-6.25 8.11	1.16 20.7
Placebo	-0.88 11.80	3.38 19	-2.62 21.31	-4.3 16.5

(*) mean difference from baseline visit
(SD) Standard Deviation

Figure 3-5 (0) Represents the baseline value (1) Baseline (2) Three months visit (3) six months visit(4) nine months visit (5) one year



Changes in oral corticosteroids dose over time between the two groups was calculated using repeated measure ANOVA. There was no significant difference between the placebo and simvastatin arm at all the time points (baseline, 3, 6, 9 and 12 months), (p-value 0.47, F value, 0.51). Although the mean prednisolone dose at 3, 6 and nine months visits was less in the simvastatin group compared to the placebo group, it was not statistically significant.

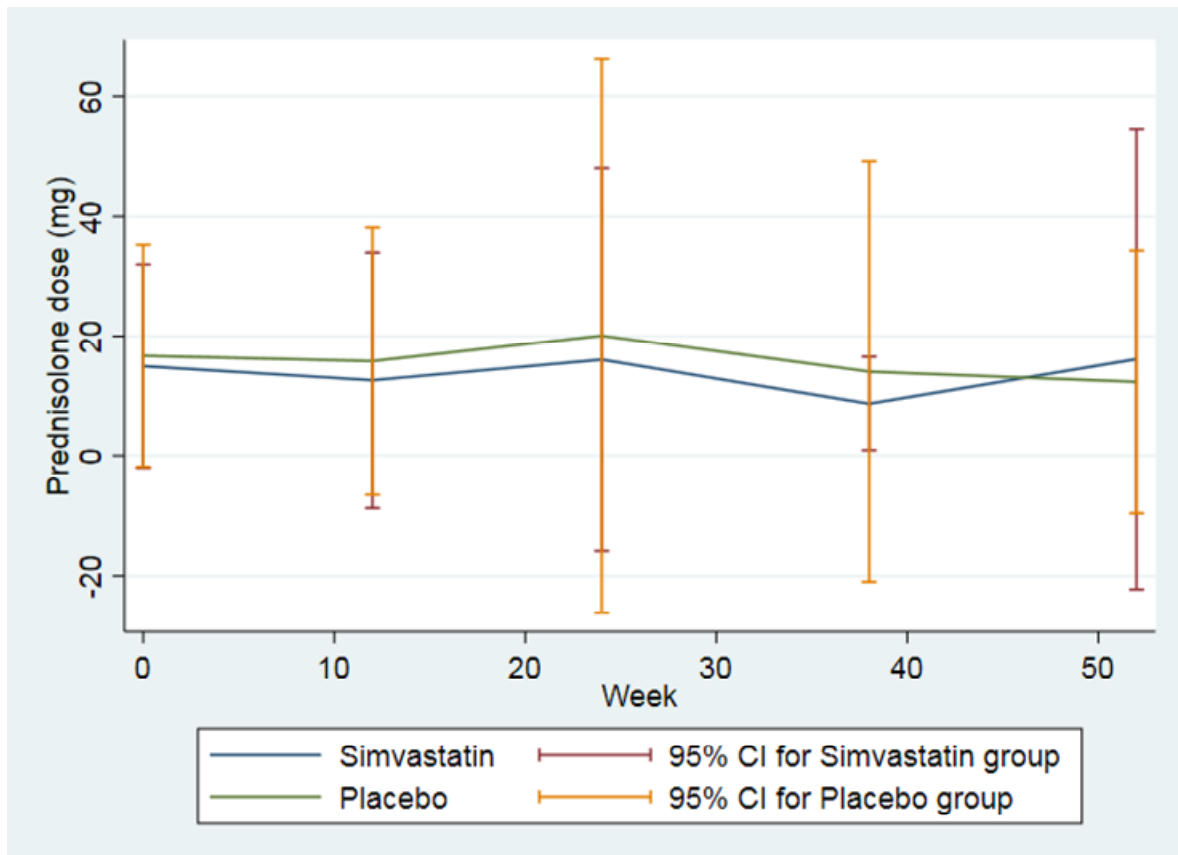
The mean prednisolone dose at 12 months was 16.2 mg \pm 19.6 SD for patients in the simvastatin group and 12.4 mg \pm 11.2 SD for patients in the placebo group. The mean dose then decreased to below 8 mg at 104 weeks for both groups. The trend for prednisolone dose at each study visit (every three months) and the percentages and the number of patients whose dose is below 10 mg per day (safe dose) for both groups from baseline to 104 weeks are displayed Table 3-7.

Table 3-7 Trend in prednisolone dose and the percentage of patients whose dose is below 10mg over 12 months by treatment group

Week	Mean dose (SD), mg		Number (percentage) of patients whose dose is below 10mg (%), N=16	
	Simvastatin	Placebo	Simvastatin	Placebo
0	15 (8.7)	16.7 (9.5)	0	0
12	12.7 (10.9)	15.8 (11.4)	7 (43.8)	6 (37.5)
24	16.1 (16.3)	20.1 (23.6)	6 (37.5)	6 (37.5)
38	8.8 (4.0)	14.1 (17.9)	6 (37.5)	7 (43.8)
52	16.2 (19.6)	12.4 (11.2)	8 (50)	6 (37.5)
104*	7.7 (6.2)	7.8 (2.5)	5 (45.5)	5 (50)
*Please note that at 104 weeks, the total number of patients is 11 and 10 for simvastatin and placebo group, respectively				

The trend of prednisolone dose every three months is graphically shown in Figure 3-6, which reflects the figures in Table 3-7. The 95% confidence interval is wide given the heterogeneity of the data.

Figure 3-6 Mean dose for simvastatin and placebo group from baseline up to 52 weeks. There was no significant difference between the two study arms.



At baseline, no patient reported having the safety dose whereas at 52 weeks, the percentage increased to 50% and 37.5% for the simvastatin and placebo group, respectively Figure 3-7.

The scatter plot of prednisolone dose at 12 months versus baseline is shown in Figure 3-8. Points above the dashed line indicate patients who have a higher dose at 12 months compared with baseline dose whereas points below the dashed line indicate patients who have a lower dose at 12 months compared with baseline dose. It can be seen from the plot that most of the patients have a lower prednisolone dose at 12 months compared with baseline.

Figure 3-7. Percentage of patients with prednisolone dose below 10mg (safety dose). There was no significant difference in proportion of patients on less than 10 mg prednisolone daily between the two groups at 3,6,9, and 12 months. (0) represents baseline where all patients were ≥ 10 mg and above (study inclusion criteria)

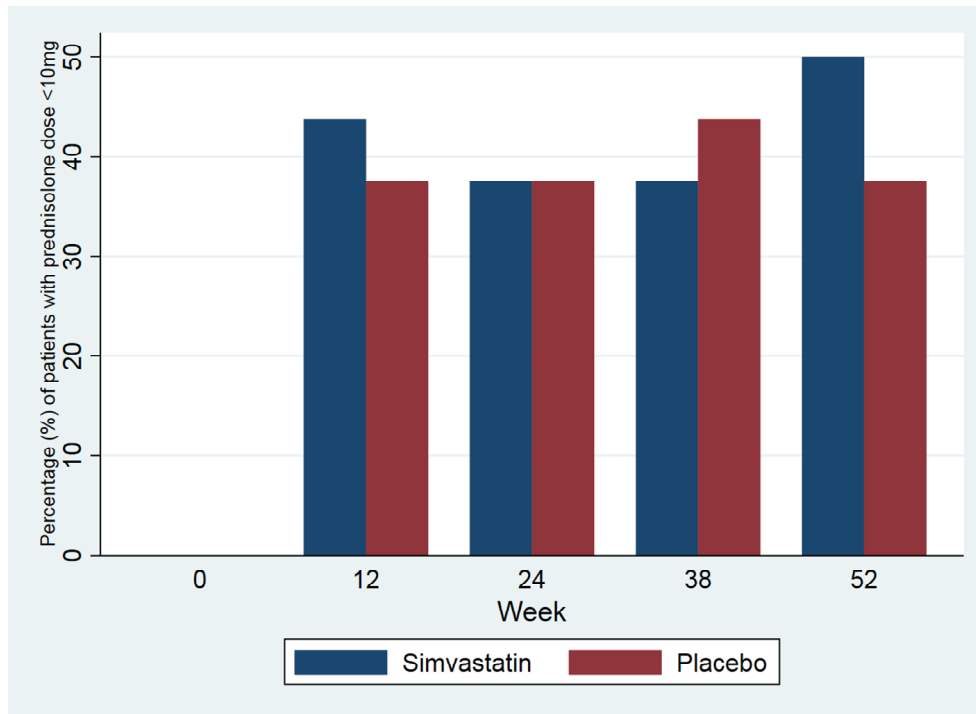
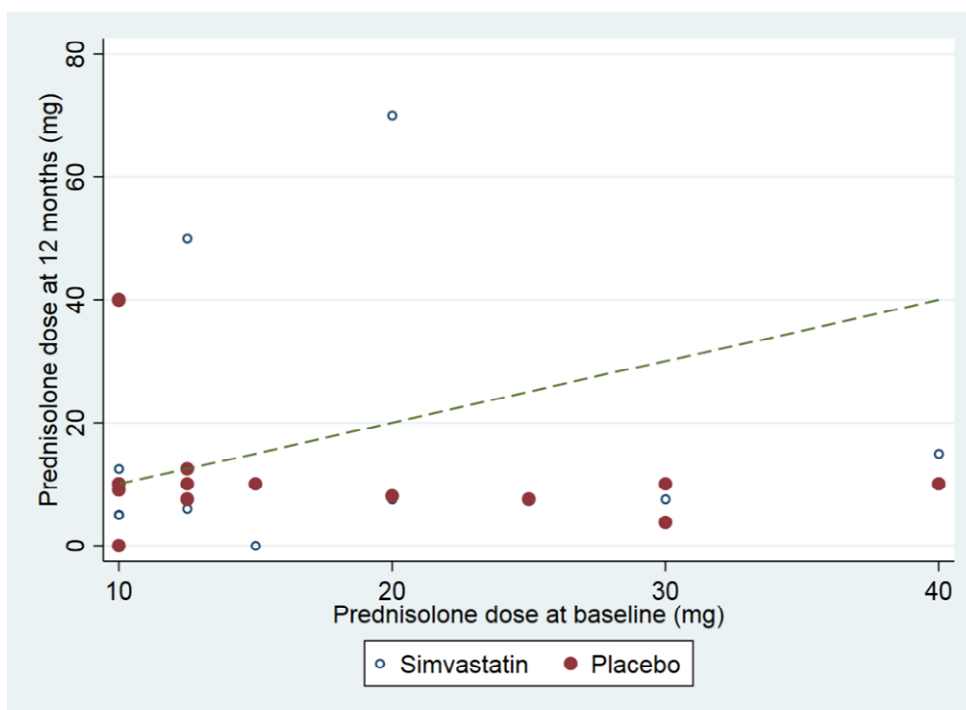


Figure 3-8. Scatter plot of prednisolone dose at 12 months versus baseline. At one year the majority of patients in the study have had their prednisolone dose reduced below 10 mg per day.



The regression analysis adjusted for baseline dose suggests no significant difference at 12 months, i.e. patients in simvastatin group have higher prednisolone dose, and the mean difference is 3.62mg (95% CI: -8.15 to 15.38) with a p-value of 0.54. Table 3-8.

Table 3-8 Regression analysis for primary outcome

Variable	Estimates	95% Confidence Interval (CI)	P-value
Simvastatin group	3.62	(-8.15, 15.38)	0.54
Baseline dose	-0.09	(-0.75, 0.58)	0.79

Adjusted analysis

The analysis further adjusted for disease duration (there is an indication of imbalance between the simvastatin and placebo group) shows similar results, i.e. the mean prednisolone dose was higher in simvastatin group (3.74mg, 95% CI: -8.89 to 16.38, P=0.55).

Subgroup analysis for patients with ocular disease only and those with ocular and systemic disease

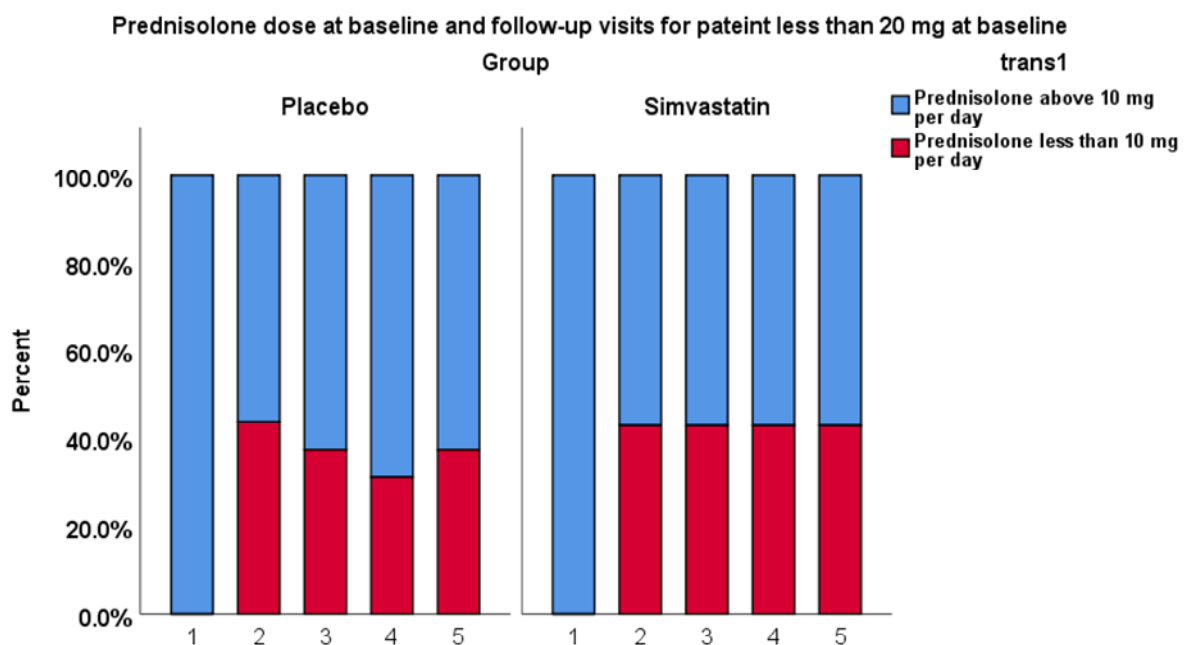
Analysing only patients with ocular disease, total of 22, (13 in the placebo and 9 in the simvastatin groups), shows no statistically significant difference in mean prednisolone dose at one-year follow-up (p-value 0.49, Mann Whitney U test, two-sided). Similarly, there was no significant difference between patients with a systemic and ocular disease (p-value = 1.0, Mann Whitney U test, two-sided). Similarly, examining only patients on simvastatin (those with and without systemic association were 7 and 9, respectively, shows no significant difference at 1-year follow-up, (p-value=0.39, Mann Whitney U, two-sided test).

Subgroup analysis for patients only under 20 mg prednisolone daily at baseline

A total of 23 patients were included in the analysis. By three months those still on 10 mg prednisolone and above were nine patients (56.25%) in the placebo group and four patients (57.1%) in simvastatin group, (p-value =1.0, Fisher's Exact test). By six months the figures were 62.5% and 57.1% in placebo and simvastatin group

respectively, (p-value =1.0, Fisher's Exact test). At nine months these proportions were 68.8% for the placebo group and 57.1% for simvastatin group (p-value =0.65, Fisher's Exact test) and by one year it was 62.5% and 57.1% for the placebo and simvastatin group respectively, (p-value =1.0, Fisher's Exact test). Figure 3-9.

Figure 3-9 Prednisolone analysis for patients with less than 20 mg at the initial study visit shows no significant difference in proportion of patients on less than 10 mg per day prednisolone at all follow-up visits between the two study arms.



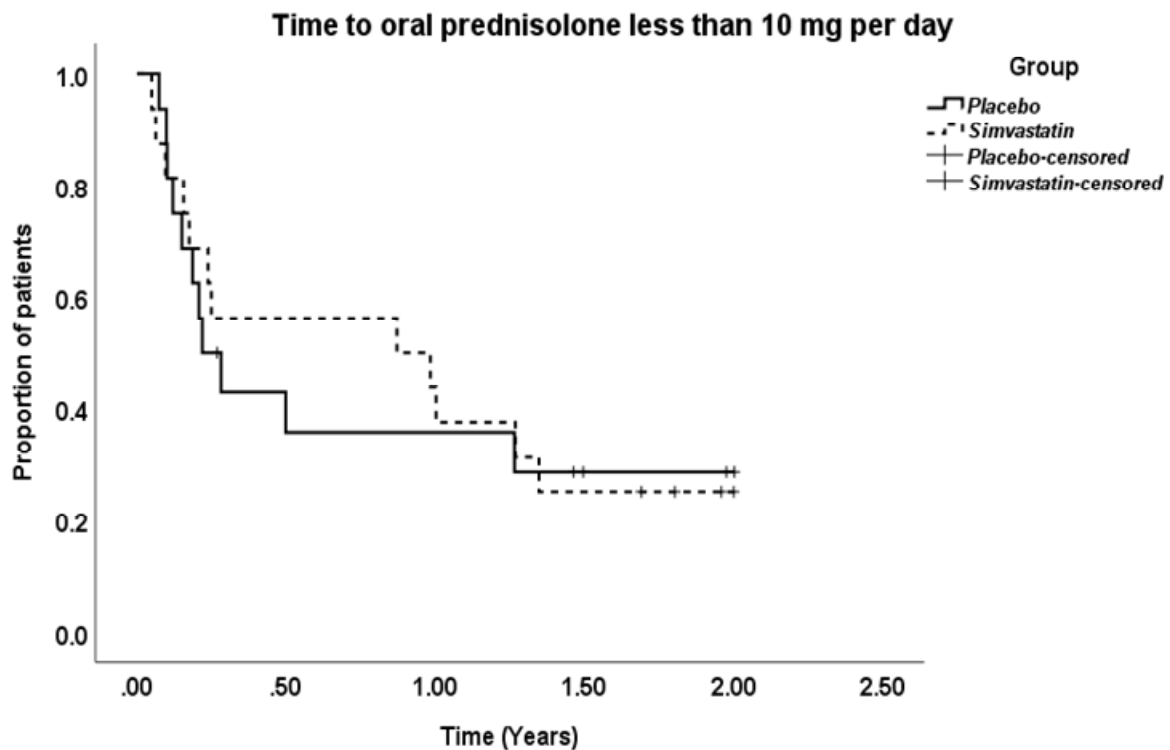
3.19.1 Time to prednisolone <10 mg per day

For all study population, the mean time to prednisolone dose less than 10 mg was 0.85 ± 0.14 SEM years; 95%CI 0.57-1.12, median time 0.28 ± 0.42 SEM years; 95%CI 0.0-1.12.

For the placebo group, mean time to prednisolone dose less than 10 mg per day was 0.79 ± 0.21 (SEM) years; 95% CI for the mean is 0.37-1.20, median time was 0.21 ± 0.06 ; 95%CI 0.08-0.35, and for the simvastatin group, the mean time was 0.90 ± 0.19 years; 95%CI 0.53-1.27, median time 0.87 ± 0.73 ; 95% CI 0.0-2.31. There was no significant difference between the two groups with regards to time to daily

prednisolone dose below 10 mg. Cox regression analysis showed a hazard ratio of 0.93, (p-value = 0.87; 95%CI 0.41-2.12), (P-value = 0.87, Log-Rank test). Figure 3-10.

Figure 3-10 Time to prednisolone dose less than 10 mg per day for simvastatin and placebo group. There was no significant difference between the two groups with regards to time to daily prednisolone dose below 10 mg (p-value = 0.87, Log-Rank test).



3.20 Secondary analysis

3.20.1 1. Prednisolone dose at 24 months

The number of patients included in the secondary analysis is 11 and 10 for simvastatin and placebo group, respectively. The results from the regression analysis suggest that there is little difference in mean prednisolone dose between the groups at 24 months (difference: -0.3 (Simvastatin.-Placebo.) 95% CI: -4.7 to 4.0, P = 0.87). Table 3-9.

Table 3-9 Regression analysis for secondary outcome

Variable	Estimates	95% Confidence Interval (CI)	P-value
Simvastatin group	-0.34	(-4.71, 4.03)	0.87
Baseline dose	-0.13	(-0.35, 0.09)	0.24

The regression analysis adjusted for baseline dose suggests that at 24 months, patients in the simvastatin group have lower prednisolone dose and the mean difference is 0.34mg. However, this is not statistically significant ($p>0.05$).

3.20.2 2. Reduction in 2nd line immunosuppressive agents by 24 months

At baseline 16 patients (50%) were receiving oral prednisolone only (9 and 7 in placebo and simvastatin arm, respectively). The other 50% had a second-line immunosuppressive agent in addition to corticosteroid. Mycophenolate mofetil (MMF) being the most commonly used agent, (n= 13 patients, 40.6%, 8 in the simvastatin group and 5 in the placebo) and three patients were taking methotrexate (9.37%).Table 3-10.

Table 3-10.Number of patients on second-line immunosuppressive agents in both, simvastatin and placebo group at baseline

Therapies	Simvastatin	Placebo	Total
Methotrexate	1	2	3
Cyclosporine	0	0	0
Mycophenolate mofetil	8	5	13
Infliximab	0	1	1
Interferon beta-1a	0	1	1
Adalimumab	1	0	1

For placebo group at baseline, nine patients (56.25%) were on oral prednisolone only. The remainder seven patients were receiving a second-line immunosuppressive agent in addition to the oral prednisolone (five patients were receiving MMF, two patients on methotrexate, and infliximab 5mg/kg infusion every eight weeks and the other patient was taking 20 mg methotrexate weekly and interferon beta-1a (44µg) 3 weekly injections. For the simvastatin group seven patients were only receiving oral prednisolone dose at 10 mg per day, the other eight patients were receiving in addition to oral prednisolone another immunosuppressive agent (five patients were on 2 gm daily, two were on 1 gm daily, and the last patient was receiving the maximum dose 3 gm daily). One patient was taking 30 mg of methotrexate weekly in addition to adalimumab 40 mg subcutaneous injections every two weeks.

The reduction of 2nd line immunosuppressive agents is displayed in Table 3-11. The total number of patients included in the analysis is 12, with 6 from each of the treatment arms. The percentages are shown in the bracket.

Table 3-11. The number of patients with a reduction in second-line immunosuppressive agents (IMT) The chi-square test suggests that there is weak evidence of a difference between the two groups regarding reduction in the second-line IMT.

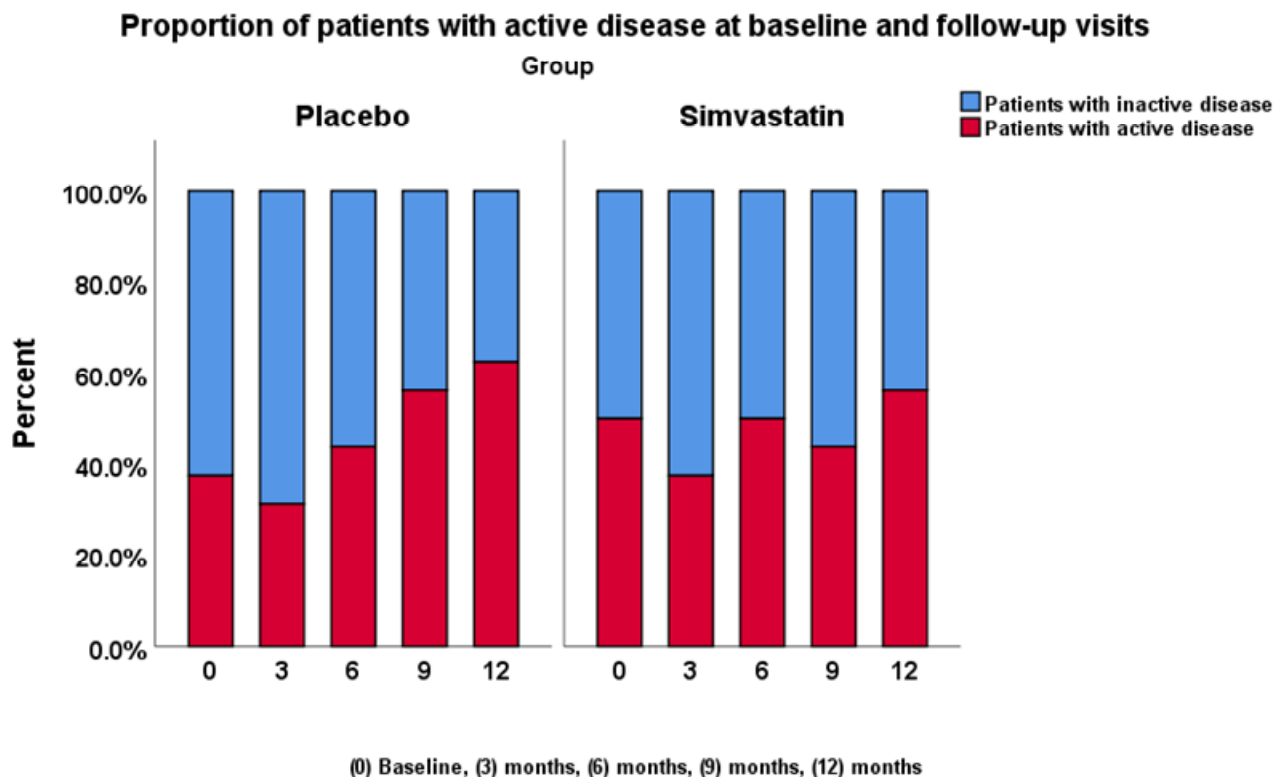
Reduction in 2 nd line IMT	Placebo, N (%)	Simvastatin, N (%)	Total
No	3 (50)	4 (66.7)	7
Yes	3 (50)	2 (33.3)	5
Total	6	6	12

The chi-square test suggests a test statistic of 0.34 with a p-value of 0.56. The reduction in second-line immunosuppressive agent does not differ significantly between the two groups at 5% level.

3.20.3 3. Disease relapses at 24 months

Disease activity scores at each study visit were analysed for 32 patients 16 in each arm. At baseline 6 (37.5%) patients in the placebo group had active disease versus eight patients (50%) in the simvastatin group. (P-value= 0.50, Chi-square test). By three months the number of patient with active disease in the placebo group increased to 9 patients (56.3%), while in the simvastatin group it decreased to 7 patients (43.8%), but this was not statistically significant (p-value 0.50, Chi-square test) (McNemar test p-value was 1.00). At the six months follow-up visit, the numbers of patients with active disease were 7 (43.8%) and 8 (50%), in placebo and simvastatin group, respectively, (p-value =0.12, Chi-square test). At nine months, the number of patients with active disease in the placebo group was five patients (31.3%) versus six patients (37.5%), again non-significant, (p-value =0.13, Chi-square test). At one-year follow-up, the figures were ten patients (62.5%) in the placebo arm and nine patients (56.3%) in the simvastatin group, (p-value =0.13, Chi-Square test). Figure 3-11.

Figure 3-11 Proportion of patients with active disease for the simvastatin and the placebo group. There was no significant difference between the two groups at all follow-up visits.



The number of patients who had disease relapses by 24 months is shown below. The numbers of patients included in the analysis were 10 and 11 for the placebo and the simvastatin group, respectively. The proportion of patients who had disease relapse by 24 months was higher in the simvastatin group (45.5%) compared to that in the placebo group (10%). Table 3-12.

Table 3-12 Number of patients with relapses by 24 months the chi-square test suggests that there is weak evidence of a difference between the two groups in disease relapses.

Relapse	Placebo, N (%)	Simvastatin, N (%)	Total, N (%)
No	9 (90)	6 (54.5)	15
Yes	1 (10)	5 (45.5)	6
Total	10	11	21
The chi-square test suggests a test statistics of 3.23 with a P-value of 0.072, therefore, the disease relapse rate does not differ significantly at 5% level.			

3.20.4 4. Blood cholesterol and lipid levels at baseline and 24 month

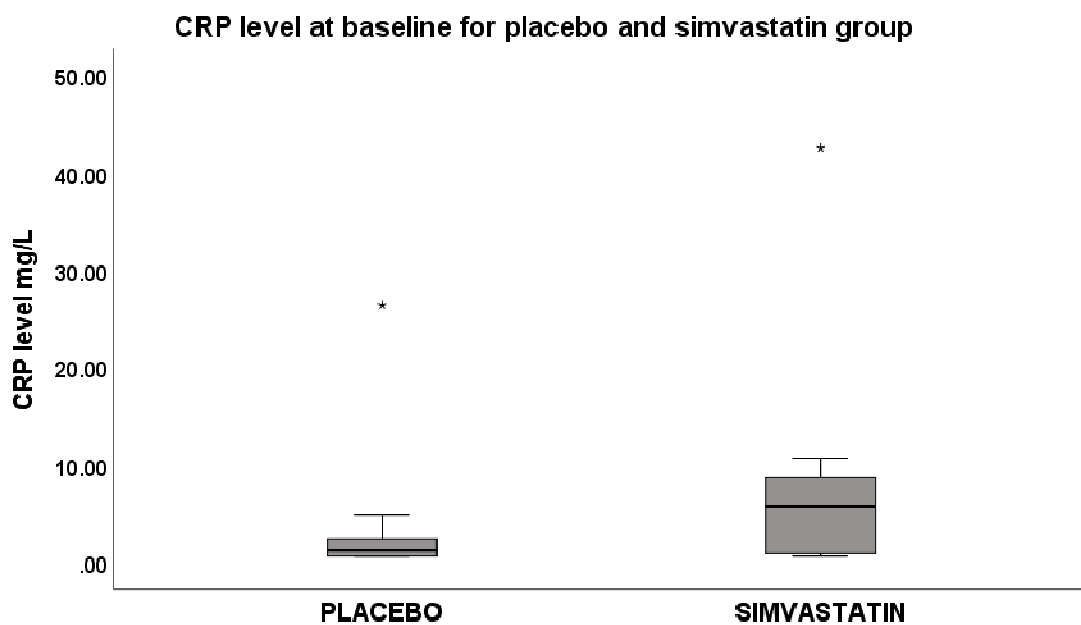
The descriptive statistics of blood cholesterol and lipid levels for both groups at baseline and 24 months are shown in Table 3-13.

Table 3-13. Descriptive analysis of blood cholesterol and lipid levels

	Baseline, mean (SD)		24 months, mean (SD)	
	Simvastatin	Placebo	Simvastatin	Placebo
CRP, mg/L	8.08 (12.07)	3.83 (7.6)	11.32 (24.26)	1.16 (0.93)
RBG, mmol/L	6.68 (3.39)	5.25 (1.09)	5.29 (1.12)	5.71 (2.94)
HbA1c, mmol/mmol (%)	6.21 (1.77)	5.76 (0.33)	6.16 (1.06)	5.63 (0.41)
Total cholesterol, mmol/L	5.29 (1.01)	5.59 (1.08)	4.56 (1.48)	9.92 (13.17)
LDL, mmol/L	2.88 (0.68)	3.07 (0.75)	2.14 (1.31)	2.63 (0.86)
HDL, mmol/L	1.76 (0.62)	1.89 (0.61)	1.7 (0.67)	1.84 (0.64)
Triglyceride, mmol/L	1.42 (0.53)	1.4 (0.58)	1.59 (1.01)	2.15 (0.90)
Creatinine, umol/L	128.63 (78.88)	136.38 (100.16)	221.7 (198.21)	130.43 (74.0)

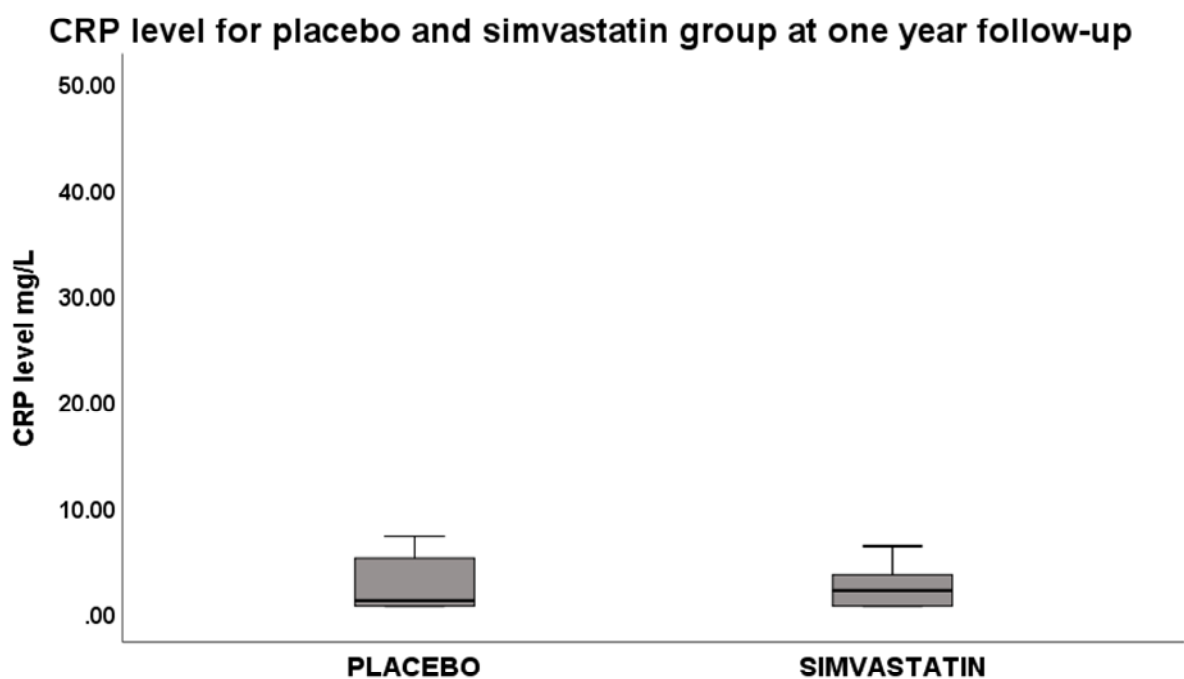
CRP analysis at baseline of 22 patients (11 in each group) shows a mean CRP level of 8.08 in the simvastatin group versus 3.83 in the placebo group. There was no significant difference between the two groups (p-value= 0.15, Mann Whitney U test, two-sided), Figure 3-12. At one-year follow-up, the mean CRP level in the simvastatin group dropped to 3.27 ± 0.62 . Comparing the CRP level in the simvastatin group at baseline and one-year follow-up shows a significant difference (p-value 0.042, Wilcoxon Sign Rank test, two-sided).

Figure 3-12 CRP level at baseline. There was no statistically significant difference between the two groups



At one-year follow-up data for only 20 patients were available for analysis. The mean CRP for the placebo group was 2.66 ± 0.84 SEM and for the simvastatin group 2.59 ± 0.69 . There was no statistically significant difference between the two groups, (p-value= 0.87, Mann Whitney U test, two-sided). Figure 3-13.

Figure 3-13 CRP level for placebo and simvastatin group at one-year follow-up. There was no statistically significant difference between the two groups (p-value=0.87)

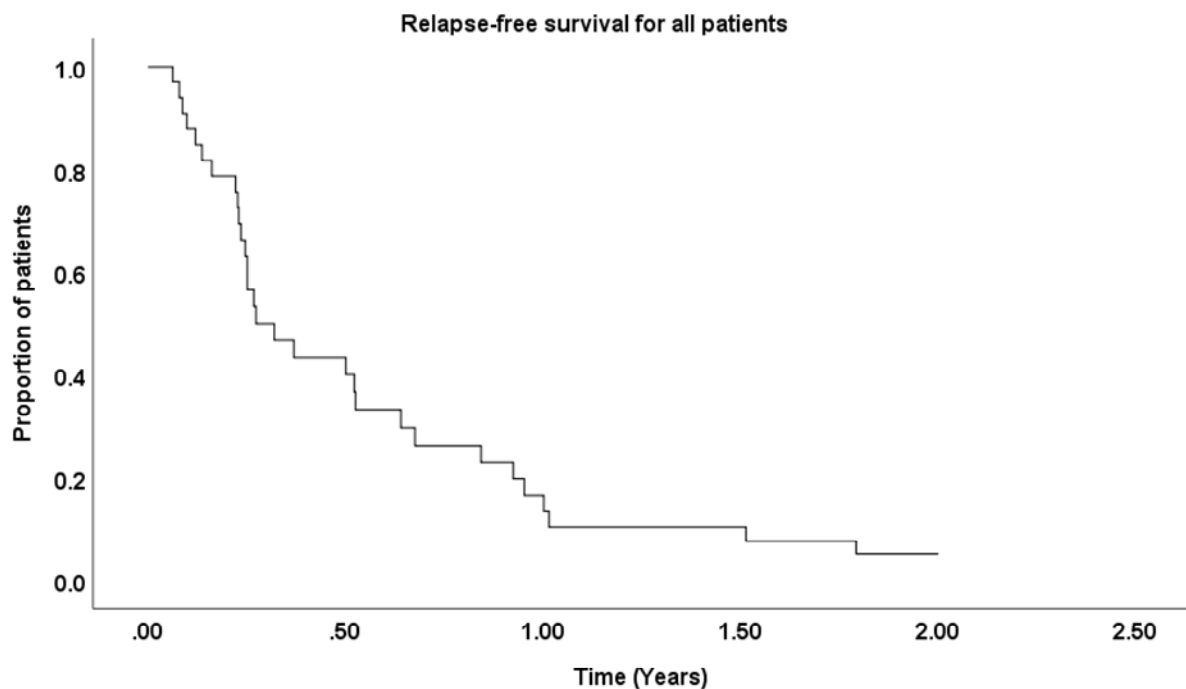


In the placebo group, there was no statistically significant difference in CRP level at baseline and one-year follow-up (p-value 0.61, Wilcoxon Sign Rank test, two-sided) whereas, in the simvastatin group the difference was significant between baseline and 1-year follow-up.

3.20.5 Relapse-free survival

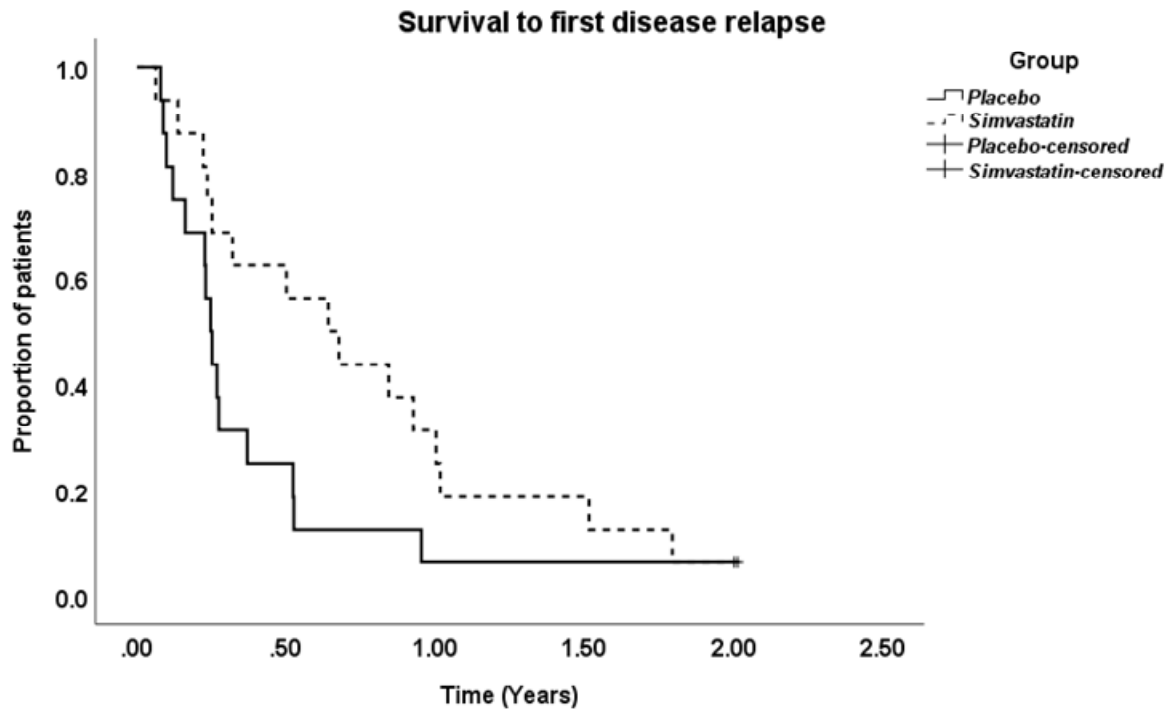
Thirty patients developed disease relapses throughout the study, and only two did not have any relapse of inflammation. Overall mean survival was 0.58 ± 0.09 SEM years; 95%CI 0.38-0.77, median survival 0.27 ± 0.08 SEM years; 95%CI (0.11-0.43). Figure 3-14.

Figure 3-14 Relapse-free survival. For all study population the overall mean survival to first relapse was 0.58 years.



The mean survival to first disease relapse for the placebo group was 0.40 ± 0.11 SEM years; 95%CI 0.17-0.63, median survival 0.24 ± 0.02 years; 95%CI 0.20-0.29. For the simvastatin arm the mean survival was 0.75 ± 0.14 years; 95%CI 0.47-1.02, median survival 0.64 ± 0.17 ; 95%CI 0.29-0.98. Although the simvastatin group had a better mean and median survival, Kaplan Meier survival analysis curve did not show a statistically significant difference between the two groups, (p-value= 0.089, Log-Rank test). Figure 3-15. Cox regression analysis between the simvastatin and placebo was not significant, (HR 0.53; 95%CI 0.25-1.11, p-value 0.09).

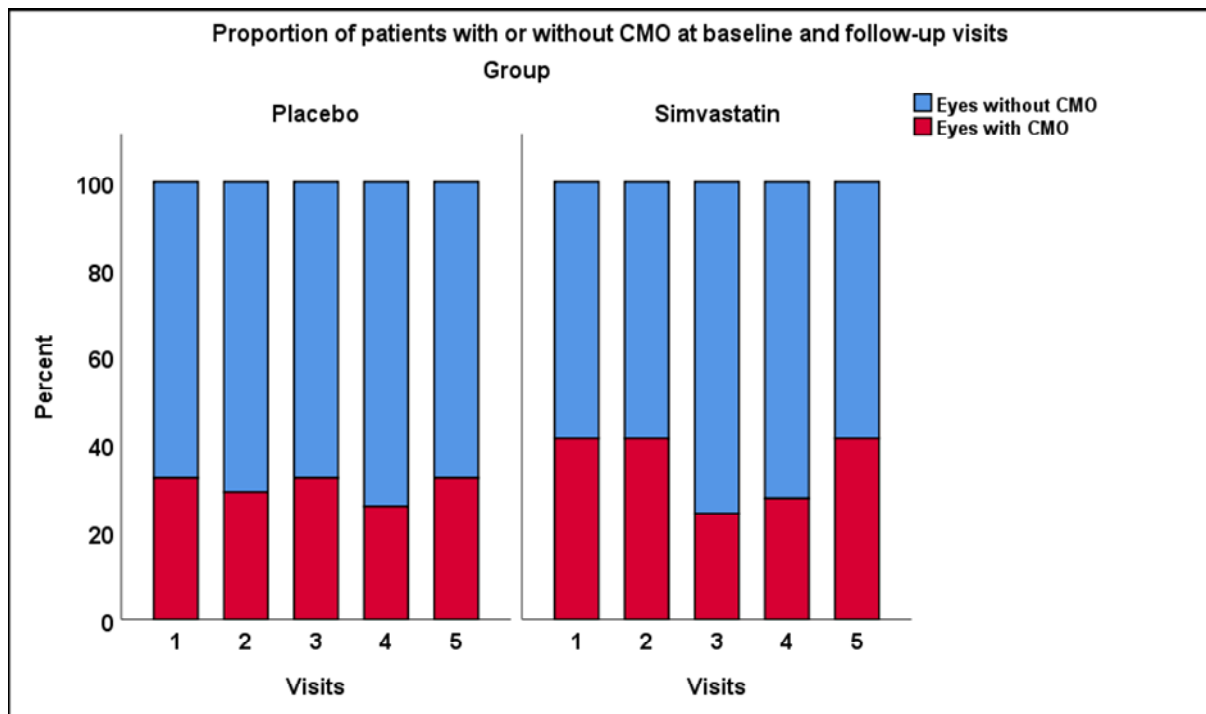
Figure 3-15 Survival to first disease relapse for simvastatin and placebo groups. Kaplan Meier survival analysis curve did not show a statistically significant difference between the two groups, (p-value= 0.089, Log-Rank test)



3.20.6 CMO

At baseline, there were 10 out of 31 eyes (33.3%) and 12 out of 29 eyes (41.3%) with CMO in the placebo and simvastatin groups, respectively. (P-value= 0.46, Chi-Square test). At, three, six, and nine months there was no statistically significant difference between the two groups, (p-value =0.31, p-value =0.48, and p-value =0.87, Chi-Square test, respectively). The proportions of eyes with CMO was lower in the placebo group, ten eyes (32.3%) than simvastatin group, 12 eyes (41.4%), but this was not statistically significant (p-value =0.46, Chi-Square test). Figure 3-16.

Figure 3-16 Proportion of patients with CMO in simvastatin and placebo groups. There was no significant difference between the two arms at all study visits.



Cholesterol data analysis

Mean cholesterol for all study population at baseline was $5.44 \pm \text{SEM } 0.18$ (SD 1.03), median 5.3, range from 3.70 -7.90. Mean total cholesterol for the simvastatin group at baseline was $5.29 \pm 1.0 \text{ SEM } 0.25$, median 5.10, range 4.20-7.90), and for the placebo group the mean total cholesterol was 5.59 ± 1.08 (SEM 0.27), range from (4.62-6.65).

No significant difference was seen at baseline with regards to total cholesterol between the two study arms (p-value 0.42, 95%CI -0.45-1.05, independent samples t-test). Figure 3-17. LDL for placebo group was 3.0 SEM 0.18 (SD 0.75), and for the simvastatin group it was 2.87 SEM 0.17 (SD 0.68), (p-value 0.45; 95% CI -0.32-0.71, two samples t-test, two-sided). Figure 3-18. HDL cholesterol for the placebo group was $1.88 \pm 0.15 \text{ SEM}$ (SD 0.61), and for the simvastatin group it was 1.76 mean $\pm 0.15 \text{ SEM}$ (0.62 SD), p-value= 0.57; (95% CI -0.32-0.57), two-sample t-test, two-sided). Figure 3-19.

Figure 3-17 the mean total cholesterol for placebo and simvastatin groups at baseline. There was no significant difference between the two groups (p-value= 0.42 independent sample t-test)

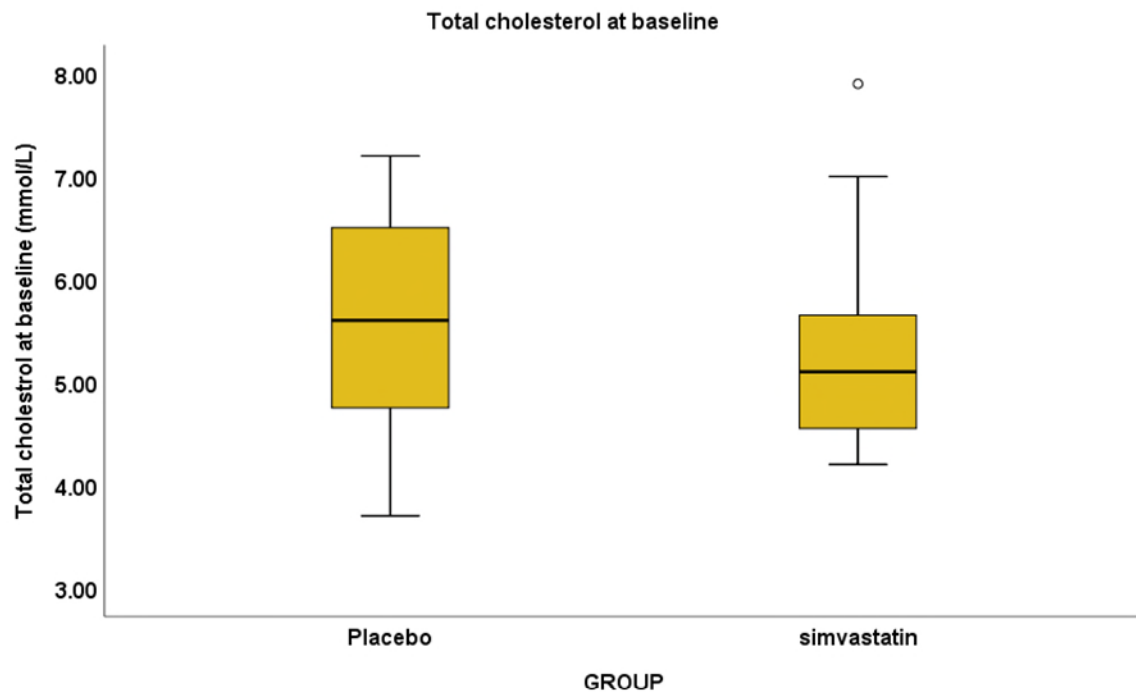


Figure 3-18 LDL cholesterol level for simvastatin and placebo groups at baseline There was no significant difference between the two groups (p-value= 0.45 independent sample t-test)

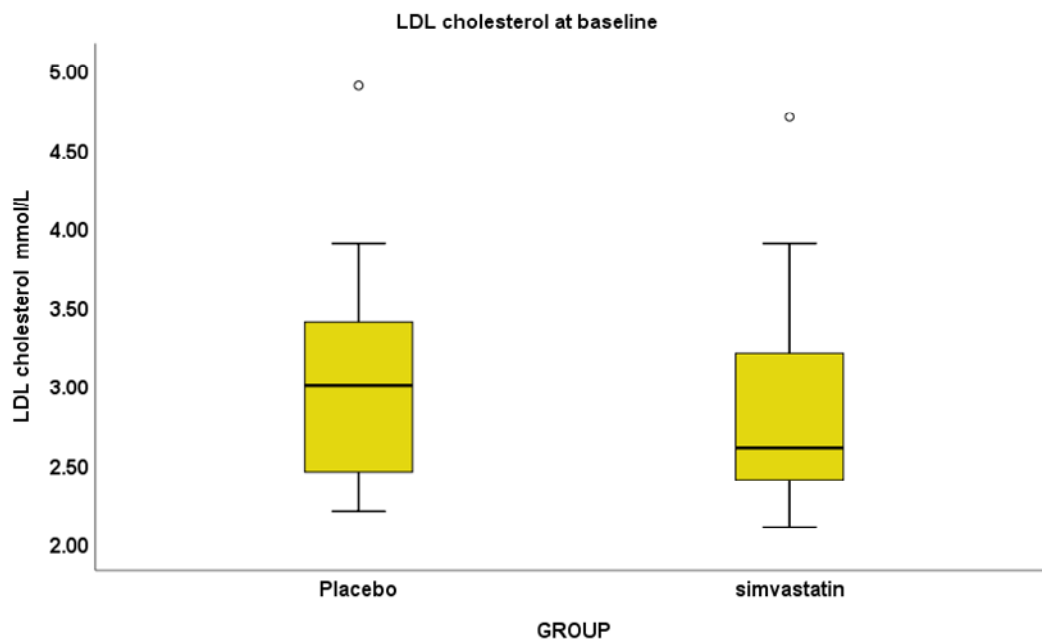
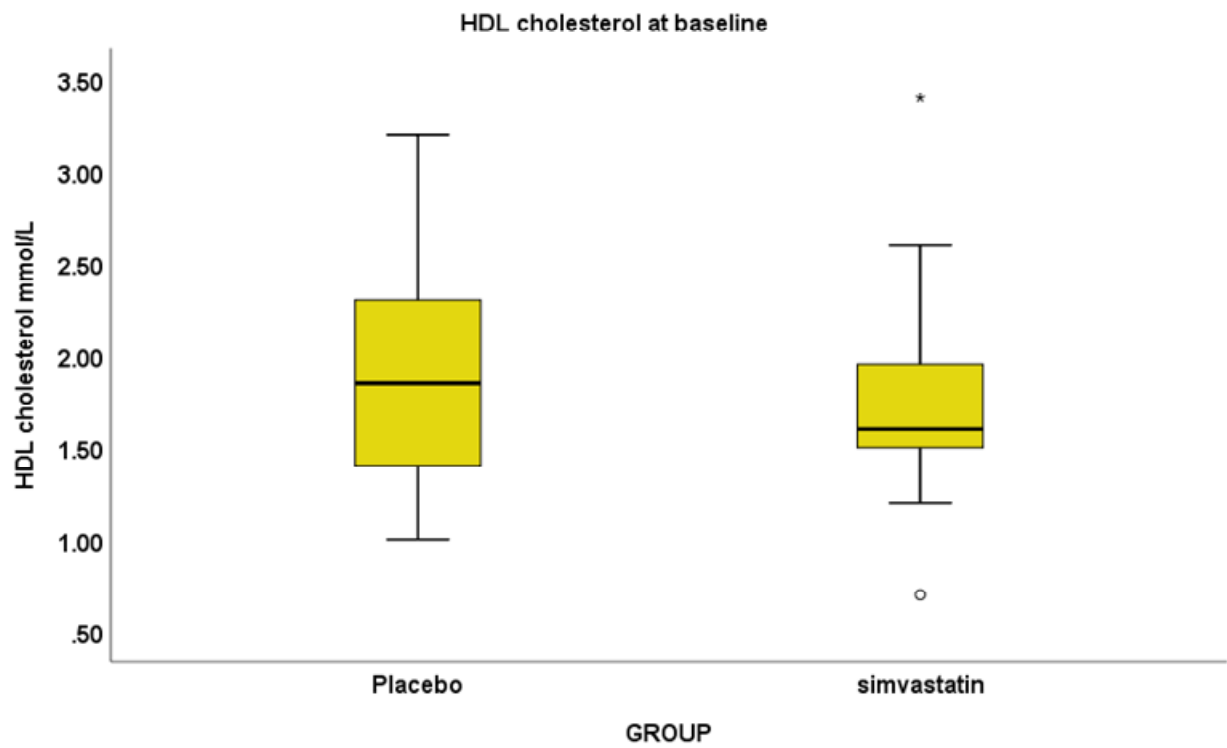
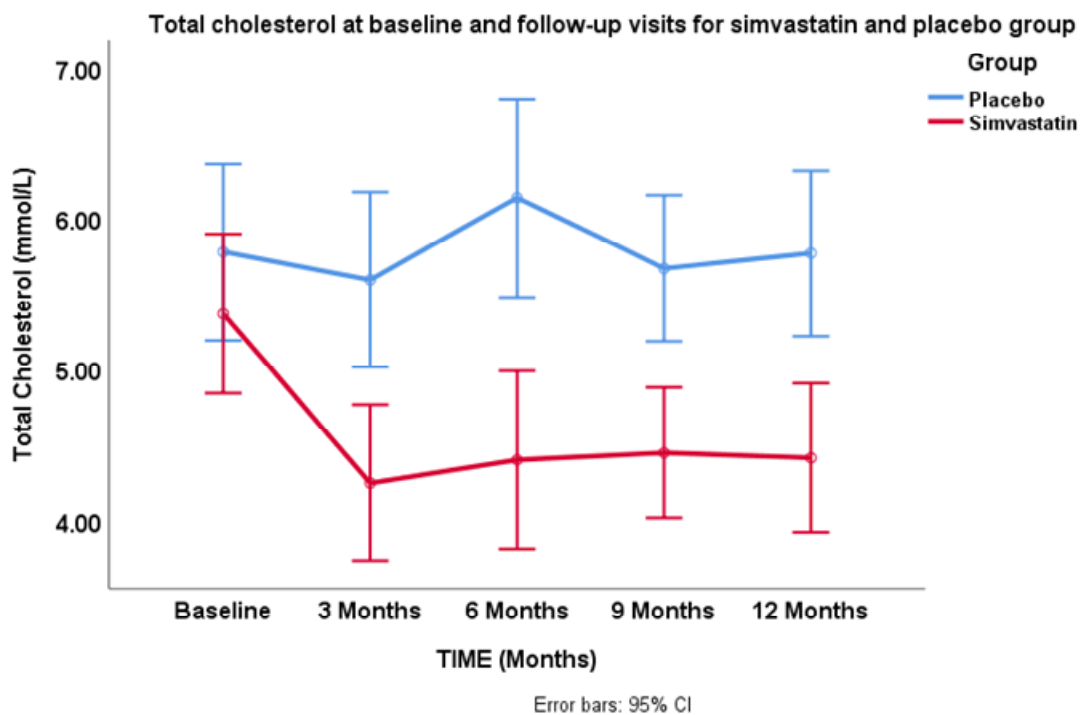


Figure 3-19 HDL cholesterol level for the placebo and simvastatin groups at baseline. (p-value= 0.57, two-sample t-test)



At one year the mean cholesterol level for the placebo group was 5.76 ± 0.80 SD, whereas for the simvastatin group mean total cholesterol was 4.41 ± 1.00 SD. One-Way Repeated measure ANOVA was used to analyse the difference in total cholesterol between the simvastatin and placebo group at baseline and throughout the follow-up visits. There was a statistically significant difference in mean total cholesterol between the two groups, (F value 14.60, $p=0.001$). Figure 3-20.

Figure 3-20 Change in total cholesterol level for the placebo and simvastatin group during the first year follow-up, p-value=0.001.



For LDL, the mean LDL level at visit number 5 (1 year) was 3.30 ± 0.47 SD for the placebo group and 2.05 ± 1.14 SD for the simvastatin group. Repeated measure One-Way ANOVA showed a highly statistically significant difference between the two groups, (F value =18.34, $p\text{-value} < 0.001$). Figure 3-21. For HDL analysis please refer to Figure 3-22. For triglycerides please refer to Figure 3-23.

Figure 3-21 Change in LDL cholesterol level for the placebo and simvastatin group during the first year follow-up. One-Way Repeated measure ANOVA showed a highly statistically significant difference between the two groups, (F value =18.34, p-value<0.001).

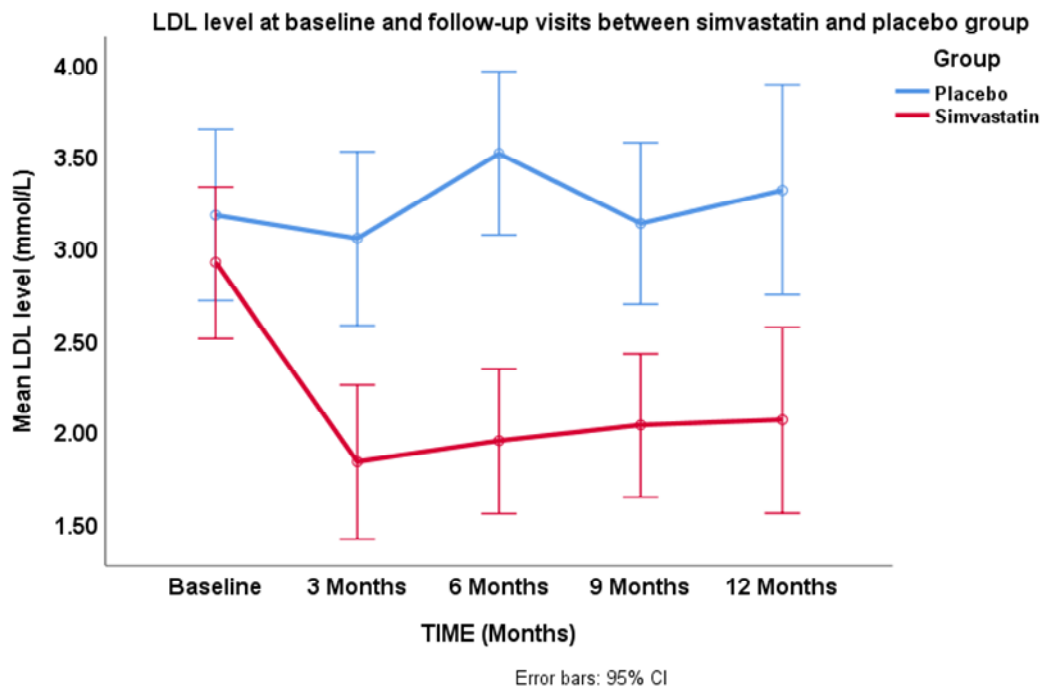


Figure 3-22 Change in HDL cholesterol level for the placebo and simvastatin group during the first year follow-up HDL did not reveal a statistically significant difference between the two group, (p-value=0.77, F value=0.082, One-Way Repeated measure ANOVA).

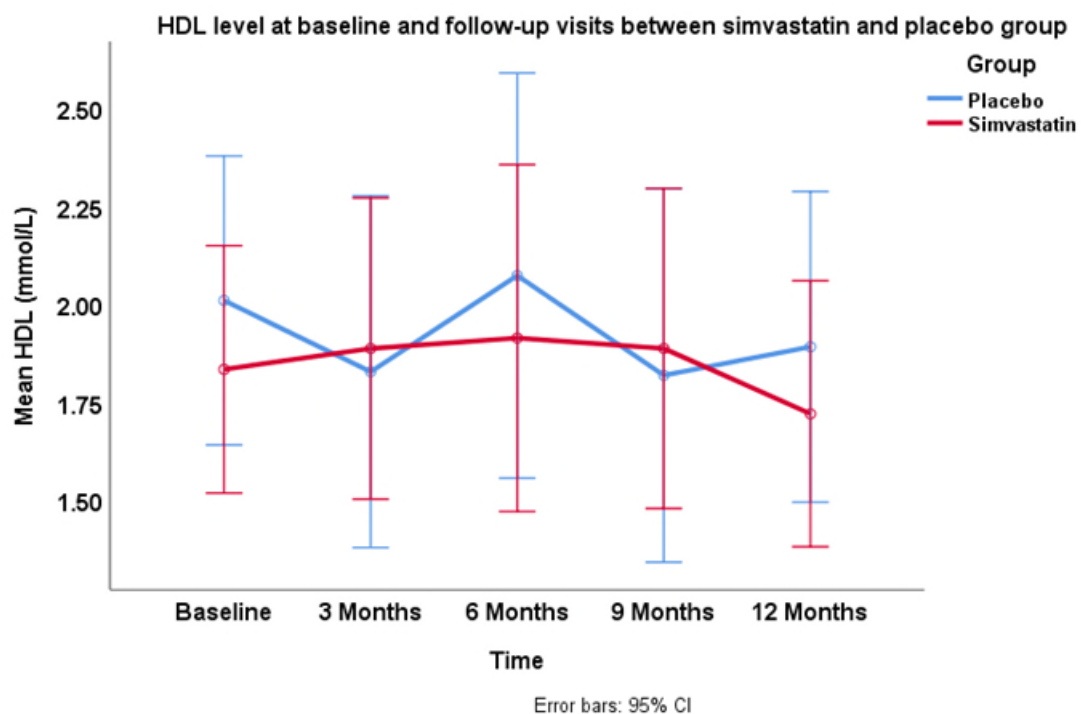
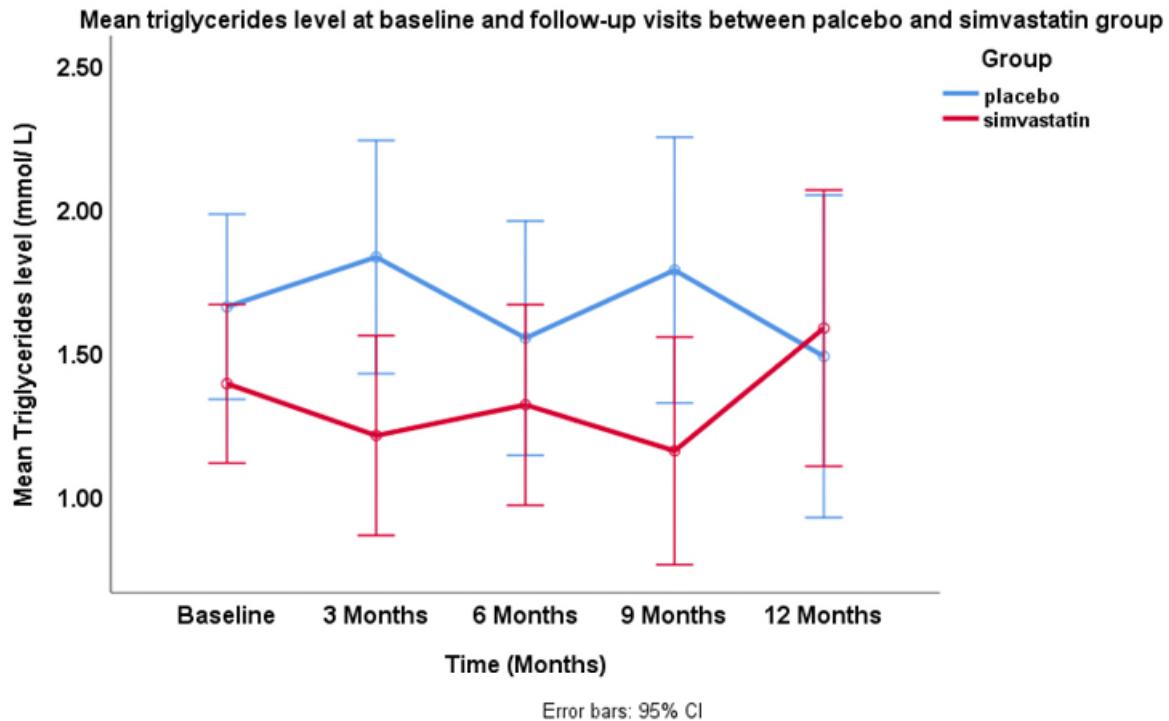


Figure 3-23 Change in triglycerides level for the placebo and simvastatin group during the first year of follow-up did not show a statistically significant difference (p-value=0.14 and the F value is 2.26, One-Way Repeated measure ANOVA).



3.20.7 Safety of simvastatin

The total number of adverse events recorded throughout the trial was 127, 51 in the placebo group and 76 in simvastatin group: Among these 5 were serious adverse events, and those were not related to the trial investigational medicinal product. In the placebo group, two sickle cell crises occurred and the last attack ended in the death of that patient. The other patient, had a cycling accident and a hip fracture. Whereas in the simvastatin group, two serious adverse events were reported, and both were elective surgeries. One patient had a hip replacement for long-standing psoriatic arthritis; the second patient had elective gallbladder removal. One patient became pregnant during the trial. Muscle and joint pain was reported 11 times in the placebo group and 22 times in the simvastatin group

3.20.8 CK

The mean CK value for the placebo group at baseline was 136.37 ± 25.0 SEM, median 101 and for the simvastatin group 128.62 ± 19.7 , at one year mean CK was 115.30 ± 18.52 , median 90 for the placebo group, whereas for the simvastatin group it was 148.06 ± 23.40 , median 115. There was no statistically significant difference between the two group at baseline (p -value=0.83, Mann Whitney U, two-sided test), Figure 3-24. Similarly, there was no significant difference at one-year follow-up visit, (p -value=0.42, Mann-Whitney U, two-sided test), Figure 3-25. For the simvastatin group, there was no significant difference between the CK enzyme level at the baseline visit and one-year, (p -value=0.33, Wilcoxon Sign Rank, two-sided test).

Figure 3-24 Creatinine kinase (CK) level at baseline for placebo and simvastatin groups, there was no statistically significant difference between the two groups (p -value=0.83).

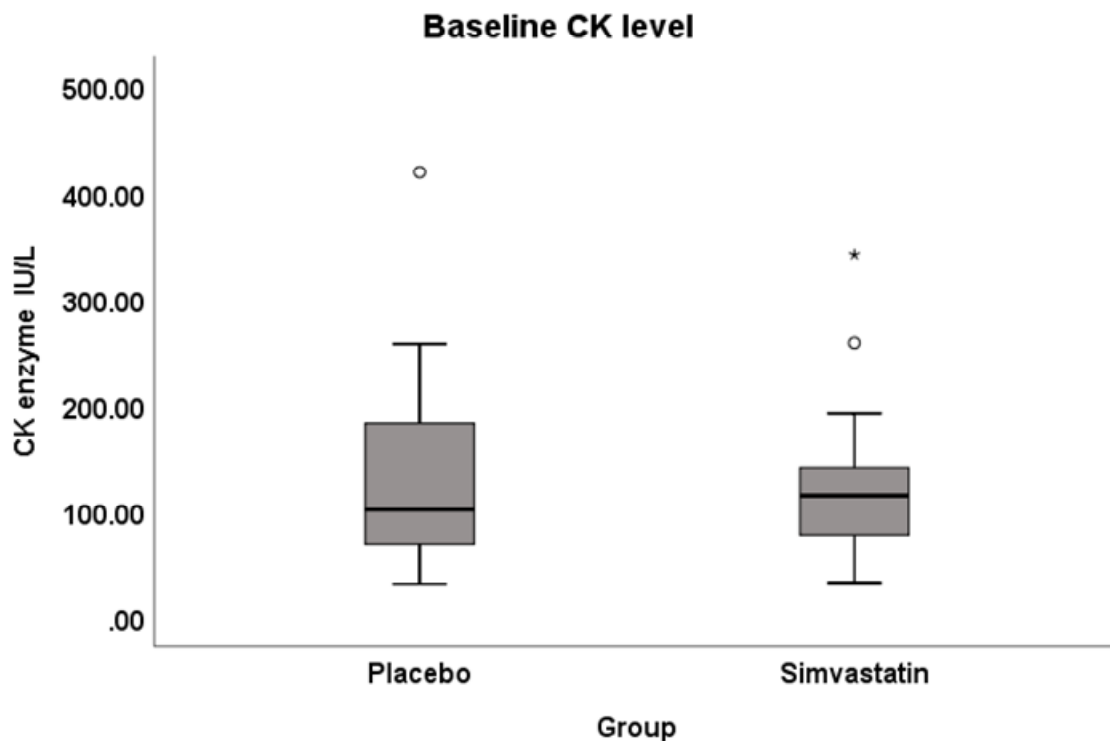
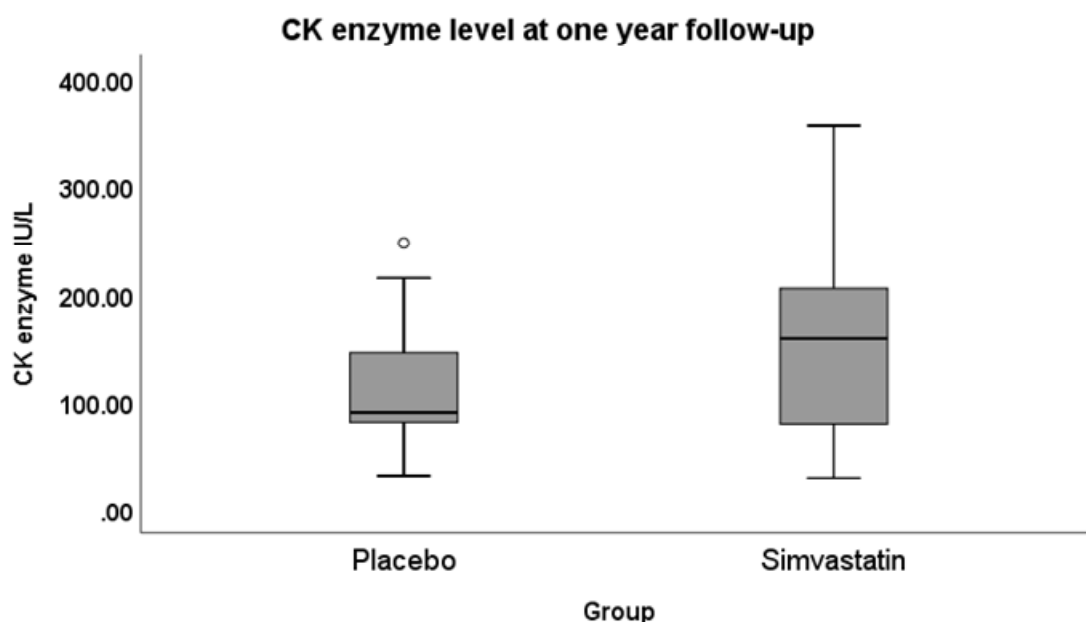


Figure 3-25 Creatinine kinase (CK) level for the placebo and the simvastatin at one year follow-up, did not show a statistically significant difference between the two groups (p-value=0.42).



3.20.9 Liver enzymes

For the placebo group, there was no significant difference in alanine transaminase (ALT) and aspartate transaminase (AST) at baseline and one-year follow-up, (p-value =0.80) and (p-value =0.62), respectively. Alkaline phosphatase (ALK) showed a significant increase from baseline (p-value=0.008, paired sample t-test, two-sided). Table 3-14.

Table 3-14 Liver enzyme analysis for the placebo group

Liver enzymes analysis (Placebo)					
		Mean	N	Std. Deviation	Std. Error Mean
Pair 1	ALK Baseline	52.50	16	11.60	2.90
	ALK 1 year	62.75	16	15.69	3.92
Pair 2	ALT baseline	24.56	16	9.54	2.38
	ALT 1 year	23.87	16	11.34	2.83
Pair 3	AST baseline	18.68	16	4.19	1.04
	AST 1 year	19.43	16	5.68	1.42

For the simvastatin group

There was no significant difference in alkaline phosphatase and alanine transaminase at baseline and one-year follow-up, p-values were (0.30) and (0.79), respectively. Only aspartate transaminase showed a statistically significant difference from baseline (p-value =0.004, paired sample t-test). Table 3-15. Mean change in ALT, AST and serum alkaline phosphates are displayed in Figures 3-26, 3-27 and 3-28, respectively.

Table 3-15 Liver enzymes analysis for the simvastatin group

Liver enzyme analysis (Simvastatin)					
		Mean	N	Std. Deviation	Std. Error Mean
Pair 1	ALK Baseline	73.25	16	18.17	4.54
	ALK 1 year	78.31	16	20.06	5.01
Pair 2	ALT baseline	22.37	16	8.00	2.00
	ALT 1 year	25.43	16	13.93	3.48
Pair 3	AST baseline	19.12	16	5.61	1.40
	AST 1 year	21.50	16	6.23	1.55

Figure 3-26 Mean difference in alanine transaminase (ALT) from baseline for placebo and simvastatin groups

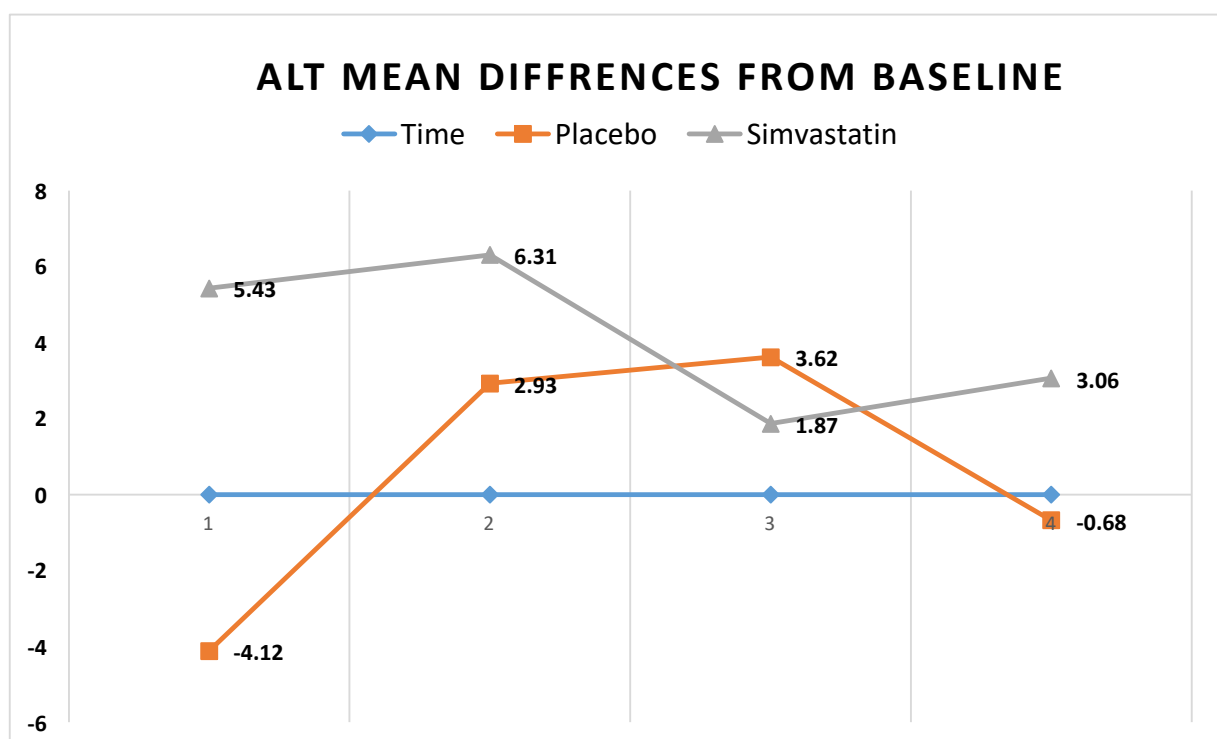


Figure 3-27 Mean difference in aspartate transaminase (AST) from baseline for placebo and simvastatin groups

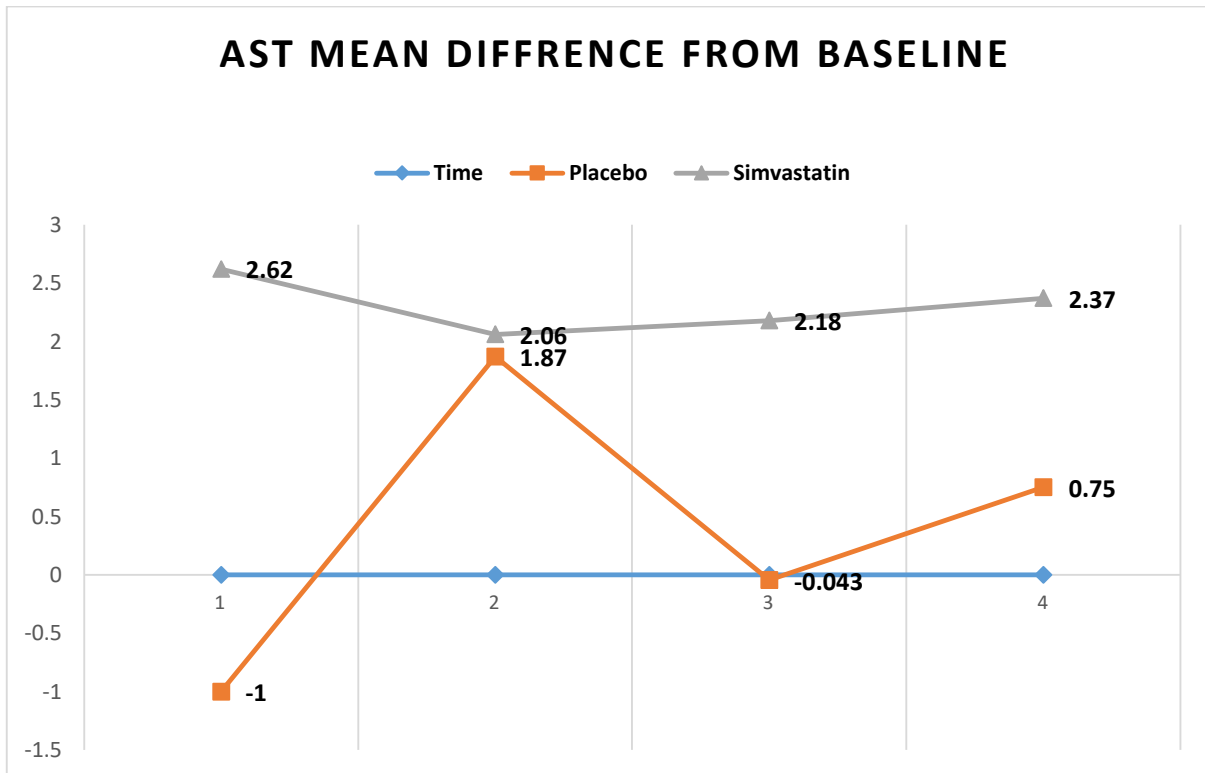
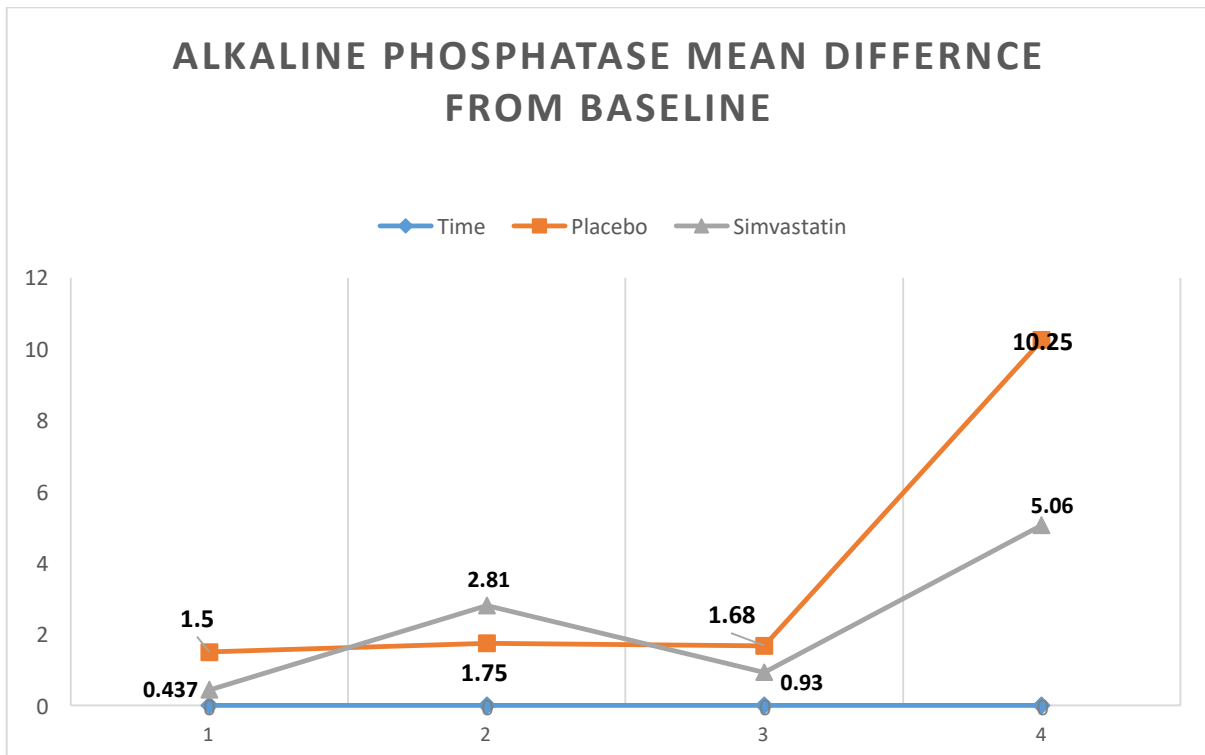


Figure 3-28 Mean difference in serum alkaline phosphatase (ALK) from baseline for placebo and simvastatin groups



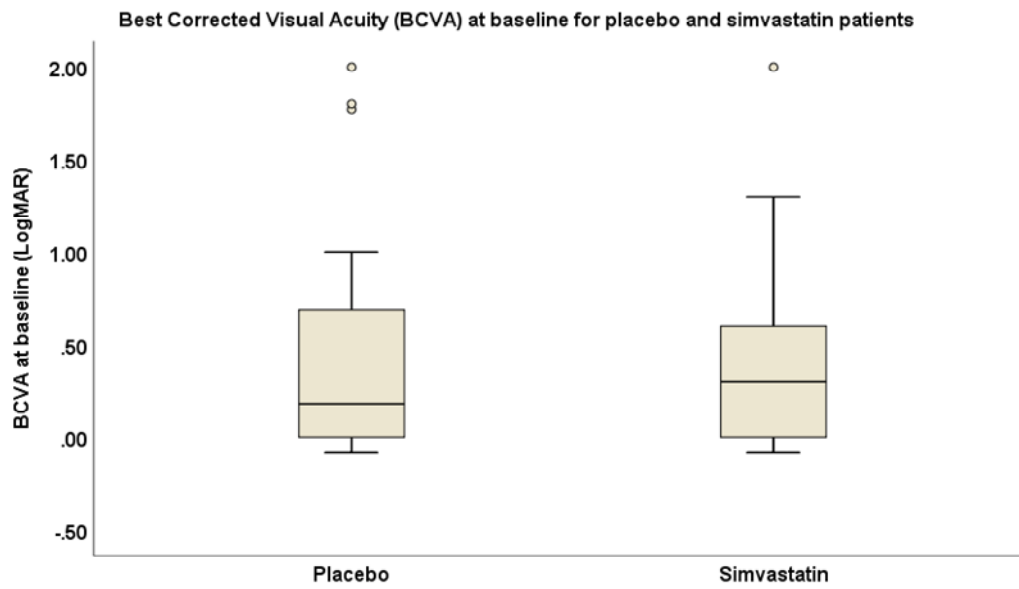
3.21 Exploratory analysis of visual acuity BCVA

The mean BCVA at baseline (n=60 eyes, 31 eyes, 51.7% in the placebo group and 29 eyes, 48.3% in the simvastatin group) was 0.42 ± 0.06 LogMAR, the median was 0.18, range -0.08 to 2 LogMAR units, Interquartile range IQR (0.0-0.73). The mean BCVA at baseline for the placebo group was 0.44 ± 0.10 , median 0.18, range -0.07-2.00 LogMAR, (IQR 0.00-0.78). Table 3-16. The mean BCVA for the simvastatin group at baseline was 0.40 ± 0.09 , median 0.30, IQR (0.00-0.69). There was no significant difference between the two groups at baseline with best corrected visual acuity, (p-value =0.89, Mann-Whitney U test, two-sided), Figure 3-29.

Table 3-16 Mean BCVA for placebo and simvastatin groups at study follow-up visits.

BCVA LogMAR unit	Placebo		Simvastatin	
	Mean	Std. Error	Mean	Std. Error
Baseline	0.44	0.10	0.40	0.09
Three months	0.43	0.10	0.49	0.09
Six-month	0.42	0.09	0.44	0.09
Nine Months	0.38	0.11	0.50	0.11
Twelve months	0.42	0.10	0.44	0.08

Figure 3-29 BCVA for the placebo and simvastatin groups at baseline



Using generalised estimating equations (GEE) (to adjust for BCVA for baseline visual acuity), there was no significant change in BCVA during follow-up, for both simvastatin and placebo groups, with no significant difference between the two groups at each follow-up visit. Table 3-17.

Table 3-17 BCVA (Log MAR) at baseline and during trial follow-up visits for the simvastatin and the placebo group.

	Simvastatin			Placebo			Between group difference	
	MD (SE)	95% C.I	P *	MD (SE)	95% C.I	P*	MD (SE)	P**
Baseline	-	-	-	-	-	-	-0.17 (0.16)	0.31
12 week	0.11 (0.08)	-0.05 – 0.27	0.18	-0.05 (0.04)	-0.13 – 0.03	0.22	-0.01 (0.15)	0.95
24 week	0.69 (0.09)	-0.12- 0.25	0.47	-0.08 (0.06)	-0.21 - 0.04	0.17	-0.01 (0.13)	0.91
38 week	0.14 (0.11)	-0.08- 0.38	0.21	-0.16 (0.10)	-0.36 – 0.04	0.12	0.13 (0.16)	0.39
52 week	0.09 (0.10)	-0.11- 0.30	0.35	-0.16 (0.12)	-0.39 – 0.07	0.18	0.08 (0.14)	0.54

MD = Mean difference, SE= Standard Error, C.I= Confidence Interval.
 *p-value within group calculated using generalized estimating equation
 **p-value between groups calculated using generalized estimating equation

The mean visual acuity for both eyes over time is shown in Table 3-18. The graphical presentation of the mean visual acuity is displayed in Figure 3.30 and 3-31. There is no considerable change in the mean visual acuity over 12 months. The 95% CI is wide given the non-homogeneity of the study population.

Table 3-18 Mean visual acuities over time (measured in LogMAR)

Time	Left eye LogMAR, mean(SD)		Right eye LogMAR, mean (SD)	
	Simvastatin (N=16)	Placebo (N=16)	Simvastatin (N=16)	Placebo (N=16)
Baseline	0.37 (0.56)	0.47 (0.65)	0.36 (0.40)	0.38 (0.50)
12 week	0.35 (0.44)	0.52 (0.62)	0.54 (0.58)	0.31 (0.58)
24 week	0.41 (0.58)	0.44 (0.59)	0.39 (0.41)	0.39 (0.52)
38 week	0.48 (0.71)	0.41 (0.61)	0.42 (0.47)	0.34 (0.62)
52 week	0.34 (0.53)	0.45 (0.55)	0.45 (0.43)	0.37 (0.62)

Figure 3-30 Trend in visual acuity over 12 months for the left eye (measured in LogMAR) shows no difference between the two study arms.

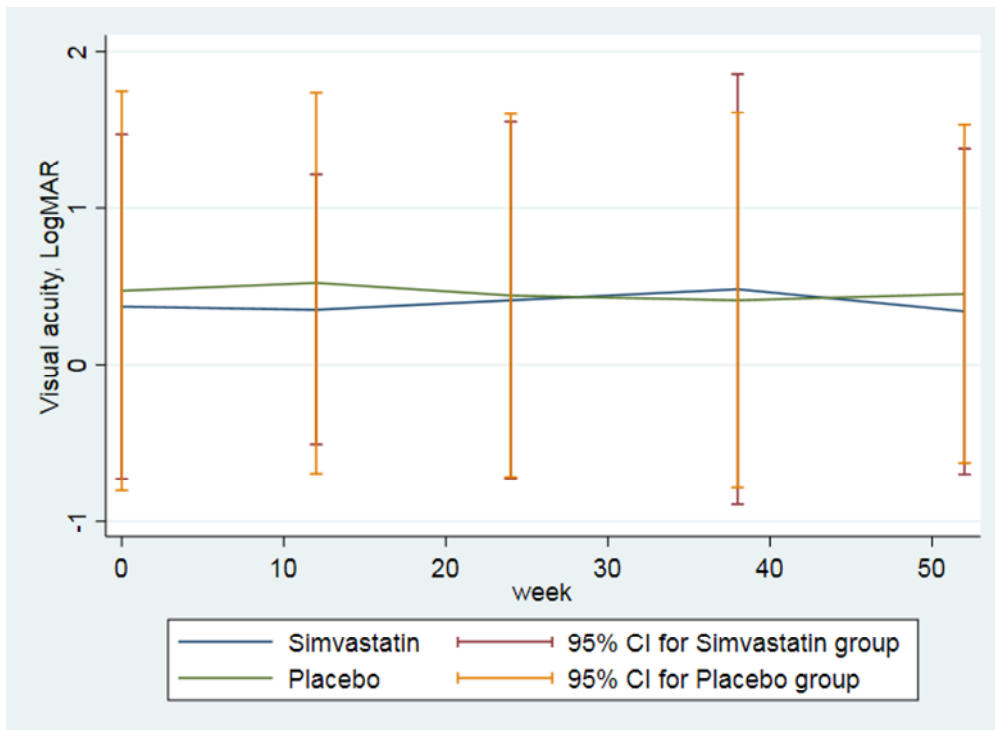
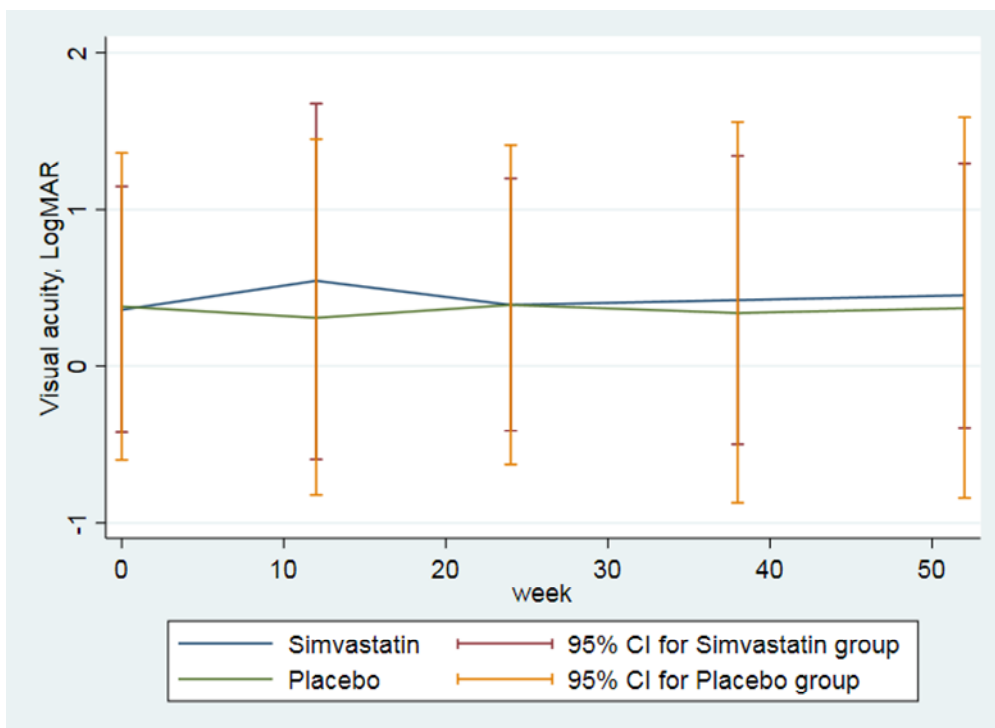


Figure 3-31 Trend in visual acuity over 12 months for the right eye (measured in LogMAR) shows no difference between the two study arms.



3.22 Discussion

Simvastatin in sight-threatening uveitis is the first double-masked, randomised control trial to compare the effect of 80 mg simvastatin versus placebo on conventional immunosuppressive therapy in patients with non-infectious intermediate, posterior and panuveitis. The mean age at presentation in our study was 47 years; there were more women than men, and this reflects the higher prevalence of uveitis in females compared to males as previously reported (Gritz and Wong 2004). The study included patients with intermediate, posterior and panuveitis on 10 mg prednisolone per day and above, idiopathic intermediate and posterior uveitis constitute 60% of all patients enrolled in the study. These uveitides have a chronic course with frequent relapses, which are mostly unpredictable, and due to the aggressive nature of the inflammation and the common involvement of the posterior pole and with a high incidence of CMO, patients are usually at high risk of vision loss. Therefore, treatment usually involves corticosteroid-based systemic immunosuppressive therapy, and these patients were managed with relatively high doses to achieve disease control and prevent disease relapse. A second-line immunosuppressive agent was used to achieve corticosteroid-sparing. At presentation, 88% of patients had bilateral disease, where systemic immunosuppressive therapy is usually the preferred option. Almost one-third of patients had systemic inflammatory conditions associated with uveitis although these were quiescent and not requiring treatment. With regards to the patient's ethnicity, 60% of patients were white. Patients recruited in the study have relatively long disease duration, and patients in the placebo group had longer mean disease duration compared to the simvastatin group, but this was not statistically significant. Finally, both groups were balanced with regards to patient's demographics.

3.22.1 Prednisolone dose analysis

Our results show that 80 mg simvastatin did not have a significant corticosteroid-sparing effect in patients with non-infectious intermediate, posterior and panuveitis, at 1 and two years follow-up. The mean prednisolone dose in simvastatin group was 3.62 mg higher compared with the placebo group at 12 months, the 95% confidence interval includes 0, and the corresponding p-value is relatively large ($p = 0.54$). Therefore, there is no significant evidence of a treatment effect at the 5% level.

However, patients recruited for the trial have a very heterogeneous disease with varying degree of inflammation and response to treatment. In uveitis, because of the limited number of patients, most drug trials are usually based on the anatomical location of the inflammation, and this allows patients with various diseases, different levels of disease activity and chronicity to be recruited. Even though these diseases share an underlying immune aetiology, they are different with regards to clinical and pathological aspects and hence response to therapy.

At initial study visit the mean daily corticosteroids dose used to control the ocular inflammation was approximately 15 mg, a relatively high dose and not ideal for long-term disease control. This high prednisolone dose was because when these patients entered the study, they were on a tapering dose of corticosteroid after a recent increase due to disease relapse, or patients were managed on 10 mg prednisolone while having disease quiescence and these doses were dropped further during follow-up.

The addition of simvastatin 80 mg to conventional therapy did not result in a significant reduction of mean corticosteroids dose at all follow-up times. However, the proportion of patients on prednisolone dose more than 10 mg per day was less in simvastatin arm compared to placebo but was not significant. At three months follow-up, the proportion of patients on daily prednisolone dose <10 mg rose in both groups but there were more patients on simvastatin versus placebo, 43.8% and 37.5%, respectively, and at one year half of the patients in the simvastatin arm achieved a safe dose (<10 mg) compared to only 37.5% of patients in the placebo arm. At two years there were approximately equal numbers of patients on less than 10 mg prednisolone in both groups. The mean prednisolone dose at 3, 6 and nine months was less in the simvastatin group compared to the placebo, and comparing the mean differences from baseline in both groups, shows a trend towards less corticosteroid dose in patients taking simvastatin.

Regression analysis adjusted for baseline prednisolone dose did not find a statistically significant difference between the two arms. Similarly, analysis of prednisolone dose adjusted for disease duration at study entry did not show a considerable difference of daily corticosteroid dose between the two study arms at one year. Although the mean prednisolone dose in the regression analysis was higher in the simvastatin group

compared to placebo, 3.62 mg difference, the results were not statistically significant (p-value=0.54). In our secondary analysis, at two-years, the difference between the two groups became minimal at 0.3 mg daily prednisolone. When adjusted for baseline prednisolone dose, patients on simvastatin had a lower prednisolone dose, mean difference on 0.34 mg compared to placebo, but the results were not statistically significant. There was no difference between patients with ocular disease only and those with ocular and systemic disease at 1-year follow-up.

The current findings show that simvastatin, compared to placebo, did not show a corticosteroid-sparing at one year follow-up and although at the two-year visit, the mean prednisolone dose was less in simvastatin arm compared to placebo, but it was not significant. We could speculate that there was an effect on daily prednisolone dose at three months, but this was lost later on. Alternatively, simvastatin may take a longer time to achieve a corticosteroid-sparing since a small effect was detected towards the end of the study (two-year follow-up visit) or simvastatin has not had a significant anti-inflammatory effect in these diseases. However, we cannot exclude a more significant effect if the eye alone but was not visible. Finally, it may be true that the effect of simvastatin was minimal and difficult to detect with daily oral corticosteroid dose.

In comparison with the SITE study, methotrexate achieved corticosteroids-sparing (complete control of inflammation for at least 28 days while on prednisolone \leq 10 mg per day) in only 41.3% and 20.7% of patients with intermediate, posterior/panuveitis, respectively, at six months follow-up. At or before 12 months corticosteroids sparing was achieved in 69% of patients with IU and 39% of those with posterior/panuveitis (Gangaputra, Newcomb et al. 2009). However, the discontinuation rate due to inefficacy was 42%, and for side effect, it was 16% within the first year follow-up.

Similarly, cyclosporine in the SITE study reported corticosteroid-sparing success in only 22% and 36% of patients at 6 and 12 months, respectively, and only 3.6% and 8.2% of the total study population, were able to stop corticosteroid completely at 6 and 12 months, respectively, and 11% discontinued the drug due to side effects (Kacmaz, Kempen et al. 2010). By contrast, corticosteroids sparing was higher on MMF, the proportion of patient were 41% and 55% at 6 and 12 months, respectively, and only 12% had to stop therapy within the first year due to side effects (Daniel, Thorne et al. 2010). Finally, the corticosteroids sparing on azathioprine was 47% at or before one

year. Nonetheless, the discontinuation rate due to side effect approached 25% (Pasadhika, Kempen et al. 2009).

In the SITE study, the corticosteroids-sparing was higher in patients with anterior uveitis compared to other types of ocular inflammation which may point out to the fact that IU, posterior and panuveitis are more aggressive forms of ocular inflammation and hence more resistant to treatment.

In patients with pulmonary sarcoidosis, one year treatment with 80 mg atorvastatin versus placebo did not show a significant difference in corticosteroid-sparing period between the two groups (the primary endpoint of the study) (prednisolone was tapered by 90% over 8 weeks periods and time when the prednisolone dose was re increase was calculated), p-value 0.56 (Moss, Stylianou et al. 2017). Interestingly, there was 82.9% relative risk reduction in pulmonary sarcoidosis flares in atorvastatin given patients compared to placebo. But this was only in patients with mild and moderate group, p-value-0.046, Fisher's Exact test, and no significant difference was noted in the severe group (patients were stratified into three different groups based on different parameters to assess disease severity). Also, time to first flare analysis shows a significant benefit for the atorvastatin group compared to placebo in patients with mild and moderate group (p-value=0.012. Log-Rank test). It is known that sarcoidosis is more sensitive to corticosteroid therapy than other ocular inflammatory disease. Also, atorvastatin in patients with severe disease did not have a significant anti-inflammatory effect which may implies a weak anti-inflammatory effect of statins.

Among published reports regarding statin immunomodulatory effect in uveitis, there are no RCTs to explore the impact of statins in humans with ocular inflammatory diseases. There is only one open-label, pilot study, published in 2017, examining the role of simvastatin 40 mg per day as an adjunct to conventional therapy (corticosteroids) versus standard treatment alone in patients with acute non-infectious uveitis. The study was for two months only and included a total of 50 patients (25 in each group) (Shirinsky, Biryukova et al. 2017). The effect of simvastatin was measured on three different outcomes; corticosteroids dose, visual acuity and intraocular pressure.

The previous study looked at the corticosteroid-sparing effect of simvastatin while achieving disease control in patients with AAU. The study defined the corticosteroids

sparing as a daily corticosteroids dose ≤ 10 mg or ≤ 2 drops per day of prednisolone acetate eye drops or equivalent, while maintaining inflammatory score of ≤ 0.5 for both anterior chamber cells and vitreous haze and without active retinal and choroidal lesions as previously defined in another study (Rathinam, Babu et al. 2014).

With regards to corticosteroids treatment, simvastatin effect was measured across three different routes: topical drops, oral and sub-conjunctival injections. With systemic corticosteroids, there was a statistically significant difference between the two groups at two weeks follow-up only, then results became non-significant at one and two months, the corresponding p-values are 0.66 and 0.33, respectively. Similarly, the difference in sub-conjunctival corticosteroids injections between the two groups was only significant at the two-week follow-up, and the results became non-significant after that, whereas the difference in topical corticosteroid drops between the two groups was statistically significantly lower in patients on simvastatin compared to control group at 4 and eight weeks study visits. The study reported substantially higher rates of corticosteroids sparing while maintaining disease control in the simvastatin group compared to conventional treatment alone. Also, there was a significant improvement in anterior segment inflammatory scores and visual acuities in the simvastatin arm.

Patients well tolerated simvastatin, and there were no serious adverse events. The authors concluded that simvastatin has a potential role in uveitis treatment. However, they pointed to the fact that these results are not conclusive, and a double-masked randomised controlled trial is warranted. The difference in anterior chamber flare was highly statistically significant at 2, 4 and eight weeks, while the difference in anterior chamber cells grade was only significant at 2 and four weeks but not at eight weeks in simvastatin arm compared to controls. There was no significant difference in vitreous haze and intraocular pressure between the two groups at the three follow-up time points.

Since the previous study had patients with AAU and short treatment duration, a direct comparison with our results is difficult. Additionally, the study has several drawbacks. Firstly, the study was open-label which creates a high chance of bias. Moreover, the vast majority of patients in the previous study, 45 out of 50 patients (90%), had anterior uveitis, and only five patients (10%) were diagnosed with intermediate and posterior uveitis. HLA-B27 was the most common aetiology (70%) in patients with anterior

uveitis, and there was an imbalance between patients in both groups, there were significantly more patients with HLA-B27 in the simvastatin group compared to placebo (17 versus 7) (p-value =0.01).

It is known that in HLA-B27 associated AAU, the disease course, response to treatment and impact on vision, differ significantly from cases with IU, posterior and panuveitis, with acute course (approximately one attack per year), better response to local corticosteroids and much less risk of ocular complications and vision loss, in the former. The acute and milder course in patients included in the previous study was reflected by the fact that topical corticosteroid was the primary treatment for all patients, and none had immunomodulatory therapy. Finally, the trial was conducted for a short period (2 months). Therefore, it is difficult to draw any conclusions with regards to the long-term efficacy of simvastatin in patients with non-anterior sight-threatening uveitis.

Simvastatin in other autoimmune diseases showed a positive effect. In patients with MS, several studies showed that simvastatin 80 mg daily could suppress the disease activity with a subsequent reduction in neurological disability. A fascinating double-masked placebo-controlled study on 140 patients with secondary progressive (MS), randomised to either 80 mg simvastatin or placebo, showed a significant reduction in brain atrophy (43%) (Imaged by serial MRI scans) in simvastatin receiving patients for 2-year follow-up (Chataway, Schuerer et al. 2014). Vollmer and colleagues reported similar findings using 80 mg simvastatin for six months on 30 MS patients with relapsing/ remitting MS. They have found a significant reduction (44%) in the mean number of contrast-enhanced lesions (Gadolinium) on MRI scans pre and post-treatment (p-value <0.0001) (Vollmer, Key et al. 2004).

However, other studies using simvastatin or atorvastatin showed no effect on relapse rate or the appearance new lesions on MRI scans in patients with early-stage multiple sclerosis (Kamm et al., 2012, Sorensen et al., 2011). Similarly, another study examining the effect of 40 mg atorvastatin in addition to β -interferon on patients with relapsing/remitting MS did not show any change in relapse rate or evidence of new lesions on MRI scan (Kamm, El-Koussy et al. 2014). Simvastatin as an add-on treatment to interferon Beta 1a in patients with relapsing-remitting MS (SIMCOMBIN)

trial, did not show a significant difference in time to first relapse or the annual relapse rate (May and Barclay).

Nonetheless, MS studies suggest that these drugs cross BBB, and since BBB and BRB are both similar in structure and function, it would be reasonable to speculate that simvastatin passes the retinal vessel walls and achieve an immunomodulatory effect in the eye.

Statins have a neuroprotective effect (van der Most, Dolga et al. 2009) and were shown to improve the haemodynamics of cerebrovascular circulation (Giannopoulos, Katsanos et al. 2012) and ameliorate the vascular endothelial cells dysfunction which was reported to be involved in the pathogenesis of MS (Greenwood and Mason 2007). Therefore, the positive effect witnessed in MS studies might be mediated via immunomodulatory-independent mechanisms. Alternatively, the improvement in vascular endothelial cell function and neuroprotection on statins might be the main drives for the positive effect noticed in MS patients. In Chataway et al. study, there was no difference between the simvastatin and the placebo group with regards to inflammatory markers (levels of pro-inflammatory cytokines such as, INF γ , and IL-17 on T cells) at any time point, nor there was a difference in anti-inflammatory cytokines (IL-4, IL-10 or FoxP3 on CD4 T cells) which are regarded as markers for T regulatory cells. Likewise, in Vollmer and associates study, the beneficial effect of simvastatin was independent of the immune cells type (Th1/Th2), and the analyses of the cytokine profile and cells surface markers before and during treatment with simvastatin did not show a difference (Vollmer, Key et al. 2004).

Moreover, in Chataway et al. study, simvastatin did not have an impact on the frequency of disease relapse. The authors acknowledged the fact that the results of simvastatin on MS patient were not fully understood, but these effects were likely to be attributed to neuroprotection properties of simvastatin. The possible mechanisms are reducing free radicles formation and preventing the cytotoxic effect of certain substances. Alternatively, simvastatin might have improved the cerebral vascular function and thus reduced hypoxic brain damage (Chataway, Schuerer et al. 2014). Nonetheless, this study was conducted on patients with advanced stage of the disease where the inflammatory component might be less substantial in driving disease progression compared to neurodegeneration and vascular dysfunction. All the

previous studies in MS support a positive effect of simvastatin in patients with MS, and these benefits were primarily driven by the neuroprotection and improvement in cerebral circulation, while the immunomodulatory effect was less pronounced.

Conversely, simvastatin in our study (uveitis) did not show a positive effect on prednisolone dose since this is directly dependent on the anti-inflammatory properties of simvastatin which were not evident in the previous studies on MS patients. Also, there are significant differences in structure, microenvironment and immune regulation between the brain tissue and the eye. Moreover, the interaction between the cerebral blood vessels and brain tissue parenchyma, and neurodegeneration which are more amenable to statins are probably more essential in disease pathogenesis in MS.

Additionally, simvastatin's down-regulation of the adhesion molecules may have a little effect on immune response in uveitis compared to MS. Immunology studies have shown that uveitis is a T cell disease, particularly CD4 cells. In sarcoidosis, for example, there is a predominance of CD4 T cells in the affected tissues, similarly, in CD4 outnumbered CD8 T cells in intermediate uveitis (Boyd, Young et al. 2001), while in MS not only CD4 T cells are increased but also CD8 and B lymphocytes (Reich, Lucchinetti et al. 2018). Different immune cells may have different susceptibility to statin's immunomodulatory effect, and therefore, CD4 T cells in uveitis may be less affected by simvastatin compared to other immune cells.

Furthermore, with regards to immune cells trafficking into the site of inflammation, in MS there is an increase in circulating lymphocytes particularly CD54 (ICAM-1) (Boyd, Young et al. 2001), and since statin downregulated the expression of this molecule, there was a positive response to simvastatin in MS patients. By contrast, in patients with intermediate and posterior uveitis, the circulating lymphocytes do not necessarily express this unique marker, and therefore the statins' immunomodulatory effect was less evident. Moreover, the immune system may adapt and seek alternative pathways to achieve effect at the site of inflammation. It has been shown that lymphocytes migrate via alternative adhesion pathways which are ICAM-1 independent, whereas, neutrophils which were recently shown to infiltrate the CNS in high proportion in early MS, (Rumble, Huber et al. 2015) are exclusively depended on ICAM-1 pathway for transcellular migration (Liversidge, Sewell et al. 1990). As well, immune cells trafficking into the eye may not represent the main disease drive in chronic ocular

inflammation, since ocular resident immune cells and other cells such as Muller cells and RPE might be the main contributors to disease chronicity or even relapse.

Finally, drugs commonly used in uveitis are not used for MS which may imply different disease pathogenesis and hence response to treatment, and the best example is anti-TNF α drugs. TNF α blockers which exacerbate disease activity in MS, and are contraindicated, are very useful in disease control in non-infectious uveitis. The efficacy of other immunosuppressive second-line agents in MS is controversial. Small open-label studies have shown that MMF, alone or in combination with interferon beta may reduce the annual number of disease relapses, limit new areas of CNS damage and may slow disease worsening. Azathioprine in MS has given mixed results while rituximab was found effective in controlling disease relapses in MS (Costello, Halper et al. 2015).

The beneficial effects of simvastatin seem to vary by the type of disease encountered, with patients with NIIPPU having minimal or no response to simvastatin compared to those with MS. The response to simvastatin may be governed by the type of inflammation, disease severity, and or other factors. Other contributory reasons could be that statins do not have the sufficient, long lasting immunomodulatory effects witnessed in vivo and in vitro studies, due to lower concentrations in human compared to other experimental studies. An early in vitro study suggested that a full or 80% blockade of isoprenoid production required statin doses that far exceed the clinical and in vitro dosage (Sinensky, Beck et al. 1990). This was supported by another study where extremely high doses (up to 200 mg/day) did not alter Ras prenylation in lymphocytes of leukemic patients (Lewis, Holstein et al. 2005). Moreover, statins might not have an equal effect on the production of various isoprenoids (Ostrowski, Wilkinson et al. 2007) nor they have a similar effect in all tissues (Ericsson, Runquist et al. 1993) or under different conditions such as inflammation. Finally, research in vitro and mice does not translate into humans because animal models of uveitis are not identical to humans with regards to organ-specific immune mechanisms.

3.22.2 Second-line immunosuppressive agent

Half of the study population were on second-line immunosuppressive agents in addition to corticosteroids to control their inflammation. The most commonly

prescribed second-line agent (40%) was MMF mycophenolate mofetil. MMF has a shown to be useful in the treatment of non-infectious uveitis and exerts its effect faster than the other second-line agent of same class such as methotrexate (Daniel, Thorne et al. 2010). Moreover, this agent was better tolerated than other immunosuppressive agents. At baseline, three patients were receiving methotrexate, one on a non-therapeutic dose (7.5 mg weekly) due to concomitant use of the biological agent (infliximab) to reduce the risk of development of anti-drug antibodies which increases the risk of drug failure. The other two patients were on therapeutic doses of methotrexate of 20 and 30 mg weekly, one patient with Behcet disease and the other one has HLA-B27 ankylosing spondylitis.

At the end of the second-year follow-up, there was no significant difference between the two arms in the reduction of second-line agents, and this coincides with the results obtained by analysing daily corticosteroids doses. Commonly in uveitis corticosteroid dose is reduced first and then the second-line agent dose is reduced or stopped based on patient's response to therapy. However, small numbers were included in this analysis, 12 patients with 6 in each arm.

3.22.3 Disease relapse

The proportion of patients with active disease decreased at three months in patients on simvastatin compared to those on placebo. Similarly, at one-year follow-up, a smaller proportion of patients had active disease compared to placebo group. However, the difference was not significant enough to reach statistical significance. At the two-year follow-up, there were more patients with disease relapse in the simvastatin group compared to placebo, but the difference was not significant. Similarly, time to first disease relapse was not significant between the simvastatin and placebo group.

3.22.4 Visual acuity analysis

When compared to baseline visual acuity, the analyses show stability in BCVA in both treatment arms, and there was no significant difference in BCVA between groups and within groups' at all follow-up visits. Since all patients were treated with high dose oral prednisolone or local corticosteroids injections to rescue vision when severe disease

relapse such as vitritis or CMO occurred, there was no difference between the groups. In the simvastatin study in patients with AAU, a significant improvement in BCVA in patients in simvastatin group at 2, 4 and eight weeks follow-up was reported. However, the method for visual acuity assessment was not validated (Shirinsky, Biryukova et al. 2017). Also, the reduction in BCVA in AAU is less common compared to those with intermediate, posterior and panuveitis which undermines the results of the aforementioned trial.

Simvastatin 80 mg for six months in a double-masked RCT showed beneficial effects on long-term visual outcomes in patient with acute optic neuritis (a demyelinating inflammatory disorder of the optic nerve head and could be a presenting feature of MS). Simvastatin showed a significant positive effect on visual evoked potential (a test used to assess the function of the optic nerve by measuring the amplitude and latency of the signal transmitted through the optic nerve). However, there was no statistically significant difference between groups in VA or colour perception (Tsakiri, Kallenbach et al. 2012). The authors attributed the beneficial effect of simvastatin to the enhancement of the repair mechanism of the axonal damage via promotion or remyelination of the damaged nerve fibres. Nonetheless, disease pathogenesis in optic neuritis is different from uveitis.

3.22.5 Cholesterol analysis

At the baseline visit, the mean blood cholesterol level was higher than normal for all the study population, and approximately 60% of patients had their total cholesterol level above 5 mmol/l. The most likely reason for that was the effect of corticosteroids-based systemic immunosuppressive therapy used to treat ocular inflammation. Systemic immunosuppression in uveitis is known to increase patient's risk of cardiovascular disease (Shirodkar, Taylor et al. 2011). Therapy with a systemic corticosteroid is known to cause dyslipidaemia with a prevalence of more than 80% in heart transplant patients (Miller 2002). The most commonly increased lipids are, very LDL (VLDL), LDL and triglycerides, while, HDL is commonly reduced on corticosteroid therapy. The high level of LDL-cholesterol plays a key role in the development of atherosclerotic diseases.

The mechanism by which corticosteroids increases serum lipids is not fully understood. However, some authors proposed that corticosteroids increase cholesterol synthesis in the liver by enhancing the action of HMG Co-A reductase enzyme. Also, impaired lipid catabolism and down-regulation of LDL receptors have also been reported on corticosteroids therapy (Kobashigawa and Kasiske 1997). Moreover, increase serum insulin due to corticosteroid-induced hepatic insulin resistance also contributes to high cholesterol level, which in turn leads to excessive production of VLDL which subsequently turns to LDL and triglycerides (Sholter and Armstrong 2000).

The effect of corticosteroids on serum lipids levels is enhanced by the concomitant use of other immunosuppressive agents which are also known to cause high blood cholesterol such as cyclosporine and tacrolimus (Miller 2002). Calcineurin inhibitors upregulate serum lipids, and one of the proposed mechanisms is inhibition of LDL receptor-mediated clearance in the liver. Other non-LDL receptor-dependent mechanisms include lipoprotein synthesis, decreased plasma lipoprotein lipase, and increased plasma apolipoprotein (Kockx and Kritharides 2016).

Chronic inflammation, on the other hand, has been shown to promote dyslipidaemia and this effect is mediated via the activity of pro-inflammatory cytokines which increase VLDL, LDL and triglycerides. Also, the inflammatory cascade induces a reduction in HDL cholesterol and this decrease in HDL could lead to a compensatory increase in production and accumulation of VLDL and triglycerides. Moreover, chronic inflammation impairs the function of HDL, which is essential in cholesterol reverse transport. HDL has antioxidant properties and helps to protect from coronary heart disease, since oxidized LDL is more atherogenic, (upregulates adhesion molecules and promote proliferation of smooth muscles), it is more damaging to endothelial cells. HDL is necessary to neutralise the harmful effects of LDL. An inverse correlation has been found between inflammatory activity and serum HDL levels (the higher concentrations of inflammatory cytokines especially IL-6 and TNF α the less the concentration of HDL. Inflammation also plays a key role in the development of atherosclerosis and metabolic syndrome (Esteve, Ricart et al. 2005). As a consequence of atherosclerosis, coronary, cerebral vessels disease ensues thus increasing cardiovascular morbidity and mortality.

Therefore, patients with chronic ocular inflammatory disease taking systemic immunosuppression are at higher risk of developing cardiovascular disease CVD and the risk is even greater when uveitis is associated with systemic inflammation. This combined risk in our group of patients compared to that present cardiovascular disease patients would warrant treatment to reduce high serum cholesterol particularly LDL, to minimise the risk of CVD in our patients given the long-term exposure to corticosteroids and second-line immunosuppressive agent.

Lipids are pro-inflammatory, and macrophages engulfing lipid (foamy cells) is a well-documented finding in atherosclerosis. Thus, when statins down-regulate cholesterol levels, inflammatory activity reduces as well, and this is reflected by a significant reduction in CRP level. The immunomodulatory effect of statins is perhaps more pronounced in coronary artery diseases not only due to blocking the intermediate metabolites in cholesterol biosynthesis pathway as studies have shown (Greenwood, Steinman et al. 2006) but also by indirect anti-inflammatory action in human atherosclerotic disease.

In our study, total cholesterol and LDL reduced significantly in the simvastatin group at 1-year follow-up. Mean cholesterol reduced from 5.36 ± 1.0 SD to $4.41(1.0)$, p-value 0.002 paired sample test and LDL reduced from 2.91 ± 0.72 to $2.05 \pm (1.14)$, (p-value = 0.006, paired sample t-test, two-sided). Our data shows that intensive lipid lowering with simvastatin 80 mg has resulted in a 30% reduction in LDL levels. When comparing the total cholesterol level between patients in both groups, there was a statistically significant difference in mean cholesterol, patients on simvastatin had lower total cholesterol compared to those on placebo (p-value =0.001). The reduction was highly statistically significant early on, and the difference remained significant throughout the follow-up time. When analysing all the three subtypes of cholesterol (LDL, HDL and triglycerides), the effect of simvastatin on total cholesterol was only significant in reducing LDL-cholesterol, which is known to be associated with increased risk of coronary heart disease. Simvastatin significantly reduced LDL-cholesterol and hence the risk of cardiovascular diseases in patients with ocular inflammation. Moreover, in the simvastatin arm, there was a significant reduction in mean CRP level at 1-year follow-up.

This reduction of LDL is still valuable in primary prevention from the atherosclerotic disease in this high-risk group. There is compelling evidence that the lower the LDL cholesterol level, the better the cardiovascular outcome and these data come from the reversal of atherosclerosis with aggressive lipid-lowering therapy (REVERSAL) study (Nissen, Tuzcu et al. 2004), where high dose atorvastatin 80mg was given to patients with coronary heart disease for 18 months. The study showed that high dose atorvastatin was able to arrest the atherosclerotic disease evident by intravascular ultrasound in patients with atherosclerotic disease, patients experiencing mean LDL level of 2.1 on treatment. Similarly, other studies suggest that lower LDL levels are associated with minimized risk of atherosclerotic progression and coronary heart disease (Breuer 2005). Treatment to new target (TNT) study showed that intensive lipid lowering with 80 mg atorvastatin resulted in 22% lower cardiovascular events compared to those treated with lower doses (LaRosa, Grundy et al. 2005). Therefore, additional clinical benefits are gained by the aggressive lowering of LDL on simvastatin in patients with ocular inflammation.

3.22.6 Safety of simvastatin

Simvastatin was safe and was well tolerated by most patients. CK enzyme analysis showed similar results in both groups. Similarly, there was no significant difference in liver enzymes between the two groups. Muscle and joint pain were higher in simvastatin group but these were mild and transient and none of the patients had to stop their trial medication.

3.23 Conclusion

In this randomised placebo-controlled clinical trial, simvastatin did not have a significant corticosteroid-sparing effect in patients with non-infectious, intermediate posterior, and panuveitis, at one and two-year follow-up. Although many in vivo and in vitro studies showed an immunomodulatory effect of simvastatin, in this study, simvastatin did not demonstrate anti-inflammatory effect measured by reduction in daily prednisolone dose. Therefore, there is no evidence to support the immunosuppressive effect of simvastatin in patients with non-infectious ocular inflammatory diseases. The heterogeneity of patients with uveitis and the aggressive

nature of the disease might have contributed to the lack of effect witnessed in the current study.

On the other hand, studies looking at the immunomodulatory effect of simvastatin in other inflammatory diseases in humans have reported positive results. A short course therapy with 80 mg simvastatin was found beneficial in patients with rheumatoid arthritis and SLE. Therefore, simvastatin might have a short-lived immunomodulatory effect, and with longer duration of treatment this effect was lost because the immune system sought alternative pathways to exert an inflammatory response. Therefore, an intermittent courses of high dose simvastatin in uveitis might show a different results, and it is worth exploring. Patients with MS treated with simvastatin had lower rate of brain atrophy compared to placebo. Nonetheless, patients were those with secondary progressive MS where neurodegeneration is more significant part of the disease process in comparison to inflammation. Also, other studies looking at the immunomodulatory effects of statins in patients with relapsing remitting MS where inflammation is part of the disease process reported conflicting results.

In this cohort, the mean total cholesterol was higher than normal, with 60% of patients had high serum cholesterol at baseline. Simvastatin significantly reduced total cholesterol and LDL, which supports the well-established action of simvastatin on serum lipids, and good compliance with the study medication. This reduction in serum lipids is important in reducing the risk of atherosclerotic disease in patients with uveitis on long-term immunosuppressive therapy and might offer patients with chronic ocular inflammatory disease, exposed to long-term corticosteroid-based immunosuppressive therapy, a protection from cardiovascular morbidity and mortality.

Finally, data regarding the risks of cardiovascular disease in patients with uveitis is particularly important in view of the chronic inflammation which could be part of a systemic disease and the well-known side effects of long-term therapy (corticosteroid and other immunosuppressive agents). There are no reports in the literature looking at prevalence and incidence of cardiovascular disease and serum cholesterol among patients with uveitis. This lack of data can make it difficult to establish the benefit of lipid lowering in this population, and this highlights the need for further research.

4 Chapter Four Ocular toxoplasmosis and the role of long-term, low-dose trimethoprim-sulfamethoxazole prophylaxis in recurrent toxoplasmic retinochoroiditis

4.1 Background

Ocular toxoplasmosis is caused by infection with *Toxoplasma gondii*, an obligate intracellular protozoan (Montoya and Liesenfeld 2004). Felines are the definitive hosts while humans' and other vertebrates serve as intermediate hosts (Dubey 2014). Ocular toxoplasmosis is the leading cause of posterior infectious uveitis worldwide in both adults and children (Tabbara 1982, Henderly, Genstler et al. 1987, Holland 2003). It has been reported that 50% of cases of posterior uveitis is attributed to toxoplasma infection (Soheilian, Heidari et al. 2004), and this can reach up to 80% in some regions, especially, when toxoplasma infection is endemic (Fernandes and Orewfice 1996). Infection in immunocompetent individuals is usually self-limiting, but it can lead to permanent loss of vision if it involves the macula or the optic nerve head (Holland 2004).

4.2 Mode of transmission

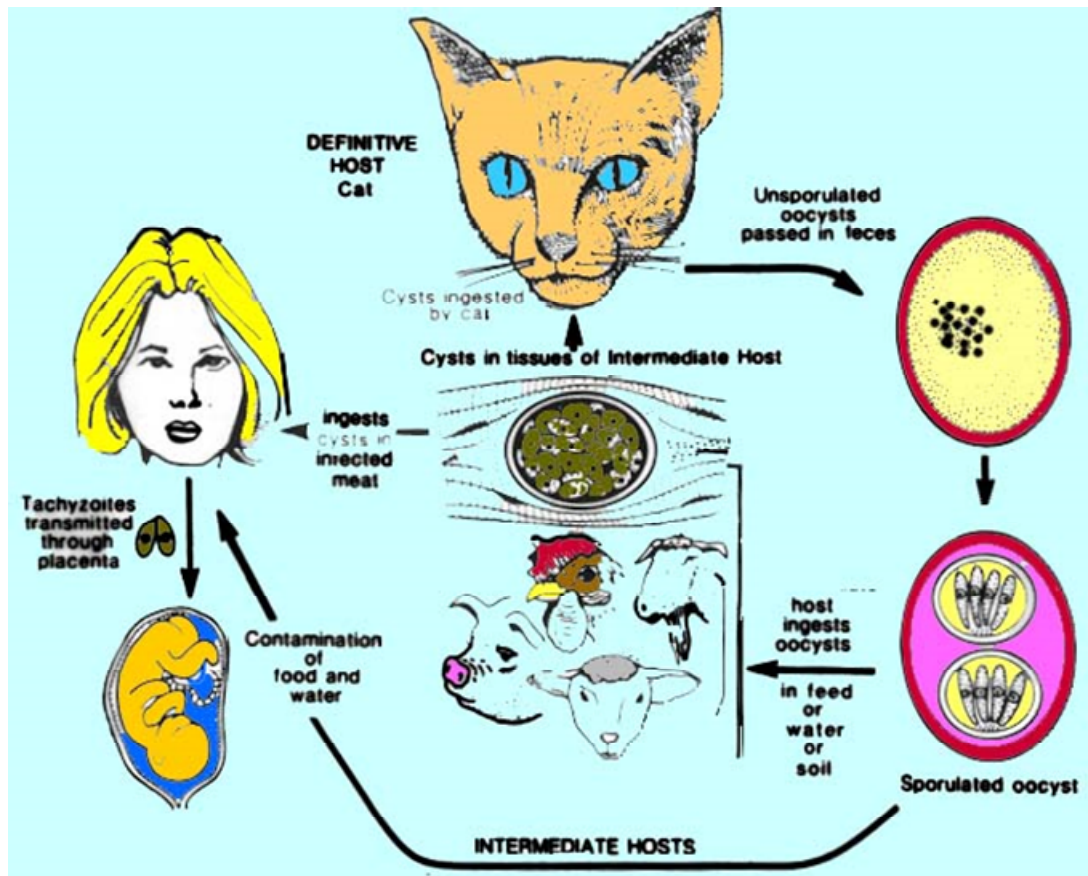
The transmission of *T. gondii* to humans and other animals may occur through accidentally eating food contaminated with oocysts, which are shed in large numbers in infected-cat faeces and contaminate the environment. These oocysts mature in soil and are ingested by the intermediate host or by another cat. Tachyzoites, the proliferative phase of the disease, travel through the circulatory system to invade all host tissues. Then these replicating tachyzoites enter a dormant stage (as bradyzoites) within intercellular tissue cyst in an immunocompetent host which is then transferred to another species. These cysts have a predilection for the neuronal and muscular organs, such as the brain, retina and skeletal muscles. Therefore, when these animals are eaten these tissue cysts get transferred to another warm-blooded species (American Academy of 2017). The life cycle of toxoplasmosis, Figure 4-1.

Toxoplasmosis infection in human may be either acquired or congenital. The main route of transmission include:

- Ingestion of undercooked, infected meat containing tissue cysts.
- Ingestion of contaminated water, fruit, or vegetables with oocysts.
- Accidental contact with cat faeces or soil contaminated with oocyst.
- Primary infection with transplacental transmission during pregnancy.

- Blood transfusion or organ transplantation.
(Silveira, Belfort et al. 1988, Vallochi, Muccioli et al. 2005).

Figure 4-1 the lifecycle of toxoplasma gondii/ Source, Image from Sherris Medical Microbiology 1996



4.3 The life cycle of toxoplasma gondii

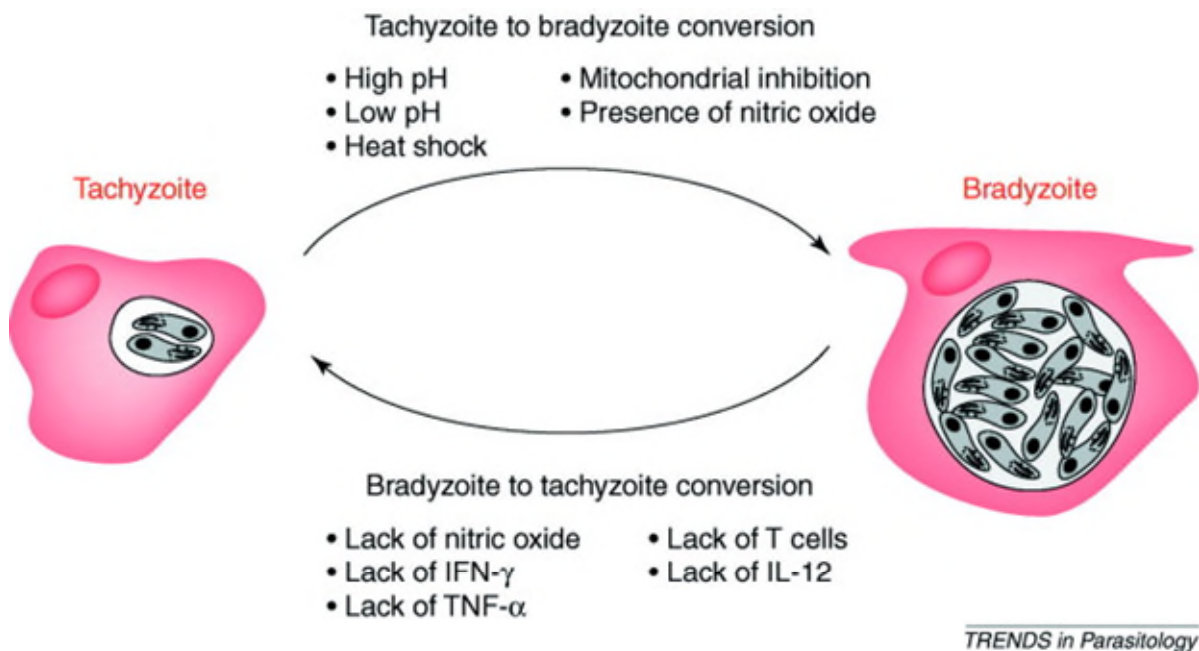
Toxoplasma gondii has a complex life cycle and occurs in three primary forms:

- The oocyst** or soil form (zygote stage); is 10-12µm in size, and is produced by the sexual reproduction of the parasite in feline's intestine before being expelled in faeces. The oocyst sporulates by dividing into sporocysts within 1-5 days after excretion, and each sporocyst contains the four sporozoites.
- The tachyzoites** or the infectious forms; are 4-8 µm in size and have a crescent shape. They can disseminate throughout the body of the intermediate host within macrophages, lymphocytes, or free in plasma. These tachyzoites keep

dividing by endodyogeny (a form of asexual reproduction, in which two daughter cells are generated by internal division within the host cell, which is then consumed by the offsprings and bursts prior their separation. The liberated tachyzoites then infect another cell and repeat the process or these infective tachyzoites may transform to bradyzoites and form a tissue cyst. The trigger for this transformation is unknown. However, it was hypothesised that an immune-mediated process might force tachyzoites to transform to bradyzoites and form tissue cyst. Nitric oxide (NO) secretion by the parasite-infected macrophages reduces the multiplication of the parasites and force them to transform to a bradyzoites stage. Also, other cytokines and immune cells are implicated in this process (Lyons, McLeod et al. 2002). Figure 4-2.

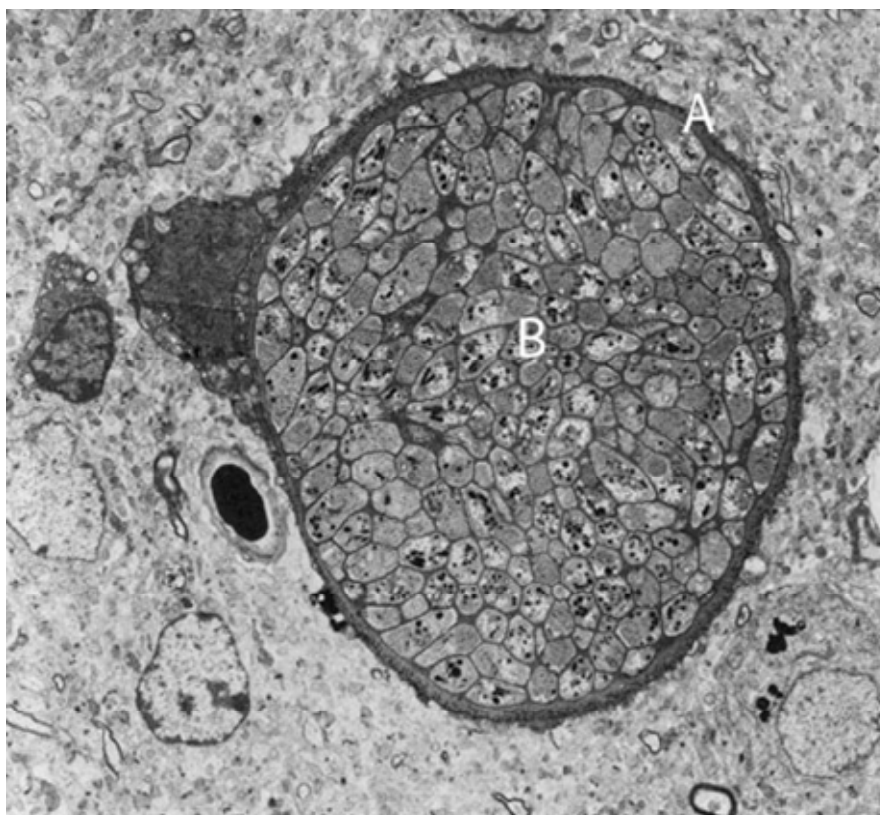
C. Bradyzoites are slow replicating, encysted form of the parasite. They only slightly differ from tachyzoites in that the nucleus is situated at the end, while in tachyzoites the nucleus is centrally located. Also, bradyzoites contain several amylopectin granules which are very scarce or absent in tachyzoites. Compared to tachyzoites, bradyzoites are less susceptible to destruction by proteolytic enzymes than are tachyzoites (Dubey, Lindsay et al. 1998).

Figure 4-2 factors involved in tachyzoites-bradyzoites interconversion (Lyons, McLeod et al. 2002)



D. The tissue cyst or (latent form) is 10-200 μm in size and contains as many as, 3000 bradyzoites. Figure 4-3. Newly formed cysts are smaller in size, but they expand to accommodate the increasing parasitic population produced by asexual replication of bradyzoites. These bradyzoites can divide within the intact cysts and may not cause any inflammation and remain for life. Tissue cysts have low immunogenicity because they develop within the host cell cytoplasm and their wall is not only intimately related to the host cell, but it is also part of it (Petersen, Dubey et al. 2001). Classically, these cysts rupture and bradyzoites switch back to tachyzoites, and when these are liberated, they cause severe inflammation and destruction due to the release of lytic enzymes and parasitic antigens. Interestingly, a mother cyst can split into several cysts, and bradyzoites can also move from one cell to infect another leaving the previous cell intact, implying a mechanism for dissemination even during latent infection. The parasite then infects other sites and forms new cysts, thus, maintaining a prolonged infective stage (Petersen, Dubey et al. 2001).

Figure 4-3 Tissue cyst in mouse brain on electronic transmission microscopy A cyst wall, B bradyzoites (Cenci-Goga, Rossitto et al. 2011). Photo by Dr. Marcello Tosti, Veterinarian, Perugia



Tissue cyst is a very important step in the life cycle of toxoplasma. Tissue cyst can form as early as three days in mice after infection with tachyzoites and with time the number within these cysts increases. With the chronic stage of infection and development of an immune response in host, more tissue cysts will form, and these can assume different shapes depending on the site. For example, in the brain, tissue cyst is usually spheroidal and smaller in size compared to intramuscular cysts which tend to be larger and more elongated. Older tissue cysts may contain degenerated bradyzoites (Dubey, Lindsay et al. 1998).

Tissue cysts rupture every now and again and cause tissue necrosis and inflammation. The host immune status plays a vital role in containing the released parasites by either directly destroying them or forcing them to form a new tissue cyst. Therefore, the reactivation of chronic infection may be partly related to interference with the host immune system responses (Gazzinelli, Denkers et al. 1993).

4.4 Epidemiology

Nearly one-third of the world population is infected with toxoplasmosis, infection is mainly acquired, and is usually subclinical, but a small proportion of patients will develop cervical lymphadenopathy or ocular disease (Montoya and Liesenfeld 2004). The seropositivity among healthy subjects varies dramatically throughout the world with 3% to 10.8% in the US and 50%-80% in France. Despite high seropositivity for toxoplasmosis, only 2-3 % of postnatally acquired toxoplasmosis will have an ocular disease (Fernandes and Orefice 1996, Vasconcelos-Santos, Machado Azevedo et al. 2009). Among HIV-infected patients, toxoplasmosis ranges from 15%- 40% (American Academy of 2017).

This considerable variation in disease prevalence depends on geographic, socioeconomic and climate factors. For example, in Southern Brazil, toxoplasma infects between 42-83% of the population, while in Eskimos the seroprevalence is 0% (Oréfice and Bahia-Oliveira 2005), because, tropical environments encourage the maturation of the oocyst (Montoya and Liesenfeld 2004). Another factor is the virulence of the parasite. In the US the prevalence of toxoplasmosis among the general population is 22.5%, but only 2% of those infected develop an ocular disease. In contrast, in Southern Brazil where 80% are infected with toxoplasma, 18% of those

have evidence of toxoplasma retinochoroiditis owing to more virulent strains (Khan, Jordan et al. 2006).

There are three different strains of *T gondii*, and these are I, II, and III, in addition to recombinant atypical genotypes (Ajzenberg, Banuls et al. 2004). These distinct clonal lineages vary in their virulence. Most infections in humans in North America and Europe are associated with the type II parasite which is less virulent than type I. In Brazil where type I is more prevalent (Khan, Jordan et al. 2006), the prevalence of the congenital disease is very high, 1 in 770 live births and the percentage of ocular infection reaches up to 80% of those infected (Fernandes and Orewfice 1996, Vasconcelos-Santos, Machado Azevedo et al. 2009). Moreover, in Brazil, there is a higher risk of disease recurrences compared to Northern European inhabitants (Gilbert, Freeman et al. 2008). In this study, Brazilian children with congenital toxoplasma infection have a five times greater risk of developing new eye lesions that are bigger and multiple and more likely to affect the central vision than those in Northern Europe. These differences also support the predominance of the more virulent strain in Brazil compared to Europe. It is hypothesised that the variation in ocular involvement and disease severity across the globe may be related to the virulence of the parasite, with type I having more aggressive disease and higher rates of ocular involvement (Khan, Jordan et al. 2006).

Initially known as a congenital disease, toxoplasma is now well-recognised as an acquired (postnatal) infection (Friedman, Luntz et al. 1982). Reports from water-borne outbreaks in Canada, Brazil and India confirm this (Talabani, Mergey et al. 2010). A study in southern Brazil reported much higher disease prevalence in older individuals compared to younger subjects (1-8 years), the figures were (21.3%) and (0.9%) in older and younger subjects, respectively (Glasner, Silveira et al. 1992). Also, the development of ocular disease in siblings of an immunised mother is another strong evidence in favour of acquired disease (Talabani, Mergey et al. 2010). It is becoming clear that postnatally acquired infection contributes to a significant proportion of ocular toxoplasmosis in children and adults (Glasner, Silveira et al. 1992, Fernandes and Orewfice 1996, Oréfice and Bahia-Oliveira 2005). A study reported that two-thirds of ocular toxoplasmosis is attributed to acquired infection (Vasconcelos-Santos 2012).

Postnatally acquired disease is usually systemically asymptomatic, and even when symptoms are present, they are usually mild and nonspecific (including lymphadenopathy and constitutional symptoms lasting 2-4 weeks). A small proportion may present with severe disease (meningoencephalitis, arthralgia and maculopapular rash (Montoya and Liesenfeld 2004). The current estimate of ocular disease in this setting ranges between 2-3% or maybe even higher in endemic areas (Glasner, Silveira et al. 1992, Holland 2003).

Distinguishing clinically between congenital and acquired disease can be difficult. However, bilateral ocular involvement is more common in congenital cases and leads to a profound vision loss due to frequent macular involvement, whereas, in those with acquired infection bilateral ocular disease is less common. Delair and associates reported bilateral disease in only 4% in patients with acquired infection versus 43.5% in those with congenital disease ($p < 0.0001$) (Delair, Monnet et al. 2008).

The frequency of ocular toxoplasmosis increases with age. A cross-sectional study in Brazil, where toxoplasma is endemic, found that nearly 50% of subjects above 60 years old have ocular lesions, and elderly patients are at higher risk of developing ocular involvement after recently acquired infection (Portela, Bethony et al. 2004). In line with this, another group reported that primarily acquired infection was more common in older patients whereas disease reactivation (active lesions next to old scar) were more common in younger patients (P -value < 0.001). Moreover, primary infection with toxoplasmosis in elderly was associated with more severe ocular inflammation (p -value < 0.001) (Bosch-Driessen, Berendschot et al. 2002). Ocular involvement in the acute phase of infection, which was reportedly higher in elderly patients, is attributed to a decline in cell-mediated immunity at an advanced age. This finding may explain why elderly patients have large lesions and poor visual outcomes (Bosch-Driessen, Berendschot et al. 2002).

A study by Arantes and associates, in a highly endemic area in Brazil, found that 69% of patients (182 out of 261) with a positive IgM had symptoms of systemic disease. Among those with infection but without ocular involvement at baseline, more than 60% developed eye disease within the next ten years, and over 75% of these patients experienced recurrent toxoplasmic retinochoroiditis. The period for most significant risk for necrotising retinochoroiditis after acute infection was during 0-48 months when

0 is time for first IgM positive test, and almost 50% of patients had the disease by the end of this interval. In those without retinal lesions at baseline, there was a higher risk of developing ocular disease among older people >40 years compared to younger subjects (hazard ratio=4.47, 95%CI= 1.67-11.93, (p-value=0.003). Also, these lesions tend to be larger in older patients. (Arantes, Silveira et al. 2015). The author concluded that age is a risk factor for developing the ocular disease.

An interesting observation was the finding that early treatment of systemic toxoplasmosis infection might reduce the risk of ocular involvement. In Arantes and associates study, patients who received anti-toxoplasma drugs had less risk of ocular involvement. They have speculated that anti-parasitic treatment may protect against ocular involvement by reducing the parasite load in the body and therefore making the ocular infection less likely (Arantes, Silveira et al. 2015). However, the authors acknowledged the fact that they were not able to determine whether the effect of initial treatment has long-lasting protection against ocular disease. If such protection exists this may warrant initial treatment for recently infected patients and assessment of its long-term benefits. However, identifying those at risk is challenging as the infection is mostly asymptomatic. Targeted screening for individuals at risk such as family members of an infected patient could be possible due to the possibility of similar exposure (Jones, Bonetti et al. 2015).

4.5 Pathogenesis of toxoplasmosis

Acute toxoplasmosis infection in an immunocompetent subject will usually result in an asymptomatic infection or sometimes produces a picture similar to infectious mononucleosis (transient lymphadenopathy, fever, malaise and myalgia) (Anderson and Remington 1975). However, infection early in pregnancy (congenital toxoplasmosis) or in an immunocompromised individual gives rise to more aggressive disease which could be even fatal. Because tachyzoites, the active form of the parasite, are capable of invading all nucleated cells. They replicate and lyse the host cell before moving to the adjacent ones. Therefore, without a competent host immune system, the infectious process continues, and more extensive damage will ensue (Petersen, Dubey et al. 2001). The latent phase of the disease, mediated by the transformation of tachyzoites into bradyzoites encapsulated within the tissue cyst in various organs, represents a significant burden of toxoplasma infection. Usually, these

bradyzoites are slow growing, inactive, and therefore rarely initiate an inflammatory response (Petersen, Dubey et al. 2001).

Another critical issue in the pathogenicity of this parasite is that it is hidden from the immune system, particularly the humoral responses (secreted antibodies, complement proteins and antimicrobial peptides) because the parasites are intracellular. Cell-mediated immunity is necessary for disease control, and this process is dominated by the secretion of interferon- γ (INF- γ) by T cells. INF γ plays a protective effect by being able to activate macrophages to suppress the replication of the toxoplasma organism. The role of T cells in combating toxoplasma infection is also supported by the fact that there is an increased risk of toxoplasma reactivation in Hodgkin's lymphoma, immunosuppressed and in HIV infected patients, where a high incidence of toxoplasmic encephalitis and retinochoroiditis is associated with a decline in the T cell population. (Petersen, Dubey et al. 2001). Serological studies have also shown that most toxoplasma infections in AIDS are latent (Israelski and Remington 1992). Importantly, failure of cell-mediated immune response leads to a fulminant disease course.

Toxoplasmic encephalitis is common among immunocompromised patients and infants with congenital infection. The brain and the retina are common places where cysts can be present in large numbers and reactivate causing local inflammation. Several factors mediate the infection of these immune-privileged sites. Firstly, the presence of blood-retinal and blood-ocular barriers, restrict the transvascular migration of immune system elements such as cells, cytokines and antibodies. Secondly, in the brain and the eye, there is a lack of lymphatics, along with the scarcity of MHC complex expression. Finally, the ability of the glial cells to suppress T cells responses allows the replication of the organism. All these factors make neuronal and ocular tissue a favourable environment for the tissue cysts to persist and reactivates (Petersen, Dubey et al. 2001).

Animal studies have shown that even normal looking retina can harbour tissue cysts (Pavesio, Chiappino et al. 1995). Retinal vasculitis and photoreceptor destruction have been documented in areas away from the organism. The loss of photoreceptors due to toxoplasma infection mimicked the picture caused by autoimmune diseases when the body immune system gets sensitised to retinal antigens (Petersen, Dubey et al.

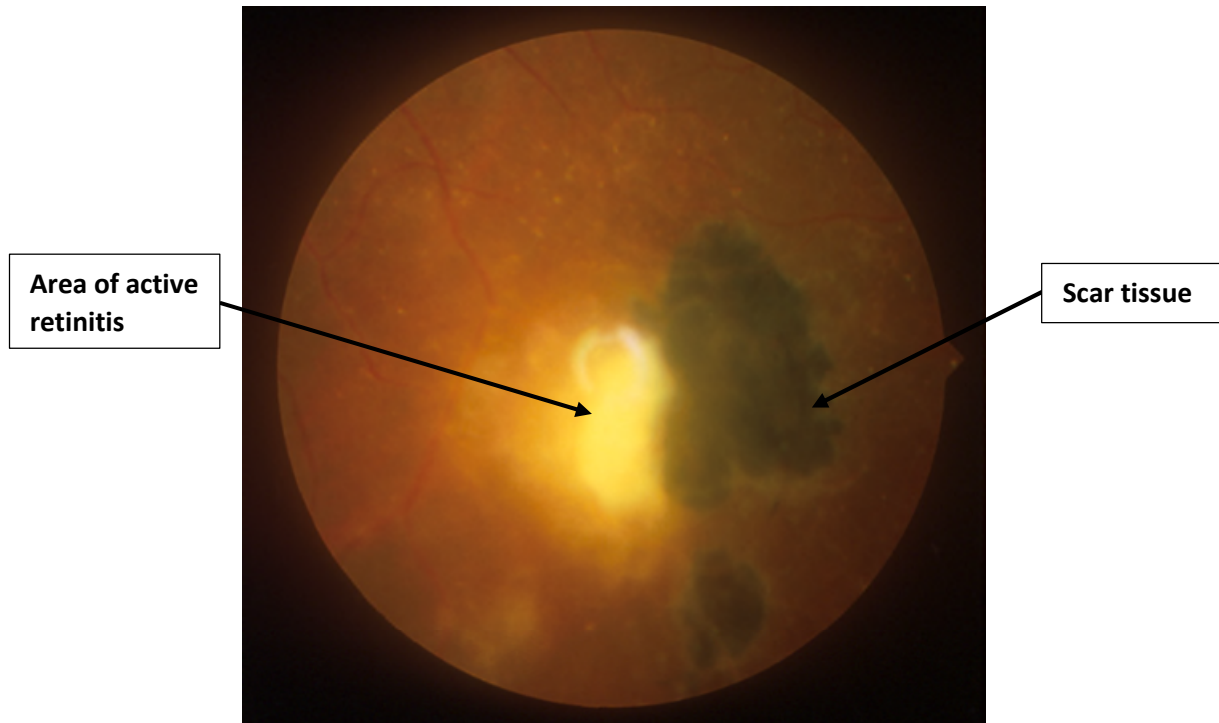
2001). Similarly, in man with focal retinochoroiditis, there is widespread retinal destruction and loss of photoreceptors with pigmentary retinopathy mimicking retinitis pigmentosa. On histopathological sections, there is a loss of photoreceptors which may suggest an autoimmune process directed against retinal antigens secondary to the parasitic infection (Silveira, Belfort et al. 1989).

4.6 Clinical presentation of ocular toxoplasmosis

The signs and symptoms of ocular toxoplasmosis vary with age. For example, children with congenital infection usually present with reduced vision, strabismus, nystagmus, leukocoria, choroidal coloboma and microphthalmia (small eye), whereas adults usually present with reduced vision, floaters and occasionally pain and photophobia. A mild granulomatous anterior uveitis may also be present. The site of the lesion within the retina also plays a role. For instance, peripheral lesions with minimal inflammation may be completely asymptomatic, while central lesions present with severe vision loss. The associated inflammation in the vitreous also produces blurred vision or haziness with floaters. The two most common causes of vision loss are macular scarring and vitreous opacities. Also, up to 20% of patients will develop a rise in intraocular pressure (Mets, Holfels et al. 1996).

The retina is the primary site for infection, and the choroid is secondarily affected. The disease usually starts at the inner retina and progresses with time to involve the choroid or even the sclera and optic nerve (Eckert, Melamed et al. 2007). A severe acute anterior uveitis might occur with mutton fat keratic precipitates and posterior synechiae (Nussenblatt and Belfort 1994). Classically, toxoplasma reactivation tends to occur at the edges of an old pigmented scar, and manifests as a focal area of necrotising retinochoroiditis with overlying vitreous inflammation. Figure 4-4. These appear as grey-white areas of retinal necrosis associated with vitritis, which is a universal finding in active disease and gives to characteristic “headlight in the fog” appearance. These lesions occur commonly in the posterior pole but it can sometimes be adjacent to or directly involving the optic nerve, being mistaken for optic neuritis. Recurrent lesions usually occur at the margin of old retinochoroidal scars. However, they can also develop at sites distant from the primary lesion (Foster and Vitale 2013). Retinal vessels may also become inflamed and show perivasculitis with diffuse venous sheathing and patchy arterial plaques (Kyrieleis arteriolitis).

Figure 4-4 Classical reactivation of ocular toxoplasmosis at the edge of a previous scar. Source Moorfields Eye Hospital



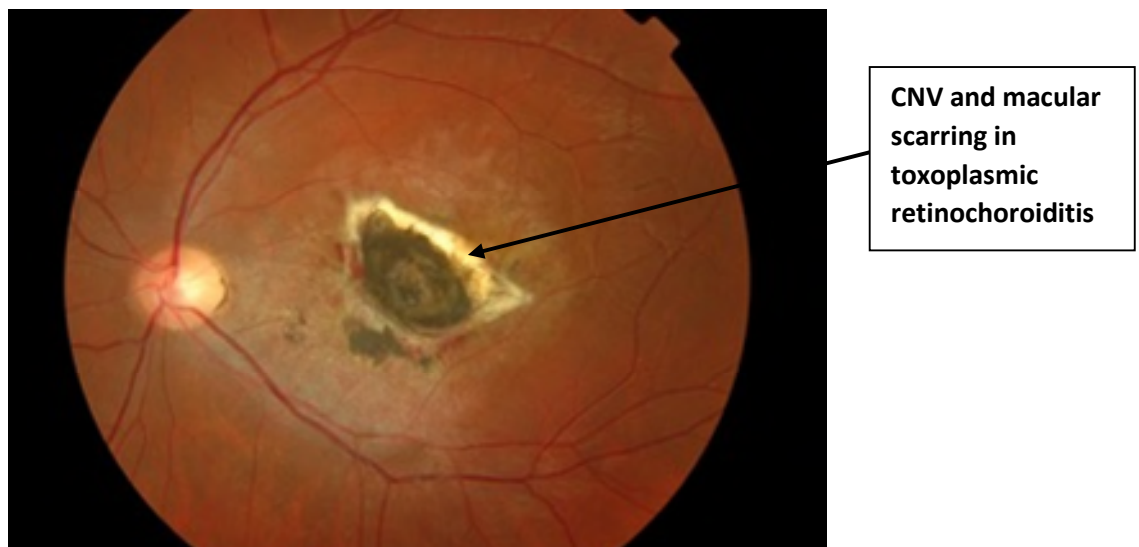Another less common presentation in ocular toxoplasmosis is punctate outer retinal toxoplasmosis (PORT). Small, multifocal, grey-white lesions at the level of the outer retina feature PORT. It is usually associated with subretinal exudation and minimal overlying vitreous inflammation (Doft and Gass 1985). An atypical presentation such as papillitis (inflammation of optic nerve head), neuroretinitis and extensive necrotising retinitis in immunocompromised hosts are also well-known.

Disease duration and severity vary, and the reasons are poorly understood but, the disease is a product of a complex interaction between parasite, host and environmental factors (Holland 2004). Larger lesions (more than one disc diameter) tend to persist longer and have higher rates of complications and vision loss compared to smaller lesions (Friedmann and Knox 1969). Rothova et al. also reported that more extensive lesions are associated with a longer duration of inflammation (Rothova, Meenken et al. 1993).

4.7 Complications of ocular toxoplasmosis

Ocular complications from toxoplasmosis are not uncommon, and these can result from the acute infection or the secondary complications. Since there is no curative treatment, the risk of complications and vision loss increases with each disease relapse. The most common complication arises from permanent structural damage to ocular structures (Reich and Mackensen 2015). Toxoplasmosis causes profound visual impairment if it involves structures critical to sight (fovea and optic disc) leading to foveal scarring and optic nerve atrophy which usually develops when toxoplasma lesions directly involve the optic nerve head, the peripapillary area or papillomacular bundle. Figure 4-5 (foveal scar) (Commodaro, Belfort et al. 2009, Jakob, Reuland et al. 2009, Petersen, Kijlstra et al. 2012).

Figure 4-5 Toxoplasmosis scar at the macula with permanent loss of vision. Source Moorfields Eye Hospital.



Reduction in vision can also result from vitreous debris, which can occur after an episode of severe inflammation. These take time to resolve, and sometimes vitreous debris can persist for several years after complete resolution of the inflammation. Furthermore, severe vitreous inflammation can predispose to posterior vitreous detachment and even retinal detachment in severe cases (Bosch-Driessen, Karimi et al. 2000). Proliferative vitreoretinopathy and contraction of fibrous bands maybe complicated by vitreous haemorrhage and tractional or rhegmatogenous retinal

detachment (RD). Additional ocular complications which can follow an acute episode of inflammation include; cataract, cystoid macular oedema, epiretinal membrane, macular hole and choroidal neovascular membrane (CNV) (American Academy of 2017). Younger patients tend to be at higher risk for these complications (Bosch-Driessen, Karimi et al. 2000).

Other complications include secondary ocular hypertension and glaucoma which usually results from mechanical obstruction of the trabecular meshwork with fibrin, or inflammatory cells and debris (Westfall, Lauer et al. 2005). Retinal vascular occlusion (mostly venous) can also develop, especially when a retinal vessel crosses an active toxoplasmic lesion. Choroidal neovascular membrane (CNV) is also associated with ocular toxoplasmosis secondary to destruction of Bruch's membrane. Finally, phthisis bulbi may rarely occur in inadequately treated severe cases of ocular toxoplasmosis (Bonfioli and Orefice 2005, Oréfice and Bahia-Oliveira 2005).

4.8 Types of ocular toxoplasmosis infection

4.8.1 Congenital toxoplasmosis

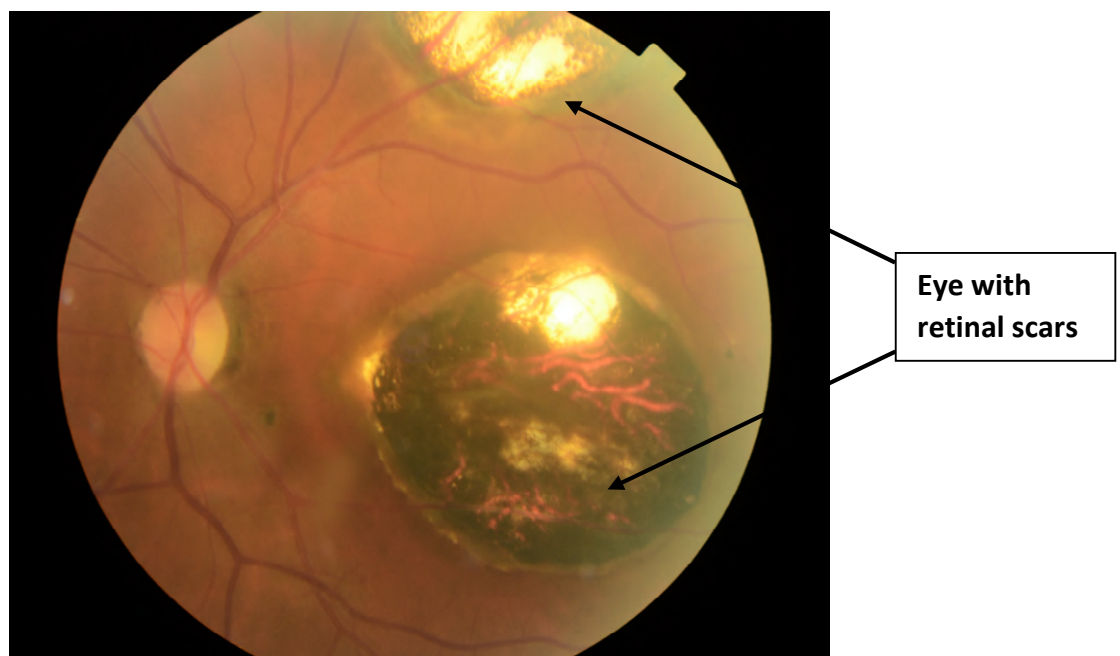
Congenital toxoplasmosis has severe complications on the developing foetus and occurs when the mother becomes infected for the first time during pregnancy. The parasite disseminates throughout the body, crosses the placenta and infects the foetus before a sufficiently protective immune response can be mounted. Thus, during the first trimester of the pregnancy, the parasite can cause substantial damage due to the immaturity of the foetal immune system whereas later on in pregnancy the immune system of the foetus can better cope with the infection resulting in subclinical disease. As a consequence, the risk of disease severity in the baby is inversely related to the gestational age. Infection early in pregnancy is commonly associated with severe disease in the foetus and may end in abortion whereas, later in pregnancy, it may result in subclinical disease (normal appearing infant with latent infection). The rate of transplacental transmission rises from approximately 10-17 % in the first trimester to 65% in the third trimester (Dunn, Wallon et al. 1999). Chronic or recurrent maternal infection during pregnancy does not carry a risk of congenital disease owing to maternal immunity which prevents transplacental infection (Kump, Androudi et al. 2005).

Congenital infection of the retina is associated with recurrent disease relapses in adult life. The exposure of the immune system to toxoplasma earlier in life may have altered the immune responses to the parasite. One theory is that T cells developed tolerance to toxoplasma antigens after being exposed to the parasite earlier in development and are therefore inefficient in disease control (Kump, Androudi et al. 2005).

4.8.2 Clinical features of congenital toxoplasmosis

Congenital toxoplasmosis classically includes retinochoroiditis. Other features such as hydrocephalus or microcephaly, intracranial calcification and cognitive damage (Sabin's triad) have been reported in approximately 10% of infected children. Retinochoroiditis is the most frequent manifestation of congenital toxoplasmosis and is present in up to 80% of infected newborns. The lesions are typically bilateral in 85% of children and have a propensity for the posterior pole and macula. Figure 4-6. Nearly half of these patients might have active lesions at presentation especially if the mother was not treated during pregnancy (Guerina, Hsu et al. 1994, Kodjikian, Wallon et al. 2006, Vasconcelos-Santos, Machado Azevedo et al. 2009).

Figure 4-6 Congenital toxoplasma infection with retinal scarring. Source Moorfields Eye Hospital.



Additional chorioretinal scarring develops in 90% of infected newborns before adulthood (Koppe, Loewer-Sieger et al. 1986, McLeod, Boyer et al. 2006, Phan, Kasza et al. 2008) and as many as 85% of infected children will develop retinochoroiditis after a mean age of 3.7 years and 25% of these become blind in one or both eyes (American Academy of 2017). Phan et al. reported that between the age of 2-10 years 72% developed at least one new retinal lesion and over 50% were central in location (Phan, Kasza et al. 2008). Where with antenatal and postnatal treatment, only 9% had ocular lesions at birth, and these were mostly at the macula. New lesions developed in only 13% of infected children and were mainly peripheral (Faucher, Garcia-Meric et al. 2012). Therefore, antiparasitic therapy for the newborns with congenital toxoplasmosis is recommended by most experts during the first year of life to reduce disease burden, irrespective to the presence of ocular or systemic signs (American Academy of 2017).

4.8.3 Toxoplasmosis in the immunocompromised host

Retinochoroiditis developing in immunocompromised patients can have a very dramatic presentation with extensive retinal involvement because the host immune system which limits disease severity is usually defective or even absent (Talabani, Mergey et al. 2010). Immunocompromised and elderly patients can present with atypical findings, including, large, multiple and bilateral lesions in the presence or absence of chorioretinal scars, with a picture similar to viral retinitis (Holland, Engstrom et al. 1988). A similar picture can also be seen in patients receiving corticosteroids therapy without antimicrobial drugs (American Academy of 2017).

Immunocompromised patients are at higher risk of toxoplasmosis, and this could be either due to reactivation of latent disease or recently acquired infection. It usually has a severe and fulminant course and could be even fatal if left untreated (Montoya and Liesenfeld 2004). The parasite has a great propensity for the CNS. Therefore, toxoplasmic encephalitis is prevalent in AIDS patients (Cohen 1999). A relapse of toxoplasma encephalitis develops in at least 50% of patients without suppressive chemotherapeutic treatment, and these relapses are usually seen on imaging at the edge of an old lesion, (Haverkos 1987). Also, AIDS patients not taking antiretroviral therapy are prone to extensive and recurrent disease (Holland, Engstrom et al. 1988).

Therefore, treatment is necessary because toxoplasmosis infection is not only sight-threatening but also life-threatening (Talabani, Mergey et al. 2010).

Similarly, elderly subjects and patients on immunosuppressive therapy are at risk of ocular toxoplasmosis and may present with a picture similar to those with AIDS. Elderly patients can present with severe vitritis, large and multiple ocular lesions and a prolonged disease course (Talabani, Mergey et al. 2010). In immunocompromised patients, the rampant proliferation of *Toxoplasma gondii* appears to be responsible directly for the retinal damage while the immune reaction from the host is much less evident (Yeo, Jakobiec et al. 1983).

The lung can be involved in these patients leading to pneumonitis and respiratory failure (Montoya and Liesenfeld 2004). Concomitant CNS involvement in ocular toxoplasmosis is reported between 25-50% of patients with AIDS, therefore a neurological examination is warranted (Cohen 1999) (Gagliuso, Teich et al. 1990).

4.9 Diagnosis

Diagnosis of ocular toxoplasmosis is made clinically by demonstration of an active retinal lesion adjacent to a pigmented retinochoroidal scar. However, serological tests help to confirm the diagnosis when ocular toxoplasmosis presents oddly. The Sabin-Feldman dye test is the gold standard technique to identify anti *T.gondii* antibodies. Other tests include complement fixation, hemagglutination and immunofluorescent antibody tests. The latter is useful for detecting an early rise in serum antibodies and quantifies IgG and IgM levels. Enzyme-linked immunosorbent assay (ELISA) is the most commonly used test and has a high sensitivity in detection of IgM antibodies for several months after acute infection (Montoya and Liesenfeld 2004) (Bonfioli and Orefice 2005) (Weiss, Velazquez et al. 1990).

Early during the acute infection IgM specific for toxoplasma typically increases in amount and remains detectable for less than a year, but it does not cross the placenta. On the other hand, IgG antibodies appear after the first two weeks of infection and remain for life but with variable levels. The presence of anti-toxoplasmic IgG supports the diagnosis of infection at some time while a negative test rules out the infection in most patients. The presence of IgM in a newborn baby confirms congenital infection

while in adults it indicates an acquired disease. IgA antibody is also useful in diagnosing congenital infection but usually disappears after seven months. The presence of IgG may be indicative of passive transplacental transfer from the maternal side and during early infancy when the production of IgM may be weak.

Intraocular production of anti-toxoplasma antibody may be measured using Goldmann-Witmer coefficient, and a ratio of more than 3 is regarded as diagnostic of local antibody formation. Polymerase Chain Reaction (PCR) is used to detect the parasite DNA, and this test is useful when patients present with atypical features. Both aqueous and vitreous samples can be used with a 50% and 25% sensitivity, respectively (Montoya, Parmley et al. 1999, Garweg 2005).

4.10 Mechanisms of relapsing toxoplasmic retinochoroiditis

Recurrent attacks of necrotising retinochoroiditis characterise ocular toxoplasmosis. On long-term follow-up, disease relapse occurs in as high as, 79% of patients, and nearly, one-fourth of patients will develop legal blindness ($VA \leq 6/60$) in at least one eye (Bosch-Driessen, Berendschot et al. 2002, Holland 2003). The exact mechanism of these episodes is not fully understood; however, there are several hypotheses. Rupture of intraretinal cysts with the release of active parasites and antigenic materials that trigger an inflammatory reaction and necrosis seems a plausible explanation.

Several mechanical factors may contribute to rupture of tissue cyst. Firstly, multiplication of the parasite with subsequent enlargement of the parasitic population within the tissue cyst can stretch the cyst leading to its rupture. Secondly, the release of toxins or lytic enzymes by the parasite or lysis of the host cell membranes can also lead to cyst rupture with subsequent release of the parasite or its antigens (Pavesio and Lightman 1996). Furthermore, an immune-mediated mechanism was proposed as a cause of recurrent disease. The theory is that retinal S antigens (arise from previous retinal damage and release of self-antigens) trigger an immune response (Nussenblatt, Mittal et al. 1989). Alternatively, host immune responses whether cellular or humoral to toxoplasma antigen can lead to reactivation of ocular disease (O'Connor, 1983).

Hormonal changes also appear to contribute to rupture of tissue cyst and subsequent disease reactivations, disease recurrences have been reported to increase in pregnancy (Garweg et al., 2005). Trauma is another factor, an increased incidence of recurrences after cataract surgery has been reported (Bosch-Driessen et al., 2002b). Finally, recirculation of parasites or reinfection with different strains have also been suggested as causes of recurrent disease (Huskinson-Mark, Araujo et al. 1991, Bosch-Driessen and Rothova 1999) (Pavesio and Lightman 1996, Araujo, Slifer et al. 1997), or seeding from circulating toxoplasma parasites in the peripheral blood (Silveira, Vallochi et al. 2011).

Recurrences are associated with progressive ocular damage and a high risk of blindness particularly if the scar enlarges to involve the fovea or the optic nerve head (Commodaro, Belfort et al. 2009). Further, vision loss may arise from secondary complications, such as retinal detachment, choroidal neovascularization or glaucoma. Therefore, chronic toxoplasmosis is a significant health issue because it leads to significant visual impairment.

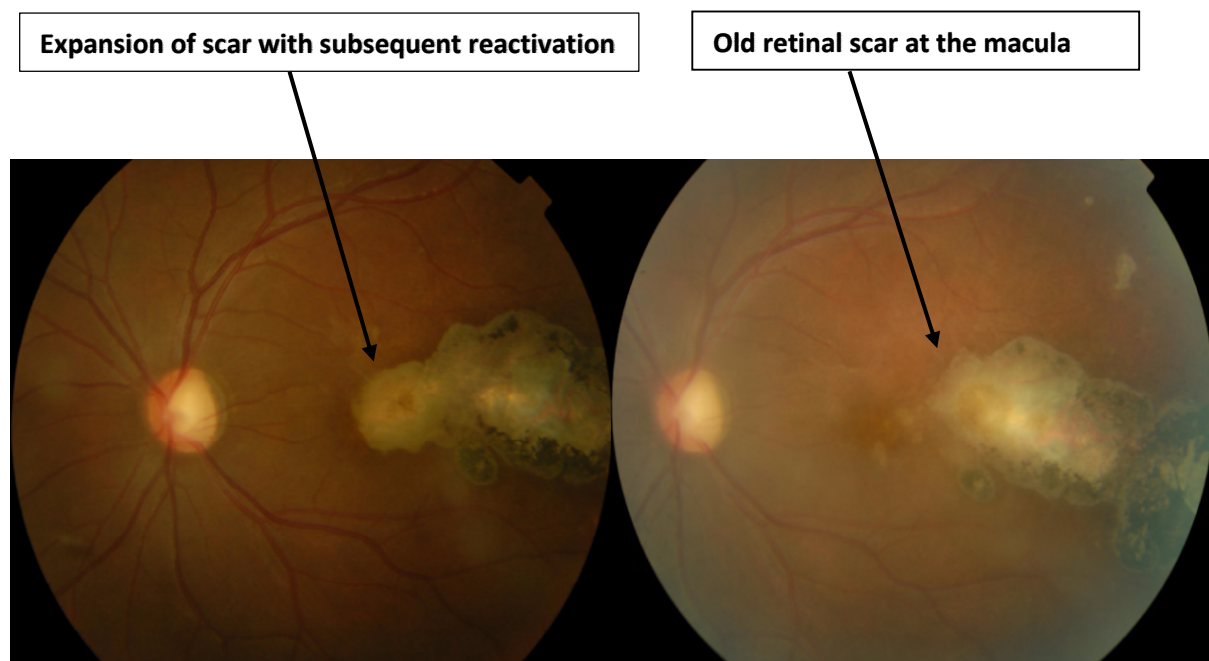
The timing of these recurrences is unpredictable and differs significantly between individuals (Silveira, Belfort et al. 2002). The risk of disease recurrence varies throughout a lifetime (Holland, Crespi et al. 2008). Recurrences occur predominantly in adolescent and young adults (Friedmann and Knox 1969, Bosch-Driessen, Berendschot et al. 2002, Holland 2004) and occur more frequently after the acute episode (Holland, Crespi et al. 2008). Garweg and co-authors have also confirmed that younger patients tend to have a higher risk of developing disease recurrences than older subjects (Garweg, Scherrer et al. 2008).

The exact reason why younger patients tend to have higher disease relapses is unknown. However, Holland et al. speculated several mechanisms. Firstly, a greater parasite burden in young individuals could be responsible for the high risk of recurrence. Secondly, with time there will be less viable tissue cysts in the retina and therefore less risk of disease recurrence. Thirdly, it may be that viable tissue cysts are sequestered in the retina over time by progressive scarring which makes the release of organisms more difficult. Finally, the stimuli for reactivation may decrease over time. However, if the reactivation does occur, the retina will be repopulated with new tissue

cysts resulting in subsequent disease flare-ups which may explain the occurrence of subsequent relapses in clusters (Holland, Crespi et al. 2008).

In the literature there is a discrepancy between the proportion of patients with recurrences and this may reflect different disease duration in these populations (younger patients with the recently acquired disease are at high risk of disease recurrence compared to those who had the disease for a long time). Rothova et al. reported a 2.7% cumulative risk of recurrences at one year (Rothova, Meenken et al. 1993), while Bosch-Driessen and co-authors stated that the risk is 29% at one year (Bosch-Driessen and Rothova 1999). All patients in the Bosch study were to have had a recently acquired infection while those in Rothova's study had had a remote infection when they were first examined (Holland, Crespi et al. 2008). However, in their work Bosch-Driessen and associates have found that recurrences are not associated with the primary treatment patients received for acute episodes, mode of transmission (congenital versus acquired) or the size of the lesions (Bosch-Driessen, Berendschot et al. 2002). Figure 4-7.

Figure 4-7 Reactivation of macular toxoplasmic retinochoroiditis lesion with subsequent loss of vision due to foveal involvement in a patient in the control group (without co-trimoxazole prophylaxis). Source Moorfields Eye Hospital.



The recurrence rate for Europeans ranges between 57%-79% (Bosch-Driessen et al., 2002a). There is a higher risk of disease recurrences in the first two years after the first episode. Among Europeans, Garweg et al. reported that disease recurrences are more common in younger subjects (<21 years) compared to older ones and after each episode, two-thirds of patients will develop another relapse, with an interval of 1 to 1.7 years between first three successive disease flare-ups (Garweg et al., 2008b). Recurrences occur in approximately 4 out of 5 patients who had been followed-up for more than five years (Bosch-Driessen et al., 2002a).

Holland et al. in his study of 143 patients, reported that disease recurrences usually occur in clusters and the risk of a recurrence was highest immediately after an acute episode and then diminished as the patients continued without disease relapse. After the acute episode, the risk of relapse of ocular toxoplasmosis decreases with time, and longer disease duration since the first episode was strongly associated with decreased risk of recurrences. Nonetheless, even after an extended period of disease-free relapse, patients remain at risk of recurrence (Holland et al., 2008a). What is interesting in the previous study and in agreement with the results of Garweg and associates was that age more than 40 years (at time of a given episode) was associated with lower risk of recurrences in univariate analysis. Similarly, the multivariate analysis suggests that contracting the disease at a later age was associated with lower risk of recurrences. These studies have important implications for disease management particularly the need to prevent relapses after an acute episode especially in young subjects.

Toxoplasma is a life-long disease with recurrent relapses. Since no therapeutic agent is superior and could prevent disease recurrences, the risk for vision loss increases with each disease reactivation. Friedmann and Knox noted that the loss of vision is associated with recurrent episodes of toxoplasmic retinochoroiditis rather than the initial lesion (Friedmann and Knox 1969). Therefore, it is essential to try to prevent these recurrences in patients where lesion reside near vision critical structures, such as the fovea and the optic nerve.

4.11 Treatment

Toxoplasmic retinochoroiditis in an immunocompetent host is a self-limiting disease, and peripheral lesions may be left untreated when are not visually threatening. However, treatment is necessary when the lesions are close to the macula, retinal blood vessels, optic disc or when associated with severe inflammation (dense vitritis). Treatment usually involves a course of anti-toxoplasma drugs with or without corticosteroids at the time of recurrence. The use of combinations of different drugs is thought to limit parasitic proliferation during active episode (Holland 2004).

There is evidence to support treatment in relapsing toxoplasmic retinochoroiditis. Recent observations suggest that parasite proliferation is a major cause of tissue damage (Holland 2004). A combination of pyrimethamine and sulfadiazine have resulted in a reduction of the final lesion size (Rothova, Meenken et al. 1993). Also, studies in animal models have reported continuously that antimicrobial drugs are highly effective in the treatment of toxoplasmosis and antimicrobial therapy resulted in rapid disease control in the majority of AIDS patients with chronic active disease (Gagliuso, Teich et al. 1990, Holland 2004).

For these reasons, most uveitis specialists tend to treat acute lesions. However, there is no consensus with regards to which treatment is best. A survey in 2002 identified a total of 9 antimicrobial drugs used to treat toxoplasmosis in 24 different strategies (combinations), with pyrimethamine and sulfadiazine with prednisolone being used in 29% of cases (Holland and Lewis 2002). Clindamycin among others was used, but its treatment is limited by diarrhoea (Tate and Martin 1977).

However, none of these drugs was shown to reduce disease duration or the incidence of disease recurrence. Also, none of the currently available anti-toxoplasma drugs is capable of destroying the bradyzoites within tissue cysts which are responsible for disease recurrence. A recent report by the American Academy of Ophthalmology confirms these findings (Kim, Scott et al. 2013). Newer therapeutic agents including azithromycin and atovaquone have been reported to reduce the number of tissue cysts in animal studies (Araujo, Huskinson et al. 1991, Huskinson-Mark, Araujo et al. 1991). However, their short-term use in humans did not prevent recurrences (Huskinson-Mark, Araujo et al. 1991) (Pearson, Piracha et al. 1999).

“In ocular toxoplasmosis, no curative therapy exists. Therefore patients carry a lifetime risk of recurrence”

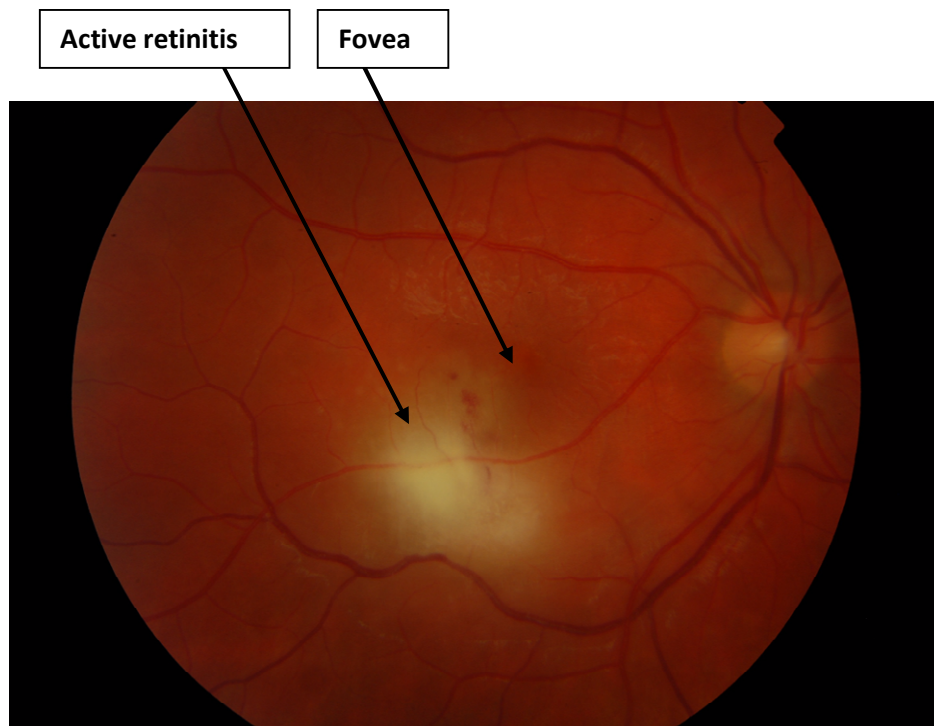
(Reich, Ruppenstein et al. 2015)

The indications for treatment are:

1. Active lesion affecting or near the optic nerve or within the temporal arcades. Figure 4-8.
2. A lesion associated with intense inflammatory reaction and associated with severe vitreous haze.
3. Multiple active lesions or extensive lesions.
4. Persistent intraocular inflammation for more than two months.
5. Primary infection in pregnancy after liaising with obstetrician about treatment choices.
6. Congenital toxoplasmosis in the first year of life to reduce the risk of future retinochoroiditis.
7. Toxoplasmosis in the immunocompromised individual (Kanski and Bowling 2011).

However, some authorities believe that all active lesions should be treated (Oréface and Bahia-Oliveira 2005) because even remote lesions can still affect vision by causing macular oedema, macular traction, severe vitritis and retinal detachment. Additionally, these active lesions may give rise to tachyzoites that may disseminate to other retinal areas and encyst (Foster and Vitale 2013).

Figure 4-8 Active toxoplasmic retinochoroiditis at the macula and close to the fovea. Source Moorfields Eye Hospital



Systemic antibiotic treatments for active toxoplasma retinochoroiditis

Multiple chemotherapeutic agents are available to treat toxoplasmosis and these agents cross the blood ocular barriers, but pyrimethamine and sulphonamides (sulphadiazine) are commonly used to treat acute episodes of toxoplasmic retinochoroiditis. Both agents inhibit the replication of toxoplasma gondii by interfering with the metabolism of folic acid. The current medications have not shown substantial evidence to be able to reduce the severity of inflammation, accelerate resolution of active lesions or reduce the risk of recurrence (Holland 2004, Petersen 2007, Stanford and Gilbert 2009).

Pyrimethamine and trimethoprim are both dihydrofolate reductase inhibitors. These agents usually have the highest antimicrobial activity against toxoplasma gondii. Pyrimethamine has the most significant activity against toxoplasmosis, while sulfamethoxazole and sulfadiazine were equally effective but at only high doses (van der Ven, Schoondermark-van de Ven et al. 1996). The same study reported that a 10-fold increment in pyrimethamine dose decreased the 50% inhibitory concentration of sulfamethoxazole by 1000 times, thus potentiating the effect of sulphonamides.

The classical antibiotic therapy against ocular toxoplasmosis which consists of sulphonamides and pyrimethamine (with folinic acid) is the most commonly used therapy in ocular toxoplasmosis. This combination synergistically inhibits the replication of toxoplasmosis. Sulphonamides and pyrimethamine inhibit sequential steps in folic acid metabolism, necessary for DNA synthesis. But, they only interfere with replication of active parasite (tachyzoites) and not the tissue-encysted form (bradyzoites) (Montoya and Liesenfeld 2004). Also, humans can metabolise folinic acid so do not become folate deficient.

Pyrimethamine activity increases six to eight times when combined with sulpha drugs (Petersen, Dubey et al. 2001). Furthermore, treatment with pyrimethamine has been shown to reduce the scar size after resolution of active lesions (Rothova, Buitenhuis et al. 1989). Therefore, it is prudent to use pyrimethamine when active toxoplasmosic retinitis threatens the macular area or the optic disc because limiting the scar size even by several microns would have a great impact on final visual acuity.

The standard treatment for an acute presentation consists of a combination of an antiparasitic drug with or without the use of systemic corticosteroids for 4-8 weeks based on disease severity. Concomitant use of oral corticosteroids is helpful in reducing the inflammation to try and minimise tissue damage. Anti-toxoplasmosis treatment is then discontinued as the lesions settle down and convert to scar tissue. Treatment will be reinstated if the disease relapses (Stanford and Gilbert 2009).

Sulfadiazine which is part of the standard treatment regime for ocular toxoplasmosis is associated with a high rate of side effects including bone marrow suppression and allergic reactions, leading to discontinuation of treatment in around 25% of patients (Engstrom Jr, Holland et al. 1991, Rothova, Meenken et al. 1993). Trimethoprim-sulfamethoxazole (co-trimoxazole), on the other hand, is well tolerated and is widely used in the treatment of acute ocular toxoplasmosis (Holland and Lewis 2002). It has been shown to be effective against toxoplasmosis in experimental studies (Grossman and Remington 1979). Trimethoprim-sulfamethoxazole is inexpensive, widely available and has a lower rate of side effects (Silveira, Belfort et al. 2002). For the mechanism of action and side effects of different anti-toxoplasma drugs please see Table 4-1.

Table 4-1 Systemic treatment option in ocular toxoplasmosis

Drug	Mechanism of action	Dose	Regimen	Side effect
Pyrimethamine	A folic acid antagonist Interferes with the metabolic cycle of the parasite by suppressing the dihydrofolate reductase thus inhibiting the conversion of folic acid to folinic acid, which is necessary for the synthesis of both DNA and RNA (Petersen, Dubey et al. 2001).	75 mg loading dose, followed by 25 mg bid	Part of the standard regimen	Bone marrow toxicity (Leukopenia, thrombocytopenia, megaloblastic anaemia) which can be reversed by the co-administration of folinic acid. Weekly blood tests should be performed to monitor for any haematological disturbance. (Petersen, Dubey et al. 2001)
Sulphonamides (sulfadiazine)	Structurally similar to paraminobenzoic acid (PABA) They act as a competitive antagonist to prevent the synthesis of folic acid by the parasite. Sulphonamides inhibit dihydrofolic acid synthase (Petersen, Dubey et al. 2001)	1 gm QDS	Part of the standard regimen	Acute haemolytic anaemia, agranulocytosis and hypersensitivity reactions ranging from photosensitivity to severe Steven-Johnson like reactions of the skin and mucous membranes (Gonzalez, Coughtrie et al. 2006). When sulpha drugs are combined with pyrimethamine, toxicity is high and reported in 60% of HIV patients with encephalitis. These include hepatitis, bone marrow suppression, leukopenia, rash and thrombocytopenia (Haverkos 1987).
Clindamycin	Effective against toxoplasmosis and achieves higher intraocular concentrations (Tabbara and O'Connor 1980).	300 mg four times daily	Clindamycin Doses of appear equivalent to combination therapy of pyrimethamine and sulphadiazine (Tabbara and O'Connor 1980).	Its use is associated with an uncommon but serious complication of pseudomembranous colitis (Petersen, Dubey et al. 2001).

Azithromycin	Azithromycin suppresses the ribosomal protein synthesis.	500 mg OD	It has been reported that azithromycin is effective against the encysted form of the parasite (bradyzoites) (Huskinson-Mark, Araujo et al. 1991, Farthing, Rendel et al. 1992).	Stomach upset, diarrhoea, vomiting or abdominal pain (Hopkins 1991).
Atovaquone	Selectively inhibits the electron transport chain in the protozoan mitochondria (Pearson, Piracha et al. 1999).	750 mg QDS	Atovaquone was found effective in ocular toxoplasmosis but did not prevent the future disease recurrence (Pearson, Piracha et al. 1999).	Rash, pruritus, headache, nausea and gastrointestinal disturbances. (Pearson, Piracha et al. 1999)
Trimethoprim-sulfamethoxazole	The sulfamethoxazole act by preventing PABA from being utilised for folic acid synthesis while trimethoprim blocks the reduction from dihydrofolate to tetrahydrofolate (Nguyen and Stadtbaeder 1975).	960 mg BID	Several studies reported equal efficacy of co-trimoxazole to standard treatment in patients with toxoplasmic encephalitis and those with toxoplasmic retinochoroiditis (Grossman and Remington 1979, Soheilian, Sadoughi et al. 2005).	Gastrointestinal disturbances, allergic reaction, itching, skin sensitivity, Steven Johnson syndrome (Silveira, Belfort et al. 2002).

4.11.1 Corticosteroids

Corticosteroids are used when there is a high risk for permanent vision loss due to macula or optic nerve involvement or when severe inflammation occurs in the vitreous. They help in reducing the inflammation and decrease the risk of complications such as CMO and persistent vitritis, and they should be discontinued before antiparasitic treatment is stopped (O'Connor and Frenkel 1976). The use of corticosteroid alone without antimicrobial therapy carries devastating consequences with a rapid spread of retinitis with visual loss (Bosch-Driessen, Berendschot et al. 2002).

Is there a superior treatment approach?

The combination of pyrimethamine with sulphadiazine and corticosteroids have been shown to reduce the time to complete inactivity (resolution of inflammation and scarring of the retinal lesion). A statistically significant difference in the proportion of patients achieved faster resolution of inflammation (within the first eight weeks of treatment), on the classical therapy compared to those spiramycin or corticosteroids alone (FAJARDO, FURGIUELE et al. 1962). Treatment with pyrimethamine has been shown to significantly reduce the healing time of active toxoplasma retinochoroiditis lesions when compared to spiramycin (Nolan and Rosen 1968).

However, this combination, when used to treat the acute episodes, is usually associated with a high rate of side effects and toxicity. Also multiple antibiotic and multiple daily doses reduce compliance (Opremcak, Scales et al. 1992). Therefore, the efficacy and tolerability of other antibiotic treatment for acute toxoplasma retinochoroiditis versus classical therapy was the subject of research in different studies.

Azithromycin has an excellent tissue penetration and concentrates in macrophages to levels that exceed the serum concentrations by 10-1000 times. Therefore, it could be useful in treating intracellular pathogens such as toxoplasmosis. Moreover, in vitro studies showed that azithromycin is active against both the cystic and active forms (tachyzoites) of toxoplasmosis. This property is also found in atovaquone but not the other anti-toxoplasma drugs (Petersen, Dubey et al. 2001). Two studies compared azithromycin against triple therapy (pyrimethamine, sulfadiazine and folinic acid).

The first study compared the time to resolution of intraocular inflammation, lesion size and visual acuity before and after four weeks of treatment with combined pyrimethamine and sulfadiazine in 22 patients versus pyrimethamine and azithromycin (250 mg) in 24 patients. In both groups, the dose of pyrimethamine was 100 mg on day one then 50 mg per day. Also, both have received folinic acid (15mg) to counteract the effect of pyrimethamine on bone marrow suppression, and oral corticosteroid was given on day three after treatment initiation for both treatment arms. This study reported no significant differences regarding the duration of inflammation, change in lesion size, improvement in visual acuity or the risk of recurrence between groups.

However, adverse reactions were more common in pyrimethamine-sulfadiazine treated-patients compared to azithromycin-pyrimethamine group (64% versus 33%) (Bosch-Driessen, Verbraak et al. 2002). The number of recurrences after one year of treatment were similar between the two groups. Of note, seven patients (29%) in the azithromycin arm and three patients (15%) from the sulfadiazine group needed to continue treatment beyond the four weeks for persistent retinal or vitreous activity, but this was not statistically significant.

The second study used azithromycin (500 mg) alone versus triple therapy in the treatment of acute ocular toxoplasmosis. Both groups received adjunctive prednisolone. However, all patients in the triple therapy group responded to triple therapy versus 90% in the azithromycin group (was not statistically significant). Adverse events such as gastrointestinal disturbances, malaise, headache and dizziness were reported by all patients in the triple therapy group versus none in azithromycin group (Balaskas, Vaudaux et al. 2012). Although azithromycin appears better tolerated when compared to triple therapy the effectiveness of azithromycin remains open to question since this study included only 19 patients (Harrell and Carvounis 2014). Also, azithromycin did not eradicate tissue cysts and was not effective in preventing disease recurrence.

In vitro and in vivo studies reported that atovaquone has a significant activity against active and encysted forms of toxoplasma gondii (Araujo, Huskinson et al. 1991). Seventeen immunocompetent patients with toxoplasma retinochoroiditis treated for three months with atovaquone showed a favourable response to treatment after 1 and 3 weeks in and therapy was well tolerated (Pearson, Piracha et al. 1999). However, atovaquone did not prevent disease recurrence after discontinuation of therapy.

Finally, a report from the Netherlands shows no significant differences between different treatments regimens and no treatment, with regards to duration of inflammatory activity or reduction in lesion size. The treatments included pyrimethamine (100 mg loading dose then 25 mg bid), sulfadiazine (1 gm qid) and prednisolone (60 mg then taper); clindamycin (300mg qid), sulphadiazine and prednisolone or trimethoprim-sulphamethoxazole (160-800 mg bid) for two weeks then 80-400 mg bid or observation for peripheral lesions. The authors concluded that none of these drug combinations is superior in terms of therapeutic benefits. Also, the

duration of inflammation was similar between the treated and non-treated group, and the most crucial factor that determines the duration of inflammation was the lesion size. However, the combination of pyrimethamine and sulfadiazine was associated with the highest frequency of side effects (52%) and these included thrombocytopenia, leukopenia, fever and skin rash (Rothova, Buitenhuis et al. 1989). The results were in agreement with another report by the same group where there is no difference in inflammatory activity, visual acuity or rate of recurrences between treated and untreated groups; the mean recurrence rate was 49% for all patients (Rothova, Meenken et al. 1993). Recurrences on clindamycin have also been reported at 7.7 % over eight years of follow-up (Lakhanpal, Schocket et al. 1983). Therefore, all treatments have similar efficacy with pyrimethamine and sulfadiazine being the least tolerated (Harrell and Carvounis 2014).

What about the number of recurrences after treatment with trimethoprim-sulfamethoxazole compared to the classical therapy? The recurrence rates in patients treated with pyrimethamine and sulphadiazine range between 13-17% (Petersen, Dubey et al. 2001), Soheilian et al. conducted a prospective randomised trial comparing the effect of combined treatment with sulfadiazine and pyrimethamine versus trimethoprim and sulfamethoxazole. There was no significant difference between the two arms with regards to lesion size, visual acuity and rate of recurrences after 24 months follow-up (Soheilian, Sadoughi et al. 2005).

In summary, in ocular toxoplasmosis, there were no significant differences, between different therapeutic agents, with regards to the duration of inflammation or rate of disease recurrence (Rothova, Buitenhuis et al. 1989).

4.12 The role of co-trimoxazole in ocular toxoplasmosis

Trimethoprim-sulfamethoxazole is regarded potentially less-toxic alternative compared to the combination of sulfadiazine and pyrimethamine. Grossman and associate have demonstrated that trimethoprim-sulfamethoxazole kills the parasite in mice (Grossman and Remington 1979). Similarly, the combination of trimethoprim and sulfamethoxazole have been found effective against intracellular replication of toxoplasma in cell cultures (Nguyen and Stadtsbaeder 1975).

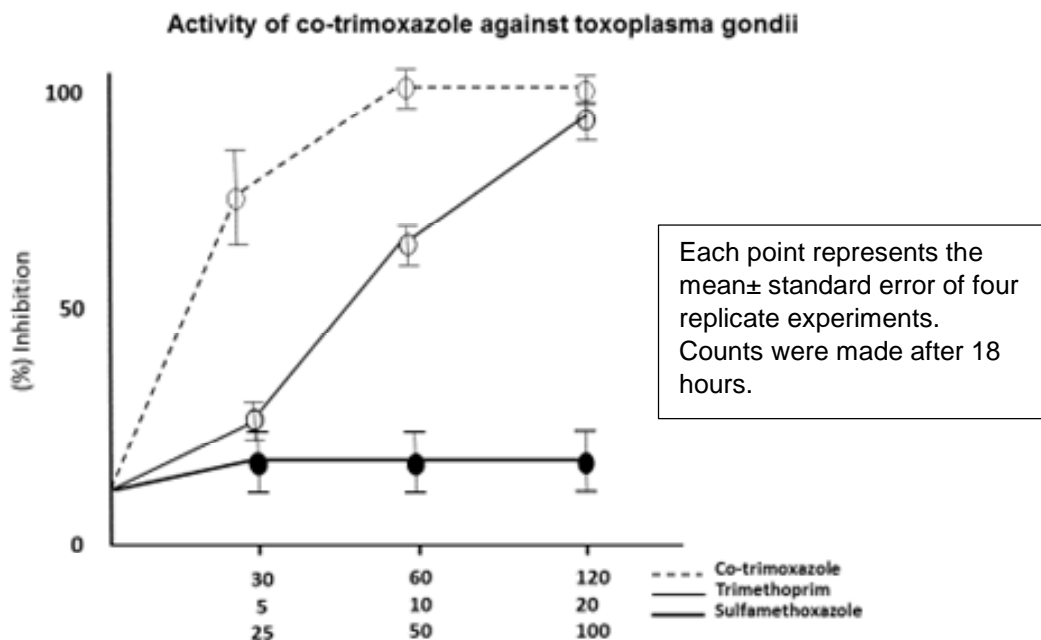
Nguyen and Stadtsbaeder in their seminal work on toxoplasmosis treatment have reported exciting findings when used co-trimoxazole in vitro. The percentage of inhibition of co-trimoxazole on intracellular toxoplasma reached 100% after 18 hours of treatment at 37°C. Prolonged treatment resulted in eradication of organisms in cell cultures in a duration-dependent fashion. This time-dependent interaction might be explained by the antimetabolic activity of co-trimoxazole on the metabolically active toxoplasma. There was a strikingly significant correlation between toxoplasma division and the percentage of inhibition ($r=0.99$, $p\text{-value} < 0.01$). Co-trimoxazole has achieved complete eradication of the parasite from tissue culture after two days of exposure, and led to the degeneration of toxoplasma within cells, resulting in reduction in the number of infected cells. Under microscopy, co-trimoxazole destroyed preformed clones of parasitic aggregates, formed after 18 hours of parasitic replication and the remarkable effect of co-trimoxazole was invariably successful across the successive division cycles of parasitic replication (Nguyen and Stadtsbaeder 1975).

Interestingly, in the same study, trimethoprim was the only effective compound on intracellular parasitic replication, and the inhibition of parasitic replication was dose-dependent while the addition of sulfamethoxazole produced a marked synergistic effect. The optimum ratio of trimethoprim and sulfamethoxazole was 1/5. Table 4-2. Sulfamethoxazole and trimethoprim when each used separately, a less marked effect was obtained than when used in combination. However, when combined with sulfamethoxazole, a similar inhibitory effect was achieved with trimethoprim but at a significantly lower dose. Figure 4-9.

Table 4-2 (Nguyen and Stadtsbaeder 1975).

Activity of trimethoprim and sulfamethoxazole , alone and in combination on the multiplication of toxoplasma gondii within mouse peritoneal macrophages. Each term represents the mean± standard error of four replicate experiments. Counts were made after 18 hours of treatment		
Trimethoprim (µg/ml)	Sulfamethoxazole (µg/ml)	(%) Inhibition
10	0	87.2±8.3
0	50	15.3±2.4
10	50	100
2	0	19.6±4.6
0	70	17.0±3.9
2	70	96.3±2.7
1	70	38.8±5.3
0.5	70	19.1±2.7
0.25	70	12.8±4.3
2	35	86.8±5.5
2	17.5	47.6±2.9
2	8.75	34.7±2.8
0	0	18.4±4.1

Figure 4-9 the activity of trimethoprim and sulfamethoxazole alone and in combination on the multiplication of toxoplasma gondii (Nguyen and Stadtsbaeder 1975)



One of the crucial issues of the success of co-trimoxazole was the superior activity and intracellular penetration. Moreover, co-trimoxazole does not affect the growth and function of host cells, nor it affects the viability of macrophages. Furthermore, the percentage of inhibition increased with duration of exposure. Lastly, animals exposed to co-trimoxazole have acquired strong immunity against toxoplasmic reinfection (Nguyen and Stadtsbaeder 1975).

In ocular toxoplasmosis, the combination of trimethoprim and sulfamethoxazole (co-trimoxazole) has been used, but the efficacy of co-trimoxazole compared to the classical therapy was controversial. Some authors have claimed that this combination is less effective in the treatment of ocular toxoplasmosis when compared to the standard regimen (pyrimethamine and sulphadiazine) (Petersen, Dubey et al. 2001, Oréfice and Bahia-Oliveira 2005, Petersen 2007). Likewise, a study by Raskin et al. compared the therapeutic efficacy of the combination of pyrimethamine and sulfadiazine versus trimethoprim and sulfamethoxazole in 49 patients, all additionally receiving corticosteroids. A faster resolution was observed with the combination of pyrimethamine and sulfadiazine (28 days) compared to trimethoprim and sulfamethoxazole treatment (35 days) (Raskin, Alves et al. 2002). No information was given regarding the rate of recurrence, lesion size, visual acuity or the basis of how the resolution of retinal inflammation was determined (Kim, Scott et al. 2013).

In contrast, other investigators in a randomised, single-blinded trial, reported similar efficacy between co-trimoxazole and the classical therapy (pyrimethamine, sulfadiazine and folinic acid). There were no significant differences regarding lesion size, mean improvement in visual acuity and recurrence rates between the two groups (Soheilian, Sadoughi et al. 2005). The authors reported that trimethoprim-sulfamethoxazole is an alternative to the standard therapy and it might be even a better option. Another study reported that the combination of trimethoprim-sulfamethoxazole in one tablet, given twice daily accelerates the resolution of toxoplasmic retinochoroiditis lesion and improves vision with a fewer side effect (Opremcak, Scales et al. 1992).

In immunocompromised patients, small observational studies have reported a 75% response rate in AIDS patients with toxoplasmic encephalitis treated with co-trimoxazole and this combination was effective in preventing recurrences of

toxoplasmic encephalitis in AIDS patients (Grossman and Remington 1979, Richards Jr, Kovacs et al. 1995). Additionally, a meta-analysis of toxoplasmic encephalitis in HIV infected patients found similar efficacy between co-trimoxazole and pyrimethamine-sulfadiazine (Yan, Huang et al. 2013)

Silveira et al. asked if the treatment with prophylactic trimethoprim-sulfamethoxazole delays the onset of recurrences Silveira suggested yes it does but could not prove it statistically.

Due to the better safety profile of trimethoprim-sulfamethoxazole and azithromycin in addition to evidence to support similar efficacy to triple therapy, more uveitis specialists have started using these agents to treat acute ocular toxoplasmosis. Co-trimoxazole is available in combined formula and less expensive of the two.

4.13 Local treatments for toxoplasma retinochoroiditis

Randomised controlled studies have looked at the efficacy of intravitreal clindamycin (1mg), and dexamethasone (0.4mg) (IVTCD) compared to pyrimethamine, sulfadiazine, folinic acid and prednisolone (conventional treatment). In IVTCD group almost half of the patients' required more than one injection and IVTCD could be repeated every two weeks based on the clinical response to treatment. There were no significant differences between the two groups concerning the reduction in lesion size, improvement in visual acuity, resolution of vitreous inflammation or rate of recurrences (recurrence rates were 5.9% in each group at two years). Serious adverse events were reported in the group treated with conventional therapy, whereas in IVTCD- treated patients there were no systemic adverse reactions noted (Soheilian, Ramezani et al. 2011).

Another prospective randomised trial by Colin and Harie comparing the treatment outcome between subconjunctival clindamycin and oral pyrimethamine with sulphadiazine in 29 patients found no significant difference in mean visual acuity and healing time; the mean healing time was 1.8 months. Recurrences after 14 months' follow-up occurred in both groups (21% with clindamycin and 36% with pyrimethamine with sulphadiazine). Apart from local injection discomfort, subconjunctival clindamycin was not associated with any other side effects (Colin and Harie 1989). These data

show that local clindamycin is a useful alternative to systemic therapy in patients unresponsive or intolerant to systemic antimicrobials or when these medications are contraindicated such as during pregnancy (Harrell and Carvounis 2014).

A pilot study evaluated the role of intravitreal trimethoprim-sulfamethoxazole in 4 patients with active toxoplasmic retinochoroiditis. The dose used was 1.28mg/0.08 ml and dexamethasone 400µg/0.1ml given every one or two weeks. Lesions responded to treatment within a week, and there was no evidence of retinal toxicity on full-field electroretinogram. Additionally, all patients have improved vision (Choudhury, Jindal et al. 2015). In conclusion, intravitreal treatment is an alternative treatment strategy for patients with toxoplasmic retinochoroiditis.

4.14 Treatments to reduce recurrent rates of toxoplasma retinochoroiditis

Historically, the application of laser photocoagulation directly to the lesion of toxoplasma retinochoroiditis and the surrounding retina was tried on 24 patients in the 1960s. These patients were known to have recurrent disease. But laser treatment did not eliminate the risk of recurrences. During the 8-33 months follow-up, 8% had disease relapse, and these recurrences occurred at sites away from the initially treated lesion (SPALTER, CAMPBELL et al. 1966). Similarly, a case series of 35 patients treated with laser photocoagulation reported a 53% recurrence rate in 5 years (Desmettre, Labalette et al. 1996). Moreover, treatment with triple therapy versus laser around the foci showed no difference in the rate of recurrences in a comparative study of 33 patients (Theodossiadis, Koutsandrea et al. 1989). Therefore, based on the above evidence laser is not a treatment for prevention of recurrent ocular toxoplasmosis.

The next option was using atovaquone or azithromycin to treat acute episodes of ocular toxoplasmosis since both agents have demonstrated cysticidal action in animal and laboratory testing (Harrell and Carvounis 2014). The clinical data was unfortunately disappointing. In a retrospective case series of 41 patients treated with atovaquone (750 mg twice to three times daily) for six weeks reported a recurrence rate of 27% by two years and 75% by six years follow-up (Winterhalter, Severing et al. 2010). Similarly, a six weeks course of 500 mg azithromycin in 11 patients did not

prevent the future disease recurrences, with 27 % of patients developing relapse of retinochoroiditis by the first year of follow-up (Rothova, Bosch-Driessen et al. 1998).

The long-term use of low dose trimethoprim-sulfamethoxazole was the only effective measure in preventing the recurrent toxoplasmic retinochoroiditis. Please see the next section for more details.

4.15 The rationale of intermittent co-trimoxazole treatment in toxoplasmic retinochoroiditis

The three weekly treatment with twice daily co-trimoxazole was adopted from studies in HIV-infected patients with low CD4+ lymphocytes count (<200 mm²), for primary and secondary prevention against cerebral toxoplasmosis and pneumocystis carinii pneumonia. A study against primary prevention of toxoplasmic encephalitis had found better protection with high doses of co-trimoxazole compared to the lower ones. Studies have shown that relapse of toxoplasmic encephalitis in HIV-infected patients occur after treatment was stopped. Also, the efficacy of co-trimoxazole would diminish if the concentration of co-trimoxazole falls below therapeutic levels when patients are poorly compliant with treatment (Ribera, Fernandez-Sola et al. 1999).

Similarly, intermittent maintenance therapy of pyrimethamine and sulfadiazine, twice weekly, was used in HIV-infected patients to prevent the relapse of toxoplasmic encephalitis. The treatment regimen was compared against daily treatment with the same medications. There was a statistically significant higher rate of relapse in toxoplasmic encephalitis in patients treated twice weekly versus those on daily dosing. Therefore, sulfadiazine pyrimethamine efficacy was compromised when treatment was reduced to twice weekly. In addition to less effective action on disease relapses with twice weekly and there was no significant difference in the rate of the adverse event between the two regimens (Podzamczer, Miro et al. 1995). However, when used thrice weekly it was as effective as daily regimen (Podzamczer, Miro et al. 2000).

4.16 When should we start prophylaxis?

The first cohort to start prophylaxis treatment was AIDS patients with toxoplasmic encephalitis where maintenance treatment was essential to prevent disease recurrence, because relapses, which are guaranteed in the absence of treatment, can

be fatal (Gagliuso, Teich et al. 1990). Long-term therapeutic doses of pyrimethamine sulphamethoxazole were poorly tolerated due to systemic toxicity. Also, results of studies on pyrimethamine prophylaxis against toxoplasmic encephalitis were inconclusive (Maslo, Matheron et al. 1991), owing to wide variation in drug plasma levels and interaction with other drugs used in HIV patients such as zidovudine (Weiss, Harris et al. 1988, Israelski, Tom et al. 1989).

On the other hand, primary prophylaxis with trimethoprim-sulfamethoxazole was found effective in preventing toxoplasma encephalitis in HIV infected patients. A comparative study on prophylactic treatment against toxoplasmic encephalitis in HIV infected patients using trimethoprim-sulfamethoxazole twice daily, two days per week, or pentamidine, found that none of the 60 patients on trimethoprim-sulfamethoxazole developed disease recurrence while 12 (33%) of patients on pentamidine had a disease relapse (p -value =0.008) (Carr, Tindall et al. 1992).

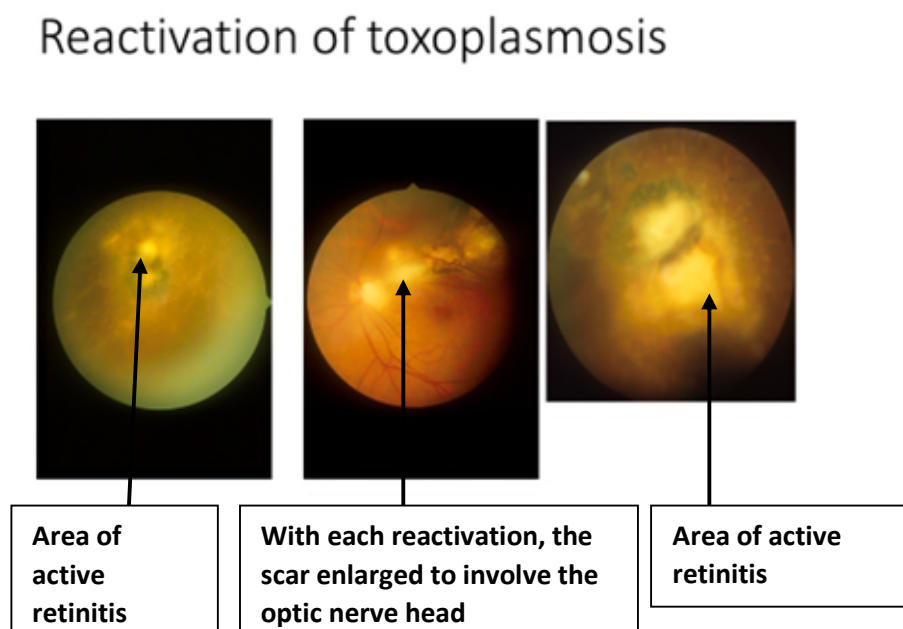
Another area where prophylactic treatment was proven effective is congenital toxoplasmosis. Studies in newborns with congenital toxoplasmosis have found that long-term treatment with pyrimethamine and sulphadiazine reduces the risk of recurrent toxoplasma retinochoroiditis. Guerina and associates have reported that one year of treatment with systemic pyrimethamine and sulphadiazine resulted in a remarkable reduction in the rate of recurrent toxoplasmic retinochoroiditis after 1-6 years follow-up, new retinal lesions only developing in 4 out of 39 children, a rate that is substantially lower than untreated children (Guerina, Hsu et al. 1994). Therefore this treatment strategy was effective in reducing the risk of future relapse in congenital toxoplasma infection with or without initial retinal involvement. Finally, in immune competent adults with frequent reactivation, or sight-threatening lesions, long-term, low-dose of trimethoprim-sulfamethoxazole was effective in reducing disease relapses (Silveira, Belfort et al. 2002).

4.17 Antibiotic prophylaxis in ocular toxoplasmosis

The currently used antibiotics are effective against the tachyzoites of *toxoplasma gondii*. However, the tissue cysts, which contain bradyzoites, are impenetrable to these antimicrobials (Bohne, Holpert et al. 1999). Therefore, the risk of toxoplasmosis recurrence persists, which carries a significant risk of visual loss (Friedmann and Knox

1969). The risk of recurrence varies in the literature and can be as high as 79% when patients are followed up for five years (Bosch-Driessen, Berendschot et al. 2002). The same study also showed that 25% of patients developed legal blindness (VA <6/60) in at least one eye due to recurrent episodes of toxoplasmic retinochoroiditis, Figure 4-10. These poor outcomes could be prevented by secondary prophylaxis in high-risk patients.

Figure 4-10 Reactivation of toxoplasmosis. Photos are courtesy of professor Lightman. Source Moorfields Eye Hospital.



The risk of recurrence is highest directly after recent active inflammation, and it then decreases over time (Holland 2003), which mandates a close follow for at least one year after an acute attack (Reich, Ruppenstein et al. 2015). Patient's age is one of the critical factors in this regard. However, there is controversy regarding which age group is at highest risk of recurrence. Holland and colleagues reported higher risk in patients over 40 years (Holland, Crespi et al. 2008), while Garweg et al. describes patients younger than 20 years to be at the higher risk of recurrence (Garweg, Scherrer et al. 2008).

Nonetheless, secondary prophylaxis seems a safe policy to avoid vision loss by preventing disease recurrence. It was recommended to be standard treatment in high-

risk patients (Grigg, Dubey et al. 2015). However, it is important to identify those at risk and also to define a time interval in which there is a high risk of recurrence so that people at high risk will benefit from treatment (Holland 2004). Reich and co-workers, in their retrospective study of 84 patients, showed that the median recurrence-free survival-time was 2.52 years. The Kaplan Meier curve shows that the risk of recurrence is highest in the first year after the most recent active lesion (Reich, Ruppenstein et al. 2015).

4.17.1 Co-trimoxazole prophylaxis in recurrent toxoplasmic retinochoroiditis

Silveira and co-authors were the first to explore the effect of long-term chemoprophylaxis in patients with recurrent ocular toxoplasmosis (Silveira, Belfort et al. 2002). In this open-label study, Silveira and associates examined the effect of trimethoprim-sulfamethoxazole on 124 patients with a history of recurrent toxoplasma retinochoroiditis who were positive for anti-toxoplasma IgG antibody. Patients were randomised to treatment with one tablet every three days (61 patients), or observation (63 patients) and patients were followed-up monthly for up to 20 months for clinical signs of recurrence. Recurrences developed in 4 treated patients 6.6% versus 15 controls 23.8%, ($p=0.01$). Silveira speculated that long-term treatment with trimethoprim-sulfamethoxazole inhibits the proliferation of occasional parasites that escape tissue cysts, hence allowing for the development of an effective immune response from the host before the disease is clinically evident. The selection of trimethoprim/sulfamethoxazole for long-term prophylaxis was based on low cost of the medication, convenience for use and a lower rate of side effects when compared to other treatments available for ocular toxoplasmosis (Silveira, Belfort et al. 2002).

However, in the above study there are flaws in the study design. Patients in the control group did not receive placebo, and all subjects examined unmasked which may have introduced bias during the examination. These factors may also compromise the ability to assess drug-related side effects (Felix, Lira et al. 2014). Furthermore, the study of Silveira lacked uniform documentation at baseline and when relapses occurred (Kim, Scott et al. 2013). Besides, it was conducted in Brazil where more virulent strains are predominant and these are responsible for more severe disease (Gilbert, Freeman et

al. 2008). Most importantly, there were no report of visual acuity or change in lesion size which were the primary outcomes for this study.

To assess the recurrence rate after stopping treatment, Silveira studied the same cohort for an extended follow-up period of 10 years from 2000-2010 included 116 patients. The rate of recurrence was similar in both groups, although the follow-up included only 50.86% of patients in the treatment group and 49.13% in the control group, suggesting that the prophylactic effect of the treatment disappeared when it was stopped (Silveira, Muccioli et al. 2015).

More recent work in this field was carried out by Felix and co-workers. They compared the effect of trimethoprim-sulfamethoxazole versus placebo on toxoplasmosis recurrences in a randomised controlled clinical trial. This study included 95 subjects, and after successful treatment for 45 days with Trimethoprim/Sulfamethoxazole 160/800mg BID, patients divided into two groups, either trimethoprim-sulfamethoxazole once every two days or placebo once every two days. The primary outcome was the number of recurrences after one year of treatment, and the secondary outcome was BCVA after one year. The incidence of recurrent toxoplasmosis after one year was 0% vs 12.80% in trimethoprim-sulfamethoxazole and placebo groups, respectively ($P=0.026$). There was no difference in BCVA in the two groups. The authors concluded that Trimethoprim-sulfamethoxazole resulted in a 100% reduction in recurrences over the one year of treatment (Felix, Lira et al. 2014).

The same group studied the effect of one year of trimethoprim-sulfamethoxazole prophylaxis over the following three years follow-up after the initial episode. The study reported significantly higher recurrences in the placebo group compared to the trimethoprim-sulfamethoxazole group. The cumulative probability of recurrences at 1, 2 and three years of follow up was 13.0%, 17.4% and 20.3% in the placebo group compared to 0% in trimethoprim-sulfamethoxazole group ($p\text{-value}<0.001$). However, there was no additional benefit of prophylactic treatment on final visual acuity. They concluded that trimethoprim-sulfamethoxazole prophylaxis for one year offers an additional two years protection against recurrent ocular toxoplasmosis (Felix, Lira et al. 2016). Finally, this study reported that there were no treatment-related toxicities and trimethoprim-sulfamethoxazole was well tolerated.

Felix et al. assumed that the additional two-year benefit of trimethoprim-sulfamethoxazole might have occurred due to the eruption of the majority of viable cysts which tend to develop in the first few months after initial infection. In accordance with this, other studies have reported a higher rate of recurrences during the first year after the initial attack (Garweg, Scherrer et al. 2008, Holland, Crespi et al. 2008). However, a large retrospective study reported that patients can still develop disease recurrences for as long as 12 years follow-up after the initial infection (Arantes, Silveira et al. 2015). Similarly, 10-years data from Silveira group (above) showed similar relapse rate in both groups which implies that tissue cysts which can remain viable for an extended period, are capable of inducing disease recurrence at extended follow-up periods.

4.18 AIM

Two groups have studied the low-dose, long-term use of trimethoprim-sulfamethoxazole as prophylaxis treatment in patients with a history of recurrent ocular toxoplasma retinochoroiditis (Silveira, Belfort et al. 2002, Felix, Lira et al. 2016). Their results were encouraging; however, these trials conducted for a maximum of 20 months and there is no evidence with regards to long-term efficacy and safety of trimethoprim-sulfamethoxazole. Furthermore, there are conflicting results regarding the rate of disease relapse after stopping the prophylactic course. Finally, both trials were conducted in Brazil where a different and more aggressive strain of the parasite exists compared to Europe. We therefore, undertook this project to gain a better understanding of the effectiveness of trimethoprim-sulfamethoxazole prophylaxis in a different population and with longer follow-up and determine whether or not there are any lasting benefits with regards to disease relapse after stopping treatment.

Hypothesis: long-term trimethoprim-sulfamethoxazole prophylaxis is effective in reducing the disease relapse rate in patients with a history of recurrent toxoplasmic retinochoroiditis and prevents vision loss.

4.19 Design

This study is a retrospective case-control study of patients with a history of recurrent ocular toxoplasmosis to determine the effect of long-term, low-dose

trimethoprim/sulfamethoxazole treatment on recurrence rate and visual acuity. For this purpose, we analysed the database of all patients at Moorfields Eye Hospital (MEH) from 2005-2018 to identify those who had prophylactic trimethoprim-sulfamethoxazole for recurrent ocular toxoplasmosis. Ethical approval for this project was obtained from the Department of Research and Development at MEH under (ROAD16039) (Visual loss in uveitis). Patients of all ages were included in the study if they had trimethoprim-sulfamethoxazole as prophylaxis with no restriction on the length of prophylaxis time. The search identified 32 Patients with a history of recurrent toxoplasmic retinochoroiditis who had trimethoprim-sulfamethoxazole as prophylaxis. Forty patients with recurrent toxoplasmic retinochoroiditis were selected randomly as a control group.

The primary endpoint was the development of recurrent toxoplasmic retinitis defined clinically as a new focus of retinitis either adjacent or remote to a pre-existing retinochoroidal scar. The statistical test used to compare the rate of recurrences between the two groups were Cox regression, and Kaplan-Meier methods. Hazard ratio and survival analysis with Log-Rank test were employed to check for statistical significance.

The secondary endpoint was the change in visual acuity during the follow-up period and the safety and tolerability of trimethoprim-sulfamethoxazole.

4.20 Definition of Terms

1. Primary/acquired OT is defined as the first active retinochoroiditis without a pre-existing scar in the eye and not due to a viral aetiology.
2. The diagnosis was based on clinical criteria made by Holland and associates: the presence of creamy-white coloured active retinal lesion with or without an adjacent hyperpigmented retinochoroidal scar (Holland, O'Connor et al. 1996). Clinical and serological tests were not routinely formed, so these were not taken into account.
3. Recurrences were defined as an active lesion involving an area of the previously normal retina in the existence of previous chorioretinal scar.

Changes in intraocular inflammatory status such as acute anterior uveitis or vitreous floaters alone were not considered as recurrences.

4. Inactivity was determined clinically by the resolution of the retinal inflammation and clearing of the vitreous.
5. High-risk patients: one to two years after the most recent active lesion, primary lesion in patients older than 40 years of age, immunosuppressed patients and lesions close to the macula or optic nerve.
6. Sight-threatening lesions are defined as those in zone 1 (this is marked by the area extending 3000 μm (2 disc diameters) from the fovea or the area enclosed by the major temporal vascular arcades or 1500 μm from the margins of optic nerve head), lesions in that portion of the retina are considered as an immediate threat to the sight. For the sake of completeness, other zones are zone 2 which lies anterior to zone one and up to equator, and zone three from the equator to the ora serrata (Holland, Buhles et al. 1989).

4.21 Methods

Patients with a history of recurrent ocular toxoplasmic retinochoroiditis presented to Moorfields Eye Hospital from May 1995 to June 2018 were identified by searching the database for the following terms (toxoplasmosis, toxoplasma, retinochoroiditis, and ocular toxo). For those who had trimethoprim-sulfamethoxazole prophylaxis, additional terms were used including (trimethoprim-sulfamethoxazole, co-trimoxazole, septrin prophylaxis toxo, toxoplasmic, toxoplasma, toxo-septrin, toxo-co-trimoxoazole) to identify those with the diagnosis of ocular toxoplasmosis and had a course of trimethoprim-sulfamethoxazole prophylaxis. Prophylaxis was defined as either 960 mg of trimethoprim-sulfamethoxazole per day three times a week or twice a week.

All patients were included in this study and no prior evidence of serological testing for IgG anti-toxoplasma antibody was required, and the diagnosis was made based on the patient's history and clinical findings. The control group was selected randomly from a list of patients whose clinic letters included the following terms (toxoplasmosis, toxoplasma, retinochoroiditis, and ocular toxo) to identify those with the diagnosis of ocular toxoplasmosis. This search was performed by the data management division at Moorfields Eye Hospital MEH on OpenEyes software and included only patients

where the registered address was in London to maximise the chances to document all disease flare-ups in the Moorfields database. The Initial list included over 1750 patients and a random code was assigned to each patient using a built-in function in Microsoft Excel, searching for the first 100 cases to identify eligible cases (patients with retinochoroidal scar that is compatible with a previous episode of toxoplasmic retinochoroiditis and history of at least one episode during the follow-up period. Retinal lesions could be unilateral or bilateral. However, only one eye for each patient was included for the control group. The first eye with disease flare-up was selected for each patient if they had at least one active episode of retinochoroiditis in one eye (study eye) and minimum one year of follow-up to balance the two groups because the prophylaxis is usually for one year. Searching the first 415 patients from our random sample list, only 40 were included in the study. Three hundred fifty-nine were excluded either due to shorter follow-up (the vast majority of patients) because patients with acute toxoplasmosis flare-up usually receive treatment for the acute episode and had one or two more visits only to ensure that the disease has settled down before they get discharged. A minority of patients will continue their follow-up, and these cases usually had a more aggressive course or disease-related complications, such as cataract, glaucoma or retinal detachment. Other patients were excluded as the letters with the terms specified in the search above were for patients with different diseases, and the toxoplasmosis was part of the differential diagnosis. Finally, few patients were referred from another hospital or optician for having inactive scars, but they had not had any disease activity at presentation or during follow up, and therefore they were excluded. Best corrected visual acuity which was collected from patient's notes (initially BVCA was recorded in Snellen format, but for analysis purpose, it was converted into (LogMAR) logarithm of the minimal angle of resolution.

For the trimethoprim-sulfamethoxazole treatment, a total of 36 patients were identified, and only 32 were included in the study. Four patients were excluded (1 patient had trimethoprim-sulfamethoxazole and valganciclovir prophylaxis for a retinal lesion which mimicked both toxoplasmosis and acute retinal necrosis (ARN). The other patient had trimethoprim-sulfamethoxazole treatment daily for more than a year, and this did not fall in the category of prophylaxis (defined earlier in this section). The last two patients that were excluded, one because he was prescribed trimethoprim-sulfamethoxazole prophylaxis but did not take the treatment and the other one did not

have any further follow-up visits and therefore, prophylaxis could not be confirmed in the latter case.

Data were collected including patient's demographics (age, gender, and ethnic background), age at first presentation, eye involved and whether the patient has a unilateral or bilateral disease, the immune status (if known) for each patient and the location of the lesion in the retina. Lesions were classified into a macular, peripheral and optic disc. The number of disease flare-ups before starting trimethoprim-sulfamethoxazole, time of initiation of co-trimoxazole prophylaxis and the dose of prophylaxis, time of stopping trimethoprim-sulfamethoxazole, number of flares during and after stopping trimethoprim-sulfamethoxazole therapy and date of each flare-up with the date of first and last visit were collected. Best corrected visual acuity was recorded for all patients in the study at the time of presentation, three months, six months, one year and at last follow up visit. The BCVA of patients on trimethoprim-sulfamethoxazole prophylaxis on starting and finishing trimethoprim-sulfamethoxazole were also recorded.

For the co-trimoxazole group, treatment was recorded as to whether the prophylaxis was indicated for recurrent disease or prophylaxis because disease recurrence is sight-threatening and if the trimethoprim-sulfamethoxazole treatment was stopped and reason to stop (disease control, drug-related side effects or others). If co-trimoxazole was reintroduced, the time was recorded and the number of disease flares during and after the second or third prophylaxis regimens were counted. If the patients had moderate or severe vision loss the cause was recorded.

The effect of systemic treatment with trimethoprim-sulfamethoxazole as a prophylactic agent against recurrent toxoplasma lesions was assessed in both eyes even when the treatment was indicated for the eye with good vision. Since disease recurrences in both eyes were possible, the second eye was included in the study even when it had a central macular scar with limited visual potential.

4.22 Statistical analysis

Data were expressed in mean, median and standard deviation and standard error of the mean (SEM) whenever possible. Mann-Whitney two-sample non-parametric test

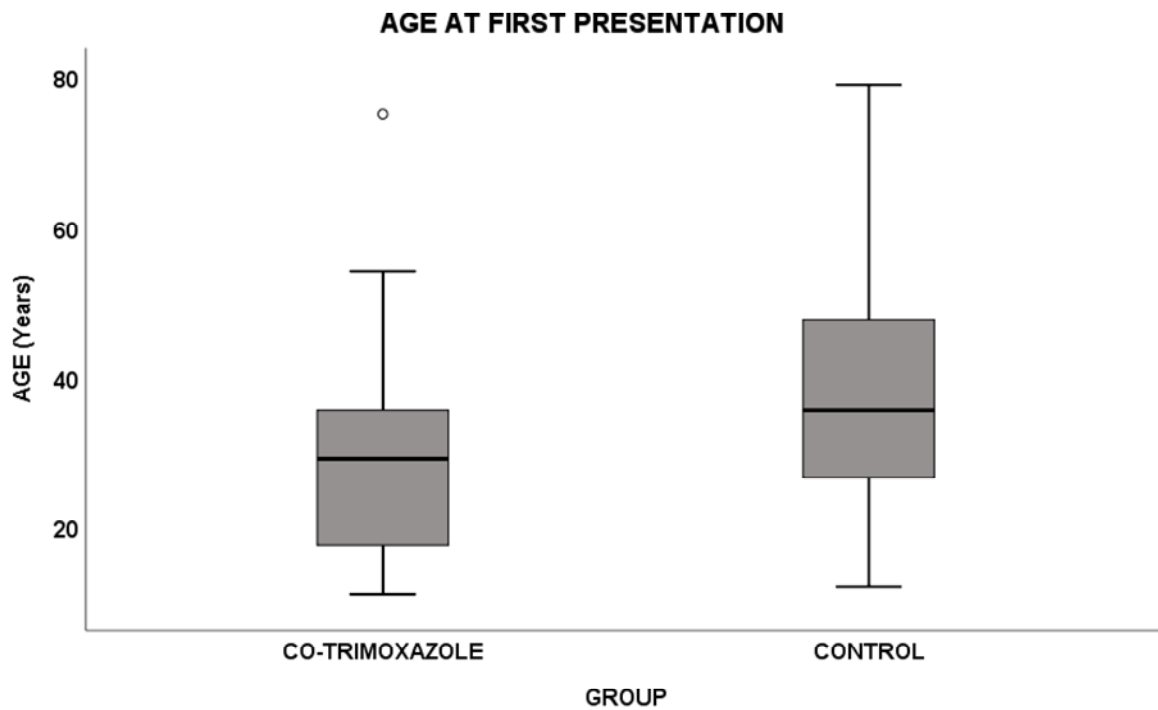
was used to measure the difference between two means of independent samples if they were not normally distributed such as visual acuity between the two groups and the number of disease flare-ups. Wilcoxon Sign rank test was used to compare the mean of two related samples such as visual acuity at first visit and last visit for each group. Cox regression analysis and Kaplan–Meier survival curves were compared statistically using log-Rank test survival curves to analyse time to disease flare between co-trimoxazole and control groups. All *p-values* represent two-tailed tests. All the analyses were performed using a statistical package software (IBM SPSS Statistics for Windows, Version 25.0. Armonk, NY: IBM Corp).

4.23 RESULTS

4.23.1 Demographics

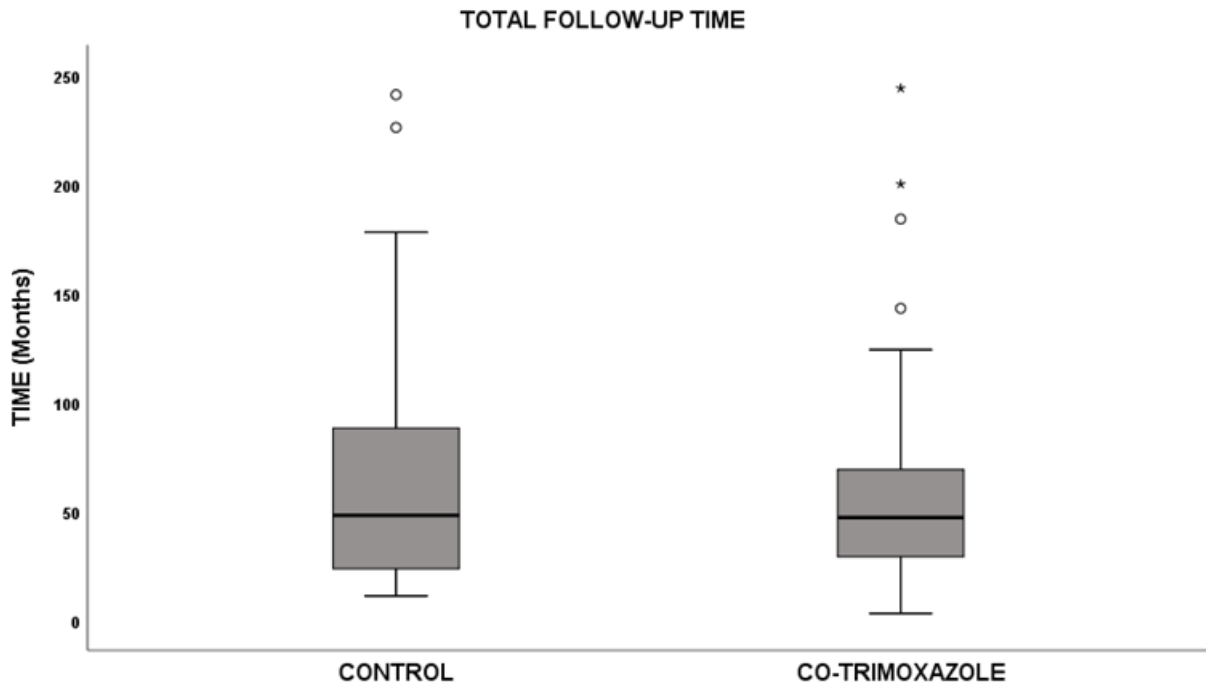
The study included 72 patients (81 eyes). Mean age at presentation for the entire study population was $32.7 \pm \text{SD}16$ years, the minimum age is 11 years, and the maximum is 79 years (IQR 19-41 years). The mean age for the control group was $37.73 \pm \text{SD} 16.48$ years, range from 12- 79 years, median 35.5 years. The mean age for the trimethoprim-sulfamethoxazole (co-trimoxazole) group was $27.93 \pm \text{SD}14.13$, range from 11-75 years, median 24 years. Although patients in the co-trimoxazole group were younger when compared to the control group, there was no statistically significant difference in age at first presentation between the two groups ($p=0.55$, Mann-Whitney, two-sided test). Figure 4-11.

Figure 4-11 Age at first presentation for the co-trimoxazole and the control group. There was no significant difference between the two groups (p value=0.55, Mann-Whitney, two-sided test).



The mean follow-up time for the entire cohort was 63.54 ± 54.23 SD months, range from 3 to 244 months. The mean follow-up time for patients in the trimethoprim-sulfamethoxazole group was 64 ± 53.78 SD, range from 3 to 244 months, median 48 months. For the control group, the mean follow-up was 63 ± 55.37 SD months, range 11 to 241 months, median 48 months. There was no statistically significant difference in follow-up time between the two groups (p-value = 0.81), Mann Whitney U two-sided test. Figure 4-12. Mean follow-up duration on co-trimoxazole was $16 \pm$ SE 2.5 months (\pm SD16.22 months); range 1 - 84 months; IQR from 4 to 20 months, and the median was 12 months.

Figure 4-12 Total follow-up time (months) for the co-trimoxazole and control groups. There was no statistically significant difference in follow-up time between the two groups (p-value = 0.81, Mann Whitney U, two-sided test).



The study included 35 male (48.6%) and 37 female (51.4%). With regards to the ethnicity of patients, 29 were White (40.3%), 23 Black (31.9%), 2 Asian (2.8%) and 18 other or not stated (25%). Thirty-two patients (41) eyes in the trimethoprim-sulfamethoxazole and 40 patients (40) eyes in the control group. Please refer to Table 4-3 for baseline demographics.

Table 4-3 Baseline characteristics

Baseline characteristics between the two groups (co-trimoxazole and control)			
	Co-trimoxazole	Control	P-value
Total number of patients	32 (41) eyes	40 (40) eyes	-
Mean follow-up	64± 53.78 SD	63 ± 55.37 SD	0.81 Mann-Whitney
Median Follow-up	49 months	45 month	
Mean age at presentation	27.93± 14.13 SD	37.73 ± 16.48 SD	P=0.55 Mann-Whitney
Male and female frequency	56% male versus 44% female	42.5% male versus 57.5 female	0.34 Fisher's Exact
BCVA at first presentation	0.42± 0.61 SD	0.67± 0.72 SD	0.054 Mann-Whitney test
Disease flare/year	Mean 2.1 ±2.3 SD	Mean 0.63± 0.40 SD	0.022 Mann-Witney test
Retinochoroidal scars at baseline Unilateral Bilateral	23 patients (72%) 9 patients (28%)	31 patients (77.5%) 9 patients (22.5%)	0.59 Fisher's Exact Test
Location	Eyes (%)	Eyes (%)	0.24 Chi square
Peripheral	14 (34)	20 (50)	
Macular	24 (59)	16 (40)	
Disc	3 (7)	4 (10)	
Immunocompromised Patients	2 (6%)	3 (7%)	0.65 Fisher's Exact
Ethnicity (no.)			0.21 Chi-Square
White	17	12	
Black	7	16	
Asian	1	1	
Others	7	11	

Two patients were known to be immunocompromised in the co-trimoxazole group, one patient due to multiple myeloma and bone marrow transplant and the other one due to lung cancer. In the control group three patients were immunocompromised one patient due to SLE (on immunosuppressive therapy), the second patient had HIV, and the third one had ulcerative colitis on immunosuppressive therapy. A unilateral disease was reported in 54 patients (75%), 23 on co-trimoxazole and 31 in the control group, while 18 patients had bilateral disease, 9 in each group.

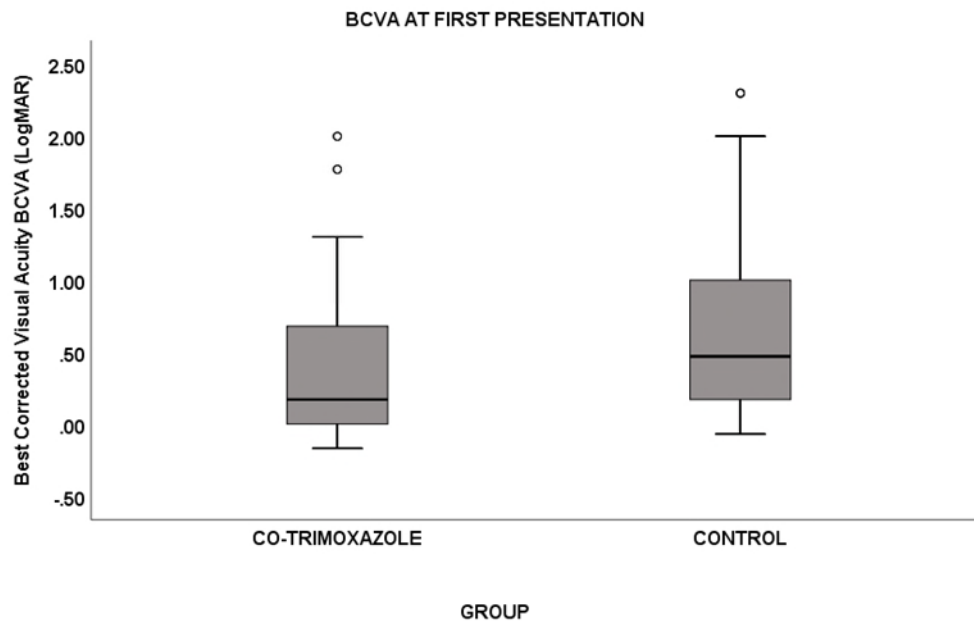
4.23.2 Location of the lesion

For the entire cohort, the most frequent location of toxoplasma retinochoroiditis lesion was macula, 40 eyes (50%) of cases followed by peripheral lesions 34 eyes (42%) and the optic disc was the least common location in 7 eyes (8%). The most frequent site in the co-trimoxazole group was macula in 24 eyes (59%) followed by peripheral location 14 eyes (34%). Conversely, in the control group, the most common lesion site was peripheral (20 patients) (50%) followed closely by macular involvement in 16 patients (40%). The optic disc involvement was in only three eyes (7%) in the co-trimoxazole group and four eyes (10%) in the control group.

4.23.3 Best corrected visual acuity

The mean best-corrected visual acuity (BCVA) at first presentation for the co-trimoxazole group was 0.42 ± 0.09 SEM range from (-0.17- 2.00) Log MAR, mean VA on starting co-trimoxazole 0.26 ± 0.08 SEM, range from (-0.17- 2.00) Log MAR, whereas, for the control group the mean BCVA at first visit was 0.67 ± 0.11 SEM, range from -0.07- 2.3 Log MAR. The difference in mean BCVA between the two groups at first presentation was not statistically significant (p-value= 0.054), Figure 4-13, whereas at last follow-up the difference was highly statistically significant (p-value=0.003) Mann-Whitney U two-sided test.

Figure 4-13 the difference in mean BCVA between the co-trimoxazole and control groups at first presentation was not statistically significant, (p-value= 0.054, Mann-Whitney U, two-sided test).



At three months mean BCVA for controls was 0.47 ± 0.10 SEM, whereas in co-trimoxazole group after three months of prophylactic treatment, 37 eyes had a mean BCVA of 0.21 ± 0.08 SEM a statistically significant difference between the two groups (p-value = 0.046) GEE. At six months follow-up 40 patients (eyes) in the control group had a mean BCVA of 0.46 ± 0.65 SD, and in co-trimoxazole group, there were 31 eyes with a mean BVCA of 0.24 ± 0.09 SEM, the difference between the two groups was not significant (p-value = 0.087) GEE. At one year 26 eyes on co-trimoxazole had a mean BCVA of 0.27 ± 0.10 SEM and control group had 40 patients with mean BCVA at one year of 0.48 ± 0.10 SEM, (p-value = 0.072), GEE. Tables 4-4 and 4-5.

Table 4-4 Mean BCVA for co-trimoxazole group and controls at baseline, three, six, twelve months and last follow-up visit.

BCVA LogMAR unit	Co-trimoxazole		Control	
	Mean	± Std. Error	Mean	± Std. Error
Baseline	0.42	0.09	0.67	0.11
Starting co-trimoxazole	0.26	0.08	-	-
Three months	0.21	0.08	0.47	0.10
Six-month	0.24	0.09	0.46	0.10
Twelve Months	0.27	0.10	0.48	0.10
Last follow-up	0.20	0.07	0.48	0.10

Generalised estimated equation (GEE) was used to compare the change in mean BCVA, adjusting for the time of follow-up and baseline visual acuity. The difference in BCVA between groups at baseline and at, three, six, twelve months and last follow-up visit, shows a statistically significant difference at three months and last follow-up visit, p-value = 0.046 and 0.044, respectively. At baseline, there was no statistically significant difference in BCVA (P-value=0.60). This p-value was close to the one obtained by Mann-Whitney U test at baseline (0.054). For the placebo group there was a significant difference in BCVA at all-time points, while for the co-trimoxazole group there was a statistically significant difference in BCVA at three months on co-trimoxazole, six months and last follow-up but not at one year when compared to baseline. Figures 4-14 and 4-15.

Table 4-5 Mean difference in BCVA from baseline and between groups using GEE.

	Co-trimoxazole			Control			Between-group difference	
	MD (SE)	95% C.I	P *	MD (SE)	95% C.I	P*	MD (SE)	P**
First presentation	-	-	-	-	-	-	-0.27 (0.14)	△0.60
Three months	-0.17 (0.08)	-0.34 - -0.014	0.034	-0.19 (0.07)	-0.35 - -0.03	0.015	-0.25 (0.12)	0.046
Six-month	-0.16 (0.08)	-0.33 - -0.003	0.045	-0.02 (0.09)	-0.38 - -0.03	0.018	-0.22 (0.13)	0.085
Twelve Months	-0.15 (0.08)	-0.32 - 0.01	0.075	-0.18 (0.09)	-0.36 - -0.008	0.041	-0.23 (0.13)	0.072
Last follow-up	-0.17 (0.07)	-0.32 - -0.02	0.024	-0.16 (0.07)	-0.30 - -0.01	0.027	-0.028 0.14	0.044

MD = Mean difference, SE= Standard Error, C.I= Confidence Interval.
 *p-value within group calculated using generalized estimating equation
 **p-value between groups calculated using generalized estimating equation
 △ At baseline *P-value* is slightly different between the two group compared to previous p-value (0.054) Mann-Whitney test, since it was calculated using GEE method.

Figure 4-14 BCVA between the two groups at three months a statistically significant difference between the two groups (p-value = 0.046, GEE).

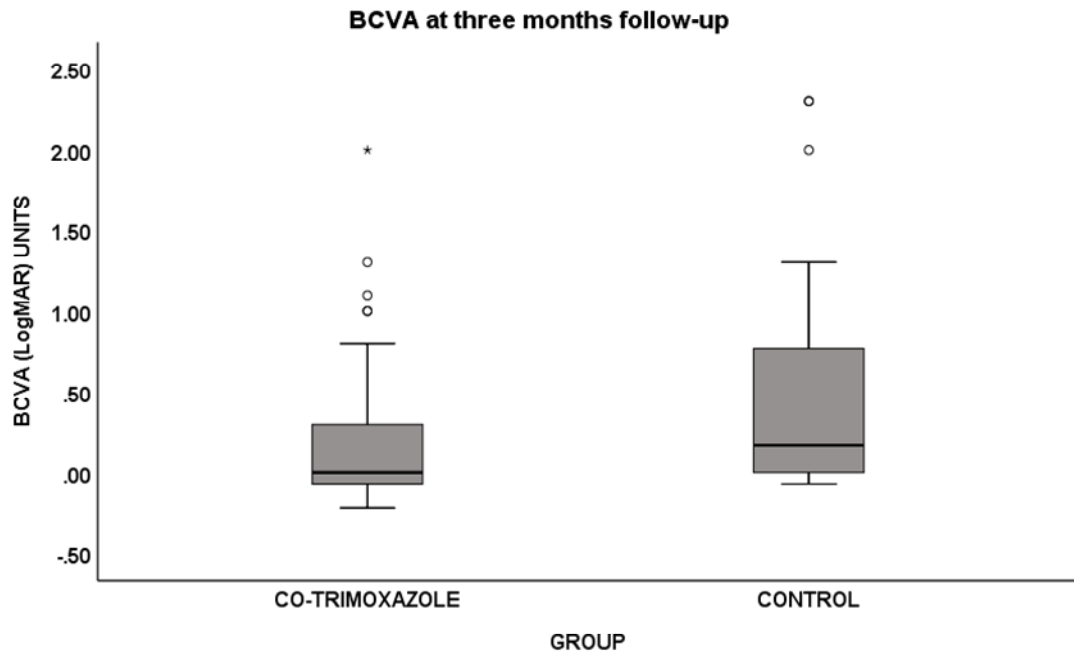
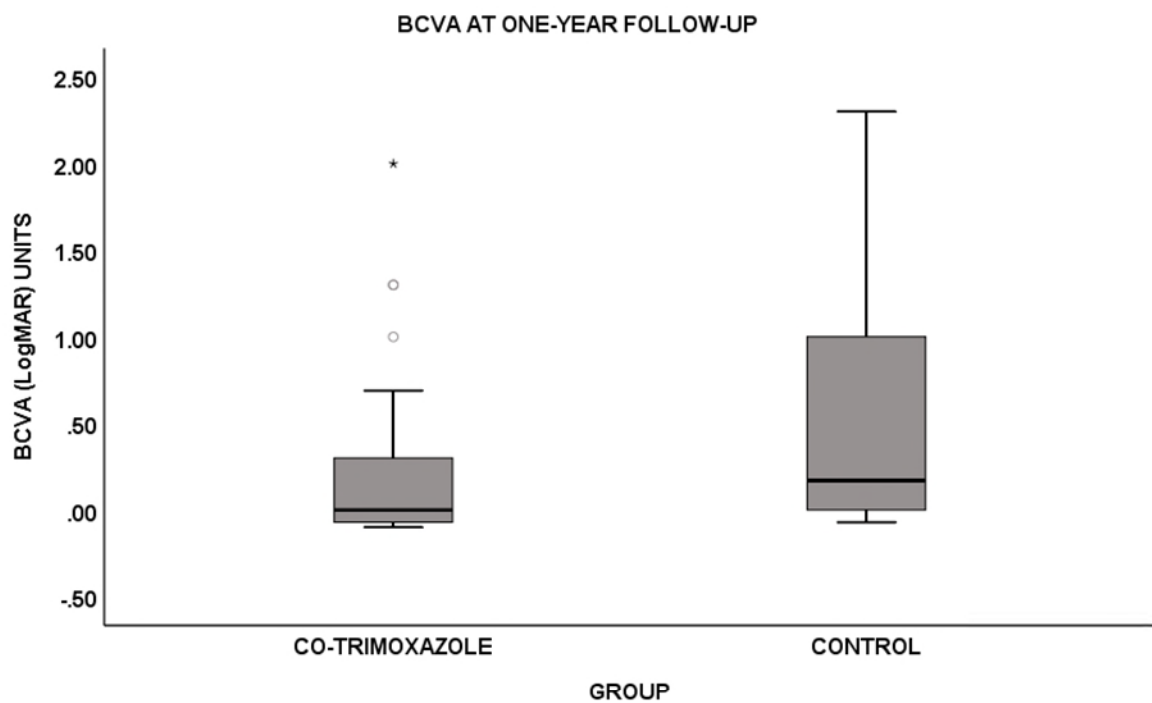


Figure 4-15 mean BCVA at one year, p-value =0.072, GEE (two-sided)



The difference in mean BCVA at last follow-up visit was statistically significant (p-value=0.044) using GEE test. Figure 4-16. There was also a statistically significant difference in mean BCVA between initiation and last visit on co-trimoxazole therapy, (P-value= 0.002), using Wilcoxon Signed Rank test. Figure 4-17.

Figure 4-16 BCVA between co-trimoxazole and control group at last follow-up. The difference in mean BCVA at last follow-up visit was highly statistically significant (p-value=0.044) using GEE test

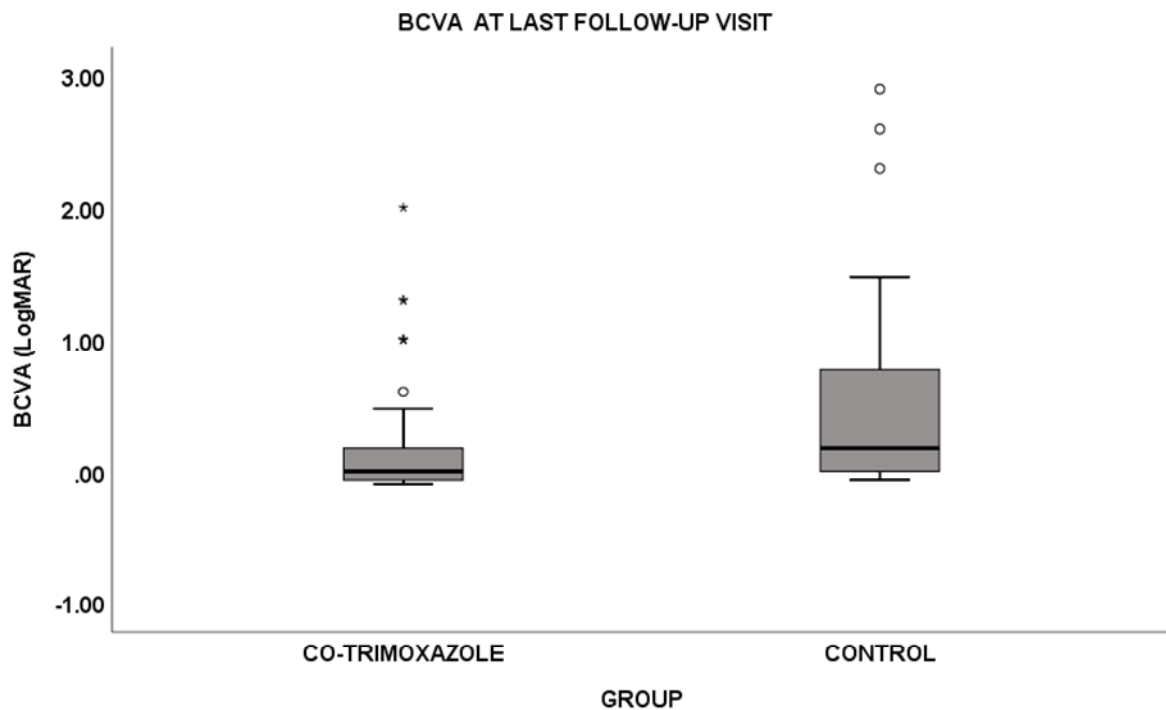
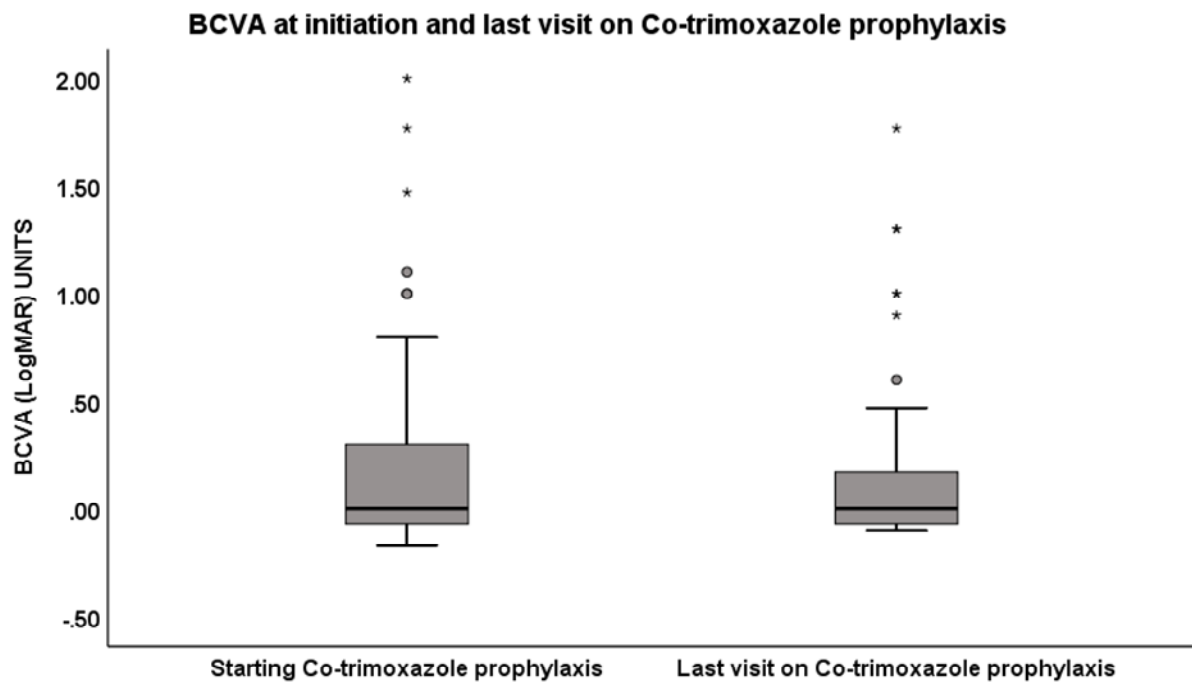


Figure 4-17 the mean BCVA at initiation and last visit on co-trimoxazole prophylaxis (p-value=0.002, Wilcoxon Signed Rank test).

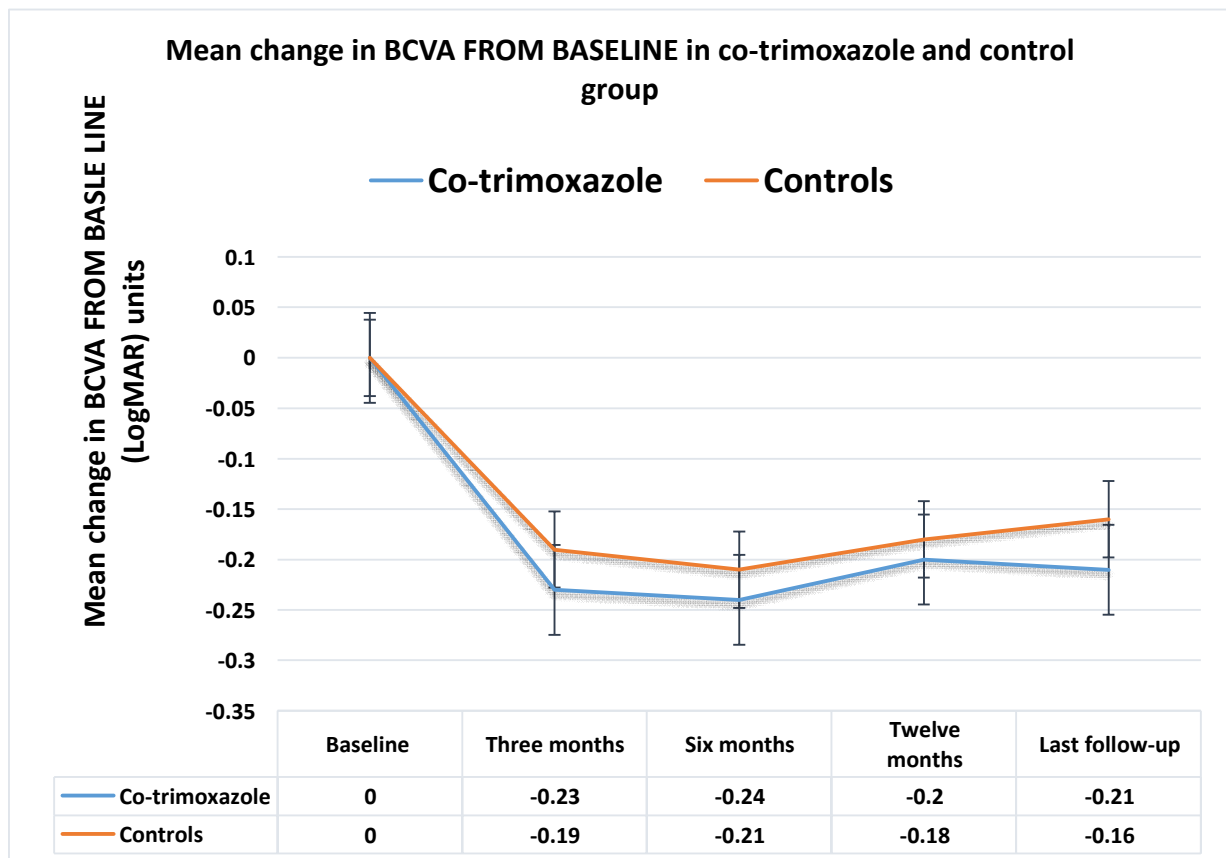


The mean difference in BCVA from baseline was higher in the co-trimoxazole group compared to controls at all time points (three, six, twelve months of co-trimoxazole treatment and at last follow-up). The mean difference was consistently bigger in patients on co-trimoxazole prophylaxis compared to controls. The higher the negative value, the better the visual acuity. Also, at last follow-up, the BCVA in the co-trimoxazole group tend to stabilise and even improve on or after co-trimoxazole therapy. Whereas, in the control group, BCVA tend to worsen at the end of follow-up and the line of mean differences shifts toward the baseline state (as the difference diminishes). Table 4-6 and Figure 4-18.

Table 4-6 Mean difference in BCVA from baseline for co-trimoxazole and control groups

Time	Co-trimoxazole		Controls	
	Mean difference	± SEM	Mean difference	± SEM
Baseline	0	-	0	-
Three months	-0.23	0.09	-0.19	0.08
Six months	-0.24	0.09	-0.21	0.09
1 year	-0.20	0.08	-0.18	0.09
Last follow-up	-0.21	0.08	-0.16	0.07

Figure 4-18 Mean change in BCVA from baseline.

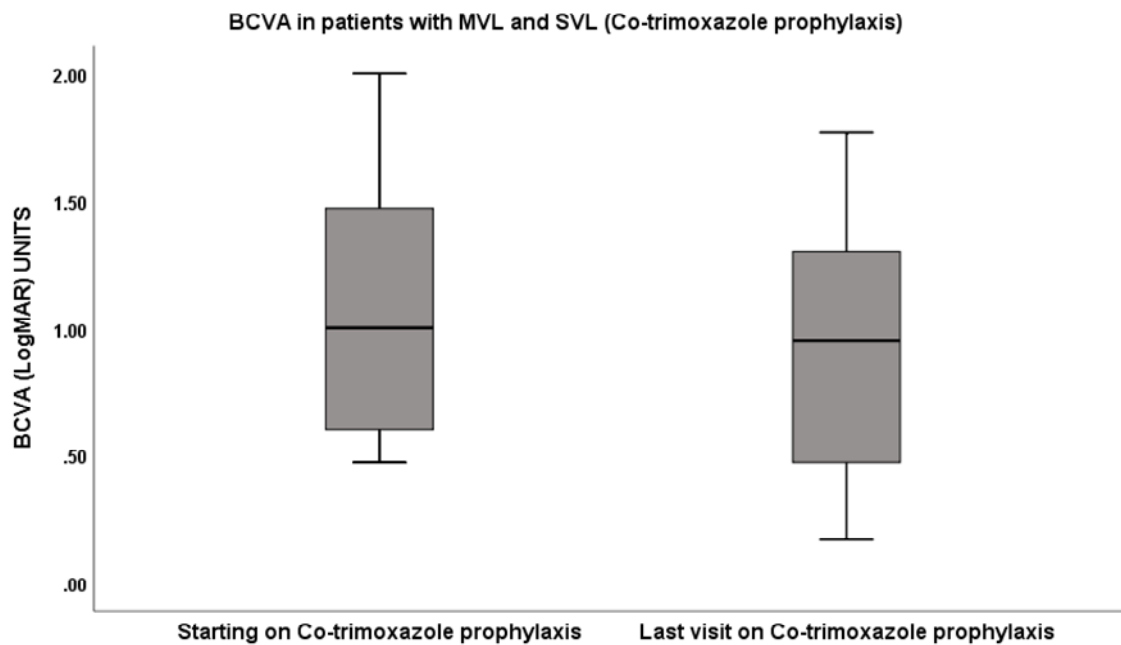


Moderate and severe vision loss analysis

There were six eyes with visual impairment, severe vision loss (SVL) or moderate vision loss (MVL) at the initiation of co-trimoxazole prophylaxis and there was no potential for visual improvement in these eyes and the treatment was indicated for the other (good) eye. Treatment is systemic, and the eyes with limited visual prognosis can still have disease recurrence, these eyes were included in the study. At the last follow-up visit, no additional eyes developed visual impairment and only 6 out of 41 eyes (14%) in the co-trimoxazole group have severe vision loss ($VA \geq 6/60$). The cause in these eyes was macular scarring, which was present at the time of starting co-trimoxazole prophylaxis, and none had a disease flare during or after co-trimoxazole prophylaxis. Only two eyes had moderate vision loss in the co-trimoxazole group at the end of follow up, and these two eyes already had moderate vision loss at the time of starting co-trimoxazole prophylaxis. Although the visual acuities for these eyes improved during the prophylaxis course, they remained with the MVL limits ($BCVA > 6/12$ and $< 6/60$).

In a sub-group analysis on ten eyes, with moderate or severe vision loss at the time of starting co-trimoxazole prophylaxis, the mean best-corrected visual acuity BCVA was 1.08 ± 0.51 SD LogMAR. These eyes showed a significant improvement in BCVA at last follow-up visit, mean 0.86 ± 0.51 SD LogMAR, (p-value 0.018, Wilcoxon Signed Ranks Test, two-sided). Figure 4-19. The mean change in vision between the first and last visit on co-trimoxazole treatment was 0.21 ± 0.22 SD LogMAR unit, the minimum is 0, and the maximum is 0.7 LogMAR unit. Interestingly only three patients did not have any change in vision, the remaining seven eyes (70%) gained vision on co-trimoxazole prophylaxis, two patients from MVL to no visual impairment and one from SVL to MVL. The other four had visual improvement but remained within the limits of either MVL or SVL, mean duration of co-trimoxazole prophylaxis was 1.29 ± 1.26 SD years. In those without vision loss at the time of initiating co-trimoxazole prophylaxis vision remained stable and there was no statistically significant difference in BCVA at last visit, (p-value 0.096, Wilcoxon sign rank Test, two-sided).

Figure 4-19 BCVA in patients with visual impairment (MVL+SVL) at initiating co-trimoxazole prophylaxis. There was a statistically significant difference in BCVA between the start and end of prophylaxis (p-value 0.018, Wilcoxon Signed Rank Test).



In the control group at last follow-up, nine patients (22.5%) had SVL in at least one eye, and in more than half of patients, the cause of SVL was macular scarring. The other two reasons of SVL in the control group were retinal detachment and glaucoma, and the percentages were 33% and 11% respectively. While only four patients had MVL at some point during their follow-up, at last follow-up visit seven patients (17.5%) had moderate vision loss and the two causes were macular scarring (71.4%) and glaucoma (28.6%). For visual impairment (MVL or SVL) at the end of follow-up, there were 16 patients in control group versus only 8 in co-trimoxazole prophylaxis group, and there was a statistically significant difference between the two groups (p-value=0.043, Chi-square, two-sided test).

In the co-trimoxazole group, there was no statistically significant difference between the proportion of patients with visual impairment at starting co-trimoxazole treatment and end of follow-up (p-value=0.50, McNemar Test). Similarly, there was no statistically significant difference in the rate of visual impairment in the control group at three months and last follow-up visit (P-value 0.26, McNemar Test). Table 4-7.

Table 4-7 causes of moderate and severe vision loss in eyes with recurrent toxoplasma retinochoroiditis

	Co-trimoxazole			Control group		
	Baseline	Last follow-up		Baseline	Last follow-up	
Causes	MVL+SVL No. (%)	MVL No. (%)	SVL No. (%)	MVL+SVL No. (%)	MVL No. (%)	SVL No. (%)
Macular scarring	9 (22%)	1 (2.5%)	6 (14%)	9 (22.5%)	5 (12.5%)	5 (12.5%)
Retinal detachment	-	-	-	1 (2.5%)	-	3 (7.5%)
Cataract	-	-	-	2 (5%)	-	-
Vitreous debris	1 (2.5%)	1 (2.5%)	-	2 (5%)	-	-
Advanced glaucoma	-	0 (0%)	0 (0%)	2 (5%)	2 (5%)	1 (2.5%)
Total	10 (24.5%)	2 (5%)	6 (14%)	16 (40%)	7 (17.5%)	9 (22.5%)

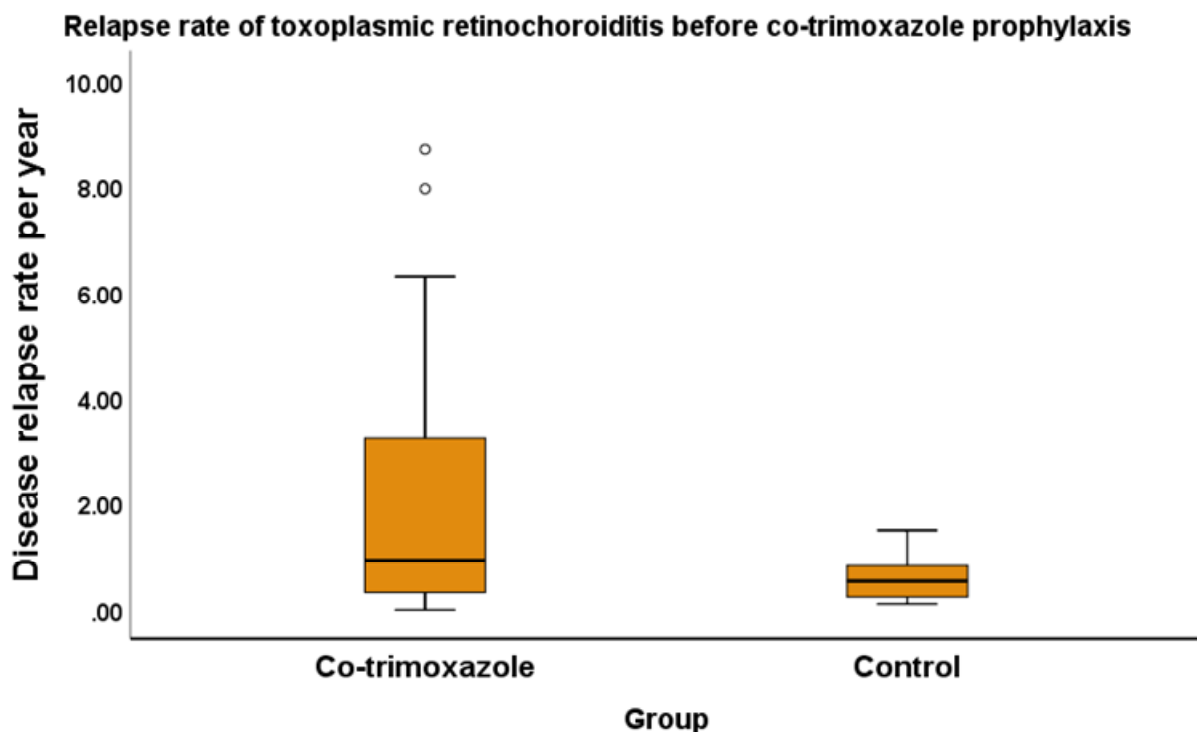
4.23.4 Relapse rates

Before starting co-trimoxazole prophylaxis, all patients (100%) had disease relapse, and the majority of patients 80% (33 out of 41 eyes) had disease relapse in at least one eye. However, during the prophylactic course, 37 eyes (90%) did not have any disease relapses, and treatment failure (development of disease flare while on prophylaxis occurred in only four patients (4 eyes) (9.75%) (two patients with prior unilateral ocular involvement and two patients with previous bilateral ocular involvement). In the prophylaxis group, disease recurrences developed at the following intervals after commencing the co-trimoxazole prophylaxis: 3 months, six months, 11 months and 18 months.

Among patients in the control group recurrences developed in 28 patients 70%; 6 (22.3%) patients had previous bilateral ocular involvement and 21 (77.7%) patients

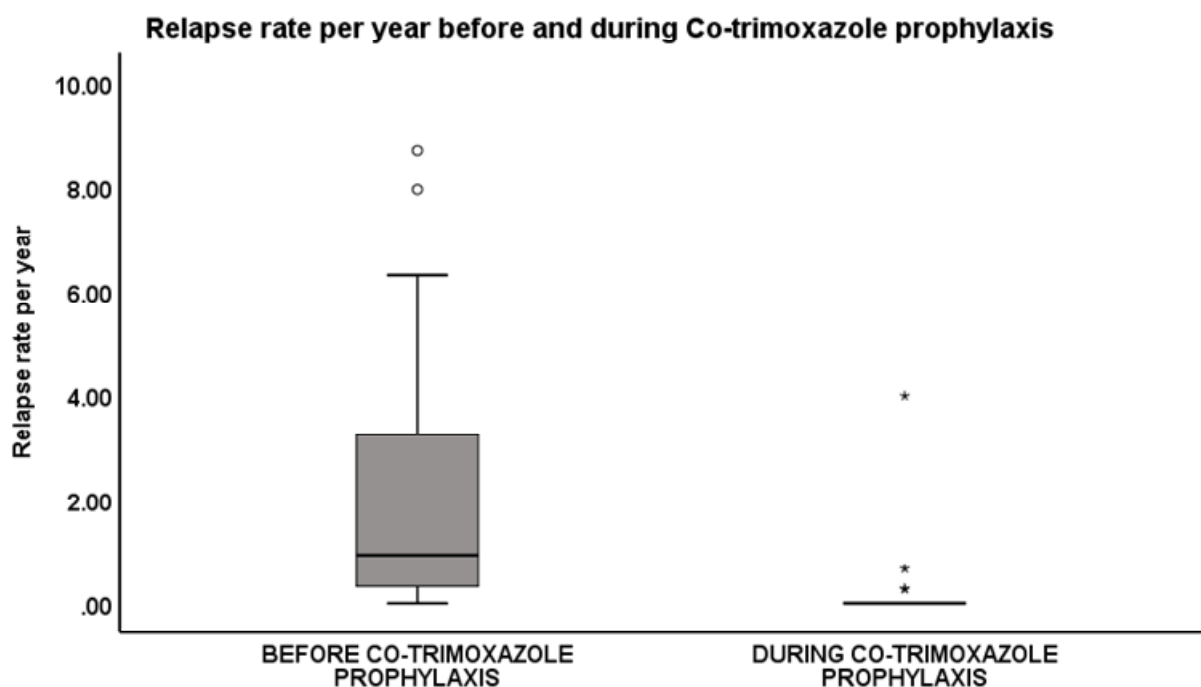
with prior unilateral ocular disease. Bilateral ocular disease was not associated with increase disease relapse (p-value 0.90, Chi square Test). Recurrences developed in the control group at different intervals, mean 27.59 ± 25.23 SD months, median 15.3 months range from 0.7 to 86.5 months, IQR from 10 to 41 months. Fourteen patients (35%) develop more than one disease relapse during the follow-up time after the first acute episode (13 patients had 2 events, and one patient had four events). The proportion of patients with disease relapses was significantly lower in the co-trimoxazole prophylaxis group when compared to the control group (p-value<0.001) Chi-square test. The average number of relapses per year for the control group during the entire follow up time was 0.63 ± 0.06 SEM disease relapse/year, whereas, for the co-trimoxazole group the average flare-ups per year before co-trimoxazole treatment is 2.10 ± 0.36 SEM. There was a statistically significant difference in the rate of disease flare-ups per year between the two groups before prophylaxis has started (p-value= 0.022, Mann Whitney U test, two-sided). Figure 4-20.

Figure 4-20 Relapse rate per year for both groups before co-trimoxazole prophylaxis, a statistically significant difference, (p-value = 0.022, Mann Whitney U test, two-sided).



During co-trimoxazole prophylaxis, the mean number of disease relapses dropped from 2.10 to only 0.12 ± 0.09 SEM, and there was a statistically significant difference between the rate of disease relapse before and during co-trimoxazole prophylaxis, ($p < 0.001$, Wilcoxon Signed Rank test, two-sided). Figure 4-21. The mean number of disease relapses in the control group after the first acute episode (time 0) was 0.28 ± 0.27 . Similarly, there was a statistically significant difference in the mean number of disease relapses per years between controls and patients on co-trimoxazole prophylaxis, (p -value < 0.001 , Mann-Whitney U test two-sided).

Figure 4-21 Relapse rate per year of toxoplasmic retinochoroiditis before and during Co-trimoxazole prophylaxis. A highly statistically significant difference (p -value < 0.001 , Wilcoxon Sign Rank test, two-sided).



The mean number of disease relapses/year since the date of initiation of co-trimoxazole prophylaxis till the last day of follow-up was 0.089 ± 0.24 SD. Interestingly, the difference in the rate of disease flare-ups/year during and after co-trimoxazole prophylaxis remained statistically significant when compared to rate before co-trimoxazole (even when 63% of patient had already stopped their prophylactic treatments), p -value < 0.001 (Wilcoxon Signed Rank test) (two-sided). Similarly,

comparing the rate of relapses/year between the control and co-trimoxazole groups since starting co-trimoxazole therapy till the last visit revealed a statistically significant difference, ($P < 0.001$), Mann-Whitney U (two-sided) test. Table 4-8.

Table 4-8 Comparison of relapse rate per year and proportion of patients with disease relapse in co-trimoxazole and control groups.

Comparison between the co-trimoxazole and control group at the end of follow-up			
	Co-trimoxazole	Control	P-value
Relapse rate	Mean 0.12 ± 0.62 SD	Mean 0.28 ± 0.27 SD	< 0.001 Mann-Whitney U
The proportion of patient with disease relapse	4 (9.75%)	28 (70%)	< 0.001 Chi-Square

After the acute episode (time 0) in the control group, 28 patients out of 40 (70%) developed further disease relapses at an average of 2.30 ± 2.10 SD years, range from 0.06 - 7.21 years (from 0.7-86 months), interquartile range IRQ (0.85-3.46) years and median is 1.28 year. 75% of patients developed disease relapses before 3.5 years. Whereas for the patients who have had the co-trimoxazole prophylaxis course only 4 out of 41 (9.75%) eyes had disease relapse during the prophylaxis course, the mean time to the first relapse was 0.81 ± 0.54 SD, range from 0.25-1.52 years, IQR 0.32 - 1.37 years and median is 0.73 years.

Disease-free survival analysis-1

A comparison between the two groups with regards to disease-free survival strictly during the period of co-trimoxazole prophylaxis (flare-ups after stopping treatment were not included) shows a statistically significant difference (p-value= 0.022, Log-Rank test). Figure 4-22. Cox-regression analysis revealed a statistically significant difference, (p-value=0.03), (HR 0.30; 95%CI; 0.10-0.88). Figure 4-23.

Figure 4-22 Relapse-free survival between the control group and co-trimoxazole group Kaplan Meir survival analysis with Log-rank test for significance (p-value =0. 022)

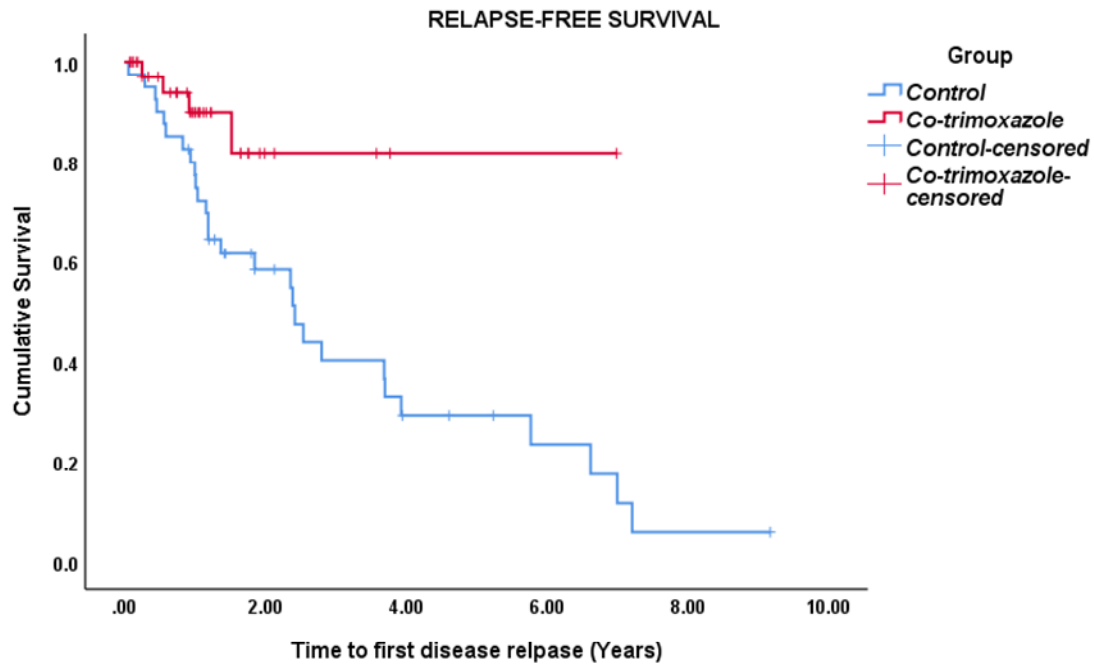
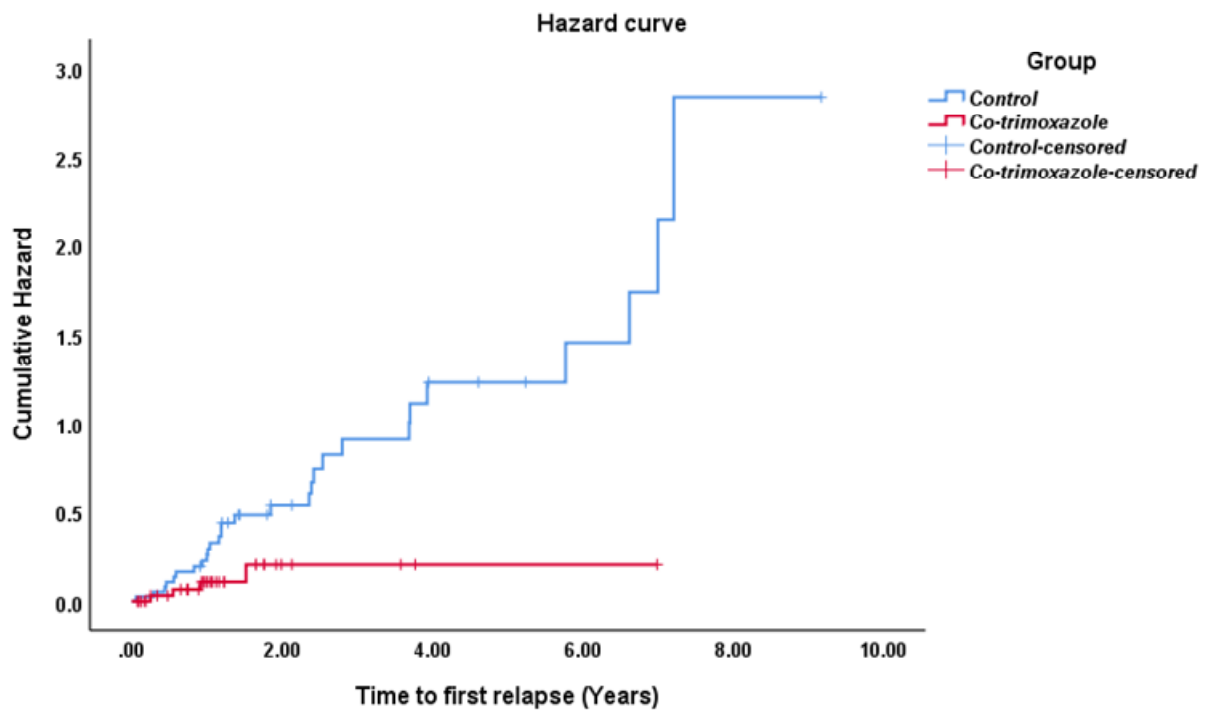


Figure 4-23 Hazard curve between the control group and co-trimoxazole group, HR 0.30 (95%CI; 0.10-0.88) (p-value=0.03)

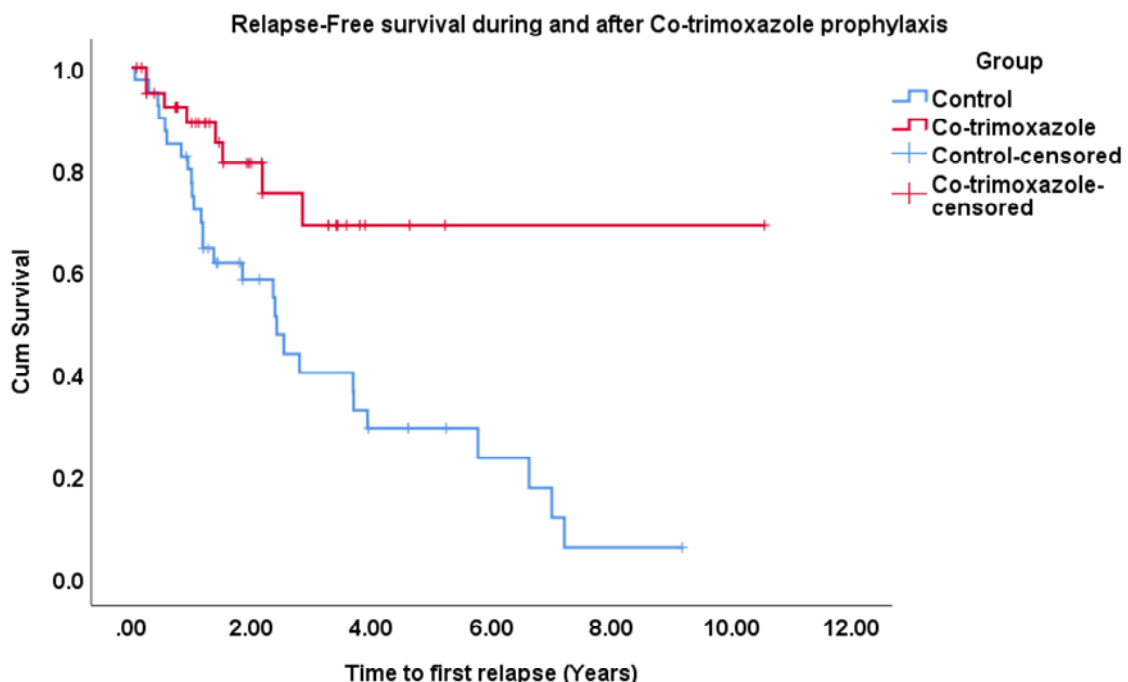


The mean survival for the control group was 3.33 ± 0.48 ; 95%CI 2.39-4.27 years; while for the co-trimoxazole group the mean relapse-free survival was 5.89 ± 0.53 ; 95%CI 4.84-5.95 years. The median relapse-free survival for the control group was 2.40 ± 0.42 ; 95%CI 1.61-3.22 whereas for the co-trimoxazole group the median time was not calculated as fewer patients had disease relapse.

Disease-free survival analysis-2

The survival rate between the two groups (the control and the co-trimoxazole prophylaxis) was also calculated from the date of starting co-trimoxazole prophylaxis till the time of the first relapse whether during the prophylaxis period or after (when the prophylaxis had stopped) or last follow-up when no disease relapse occurred. The result shows a significant difference in risk of disease relapse (p-value=0.009 HR 0.34; 95%CI 0.15-0.77), using Cox regression analysis. There was a statistically significant difference between the two groups even when the majority of patients (63%) had stopped their treatment. Kaplan Meir survival curves show a significant difference in disease relapses between the two groups (p-value of 0.007, Log Rank). Figure 4-24.

Figure 4-24 Disease-free survival between the control group and co-trimoxazole group. Kaplan Meir survival curves show a significant difference in disease relapses between the two groups (p-value of 0.007, Log Rank Test)

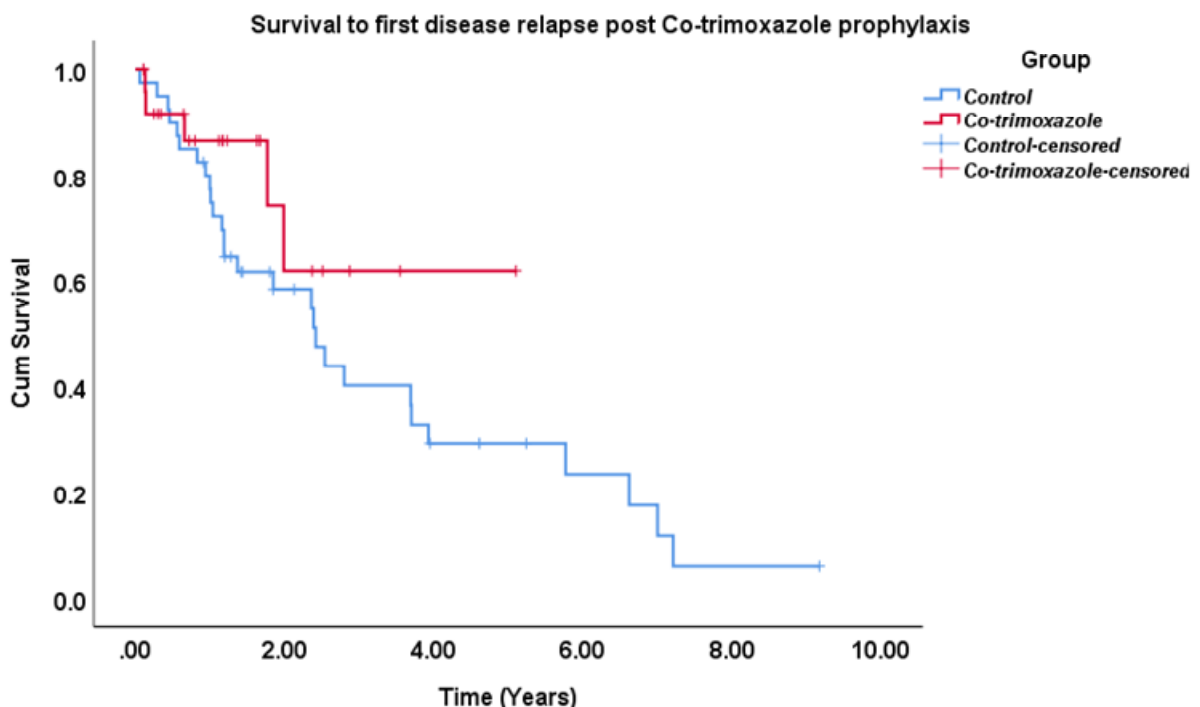


In the Cox regression equation, the median survival time (time point at which 50% of subjects in a particular group had the event (disease relapse) was not applicable for the co-trimoxazole group because the majority of patients (80%) did not flare during the follow-up period. Conversely, in the control group the median survival time was 2.42 ± 0.41 SE; 95%CI 1.61-3.22, the mean survival time for the co-trimoxazole group was 7.75 ± 0.86 SE; 95%CI 6.05-9.46), while the mean survival time for the control subjects was 3.33 ± 0.48 SE (95%CI 2.39 – 4.27) years.

Disease-free survival analysis-3

The third Cox regression analysis was performed on patients who have stopped taking their co-trimoxazole prophylaxis (26 eyes) of whom five had disease relapse (Mean 0.93 ± 0.39 SE, median 0.66 year, range from 0.13 to 1.99 years. Cox regression p-value =0.18; HR 0.51; 95%CI 0.19-1.37. In survival analysis mean time to the first flare after co-trimoxazole was 3.66 ± 0.55 SE; 95%CI 2.58-4.74 years. Whereas, for the control group the mean time to the first flare was 3.33 ± 0.48 SE (95%CI 2.39-4.27) years. Median survival for the co-trimoxazole group could not be estimated. Log Rank test p-value=0.17. Figure 4-25.

Figure 4-25 Post co-trimoxazole prophylaxis survival curves between the control group and co-trimoxazole group (p-value=0.17, Log Rank Test)



4.23.5 Multiple prophylactic courses

Four patients (5 eyes) had more than one course of co-trimoxazole prophylaxis. The first patient had a second prophylactic course for one year and seven months and did not develop any disease flare-ups during that period similar to his initial course where no disease relapses had occurred. The reason to restart co-trimoxazole prophylaxis was the development of disease flare after stopping the initial prophylaxis course which was for one year and nine months. The second patient had two additional prophylaxis courses, his second prophylaxis session which lasted for approximately ten months during which he had no disease flare; similarly, the third prophylaxis continued for 12 months, and no disease flare-up was noticed during that period. While with the initial course the patient had a disease flare after six months of therapy in the following two courses no disease relapse was noticed. The reason to start the third course of co-trimoxazole was the development of relapse two months after stopping the second prophylaxis treatment. No flare-ups were recorded after the third prophylaxis. The patient who failed the first course of co-trimoxazole (developed disease flare on prophylaxis treatment) had no disease relapse in the subsequent course. The third patient had disease flare-up during his first and second prophylaxes, the first disease recurrence while on therapy occurred after only three months of starting co-trimoxazole prophylaxis while the second relapse occurred after 2.5 years. This patient was immunocompromised (multiple myeloma and bone marrow transplant) and he continued his prophylactic treatment and had retained normal visual acuity at last follow-up. The fourth patient had a disease flare eight months after stopping his primary prophylaxis. He developed a disease relapse after 4.5 months of starting the second prophylactic course while no relapses developed in his first session. The secondary prophylaxis was shorter due to the development of flare-up during the second prophylaxis. The first two patients had suboptimal doses of co-trimoxazole during the prophylaxis period 960 mg twice per week instead of 960 mg three times per week.

The first prophylactic course stopped in 17 patients (22 eyes) due to disease control (52%), one patient due to pregnancy (3%) whereas nine patients (11) eyes (26%) continued the prophylaxis treatment and had no recurrence during this time and till their last follow-up. Three patient resumed their prophylaxis due to the development

of disease flare after stopping trimoxazole prophylaxis, and therefore, 12 patients (15 eyes) were on co-trimoxazole till their last follow-up.

4.23.6 Safety of prophylaxis treatment

Treatment with Co-trimoxazole was well-tolerated by the majority of patients and was stopped by only 3 out of 32 patients (9%) due to the development of drug-related side effects (urticarial skin rash in all three patients and no significant side effects occurred). All these drug-related side effects happened early in the course of prophylactic treatment, mean time 0.18 years (\approx 2 months), range 1- 4 months. These side effects disappeared after stopping the treatment.

4.24 Discussion

In toxoplasmic retinochoroiditis, the mechanisms through which disease recurrences occur remain unclear, and with each disease relapse, more retinal tissue damage will ensue, and if the scar involves the fovea or the optic disc, severe sight loss will result. Both sexes are equally affected, and all age groups are at risk, and there is no cure for it. Patients with congenital infection tend to be at high risk of bilateral disease with macular involvement, and this age group is at risk of disease recurrences—similarly, younger patients with acquired infection at higher risk of future disease relapses and subsequent visual loss. Since current antibiotics do not eradicate the tissue cysts; recently, two studies have looked at a prophylactic treatment to protect from disease relapse and prevent loss of vision in patients with recurrent disease. However, these studies were conducted in Brazil where different disease strains, with high virulence, exist. Also, both studies lacked long-term follow-up and have reported conflicting results with regards to post prophylactic protection against disease recurrences. Also, the impact of preventative treatment on the final visual acuity was unclear in these results. Assessing the long-term benefits of co-trimoxazole prophylaxis in a different population will help better understand disease course and improves management of patients with high risk of sight loss due to toxoplasmic retinochoroiditis.

In this study, we assessed the prophylactic effect of co-trimoxazole retrospectively in a cohort of patients in the UK with longer follow-up time to see if the efficacy of prophylactic treatment is different from those in Brazil, using survival analysis.

Additionally, evaluating the long-term effects of antibiotic prophylaxis on disease relapses and the impact of prophylactic treatment on the final visual acuity in patients treated with co-trimoxazole versus control group, since recurrent relapses are associated with sight loss. The primary study findings were that prophylactic co-trimoxazole has significantly reduced the rate of disease recurrence compared to the control group and also, substantially improved relapse-free survival time among treated patients. Importantly, there was a significant improvement in vision in patients received prophylactic treatment which may be due to much-improved disease control.

Our data shows that the mean age at presentation with symptomatic ocular toxoplasmosis was 32 years, which is similar the mean age of first attack reported previously (Bosch-Driessen, Berendschot et al. 2002, Silveira, Belfort et al. 2002). Mean age at first presentation for the co-trimoxazole subjects was lower than the control group (27 versus 37) years but was not statistically significant. The mean age for patients in the co-trimoxazole prophylaxis group (27 years) was close to what was reported in Silveira et al. study (26.4 years). Patients on co-trimoxazole prophylaxis were younger and had more frequent disease relapses compared to the control group. As previously shown in other studies younger subjects experienced higher recurrence rate and were at high risk of vision loss (Garweg, Scherrer et al. 2008) (Holland, Crespi et al. 2008). This difference may reflect different disease course in younger subjects compared to older ones, therefore, they were placed on prophylactic course. Alternatively, prophylaxis started because after subsequent relapses the retinochoroidal scar expanded to an extent that with the following relapse, which usually occurs at the edge of the scar, important structures, namely, the fovea and the optic nerve head are at risk of permanent damage and severe vision loss.

In our study both, (co-trimoxazole and control group) have an approximately same mean duration of follow-up (almost 64 months). The rate of disease relapse is both age and time-dependent. As previously mentioned, younger patients tend to develop more frequent disease relapses, and the frequency of disease relapses may also decrease over time. However, with longer follow-up a higher proportion of patients will eventually develop disease relapse. Therefore, comparing disease relapse rate between two groups with equal follow-up time would help better estimate the effect of the intervention (prophylactic co-trimoxazole) in the presence of several confounding factors in the background.

The mean duration of follow-up on co-trimoxazole prophylaxis only was 16 months, IQR 4-20 months. Most patients in our study had 1 or two years course based on the previous studies (Silveira, Belfort et al. 2002) (Felix, Lira et al. 2016), and patients with more-extended prophylaxis were those who elected to continue on co-trimoxazole to avoid the future disease relapses when co-trimoxazole has stopped.

Bilateral involvement with ocular toxoplasmosis was previously reported to vary between 22 and 40% (Bosch-Driessen, Berendschot et al. 2002), which is consistent with our finding of 25%. Bilateral involvement was reported higher in patients with congenital disease 65-97% (Bosch-Driessen, Berendschot et al. 2002). Previous studies on co-trimoxazole prophylaxis reported different figures for bilateral ocular involvement, in Silveira et al. it was 54% whereas, in Felix et al. bilateral ocular involvement was 14%. Most patients in our study have unilateral disease 75%, and this is higher than previously reported in studies on co-trimoxazole prophylaxis, which might be due to an acquired infection rather than a congenital one. However, in our cohort, a bilateral ocular disease has not been shown to influence disease relapses (p-value 0.90, Chi-square test).

Our series shows a higher percentage of patients with macular involvement in the co-trimoxazole group (60%) compared to control (40%). The frequent macular involvement in the co-trimoxazole group is not surprising, as these patients are at higher risk of vision loss from disease reactivation with enlargement of the scar with subsequent loss of central vision. Therefore, it was prudent to start co-trimoxazole prophylaxis to prevent disease recurrences and irreversible loss of sight.

The control group, on the other hand, had peripheral retina most commonly involved by toxoplasma lesions, followed by macular involvement. The exact location of the retinal lesions of ocular toxoplasmosis was not reported in Silveira et al. study. However, macular involvement was higher in our study compared to the previous report from Felix and associate where macular lesions were found in only 30% of co-trimoxazole and 34% in the placebo group, and none had disc involvement.

While the previous studies have excluded immunocompromised patients, this study included five immunocompromised patients two in the co-trimoxazole group and three in control. The efficacy of co-trimoxazole prophylaxis did not differ among those patients compared to immunocompetent subjects. Also, this study has also included

all age group and patient as young as 11 years old had co-trimoxazole prophylaxis. Co-trimoxazole prophylaxis was safe and effective in children and immunocompromised patients.

4.24.1 Best Corrected Visual Acuity

Sight-threatening toxoplasmosis lesions were defined as those near the fovea or the optic nerve which was previously described in other studies (Pearson, Piracha et al. 1999, Bosch-Driessen, Verbraak et al. 2002), and these patients were more likely to start the chemoprophylaxis to preserve their sight. The first visit is often associated with a disease relapse, and therefore, BCVA is usually compromised due to increased inflammatory activity in the vitreous in association with active retinitis. Therefore the BCVA scores were lowest at first visit. After three months (with or without treatment), the inflammation usually settles down, and the patients return to their baseline visual acuity (before relapse) unless permanent damage to visual sensitive structures had taken place (fovea, disc).

There was no statistically significant difference between the mean BCVA of co-trimoxazole and control group at initial presentation, 0.42 versus 0.67 Log MAR (p-value 0.054 Mann-Whitney test). For patients treated with co-trimoxazole prophylaxis, the mean BCVA at first visit was worse than that at starting co-trimoxazole prophylaxis 0.42 versus 0.26 Log MAR (lower scores indicate a better vision). Most patients would start their prophylaxis treatment after being treated for the acute attack, usually with oral antiparasitic agents and corticosteroids to reduce the inflammatory activity. However, at the end of follow-up patients on co-trimoxazole prophylaxis have better vision compared to the ones without prophylactic therapy (p-value = 0.003), Mann-Whitney test.

Using generalised estimating equation (GEE) model adjusted for time of follow-up and baseline visual acuity, also shows a statistically significant difference between the two groups at last follow-up visit, (P-value= 0.044), whereas, at baseline, there was no significant difference, (P-value=0.060).

This significant difference in BCVA at last follow reflects better disease control and fewer complications in the co-trimoxazole group compared to the control group. Interestingly, there was a statistically significant difference in mean BCVA at starting

co-trimoxazole prophylaxis and last follow-up visit (p-value 0.002). This is probably because the majority of patients enjoyed a relapse-free period which allowed for better visual recovery and remodelling of the scar tissue. Sub-group analysis showed that the difference lies within the group of moderate and severe vision loss (MVL+SVL). Patients with visual impairment at starting co-trimoxazole prophylaxis have gained vision at the end of follow-up (p-value = 0.018). Whereas, in controls, comparing the BCVA at three months and the last follow-up revealed no statistically significant difference in BCVA (p-value 0.55, Wilcoxon Signed Rank Test).

In Felix et al. study, although, the figures for final BCVA suggests that patients with disease relapse had lower vision compared to those without relapse, the difference between the two groups was not significant at last follow-up (12 months), (p-value = 0.17). Failure to show a significant difference in BCVA between the two groups might be because over 65% of subjects in both groups had peripheral lesions and the impact of this location on final visual acuity is very minute if none. While in our study 60% of co-trimoxazole group and 40% of control patients had macular involving lesions which have a high impact on final vision. Alternatively, shorter follow-up in Felix study might have contributed to the lack of difference in BCVA between the two groups. Silveira et al. study did not report data with regards to the location of the lesion within the ocular fundus nor did it give an account on the visual acuity of patients at starting the trial and last follow-up visit. The longer follow-up (mean of 5 years) for all our study population and frequent macular involvement might explain the significant difference in BCVA between the two groups in our study.

The other important cause for the significant difference in BCVA between the two groups in our study compared to the previous reports is the higher rate of disease recurrence in the control group. As previously mentioned recurrent disease is associated with poor final vision in patients with toxoplasmic retinochoroiditis (Holland, Crespi et al. 2008), and the risk of disease relapse is higher with longer duration follow-up. Our data show that with a mean follow-up of five years, more than two-thirds of patients in the control group have developed one or more disease relapses in the study eye. By contrast, previous studies on co-trimoxazole prophylaxis, the highest percentage reported for patients with disease relapse was around 20%. Compared to previous, the proportion of patients in our study who developed disease relapse, was three times larger than those in previous studies and since recurrent flare-ups are

associated with poor vision, the difference noticed in final BCVA may be attributed to the higher proportion of patients with relapses in our control group.

Some might argue that there is a natural improvement in BCVA after the attack of ocular toxoplasmosis and therefore, the effect on vision is not specific to co-trimoxazole prophylaxis. However, the improvement witnessed with co-trimoxazole prophylaxis was not replicated in the control group. Therefore, the lower rate of disease relapse in co-trimoxazole group had led to a significantly better visual acuity in prophylactic treated patients compared to controls. Alternatively, co-trimoxazole therapy might have controlled a state of subclinical infection or inflammation associated with parasitic activity within the retina that would interfere with good visual recovery even when no apparent inflammation is present.

However, these results must be interpreted with caution since the follow-up time varies between subjects within the co-trimoxazole group and control group. Moreover, the allocation of patients to prophylaxis may have involved significant bias as most patients who have started the prophylactic course have good vision since prophylactic treatment has been adopted in previous studies to preserve visual function in high-risk patients (those with recurrent or sight-threatening lesions). Therefore, a selection bias could not be ruled out, however, with respect to vision at the start of follow-up, there was no statistically significant difference between the two groups. Compliance with co-trimoxazole could not be adequately assessed, since any non-compliance may have an impact upon the efficacy of the treatment. Without prophylactic co-trimoxazole those patients final BCVA would have been much worse due to scarring in retinal sites critical for vision or damage to the optic nerve. To our knowledge, this is the first study to report improvement in vision on co-trimoxazole prophylaxis.

4.24.2 Visual impairment

At the end of follow-up, only six eyes (14.6%) on co-trimoxazole prophylaxis had severe vision loss, and this was present before the introduction of co-trimoxazole prophylaxis, and none had disease flare-up during or after the therapy. Similarly, only two eyes had moderate vision loss at the end of prophylaxis which was recorded at the time of starting co-trimoxazole prophylaxis. Interestingly, the visual acuities in these eye with moderate or severe vision loss have improved during co-trimoxazole

prophylaxis. However, they remained within the range of visual impairment. No other eye had developed severe or moderate vision loss during or after prophylaxis.

By contrast, the control group had higher frequencies of severe vision loss in at least one eye. The most common cause of severe vision loss was similar to that of the co-trimoxazole group, macular scarring. However, patients in the control group have had in addition to macular scarring, glaucoma and retinal detachment, whereas none in co-trimoxazole groups have had these as a direct cause for visual impairment. Legal blindness ($VA \leq 6/60$) in at least one eye, in the control group developed in nearly a quarter of patients and the leading causes were; macular location of the retinal lesions and retinal detachment, findings that are consistent with the literature (Montoya, Parmley et al. 1999, Bosch-Driessen, Karimi et al. 2000). Higher disease relapses in the control group were the primary cause of the poor final visual outcome, in an agreement with a previously published large series where the majority of patients with severe vision loss were those with a recurrent disease over five years follow-up (Bosch-Driessen, Berendschot et al. 2002).

In the co-trimoxazole group, legal blindness was only 14% compared to 22.5% in controls. Patients on co-trimoxazole prophylaxis have already had scars at the macula before starting co-trimoxazole prophylaxis. An interesting finding in our study is that the proportion of patients with visual impairment (moderate and severe vision loss) at first visit reduced from 24.5 % to 19%, whereas those in the control group the proportion of patients with visual impairment remained unchanged at 40% at the start and end of follow-up. With regards to proportion of patients with visual impairment, there was a statistically significant difference between the co-trimoxazole and the control group at the end of follow-up (p -value=0.043).

4.24.3 Relapses

There was a higher rate of disease relapse in patients in the co-trimoxazole before starting the prophylaxis therapy compared the control group, and the difference in the mean number of disease relapses between the control and the co-trimoxazole group (before prophylaxis) was significant, 0.63 versus 2.1 relapses per year (p -value=0.022). Figure 4-21. Our study also shows that the patients in the co-

trimoxazole group were younger than controls and those are known to have more disease relapses and therefore are at higher risk of vision loss.

Before prophylactic treatment, all patients had disease relapse in at least one eye. However, after the introduction of co-trimoxazole, the rate of disease relapse reduced dramatically, from 2.1 to only 0.12 relapse/year (p -value < 0.001), Figure 4-22. There was a significant reduction in the average number of disease flare-ups/year after starting co-trimoxazole and the rate of disease relapse/year reduced by 17.5 times during prophylaxis compared with pre co-trimoxazole prophylaxis. The average flare-ups per year remained low throughout the entire follow-up, even when approximately two-third of patients have stopped their prophylaxis treatment.

In our analysis of relapse rate, no adjustments between the two eyes of the same patients were made, and this was based on the assumption that both eyes behave differently with regards to disease relapses. In patients with primary infection with *Toxoplasma gondii* species, the seeding into one or both retinæ is what will determine the initial ocular disease and future relapses. Although *Toxoplasma* is a systemic infection initially with very mild or no symptoms at all, clinically apparent relapses are confined to the eye in immunocompetent individuals, and these relapses usually arise from tissue cysts within the retina whether at or remote from a previous toxoplasmic scar. These relapses are mostly due to local factors (within the eye) such as tissue cyst stability, parasitic and immune environment. Therefore, there is no reason for us to assume that the reactivations of the two eyes are linked.

Only 4 out of 41 eyes (9.75%) developed a relapse of toxoplasmic retinochoroiditis during the prophylactic course and approximately 90% of eyes on co-trimoxazole prophylaxis did not have disease relapses. Similarly, in Silveira et al. study only four patients out of 61 patients (6.6%) had a disease flare during the co-trimoxazole prophylaxis (Silveira et al., 2002b).

Compared to previous studies on co-trimoxazole prophylaxis our results show a higher percentage of patients with disease recurrence in the control group (70%). The reported recurrence rates vary widely between different populations studied and the duration of follow-up. The recurrence rate reported being as high as 79% when patients were followed-up for more than five years (Bosch-Driessen, Berendschot et

al. 2002). Silveira et al. reported 23.8% disease flare-ups in the control group, while Felix and associates reported only 12.8% recurrence rate in the placebo group. The lower proportion of patients with disease flare-ups in these two studies is probably due to the shorter duration of follow-up, 20 months and 12 months in Silveira and Felix studies, respectively. In Felix et al. the three-year follow-up study, the relapse rate in the control group rose from only 13% at year one to 17.4% and 20.3% in the second and third-year follow-up, respectively. This finding supports the fact that with longer follow-up, a higher proportion of patients will develop disease relapse.

In our study the mean follow-up time for the control group was 5.24 ± 4.61 SD years, range from 1 to 20 years, IQR 2-7.5 years, median 3.98 years. This follow-up time exceeds the follow-up in the previous two studies which were 1 year and 1.6 years in Felix et al. and Silveira et al., respectively. Therefore, a longer follow-up, the strength of this study, showed that more patients would eventually develop disease relapse. Our results confirm that ocular toxoplasmosis is a recurrent disease and with longer follow-up, more patients will experience disease relapses. Our results also show that 75% of patients will have their subsequent disease relapse within 2.5 years from the date of the acute episode. However, the range was wide, and some patients developed a relapse in less than a month while others experienced the subsequent relapse after 6.6 years.

Holland et al. have found that the longer follow-up was associated with higher risk of disease recurrences (Holland, Crespi et al. 2008), adjusted relative risk 1.05 per 10 years increase in follow up, 95%CI 1.01-1.08; (p-value 0.007). The time to relapse depends on several factors, but with more follow-up time a higher proportion of patients will eventually develop disease flare.

Four patients (5 eyes) in our study had two or more course of prophylaxis. The main reason for restarting the prophylactic course with co-trimoxazole was due to the development of disease flare-ups after stopping the primary co-trimoxazole prophylaxis, when disease control was initially achieved. The prophylactic treatment was still valid and well tolerated in the second and third prophylactic courses.

4.24.4 Survival to first disease relapse

In regression analysis, our results showed a 70% relative risk reduction in disease recurrence in patients during co-trimoxazole prophylaxis compared to controls, a statistically significant difference, (p-value= 0.03), hazard ratio HR 0.30, (95%CI; 0.10-0.88). This finding represents an agreement with the first results published by Silveira and co-authors on co-trimoxazole prophylaxis (Silveira, Belfort et al. 2002) who reported a hazard ratio of 0.25 (95%CI 0.08-0.75) and 75% risk reduction in disease recurrences among patients on co-trimoxazole prophylaxis. The wide confidence interval reflects the small sample size presented in our study. However, the survival curves show an early and significant separation between the control and the co-trimoxazole group, where 9.75% had disease relapses in the co-trimoxazole group compared to 70% controls. Our results show that three patients out of four (75%), had their first relapse within the first year of starting the prophylaxis. Furthermore, mean relapse-free survival in the co-trimoxazole group was significantly longer than control group (5.89 versus 3.33 years). The median survival for controls was 2.40 years while for co-trimoxazole group that was not applicable since >90 of eyes had no flare on co-trimoxazole prophylaxis. However, the follow-up time on co-trimoxazole prophylaxis only was relatively short compared to the control group.

Felix and associates reported no disease flare on co-trimoxazole prophylaxis versus 12.80% (6 out of 47) in the placebo group, this could be due to the design of the study where all patients with active disease were treated with co-trimoxazole for 6.5 weeks before being assigned to prophylactic treatment. Also, they were followed-up for only 12 months. Therefore, the limited duration of follow-up might have influenced the recurrence rate in both groups. Another critical factor is the patient's compliance, in RCT and due to pill count, there is a high chance of better compliance in comparison to daily clinical practice. As a result, patients on prophylaxis therapy in Felix study did not have a recurrence compared to our study.

Felix et al. have published their three years follow-up data and claimed that the initial one-year co-trimoxazole prophylaxis has a two years protection (post prophylaxis effect). In their study, none of the patients who had 1-year course of co-trimoxazole prophylaxis developed disease flare-up within the subsequent 2-years after stopping the treatment (at the end of the study follow-up, relapses developed in 20.3% of the

control group versus 0% in the co-trimoxazole group). We have performed a second regression analysis to assess for the post-prophylaxis effect. Our Cox regression model assessed the hazard ratio (HR) between the two groups after stopping co-trimoxazole, in 26 eyes (20 patients). The results showed no significant difference in disease relapse between the two groups (p-value 0.18). Four out of 20 patients (20%) developed disease relapse after stopping co-trimoxazole, mean time to relapse is 1.34 ± 1.19 SD years, minimum 0.13-2.82 years. Patients can develop relapse three years after stopping the prophylactic course. Although the graph in Figure 4-25 shows a separation between the curves after one-year follow-up and this separation tend to get broader after two years follow-up, but it was not statistically significant. This contrasts the data reported by Felix group, where no disease relapse were reported after the prophylactic course, however, the follow-up was for only 2-years after stopping co-trimoxazole (Felix, Lira et al. 2016).

In line with this, Silveira followed-up patients, who had 20 months of co-trimoxazole or no treatment, for up to 10 years, there was a similar rate of disease relapse, 37% and 38% in patients previously treated with co-trimoxazole and control group, respectively, suggesting that treatment effect disappears after discontinuation of treatment. However, there was a 50% loss of the original study population at the end of follow-up.

The original theory proposed by Silveira on the mechanism of action of prophylactic co-trimoxazole states that co-trimoxazole destroys occasional parasites that escape tissue cyst and therefore helps the host immune system to re-establish disease control by forcing the parasite to go back to cyst stage before the inflammation is clinically apparent (relapse). Therefore, it is logical to speculate that when co-trimoxazole prophylaxis has stopped its effect disappears, and patients are no longer protected from disease relapse. This finding also supports the theory of ruptured tissue cysts as a direct cause of disease recurrences while the immune response and inflammation in this setting are secondary to rupture of tissue cyst and release of active tachyzoites and not the initial trigger as previously stated. Therefore, co-trimoxazole prophylaxis is only effective while patients are taking them and there are no long-term benefits once treatment had stopped.

Felix suggested that the further two years protection after cessation of treatment might be due to most viable cysts tending to erupt in the first months after initial infection. Nonetheless, several studies have shown that patients can still have a disease relapse many years after an acute episode of toxoplasmic retinochoroiditis and these are most likely due to reactivation of tissue cysts which can stay viable in the retina for many years after the initial infection.

Due to the relatively small sample size in our study, as only 20 patients have had their prophylactic co-trimoxazole stopped and the duration of prophylaxis varied between individuals, it is difficult to draw any firm conclusions on whether prophylactic co-trimoxazole had any protective effect when treatment was discontinued. Therefore, we undertook our final analysis on all patients on co-trimoxazole and followed-up till the first relapse regardless whether the prophylaxis had stopped or not. The incidence of recurrent disease among those treated with co-trimoxazole prophylaxis was much lower than those in the control group, results were significant (p -value= 0.009), HR 0.34. Therefore, there is a 66% reduction in the risk of first disease relapse when 62.5% of patients are no longer on prophylaxis treatment. The median time to first relapse for the co-trimoxazole group was not assessable as because the majority of patients (80%) did not have disease relapse, whereas for the control group the median time to relapse was 2.3 years. The mean survival time for the co-trimoxazole group is twice the survival time for the control group, 7.7 and 3.4 years for the co-trimoxazole and control groups, respectively. As a result, patients who had co-trimoxazole prophylaxis had more than double relapse-free time than those in the control group even when prophylaxis had stopped in almost two-thirds of patients.

Further, Felix study reported that new disease recurrences were significantly higher in women compared to men. Our data show that there is no significant difference between the proportion of males and females who developed disease recurrences (p -value = 0.55, Chi-square test).

4.24.5 Explanation of current findings

The transition from bradyzoites to tachyzoites and vice versa is a unique feature of toxoplasmosis which enables this parasite to propagate clonally in its intermediate hosts without the need for the definitive host. This feature is mediated via the ability of

the parasite to form tissue cysts within its host. Toxoplasmic tissue cyst does not only help the parasite being more transmissible and escaping digestive enzymes of the host but it also, helps the parasite establishing a state of chronic infection via protection from host immune responses. Tissue cyst rupture is responsible for the recurrent disease relapses in immunocompetent and immunosuppressed hosts. Most strains of toxoplasma produce tissue cysts, however, strains with low replication rate, which are less pathogenic in animals, usually form more tissue cysts compared to those more virulent and rapidly dividing (Dubey, Lindsay et al. 1998).

The cyst wall which contains the bradyzoites has a very limited perfusion and is only permeable to small molecules, 10 kiloDaltons (kDa), whereas the tachyzoites have a membrane which allows larger molecules to permeate through 1291 (kDa), which may explain the sensitivity of tachyzoites to anti-toxoplasmic antibiotics (Tu, Yakubu et al. 2017).

Classically, rupture of tissue cyst releases parasites which leads to disease reactivation and dissemination of tachyzoites which form new tissue cysts. However, research in vitro has also shown that some bradyzoites are capable of forming new tissue cysts directly without conversion into tachyzoites (WEISS, LAPLACE et al. 1995). The exact mechanism of new tissue cyst formation in latent infection is unknown. However, one theory was that bradyzoites emerge from tissue cyst by boring a hole and move to form new cyst without visible clinical manifestations (Van der Waaij 1959). Studies in animals have shown that toxoplasma gondii forms new tissue cysts even in chronic infection. Moreover, free tachyzoites were found present in the neuronal tissue of chronically infected, asymptomatic mice. Therefore, the question remains as to whether a relapse is caused by dormant tachyzoites or bradyzoites released from tissue cyst is yet to be answered (Dubey, Lindsay et al. 1998).

The viability of tissue cysts, on the other hand, depends on the duration of infection, host immune status and type of parasite. The number and size of tissue cysts are also dependent on these factors in addition to the route of inoculation, number and stage of parasites (infection with oocysts and bradyzoites leads to faster disease dissemination compared to tachyzoites, which usually get destroyed by gastric acid secretions in the host). Dubey et al. reported that tissue cysts in vivo studies have increased in number without clinical signs of disease reactivation and these cysts

usually occur in clusters. The larger number of tissue cysts led to increased mortality in mice studies (Dubey, Lindsay et al. 1998). This points out to the possibility of dissemination of toxoplasmosis in humans without apparent signs of disease reactivation. Furthermore, more significant numbers of tissue cysts might lead to more frequent and severe disease relapses in the retina (toxoplasmic retinochoroiditis) or the brain (toxoplasmic encephalitis) since the parasite is most frequently found in the brain and the retinal tissues. As a result co-trimoxazole prophylaxis limited disease dissemination within the retina and prevented disease recurrence.

A study by Nguyen and co-author, has shown was that co-trimoxazole and the combination of sulfadiazine/pyrimethamine have similar efficacy in rapidly eradicating the tachyzoites from the infected animal (Nguyen and Stadtsbaeder 1983). However, this experiment failed to show whether treatment with anti-toxoplasma antibiotics have a substantial effect on reducing the number of tissue cysts in the brain. However, this study was only for a short period.

The authors proposed three different possibilities to explain the lack of co-trimoxazole efficacy upon toxoplasma tissue cyst. The first was that co-trimoxazole which interferes with the folate metabolism pathway, which is essential for thymidine and purine synthesis, is only useful in rapidly dividing tachyzoites. Since bradyzoites have significantly lower metabolic activity compared to tachyzoites, the antimetabolite activity of co-trimoxazole is unlikely to affect these dormant bradyzoites. Nonetheless, cysts are not static structures, and recent research has shown that the parasites within tissue cyst replicate (Tu, Yakubu et al. 2017). Therefore, it is very tempting to assume that co-trimoxazole reduced the number of parasites within tissue cyst, therefore it prevented the subsequent enlargement and rupture of tissue cyst in normal condition (without treatment).

The second assumption was the presence of tissue cyst which acts as a barrier, protect the bradyzoites from being destroyed by co-trimoxazole. However, recent research has shown that tissue cyst is a highly specialised membrane which helps with the exchange of materials between the parasites and their external environment. The tissue cyst wall is a modified parasitophorous vacuole membrane containing vesicles and tubular structures, which possibly create a very well controlled communication and transport system between the parasite and its external

environment. (Tu, Yakubu et al. 2017). Therefore, co-trimoxazole may get diffused, even in a very trace amount, into the tissue cyst matrix and kill some of the parasites. Moreover, there is a high intracellular concentration of co-trimoxazole within the vicinity of tissue cyst prevented its growth and inhibited the dissemination of parasites.

Lastly, Nguyen and co-author reported that the location of these cysts in the brain makes the diffusion of co-trimoxazole difficult or perhaps drug concentrations fall below therapeutic levels. But, studies in HIV-patients with toxoplasmic encephalitis disagree with their assumption since disease relapse rate fall significantly in patients on co-trimoxazole compared to historical controls as previously mentioned.

Laboratory studies have shown that the bradyzoites within tissue cyst needed time to proliferate into tachyzoites, and at the intermediate stage of conversion the parasite exhibited markers for both bradyzoites and tachyzoites. However, after few cycles, the numbers of bradyzoites declined sharply and eventually disappeared, and the multiplication of tachyzoites became the dominant feature. It is possible that the interconversion to tachyzoites occurs in tissue cysts *in vivo* and this event preceded disease reactivation. The presence of tachyzoites with degenerated bradyzoites in mature tissue cysts confirms this finding (WEISS, LAPLACE et al. 1995). The process of transformation from bradyzoites to tachyzoites usually takes 48 hours whereas that from tachyzoites to bradyzoites usually takes 72 hours (in a laboratory setting and in the absence of any immune factors). The question as to whether the immune responses of the host are involved in the stage conversion remains open (Soete, Fortier et al. 1993).

Bradyzoites are known to have low metabolic activity, however, when the multiplication process starts, the metabolic demands increases, therefore co-trimoxazole becomes more effective as previously shown (Nguyen and Stadtsbaeder 1983). From the discussion above it seems plausible to speculate that co-trimoxazole suppresses parasitic multiplication within tissue cyst and at its vicinity before the full conversion into tachyzoites. Therefore, co-trimoxazole will subsequently lead to a reduction in the number of viable cysts and reduction in their size which helps to establish better disease control and prevent future disease relapse in toxoplasmosis.

Also, after the acute infection or recent disease relapse, with the progressive development of the parasite, the cyst wall became denser and well defined on electron microscopy (WEISS, LAPLACE et al. 1995). The immaturity of cyst wall at early stages of development may render newly formed tissue cysts at higher risk of eradication with anti-toxoplasmic antibiotics. Therefore, when co-trimoxazole was used early on after the acute episode of toxoplasmic retinochoroiditis, a maximum benefit was obtained. Patients placed on co-trimoxazole prophylaxis immediately after disease recurrence in Felix et al. study had enjoyed better disease control with zero relapses, even when drug was stopped, compared to those who started the prophylaxis later when the cysts became more mature and resistant to eradication by antibiotics such as, those patients in Silveira et al. study and our study.

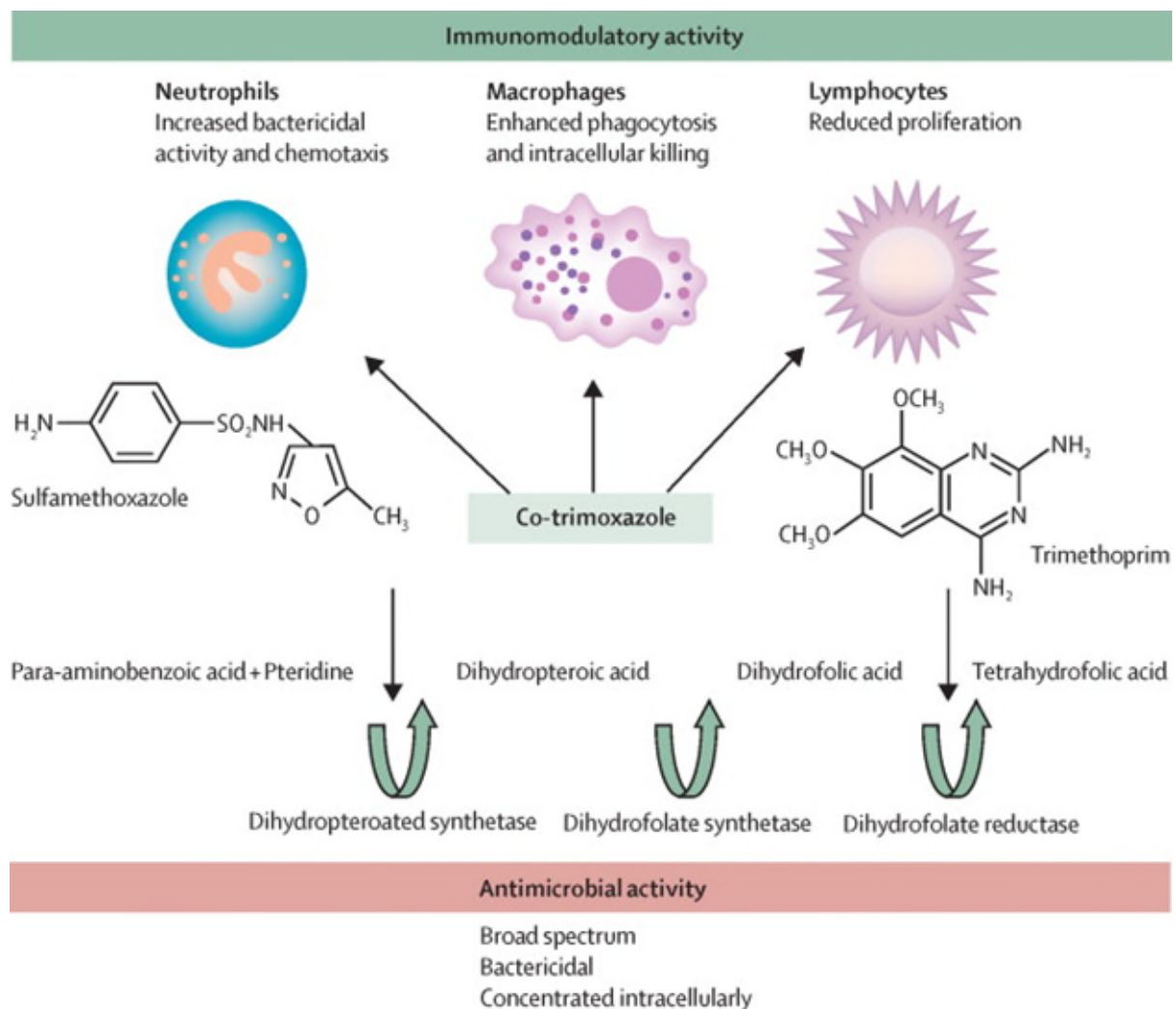
Another critical factor is the pharmacokinetics of co-trimoxazole. Dudley and co-authors have found that trimethoprim and sulfamethoxazole have excellent penetration into the CSF in uninflamed meninges (Dudley, Levitz et al. 1984). Trimethoprim achieves higher concentration intracellularly compared to plasma, whereas the concentrations of sulfamethoxazole are lower in tissues compared to plasma (Wormser, Keusch et al. 1982). Each agent alone is bacteriostatic, but when combined they are bactericidal as they block sequential steps in folic acid metabolism (Church, Fitzgerald et al. 2015).

With regards to the physiochemical properties of co-trimoxazole, the molecular weight is 543.9 g/mol with 4 hydrogen bond donor count and 13 hydrogen bond donor count and 38 heavy atom count (Open Chemistry data base). The chemical formula is C₂₄H₂₉N₇O₆S. The maximum plasma concentrations for sulfamethoxazole and trimethoprim are 53.1 and 1.48 µ/mL, respectively. Peak serum level is achieved after approximately 4 hours. Higher concentration of sulfamethoxazole in serum compared to trimethoprim is due to much higher trimethoprim concentration in tissues. The elimination half-lives of trimethoprim and sulfamethoxazole are 11 and 9 hours, respectively. However, these figures vary considerably between individuals (Patel and Welling 1980).

An exciting aspect of co-trimoxazole is its immunomodulatory effect beyond its antimicrobial action, and these may be responsible for some of its clinical benefits noticed in previous studies including our one. Trimethoprim has a pyrimidine ring

which is structurally similar to azathioprine (an immunosuppressive agent). A study by Ghilchik and associates showed that intramuscular injection of trimethoprim prolonged skin grafts transplanted from difference mice strains and the graft survival times were similar to that achieved with azathioprine (Ghilchik, Morris et al. 1970). The authors proposed that the immunosuppressive effect noticed could be probably due to the antifolate action which exerts the antimicrobial activity or it might be through inhibition of T cells. Others researchers have also confirmed this finding when cultured human T cells with co-trimoxazole. They have found that this drug inhibited the proliferation of T cells (Gaylarde and Sarkany 1972). Figure 4-26.

Figure 4-26 Immunomodulatory effect of co-trimoxazole (Church, Fitzgerald et al. 2015).



Moreover, studies in autoimmune diseases have shown that co-trimoxazole improved clinical function and reduced inflammation in patients with rheumatoid arthritis (Rozin, Schapira et al. 2001). Also, it has been used to prevent disease relapses of Wegener's granulomatosis (Stegeman, Tervaert et al. 1996). Lastly, there were reports that co-trimoxazole conversely enhances the innate immunity by increasing the bactericidal activity of neutrophils and enhances the phagocytosis and intracellular killing of macrophages (Church, Fitzgerald et al. 2015). In vitro, co-trimoxazole enhances the phagocytic ability of macrophages which improves the intracellular killing of pathogens such as *Toxoplasma gondii* (Carre, Forgue et al. 1990). Co-trimoxazole increased nitric oxide secretion in neutrophils and enhanced the bactericidal activity in patients treated with co-trimoxazole (Tsuji, Taniuchi et al. 2002). This effects may be attributed to the suppressive effect of trimethoprim on folate reductase enzyme in humans (Church, Fitzgerald et al. 2015). Therefore, co-trimoxazole may have also an additional immune enhancing action to destroy the parasites within the retina, particularly its positive effect on NO synthesis in macrophages.

Alternatively, the anti-inflammatory effect of co-trimoxazole may also help reduce with toxoplasmic retinochoroiditis disease relapses. As previously mentioned immune-mediated process to *Toxoplasma* or retinal S antigen may be responsible for the recurrent disease relapse in humans. Immune triggers to tissue cysts could perhaps open the door for the rupture of tissue cyst and subsequent fulminant inflammatory reaction.

Finally, systemic treatment with co-trimoxazole significantly inhibited the development of choroidal neovascular membrane in a mouse model. This inhibition was thought to be related to the anti-inflammatory effect of co-trimoxazole. Treatment with co-trimoxazole considerably reduced CNV associated inflammation. The researches hypothesised that a state of chronic inflammation at the RPE layer due to persistent infection contributes to the pathogenesis of the CNV (Yu Su et al. at ARVO conference 2018) (unpublished data). CNV in ocular toxoplasmosis is a well-known complication. Therefore, treatment with co-trimoxazole may help reduce the risk of this complication via the anti-inflammatory effect or inhibition of the infection which triggers chronic inflammation and CNV development.

In summary, co-trimoxazole achieves high intracellular concentration and therefore establishes a parasite-unfavourable environment within host cells cytoplasm where the tissue cyst resides. Since dividing bradyzoites will need folate pathway for DNA synthesis for the daughter cells, our theory is that co-trimoxazole affected the growth of tissue cysts by suppressing the division of bradyzoites with subsequent retardation of cyst growth and development. In other words, co-trimoxazole shifted the dynamics of parasitic differentiation in vivo by inhibiting bradyzoites overgrowth thus reducing the risk of tissue cyst rupture and subsequent disease relapse. Alternatively, the newly formed tissue cysts might be more susceptible to co-trimoxazole compared to old ones, which reduced the number of tissue cysts in the retina. Moreover, the effect of co-trimoxazole on free tachyzoites and bradyzoites within the retina of an asymptomatic individual is a very compelling theory. Therefore, co-trimoxazole prevented parasites from invading adjacent cells and forming new tissue cysts and subsequent disease relapse. Finally, co-trimoxazole may have also enhanced the intracellular killing of toxoplasmosis by macrophages or modulated the host immune response to toxoplasmic infected cells.

4.24.6 Safety and tolerability of Co-trimoxazole

Co-trimoxazole prophylaxis is generally safe treatment and well-tolerated by most patients. Our results show that few patients 3 (9%), discontinued medication due to side effects which were mild (in the form of skin rash and urticarial). Drug-related adverse events happened shortly after starting trimethoprim-sulfamethoxazole, mean time to stop co-trimoxazole was 0.18 ± 0.13 SD, range from 0.08-0.34 years (1 to 4 months). The rate of side effects of co-trimoxazole that led to early drug discontinuation in Silveira et al. study was (6.5%), and all patients had mild drug reactions which resolved when treatment was discontinued (Silveira, Belfort et al. 2002). Felix et al. reported a mild drug reaction in 3%, and none of the patients on co-trimoxazole stopped treatment due to the side effect. Other study reported 5% (3 out of 60 patients discontinuation rate for co-trimoxazole primary prophylaxis against cerebral toxoplasmosis because of nausea (Carr, Tindall et al. 1992).

Previous reports confirms these findings. The most common side effects of co-trimoxazole are skin eruption and mild gastrointestinal symptoms, each occurring in

around 3% of patients. Haematological disturbances such as leukopenia or agranulocytosis, thrombocytopenia, anaemia and eosinophilia occur in 0.5% of patients. Hepatitis, hepatic necrosis and intrahepatic cholestasis have been reported in few patients. Lower incidence of side effects are encountered when trimethoprim is used alone (Wormser, Keusch et al. 1982).

Co-trimoxazole was not only very useful, but it was also well tolerated by most patients, and none of them had a significant sided effect. More than half of patients stopped their co-trimoxazole prophylaxis due to disease control. Due to chronic treatment with co-trimoxazole, there is a potential for development of drug resistance. A report by Doliwa et al. highlighted the fact that there are several strains of naturally occurring *toxoplasma gondii* who developed resistant to sulphadiazine and the possible mechanism include gene mutations (Doliwa, Escotte-Binet et al. 2013). However, all the studies of co-trimoxazole prophylaxis including our study have shown that treatment was effective even with prolonged follow-up.

Finally, one additional benefit of co-trimoxazole treatment in this setting is that it could protect against toxoplasmosis in other sites such as the brain, cardiac and pulmonary particularly in immunocompromised individuals.

4.25 Limitations

Retrospective in nature, patients on co-trimoxazole prophylaxis, may not be representative of all patients with toxoplasmosis, since those patients were the ones with recurrent disease or a sight-threatening lesion, as those with retinochoroidal scars adjacent to the fovea at higher risk of profound vision loss that results from any reactivation. Finally, there was a considerable variation in durations of follow-up, and lack of uniform documentation.

4.26 Conclusion

In accordance with previously published reports, our data shows that co-trimoxazole prophylaxis was effective against recurrent ocular toxoplasmosis. A considerable benefit from prophylactic treatment was evident by a significant reduction in the number of disease relapses during prophylactic course. There are several possible theories. Firstly, co-trimoxazole neutralizes the occasional parasites that escape

tissue cyst and therefore prevents disease relapse and dissemination of parasite. Also, co-trimoxazole might reduce the rate of toxoplasma replication within the tissue cyst, therefore, prevents its expansion and subsequent rupture (disease relapse). Secondly, co-trimoxazole enhances the intracellular killing of toxoplasmosis within macrophages and upregulates NO production which helps with elimination of the parasite from the infected cells. Therefore, co-trimoxazole helps establish better disease control.

Once treatment stops there is evidence that some patients has long-lasting protection against disease relapse. However, it is difficult to draw any firm conclusions regarding post prophylactic protective effect due to small number of patients in our study. Also, other factors such as the age of tissue cysts, virulence of parasite, and immune status of the host which play a significant role in disease recurrences are difficult to assess.

By reducing disease relapses which would have a profound impact on vision, the prophylactic treatment used in this study was found to benefit the final BCVA. However, previous studies did not report a significant change in BCVA. In the current study the proportion of patients with sight impairment was significantly lower in patients in the co-trimoxazole group compared to the controls. Interestingly, patients with visual impairment due to macular location of the scar benefited from co-trimoxazole. There was significant improvement in vision on last visit follow-up on co-trimoxazole. Contrarily to previous reports, macular involvement was higher in this study which has a greater impact on final visual acuity. Our assumption is that prophylactic treatment might have controlled a state of chronic infection and secondary inflammation due to toxoplasma activity, and this allowed better tissue healing and improvement of vision. Nonetheless, because of the small sample size in the current study (which is not representative of all patients with ocular toxoplasmosis) a randomised placebo-controlled trial is warranted to test the impact of co-trimoxazole prophylaxis on visual acuity in a larger number of patients.

Co-trimoxazole prophylaxis was safe and well-tolerated by the majority of patients in our study, and it was equally effective in immunocompetent and immunocompromised subjects with no increased toxicity with time. However, due to the small sample size in the current study the safety of co-trimoxazole needs to be confirmed in a randomised controlled trial with a larger sample size.

This research has several implications in the management of patients with recurrent ocular toxoplasmosis. Firstly, co-trimoxazole should be widely used in patients with recurrent disease relapse even when the lesions are not sight-threatening, because disease recurrence can lead to repopulation of previously healthy retina with tissue cysts and disease dissemination. Secondly, patients with moderate degree of visual impairment would benefit from long-term prophylaxis to allow for better visual recovery during a relapse-free period. Finally, low dose, trimethoprim–sulfamethoxazole is very useful as secondary prophylaxis in eyes with a history of recurrent toxoplasmic retinochoroiditis and high risk of vision loss.

5 Chapter Five Discussion and summary of this research, conclusions and recommendations

Rare events such as, uveitis have proven challenging to explain and predict, a problem that seems to have at least two origins. First, is the complexities of the immune reactions that govern uveitis and these are yet to be fully understood. Second, is, the marked heterogeneity between different diseases and even individuals with the same disease. For example, the genetic makeup which controls both immune reactions and the subject's response to treatment can lead to a significant variation between subjects.

In uveitis, studies have always aimed at collecting a large number of observations to try to understand as many aspects of these diseases as possible. Data collection strategies in uveitis try to understand the disease course and its response to different treatments and are successful in this regard, for example, these record the patient's demographics, clinical manifestations of the disease, AC cellular activity, vitreous haze, central retinal thickness (CMO) and visual acuity. These bio scores are commonly used as surrogate measures for inflammation. Then reassess the same subjects after treatment to measure the effect of the intervention.

However, disease activity is different among different uveitis groups, and the commonly used methods to assess for inflammation are not always applicable to all forms of uveitis. For example, in conditions such as anterior uveitis, intermediate uveitis and idiopathic panuveitis, the cellular reaction is the hallmark of the disease process. However, there are other conditions such as, PIC, serpiginous choroiditis, where there is usually no anterior chamber or vitreous activity, and yet the underlying inflammatory drive produces scarring at the retina and promotes the growth of choroidal neovascular membranes, that take a toll on vision. The subclinical aspects of inflammation in these conditions remain undefined.

Nonetheless, despite this well-recognised heterogeneity in measuring disease activity in uveitis, some measures are commonly used to assess change in inflammatory status and are proven effective in leading the therapeutic adjustments in uveitis (Dick, Rosenbaum et al. 2018). These are: significant reduction in visual acuity, increased AC activity, increase in vitreous haze, new chorioretinal lesions, retinal vascular lesions and macular or optic nerve involvement.

Among all others, the visual acuity remains a very sensitive and essential parameter that reflects the status of ocular inflammation for several reasons. Firstly, persistent activity or repeated relapses can lead to a marked reduction in vision and even blindness in a significant proportion of patients with uveitis (Durrani, Tehrani et al. 2004). It is the recurrent episodes of uveitis that lead to visual impairment, due to the cumulative damage to the eye, rather than a single episode of inflammation. Secondly, some uveitic eyes may develop refractory CMO after a single severe episode of inflammation, while others such as Behcet's disease patients may have devastating consequences on vision within few days of the acute attack even when appropriate immunosuppression was timely instituted (Durrani, Tehrani et al. 2004). Moreover, there are some ocular conditions where the patient is visually symptomatic without apparent inflammatory activity because some of the parameters that reflect the disease activity are still not amenable to examination.

Most of the current methods used are solely deployed to detect the relapse of intraocular inflammation and measure its magnitude and treatment is directed to control the acute episode and is adjusted according to the disease severity. Disease course is mostly unpredictable, and there are no measures to predict relapse of uveitis or anticipate the response to immunomodulatory therapy. Therefore, it seems very plausible to use a therapeutic strategies prevent disease recurrence and preserve sight.

The risk of uveitis-related complications is less when inflammation is under control. Corticosteroids continue as the mainstay of treatment despite their predicted very-well known systemic side effects. Corticosteroids can be used either locally (periocular or intravitreal) or systemically. Local routes are associated with high risk of ocular side effects such as increased intraocular pressure, glaucoma and cataract. The MUST trials have demonstrated the superiority of systemic treatment over their local equivalents. Also, in patients with chronic sight-threatening uveitis, long-term systemic treatment had shown better outcomes in comparison to intermittent topical or systemic corticosteroids used only to manage disease relapse (Baughman, Lower et al. 2012). Different classes of immunomodulatory therapy help with inflammatory disease control and full therapeutic doses should be tried first before changing to or adding a different class IMT or even trying a biological agent.

Studies have shown that treatment with immunosuppressive drugs appears very effective in controlling the inflammation, thus preventing disease complications and loss of sight (Michel, Ekong et al. 2002). However, research in patients with JIA shows another exciting aspect of immunosuppressive therapy. Treatment with methotrexate for the joints disease reduced the incidence of uveitis by approximately 50% in JIA patients presenting with arthritis, the frequency of uveitis was 10.5% versus 20.1% in those treated and not treated with methotrexate, respectively (Papadopoulou, Kostik et al. 2013).

Similarly, azathioprine (in a placebo-controlled study) prevented the development of ocular inflammation in patients with systemic manifestations of Behcet's disease (Yazici, Pazarli et al. 1990). Furthermore, patients taking azathioprine have less frequent systemic relapses. Long-term follow-up on these patients showed that a significantly higher percentage of patients initially allocated to placebo became blind 40% compared to only 13% of patients in the azathioprine group. The beneficial effects of azathioprine were more pronounced when treatment was instituted shortly after eye involvement (Hamuryudan, Özyazgan et al. 1997).

Likewise, treatment with biologic agents has also prevented disease relapse in uveitis. Pooled data from seven studies (four placebo-controlled and three open-label trials) with TNF α blockers on 717 patients with ankylosing spondylitis (a disease frequently associated with acute anterior uveitis AAU) showed reduced incidence of AAU in those on anti-TNF α compared to placebo. The flare-ups of acute anterior uveitis were significantly less frequent in patients receiving infliximab or etanercept, than those on placebo agents, 15.6 per 100 patients/year in placebo versus 6.8 anterior uveitis flares per 100 patients/year in those on TNF α blockers (p-value = 0.01) (Braun, Baraliakos et al. 2005). Not surprisingly, infliximab achieved better disease control and less frequent relapses of anterior uveitis compared to etanercept 3.4 and 7.9 per patients per year, respectively.

Furthermore, adalimumab significantly reduced the rate of chronic anterior uveitis in patients with ankylosing spondylitis, a 45% reduction in chronic uveitis flare in 43 patients treated with adalimumab (p-value =0.002) (Rudwaleit, Rødevand et al. 2009). The same study also reported that adalimumab decreased the number of relapses of acute anterior uveitis in patients with ankylosing spondylitis by 51% during treatment

(p-value =0.001). Similarly, Van Denderen et al. reported 80% reduction in the rate of uveitis flares after treatment with adalimumab in 77 patient with AS. Also, there was a significant reduction in the median number of attacks in patients with recurrent flares reduced from 2.0 attacks per year before adalimumab to only 0.56 per year after treatment with adalimumab (p =0.0001) (van Denderen, Visman et al. 2014). Therefore, adalimumab, prescribed for systemic disease in ankylosing spondylitis (AS) and not for anterior uveitis, resulted in a reduction in the number flares of anterior uveitis in patients with AS.

Several international bodies that have published recommendations for the treatment of Spondyloarthropathies have suggested that adalimumab and infliximab are preferred biologic agents not only for treatment for other extra-articular manifestations of spondyloarthropathies but also effective at preventing uveitis in these patients in whom the risk of uveitis development approaches 60% (Dick, Rosenbaum et al. 2018). Therefore, the best approach for patients with uveitis would be prevention rather than treating the active inflammatory episodes.

Biologic response modifiers

Many patients with NIIPPU either do not respond, or they are intolerant to IMT therapies, or they relapse despite having these aggressive drugs (Diaz-Llopis, Garcia-Delpech et al. 2008). Hence there is always need for more efficacious and safer alternatives to control uveitis. The advances in research into pathophysiological mechanisms of autoimmune diseases have led to the development of new therapeutic options such as biologic response modifiers. These agents offer a more targeted therapy in autoimmune diseases, and the use of biologics in patients with non-infectious uveitis is on the rise, especially for those refractory to conventional immunosuppression.

Our results show better disease control on biologics and a significant corticosteroid reduction, and the effect was maintained up to 5 years follow-up. Corticosteroids sparing was achieved in 92% of patients by a median of three months, and patients with BD had lower mean corticosteroid dose compared to non-Behcet disease subjects. IMT was stopped or reduced in a significant proportion of patients on biologic treatment. Moreover, there was compelling evidence of a reduction in dose of second-

line immunosuppressive agents as much, on biologics. The reduction in the dose of immunosuppressive medications was accompanied by an initial improvement in BCVA and stability during the follow-up time.

Importantly, biologics achieved better disease control by significantly reducing the number of disease recurrences. Disease recurrences were reduced in both groups Behcet and non-Behcet. However, the effect of biologics was more pronounced in BD subjects compared to other uveitis etiologies. BD had a 75% reduction in risk of disease relapse on anti-TNF α drugs compared to non-Behcet disease patients, this would probably be due to the more central role of TNF α in the pathogenesis of BD.

As previously mentioned in BD patients TNF α might be the drive for disease relapse, and therefore treatment with TNF α blockers resulted in an impressive and highly significant reduction in the rate of disease relapse. On the grounds of these results, BD patients would have been better offered infliximab and adalimumab initially and even before instituting second-line agents. The concomitant use of immunosuppressive agents might have led to superior disease control with biologics in BD subjects. However, we could not confirm that since most patients in our study were taking biologics in addition to conventional immunosuppression.

Comparing different biologics, especially anti-TNF α agents, shows exciting results. As previously reported, etanercept has the worst outcome in uveitis control. Treatment failure on etanercept has occurred in all patients (100%). Therefore, this biologic should be avoided in patients with uveitis (please refer to page 151 for possible underlying mechanisms). Rituximab was effective in controlling uveitis and was associated with lower rate of disease relapse. With regards to the efficacy of infliximab and adalimumab, analysing the mean reduction in daily prednisolone dose at all follow-up points, time to reduction of prednisolone dose to less than 10 mg per day and time to first disease relapse in all patients did not show any significant difference. Therefore, it would be seen reasonable to speculate that these two biologics have similar efficacy in ocular inflammatory diseases.

Nonetheless, there were significantly lower rates of treatment failure on adalimumab compared to infliximab. The most common causes for treatment failure on infliximab were drug-related infusion reactions and allergy followed by an inadequate response to treatment. The differences in drug retention rates (treatment failures) between

infliximab and adalimumab could be attributed to the molecular structure of infliximab, where mouse protein is part of the antibody, and therefore there is a higher risk for an immune reaction. Adalimumab, on the other hand, is fully humanised and less immunogenic, and therefore it is more tolerated by patients. Patients switched from infliximab to adalimumab have shown an excellent response to treatment, and more than 70% of these patients continued treatment till their last follow-up or till drug was stopped owing to disease control. Finally, treatment with biologics was safe and well-tolerated. However due to small sample size further research is encouraged to prove the safety of biologics in patients with uveitis, and support their efficacy in different sight-threatening ocular inflammatory diseases.

Statins

The immunomodulatory effects of statins are well documented in many cell cultures and animal models. In humans, statin's immunomodulatory effect initially discovered in cardiovascular disease where statin use was associated with a significant decrease in CRP independent of cholesterol reduction. Then statins were tried in MS and dementia with promising results. We have undertaken the first project (as a proof of concept) in the field of ocular inflammation. This RCT, two-year follow-up, compared the effect of 80mg simvastatin versus placebo on the concomitant dose of immunosuppressive medications in patients with sight-threatening non-infectious intermediate, posterior and panuveitis.

At one-year follow-up (primary end-point), the mean prednisolone dose for simvastatin group was 3.62 mg higher compared to the placebo group, (p-value =0.54). There was no significant evidence of treatment effect. Similarly, in regression analysis adjusted for the baseline dose and disease duration there was no significant difference in mean prednisolone dose between the two groups. A wide confidence interval generated in these analyses could be attributed to disease heterogeneity.

Although most patients have achieved a prednisolone dose of <10 mg per day, early in treatment course, there was a trend toward less prednisolone dose in patients on simvastatin, but this effect was lost after nine months follow-up. Moreover, at one-year follow-up, the proportion of patients on <10 mg daily prednisolone rose from zero (at baseline) to 50% and 37% for the simvastatin and placebo group, respectively. At one-

year follow-up visit, the increased mean prednisolone was because two patients had their prednisolone increased to 70 mg which has skewed the mean dose for the whole group. Simvastatin might have a short-lived immunomodulatory effect and this effect was lost after several months. One of the possibilities is that the immune system has adopted compensatory mechanisms to overcome pathways affected by isoprenoids blockage. In accordance with this, short-term simvastatin therapy (8 days) achieved positive results on kidney function in patients with SLE (Abud-Mendoza, de la Fuente et al. 2003).

Secondary analysis at 104 weeks also showed no significant difference between the two groups in mean prednisolone dose (p-value =0.87). Likewise, the reduction in second-line immunosuppressive dose at two-year showed no significant difference (p= 0.56). Surprisingly, at 104 weeks the proportion of patients who had disease relapses was higher in the simvastatin group compared to placebo (45.5% versus 10%), p-value =0.072. Finally, simvastatin was safe and well-tolerated by many patients.

Statins attenuated the increased risk of major cardiovascular events in patients with elevated CRP (Walter, Fichtlscherer et al. 2001). While statins prevented the progression of atherosclerotic diseases (partly due to an immune-mediated action) it failed to show an effect in chronic ocular inflammatory disease. The question is why statins work in cardiovascular disease, but no evidence was demonstrated in the present study in non-infectious ocular inflammatory diseases? There are several possible theories. Firstly, the differences in the inflammatory processes at the vessel wall in atheroma-associated vascular disease and that of uveitis. It seems that the inflammation in cardiovascular disease is triggered by cholesterol deposition unlike the inflammatory eye diseases where unknown stimuli trigger a severe inflammatory reaction. Secondly, the lower grade of inflammation (detected by increased CRP levels) which predispose to recurrent coronary events is amenable to statin immunosuppression, whereas those with uveitis have inflammation at a much broader scale and more aggressive nature. The inflammatory cytokines that predominate the pathophysiological processes in an age-related chronic progressive vascular disease that commonly accompany atherosclerotic disease are substantially different from autoimmune diseases including uveitis. Therefore with these differences in the clinical presentation, statins would have a negligible action if any. Thirdly, in the Cholesterol

And Recurrent Events (CARE) study, it took two years to show the beneficial effects of statin, demonstrated by a significant reduction in cardiovascular events (Ridker, Rifai et al. 1998).

Therefore, statins seem to influence specifically the pathophysiological mechanisms involved in the acceleration of atherosclerotic disease (Walter, Fichtlscherer et al. 2001) but probably not in uveitis. Finally, the intensive lipid-lowering therapy with simvastatin 80 mg in our study led to a significant reduction in serum cholesterol and LDL; this offers protection from atherosclerotic diseases in uveitic patients where systemic corticosteroids and immunosuppressive agents are used at high doses and for an extended period.

In ocular toxoplasmosis (a disease featured by recurrent relapses which can recur in up to 80% of patients followed for 5-years), there was no improvement in visual prognosis over the past half-century (Bosch-Driessen, Berendschot et al. 2002). The current practice is to treat only the acute disease episode in which the eye has already suffered an inflammatory attack. The currently available antiparasitic drugs with or without corticosteroids only accelerate the resolution of an already active lesion. With disease recurrence, there is a higher risk of visual morbidity. Several factors can lead to loss of vision. Firstly, expansion of the lesion to involve sight sensitive structures such as the fovea and the optic nerve. Moreover, debris from inflammation accumulate in the vitreous and affect the vision if they involve the visual axis. Finally, with severe inflammation, there will be a higher risk of retinal detachment, cataract and glaucoma.

The current standard treatment has not altered the relapse rate and subsequently the prognosis in recurrent ocular toxoplasmosis. Conversely, our data show that with prophylactic co-trimoxazole aiming at preventing disease recurrence a significant improvement in visual acuity and disease relapse rate was achieved. Our five years follow-up data shows that recurrent toxoplasmosis occurs mainly in young people with a mean age at onset of 32 years, with nearly half of patients presenting with macular involvement, hence the higher risk of vision loss. There was a significantly lower proportion of patients with disease relapse on co-trimoxazole compared to control groups. Disease recurrences developed in just under 10% of patients on co-trimoxazole prophylaxis compared to 70% controls, with 35% of patients without

prophylaxis having more than one disease recurrence. It is important to mention that patients who started prophylaxis treatment had a higher (3.4 times more) disease recurrence rate per year compared to controls. The rate of disease recurrence of toxoplasmic retinochoroiditis had dropped significantly by almost 18 times on prophylaxis (p-value <0.001).

Interestingly the figures remained significant between the two groups even when 2/3 of patients stopped treatment. The visual acuity at baseline did not differ significantly between the co-trimoxazole and controls group. However, at three months follow-up the visual acuity was significantly better in co-trimoxazole treated patients compared to controls. Similarly, at last follow-up, the BCVA was significantly better in the prophylaxis group. Therefore, prevention of disease relapses in patients on co-trimoxazole prophylaxis translated to improvement in vision in comparison to control group. Most importantly the treatment was well tolerated by most patients for extended follow up times. Drug-related reactions reported in 9% of patients and were mild skin reaction and urticaria. However, due to small sample size and variable follow-up time in our study, further studies with large sample size are encouraged to confirm these results.

The question remains as to whether prophylactic treatment initiated immediately after controlling the acute episode when newly formed tissue cysts still have immature wall differs from those with a remote episode. Further studies are needed to explore this area. Moreover, exploring the effect of prophylactic treatment on the other manifestations of ocular toxoplasmosis such as acute anterior uveitis and vitritis which are thought to be related to tissue cyst rupture or autoimmunity is another interesting area of research. Also, other interesting aspect in this regards is studying other agents such as azithromycin which might offer patients with recurrent ocular toxoplasmosis an alternative option against recurrent disease and help preserve visual function. Moreover, the effect of the size and the number of the retinal lesions and recurrence rate during prophylaxis should be taken into account. Finally further research is encouraged to define the optimum duration of prophylaxis and whether long prophylaxis periods are more likely to eliminate the risk of future disease recurrence compared to shorter follow-ups.

To sum up, our data show that most patients with uveitis were young and had sight-threatening diseases which would have devastating consequences on their quality of life if was poorly managed. Ocular inflammation predisposes to injury and damage to the vision sensitive structures. This damage is mediated by frequent disease relapse or chronic disease course. Classically, the aim of treating ocular inflammation is to control the inflammation and achieve disease inactivity for a long-term. Based on our research findings, best management in uveitis would be preventing disease relapse, and therapeutic interventions specifically tailored to prevent disease recurrence (achieve long-term disease control) significantly improved treatment outcomes particularly stability of best corrected visual acuity. Also, targeted therapy seems more effective in controlling ocular inflammation and reducing the risk of complications which improves visual outcomes, therefore, further research to more understand the critical steps in pathophysiological mechanisms in different ocular inflammatory disease will be invaluable in guiding the best treatment approach for each disease entity.

Finally, Uveitis remains a challenging field and more to be discovered!

6 References

(1999). "TNF neutralization in MS: results of a randomized, placebo-controlled multicenter study. The Lenercept Multiple Sclerosis Study Group and The University of British Columbia MS/MRI Analysis Group." Neurology **53**(3): 457-465.

Abásolo, L., Z. Rosales, D. Díaz-Valle, A. Gómez-Gómez, R. C. Peña-Blanco, Á. Prieto-García, J. M. Benítez-del-Castillo, E. Pato, J. García-Feijoo and B. Fernández-Gutiérrez (2016). "Immunosuppressive drug discontinuation in noninfectious uveitis from real-life clinical practice: a survival analysis." American journal of ophthalmology **169**: 1-8.

Abbas, A. K., A. H. Lichtman and S. Pillai (2014). Basic immunology: functions and disorders of the immune system, Elsevier Health Sciences.

Abela-Formanek, C., M. Amon, J. Schauersberger, A. Kruger, J. Nepp and G. Schild (2002). "Results of hydrophilic acrylic, hydrophobic acrylic, and silicone intraocular lenses in uveitic eyes with cataract: Comparison to a control group1." Journal of Cataract & Refractive Surgery **28**(7): 1141-1152.

Absinta, M., G. Nair, P. Sati, I. C. Cortese, M. Filippi and D. S. Reich (2015). "Direct MRI detection of impending plaque development in multiple sclerosis." Neurol Neuroimmunol Neuroinflamm **2**(5): e145.

Abu El-Asrar, A. M., C. P. Herbort and K. F. Tabbara (2005). "Retinal vasculitis." Ocul Immunol Inflamm **13**(6): 415-433.

Abud-Mendoza, C., H. de la Fuente, E. Cuevas-Orta, L. Baranda, J. Cruz-Rizo and R. Gonzalez-Amaro (2003). "Therapy with statins in patients with refractory rheumatic diseases: a preliminary study." Lupus **12**(8): 607-611.

Accardo-Palumbo, A., G. Triolo, M. Carbone, A. Ferrante, F. Ciccia and E. Giardina (2000). "leukocyte myeloper-oxidase levels in patients with Behçet's." Clinical and experimental rheumatology **18**: 495-498.

Accorinti, M., M. P. Pirraglia, M. P. Paroli, R. Priori, F. Conti and P. Pivetti-Pezzi (2007). "Infliximab treatment for ocular and extraocular manifestations of Behcet's disease." Jpn J Ophthalmol **51**(3): 191-196.

Accorinti, M., M. P. Pirraglia, M. P. Paroli, R. Priori, F. Conti and P. Pivetti-Pezzi (2007). "Infliximab treatment for ocular and extraocular manifestations of Behcet's disease." Japanese journal of ophthalmology **51**(3): 191-196.

Adamson, P., H. F. Paterson and A. Hall (1992). "Intracellular-Localization of the P21(Rho) Proteins." Journal of Cell Biology **119**(3): 617-627.

Adu, D., J. Cross and D. R. Jayne (2001). "Treatment of systemic lupus erythematosus with mycophenolate mofetil." Lupus **10**(3): 203-208.

Aikawa, M., E. Rabkin, S. Sugiyama, S. J. Voglic, Y. Fukumoto, Y. Furukawa, M. Shiomi, F. J. Schoen and P. Libby (2001). "An HMG-CoA reductase inhibitor, cerivastatin, suppresses growth of macrophages expressing matrix metalloproteinases and tissue factor in vivo and in vitro." Circulation **103**(2): 276-283.

Ajzenberg, D., A. Banuls, C. Su, A. Dumetre, M. Demar, B. Carne and M. Dardé (2004). "Genetic diversity, clonality and sexuality in *Toxoplasma gondii*." International journal for parasitology **34**(10): 1185-1196.

- Akassoglou, K., L. Probert, G. Kontogeorgos and G. Kollias (1997). "Astrocyte-specific but not neuron-specific transmembrane TNF triggers inflammation and degeneration in the central nervous system of transgenic mice." J Immunol **158**(1): 438-445.
- Akova, Y. A., N. S. Jabbur and C. S. Foster (1993). "Ocular presentation of polyarteritis nodosa. Clinical course and management with steroid and cytotoxic therapy." Ophthalmology **100**(12): 1775-1781.
- Akpek, E. K., D. A. Jabs, H. H. Tessler, B. C. Joondeph and C. S. Foster (2002). "Successful treatment of serpiginous choroiditis with alkylating agents." Ophthalmology **109**(8): 1506-1513.
- Aktas, O., S. Waiczies, A. Smorodchenko, J. Dorr, B. Seeger, T. Prozorovski, S. Sallach, M. Endres, S. Brocke, R. Nitsch and F. Zipp (2003). "Treatment of relapsing paralysis in experimental encephalomyelitis by targeting Th1 cells through atorvastatin." J Exp Med **197**(6): 725-733.
- Al Rashidi, S., A. Al Fawaz, D. Kangave and A. M. Abu El-Asrar (2013). "Long-term clinical outcomes in patients with refractory uveitis associated with Behcet disease treated with infliximab." Ocul Immunol Inflamm **21**(6): 468-474.
- Al Rashidi, S., A. Al Fawaz, D. Kangave and A. M. Abu El-Asrar (2013). "Long-term clinical outcomes in patients with refractory uveitis associated with Behçet disease treated with infliximab." Ocular immunology and inflammation **21**(6): 468-474.
- Albert, D. M. and F. A. Jakobiec Principles and practice of ophthalmology : clinical practice.
- Albert, M. A., R. J. Glynn and P. M. Ridker (2003). "Plasma concentration of C-reactive protein and the calculated Framingham Coronary Heart Disease Risk Score." Circulation **108**(2): 161-165.
- Allison, A. C. (2005). "Mechanisms of action of mycophenolate mofetil." Lupus **14 Suppl 1**: s2-8.
- Allison, A. C., W. J. Kowalski, C. J. Muller, R. V. Waters and E. M. Eugui (1993). "Mycophenolic acid and brequinar, inhibitors of purine and pyrimidine synthesis, block the glycosylation of adhesion molecules." Transplant Proc **25**(3 Suppl 2): 67-70.
- American Academy of, O. (2017). Fundamentals and principles of ophthalmology.
- American Academy of, O. (2017). Intraocular inflammation and uveitis.
- Anderson, S. E. and J. S. Remington (1975). "The diagnosis of toxoplasmosis." Southern medical journal **68**(11): 1433-1443.
- Antcliff, R. J., M. R. Stanford, D. S. Chauhan, E. M. Graham, D. J. Spalton, J. S. Shilling, T. J. Ffytche and J. Marshall (2000). "Comparison between optical coherence tomography and fundus fluorescein angiography for the detection of cystoid macular edema in patients with uveitis." Ophthalmology **107**(3): 593-599.
- Arantes, T. E., C. Silveira, G. N. Holland, C. Muccioli, F. Yu, J. L. Jones, R. Goldhardt, K. G. Lewis and R. Belfort, Jr. (2015). "Ocular Involvement Following Postnatally Acquired Toxoplasma gondii Infection in Southern Brazil: A 28-Year Experience." Am J Ophthalmol **159**(6): 1002-1012.e1002.
- Araujo, F., J. Huskinson and J. Remington (1991). "Remarkable in vitro and in vivo activities of the hydroxynaphthoquinone 566C80 against tachyzoites and tissue cysts of Toxoplasma gondii." Antimicrobial agents and chemotherapy **35**(2): 293-299.
- Araujo, F., T. Slifer and S. Kim (1997). "Chronic infection with Toxoplasma gondii does not prevent acute disease or colonization of the brain with tissue cysts following reinfection with different strains of the parasite." The Journal of parasitology **83**(3): 521-522.
- Arnold, A. C., J. S. Pepose, R. S. Hepler and R. Y. Foos (1984). "Retinal periphlebitis and retinitis in multiple sclerosis. I. Pathologic characteristics." Ophthalmology **91**(3): 255-262.

- Atmaca, L. S. (1989). "Fundus changes associated with Behçet's disease." Graefe's archive for clinical and experimental ophthalmology **227**(4): 340-344.
- Atmaca, L. S., T. Simsek, P. Atmaca Sonmez and K. Sonmez (2006). "Fluorescein and indocyanine green angiography in ocular toxoplasmosis." Graefes Arch Clin Exp Ophthalmol **244**(12): 1688-1691.
- Au, A. and J. O'day (2004). "Review of severe vaso-occlusive retinopathy in systemic lupus erythematosus and the antiphospholipid syndrome: associations, visual outcomes, complications and treatment." Clinical & experimental ophthalmology **32**(1): 87-100.
- Awan, M. A., P. K. Agarwal, D. G. Watson, C. N. McGhee and G. N. Dutton (2009). "Penetration of topical and subconjunctival corticosteroids into human aqueous humour and its therapeutic significance." Br J Ophthalmol **93**(6): 708-713.
- Ayata, A., S. Dođru, M. G. Şenol, M. Ünal, D. Erşanlı and A. H. Bilge (2009). "Autofluorescence findings in Vogt-Koyanagi-Harada disease." European journal of ophthalmology **19**(6): 1094-1097.
- Baarsma, G. S. (1992). "The epidemiology and genetics of endogenous uveitis: a review." Curr Eye Res **11 Suppl**: 1-9.
- Baker, K. J. (1966). "Binding of sulfobromophthalein (BSP) sodium and indocyanine green (ICG) by plasma alpha-1 lipoproteins." Proc Soc Exp Biol Med **122**(4): 957-963.
- Balaskas, K., J. Vaudaux, N. Boillat-Blanco and Y. Guex-Crosier (2012). "Azithromycin versus Sulfadiazine and Pyrimethamine for non-vision-threatening toxoplasmic retinochoroiditis: a pilot study." Medical science monitor: international medical journal of experimental and clinical research **18**(5): CR296.
- Bamforth, S. D., S. L. Lightman and J. Greenwood (1997). "Interleukin-1 beta-induced disruption of the retinal vascular barrier of the central nervous system is mediated through leukocyte recruitment and histamine." The American journal of pathology **150**(1): 329.
- Bansal, R., A. Gupta and V. Gupta (2012). "Imaging in the diagnosis and management of serpiginous choroiditis." International ophthalmology clinics **52**(4): 229-236.
- Bartelds, G. M., C. L. Kriekaert, M. T. Nurmohamed, P. A. van Schouwenburg, W. F. Lems, J. W. Twisk, B. A. Dijkmans, L. Aarden and G. J. Wolbink (2011). "Development of antidrug antibodies against adalimumab and association with disease activity and treatment failure during long-term follow-up." Jama **305**(14): 1460-1468.
- Baughman, R. P., E. E. Lower, R. Ingledue and A. H. Kaufman (2012). "Management of ocular sarcoidosis." Sarcoidosis Vasc Diffuse Lung Dis **29**(1): 26-33.
- Baxter, S. L., M. Pistilli, S. S. Pujari, T. L. Liesegang, E. B. Suhler, J. E. Thorne, C. S. Foster, D. A. Jabs, G. A. Levy-Clarke, R. B. Nussenblatt, J. T. Rosenbaum and J. H. Kempen (2013). "Risk of choroidal neovascularization among the uveitides." Am J Ophthalmol **156**(3): 468-477.e462.
- Becker, M. and J. L. Davis (2008). Surgical management of inflammatory eye disease, Springer.
- Behrend, M. (2001). "Adverse gastrointestinal effects of mycophenolate mofetil: aetiology, incidence and management." Drug Saf **24**(9): 645-663.
- Bélaïr, M.-L., S. J. Kim, J. E. Thorne, J. P. Dunn, S. R. Kedhar, D. M. Brown and D. A. Jabs (2009). "Incidence of cystoid macular edema after cataract surgery in patients with and without uveitis using optical coherence tomography." American journal of ophthalmology **148**(1): 128-135. e122.
- Belardelli, F., M. Ferrantini, E. Proietti and J. M. Kirkwood (2002). "Interferon-alpha in tumor immunity and immunotherapy." Cytokine & growth factor reviews **13**(2): 119-134.
- Belardelli, F. and I. Gresser (1996). "The neglected role of type I interferon in the T-cell response: implications for its clinical use." Immunology today **17**(8): 369-372.

- Benezra, D. and E. Cohen (1986). "Treatment and visual prognosis in Behcet's disease." Br J Ophthalmol **70**(8): 589-592.
- BenEzra, D., E. Cohen, M. Rakotomalala, C. de Courten, W. Harris, T. Chajek, G. Friedman and N. Matamoros (1988). "Treatment of endogenous uveitis with cyclosporine A." Transplant Proc **20**(3 Suppl 4): 122-127.
- Bentley, C. R., M. R. Stanford, J. S. Shilling, M. D. Sanders and E. M. Graham (1993). "Macular ischaemia in posterior uveitis." Eye (Lond) **7 (Pt 3)**: 411-414.
- Bevilacqua, M. P., S. Stengelin, M. A. Gimbrone, Jr. and B. Seed (1989). "Endothelial leukocyte adhesion molecule 1: an inducible receptor for neutrophils related to complement regulatory proteins and lectins." Science **243**(4895): 1160-1165.
- Bhatt, N., W. Tucker, H. N. Sen and R. B. Nussenblatt (2016). "Biologic Therapies: Anti-Tumor Necrosis Factor-alpha, Anti-Interleukins, Rituximab and Others." Dev Ophthalmol **55**: 252-264.
- Bian, Z. M., S. G. Elner and V. M. Elner (2007). "Regulation of VEGF mRNA expression and protein secretion by TGF-beta2 in human retinal pigment epithelial cells." Exp Eye Res **84**(5): 812-822.
- Biester, S., C. Deuter, H. Michels, R. Haefner, J. Kuemmerle-Deschner, D. Doycheva and M. Zierhut (2007). "Adalimumab in the therapy of uveitis in childhood." Br J Ophthalmol **91**(3): 319-324.
- Bischoff, P. (1999). "[Macular edema: from symptom to diagnosis]." Klin Monbl Augenheilkd **214**(5): 311-316.
- Bloch-Michel, E. and R. B. Nussenblatt (1987). "International Uveitis Study Group recommendations for the evaluation of intraocular inflammatory disease." American journal of ophthalmology **103**(2): 234-235.
- Blumenkranz, M. S., J. D. Gass and J. G. Clarkson (1982). "Atypical serpiginous choroiditis." Arch Ophthalmol **100**(11): 1773-1775.
- Bohne, W., M. Holpert and U. Gross (1999). "Stage differentiation of the protozoan parasite *Toxoplasma gondii*." Immunobiology **201**(2): 248-254.
- Bonfioli, A. A., F. M. Damico, A. L. Curi and F. Orefice (2005). Intermediate uveitis. Seminars in ophthalmology, Taylor & Francis.
- Bonfioli, A. A. and F. Orefice (2005). "Sarcoidosis." Semin Ophthalmol **20**(3): 177-182.
- Bonfioli, A. A. and F. Orefice (2005). "Toxoplasmosis." Semin Ophthalmol **20**(3): 129-141.
- Borkar, D. S., V. M. Tham, E. Shen, J. V. Parker, A. Uchida, A. C. Vinoya and N. R. Acharya (2015). "Association between statin use and uveitis: results from the Pacific Ocular Inflammation study." Am J Ophthalmol **159**(4): 707-713.
- Bosch-Driessen, E. and A. Rothova (1999). "Recurrent ocular disease in postnatally acquired toxoplasmosis." American journal of ophthalmology **128**(4): 421-425.
- Bosch-Driessen, L. E., T. T. Berendschot, J. V. Ongkosuwito and A. Rothova (2002). "Ocular toxoplasmosis: clinical features and prognosis of 154 patients." Ophthalmology **109**(5): 869-878.
- Bosch-Driessen, L. H., S. Karimi, J. S. Stilma and A. Rothova (2000). "Retinal detachment in ocular toxoplasmosis." Ophthalmology **107**(1): 36-40.
- Bosch-Driessen, L. H., M. B. Plaisier, J. S. Stilma, A. Van der Lelij and A. Rothova (2002). "Reactivations of ocular toxoplasmosis after cataract extraction." Ophthalmology **109**(1): 41-45.
- Bosch-Driessen, L. H., F. D. Verbraak, M. S. Suttorp-Schulten, R. L. van Ruyven, A. M. Klok, C. B. Hoyng and A. Rothova (2002). "A prospective, randomized trial of pyrimethamine and azithromycin vs

pyrimethamine and sulfadiazine for the treatment of ocular toxoplasmosis." Am J Ophthalmol **134**(1): 34-40.

Bottazzo, G. F., R. Pujol-Borrell, T. Hanafusa and M. Feldmann (1983). "Role of aberrant HLA-DR expression and antigen presentation in induction of endocrine autoimmunity." Lancet **2**(8359): 1115-1119.

Boyd, S. R., S. Young and S. Lightman (2001). "Immunopathology of the noninfectious posterior and intermediate uveitides." Survey of Ophthalmology **46**(3): 209-233.

Braun, J., X. Baraliakos, J. Listing and J. Sieper (2005). "Decreased incidence of anterior uveitis in patients with ankylosing spondylitis treated with the anti-tumor necrosis factor agents infliximab and etanercept." Arthritis Rheum **52**(8): 2447-2451.

Braun, J. and J. Sieper (2007). "Ankylosing spondylitis." The Lancet **369**(9570): 1379-1390.

Breuer, H. (2005). "Low density lipoprotein cholesterol and coronary heart disease—lower is better." Eur Cardiol.

Brewerton, D., F. D. Hart, A. Nicholls, M. Caffrey, D. James and R. Sturrock (1973). "Ankylosing spondylitis and HL-A 27." The Lancet **301**(7809): 904-907.

Brown, J., J. C. Folk, C. V. Reddy and A. E. Kimura (1996). "Visual prognosis of multifocal choroiditis, punctate inner choroidopathy, and the diffuse subretinal fibrosis syndrome." Ophthalmology **103**(7): 1100-1105.

Brownlee, W. J., T. A. Hardy, F. Fazekas and D. H. Miller (2017). "Diagnosis of multiple sclerosis: progress and challenges." Lancet **389**(10076): 1336-1346.

Buggage, R. R., G. Levy-Clarke, H. N. Sen, R. Ursea, S. K. Srivastava, E. B. Suhler, C. Altemare, G. Velez, J. Ragheb and C.-C. Chan (2007). "A double-masked, randomized study to investigate the safety and efficacy of daclizumab to treat the ocular complications related to Behcet's disease." Ocular immunology and inflammation **15**(2): 63-70.

Busacca, A. (1957). "[Report on the biomicroscopy of the vitreous body & the eye fundus]." Bull Mem Soc Fr Ophtalmol **70**: 257-282; discussion 283-301.

Bykhovskaya, I., J. E. Thorne, J. H. Kempen, J. P. Dunn and D. A. Jabs (2005). "Vogt-Koyanagi-Harada disease: clinical outcomes." American journal of ophthalmology **140**(4): 674. e671-674. e676.

Cada, D. J., T. L. Levien and D. E. Baker (2009). "Golimumab." Hospital Pharmacy **44**(10): 894-907.

Calabrese, L. (2003). "Molecular differences in anticytokine therapies." Clinical and experimental rheumatology **21**(2): 241-248.

Callejas-Rubio, J. L., N. Ortego-Centeno, L. Lopez-Perez and M. N. Benticuaga (2006). "Treatment of therapy-resistant sarcoidosis with adalimumab." Clin Rheumatol **25**(4): 596-597.

Callejas-Rubio, J. L., D. Sánchez-Cano, J. L. G. Serrano and N. Ortego-Centeno (2008). "Adalimumab therapy for refractory uveitis: a pilot study." Journal of Ocular Pharmacology and Therapeutics **24**(6): 613-614.

Canete, J. D., J. L. Pablos, R. Sanmarti, C. Mallofre, S. Marsal, J. Maymo, J. Gratacos, J. Mezquita, C. Mezquita and M. C. Cid (2004). "Antiangiogenic effects of anti-tumor necrosis factor alpha therapy with infliximab in psoriatic arthritis." Arthritis Rheum **50**(5): 1636-1641.

Cantarini, L., R. Talarico, E. Generali, G. Emmi, G. Lopalco, L. Costa, E. Silvestri, F. Caso, R. Franceschini and R. Cimaz (2017). "Safety profile of biologic agents for Behçet's disease in a multicenter observational cohort study." International journal of rheumatic diseases **20**(1): 103-108.

- Carpenter, W. T., Jr. and P. H. Gruen (1982). "Cortisol's effects on human mental functioning." J Clin Psychopharmacol **2**(2): 91-101.
- Carr, A., B. Tindall, B. J. Brew, D. J. Marriott, J. L. Harkness, R. Penny and D. A. Cooper (1992). "Low-dose trimethoprim-sulfamethoxazole prophylaxis for toxoplasmic encephalitis in patients with AIDS." Annals of internal medicine **117**(2): 106-111.
- Carre, P., M. F. Forgue, B. Pipy, M. Beraud, M. H. Bessieres, A. Didier and P. Leophonte (1990). "[Effects of cotrimoxazole on some macrophage functions: microbicide, tumoricide, production of free oxygen radicals, prostaglandins and leukotrienes]." Pathol Biol (Paris) **38**(4): 289-293.
- Caspi, R. R. (2011). "Understanding autoimmune uveitis through animal models. The Friedenwald Lecture." Invest Ophthalmol Vis Sci **52**(3): 1872-1879.
- Caspi, R. R., F. G. Roberge and R. B. Nussenblatt (1987). "Organ-resident, nonlymphoid cells suppress proliferation of autoimmune T-helper lymphocytes." Science **237**(4818): 1029-1032.
- Cenci-Goga, B. T., P. V. Rossitto, P. Sechi, C. M. McCrindle and J. S. Cullor (2011). "Toxoplasma in animals, food, and humans: an old parasite of new concern." Foodborne Pathogens and Disease **8**(7): 751-762.
- Cha, H. S., E. K. Bae, J. H. Koh, J. Y. Chai, C. H. Jeon, K. S. Ahn, J. Kim and E. M. Koh (2007). "Tumor necrosis factor-alpha induces vascular endothelial growth factor-C expression in rheumatoid synoviocytes." J Rheumatol **34**(1): 16-19.
- Chajek, T. and M. Fainaru (1975). "Behcet's disease. Report of 41 cases and a review of the literature." Medicine (Baltimore) **54**(3): 179-196.
- Chakrabarti, R. and E. G. Engleman (1991). "Interrelationships between mevalonate metabolism and the mitogenic signaling pathway in T lymphocyte proliferation." J Biol Chem **266**(19): 12216-12222.
- Chan, C. C., B. Detrick, R. B. Nussenblatt, A. G. Palestine, L. S. Fujikawa and J. J. Hooks (1986). "HLA-DR antigens on retinal pigment epithelial cells from patients with uveitis." Arch Ophthalmol **104**(5): 725-729.
- Charteris, D. G., C. Champ, A. R. Rosenthal and S. L. Lightman (1992). "Behcet's disease: activated T lymphocytes in retinal perivasculitis." Br J Ophthalmol **76**(8): 499-501.
- Chataway, J., N. Schuerer, A. Alsanousi, D. Chan, D. MacManus, K. Hunter, V. Anderson, C. R. Bangham, S. Clegg, C. Nielsen, N. C. Fox, D. Wilkie, J. M. Nicholas, V. L. Calder, J. Greenwood, C. Frost and R. Nicholas (2014). "Effect of high-dose simvastatin on brain atrophy and disability in secondary progressive multiple sclerosis (MS-STAT): a randomised, placebo-controlled, phase 2 trial." Lancet **383**(9936): 2213-2221.
- Chee, S.-P., S.-E. Ti, M. Sivakumar and D. T. Tan (1999). "Postoperative inflammation: extracapsular cataract extraction versus phacoemulsification." Journal of Cataract & Refractive Surgery **25**(9): 1280-1285.
- Cheung, N., S.-P. Tan, S. Y. Lee, G. C. M. Cheung, G. Tan, N. Kumar, C.-Y. Cheng and T. Y. Wong (2016). "Prevalence and risk factors for epiretinal membrane: the Singapore Epidemiology of Eye Disease study." British Journal of Ophthalmology: bjophthalmol-2016-308563.
- Cho, S., G. Danovitch, M. Deierhoi, R. Ferguson, T. Gonwa, E. Hodge, C. Johnson, J. Miller, J. Neylan and D. Norman (1995). "Mycophenolate mofetil for the prevention of acute rejection in primary cadaveric renal allograft recipients." Transplantation **60**(3): 225-232.
- Choudhury, H., A. Jindal, A. Pathengay, A. Bawdekar, T. Albin and H. W. Flynn, Jr. (2015). "The role of intravitreal trimethoprim/sulfamethoxazole in the treatment of toxoplasma retinochoroiditis." Ophthalmic Surg Lasers Imaging Retina **46**(1): 137-140.

- Christmas, N. J., K. T. Oh, D. M. Oh and J. C. Folk (2002). "Long-term follow-up of patients with serpiginous choroiditis." Retina **22**(5): 550-556.
- Chung, C. H. (2008). "Managing premedications and the risk for reactions to infusional monoclonal antibody therapy." The oncologist **13**(6): 725-732.
- Church, J. A., F. Fitzgerald, A. S. Walker, D. M. Gibb and A. J. Prendergast (2015). "The expanding role of co-trimoxazole in developing countries." The Lancet Infectious Diseases **15**(3): 327-339.
- Clarkson, J. G., W. R. Green and D. Massof (1977). "A histopathologic review of 168 cases of preretinal membrane." American journal of ophthalmology **84**(1): 1-17.
- Cohen, B. A. (1999). Neurologic manifestations of toxoplasmosis in AIDS. Seminars in neurology, © 1999 by Thieme Medical Publishers, Inc.
- Colin, J. and J. Harie (1989). "Presumed toxoplasmic chorioretinitis: comparative study of treatment with pyrimethamine and sulfadiazine or clindamycin." Journal francais d'ophtalmologie **12**(3): 161-165.
- Commodaro, A. G., R. N. Belfort, L. V. Rizzo, C. Muccioli, C. Silveira, M. N. Burnier Jr and R. Belfort Jr (2009). "Ocular toxoplasmosis: an update and review of the literature." Mem Inst Oswaldo Cruz **104**(2): 345-350.
- Costello, K., J. Halper, R. Kalb, L. Skutnik and R. Rapp (2015). "The use of disease-modifying therapies in multiple sclerosis: principles and current evidence." A consensus paper by the multiple sclerosis coalition.
- Crane, I. J., C. A. Wallace, S. McKillop-Smith and J. V. Forrester (2000). "CXCR4 receptor expression on human retinal pigment epithelial cells from the blood-retina barrier leads to chemokine secretion and migration in response to stromal cell-derived factor 1 alpha." J Immunol **165**(8): 4372-4378.
- Crick, R. P., C. Hoyle and H. Smellie (1961). "The eyes in sarcoidosis." The British journal of ophthalmology **45**(7): 461.
- Crisby, M., G. Nordin-Fredriksson, P. K. Shah, J. Yano, J. Zhu and J. Nilsson (2001). "Pravastatin treatment increases collagen content and decreases lipid content, inflammation, metalloproteinases, and cell death in human carotid plaques: implications for plaque stabilization." Circulation **103**(7): 926-933.
- Cronstein, B. N. (1996). "Molecular therapeutics. Methotrexate and its mechanism of action." Arthritis Rheum **39**(12): 1951-1960.
- Cunningham, E. T. and M. Zierhut (2010). "TNF inhibitors for uveitis: balancing efficacy and safety." Ocul Immunol Inflamm **18**(6): 421-423.
- Cuthbert, J. A. and P. E. Lipsky (1991). "A product of mevalonate proximal to isoprenoids is the source of both a necessary growth factor and an inhibitor of cell proliferation." Trans Assoc Am Physicians **104**: 97-106.
- Cybulsky, M. I. and M. A. Gimbrone, Jr. (1991). "Endothelial expression of a mononuclear leukocyte adhesion molecule during atherogenesis." Science **251**(4995): 788-791.
- D'Angelo, S., P. Leccese, A. Padula, A. Nigro, M. Gilio, A. Carriero, C. Palazzi and I. Olivieri (2015). "FRI0254 predictive factors for the response to infliximab therapy in patients with Behçet's disease." Annals of the Rheumatic Diseases **74**: 516.
- Dammacco, R. (2017). "Systemic lupus erythematosus and ocular involvement: an overview." Clin Exp Med.
- Damsker, J. M., A. M. Hansen and R. R. Caspi (2010). "Th1 and Th17 cells: adversaries and collaborators." Ann N Y Acad Sci **1183**: 211-221.

- Dana, M.-R., J. Merayo-Lloves, D. A. Schaumberg and C. S. Foster (1996). "Prognosticators for visual outcome in sarcoid uveitis." Ophthalmology **103**(11): 1846-1853.
- Dandona, L., R. Dandona, R. K. John, C. A. McCarty and G. N. Rao (2000). "Population based assessment of uveitis in an urban population in southern India." Br J Ophthalmol **84**(7): 706-709.
- Daniel, E., M. Pistilli, S. S. Pujari, R. O. Kacmaz, R. B. Nussenblatt, J. T. Rosenbaum, E. B. Suhler, J. E. Thorne, C. S. Foster, D. A. Jabs, G. A. Levy-Clarke and J. H. Kempen (2012). "Risk of hypotony in noninfectious uveitis." Ophthalmology **119**(11): 2377-2385.
- Daniel, E., J. E. Thorne, C. W. Newcomb, S. S. Pujari, R. O. Kaçmaz, G. A. Levy-Clarke, R. B. Nussenblatt, J. T. Rosenbaum, E. B. Suhler and C. S. Foster (2010). "Mycophenolate mofetil for ocular inflammation." American journal of ophthalmology **149**(3): 423-432. e422.
- Darrell, R. W., H. P. Wagener and L. T. Kurland (1962). "Epidemiology of uveitis. Incidence and prevalence in a small urban community." Arch Ophthalmol **68**: 502-514.
- de Bustros, S., T. A. Rice, R. G. Michels, J. T. Thompson, S. Marcus and B. M. Glaser (1988). "Vitrectomy for macular pucker: use after treatment of retinal tears or retinal detachment." Archives of Ophthalmology **106**(6): 758-760.
- De Smet, M., F. Gunning and R. Feenstra (2005). "The surgical management of chronic hypotony due to uveitis." Eye **19**(1): 60.
- de Vries, H. S., M. G. van Oijen and D. J. de Jong (2008). "Serious events with infliximab in patients with inflammatory bowel disease." Drug safety **31**(12): 1135-1144.
- de Vries, M. K., G. J. Wolbink, S. O. Stapel, H. de Vrieze, J. C. Van Denderen, B. A. Dijkmans, L. A. Aarden and I. E. van der Horst-Bruinsma (2007). "Decreased clinical response to infliximab in ankylosing spondylitis is correlated with anti-infliximab formation." Annals of the rheumatic diseases **66**(9): 1252-1254.
- del Rincón, I., D. F. Battafarano, J. F. Restrepo, J. M. Erikson and A. Escalante (2014). "Glucocorticoid dose thresholds associated with all-cause and cardiovascular mortality in rheumatoid arthritis." Arthritis & rheumatology **66**(2): 264-272.
- Delair, E., D. Monnet, S. Grabar, J. Dupouy-Camet, H. Yera and A. P. Brézin (2008). "Respective roles of acquired and congenital infections in presumed ocular toxoplasmosis." American journal of ophthalmology **146**(6): 851-855.
- Delori, F. C., C. K. Dorey, G. Staurenghi, O. Arend, D. G. Goger and J. J. Weiter (1995). "In vivo fluorescence of the ocular fundus exhibits retinal pigment epithelium lipofuscin characteristics." Investigative ophthalmology & visual science **36**(3): 718-729.
- Delves, P. J., S. J. Martin, D. R. Burton and I. M. Roitt (2017). Essential immunology, John Wiley & Sons.
- Derijks, L. J. and D. W. Hommes (2006). "Thiopurines in inflammatory bowel disease: new strategies for optimization of pharmacotherapy?" Curr Gastroenterol Rep **8**(2): 89-92.
- Desmettre, T., P. Labalette, B. Fortier, S. Mordon and G. Constantinides (1996). "Laser photocoagulation around the foci of toxoplasma retinochoroiditis: a descriptive statistical analysis of 35 patients with long-term follow-up." Ophthalmologica **210**(2): 90-94.
- Detrick, B. and J. J. Hooks (2010). "Immune regulation in the retina." Immunologic research **47**(1-3): 153-161.
- Deubelbeiss, U., A. Gemperli, C. Schindler, F. Baty and M. H. Brutsche (2010). "Prevalence of sarcoidosis in Switzerland is associated with environmental factors." European Respiratory Journal **35**(5): 1088-1097.

- Dev, S., W. F. Mieler, J. S. Pulido and R. A. Mitra (1999). "Visual outcomes after pars plana vitrectomy for epiretinal membranes associated with pars planitis." Ophthalmology **106**(6): 1086-1090.
- Devine, L., S. Lightman and J. Greenwood (1996). "Role of LFA-1, ICAM-1, VLA-4 and VCAM-1 in lymphocyte migration across retinal pigment epithelial monolayers in vitro." Immunology **88**(3): 456-462.
- Dhingra, N., S. Kelly, M. A. Majid, C. B. Bailey and A. D. Dick (2010). "Inflammatory choroidal neovascular membrane in posterior uveitis-pathogenesis and treatment." Indian J Ophthalmol **58**(1): 3-10.
- Diaz-Llopis, M., S. Garcia-Delpech, D. Salom, P. Udaondo, M. Hernandez-Garfella, F. Bosch-Morell, A. Quijada and F. J. Romero (2008). "Adalimumab therapy for refractory uveitis: a pilot study." J Ocul Pharmacol Ther **24**(3): 351-361.
- Díaz-Llopis, M., D. Salom, C. Garcia-de-Vicuña, M. Cordero-Coma, G. Ortega, N. Ortego, M. Suarez-de-Figueroa, M. J. Rio-Pardo, C. Fernandez-Cid and A. Fonollosa (2012). "Treatment of refractory uveitis with adalimumab: a prospective multicenter study of 131 patients." Ophthalmology **119**(8): 1575-1581.
- Dick, A. D., J. V. Forrester, J. Liversidge and A. P. Cope (2004). "The role of tumour necrosis factor (TNF- α) in experimental autoimmune uveoretinitis (EAU)." Prog Retin Eye Res **23**(6): 617-637.
- Dick, A. D., J. V. Forrester, J. Liversidge and A. P. Cope (2004). "The role of tumour necrosis factor (TNF- α) in experimental autoimmune uveoretinitis (EAU)." Progress in Retinal and Eye Research **23**(6): 617-637.
- Dick, A. D., P. G. McMenamin, H. Korner, B. J. Scallon, J. Ghayeb, J. V. Forrester and J. D. Sedgwick (1996). "Inhibition of tumor necrosis factor activity minimizes target organ damage in experimental autoimmune uveoretinitis despite quantitatively normal activated T cell traffic to the retina." Eur J Immunol **26**(5): 1018-1025.
- Dick, A. D., J. T. Rosenbaum, H. A. Al-Dhibi, R. Belfort, A. P. Brézin, S. P. Chee, J. L. Davis, A. V. Ramanan, K.-H. Sonoda and E. Carreño (2018). "Guidance on Noncorticosteroid Systemic Immunomodulatory Therapy in Noninfectious Uveitis: Fundamentals Of Care for Uveitis (FOCUS) Initiative." Ophthalmology.
- Dick, A. D., N. Tundia, R. Sorg, C. Zhao, J. Chao, A. Joshi and M. Skup (2016). "Risk of ocular complications in patients with noninfectious intermediate uveitis, posterior uveitis, or panuveitis." Ophthalmology **123**(3): 655-662.
- Dobner, B. C., R. Max, M. D. Becker, C. Heinz, I. Veltrup, A. Heiligenhaus, T. Barisani-Asenbauer and F. Mackensen (2012). "A three-centre experience with adalimumab for the treatment of non-infectious uveitis." British Journal of Ophthalmology: bjophthalmol-2011-301401.
- Doctor, P. P., P. Bhat, R. Sayed and C. S. Foster (2009). "Intravitreal bevacizumab for uveitic choroidal neovascularization." Ocular immunology and inflammation **17**(2): 118-126.
- Doft, B. H. and D. M. Gass (1985). "Punctate outer retinal toxoplasmosis." Arch Ophthalmol **103**(9): 1332-1336.
- Doliwa, C., S. Escotte-Binet, D. Aubert, V. Sauvage, F. Velard, A. Schmid and I. Villena (2013). "Sulfadiazine resistance in *Toxoplasma gondii*: no involvement of overexpression or polymorphisms in genes of therapeutic targets and ABC transporters." Parasite **20**.
- Donaldson, M. J., J. S. Pulido, D. C. Herman, N. Diehl and D. Hodge (2007). "Pars planitis: a 20-year study of incidence, clinical features, and outcomes." American journal of ophthalmology **144**(6): 812-817. e812.

- Dreyer, R. F. and J. D. M. Gass (1984). "Multifocal choroiditis and panuveitis: a syndrome that mimics ocular histoplasmosis." Archives of ophthalmology **102**(12): 1776-1784.
- Dubey, J., D. Lindsay and C. Speer (1998). "Structures of *Toxoplasma gondii* tachyzoites, bradyzoites, and sporozoites and biology and development of tissue cysts." Clinical microbiology reviews **11**(2): 267-299.
- Dubey, J. P. (2014). The history and life cycle of *Toxoplasma gondii*. Toxoplasma Gondii (Second Edition), Elsevier: 1-17.
- Dudley, M. N., R. Levitz, R. Quintiliani, J. Hickingbotham and C. Nightingale (1984). "Pharmacokinetics of trimethoprim and sulfamethoxazole in serum and cerebrospinal fluid of adult patients with normal meninges." Antimicrobial agents and chemotherapy **26**(6): 811-814.
- Duker, J. S., G. C. Brown and L. Brooks (1987). "Retinal vasculitis in Crohn's disease." American journal of ophthalmology **103**(5): 664-668.
- Dunn, D., M. Wallon, F. Peyron, E. Petersen, C. Peckham and R. Gilbert (1999). "Mother-to-child transmission of toxoplasmosis: risk estimates for clinical counselling." The Lancet **353**(9167): 1829-1833.
- Dunn, S. E., S. Youssef, M. J. Goldstein, T. Prod'homme, M. S. Weber, S. S. Zamvil and L. Steinman (2006). "Isoprenoids determine Th1/Th2 fate in pathogenic T cells, providing a mechanism of modulation of autoimmunity by atorvastatin." J Exp Med **203**(2): 401-412.
- Durrani, K., G. N. Papaliodis and C. S. Foster (2004). "Pulse IV cyclophosphamide in ocular inflammatory disease: efficacy and short-term safety." Ophthalmology **111**(5): 960-965.
- Durrani, O., N. Tehrani, J. Marr, P. Moradi, P. Stavrou and P. Murray (2004). "Degree, duration, and causes of visual loss in uveitis." British Journal of Ophthalmology **88**(9): 1159-1162.
- Durrani, O. M., C. A. Meads and P. I. Murray (2004). "Uveitis: a potentially blinding disease." Ophthalmologica **218**(4): 223-236.
- Durrani, O. M., N. N. Tehrani, J. E. Marr, P. Moradi, P. Stavrou and P. I. Murray (2004). "Degree, duration, and causes of visual loss in uveitis." Br J Ophthalmol **88**(9): 1159-1162.
- Eckert, G. U., J. Melamed and B. Menegaz (2007). "Optic nerve changes in ocular toxoplasmosis." Eye (Lond) **21**(6): 746-751.
- Eigler, A., B. Sinha, G. Hartmann and S. Endres (1997). "Taming TNF: strategies to restrain this proinflammatory cytokine." Immunol Today **18**(10): 487-492.
- El-Asrar, A. M., C. P. Herbort and K. F. Tabbara (2010). "A clinical approach to the diagnosis of retinal vasculitis." Int Ophthalmol **30**(2): 149-173.
- Endo, A., M. Kuroda and Y. Tsujita (1976). "ML-236A, ML-236B, and ML-236C, new inhibitors of cholesterol synthesis produced by *Penicillium citrinum*." J Antibiot (Tokyo) **29**(12): 1346-1348.
- Engelhard, S. B., V. Patel and A. K. Reddy (2015). "Intermediate uveitis, posterior uveitis, and panuveitis in the Mid-Atlantic USA." Clinical ophthalmology (Auckland, NZ) **9**: 1549.
- Engell, T. and P. K. Andersen (1982). "The frequency of periphlebitis retinae in multiple sclerosis." Acta Neurol Scand **65**(6): 601-608.
- Engstrom Jr, R. E., G. N. Holland, R. B. Nussenblatt and D. A. Jabs (1991). "Current practices in the management of ocular toxoplasmosis." American journal of ophthalmology **111**(5): 601-610.
- Erckens, R., R. Mostard, P. Wijnen, J. Schouten and M. Drent (2012). "Adalimumab successful in sarcoidosis patients with refractory chronic non-infectious uveitis." Graefe's Archive for Clinical and Experimental Ophthalmology **250**(5): 713-720.

- Ericsson, J., M. Runquist, A. Thelin, M. Andersson, T. Chojnacki and G. Dallner (1993). "Distribution of prenyltransferases in rat tissues. Evidence for a cytosolic all-trans-geranylgeranyl diphosphate synthase." Journal of Biological Chemistry **268**(2): 832-838.
- Esatoglu, S. N., Z. Kutlubay, D. Ucar, I. Hatemi, U. Uygunoglu, A. Siva and G. Hatemi (2017). "Behcet's syndrome: providing integrated care." J Multidiscip Healthc **10**: 309-319.
- Essex, R. W., J. Wong, L. M. Jampol, J. Dowler and A. C. Bird (2013). Idiopathic multifocal choroiditis: a comment on present and past nomenclature, LWW.
- Esteve, E., W. Ricart and J. M. Fernandez-Real (2005). "Dyslipidemia and inflammation: an evolutionary conserved mechanism." Clinical nutrition **24**(1): 16-31.
- Estrach, C., S. Mpfu and R. Moots (2002). "Behcet's syndrome: response to infliximab after failure of etanercept." Rheumatology **41**(10): 1213-1214.
- Etienne, S., P. Adamson, J. Greenwood, A. D. Strosberg, S. Cazaubon and P. O. Couraud (1998). "ICAM-1 signaling pathways associated with Rho activation in microvascular brain endothelial cells." J Immunol **161**(10): 5755-5761.
- Everklioglu, C. (2005). "Current concepts in the etiology and treatment of Behçet disease." Survey of ophthalmology **50**(4): 297-350.
- Everklioglu, C., H. Er, Y. Türköz and M. Çekmen (2002). "Serum levels of TNF- α , sIL-2R, IL-6, and IL-8 are increased and associated with elevated lipid peroxidation in patients with Behçet's disease." Mediators of inflammation **11**(2): 87-93.
- Fabbroni, M., L. Cantarini, F. Caso, L. Costa, V. A. Pagano, B. Frediani, S. Manganelli and M. Galeazzi (2014). "Drug retention rates and treatment discontinuation among anti-TNF-alpha agents in psoriatic arthritis and ankylosing spondylitis in clinical practice." Mediators Inflamm **2014**: 862969.
- Fabiani, C., J. Sota, A. Vitale, G. Emmi, L. Vannozzi, D. Bacherini, G. Lopalco, S. Guerriero, V. Venerito and I. Orlando (2017). "Ten-Year Retention Rate of Infliximab in Patients with Behçet's Disease-Related Uveitis." Ocular immunology and inflammation: 1-6.
- Fabiani, C., J. Sota, A. Vitale, D. Rigante, G. Emmi, L. Vannozzi, D. Bacherini, G. Lopalco, S. Guerriero and S. Gentileschi (2018). "Cumulative retention rate of adalimumab in patients with Behçet's disease-related uveitis: a four-year follow-up study." British Journal of Ophthalmology **102**(5): 637-641.
- Fabiani, C., A. Vitale, G. Emmi, A. Bitossi, G. Lopalco, J. Sota, S. Guerriero, I. Orlando, M. Capozzoli, F. Fusco, F. Rana, F. Iannone, B. Frediani, M. Galeazzi, L. Vannozzi, G. M. Tosi and L. Cantarini (2018). "Long-term retention rates of adalimumab and infliximab in non-infectious intermediate, posterior, and panuveitis." Clin Rheumatol.
- Fabiani, C., A. Vitale, I. Orlando, M. Capozzoli, F. Fusco, F. Rana, R. Franceschini, J. Sota, B. Frediani and M. Galeazzi (2017). "Impact of Uveitis on Quality of Life: A Prospective Study from a Tertiary Referral Rheumatology-Ophthalmology Collaborative Uveitis Center in Italy." The Israel Medical Association journal: IMAJ **19**(8): 478-483.
- Fabiani, C., A. Vitale, D. Rigante, G. Emmi, A. Bitossi, G. Lopalco, J. Sota, S. Guerriero, I. Orlando and S. Gentileschi (2018). "Comparative efficacy between adalimumab and infliximab in the treatment of non-infectious intermediate uveitis, posterior uveitis, and panuveitis: a retrospective observational study of 107 patients." Clinical rheumatology: 1-9.
- FAJARDO, R. V., F. P. FURGIUELE and I. H. LEOPOLD (1962). "Treatment of toxoplasmosis uveitis." Archives of Ophthalmology **67**(6): 712-720.
- Farthing, C., M. Rendel, B. Currie and M. Seidlin (1992). "Azithromycin for cerebral toxoplasmosis." The Lancet **339**(8790): 437-438.

- Faucher, B., P. Garcia-Meric, J. Franck, P. Minodier, P. Francois, S. Gonnet, C. L'ollivier and R. Piarroux (2012). "Long-term ocular outcome in congenital toxoplasmosis: a prospective cohort of treated children." Journal of Infection **64**(1): 104-109.
- Fauci, A. S. (1978). "Mechanisms of the immunosuppressive and anti-inflammatory effects of glucocorticosteroids." J Immunopharmacol **1**(1): 1-25.
- Felix, J. P., R. P. Lira, R. S. Zacchia, J. M. Toribio, M. A. Nascimento and C. E. Arieta (2014). "Trimethoprim-sulfamethoxazole versus placebo to reduce the risk of recurrences of *Toxoplasma gondii* retinochoroiditis: randomized controlled clinical trial." Am J Ophthalmol **157**(4): 762-766.e761.
- Felix, J. P. F., R. P. C. Lira, A. B. Cosimo, R. L. C. da Costa, M. A. Nascimento and C. E. L. Arieta (2016). "Trimethoprim-Sulfamethoxazole versus placebo in reducing the risk of toxoplasmic retinochoroiditis recurrences: A three-year follow-up." American journal of ophthalmology **170**: 176-182.
- Ferguson, T. A., D. R. Green and T. S. Griffith (2002). "Cell death and immune privilege." Int Rev Immunol **21**(2-3): 153-172.
- Fernandes, L. and F. Orewfice (1996). "Clinical and epidemiological aspects of uveitis in reference services from Belo Horizonte, from 1970 to 1993." Part II. Rev Bras Oftal **55**: 19-32.
- Fernandez Fabrellas, E. (2007). "[Epidemiology of sarcoidosis]." Arch Bronconeumol **43**(2): 92-100.
- Fine, H. F., J. Baffi, G. F. Reed, K. G. Csaky and R. B. Nussenblatt (2001). "Aqueous humor and plasma vascular endothelial growth factor in uveitis-associated cystoid macular edema." American journal of ophthalmology **132**(5): 794-796.
- Fisher, R. (1981). "The lens in uveitis." Transactions of the ophthalmological societies of the United Kingdom **101**(3): 317-320.
- Foeldvari, I. and A. Wierk (2005). "Methotrexate is an effective treatment for chronic uveitis associated with juvenile idiopathic arthritis." J Rheumatol **32**(2): 362-365.
- Forooghian, F., N. Gulati and D. A. Jabs (2010). "Restoration of retinal architecture following systemic immunosuppression in birdshot chorioretinopathy." Ocular immunology and inflammation **18**(6): 470-471.
- Forrester, J. V. (2007). Intermediate and posterior uveitis. Immune Response and the Eye, Karger Publishers. **92**: 228-243.
- Foster, C. S., G. Alter, L. R. DeBarge, M. B. Raizman, J. L. Crabb, C. I. Santos, L. S. Feiler and M. H. Friedlaender (1996). "Efficacy and safety of rimexolone 1% ophthalmic suspension vs 1% prednisolone acetate in the treatment of uveitis." Am J Ophthalmol **122**(2): 171-182.
- Foster, C. S., S. Kothari, S. D. Anesi, A. T. Vitale, D. Chu, J. L. Metzinger and O. Ceron (2016). "The Ocular Immunology and Uveitis Foundation preferred practice patterns of uveitis management." Surv Ophthalmol **61**(1): 1-17.
- Foster, C. S. and S. Rashid (2003). "Management of coincident cataract and uveitis." Current opinion in ophthalmology **14**(1): 1-6.
- Foster, C. S., F. Tufail, N. K. Waheed, D. Chu, E. Miserocchi, S. Baltatzis and C. M. Vredeveld (2003). "Efficacy of etanercept in preventing relapse of uveitis controlled by methotrexate." Arch Ophthalmol **121**(4): 437-440.
- Foster, C. S. and A. T. Vitale (2002). Diagnosis and treatment of uveitis. Philadelphia, Pa. ; London, W.B. Saunders.
- Foster, C. S. and A. T. Vitale (2013). Diagnosis & Treatment of Uveitis, JP Medical Ltd.

- Foster, G. and N. Finter (1998). "Are all type I human interferons equivalent?" Journal of viral hepatitis **5**(3): 143-152.
- Foxman, E. F., M. Zhang, S. D. Hurst, T. Muchamuel, D. Shen, E. F. Wawrousek, C. C. Chan and I. Gery (2002). "Inflammatory mediators in uveitis: differential induction of cytokines and chemokines in Th1-versus Th2-mediated ocular inflammation." J Immunol **168**(5): 2483-2492.
- Friedman, A. H., M. H. Luntz and W. L. Henley (1982). Diagnosis and management of uveitis: an atlas approach, Williams & Wilkins.
- Friedman, D. S., J. T. Holbrook, H. Ansari, J. Alexander, A. Burke, S. B. Reed, J. Katz, J. E. Thorne, S. L. Lightman and J. H. Kempen (2013). "Risk of elevated intraocular pressure and glaucoma in patients with uveitis: results of the multicenter uveitis steroid treatment trial." Ophthalmology **120**(8): 1571-1579.
- Friedman, D. S., J. T. Holbrook, H. Ansari, J. Alexander, A. Burke, S. B. Reed, J. Katz, J. E. Thorne, S. L. Lightman and J. H. Kempen (2013). "Risk of elevated intraocular pressure and glaucoma in patients with uveitis: results of the multicenter uveitis steroid treatment trial." Ophthalmology **120**(8): 1571-1579.
- Friedmann, C. T. and D. L. Knox (1969). "Variations in recurrent active toxoplasmic retinochoroiditis." Arch Ophthalmol **81**(4): 481-493.
- Gagliuso, D. J., S. A. Teich, A. H. Friedman and J. Orellana (1990). "Ocular toxoplasmosis in AIDS patients." Trans Am Ophthalmol Soc **88**: 63-86; discussion 86-68.
- Galor, A., V. L. Perez, J. P. Hammel and C. Y. Lowder (2006). "Differential effectiveness of etanercept and infliximab in the treatment of ocular inflammation." Ophthalmology **113**(12): 2317-2323.
- Gandorfer, A., M. Rohleder and A. Kampik (2002). "Epiretinal pathology of vitreomacular traction syndrome." British Journal of Ophthalmology **86**(8): 902-909.
- Ganesh, S. K., K. Babu and J. Biswas (2004). "Cataract surgery in patients with Vogt-Koyanagi-Harada syndrome." Journal of Cataract & Refractive Surgery **30**(1): 95-100.
- Ganesh, S. K., K. Babu and J. Biswas (2004). "Phacoemulsification with intraocular lens implantation in cases of pars planitis." Journal of Cataract & Refractive Surgery **30**(10): 2072-2076.
- Gangaputra, S., C. W. Newcomb, T. L. Liesegang, R. O. Kacmaz, D. A. Jabs, G. A. Levy-Clarke, R. B. Nussenblatt, J. T. Rosenbaum, E. B. Suhler, J. E. Thorne, C. S. Foster and J. H. Kempen (2009). "Methotrexate for ocular inflammatory diseases." Ophthalmology **116**(11): 2188-2198.e2181.
- Garces, S., J. Demengeot and E. Benito-Garcia (2013). "The immunogenicity of anti-TNF therapy in immune-mediated inflammatory diseases: a systematic review of the literature with a meta-analysis." Ann Rheum Dis **72**(12): 1947-1955.
- Garweg, J. G. (2005). "Determinants of immunodiagnostic success in human ocular toxoplasmosis." Parasite Immunol **27**(3): 61-68.
- Garweg, J. G., J. N. Scherrer and M. Halberstadt (2008). "Recurrence characteristics in European patients with ocular toxoplasmosis." British journal of ophthalmology **92**(9): 1253-1256.
- Garweg, J. G., J. N. Scherrer and M. Halberstadt (2008). "Recurrence characteristics in European patients with ocular toxoplasmosis." Br J Ophthalmol **92**(9): 1253-1256.
- Gass, J. D. and C. L. Olson (1976). "Sarcoidosis with optic nerve and retinal involvement." Arch Ophthalmol **94**(6): 945-950.
- Gaudio, P. A., D. B. Kaye and J. B. Crawford (2002). "Histopathology of birdshot retinochoroidopathy." Br J Ophthalmol **86**(12): 1439-1441.

- Gaujoux-Viala, C., C. Giampietro, T. Gaujoux, H. K. Ea, C. Prati, P. Orcel, D. Wendling and F. Liote (2012). "Scleritis: a paradoxical effect of etanercept? Etanercept-associated inflammatory eye disease." J Rheumatol **39**(2): 233-239.
- Gaylarde, P. and I. Sarkany (1972). "Suppression of thymidine uptake of human lymphocytes by co-trimoxazole." Br Med J **3**(5819): 144-146.
- Gazzinelli, R., E. Y. Denkers and A. Sher (1993). "Host resistance to *Toxoplasma gondii*: model for studying the selective induction of cell-mediated immunity by intracellular parasites." Infectious agents and disease **2**(3): 139-149.
- Gegg, M. E., R. Harry, D. Hankey, H. Zambarakji, G. Pryce, D. Baker, P. Adamson, V. Calder and J. Greenwood (2005). "Suppression of autoimmune retinal disease by lovastatin does not require Th2 cytokine induction." J Immunol **174**(4): 2327-2335.
- Gerstenblith, A. T., J. E. Thorne, L. Sobrin, D. V. Do, S. M. Shah, C. S. Foster, D. A. Jabs and Q. D. Nguyen (2007). "Punctate inner choroidopathy: a survey analysis of 77 persons." Ophthalmology **114**(6): 1201-1204.
- Ghilchik, M. W., A. Morris and D. Reeves (1970). "Immunosuppressive powers of the antibacterial agent trimethoprim." Nature **227**(5256): 393-394.
- Giannopoulos, S., A. H. Katsanos, G. Tsvigoulis and R. S. Marshall (2012). "Statins and cerebral hemodynamics." Journal of Cerebral Blood Flow & Metabolism **32**(11): 1973-1976.
- Giansanti, F., M. Barbera, G. Virgili, B. Pieri, L. Emmi and U. Menchini (2004). *Infliximab for the treatment of posterior uveitis with retinal neovascularization in Behçet disease*, SAGE Publications Sage UK: London, England.
- Giganti, M., P. M. Beer, N. Lemanski, C. Hartman, J. Schartman and N. Falk (2010). "Adverse events after intravitreal infliximab (Remicade)." Retina **30**(1): 71-80.
- Gilbert, R. E., D. T. Dunn, S. Lightman, P. I. Murray, C. E. Pavesio, P. D. Gormley, J. Masters, S. P. Parker and M. R. Stanford (1999). "Incidence of symptomatic toxoplasma eye disease: aetiology and public health implications." Epidemiol Infect **123**(2): 283-289.
- Gilbert, R. E., K. Freeman, E. G. Lago, L. M. Bahia-Oliveira, H. K. Tan, M. Wallon, W. Buffolano, M. R. Stanford and E. Petersen (2008). "Ocular sequelae of congenital toxoplasmosis in Brazil compared with Europe." PLoS Negl Trop Dis **2**(8): e277.
- Giles, C. L., G. L. Mason, I. F. Duff and J. A. McLean (1962). "The association of cataract formation and systemic corticosteroid therapy." JAMA **182**(7): 719-722.
- Giovannini, A., G. Amato, C. Mariotti and B. Scassellati-Sforzolini (1999). "OCT imaging of choroidal neovascularisation and its role in the determination of patients' eligibility for surgery." British Journal of Ophthalmology **83**(4): 438-442.
- Glasner, P. D., C. Silveira, D. Kruszon-Moran, M. C. Martins, M. Burnier, S. Silveira, M. E. Camargo, R. B. Nussenblatt, R. A. Kaslow and R. Belfort (1992). "An unusually high prevalence of ocular toxoplasmosis in southern Brazil." American journal of ophthalmology **114**(2): 136-144.
- Goldberg, N. R., T. Lyu, E. Moshier, J. Godbold and D. A. Jabs (2014). "Success with single-agent immunosuppression for multifocal choroidopathies." Am J Ophthalmol **158**(6): 1310-1317.
- Goldstein, J. L. and M. S. Brown (1990). "Regulation of the mevalonate pathway." Nature **343**(6257): 425-430.
- Gonzalez, F., M. Coughtrie and R. Tukey (2006). *Goodman and Gilman's Pharmacological Basis of Therapeutics*. The McGraw-Hill Companies, Inc, New York: 71-92.

- Gordon, L. K., D. Monnet, G. N. Holland, A. P. Brézin, F. Yu and R. D. Levinson (2007). "Longitudinal cohort study of patients with birdshot chorioretinopathy. IV. Visual field results at baseline." American journal of ophthalmology **144**(6): 829-837. e821.
- Gordon, S. (2003). "Alternative activation of macrophages." Nat Rev Immunol **3**(1): 23-35.
- Graaf, M. R., D. J. Richel, C. J. van Noorden and H. J. Guchelaar (2004). "Effects of statins and farnesyltransferase inhibitors on the development and progression of cancer." Cancer Treat Rev **30**(7): 609-641.
- Gragoudas, E. S. and C. D. Regan (1981). "Peripapillary subretinal neovascularization in presumed sarcoidosis." Archives of Ophthalmology **99**(7): 1194-1197.
- Graham, E. M., D. A. Francis, M. D. Sanders and P. Rudge (1989). "Ocular inflammatory changes in established multiple sclerosis." J Neurol Neurosurg Psychiatry **52**(12): 1360-1363.
- Graham, E. M., D. J. Spalton, R. O. Barnard, A. Garner and R. W. Russell (1985). "Cerebral and retinal vascular changes in systemic lupus erythematosus." Ophthalmology **92**(3): 444-448.
- Graham, E. M., M. R. Stanford, M. D. Sanders, E. Kasp and D. C. Dumonde (1989). "A point prevalence study of 150 patients with idiopathic retinal vasculitis: 1. Diagnostic value of ophthalmological features." Br J Ophthalmol **73**(9): 714-721.
- Gran, J. T. and J. F. Skomsvoll (1997). "The outcome of ankylosing spondylitis: a study of 100 patients." Rheumatology **36**(7): 766-771.
- Green, W. R., K. R. Kenyon, R. G. Michels, H. D. Gilbert and Z. De La Cruz (1979). "Ultrastructure of epiretinal membranes causing macular pucker after retinal re-attachment surgery." Trans Ophthalmol Soc U K **99**(1): 65-77.
- Greenwood, A., M. Stanford and E. Graham (1998). "The role of azathioprine in the management of retinal vasculitis." Eye **12**(5): 783.
- Greenwood, J., R. Howes and S. Lightman (1994). "The blood-retinal barrier in experimental autoimmune uveoretinitis. Leukocyte interactions and functional damage." Laboratory investigation; a journal of technical methods and pathology **70**(1): 39-52.
- Greenwood, J. and J. C. Mason (2007). "Statins and the vascular endothelial inflammatory response." Trends in immunology **28**(2): 88-98.
- Greenwood, J., L. Steinman and S. S. Zamvil (2006). "Statin therapy and autoimmune disease: from protein prenylation to immunomodulation." Nat Rev Immunol **6**(5): 358-370.
- Greenwood, J., C. E. Walters, G. Pryce, N. Kanuga, E. Beraud, D. Baker and P. Adamson (2003). "Lovastatin inhibits brain endothelial cell Rho-mediated lymphocyte migration and attenuates experimental autoimmune encephalomyelitis." FASEB J **17**(8): 905-907.
- Greiner, J. V. and L. T. Chylack (1979). "Posterior subcapsular cataracts: histopathologic study of steroid-associated cataracts." Archives of Ophthalmology **97**(1): 135-144.
- Greiner, K., C. C. Murphy, F. Willermain, L. Duncan, J. Plskova, G. Hale, J. D. Isaacs, J. V. Forrester and A. D. Dick (2004). "Anti-TNF α therapy modulates the phenotype of peripheral blood CD4+ T cells in patients with posterior segment intraocular inflammation." Investigative ophthalmology & visual science **45**(1): 170-176.
- Grigg, M. E., J. P. Dubey and R. B. Nussenblatt (2015). "Ocular toxoplasmosis: lessons from Brazil." American journal of ophthalmology **159**(6): 999-1001.
- Gritz, D. C. and I. G. Wong (2004). "Incidence and prevalence of uveitis in Northern California: the Northern California epidemiology of uveitis study." Ophthalmology **111**(3): 491-500.

- Gritz, D. C. and I. G. Wong (2004). "Incidence and prevalence of uveitis in Northern California; the Northern California Epidemiology of Uveitis Study." Ophthalmology **111**(3): 491-500; discussion 500.
- Grossman, P. L. and J. S. Remington (1979). "The effect of trimethoprim and sulfamethoxazole on *Toxoplasma gondii* in vitro and in vivo." The American journal of tropical medicine and hygiene **28**(3): 445-455.
- Grossniklaus, H. E., P. H. Miskala, W. R. Green, S. B. Bressler, B. S. Hawkins, C. Toth, D. J. Wilson and N. M. Bressler (2005). "Histopathologic and ultrastructural features of surgically excised subfoveal choroidal neovascular lesions: submacular surgery trials report no. 7." Archives of ophthalmology (Chicago, Ill.: 1960) **123**(7): 914-921.
- Group, E. M. M. C. S. (1995). "Placebo-controlled study of mycophenolate mofetil combined with cyclosporin and corticosteroids for prevention of acute rejection." The Lancet **345**(8961): 1321-1325.
- Guerina, N. G., H.-W. Hsu, H. C. Meissner, J. H. Maguire, R. Lynfield, B. Stechenberg, I. Abrams, M. S. Pasternack, R. Hoff and R. B. Eaton (1994). "Neonatal serologic screening and early treatment for congenital *Toxoplasma gondii* infection." New England Journal of Medicine **330**(26): 1858-1863.
- Guex-Crosier, Y. and C. P. Herbort (1997). "Prolonged retinal arterio-venous circulation time by fluorescein but not by indocyanine green angiography in birdshot chorioretinopathy." Ocul Immunol Inflamm **5**(3): 203-206.
- Gulati, N., F. Forooghian, R. Lieberman and D. A. Jabs (2011). "Vascular endothelial growth factor inhibition in uveitis: a systematic review." Br J Ophthalmol **95**(2): 162-165.
- Gupta, V., A. Gupta, S. Arora, P. Bambery, M. R. Dogra and A. Agarwal (2003). "Presumed tubercular serpiginoislike choroiditis: clinical presentations and management." Ophthalmology **110**(9): 1744-1749.
- Haen, S. P. and R. F. Spaide (2008). "Fundus autofluorescence in multifocal choroiditis and panuveitis." American journal of ophthalmology **145**(5): 847-853.
- Haghjou, N., M. Soheilian and M. J. Abdekhodaie (2011). "Sustained release intraocular drug delivery devices for treatment of uveitis." J Ophthalmic Vis Res **6**(4): 317-329.
- Hall, A. (1998). "Rho GTPases and the actin cytoskeleton." Science **279**(5350): 509-514.
- Hamuryudan, V., Y. Özyazgan, N. Hizli, C. Mat, S. Yurdakul, Y. Tüzün, M. Şlenocak and H. Yazici (1997). "Azathioprine in Behçet's syndrome. Effects on long-term prognosis." Arthritis & Rheumatology **40**(4): 769-774.
- Hansel, T. T., H. Kropshofer, T. Singer, J. A. Mitchell and A. J. George (2010). "The safety and side effects of monoclonal antibodies." Nat Rev Drug Discov **9**(4): 325-338.
- Haraoui, B. and E. Keystone (2006). "Musculoskeletal manifestations and autoimmune diseases related to new biologic agents." Curr Opin Rheumatol **18**(1): 96-100.
- Harrell, M. and P. E. Carvounis (2014). "Current treatment of toxoplasma retinochoroiditis: an evidence-based review." Journal of ophthalmology **2014**.
- Hassan, M., A. Agarwal, R. Afridi, I. Karaca, M. A. Sadiq, Q. D. Nguyen and D. V. Do (2016). "The role of optical coherence tomography angiography in the Management of Uveitis." International ophthalmology clinics **56**(4): 1-24.
- Hassenstein, A. and C. H. Meyer (2009). "Clinical use and research applications of Heidelberg retinal angiography and spectral-domain optical coherence tomography—a review." Clinical & experimental ophthalmology **37**(1): 130-143.

- Hatemi, G., A. Silman, D. Bang, B. Bodaghi, A. Chamberlain, A. Gul, M. Houman, I. Kötter, I. Olivieri and C. Salvarani (2008). "EULAR recommendations for the management of Behçet disease." Annals of the rheumatic diseases **67**(12): 1656-1662.
- Haverkos, H. W. (1987). "Assessment of therapy for toxoplasma encephalitis: the TE study group." The American journal of medicine **82**(5): 907-914.
- Hayasaka, S., K. Kawamoto, S. Noda and T. Kodama (1994). "Visual prognosis in patients with Behcet's disease receiving colchicine, systemic corticosteroid or cyclosporin." Ophthalmologica **208**(4): 210-213.
- Haynes, B. F., M. L. Fishman, A. S. Fauci and S. M. Wolff (1977). "The ocular manifestations of Wegener's granulomatosis. Fifteen years experience and review of the literature." Am J Med **63**(1): 131-141.
- Heiligenhaus, A., S. Thureau, M. Hennig, R. S. Grajewski and G. Wildner (2010). "Anti-inflammatory treatment of uveitis with biologicals: new treatment options that reflect pathogenetic knowledge of the disease." Graefes Arch Clin Exp Ophthalmol **248**(11): 1531-1551.
- Henderly, D. E., A. J. Genstler, R. E. Smith and N. A. Rao (1987). "Changing patterns of uveitis." American journal of ophthalmology **103**(2): 131-136.
- Herbert, H. M., A. Viswanathan, H. Jackson and S. L. Lightman (2004). "Risk factors for elevated intraocular pressure in uveitis." Journal of glaucoma **13**(2): 96-99.
- Herbert, C. P., L. Cimino and A. M. Abu El Asrar (2005). "Ocular vasculitis: a multidisciplinary approach." Curr Opin Rheumatol **17**(1): 25-33.
- Heuer, D. K., W. E. Gager and F. H. Reeser (1982). "Ischemic optic neuropathy associated with Crohn's disease." Journal of clinical neuro-ophthalmology **2**(3): 175-181.
- Holder, G. E., A. G. Robson, C. Pavesio and E. M. Graham (2005). "Electrophysiological characterisation and monitoring in the management of birdshot chorioretinopathy." Br J Ophthalmol **89**(6): 709-718.
- Holland, G., G. O'Connor, R. Belfort, J. Remington and J. Pepose (1996). "Ocular infection and immunity." Mosby-Year Book, St. Louis: 1183-1223.
- Holland, G. N. (2003). "Ocular toxoplasmosis: a global reassessment. Part I: epidemiology and course of disease." Am J Ophthalmol **136**(6): 973-988.
- Holland, G. N. (2003). "Ocular toxoplasmosis: a global reassessment: Part I: epidemiology and course of disease." American journal of ophthalmology **136**(6): 973-988.
- Holland, G. N. (2004). "Ocular toxoplasmosis: a global reassessment. Part II: disease manifestations and management." Am J Ophthalmol **137**(1): 1-17.
- Holland, G. N. (2004). "Ocular toxoplasmosis: a global reassessment: part II: disease manifestations and management." American journal of ophthalmology **137**(1): 1-17.
- Holland, G. N., W. C. Buhles, B. Mastre and H. J. Kaplan (1989). "A controlled retrospective study of ganciclovir treatment for cytomegalovirus retinopathy: use of a standardized system for the assessment of disease outcome." Archives of Ophthalmology **107**(12): 1759-1766.
- Holland, G. N., C. M. Crespi, N. ten Dam-van Loon, A. C. Charonis, F. Yu, L. H. Bosch-Driessen and A. Rothova (2008). "Analysis of recurrence patterns associated with toxoplasmic retinochoroiditis." American journal of ophthalmology **145**(6): 1007-1013. e1001.
- Holland, G. N., C. M. Crespi, N. ten Dam-van Loon, A. C. Charonis, F. Yu, L. H. Bosch-Driessen and A. Rothova (2008). "Analysis of recurrence patterns associated with toxoplasmic retinochoroiditis." Am J Ophthalmol **145**(6): 1007-1013.

- Holland, G. N., R. E. Engstrom, B. J. Glasgow, B. B. Berger, S. A. Daniels, Y. Sidikaro, J. A. Harmon, D. H. Fischer, D. S. Boyer and N. A. Rao (1988). "Ocular toxoplasmosis in patients with the acquired immunodeficiency syndrome." American journal of ophthalmology **106**(6): 653-667.
- Holland, G. N. and K. G. Lewis (2002). "An update on current practices in the management of ocular toxoplasmosis1, 2." American journal of ophthalmology **134**(1): 102-114.
- Hooper, P. L. and H. J. Kaplan (1991). "Triple agent immunosuppression in serpiginous choroiditis." Ophthalmology **98**(6): 944-952.
- Hooper, P. L., N. A. Rao and R. E. Smith (1990). "Cataract extraction in uveitis patients." Survey of ophthalmology **35**(2): 120-144.
- Hopkins, S. (1991). "Clinical toleration and safety of azithromycin." The American journal of medicine **91**(3): S40-S45.
- Hsu, C. T., J. B. Kerrison, N. R. Miller and M. F. Goldberg (2001). "Choroidal infarction, anterior ischemic optic neuropathy, and central retinal artery occlusion from polyarteritis nodosa." Retina **21**(4): 348-351.
- Huang, D., E. A. Swanson, C. P. Lin, J. S. Schuman, W. G. Stinson, W. Chang, M. R. Hee, T. Flotte, K. Gregory, C. A. Puliafito and et al. (1991). "Optical coherence tomography." Science **254**(5035): 1178-1181.
- Hughes, E. and A. Dick (2003). "The pathology and pathogenesis of retinal vasculitis." Neuropathology and applied neurobiology **29**(4): 325-340.
- Hunter, D. and C. Foster (1999). "Systemic manifestations of sarcoidosis." Principles and Practice of Ophthalmology: Section XVII: 2.
- Huskinson-Mark, J., F. G. Araujo and J. S. Remington (1991). "Evaluation of the effect of drugs on the cyst form of *Toxoplasma gondii*." J Infect Dis **164**(1): 170-171.
- Huskinson-Mark, J., F. G. Araujo and J. S. Remington (1991). "Evaluation of the effect of drugs on the cyst form of *Toxoplasma gondii*." Journal of Infectious Diseases **164**(1): 170-177.
- Iida, T., R. F. Spaide and J. Kantor (2002). "Retinal and choroidal arterial occlusion in Wegener's granulomatosis." Am J Ophthalmol **133**(1): 151-152.
- Israelski, D. and J. Remington (1992). "AIDS-associated toxoplasmosis." The medical management of AIDS, 3rd ed. Philadelphia: WB Saunders: 319-345.
- Israelski, D., C. Tom and J. Remington (1989). "Zidovudine antagonizes the action of pyrimethamine in experimental infection with *Toxoplasma gondii*." Antimicrobial agents and chemotherapy **33**(1): 30-34.
- Istvan, E. S. and J. Deisenhofer (2001). "Structural mechanism for statin inhibition of HMG-CoA reductase." Science **292**(5519): 1160-1164.
- Jabs, D., R. Nussenblatt and J. Rosenbaum (2005). "Standardization of Uveitis Nomenclature (SUN) Working Group. Standardization of uveitis nomenclature for reporting clinical data. Results of the First International Workshop." Am J Ophthalmol **140**(3): 509-516.
- Jabs, D. A. (2017). "Immunosuppression for the Uveitides." Ophthalmology.
- Jabs, D. A. and C. J. Johns (1986). "Ocular involvement in chronic sarcoidosis." American journal of ophthalmology **102**(3): 297-301.
- Jabs, D. A., A. Mudun, J. P. Dunn and M. J. Marsh (2000). "Episcleritis and scleritis: clinical features and treatment results." Am J Ophthalmol **130**(4): 469-476.

- Jabs, D. A., R. B. Nussenblatt and J. T. Rosenbaum (2005). "Standardization of uveitis nomenclature for reporting clinical data. Results of the First International Workshop." *Am J Ophthalmol* **140**(3): 509-516.
- Jabs, D. A., J. T. Rosenbaum, C. S. Foster, G. N. Holland, G. J. Jaffe, J. S. Louie, R. B. Nussenblatt, E. R. Stiehm, H. Tessler, R. N. Van Gelder, S. M. Whitcup and D. Yocum (2000). "Guidelines for the use of immunosuppressive drugs in patients with ocular inflammatory disorders: recommendations of an expert panel." *Am J Ophthalmol* **130**(4): 492-513.
- Jaffe, G. J., A. D. Dick, A. P. Brézin, Q. D. Nguyen, J. E. Thorne, P. Kestelyn, T. Barisani-Asenbauer, P. Franco, A. Heiligenhaus and D. Scales (2016). "Adalimumab in patients with active noninfectious uveitis." *New England Journal of Medicine* **375**(10): 932-943.
- Jager, A. and V. K. Kuchroo (2010). "Effector and regulatory T-cell subsets in autoimmunity and tissue inflammation." *Scand J Immunol* **72**(3): 173-184.
- Jain, M. K. and P. M. Ridker (2005). "Anti-inflammatory effects of statins: clinical evidence and basic mechanisms." *Nat Rev Drug Discov* **4**(12): 977-987.
- Jain, R., P. Ferrante, G. T. Reddy and S. Lightman (2005). "Clinical features and visual outcome of intermediate uveitis in children." *Clinical & experimental ophthalmology* **33**(1): 22-25.
- Jakob, E., M. S. Reuland, F. Mackensen, N. Harsch, M. Fleckenstein, H. M. Lorenz, R. Max and M. D. Becker (2009). "Uveitis subtypes in a german interdisciplinary uveitis center--analysis of 1916 patients." *J Rheumatol* **36**(1): 127-136.
- Jameel, A., K. G. Ooi, N. R. Jeffs, G. Galatowicz, S. L. Lightman and V. L. Calder (2013). "Statin Modulation of Human T-Cell Proliferation, IL-1beta and IL-17 Production, and IFN-gamma T Cell Expression: Synergy with Conventional Immunosuppressive Agents." *Int J Inflamm* **2013**: 434586.
- Jarvisalo, M. J., J. O. Toikka, T. Vasankari, J. Mikkola, J. S. Viikari, J. J. Hartiala and O. T. Raitakari (1999). "HMG CoA reductase inhibitors are related to improved systemic endothelial function in coronary artery disease." *Atherosclerosis* **147**(2): 237-242.
- Jayne, D. R., G. Gaskin, C. D. Pusey and C. M. Lockwood (1995). "ANCA and predicting relapse in systemic vasculitis." *Qim* **88**(2): 127-133.
- Johnson-Anuna, L. N., G. P. Eckert, J. H. Keller, U. Igbavboa, C. Franke, T. Fechner, M. Schubert-Zsilavec, M. Karas, W. E. Muller and W. G. Wood (2005). "Chronic administration of statins alters multiple gene expression patterns in mouse cerebral cortex." *J Pharmacol Exp Ther* **312**(2): 786-793.
- Johnson, D. H. (1996). "Human trabecular meshwork cell survival is dependent on perfusion rate." *Invest Ophthalmol Vis Sci* **37**(6): 1204-1208.
- Johnston, A., J. E. Gudjonsson, H. Sigmundsdottir, B. R. Ludviksson and H. Valdimarsson (2005). "The anti-inflammatory action of methotrexate is not mediated by lymphocyte apoptosis, but by the suppression of activation and adhesion molecules." *Clin Immunol* **114**(2): 154-163.
- Jones, N. and N. P. Jones (2012). *Uveitis*, JP Medical Ltd.
- Kaburaki, T., F. Araki, M. Takamoto, K. Okinaga, A. Yoshida, J. Numaga, Y. Fujino and H. Kawashima (2010). "Best-corrected visual acuity and frequency of ocular attacks during the initial 10 years in patients with Behçet's disease." *Graefe's Archive for Clinical and Experimental Ophthalmology* **248**(5): 709-714.
- Kacmaz, R. O., J. H. Kempen, C. Newcomb, E. Daniel, S. Gangaputra, R. B. Nussenblatt, J. T. Rosenbaum, E. B. Suhler, J. E. Thorne, D. A. Jabs, G. A. Levy-Clarke and C. S. Foster (2010). "Cyclosporine for ocular inflammatory diseases." *Ophthalmology* **117**(3): 576-584.
- Kaçmaz, R. O., J. H. Kempen, C. Newcomb, S. Gangaputra, E. Daniel, G. A. Levy-Clarke, R. B. Nussenblatt, J. T. Rosenbaum, E. B. Suhler and J. E. Thorne (2008). "Ocular inflammation in Behçet

disease: incidence of ocular complications and of loss of visual acuity." American journal of ophthalmology **146**(6): 828-836.

Kamm, C. P., M. El-Koussy, S. Humpert, O. Findling, Y. Burren, G. Schwegler, F. Donati, M. Muller, F. Muller, J. Slotboom, L. Kappos, Y. Naegelin and H. P. Mattle (2014). "Atorvastatin added to interferon beta for relapsing multiple sclerosis: 12-month treatment extension of the randomized multicenter SWABIMS trial." PLoS One **9**(1): e86663.

Kampik, A., K. R. Kenyon, R. G. Michels, W. R. Green and Z. C. de la Cruz (2005). "Epiretinal and vitreous membranes: comparative study of 56 cases. 1981." Retina **25**(5 Suppl): 1445-1454.

Kanski, J. J. and B. Bowling (2011). Clinical ophthalmology: a systematic approach, Elsevier Health Sciences.

Kapur, R., A. D. Birnbaum, D. A. Goldstein, H. H. Tessler, M. J. Shapiro, L. J. Ulanski and M. P. Blair (2010). "Treating uveitis-associated hypotony with pars plana vitrectomy and silicone oil injection." Retina (Philadelphia, Pa.) **30**(1): 140.

Katznelson, S., A. H. Wilkinson, J. A. Kobashigawa, X. M. Wang, D. Chia, M. Ozawa, H. P. Zhong, M. Hirata, A. H. Cohen, P. I. Teraski and et al. (1996). "The effect of pravastatin on acute rejection after kidney transplantation--a pilot study." Transplantation **61**(10): 1469-1474.

Keane, J. (2005). "TNF-blocking agents and tuberculosis: new drugs illuminate an old topic." Rheumatology **44**(6): 714-720.

Kedhar, S. R., J. E. Thorne, S. Wittenberg, J. P. Dunn and D. A. Jabs (2007). "Multifocal choroiditis with panuveitis and punctate inner choroidopathy: comparison of clinical characteristics at presentation." Retina **27**(9): 1174-1179.

Kempen, J. H., M. M. Altaweel, L. T. Drye, J. T. Holbrook, D. A. Jabs, E. A. Sugar and J. E. Thorne (2015). "Benefits of Systemic Anti-inflammatory Therapy versus Fluocinolone Acetonide Intraocular Implant for Intermediate Uveitis, Posterior Uveitis, and Panuveitis: Fifty-four-Month Results of the Multicenter Uveitis Steroid Treatment (MUST) Trial and Follow-up Study." Ophthalmology **122**(10): 1967-1975.

Kempen, J. H., M. M. Altaweel, J. T. Holbrook, D. A. Jabs and E. A. Sugar (2010). "The multicenter uveitis steroid treatment trial: rationale, design, and baseline characteristics." Am J Ophthalmol **149**(4): 550-561.e510.

Kempen, J. H., M. M. Altaweel, J. T. Holbrook, E. A. Sugar, J. E. Thorne and D. A. Jabs (2017). "Association Between Long-Lasting Intravitreal Fluocinolone Acetonide Implant vs Systemic Anti-inflammatory Therapy and Visual Acuity at 7 Years Among Patients With Intermediate, Posterior, or Panuveitis." Jama **317**(19): 1993-2005.

Kempen, J. H., E. Daniel, J. P. Dunn, C. S. Foster, S. Gangaputra, A. Hanish, K. J. Helzlsouer, D. A. Jabs, R. O. Kaçmaz and G. A. Levy-Clarke (2009). "Overall and cancer related mortality among patients with ocular inflammation treated with immunosuppressive drugs: retrospective cohort study." Bmj **339**: b2480.

Kempen, J. H., S. Gangaputra, E. Daniel, G. A. Levy-Clarke, R. B. Nussenblatt, J. T. Rosenbaum, E. B. Suhler, J. E. Thorne, C. S. Foster and D. A. Jabs (2008). "Long-term risk of malignancy among patients treated with immunosuppressive agents for ocular inflammation: a critical assessment of the evidence." American journal of ophthalmology **146**(6): 802-812. e801.

Kempen, J. H., S. Gangaputra, E. Daniel, G. A. Levy-Clarke, R. B. Nussenblatt, J. T. Rosenbaum, E. B. Suhler, J. E. Thorne, C. S. Foster, D. A. Jabs and K. J. Helzlsouer (2008). "Long-term risk of malignancy among patients treated with immunosuppressive agents for ocular inflammation: a critical assessment of the evidence." Am J Ophthalmol **146**(6): 802-812.e801.

- Kempen, J. H., E. A. Sugar, G. J. Jaffe, N. R. Acharya, J. P. Dunn, S. G. Elner, S. L. Lightman, J. E. Thorne, A. T. Vitale and M. M. Altaweel (2013). "Fluorescein angiography versus optical coherence tomography for diagnosis of uveitic macular edema." Ophthalmology **120**(9): 1852-1859.
- Kenyon, K. R., J. E. Pederson, W. R. Green and A. E. Maumenee (1975). "Fibroglial proliferation in pars planitis." Trans Ophthalmol Soc U K **95**(3): 391-397.
- Keown, P., P. Häyry, P. Morris, C. Stiller, C. Barker, L. Carr, D. Landsberg, I. Hardie, R. Rigby and H. Isoniemi (1996). "A blinded, randomized clinical trial of mycophenolate mofetil for the prevention of acute rejection in cadaveric renal transplantation." Transplantation **61**(7): 1029-1037.
- Kerckhoff, F. T., Q. J. Lamberts, P. R. van den Biesen and A. Rothova (2003). "Rhegmatogenous retinal detachment and uveitis." Ophthalmology **110**(2): 427-431.
- Khan, A., C. Jordan, C. Muccioli, A. L. Vallochi, L. V. Rizzo, R. Belfort Jr, R. W. Vitor, C. Silveira and L. D. Sibley (2006). "Genetic divergence of *Toxoplasma gondii* strains associated with ocular toxoplasmosis, Brazil." Emerging infectious diseases **12**(6): 942.
- Khanamiri, H. N. and N. A. Rao (2013). "Serpiginous choroiditis and infectious multifocal serpiginoid choroiditis." Survey of ophthalmology **58**(3): 203-232.
- Kiernan, D. F., W. F. Mieler and S. M. Hariprasad (2010). "Spectral-domain optical coherence tomography: a comparison of modern high-resolution retinal imaging systems." Am J Ophthalmol **149**(1): 18-31.
- Kilmartin, D. J., J. V. Forrester and A. D. Dick (1998). "Rescue therapy with mycophenolate mofetil in refractory uveitis." Lancet **352**(9121): 35-36.
- Kim, S. J., A. J. Flach and L. M. Jampol (2010). "Nonsteroidal anti-inflammatory drugs in ophthalmology." Survey of ophthalmology **55**(2): 108-133.
- Kim, S. J., I. U. Scott, G. C. Brown, M. M. Brown, A. C. Ho, M. S. Ip and F. M. Recchia (2013). "Interventions for toxoplasma retinochoroiditis: a report by the American Academy of Ophthalmology." Ophthalmology **120**(2): 371-378.
- Kiss, C. G., T. Barisani-Asenbauer, S. Maca, S. Richter-Mueksch and W. Radner (2006). "Reading performance of patients with uveitis-associated cystoid macular edema." American journal of ophthalmology **142**(4): 620-624. e621.
- Kiss, S., M. Ahmed, E. Letko and C. S. Foster (2005). "Long-term follow-up of patients with birdshot retinochoroidopathy treated with corticosteroid-sparing systemic immunomodulatory therapy." Ophthalmology **112**(6): 1066-1071.
- Kitaichi, N., A. Miyazaki, D. Iwata, S. Ohno, M. R. Stanford and H. Chams (2007). "Ocular features of Behçet's disease: an international collaborative study." British Journal of Ophthalmology **91**(12): 1579-1582.
- Kittleson, M. M. and J. A. Kobashigawa (2013). "Statins in heart transplantation." Clin Transpl: 135-143.
- Kobashigawa, J. A. and B. L. Kasiske (1997). "Hyperlipidemia in solid organ transplantation." Transplantation **63**(3): 331-338.
- Kobashigawa, J. A., S. Katznelson, H. Laks, J. A. Johnson, L. Yeatman, X. M. Wang, D. Chia, P. I. Terasaki, A. Sabad, G. A. Cogert and et al. (1995). "Effect of pravastatin on outcomes after cardiac transplantation." N Engl J Med **333**(10): 621-627.
- Kockx, M. and L. Kritharides (2016). "Hyperlipidaemia in immunosuppression." Curr Opin Lipidol **27**(6): 631-632.

- Kodjikian, L., M. Wallon, J. Fleury, P. Denis, C. Binquet, F. Peyron and J. G. Garweg (2006). "Ocular manifestations in congenital toxoplasmosis." Graefe's archive for clinical and experimental ophthalmology **244**(1): 14-21.
- Kohno, H., T. Sakai, S. Saito, K. Okano and K. Kitahara (2007). "Treatment of experimental autoimmune uveoretinitis with atorvastatin and lovastatin." Exp Eye Res **84**(3): 569-576.
- Kok, H., C. Lau, N. Maycock, P. McCluskey and S. Lightman (2005). "Outcome of intravitreal triamcinolone in uveitis." Ophthalmology **112**(11): 1916. e1911-1916. e1917.
- Kollias, G. (2005). TNF pathophysiology in murine models of chronic inflammation and autoimmunity. Seminars in arthritis and rheumatism, Elsevier.
- Kollias, G., E. Douni, G. Kassiotis and D. Kontoyiannis (1999). "The function of tumour necrosis factor and receptors in models of multi-organ inflammation, rheumatoid arthritis, multiple sclerosis and inflammatory bowel disease." Ann Rheum Dis **58 Suppl 1**: I32-39.
- Kollias, G., E. Douni, G. Kassiotis and D. Kontoyiannis (1999). "On the role of tumor necrosis factor and receptors in models of multiorgan failure, rheumatoid arthritis, multiple sclerosis and inflammatory bowel disease." Immunological reviews **169**(1): 175-194.
- Koppe, J., D. Loewer-Sieger and H. de Roever-Bonnet (1986). "Results of 20-year follow-up of congenital toxoplasmosis." The Lancet **327**(8475): 254-256.
- Kotake, S., K. Higashi, K. Yoshikawa, Y. Sasamoto, T. Okamoto and H. Matsuda (1999). "Central nervous system symptoms in patients with Behçet disease receiving cyclosporine therapy." Ophthalmology **106**(3): 586-589.
- Kotsolis, A. I., F. A. Killian, I. D. Ladas and L. A. Yannuzzi (2010). "Fluorescein angiography and optical coherence tomography concordance for choroidal neovascularisation in multifocal choroiditis." Br J Ophthalmol **94**(11): 1506-1508.
- Kotsolis, A. I., F. A. Killian, I. D. Ladas and L. A. Yannuzzi (2010). "Fluorescein angiography and optical coherence tomography concordance for choroidal neovascularisation in multifocal choroiditis." British Journal of Ophthalmology: bjo. 2009.159913.
- Kötter, I., I. Günaydin, M. Zierhut and N. Stübiger (2004). The use of interferon α in Behçet disease: review of the literature. Seminars in arthritis and rheumatism, Elsevier.
- Kruh, J. N., P. Yang, A. M. Suelves and C. S. Foster (2014). "Infliximab for the treatment of refractory noninfectious Uveitis: a study of 88 patients with long-term follow-up." Ophthalmology **121**(1): 358-364.
- Kuiper, J. J., T. Mutis, W. de Jager, J. D. de Groot-Mijnes and A. Rothova (2011). "Intraocular interleukin-17 and proinflammatory cytokines in HLA-A29-associated birdshot chorioretinopathy." Am J Ophthalmol **152**(2): 177-182.e171.
- Kuipers, H. F., P. J. Biesta, T. A. Groothuis, J. J. Neefjes, A. M. Mommaas and P. J. van den Elsen (2005). "Statins affect cell-surface expression of major histocompatibility complex class II molecules by disrupting cholesterol-containing microdomains." Hum Immunol **66**(6): 653-665.
- Kump, L. I., S. N. Androudi and C. Foster (2005). "Ocular toxoplasmosis in pregnancy." Clinical & experimental ophthalmology **33**(5): 455-460.
- Kurz, P. A., E. B. Suhler, D. Choi and J. T. Rosenbaum (2009). "Rituximab for treatment of ocular inflammatory disease: a series of four cases." Br J Ophthalmol **93**(4): 546-548.
- Kwak, B., F. Mulhaupt, S. Myit and F. Mach (2000). "Statins as a newly recognized type of immunomodulator." Nat Med **6**(12): 1399-1402.

- La Mura, V., M. Pasarin, C. Z. Meireles, R. Miquel, A. Rodriguez-Vilarrupla, D. Hide, J. Gracia-Sancho, J. C. Garcia-Pagan, J. Bosch and J. G. Abraldes (2013). "Effects of simvastatin administration on rodents with lipopolysaccharide-induced liver microvascular dysfunction." Hepatology **57**(3): 1172-1181.
- Ladas, J. G., F. Yu, R. Loo, J. L. Davis, A. L. Coleman, R. D. Levinson and G. N. Holland (2001). "Relationship between aqueous humor protein level and outflow facility in patients with uveitis." Invest Ophthalmol Vis Sci **42**(11): 2584-2588.
- Lakhanpal, V., S. S. Schocket and V. S. Nirankari (1983). "Clindamycin in the treatment of toxoplasmic retinochoroiditis." Am J Ophthalmol **95**(5): 605-613.
- Lardenoye, C. W., B. van Kooij and A. Rothova (2006). "Impact of macular edema on visual acuity in uveitis." Ophthalmology **113**(8): 1446-1449.
- Larkin, G. and S. Lightman (1999). "Mycophenolate mofetil. A useful immunosuppressive in inflammatory eye disease." Ophthalmology **106**(2): 370-374.
- LaRosa, J. C., S. M. Grundy, D. D. Waters, C. Shear, P. Barter, J.-C. Fruchart, A. M. Gotto, H. Greten, J. J. Kastelein and J. Shepherd (2005). "Intensive lipid lowering with atorvastatin in patients with stable coronary disease." New England Journal of Medicine **352**(14): 1425-1435.
- Lassmann, H. (2014). "Mechanisms of white matter damage in multiple sclerosis." Glia **62**(11): 1816-1830.
- Lau, C. H., M. Comer and S. Lightman (2003). "Long-term efficacy of mycophenolate mofetil in the control of severe intraocular inflammation." Clin Exp Ophthalmol **31**(6): 487-491.
- Lauer, A. K., J. R. Smith, J. E. Robertson and J. T. Rosenbaum (2002). "Vitreous hemorrhage is a common complication of pediatric pars planitis." Ophthalmology **109**(1): 95-98.
- Leder, H. A., D. A. Jabs, A. Galor, J. P. Dunn and J. E. Thorne (2011). "Periocular triamcinolone acetonide injections for cystoid macular edema complicating noninfectious uveitis." American journal of ophthalmology **152**(3): 441-448. e442.
- Lee, D. K., E. B. Suhler, W. Augustin and R. R. Buggage (2003). "Serpiginous choroidopathy presenting as choroidal neovascularisation." Br J Ophthalmol **87**(9): 1184-1185.
- Lee, K., A. Bajwa, C. A. Freitas-Neto, J. L. Metzinger, B. A. Wentworth and C. S. Foster (2014). "A comprehensive review and update on the biologic treatment of adult noninfectious uveitis: part II." Expert Opin Biol Ther **14**(11): 1651-1666.
- Lee, K., A. Bajwa, C. A. Freitas-Neto, J. L. Metzinger, B. A. Wentworth and C. S. Foster (2014). "A comprehensive review and update on the non-biologic treatment of adult noninfectious uveitis: part I." Expert Opin Pharmacother **15**(15): 2141-2154.
- Leeper, N. J., R. Ardehali, E. M. deGoma and P. A. Heidenreich (2007). "Statin use in patients with extremely low low-density lipoprotein levels is associated with improved survival." Circulation **116**(6): 613-618.
- Leopold, I. H. and F. R. Maylath (1952). "Intraocular penetration of cortisone and its effectiveness against experimental corneal burns." Am J Ophthalmol **35**(8): 1125-1134.
- Lertsumitkul, S., S. M. Whitcup, R. B. Nussenblatt and C. C. Chan (1999). "Subretinal fibrosis and choroidal neovascularization in Vogt-Koyanagi-Harada syndrome." Graefes Arch Clin Exp Ophthalmol **237**(12): 1039-1045.
- Leung, T. G., A. Moradi, D. Liu, Q. D. Nguyen, J. P. Dunn, B. Burkholder, N. J. Butler, T. Ostheimer and J. E. Thorne (2014). "Clinical features and incidence rate of ocular complications in punctate inner choroidopathy." Retina **34**(8): 1666-1674.

- Levinson, R. D. (2005). Immunogenetics of ocular inflammatory disease. *Uveitis and Immunological Disorders*, Springer: 91-107.
- Levinson, R. D., A. Brezin, A. Rothova, M. Accorinti and G. N. Holland (2006). "Research criteria for the diagnosis of birdshot chorioretinopathy: results of an international consensus conference." *Am J Ophthalmol* **141**(1): 185-187.
- Levinson, R. D., D. Monnet, F. Yu, G. N. Holland, P. Gutierrez and A. P. Brezin (2009). "Longitudinal cohort study of patients with birdshot chorioretinopathy. V. Quality of life at baseline." *Am J Ophthalmol* **147**(2): 346-350.e342.
- Levy-Clarke, G., D. A. Jabs, R. W. Read, J. T. Rosenbaum, A. Vitale and R. N. Van Gelder (2014). "Expert panel recommendations for the use of anti-tumor necrosis factor biologic agents in patients with ocular inflammatory disorders." *Ophthalmology* **121**(3): 785-796. e783.
- Lewandowski, J., M. Sinski, J. Bidiuk, P. Abramczyk, A. Dobosiewicz, A. Ciarka and Z. Gaciong (2010). "Simvastatin reduces sympathetic activity in men with hypertension and hypercholesterolemia." *Hypertens Res* **33**(10): 1038-1043.
- Lewis, K. A., S. A. Holstein and R. J. Hohl (2005). "Lovastatin alters the isoprenoid biosynthetic pathway in acute myelogenous leukemia cells in vivo." *Leukemia research* **29**(5): 527-533.
- Lightman, S., W. I. McDonald, A. C. Bird, D. A. Francis, A. Hoskins, J. R. Batchelor and A. M. Halliday (1987). "Retinal venous sheathing in optic neuritis. Its significance for the pathogenesis of multiple sclerosis." *Brain* **110 (Pt 2)**: 405-414.
- Lightman, S., S. R. Taylor, C. Bunce, H. Longhurst, W. Lynn, R. Moots, M. Stanford, O. Tomkins-Netzer, D. Yang, V. L. Calder and D. O. Haskard (2015). "Pegylated interferon-alpha-2b reduces corticosteroid requirement in patients with Behcet's disease with upregulation of circulating regulatory T cells and reduction of Th17." *Ann Rheum Dis* **74**(6): 1138-1144.
- Lim, J. I. and R. W. Flower (1995). "Indocyanine green angiography." *Int Ophthalmol Clin* **35**(4): 59-70.
- Lim, L. L., F. W. Fraunfelder and J. T. Rosenbaum (2007). "Do tumor necrosis factor inhibitors cause uveitis? A registry-based study." *Arthritis Rheum* **56**(10): 3248-3252.
- Lin, F.-c. and H. A. Young (2014). "Interferons: success in anti-viral immunotherapy." *Cytokine & growth factor reviews* **25**(4): 369-376.
- Liversidge, J., H. Sewell and J. Forrester (1990). "Interactions between lymphocytes and cells of the blood-retina barrier: mechanisms of T lymphocyte adhesion to human retinal capillary endothelial cells and retinal pigment epithelial cells in vitro." *Immunology* **71**(3): 390.
- Lopez-Olivo, M. A., J. H. Tayar, J. A. Martinez-Lopez, E. N. Pollono, J. P. Cueto, M. R. Gonzales-Crespo, S. Fulton and M. E. Suarez-Almazor (2012). "Risk of malignancies in patients with rheumatoid arthritis treated with biologic therapy: a meta-analysis." *Jama* **308**(9): 898-908.
- Luscinskas, F. W., A. F. Brock, M. A. Arnaout and M. A. Gimbrone, Jr. (1989). "Endothelial-leukocyte adhesion molecule-1-dependent and leukocyte (CD11/CD18)-dependent mechanisms contribute to polymorphonuclear leukocyte adhesion to cytokine-activated human vascular endothelium." *J Immunol* **142**(7): 2257-2263.
- Lyons, R. E., R. McLeod and C. W. Roberts (2002). "Toxoplasma gondii tachyzoite-bradyzoite interconversion." *Trends in parasitology* **18**(5): 198-201.
- Machida, S., T. Fujiwara, K. Murai, M. Kubo and D. Kurosaka (2008). "Idiopathic choroidal neovascularization as an early manifestation of inflammatory chorioretinal diseases." *Retina* **28**(5): 703-710.

- Maggi, P., S. M. Macri, M. I. Gaitan, E. Leibovitch, J. E. Wholer, H. L. Knight, M. Ellis, T. Wu, A. C. Silva, L. Massacesi, S. Jacobson, S. Westmoreland and D. S. Reich (2014). "The formation of inflammatory demyelinated lesions in cerebral white matter." Ann Neurol **76**(4): 594-608.
- Maini, R. N., F. C. Breedveld, J. R. Kalden, J. S. Smolen, D. Davis, J. D. Macfarlane, C. Antoni, B. Leeb, M. J. Elliott, J. N. Woody, T. F. Schaible and M. Feldmann (1998). "Therapeutic efficacy of multiple intravenous infusions of anti-tumor necrosis factor alpha monoclonal antibody combined with low-dose weekly methotrexate in rheumatoid arthritis." Arthritis Rheum **41**(9): 1552-1563.
- Male, D., J. Rahman, G. Pryce, T. Tamatani and M. Miyasaka (1994). "Lymphocyte migration into the CNS modelled in vitro: roles of LFA-1, ICAM-1 and VLA-4." Immunology **81**(3): 366-372.
- Malinowski, S. M., J. S. Pulido and J. C. Folk (1993). "Long-term visual outcome and complications associated with pars planitis." Ophthalmology **100**(6): 818-825.
- Marak Jr, G. E., N. A. Rao, J. M. Scott, R. Duque and P. A. Ward (1985). "Antioxidant modulation of phacoanaphylactic endophthalmitis." Ophthalmic research **17**(5): 297-301.
- Margolis, R. and R. F. Spaide (2009). "A pilot study of enhanced depth imaging optical coherence tomography of the choroid in normal eyes." Am J Ophthalmol **147**(5): 811-815.
- Mariette, X., F. Tubach, H. Bagheri, M. Bardet, J. M. Berthelot, P. Gaudin, D. Heresbach, A. Martin, T. Schaevebeke, D. Salmon, M. Lemann, O. Hermine, M. Raphael and P. Ravaud (2010). "Lymphoma in patients treated with anti-TNF: results of the 3-year prospective French RATIO registry." Ann Rheum Dis **69**(2): 400-408.
- Markomichelakis, N. N., I. Halkiadakis, E. Pantelia, V. Peponis, A. Patelis, P. Theodossiadis and G. Theodossiadis (2004). "Patterns of macular edema in patients with uveitis: qualitative and quantitative assessment using optical coherence tomography." Ophthalmology **111**(5): 946-953.
- Markomichelakis, N. N., I. Halkiadakis, E. Pantelia, V. Peponis, A. Patelis, P. Theodossiadis and G. Theodossiadis (2004). "Patterns of macular edema in patients with uveitis: qualitative and quantitative assessment using optical coherence tomography." Ophthalmology **111**(5): 946-953.
- Markomichelakis, N. N., P. G. Theodossiadis, E. Pantelia, S. Papaefthimiou, G. P. Theodossiadis and P. P. Sfikakis (2004). "Infliximab for chronic cystoid macular edema associated with uveitis." American journal of ophthalmology **138**(4): 648-650.
- Martel, J. N., E. Esterberg, A. Nagpal and N. R. Acharya (2012). "Infliximab and adalimumab for uveitis." Ocular immunology and inflammation **20**(1): 18-26.
- Martín-Varillas, J. L., V. Calvo-Río, E. Beltrán, J. Sánchez-Bursón, M. Mesquida, A. Adán, M. V. Hernandez, M. H. Garfella, E. V. Pascual and L. Martínez-Costa (2018). "Successful Optimization of Adalimumab Therapy in Refractory Uveitis Due to Behçet's Disease." Ophthalmology **125**(9): 1444-1451.
- Maslo, C., S. Matheron, S. Fegueux, P. De Truchis, A. Saimot and J. Coulaud (1991). Assessment of maintenance therapy for brain toxoplasmosis. Int Conf AIDS.
- Matsumura, N. and Y. Mizushima (1975). "Leucocyte movement and colchicine treatment in Behcet's disease." Lancet **2**(7939): 813.
- May, T. S. and L. Barclay MD. Simvastatin Does Not Antagonize Interferon-Beta, Interim Analysis Suggests. 23rd Congress of the European Committee for the Treatment and Research in Multiple Sclerosis: Parallel Session.
- McCannel, C. A., G. N. Holland, C. J. Helm, P. J. Cornell, J. V. Winston and T. G. Rimmer (1996). "Causes of uveitis in the general practice of ophthalmology. UCLA Community-Based Uveitis Study Group." Am J Ophthalmol **121**(1): 35-46.

- McCarey, D. W., I. B. McInnes, R. Madhok, R. Hampson, O. Scherbakov, I. Ford, H. A. Capell and N. Sattar (2004). "Trial of Atorvastatin in Rheumatoid Arthritis (TARA): double-blind, randomised placebo-controlled trial." Lancet **363**(9426): 2015-2021.
- McColgin, A. Z. and J. S. Heier (2000). "Control of intraocular inflammation associated with cataract surgery." Current opinion in ophthalmology **11**(1): 3-6.
- McLeod, R., K. Boyer, T. Karrison, K. Kasza, C. Swisher, N. Roizen, J. Jalbrzikowski, J. Remington, P. Heydemann and A. G. Noble (2006). "Outcome of treatment for congenital toxoplasmosis, 1981–2004: the national collaborative Chicago-based, congenital toxoplasmosis study." Clinical Infectious Diseases **42**(10): 1383-1394.
- Melikoglu, M., I. Fresko, C. Mat, Y. Ozyazgan, F. Gogus, S. Yurdakul, V. Hamuryudan and H. Yazici (2005). "Short-term trial of etanercept in Behcet's disease: a double blind, placebo controlled study." The Journal of Rheumatology **32**(1): 98-105.
- Mercanti, A., B. Parolini, A. Bonora, Q. Lequaglie and L. Tomazzoli (2001). "Epidemiology of endogenous uveitis in north-eastern Italy. Analysis of 655 new cases." Acta Ophthalmologica **79**(1): 64-68.
- Mets, M. B., E. Holfels, K. M. Boyer, C. N. Swisher, N. Roizen, L. Stein, M. Stein, J. Hopkins, S. Withers and D. Mack (1996). "Eye manifestations of congenital toxoplasmosis." American journal of ophthalmology **122**(3): 309-324.
- Michel, L., H. Touil, N. B. Pikor, J. L. Gommerman, A. Prat and A. Bar-Or (2015). "B Cells in the Multiple Sclerosis Central Nervous System: Trafficking and Contribution to CNS-Compartmentalized Inflammation." Front Immunol **6**: 636.
- Michel, S. S., A. Ekong, S. Baltatzis and C. S. Foster (2002). "Multifocal choroiditis and panuveitis: immunomodulatory therapy." Ophthalmology **109**(2): 378-383.
- Michelson, J. B., P. E. Michelson and F. V. Chisari (1980). "Subretinal neovascular membrane and disciform scar in Behçet's disease." American journal of ophthalmology **90**(2): 182-185.
- Miehlsler, W., W. Reinisch, G. Moser, A. Gangl and H. Vogelsang (2001). "Is mycophenolate mofetil an effective alternative in azathioprine-intolerant patients with chronic active Crohn's disease?" The American journal of gastroenterology **96**(3): 782-787.
- Miller, L. W. (2002). "Cardiovascular toxicities of immunosuppressive agents." American Journal of Transplantation **2**(9): 807-818.
- Miserocchi, E., I. Pontikaki, G. Modorati, M. Gattinara, P. L. Meroni and V. Gerloni (2011). "Anti-CD 20 monoclonal antibody (rituximab) treatment for inflammatory ocular diseases." Autoimmun Rev **11**(1): 35-39.
- Mitoma, H., T. Horiuchi, H. Tsukamoto, Y. Tamimoto, Y. Kimoto, A. Uchino, K. To, S. I. Harashima, N. Hatta and M. Harada (2008). "Mechanisms for cytotoxic effects of anti-tumor necrosis factor agents on transmembrane tumor necrosis factor α -expressing cells: comparison among infliximab, etanercept, and adalimumab." Arthritis & Rheumatology **58**(5): 1248-1257.
- Miyaki, K., A. Matsubara, A. Nishiwaki, K. Tomida, H. Morita, M. Yoshida and Y. Ogura (2009). "Pitavastatin attenuates leukocyte-endothelial interactions induced by ischemia-reperfusion injury in the rat retina." Curr Eye Res **34**(1): 10-17.
- Montoya, J. G. and O. Liesenfeld (2004). "Toxoplasmosis." Lancet **363**(9425): 1965-1976.
- Montoya, J. G., S. Parmley, O. Liesenfeld, G. J. Jaffe and J. S. Remington (1999). "Use of the polymerase chain reaction for diagnosis of ocular toxoplasmosis." Ophthalmology **106**(8): 1554-1563.

- Moorthy, R. S., L. P. Chong, R. E. Smith and N. A. Rao (1993). "Subretinal neovascular membranes in Vogt-Koyanagi-Harada syndrome." Am J Ophthalmol **116**(2): 164-170.
- Moorthy, R. S., H. Inomata and N. A. Rao (1995). "Vogt-Koyanagi-Harada syndrome." Surv Ophthalmol **39**(4): 265-292.
- Moss, J., M. Stylianou, S. Levine, A. Barochia, N. Weir, S. Parrish, A. Lazarus, J. Nations, S. McKay and J. Fontana (2017). "Atorvastatin Treatment For Pulmonary Sarcoidosis, A Randomized, Double-Blind, Placebo-Controlled Clinical Trial." Am J Respir Crit Care Med **195**: A4755.
- Mulligan, M. S., J. Varani, M. K. Dame, C. L. Lane, C. W. Smith, D. C. Anderson and P. A. Ward (1991). "Role of endothelial-leukocyte adhesion molecule 1 (ELAM-1) in neutrophil-mediated lung injury in rats." J Clin Invest **88**(4): 1396-1406.
- Murphy, C. C., K. Greiner, J. Plskova, L. Duncan, N. A. Frost, J. V. Forrester and A. D. Dick (2005). "Cyclosporine vs tacrolimus therapy for posterior and intermediate uveitis." Archives of Ophthalmology **123**(5): 634-641.
- Mushtaq, B., T. Saeed, R. Situnayake and P. Murray (2007). "Adalimumab for sight-threatening uveitis in Behçet's disease." Eye **21**(6): 824.
- Mushtaq, B., T. Saeed, R. D. Situnayake and P. I. Murray (2007). "Adalimumab for sight-threatening uveitis in Behcet's disease." Eye (Lond) **21**(6): 824-825.
- Musial, J., A. Undas, P. Gajewski, M. Jankowski, W. Sydor and A. Szczeklik (2001). "Anti-inflammatory effects of simvastatin in subjects with hypercholesterolemia." Int J Cardiol **77**(2-3): 247-253.
- Nagashima, T., H. Okazaki, K. Yudoh, H. Matsuno and S. Minota (2006). "Apoptosis of rheumatoid synovial cells by statins through the blocking of protein geranylgeranylation: a potential therapeutic approach to rheumatoid arthritis." Arthritis Rheum **54**(2): 579-586.
- Namba, K., H. Goto, T. Kaburaki, N. Kitaichi, N. Mizuki, Y. Asukata, Y. Fujino, A. Meguro, S. Sakamoto, E. Shibuya, K. Yokoi and S. Ohno (2015). "A Major Review: Current Aspects of Ocular Behçet's Disease in Japan." Ocul Immunol Inflamm **23 Suppl 1**: S1-23.
- Nath, N., S. Giri, R. Prasad, A. K. Singh and I. Singh (2004). "Potential targets of 3-hydroxy-3-methylglutaryl coenzyme A reductase inhibitor for multiple sclerosis therapy." J Immunol **172**(2): 1273-1286.
- Nath, N., S. Giri, R. Prasad, A. K. Singh and I. Singh (2004). "Potential targets of 3-hydroxy-3-methylglutaryl coenzyme A reductase inhibitor for multiple sclerosis therapy." Journal of Immunology **172**(2): 1273-1286.
- Neri, P., A. Azuara-Blanco and J. V. Forrester (2004). "Incidence of glaucoma in patients with uveitis." Journal of glaucoma **13**(6): 461-465.
- Neuhaus, O., S. Strasser-Fuchs, F. Fazekas, B. C. Kieseier, G. Niederwieser, H. P. Hartung and J. J. Archelos (2002). "Statins as immunomodulators: comparison with interferon-beta 1b in MS." Neurology **59**(7): 990-997.
- Nguyen, B. and S. Stadtsbaeder (1975). "In vitro activity of cotrimoxazole on the intracellular multiplication of *Toxoplasma gondii*." Pathologia Europaea **10**(4): 307-315.
- Nguyen, B. and S. Stadtsbaeder (1983). "Comparative effects of cotrimoxazole (trimethoprim-sulphamethoxazole), pyrimethamine-sulphadiazine and spiramycin during avirulent infection with *Toxoplasma gondii* (Beverley strain) in mice." British journal of pharmacology **79**(4): 923-928.
- Nguyen, Q. D., P. T. Merrill, G. J. Jaffe, A. D. Dick, S. K. Kurup, J. Sheppard, A. Schlaen, C. Pavesio, L. Cimino and J. Van Calster (2016). "Adalimumab for prevention of uveitic flare in patients with inactive

non-infectious uveitis controlled by corticosteroids (VISUAL II): a multicentre, double-masked, randomised, placebo-controlled phase 3 trial." The Lancet **388**(10050): 1183-1192.

Niccoli, L., C. Nannini, M. Benucci, D. Chindamo, E. Cassara, C. Salvarani, L. Cimino, G. Gini, I. Lenzetti and F. Cantini (2007). "Long-term efficacy of infliximab in refractory posterior uveitis of Behcet's disease: a 24-month follow-up study." Rheumatology (Oxford) **46**(7): 1161-1164.

Nicholson, B. P., M. Zhou, M. Rostamizadeh, P. Mehta, E. Agrón, W. Wong, H. Wiley, R. Nussenblatt and H. N. Sen (2014). "Epidemiology of epiretinal membrane in a large cohort of patients with uveitis." Ophthalmology **121**(12): 2393-2398.

Nickla, D. L. and J. Wallman (2010). "The multifunctional choroid." Prog Retin Eye Res **29**(2): 144-168.

Nieder Korn, J. Y. (2007). The induction of anterior chamber-associated immune deviation. Immune Response and the Eye, Karger Publishers. **92**: 27-35.

Nissen, S. E., E. M. Tuzcu, P. Schoenhagen, B. G. Brown, P. Ganz, R. A. Vogel, T. Crowe, G. Howard, C. J. Cooper, B. Brodie, C. L. Grines and A. N. DeMaria (2004). "Effect of intensive compared with moderate lipid-lowering therapy on progression of coronary atherosclerosis: a randomized controlled trial." Jama **291**(9): 1071-1080.

Nolan, J. and E. Rosen (1968). "Treatment of active toxoplasmic retino-choroiditis." The British journal of ophthalmology **52**(5): 396.

Nordgaard-Lassen, I., J. F. Dahlerup and L. Tjellessen (2011). "GUIDELINES FOR SCREENING, PROPHYLAXIS AND CRITICAL INFORMATION PRIOR TO INITIATING ANTI-TNF-ALPHA TREATMENT." Dan Med J 2012; **59**: C4480.

Nussenblatt, R. B. (1991). "Proctor Lecture. Experimental autoimmune uveitis: mechanisms of disease and clinical therapeutic indications." Invest Ophthalmol Vis Sci **32**(13): 3131-3141.

Nussenblatt, R. B. and R. Belfort, Jr. (1994). "Ocular toxoplasmosis. An old disease revisited." Jama **271**(4): 304-307.

Nussenblatt, R. B., K. K. Mittal, S. Fuhrman, S. D. Sharma and A. G. Palestine (1989). "Lymphocyte proliferative responses of patients with ocular toxoplasmosis to parasite and retinal antigens." American journal of ophthalmology **107**(6): 632-641.

Nussenblatt, R. B., A. G. Palestine, C.-C. Chan and F. Roberge (1985). "Standardization of Vitreal inflammatory Activity in Intermediate and Posterior Uveitis." Ophthalmology **92**(4): 467-471.

Nussenblatt, R. B., A. G. Palestine, C. C. Chan, M. Mochizuki and K. Yancey (1985). "Effectiveness of cyclosporin therapy for Behcet's disease." Arthritis Rheum **28**(6): 671-679.

Nussenblatt, R. B., A. G. Palestine, C. C. Chan, G. Stevens Jr, S. D. Mellow and S. B. Green (1991). "Randomized, double-masked study of cyclosporine compared to prednisolone in the treatment of endogenous uveitis." American journal of ophthalmology **112**(2): 138-146.

Nussenblatt, R. B. and S. M. Whitcup (2010). Uveitis fundamentals and clinical practice. Edinburgh, Mosby/Elsevier.

Nussenblatt, R. B., S. M. Whitcup and A. G. Palestine (1996). Uveitis: fundamentals and clinical practice, Mosby St. Louis.

O'Connor, G. (1982). Epidemiology and pathogenesis of the ocular and cerebral forms of Behçet's disease. Behçet's Disease. Pathogenetic Mechanism and Clinical Future, University of Tokyo Press, Tokyo: 115.

O'Connor, G. R. and J. K. Frenkel (1976). "Editorial: Dangers of steroid treatment in toxoplasmosis. Periocular injections and systemic therapy." Arch Ophthalmol **94**(2): 213.

- O'Shea, J. J., A. Ma and P. Lipsky (2002). "Cytokines and autoimmunity." Nat Rev Immunol **2**(1): 37-45.
- Obenaus, C. D., H. E. Shaw, C. F. Sydnor and G. K. Klintworth (1978). "Sarcoidosis and its ophthalmic manifestations." American journal of ophthalmology **86**(5): 648-655.
- Oh, K. T., N. J. Christmas and J. C. Folk (2002). "Birdshot retinochoroiditis: long term follow-up of a chronically progressive disease." American journal of ophthalmology **133**(5): 622-629.
- Ohno, S., S. Nakamura, S. Hori, M. Shimakawa, H. Kawashima, M. Mochizuki, S. Sugita, S. Ueno, K. Yoshizaki and G. Inaba (2004). "Efficacy, safety, and pharmacokinetics of multiple administration of infliximab in Behcet's disease with refractory uveoretinitis." J Rheumatol **31**(7): 1362-1368.
- Okada, A. A. (2000). "Drug therapy in Behcet's disease." Ocul Immunol Inflamm **8**(2): 85-91.
- Olsen, T. W., A. Capone, P. Sternberg, H. E. Grossniklaus, D. F. Martin and T. M. Aaberg (1996). "Subfoveal choroidal neovascularization in punctate inner choroidopathy: surgical management and pathologic findings." Ophthalmology **103**(12): 2061-2069.
- Olson, N. Y., C. B. Lindsley and W. A. Godfrey (1988). "Nonsteroidal anti-inflammatory drug therapy in chronic childhood iridocyclitis." American Journal of Diseases of Children **142**(12): 1289-1292.
- Ooi, K. G., G. Galatowicz, V. L. Calder and S. L. Lightman (2006). "Cytokines and chemokines in uveitis: is there a correlation with clinical phenotype?" Clin Med Res **4**(4): 294-309.
- Opremcak, E. M., D. K. Scales and M. R. Sharpe (1992). "Trimethoprim-sulfamethoxazole therapy for ocular toxoplasmosis." Ophthalmology **99**(6): 920-925.
- Opremcak, E. M., D. K. Scales and M. R. Sharpe (1992). "Trimethoprim-sulfamethoxazole therapy for ocular toxoplasmosis." Ophthalmology **99**(6): 920-925.
- Oréface, F. and L. Bahia-Oliveira (2005). "Toxoplasmose." Uveíte Clínica e Cirúrgica: Texto & Atlas **2**: 699-804.
- Orth, D., B. Fine, W. Fagman and T. Quirk (1977). "Clarification of foveomacular nomenclature and grid for quantitation of macular disorders." Transactions. Section on Ophthalmology. American Academy of Ophthalmology and Otolaryngology **83**(3 Pt 1): OP506-514.
- Ostrowski, S. M., B. L. Wilkinson, T. E. Golde and G. Landreth (2007). "Statins reduce amyloid- β production through inhibition of protein isoprenylation." Journal of Biological Chemistry **282**(37): 26832-26844.
- Owens, T., H. Wekerle and J. Antel (2001). "Genetic models for CNS inflammation." Nat Med **7**(2): 161-166.
- Ozyazgan, Y., S. Yurdakul, H. Yazici, B. Tüzün, A. İşçimen, Y. Tüzün, T. Aktunc, H. Pazarli, V. Hamuryudan and A. Müftüoğlu (1992). "Low dose cyclosporin A versus pulsed cyclophosphamide in Behcet's syndrome: a single masked trial." British Journal of Ophthalmology **76**(4): 241-243.
- Pahan, K., F. G. Sheikh, A. M. Namboodiri and I. Singh (1997). "Lovastatin and phenylacetate inhibit the induction of nitric oxide synthase and cytokines in rat primary astrocytes, microglia, and macrophages." J Clin Invest **100**(11): 2671-2679.
- Paivonsalo-Hietanen, T., H. Vaahoranta-Lehtonen, J. Tuominen and K. M. Saari (1994). "Uveitis survey at the University Eye Clinic in Turku." Acta Ophthalmol (Copenh) **72**(4): 505-512.
- Palmer, H. E., M. R. Stanford, M. D. Sanders and E. M. Graham (1996). "Visual outcome of patients with idiopathic ischaemic and non-ischaemic retinal vasculitis." Eye (Lond) **10** (Pt 3): 343-348.
- Palmer, H. E., A. G. Zaman, C. E. Edelsten, M. R. Stanford and E. M. Graham (1995). "Systemic morbidity in patients with isolated idiopathic retinal vasculitis." Lancet **346**(8973): 505-506.

- Panek, W. C., G. N. Holland, D. A. Lee and R. E. Christensen (1990). "Glaucoma in patients with uveitis." British Journal of Ophthalmology **74**(4): 223-227.
- Papadia, M. and C. P. Herbort (2013). "Reappraisal of birdshot retinochoroiditis (BRC): a global approach." Graefes Arch Clin Exp Ophthalmol **251**(3): 861-869.
- Papadia, M., B. Jeannin and C. P. Herbort (2012). "OCT findings in birdshot chorioretinitis: a glimpse into retinal disease evolution." Ophthalmic Surg Lasers Imaging **43**(6 Suppl): S25-31.
- Papadopoulou, C., M. Kostik, M. Bohm, J. C. Nieto-Gonzalez, M. I. Gonzalez-Fernandez, A. Pistorio, A. Martini and A. Ravelli (2013). "Methotrexate therapy may prevent the onset of uveitis in juvenile idiopathic arthritis." J Pediatr **163**(3): 879-884.
- Pasadhika, S., J. H. Kempen, C. W. Newcomb, T. L. Liesegang, S. S. Pujari, J. T. Rosenbaum, J. E. Thorne, C. S. Foster, D. A. Jabs, G. A. Levy-Clarke, R. B. Nussenblatt and E. B. Suhler (2009). "Azathioprine for ocular inflammatory diseases." Am J Ophthalmol **148**(4): 500-509.e502.
- Patel, A. A., R. A. Swerlick and C. O. McCall (2006). "Azathioprine in dermatology: the past, the present, and the future." J Am Acad Dermatol **55**(3): 369-389.
- Patel, K. H., A. D. Birnbaum, H. H. Tessler and D. A. Goldstein (2011). "Presentation and outcome of patients with punctate inner choroidopathy at a tertiary referral center." Retina **31**(7): 1387-1391.
- Patel, R. B. and P. G. Welling (1980). "Clinical pharmacokinetics of co-trimoxazole (trimethoprim-sulphamethoxazole)." Clinical pharmacokinetics **5**(5): 405-423.
- Pato, E., S. Muñoz-Fernández, F. Francisco, M. A. Abad, J. Maese, A. Ortiz and L. Carmona (2011). Systematic review on the effectiveness of immunosuppressants and biological therapies in the treatment of autoimmune posterior uveitis. Seminars in arthritis and rheumatism, Elsevier.
- Pavesio, C., M. L. Chiappino, P. Gormley, P. Y. Setzer and B. A. Nichols (1995). "Acquired retinochoroiditis in hamsters inoculated with ME 49 strain Toxoplasma." Investigative ophthalmology & visual science **36**(11): 2166-2175.
- Pavesio, C. and S. Lightman (1996). "Toxoplasma gondii and ocular toxoplasmosis: pathogenesis." The British journal of ophthalmology **80**(12): 1099.
- Pearson, P. A., A. R. Piracha, H. A. Sen and G. J. Jaffe (1999). "Atovaquone for the treatment of toxoplasma retinochoroiditis in immunocompetent patients1." Ophthalmology **106**(1): 148-153.
- Pederson, J. E., K. R. Kenyon, W. R. Green and A. E. Maumenee (1978). "Pathology of pars planitis." Am J Ophthalmol **86**(6): 762-774.
- Penn, J. (2008). Retinal and choroidal angiogenesis, Springer Science & Business Media.
- Perez-Miralles, F. C. (2018). "Daclizumab in multiple sclerosis." Revista de neurologia **66**(8): 271-282.
- Perez, V. L., S. H. Chavala, M. Ahmed, D. Chu, P. Zafirakis, S. Baltatzis, V. Ocampo and C. S. Foster (2004). "Ocular manifestations and concepts of systemic vasculitides." Surv Ophthalmol **49**(4): 399-418.
- Peters, D. H., A. Fitton, G. L. Plosker and D. Faulds (1993). "Tacrolimus." Drugs **46**(4): 746-794.
- Petersen, E. (2007). "Toxoplasmosis." Semin Fetal Neonatal Med **12**(3): 214-223.
- Petersen, E., J. Dubey, D. Joynson and T. Wreghitt (2001). "Toxoplasmosis: a comprehensive clinical guide."
- Petersen, E., A. Kijlstra and M. Stanford (2012). "Epidemiology of ocular toxoplasmosis." Ocul Immunol Inflamm **20**(2): 68-75.

- Phan, L., K. Kasza, J. Jalbrzikowski, A. G. Noble, P. Latkany, A. Kuo, W. Mieler, S. Meyers, P. Rabiah and K. Boyer (2008). "Longitudinal study of new eye lesions in children with toxoplasmosis who were not treated during the first year of life." American journal of ophthalmology **146**(3): 375-384. e374.
- Piccirillo, C. A. (2008). "Regulatory T cells in health and disease." Cytokine **43**(3): 395-401.
- Piccolino, F. C., A. Grosso and E. Savini (2009). "Fundus autofluorescence in serpiginous choroiditis." Graefe's Archive for Clinical and Experimental Ophthalmology **247**(2): 179-185.
- Planck, S. R., T. T. Dang, D. Graves, D. Tara, J. C. Ansel and J. T. Rosenbaum (1992). "Retinal pigment epithelial cells secrete interleukin-6 in response to interleukin-1." Invest Ophthalmol Vis Sci **33**(1): 78-82.
- Plasencia, C., D. Pascual-Salcedo, L. Nuno, G. Bonilla, A. Villalba, D. Peiteado, J. Diez, D. Nagore, A. R. del Agua, R. Moral, E. Martin-Mola and A. Balsa (2012). "Influence of immunogenicity on the efficacy of longterm treatment of spondyloarthritis with infliximab." Ann Rheum Dis **71**(12): 1955-1960.
- Pleyer, U. and C. S. Foster (2007). Uveitis and immunological disorders, Springer.
- Podzamczar, D., J. Miro, E. Ferrer, J. Gatell, J. Ramón, E. Ribera, G. Sirera, A. Cruceta, H. Knobel and P. Domingo (2000). "Thrice-weekly sulfadiazine-pyrimethamine for maintenance therapy of toxoplasmic encephalitis in HIV-infected patients." European Journal of Clinical Microbiology and Infectious Diseases **19**(2): 89-95.
- Podzamczar, D., J. M. Miro, F. Bolao, J. M. Gatell, J. Cosin, G. Sirera, P. Domingo, F. Laguna, J. Santamaria and J. Verdejo (1995). "Twice-weekly maintenance therapy with sulfadiazine-pyrimethamine to prevent recurrent toxoplasmic encephalitis in patients with AIDS." Annals of internal medicine **123**(3): 175-180.
- Portela, R. W., J. Bethony, M. I. Costa, A. Gazzinelli, R. W. Vitor, F. M. Hermeto, R. Correa-Oliveira and R. T. Gazzinelli (2004). "A multihousehold study reveals a positive correlation between age, severity of ocular toxoplasmosis, and levels of glycoinositolphospholipid-specific immunoglobulin A." The Journal of infectious diseases **190**(1): 175-183.
- Presta, L. G. (2006). "Engineering of therapeutic antibodies to minimize immunogenicity and optimize function." Advanced drug delivery reviews **58**(5-6): 640-656.
- Raja, S. C., D. A. Jabs, J. Dunn, S. Fekrat, C. H. Machan, M. J. Marsh and N. M. Bressler (1999). "Pars planitis: clinical features and class II HLA associations." Ophthalmology **106**(3): 594-599.
- Ram, J., A. Gupta, S. Kumar, S. Kaushik, N. Gupta and S. Severia (2010). "Phacoemulsification with intraocular lens implantation in patients with uveitis." Journal of Cataract & Refractive Surgery **36**(8): 1283-1288.
- Ramanan, A. V., A. D. Dick, A. P. Jones, A. McKay, P. R. Williamson, S. Compeyrot-Lacassagne, B. Hardwick, H. Hickey, D. Hughes and P. Woo (2017). "Adalimumab plus methotrexate for uveitis in juvenile idiopathic arthritis." New England Journal of Medicine **376**(17): 1637-1646.
- Ramos-Casals, M., P. Brito-Zeron, S. Munoz, N. Soria, D. Galiana, L. Bertolaccini, M. J. Cuadrado and M. A. Khamashta (2007). "Autoimmune diseases induced by TNF-targeted therapies: analysis of 233 cases." Medicine (Baltimore) **86**(4): 242-251.
- Rankin, G. B., H. D. Watts, C. S. Melnyk and M. L. Kelley (1979). "National Cooperative Crohn's Disease Study: extraintestinal manifestations and perianal complications." Gastroenterology **77**(4): 914-920.
- Rao, N. A. (2007). "Pathology of Vogt–Koyanagi–Harada disease." International ophthalmology **27**(2-3): 81-85.

- Raskin, E., M. Alves, G. Eredia, A. Raskin and M. R. Alves (2002). "Ocular toxoplasmosis: a comparative study of the treatment with sulfadiazine and pyrimethamine versus sulphametoxazole-trimethoprim." Rev Bras Oftalmol **61**: 335-338.
- Rathinam, S. R., M. Babu, R. Thundikandy, A. Kanakath, N. Nardone, E. Esterberg, S. M. Lee, W. T. Enanoria, T. C. Porco and E. N. Browne (2014). "A randomized clinical trial comparing methotrexate and mycophenolate mofetil for noninfectious uveitis." Ophthalmology **121**(10): 1863-1870.
- Rathinam, S. R. and E. T. Cunningham, Jr. (2000). "Infectious causes of uveitis in the developing world." Int Ophthalmol Clin **40**(2): 137-152.
- Rauz, S., P. Stavrou and P. I. Murray (2000). "Evaluation of foldable intraocular lenses in patients with uveitis." Ophthalmology **107**(5): 909-919.
- Read, R. W., A. Rechodouni, N. Butani, R. Johnston, L. D. LaBree, R. E. Smith and N. A. Rao (2001). "Complications and prognostic factors in Vogt-Koyanagi-Harada disease." Am J Ophthalmol **131**(5): 599-606.
- Reddy, V. M., R. L. Zamora and H. J. Kaplan (1995). "Distribution of growth factors in subfoveal neovascular membranes in age-related macular degeneration and presumed ocular histoplasmosis syndrome." American journal of ophthalmology **120**(3): 291-301.
- Reich, D. S., C. F. Lucchinetti and P. A. Calabresi (2018). "Multiple Sclerosis." N Engl J Med **378**(2): 169-180.
- Reich, M. and F. Mackensen (2015). "Ocular toxoplasmosis: background and evidence for an antibiotic prophylaxis." Curr Opin Ophthalmol **26**(6): 498-505.
- Reich, M., M. Ruppenstein, M. D. Becker and F. Mackensen (2015). "Time patterns of recurrences and factors predisposing for a higher risk of recurrence of ocular toxoplasmosis." Retina **35**(4): 809-819.
- Rhen, T. and J. A. Cidlowski (2005). "Antiinflammatory action of glucocorticoids--new mechanisms for old drugs." N Engl J Med **353**(16): 1711-1723.
- Ribera, E., A. Fernandez-Sola, C. Juste, A. Rovira, F. J. Romero, L. Armadans-Gil, I. Ruiz, I. Ocaña and A. Pahissa (1999). "Comparison of high and low doses of trimethoprim-sulfamethoxazole for primary prevention of toxoplasmic encephalitis in human immunodeficiency virus-infected patients." Clinical infectious diseases **29**(6): 1461-1466.
- Richards Jr, F. O., J. A. Kovacs and B. J. Luft (1995). "Preventing toxoplasmic encephalitis in persons infected with human immunodeficiency virus." Clinical infectious diseases **21**(Supplement_1): S49-S56.
- Ridker, P. M., N. Rifai, M. A. Pfeffer, F. M. Sacks, L. A. Moye, S. Goldman, G. C. Flaker and E. Braunwald (1998). "Inflammation, pravastatin, and the risk of coronary events after myocardial infarction in patients with average cholesterol levels." Circulation **98**(9): 839-844.
- Robinson, R., C. E. Ho, Q. S. Tan, C. D. Luu, K. T. Moe, C. Y. Cheung, T. Y. Wong and V. A. Barathi (2011). "Fluvastatin downregulates VEGF-A expression in TNF-alpha-induced retinal vessel tortuosity." Invest Ophthalmol Vis Sci **52**(10): 7423-7431.
- Rodrigues, E. B., M. E. Farah, M. Maia, F. M. Penha, C. Regatieri, G. B. Melo, M. M. Pinheiro and C. R. Zanetti (2009). "Therapeutic monoclonal antibodies in ophthalmology." Progress in retinal and eye research **28**(2): 117-144.
- Rodriguez, A., Y. A. Akova, M. Pedroza-Seres and C. S. Foster (1994). "Posterior segment ocular manifestations in patients with HLA-B27-associated uveitis." Ophthalmology **101**(7): 1267-1274.
- Rodriguez, A., M. Calonge, M. Pedroza-Seres, Y. A. Akova, E. M. Messmer, D. J. D'Amico and C. S. Foster (1996). "Referral patterns of uveitis in a tertiary eye care center." Arch Ophthalmol **114**(5): 593-599.

- Rosenbaum, J. T., C. H. Sibley and P. Lin (2016). "Retinal vasculitis." Curr Opin Rheumatol **28**(3): 228-235.
- Rothova, A. (2007). "Inflammatory cystoid macular edema." Current Opinion in Ophthalmology **18**(6): 487-492.
- Rothova, A., C. Alberts, E. Glasius, A. Kijlstra, H. Buitenhuis and A. Breebaart (1989). "Risk factors for ocular sarcoidosis." Documenta Ophthalmologica **72**(3-4): 287-296.
- Rothova, A., L. E. Bosch-Driessen, N. H. Van Loon and W. F. Treffers (1998). "Azithromycin for ocular toxoplasmosis." British journal of ophthalmology **82**(11): 1306-1308.
- Rothova, A., H. J. Buitenhuis, C. Meenken, G. S. Baarsma, T. N. Boen-Tan, P. T. de Jong, C. M. Schweitzer, Z. Timmerman, J. de Vries, M. J. Zaal and et al. (1989). "Therapy of ocular toxoplasmosis." Int Ophthalmol **13**(6): 415-419.
- Rothova, A., H. J. Buitenhuis, C. Meenken, C. Brinkman, A. Linssen, C. Alberts, L. Luyendijk and A. Kijlstra (1992). "Uveitis and systemic disease." British Journal of Ophthalmology **76**(3): 137-141.
- Rothova, A., C. Meenken, H. J. Buitenhuis, C. J. Brinkman, G. S. Baarsma, T. N. Boen-Tan, P. T. de Jong, N. Klaassen-Broekema, C. M. Schweitzer, Z. Timmerman and et al. (1993). "Therapy for ocular toxoplasmosis." Am J Ophthalmol **115**(4): 517-523.
- Rothova, A., M. Suttorp-van Schulten, W. F. Treffers and A. Kijlstra (1996). "Causes and frequency of blindness in patients with intraocular inflammatory disease." British Journal of Ophthalmology **80**(4): 332-336.
- Rothova, A., W. G. van Venedaal, A. Linssen, E. Glasius, A. Kijlstra and P. T. de Jong (1987). "Clinical features of acute anterior uveitis." Am J Ophthalmol **103**(2): 137-145.
- Rotsos, T. G. and M. M. Moschos (2008). "Cystoid macular edema." Clin Ophthalmol **2**(4): 919-930.
- Rozin, A., D. Schapira, Y. Braun-Moscovici and A. M. Nahir (2001). "Cotrimoxazole treatment for rheumatoid arthritis." Semin Arthritis Rheum **31**(2): 133-141.
- Rudwaleit, M., E. Rødevand, P. Holck, J. Vanhoof, M. Kron, S. Kary and H. Kupper (2009). "Adalimumab effectively reduces the rate of anterior uveitis flares in patients with active ankylosing spondylitis: results of a prospective open-label study." Annals of the rheumatic diseases **68**(5): 696-701.
- Rumble, J. M., A. K. Huber, G. Krishnamoorthy, A. Srinivasan, D. A. Giles, X. Zhang, L. Wang and B. M. Segal (2015). "Neutrophil-related factors as biomarkers in EAE and MS." J Exp Med **212**(1): 23-35.
- Russell, A., B. Lentle and J. Dossetor (1979). "Acute anterior uveitis. A clinical, HLA and scintiscan survey." Acta rheumatologica **3**(2): 156.
- Rutnin, U. (1967). "Fundus appearance in normal eyes. I. The choroid." Am J Ophthalmol **64**(5): 821-839.
- Rychwalski, P. J., O. A. Cruz, G. Alanis-Lambreton, T. M. Foy and R. E. Kane (1997). "Asymptomatic uveitis in young people with inflammatory bowel disease." Journal of American Association for Pediatric Ophthalmology and Strabismus **1**(2): 111-114.
- Saadoun, D., B. Wechsler, C. Terrada, D. Hajage, D. Le Thi Huong, M. Resche-Rigon, N. Cassoux, P. Le Hoang, Z. Amoura, B. Bodaghi and P. Cacoub (2010). "Azathioprine in severe uveitis of Behcet's disease." Arthritis Care Res (Hoboken) **62**(12): 1733-1738.
- Saatci, O. A., N. Kocak, I. Durak and M. H. Ergin (2001). "Unilateral retinal vasculitis, branch retinal artery occlusion and subsequent retinal neovascularization in Crohn's disease." Int Ophthalmol **24**(2): 89-92.

- Sacks, F. M., M. A. Pfeffer, L. A. Moye, J. L. Rouleau, J. D. Rutherford, T. G. Cole, L. Brown, J. W. Warnica, J. M. Arnold, C. C. Wun, B. R. Davis and E. Braunwald (1996). "The effect of pravastatin on coronary events after myocardial infarction in patients with average cholesterol levels. Cholesterol and Recurrent Events Trial investigators." N Engl J Med **335**(14): 1001-1009.
- Sadeghi, M. M., A. Tiglio, K. Sadigh, L. O'Donnell, M. Collinge, R. Pardi and J. R. Bender (2001). "Inhibition of interferon-gamma-mediated microvascular endothelial cell major histocompatibility complex class II gene activation by HMG-CoA reductase inhibitors." Transplantation **71**(9): 1262-1268.
- Sainz de la Maza, M., N. S. Jabbur and C. S. Foster (1994). "Severity of scleritis and episcleritis." Ophthalmology **101**(2): 389-396.
- Sakane, T. and M. Takeno (2000). "Novel approaches to Behcet's disease." Expert Opin Investig Drugs **9**(9): 1993-2005.
- Salmon, J. F., P. G. Ursell and P. Frith (2000). "Neovascular glaucoma as a complication of retinal vasculitis in Crohn disease." Am J Ophthalmol **130**(4): 528-530.
- Sangwan, V. S. (2010). "Treatment of uveitis: beyond steroids." Indian J Ophthalmol **58**(1): 1-2.
- Santos Lacomba, M., C. Marcos Martin, J. M. Gallardo Galera, M. A. Gomez Vidal, E. Collantes Estevez, R. Ramirez Chamond and M. Omar (2001). "Aqueous humor and serum tumor necrosis factor-alpha in clinical uveitis." Ophthalmic Res **33**(5): 251-255.
- Sarabi, Z. S., M. G. Saeidi, M. Khodashahi, A. E. Rezaie, K. Hashemzadeh, R. Khodashahi and H. Heidari (2016). "Evaluation of the Anti-inflammatory Effects of Atorvastatin on Patients with Rheumatoid Arthritis: A Randomized Clinical Trial." Electron Physician **8**(8): 2700-2706.
- Sayani, F. A., C. Prosser, R. J. Bailey, P. Jacobs and R. N. Fedorak (2005). "Thiopurine methyltransferase enzyme activity determination before treatment of inflammatory bowel disease with azathioprine: effect on cost and adverse events." Canadian Journal of Gastroenterology and Hepatology **19**(3): 147-151.
- Scallon, B., A. Cai, N. Solowski, A. Rosenberg, X.-Y. Song, D. Shealy and C. Wagner (2002). "Binding and functional comparisons of two types of tumor necrosis factor antagonists." Journal of Pharmacology and Experimental Therapeutics **301**(2): 418-426.
- Schmeling, H. and G. Horneff (2005). "Etanercept and uveitis in patients with juvenile idiopathic arthritis." Rheumatology (Oxford) **44**(8): 1008-1011.
- Schmitz-Valckenberg, S., F. G. Holz, A. C. Bird and R. F. Spaide (2008). "Fundus autofluorescence imaging: review and perspectives." Retina **28**(3): 385-409.
- Secchi, A. (1982). "Cataracts in Uveitis." Transactions of the ophthalmological societies of the United Kingdom **102**: 390-394.
- Sedwick, L. A., T. G. Klingele, R. M. Burde and M. M. Behrens (1984). "Optic neuritis in inflammatory bowel disease." Journal of clinical neuro-ophthalmology **4**(1): 3-6.
- Segal, R., E. Mozes, M. Yaron and B. Tartakovsky (1989). "The effects of methotrexate on the production and activity of interleukin-1." Arthritis Rheum **32**(4): 370-377.
- Selmaj, K., C. S. Raine and A. H. Cross (1991). "Anti-tumor necrosis factor therapy abrogates autoimmune demyelination." Ann Neurol **30**(5): 694-700.
- Senda, M., B. DeLustro, E. Eugui and Y. Natsumeda (1995). "Mycophenolic acid, an inhibitor of IMP dehydrogenase that is also an immunosuppressive agent, suppresses the cytokine-induced nitric oxide production in mouse and rat vascular endothelial cells." Transplantation **60**(10): 1143-1148.
- Sever, P. S., B. Dahlof, N. R. Poulter, H. Wedel, G. Beevers, M. Caulfield, R. Collins, S. E. Kjeldsen, A. Kristinsson, G. T. McInnes, J. Mehlsen, M. Nieminen, E. O'Brien, J. Ostergren and A. Investigators

(2004). "Prevention of coronary and stroke events with atorvastatin in hypertensive patients who have average or lower-than-average cholesterol concentrations, in the Anglo-Scandinavian Cardiac Outcomes Trial--Lipid Lowering Arm (ASCOT-LLA): a multicentre randomised controlled trial." Drugs **64 Suppl 2**: 43-60.

Sfikakis, P., P. Kaklamanis, A. Elezoglou, N. Katsilambros, P. Theodossiadis, S. Papaefthimiou and N. Markomichelakis (2004). "Infliximab for recurrent, sight-threatening ocular inflammation in Adamantiades-Behçet disease." Annals of Internal Medicine **140**(5): 404-406.

Shah, K. H., R. D. Levinson, F. Yu, R. Goldhardt, L. K. Gordon, C. R. Gonzales, J. R. Heckenlively, P. J. Kappel and G. N. Holland (2005). "Birdshot chorioretinopathy." Surv Ophthalmol **50**(6): 519-541.

Shao, E. H., V. Menezo and S. R. Taylor (2014). "Birdshot chorioretinopathy." Curr Opin Ophthalmol **25**(6): 488-494.

Sharief, L., S. Lightman, J. Baltinas and O. Tomkins-Netzer (2018). "Long-term effect of cataract phacoemulsification on the inflammation control and clinical outcome in uveitis patients." Clinical & experimental ophthalmology.

Sharma, O. P. (1984). Sarcoidosis--clinical management, Butterworth-Heinemann.

Sheppard, J. D., T. L. Comstock and M. E. Cavet (2016). "Impact of the topical ophthalmic corticosteroid loteprednol etabonate on intraocular pressure." Advances in therapy **33**(4): 532-552.

Sheremata, W. A., A. Minagar, J. S. Alexander and T. Vollmer (2005). "The Role of Alpha-4 Integrin in the Aetiology of Multiple Sclerosis." CNS drugs **19**(11): 909-922.

Shirinsky, I. V., A. A. Biryukova and V. S. Shirinsky (2017). "Simvastatin as an Adjunct to Conventional Therapy of Non-infectious Uveitis: A Randomized, Open-Label Pilot Study." Current eye research **42**(12): 1713-1718.

Shirodkar, A.-I., S. Taylor and S. Lightman (2011). "Retinal Vein Occlusions In Patients With Uveitis." Investigative Ophthalmology & Visual Science **52**(14): 2726-2726.

Sholter, D. E. and P. W. Armstrong (2000). "Adverse effects of corticosteroids on the cardiovascular system." The Canadian journal of cardiology **16**(4): 505-511.

Silveira, C., R. Belfort, Jr., M. Burnier, Jr. and R. Nussenblatt (1988). "Acquired toxoplasmic infection as the cause of toxoplasmic retinochoroiditis in families." Am J Ophthalmol **106**(3): 362-364.

Silveira, C., R. Belfort, Jr., C. Muccioli, G. N. Holland, C. G. Victora, B. L. Horta, F. Yu and R. B. Nussenblatt (2002). "The effect of long-term intermittent trimethoprim/sulfamethoxazole treatment on recurrences of toxoplasmic retinochoroiditis." Am J Ophthalmol **134**(1): 41-46.

Silveira, C., R. Belfort, C. Muccioli, G. N. Holland, C. G. Victora, B. L. Horta, F. Yu and R. B. Nussenblatt (2002). "The effect of long-term intermittent trimethoprim/sulfamethoxazole treatment on recurrences of toxoplasmic retinochoroiditis." American journal of ophthalmology **134**(1): 41-46.

Silveira, C., R. Belfort, R. Nussenblatt, M. Farah, W. Takahashi, P. Imamura and M. Burnier (1989). "Unilateral pigmentary retinopathy associated with ocular toxoplasmosis." American journal of ophthalmology **107**(6): 682-684.

Silveira, C., C. Muccioli, R. Nussenblatt and R. Belfort, Jr. (2015). "The Effect of Long-term Intermittent Trimethoprim/Sulfamethoxazole Treatment on Recurrences of Toxoplasmic Retinochoroiditis: 10 Years of Follow-up." Ocul Immunol Inflamm **23**(3): 246-247.

Silveira, C., A. L. Vallochi, U. Rodrigues da Silva, C. Muccioli, G. N. Holland, R. B. Nussenblatt, R. Belfort and L. V. Rizzo (2011). "Toxoplasma gondii in the peripheral blood of patients with acute and chronic toxoplasmosis." Br J Ophthalmol **95**(3): 396-400.

- Simonini, G., A. Taddio, M. Cattalini, R. Caputo, C. De Libero, S. Naviglio, C. Bresci, M. Lorusso, L. Lepore and R. Cimaz (2011). "Prevention of flare recurrences in childhood-refractory chronic uveitis: An open-label comparative study of adalimumab versus infliximab." Arthritis care & research **63**(4): 612-618.
- Sinensky, M., L. Beck, S. Leonard and R. Evans (1990). "Differential inhibitory effects of lovastatin on protein isoprenylation and sterol synthesis." Journal of Biological Chemistry **265**(32): 19937-19941.
- Singh, J. A., G. A. Wells, R. Christensen, E. Tanjong Ghogomu, L. Maxwell, J. Macdonald, G. Filippini, N. Skoetz, D. Francis and L. Lopes (2010). "Adverse effects of biologics: a network meta-analysis and Cochrane overview." Cochrane Database of Systematic Reviews **2**.
- Singh, R., V. Gupta and A. Gupta (2004). "Pattern of uveitis in a referral eye clinic in north India." Indian journal of ophthalmology **52**(2): 121.
- Skalka, H. W. and J. T. Prchal (1980). "Effect of corticosteroids on cataract formation." Archives of Ophthalmology **98**(10): 1773-1777.
- Slakter, J. S., A. Giovannini, L. A. Yannuzzi, B. Scassellati-Sforzolini, D. R. Guyer, J. A. Sorenson, R. F. Spaide and D. Orlock (1997). "Indocyanine green angiography of multifocal choroiditis." Ophthalmology **104**(11): 1813-1819.
- Smeeth, L., I. Douglas, A. J. Hall, R. Hubbard and S. Evans (2009). "Effect of statins on a wide range of health outcomes: a cohort study validated by comparison with randomized trials." Br J Clin Pharmacol **67**(1): 99-109.
- Smit, R. L., G. S. Baarsma and J. de Vries (1993). "Classification of 750 consecutive uveitis patients in the Rotterdam Eye Hospital." Int Ophthalmol **17**(2): 71-76.
- Smith, J. A., D. J. Thompson, S. M. Whitcup, E. Suhler, G. Clarke, S. Smith, M. Robinson, J. Kim and K. S. Barron (2005). "A randomized, placebo-controlled, double-masked clinical trial of etanercept for the treatment of uveitis associated with juvenile idiopathic arthritis." Arthritis Care & Research **53**(1): 18-23.
- Soete, M., B. Fortier, D. Camus and J. Dubremetz (1993). "Toxoplasma gondii: kinetics of bradyzoite-tachyzoite interconversion in vitro." Experimental parasitology **76**(3): 259-264.
- Soheilian, M., K. Heidari, S. Yazdani, M. Shahsavari, H. Ahmadih and M. Dehghan (2004). "Patterns of uveitis in a tertiary eye care center in Iran." Ocul Immunol Inflamm **12**(4): 297-310.
- Soheilian, M., A. Ramezani, A. Azimzadeh, M. M. Sadoughi, M. H. Dehghan, R. Shahghadami, M. Yaseri and G. A. Peyman (2011). "Randomized trial of intravitreal clindamycin and dexamethasone versus pyrimethamine, sulfadiazine, and prednisolone in treatment of ocular toxoplasmosis." Ophthalmology **118**(1): 134-141.
- Soheilian, M., M.-M. Sadoughi, M. Ghajarnia, M. H. Dehghan, S. Yazdani, H. Behboudi, A. Anisian and G. A. Peyman (2005). "Prospective randomized trial of trimethoprim/sulfamethoxazole versus pyrimethamine and sulfadiazine in the treatment of ocular toxoplasmosis." Ophthalmology **112**(11): 1876-1882.
- Soheilian, M., M. M. Sadoughi, M. Ghajarnia, M. H. Dehghan, S. Yazdani, H. Behboudi, A. Anisian and G. A. Peyman (2005). "Prospective randomized trial of trimethoprim/sulfamethoxazole versus pyrimethamine and sulfadiazine in the treatment of ocular toxoplasmosis." Ophthalmology **112**(11): 1876-1882.
- Soukiasian, S. H., C. S. Foster and M. B. Raizman (1994). "Treatment strategies for scleritis and uveitis associated with inflammatory bowel disease." American journal of ophthalmology **118**(5): 601-611.
- Spaide, R. F., N. Goldberg and K. B. Freund (2013). "Redefining multifocal choroiditis and panuveitis and punctate inner choroidopathy through multimodal imaging." Retina **33**(7): 1315-1324.

- SPALTER, H. F., C. J. CAMPBELL, K. S. NOYORI, M. C. RITTLER and C. J. KOESTER (1966). "Prophylactic photocoagulation of recurrent toxoplasmic retinochoroiditis: a preliminary report." Archives of Ophthalmology **75**(1): 21-31.
- Spencer, W. (1985). Lens. Ophthalmic Pathology: An Atlas and Textbook, WB Saunders, Philadelphia: 423-479.
- Springer, T. A. (1994). "Traffic signals for lymphocyte recirculation and leukocyte emigration: the multistep paradigm." Cell **76**(2): 301-314.
- Stanbury, R. M. and E. M. Graham (1998). "Systemic corticosteroid therapy—side effects and their management." British Journal of Ophthalmology **82**(6): 704-708.
- Stanford, M. R. and R. E. Gilbert (2009). "Treating ocular toxoplasmosis: current evidence." Mem Inst Oswaldo Cruz **104**(2): 312-315.
- Steahly, L. (1988). "Sarcoidosis and peripheral neovascularization." Annals of ophthalmology **20**(11): 426-427, 430.
- Stegeman, C. A., J. W. Tervaert, P. E. de Jong and C. G. Kallenberg (1996). "Trimethoprim-sulfamethoxazole (co-trimoxazole) for the prevention of relapses of Wegener's granulomatosis. Dutch Co-Trimoxazole Wegener Study Group." N Engl J Med **335**(1): 16-20.
- Steimle, V., C. A. Siegrist, A. Mottet, B. Lisowska-Groszpiette and B. Mach (1994). "Regulation of MHC class II expression by interferon-gamma mediated by the transactivator gene CIITA." Science **265**(5168): 106-109.
- Steuer, H., A. Jaworski, B. Elger, M. Kausmann, J. Keldenich, H. Schneider, D. Stoll and B. Schloschauer (2005). "Functional characterization and comparison of the outer blood-retina barrier and the blood-brain barrier." Invest Ophthalmol Vis Sci **46**(3): 1047-1053.
- Stevenson, W., C. M. P. Ponce, D. R. Agarwal, R. Gelman and J. B. Christoforidis (2016). "Epiretinal membrane: optical coherence tomography-based diagnosis and classification." Clinical ophthalmology (Auckland, NZ) **10**: 527.
- Streilein, J. W. (1993). "Immune privilege as the result of local tissue barriers and immunosuppressive microenvironments." Curr Opin Immunol **5**(3): 428-432.
- Sugar, E. A., J. T. Holbrook, J. H. Kempen, A. E. Burke, L. T. Drye, J. E. Thorne, T. A. Louis, D. A. Jabs, M. M. Altaweel and K. D. Frick (2014). "Cost-effectiveness of fluocinolone acetonide implant versus systemic therapy for noninfectious intermediate, posterior, and panuveitis." Ophthalmology **121**(10): 1855-1862.
- Sugita, S., Y. Kawazoe, A. Imai, Y. Yamada, S. Horie and M. Mochizuki (2012). "Inhibition of Th17 differentiation by anti-TNF-alpha therapy in uveitis patients with Behcet's disease." Arthritis research & therapy **14**(3): R99.
- Sugita, S., T. F. Ng, P. J. Lucas, R. E. Gress and J. W. Streilein (2006). "B7+ iris pigment epithelium induce CD8+ T regulatory cells; both suppress CTLA-4+ T cells." The Journal of Immunology **176**(1): 118-127.
- Suhler, E. B., A. Adán, A. P. Brézin, E. Fortin, H. Goto, G. J. Jaffe, T. Kaburaki, M. Kramer, L. L. Lim and C. Muccioli (2018). "Safety and efficacy of adalimumab in patients with noninfectious uveitis in an ongoing open-label study: VISUAL III." Ophthalmology.
- Suhler, E. B., C. Y. Lowder, D. A. Goldstein, T. Giles, A. K. Lauer, P. A. Kurz, S. Pasadhika, S. T. Lee, A. de Saint Sardos and N. J. Butler (2013). "Adalimumab therapy for refractory uveitis: results of a multicentre, open-label, prospective trial." British Journal of Ophthalmology: bjophthalmol-2012-302292.

- Suhler, E. B., C. Y. Lowder, D. A. Goldstein, T. Giles, A. K. Lauer, P. A. Kurz, S. Pasadhika, S. T. Lee, A. de Saint Sardos, N. J. Butler, H. H. Tessler, J. R. Smith and J. T. Rosenbaum (2013). "Adalimumab therapy for refractory uveitis: results of a multicentre, open-label, prospective trial." Br J Ophthalmol **97**(4): 481-486.
- Suhler, E. B., J. R. Smith, T. R. Giles, A. K. Lauer, M. S. Wertheim, D. E. Kurz, P. A. Kurz, L. Lim, F. Mackensen, T. D. Pickard and J. T. Rosenbaum (2009). "Infliximab therapy for refractory uveitis: 2-year results of a prospective trial." Arch Ophthalmol **127**(6): 819-822.
- Suhler, E. B., J. R. Smith, M. S. Wertheim, A. K. Lauer, D. E. Kurz, T. D. Pickard and J. T. Rosenbaum (2005). "A prospective trial of infliximab therapy for refractory uveitis: preliminary safety and efficacy outcomes." Archives of Ophthalmology **123**(7): 903-912.
- Suzuki Kurokawa, M. and N. Suzuki (2004). "Behcet's disease." Clin Exp Med **4**(1): 10-20.
- Tabbara, K. (1982). "Management of ocular toxoplasmosis." Trans Pac Coast Otophthalmol Soc **63**: 23-34.
- Tabbara, K. F. and G. R. O'Connor (1980). "Treatment of ocular toxoplasmosis with clindamycin and sulfadiazine." Ophthalmology **87**(2): 129-134.
- Tabrizi, M. A., C.-M. L. Tseng and L. K. Roskos (2006). "Elimination mechanisms of therapeutic monoclonal antibodies." Drug discovery today **11**(1-2): 81-88.
- Takase, K., S. Ohno, H. Ideguchi, E. Uchio, M. Takeno and Y. Ishigatsubo (2011). "Successful switching to adalimumab in an infliximab-allergic patient with severe Behçet disease-related uveitis." Rheumatology international **31**(2): 243-245.
- Takeuchi, M., H. Hokama, R. Tsukahara, T. Kezuka, H. Goto, J.-i. Sakai and M. Usui (2005). "Risk and prognostic factors of poor visual outcome in Behcet's disease with ocular involvement." Graefe's Archive for Clinical and Experimental Ophthalmology **243**(11): 1147-1152.
- Takeuchi, M., T. Kezuka, S. Sugita, H. Keino, K. Namba, T. Kaburaki, K. Maruyama, K. Nakai, K. Hijioka and E. Shibuya (2014). "Evaluation of the long-term efficacy and safety of infliximab treatment for uveitis in Behcet's disease: a multicenter study." Ophthalmology **121**(10): 1877-1884.
- Talabani, H., T. Mergey, H. Yera, E. Delair, A. Brezin, G. Langsley and J. Dupouy-Camet (2010). "Factors of occurrence of ocular toxoplasmosis. A review." Parasite **17**(3): 177-182.
- Tamesis, R. R., A. Rodriguez, W. G. Christen, Y. A. Akova, E. Messmer and C. S. Foster (1996). "Systemic drug toxicity trends in immunosuppressive therapy of immune and inflammatory ocular disease." Ophthalmology **103**(5): 768-775.
- Tappeiner, C., C. Heinz, C. Specker and A. Heiligenhaus (2007). "Rituximab as a treatment option for refractory endogenous anterior uveitis." Ophthalmic Res **39**(3): 184-186.
- Tate, G. W., Jr. and R. G. Martin (1977). "Clindamycin in the treatment of human ocular toxoplasmosis." Can J Ophthalmol **12**(3): 188-195.
- Taylor, S. R., A. Banker, A. Schlaen, C. Couto, E. Matthe, L. Joshi, V. Menezo, E. Nguyen, O. Tomkins-Netzer, A. Bar, J. Morarji, P. McCluskey and S. Lightman (2013). "Intraocular methotrexate can induce extended remission in some patients in noninfectious uveitis." Retina **33**(10): 2149-2154.
- Taylor, S. R., Z. Habot-Wilner, P. Pacheco and S. L. Lightman (2009). "Intraocular methotrexate in the treatment of uveitis and uveitic cystoid macular edema." Ophthalmology **116**(4): 797-801.
- Taylor, S. R., S. L. Lightman, E. A. Sugar, G. J. Jaffe, W. R. Freeman, M. M. Altaweel, I. Kozak, J. T. Holbrook, D. A. Jabs and J. H. Kempen (2012). "The impact of macular edema on visual function in intermediate, posterior, and panuveitis." Ocul Immunol Inflamm **20**(3): 171-181.

- Taylor, S. R., A. D. Salama, L. Joshi, C. D. Pusey and S. L. Lightman (2009). "Rituximab is effective in the treatment of refractory ophthalmic Wegener's granulomatosis." Arthritis Rheum **60**(5): 1540-1547.
- Teasley, L. A., W. G. Christen and C. S. Foster (2007). "Oral nonsteroidal anti-inflammatory agents in the treatment of chronic or recurrent noninfectious uveitis." Contemporary Ophthalmology **6**(11): 1-6.
- Theodossiadis, G., C. Koutsandrea and A. Tzonou (1989). "A comparative study concerning the treatment of active toxoplasmic retinochoroiditis with argon laser and medication (follow-up 2–9 years)." Ophthalmologica **199**(2-3): 77-83.
- Theodossiadis, P., S. Kokolakis, I. Ladas, A. Kollia, D. Chatzoulis and G. Theodossiadis (1995). "Retinal vascular involvement in acute toxoplasmic retinochoroiditis." International ophthalmology **19**(1): 19-24.
- Thompson, J. T. (2006). "Cataract formation and other complications of intravitreal triamcinolone for macular edema." Am J Ophthalmol **141**(4): 629-637.
- Thorne, J. E., D. A. Jabs, G. B. Peters, D. Hair, J. P. Dunn and J. H. Kempen (2005). "Birdshot retinochoroidopathy: ocular complications and visual impairment." American journal of ophthalmology **140**(1): 45. e41-45. e48.
- Thorne, J. E., D. A. Jabs, F. A. Qazi, Q. D. Nguyen, J. H. Kempen and J. P. Dunn (2005). "Mycophenolate mofetil therapy for inflammatory eye disease." Ophthalmology **112**(8): 1472-1477.
- Thorne, J. E., E. A. Sugar, J. T. Holbrook, A. E. Burke, M. M. Altaweel, A. T. Vitale, N. R. Acharya, J. H. Kempen and D. A. Jabs (2018). "Periocular Triamcinolone vs. Intravitreal Triamcinolone vs. Intravitreal Dexamethasone Implant for the Treatment of Uveitic Macular Edema: The PeriOcular vs. INTravitreal corticosteroids for uveitic macular edema (POINT) Trial." Ophthalmology.
- Thorne, J. E., E. Suhler, M. Skup, S. Tari, D. Macaulay, J. Chao and A. Ganguli (2016). "Prevalence of noninfectious uveitis in the United States: a claims-based analysis." JAMA ophthalmology **134**(11): 1237-1245.
- Thorne, J. E., S. Wittenberg, D. A. Jabs, G. B. Peters, T. L. Reed, S. R. Kedhar and J. P. Dunn (2006). "Multifocal choroiditis with panuveitis incidence of ocular complications and of loss of visual acuity." Ophthalmology **113**(12): 2310-2316.
- Thorne, J. E., F. Woreta, S. R. Kedhar, J. P. Dunn and D. A. Jabs (2007). "Juvenile idiopathic arthritis-associated uveitis: incidence of ocular complications and visual acuity loss." American journal of ophthalmology **143**(5): 840-846. e842.
- Tiede, I., G. Fritz, S. Strand, D. Poppe, R. Dvorsky, D. Strand, H. A. Lehr, S. Wirtz, C. Becker, R. Atreya, J. Mudter, K. Hildner, B. Bartsch, M. Holtmann, R. Blumberg, H. Walczak, H. Iven, P. R. Galle, M. R. Ahmadian and M. F. Neurath (2003). "CD28-dependent Rac1 activation is the molecular target of azathioprine in primary human CD4+ T lymphocytes." J Clin Invest **111**(8): 1133-1145.
- Tomkins-Netzer, O., L. Talat, A. Bar, A. Lula, S. R. Taylor, L. Joshi and S. Lightman (2014). "Long-term clinical outcome and causes of vision loss in patients with uveitis." Ophthalmology **121**(12): 2387-2392.
- Tomkins-Netzer, O., L. Talat, A. Bar, A. Lula, S. R. Taylor, L. Joshi and S. Lightman (2014). "Long-term clinical outcome and causes of vision loss in patients with uveitis." Ophthalmology **121**(12): 2387-2392.
- Tomkins-Netzer, O., S. R. Taylor and S. Lightman (2014). "Long-term clinical and anatomic outcome of birdshot chorioretinopathy." JAMA ophthalmology **132**(1): 57-62.
- Towler, H. and S. Lightman (2000). "Symptomatic intraocular inflammation in multiple sclerosis." Clinical & experimental ophthalmology **28**(2): 97-102.

- Tran, T. H., M. D. de Smet, B. Bodaghi, C. Fardeau, N. Cassoux and P. Lehoang (2008). "Uveitic macular oedema: correlation between optical coherence tomography patterns with visual acuity and fluorescein angiography." Br J Ophthalmol **92**(7): 922-927.
- Tran, V. T., C. Auer, Y. Guex-Crosier, N. Pittet and C. P. Herbort (1994). "Epidemiology of uveitis in Switzerland." Ocul Immunol Inflamm **2**(3): 169-176.
- Tsakiri, A., K. Kallenbach, D. Fuglø, B. Wanscher, H. Larsson and J. Frederiksen (2012). "Simvastatin improves final visual outcome in acute optic neuritis: a randomized study." Multiple Sclerosis Journal **18**(1): 72-81.
- Tsuji, S., S. Taniuchi, M. Hasui, A. Yamamoto and Y. Kobayashi (2002). "Increased nitric oxide production by neutrophils from patients with chronic granulomatous disease on trimethoprim-sulfamethoxazole." Nitric Oxide **7**(4): 283-288.
- Tu, V., R. Yakubu and L. M. Weiss (2017). "Observations on bradyzoite biology." Microbes and infection.
- Tugal-Tutkun, I., C. P. Herbort, M. Khairallah and A. S. f. U. W. Group (2010). "Scoring of dual fluorescein and ICG inflammatory angiographic signs for the grading of posterior segment inflammation (dual fluorescein and ICG angiographic scoring system for uveitis)." International ophthalmology **30**(5): 539-552.
- Tugal-Tutkun, I., A. Mudun, M. Urgancioglu, S. Kamali, E. Kasapoglu, M. Inanc and A. Gul (2005). "Efficacy of infliximab in the treatment of uveitis that is resistant to treatment with the combination of azathioprine, cyclosporine, and corticosteroids in Behcet's disease: an open-label trial." Arthritis Rheum **52**(8): 2478-2484.
- Tugal-Tutkun, I., S. Onal, R. Altan-Yaycioglu, H. H. Altunbas and M. Urgancioglu (2004). "Uveitis in Behçet disease: an analysis of 880 patients." American journal of ophthalmology **138**(3): 373-380.
- Turan, B., H. Gallati, H. Erdi, A. Gürler, B. Michel and P. Villiger (1997). "Systemic levels of the T cell regulatory cytokines IL-10 and IL-12 in Behçet's disease; soluble TNFR-75 as a biological marker of disease activity." The Journal of rheumatology **24**(1): 128-132.
- Valentincic, N. V., A. Kraut and A. Rothova (2007). "Vitreous hemorrhage in multiple sclerosis-associated uveitis." Ocul Immunol Inflamm **15**(1): 19-25.
- Vallet, H., P. Seve, L. Biard, J. Baptiste Fraison, P. Bielefeld, L. Perard, B. Bienvenu, S. Abad, A. Rigolet, A. Deroux, D. Sene, A. Perlat, I. Marie, E. Feurer, E. Hachulla, O. Fain, G. Clavel, S. Riviere, P. A. Bouche, J. Gueudry, G. Pugnet, P. Le Hoang, M. Resche Rigon, P. Cacoub, B. Bodaghi and D. Saadoun (2016). "Infliximab Versus Adalimumab in the Treatment of Refractory Inflammatory Uveitis: A Multicenter Study From the French Uveitis Network." Arthritis Rheumatol **68**(6): 1522-1530.
- Vallochi, A. L., C. Muccioli, M. C. Martins, C. Silveira, R. Belfort, Jr. and L. V. Rizzo (2005). "The genotype of *Toxoplasma gondii* strains causing ocular toxoplasmosis in humans in Brazil." Am J Ophthalmol **139**(2): 350-351.
- van Denderen, J. C., I. M. Visman, M. T. Nurmohamed, M. S. Suttorp-Schulten and I. E. van der Horst-Bruinsma (2014). "Adalimumab significantly reduces the recurrence rate of anterior uveitis in patients with ankylosing spondylitis." The Journal of rheumatology **41**(9): 1843-1848.
- van der Heijde, D., A. L. Pangan, M. H. Schiff, J. Braun, M. Borofsky, J. Torre, J. C. Davis, Jr., R. L. Wong, H. Kupper and E. Collantes (2008). "Adalimumab effectively reduces the signs and symptoms of active ankylosing spondylitis in patients with total spinal ankylosis." Ann Rheum Dis **67**(9): 1218-1221.
- van der Most, P. J., A. M. Dolga, I. M. Nijholt, P. G. Luiten and U. L. Eisel (2009). "Statins: mechanisms of neuroprotection." Progress in neurobiology **88**(1): 64-75.

- van der Ven, A. J., E. M. Schoondermark-van de Ven, W. Camps, W. J. Melchers, P. P. Koopmans, J. W. van der Meer and J. M. Galama (1996). "Anti-toxoplasma effect of pyrimethamine, trimethoprim and sulphonamides alone and in combination: implications for therapy." Journal of antimicrobial chemotherapy **38**(1): 75-80.
- Van der Waaij, D. (1959). "Formation, growth and multiplication of *Toxoplasma gondii* cysts in mouse brains." Tropical and Geographical Medicine **11**(4): 345-360.
- Van Kooij, B., K. Probst, R. Fijnheer, M. Roest, W. De Loos and A. Rothova (2008). "Risk factors for cystoid macular oedema in patients with uveitis." Eye **22**(2): 256.
- Van Laar, J., T. Missotten, P. Van Daele, A. Jamnitski, G. Baarsma and P. Van Hagen (2007). "Adalimumab: a new modality for Behçet's disease?" Annals of the rheumatic diseases **66**(4): 565-566.
- van Oosten, B. W., F. Barkhof, L. Truyen, J. B. Boringa, F. W. Bertelsmann, B. M. von Blomberg, J. N. Woody, H. P. Hartung and C. H. Polman (1996). "Increased MRI activity and immune activation in two multiple sclerosis patients treated with the monoclonal anti-tumor necrosis factor antibody cA2." Neurology **47**(6): 1531-1534.
- Vasconcelos-Santos, D. V. (2012). "Ocular manifestations of systemic disease: toxoplasmosis." Curr Opin Ophthalmol **23**(6): 543-550.
- Vasconcelos-Santos, D. V., D. O. Machado Azevedo, W. R. Campos, F. Orefice, G. M. Queiroz-Andrade, E. V. Carellos, R. M. Castro Romanelli, J. N. Januario, L. M. Resende, O. A. Martins-Filho, A. C. de Aguiar Vasconcelos Carneiro, R. W. Almeida Vitor and W. T. Caiaffa (2009). "Congenital toxoplasmosis in southeastern Brazil: results of early ophthalmologic examination of a large cohort of neonates." Ophthalmology **116**(11): 2199-2205.e2191.
- Vazquez-Cobian, L. B., T. Flynn and T. J. Lehman (2006). "Adalimumab therapy for childhood uveitis." J Pediatr **149**(4): 572-575.
- Verity, D., G. Wallace, R. Vaughan and M. Stanford (2003). "Behçet's disease: from Hippocrates to the third millennium." British Journal of Ophthalmology **87**(9): 1175-1183.
- Vine, A. K. (1992). "Severe periphlebitis, peripheral retinal ischemia, and preretinal neovascularization in patients with multiple sclerosis." Am J Ophthalmol **113**(1): 28-32.
- Vitale, A., G. Emmi, G. Lopalco, C. Fabiani, S. Gentileschi, E. Silvestri, F. Iannone, B. Frediani, M. Galeazzi and G. Lapadula (2017). "Long-term efficacy and safety of golimumab in the treatment of multirefractory Behçet's disease." Clinical rheumatology **36**(9): 2063-2069.
- Vitale, A., G. Emmi, G. Lopalco, S. Gentileschi, E. Silvestri, C. Fabiani, M. L. Urban, B. Frediani, M. Galeazzi and F. Iannone (2017). "Adalimumab effectiveness in Behçet's disease: short and long-term data from a multicenter retrospective observational study." Clinical rheumatology **36**(2): 451-455.
- Vogt, S. D., S. R. Barnum, C. A. Curcio and R. W. Read (2006). "Distribution of complement anaphylatoxin receptors and membrane-bound regulators in normal human retina." Experimental eye research **83**(4): 834-840.
- Vollmer, T., L. Key, V. Durkalski, W. Tyor, J. Corboy, S. Markovic-Plese, J. Preiningerova, M. Rizzo and I. Singh (2004). "Oral simvastatin treatment in relapsing-remitting multiple sclerosis." Lancet **363**(9421): 1607-1608.
- Wakefield, D. and A. Lloyd (1992). "The role of cytokines in the pathogenesis of inflammatory eye disease." Cytokine **4**(1): 1-5.
- Wallis, R. S. and S. Ehlers (2005). Tumor necrosis factor and granuloma biology: explaining the differential infection risk of etanercept and infliximab. Seminars in arthritis and rheumatism, Elsevier.

- Walter, D. H., S. Fichtlscherer, M. Sellwig, W. Auch-Schwelk, V. Schächinger and A. M. Zeiher (2001). "Preprocedural C-reactive protein levels and cardiovascular events after coronary stent implantation." Journal of the American College of Cardiology **37**(3): 839-846.
- Wang, J. M., A. Sica, G. Peri, S. Walter, I. M. Padura, P. Libby, M. Ceska, I. Lindley, F. Colotta and A. Mantovani (1991). "Expression of monocyte chemotactic protein and interleukin-8 by cytokine-activated human vascular smooth muscle cells." Arterioscler Thromb **11**(5): 1166-1174.
- Wang, R. K. (2010). "Optical Microangiography: A Label Free 3D Imaging Technology to Visualize and Quantify Blood Circulations within Tissue Beds in vivo." IEEE J Sel Top Quantum Electron **16**(3): 545-554.
- Watanabe, A., S. Arimoto and O. Nishi (2009). "Correlation between metamorphopsia and epiretinal membrane optical coherence tomography findings." Ophthalmology **116**(9): 1788-1793.
- Watzke, R. C., A. J. Packer, J. C. Folk, W. E. Benson, D. Burgess and R. R. Ober (1984). "Punctate inner choroidopathy." Am J Ophthalmol **98**(5): 572-584.
- Wechsler, F. and F. Davatchi (1990). "Criteria for diagnosis of Behçet's disease." The Lancet **335**(8697): 1078-1080.
- Weijtens, O., R. C. Schoemaker, F. P. Romijn, A. F. Cohen, E. G. Lentjes and J. C. van Meurs (2002). "Intraocular penetration and systemic absorption after topical application of dexamethasone disodium phosphate." Ophthalmology **109**(10): 1887-1891.
- Weinblatt, M. E., E. C. Keystone, D. E. Furst, L. W. Moreland, M. H. Weisman, C. A. Birbara, L. A. Teoh, S. A. Fischkoff and E. K. Chartash (2003). "Adalimumab, a fully human anti-tumor necrosis factor α monoclonal antibody, for the treatment of rheumatoid arthritis in patients taking concomitant methotrexate: the ARMADA trial." Arthritis & Rheumatology **48**(1): 35-45.
- Weiss, L. M., C. Harris, M. Berger, H. B. Tanowitz and M. Wittner (1988). "Pyrimethamine concentrations in serum and cerebrospinal fluid during treatment of acute Toxoplasma encephalitis in patients with AIDS." The Journal of infectious diseases **157**(3): 580-583.
- WEISS, L. M., D. LAPLACE, P. M. TAKVORIAN, H. B. TANOWITZ, A. Cali and M. WITTNER (1995). "A cell culture system for study of the development of Toxoplasma gondii bradyzoites." Journal of Eukaryotic Microbiology **42**(2): 150-157.
- Weiss, M. J., N. Velazquez and A. J. Hofeldt (1990). "Serologic tests in the diagnosis of presumed toxoplasmic retinochoroiditis." Am J Ophthalmol **109**(4): 407-411.
- Weitz-Schmidt, G., K. Welzenbach, V. Brinkmann, T. Kamata, J. Kallen, C. Bruns, S. Cottens, Y. Takada and U. Hommel (2001). "Statins selectively inhibit leukocyte function antigen-1 by binding to a novel regulatory integrin site." Nat Med **7**(6): 687-692.
- Westfall, A. C., A. K. Lauer, E. B. Suhler and J. T. Rosenbaum (2005). "Toxoplasmosis retinochoroiditis and elevated intraocular pressure: a retrospective study." J Glaucoma **14**(1): 3-10.
- Whitcup, S. M., E. C. Salvo, Jr. and R. B. Nussenblatt (1994). "Combined cyclosporine and corticosteroid therapy for sight-threatening uveitis in Behcet's disease." Am J Ophthalmol **118**(1): 39-45.
- Williamson, J., R. Paterson, D. McGavin, M. Jasani, J. Boyle and W. Doig (1969). "Posterior subcapsular cataracts and glaucoma associated with long-term oral corticosteroid therapy. In patients with rheumatoid arthritis and related conditions." The British journal of ophthalmology **53**(6): 361.
- Wilson, S. H., R. D. Simari, P. J. Best, T. E. Peterson, L. O. Lerman, M. Aviram, K. A. Nath, D. R. Holmes, Jr. and A. Lerman (2001). "Simvastatin preserves coronary endothelial function in hypercholesterolemia in the absence of lipid lowering." Arterioscler Thromb Vasc Biol **21**(1): 122-128.

- Winterhalter, S., K. Severing, J. Stammen, A. K. Maier, E. Godehardt and A. M. Jousen (2010). "Does atovaquone prolong the disease-free interval of toxoplasmic retinochoroiditis?" Graefe's Archive for Clinical and Experimental Ophthalmology **248**(8): 1187-1192.
- Wormser, G. P., G. T. Keusch and R. C. Heel (1982). "Co-trimoxazole (trimethoprim-sulfamethoxazole)." Drugs **24**(6): 459-518.
- Wright, K. W., P. H. Spiegel and T. Hengst (2013). Pediatric ophthalmology and strabismus, Springer Science & Business Media.
- Wyngaarden, S. and L. Smith (1992). "Bennett." Cecil Textbook of Medicine. WB Saunders Company, Philadelphia.
- Yan, J., B. Huang, G. Liu, B. Wu, S. Huang, H. Zheng, J. Shen, Z.-R. Lun, Y. Wang and F. Lu (2013). "Meta-analysis of prevention and treatment of toxoplasmic encephalitis in HIV-infected patients." Acta tropica **127**(3): 236-244.
- Yang, P. and C. S. Foster (2013). "Interleukin 21, interleukin 23, and transforming growth factor beta1 in HLA-A29-associated birdshot retinochoroidopathy." Am J Ophthalmol **156**(2): 400-406.e402.
- Yazici, H., H. Pazarli, C. G. Barnes, Y. Tuzun, Y. Ozyazgan, A. Silman, S. Serdaroglu, V. Oguz, S. Yurdakul, G. E. Lovatt and et al. (1990). "A controlled trial of azathioprine in Behcet's syndrome." N Engl J Med **322**(5): 281-285.
- Yeh, S., F. Forooghian, W. T. Wong, L. J. Faia, C. Cukras, J. C. Lew, K. Wroblewski, E. D. Weichel, C. B. Meyerle and H. N. Sen (2010). "Fundus autofluorescence imaging of the white dot syndromes." Archives of ophthalmology **128**(1): 46-56.
- Yeo, J. H., F. A. Jakobiec, T. Iwamoto, G. Richard and I. Kreissig (1983). "Opportunistic toxoplasmic retinochoroiditis following chemotherapy for systemic lymphoma: a light and electron microscopic study." Ophthalmology **90**(8): 885-898.
- Yla-Herttuala, S., B. A. Lipton, M. E. Rosenfeld, T. Sarkioja, T. Yoshimura, E. J. Leonard, J. L. Witztum and D. Steinberg (1991). "Expression of monocyte chemoattractant protein 1 in macrophage-rich areas of human and rabbit atherosclerotic lesions." Proc Natl Acad Sci U S A **88**(12): 5252-5256.
- Yoshida, A., Y. Koide, M. Uchijima and T. O. Yoshida (1994). "IFN-gamma induces IL-12 mRNA expression by a murine macrophage cell line, J774." Biochem Biophys Res Commun **198**(3): 857-861.
- Yoshida, M., T. Sawada, H. Ishii, R. E. Gerszten, A. Rosenzweig, M. A. Gimbrone, Y. Yasukochi and F. Numano (2001). "HMG-CoA reductase inhibitor modulates monocyte-endothelial cell interaction under physiological flow conditions in vitro." Arteriosclerosis, Thrombosis, and Vascular Biology **21**(7): 1165-1171.
- Youssef, S., O. Stuve, J. C. Patarroyo, P. J. Ruiz, J. L. Radosevich, E. M. Hur, M. Bravo, D. J. Mitchell, R. A. Sobel, L. Steinman and S. S. Zamvil (2002). "The HMG-CoA reductase inhibitor, atorvastatin, promotes a Th2 bias and reverses paralysis in central nervous system autoimmune disease." Nature **420**(6911): 78-84.
- Yunker, J. J., G. McGwin, Jr. and R. W. Read (2013). "Statin use and ocular inflammatory disease risk." J Ophthalmic Inflamm Infect **3**(1): 8.
- Zannin, M. E., C. Birolo, V. M. Gerloni, E. Miserocchi, I. Pontikaki, M. P. Paroli, C. Bracaglia, A. Shardlow, F. Parentin, R. Cimaz, G. Simonini, F. Falcini, F. Corona, S. Viola, R. De Marco, L. Breda, F. La Torre, F. Vittadello, G. Martini and F. Zulian (2013). "Safety and efficacy of infliximab and adalimumab for refractory uveitis in juvenile idiopathic arthritis: 1-year followup data from the Italian Registry." J Rheumatol **40**(1): 74-79.

Zhang, Y., Z. Zhang and H. Yan (2015). "Simvastatin inhibits ischemia/reperfusion injury-induced apoptosis of retinal cells via downregulation of the tumor necrosis factor-alpha/nuclear factor-kappaB pathway." Int J Mol Med **36**(2): 399-405.

Zhou, H. (2005). "Clinical pharmacokinetics of etanercept: a fully humanized soluble recombinant tumor necrosis factor receptor fusion protein." J Clin Pharmacol **45**(5): 490-497.

Zhou, M., C. Jiang, R. Gu, Z. Sun, N. Huynh and Q. Chang (2015). "Correlation between Retinal Changes and Visual Function in Late-Stage Vogt-Koyanagi-Harada Disease: An Optical Coherence Tomography Study." J Ophthalmol **2015**: 916485.

Zierhut, M., A. M. Abu El-Asrar, B. Bodaghi and I. Tugal-Tutkun (2014). "Therapy of ocular Behçet disease." Ocular immunology and inflammation **22**(1): 64-76.

Zierhut, M., C. Pavesio, S. Ohno, F. Orefice and N. A. Rao (2016). Intraocular Inflammation. Berlin, Heidelberg, Springer Berlin Heidelberg : Imprint: Springer.

7 Appendices

1. Statins in retinal disease
2. The role of biologics in NIIPPU, (poster presented in ARVO 2018)