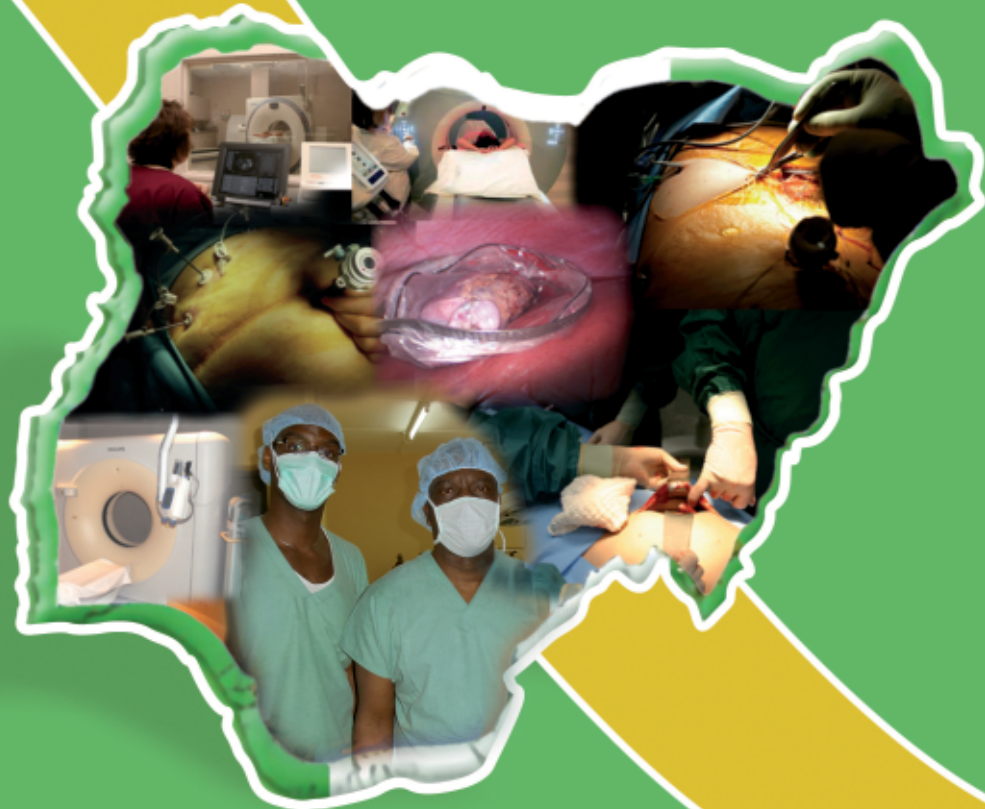



Nigerian Journal of Clinical Practice



- ☞ Currently listed in Pubmed, Index Medicus, SCOPUS, Index Copemicus, Science Citation Index Expanded, Journal Citation Reports and AJOL
- ☞ Official Publication of the Medical and Dental Consultants' Association of Nigeria

Impact Factor® for 2017: 0.713

Pattern of Tympanic Membrane Perforation in a Tertiary Hospital in Nigeria

WA Adegbiyi, GT Olajide¹, OA Olajuyin, F Olatoke², CC Nwawolo³

Department of ENT, Ekiti State University Teaching Hospital, Ado Ekiti,
¹Department of ENT, Federal Teaching Hospital, Ido Ekiti, Ekiti State, ²Department of Surgery, ENT Unit, Federal Medical Centre, Lokoja, ³Department of ENT, Lagos University Teaching Hospital, Lagos, Nigeria

ABSTRACT

Background/Objectives: Tympanic membrane perforation is a common otological disorder with associated hearing impairment. This study aimed at determining the clinicoepidemiological pattern, etiological factors, clinical presentation, and management of tympanic membrane perforation in a tertiary hospital in Nigeria.

Materials and Methods: This was a prospective, hospital-based study of patients with the clinical finding of perforated tympanic membrane. The study was carried out over a period of 5 years (September 2012 to August 2017). Interviewer-assisted questionnaire was administered to obtain the detailed history and clinical findings from consenting patients. Data collected were collated and analyzed using SPSS version 16.0. **Results:** A total of 529 patients had tympanic membrane perforation, of which 368 (69.6%) were males and 161 (30.4%) were females with a male-to-female ratio of 2:1. The prevalence of tympanic membrane perforation in this study was 7.8%. The most common presenting symptom among the patients was otorrhea in 81.5%, otalgia in 72.8%, and tinnitus in 55.7%. Acute suppurative otitis media was a cause of tympanic membrane perforation in 28.4% of the patients while 55.7% of the patients proceed to chronic suppurative otitis media. Unilateral tympanic membrane perforation was 79.0%. The left ear tympanic membrane perforation was 43.9%. Grade 1 tympanic membrane perforation accounted for 39.3% while grade 2 accounted for 32.3%. The most common types of tympanic membrane perforation were central in 38.2%, anterior central in 32.3%, and posterior central in 19.3%. Conductive hearing impairment accounted for 61.6% while sensorineural hearing impairment 25.3%. The most common degrees of hearing impairment were mild and moderate and accounted for 47.1% and 25.1%, respectively. The most common complications of tympanic membrane perforation were hearing impairment in 52.6%. Majority of the patients (425) were treated conservatively, six had fat patches, while 98 were treated surgically. Tympanic membrane perforation healed at the end of 3 months in 81.5%, while 18.5% did not heal after 3 months. **Conclusion:** Tympanic membrane perforation arises mainly from middle ear infections and traumatic causes. At presentation, size and location of perforation vary which depend on duration of infection or the traumatic causes.

KEYWORDS: Ear trauma, hearing impairment, otitis media, tympanic membrane perforation

Date of Acceptance:
17-Apr-2018

INTRODUCTION

The normal tympanic membrane is a translucent, gray-colored, lustrous, concave, and oval-shaped structure separating external ear from the middle ear. It is divided into pars tensa and pars flaccida by the

Address for correspondence: Dr. GT Olajide,

Department of ENT, Federal Teaching Hospital/College of Medicine and Health Sciences, Afe Babalola University, Ido Ekiti, Ekiti State, Nigeria.
E-mail: toyelajide@yahoo.co.uk

This is an open access journal, and articles are distributed under the terms of the Creative Commons Attribution-NonCommercial-ShareAlike 4.0 License, which allows others to remix, tweak, and build upon the work non-commercially, as long as appropriate credit is given and the new creations are licensed under the identical terms.

For reprints contact: reprints@medknow.com

How to cite this article: Adegbiyi WA, Olajide GT, Olajuyin OA, Olatoke F, Nwawolo CC. Pattern of tympanic membrane perforation in a tertiary hospital in Nigeria. Niger J Clin Pract 2018;21:1044-9.

Access this article online

Quick Response Code:



Website: www.njcponline.com

DOI: 10.4103/njcp.njcp_380_17

anterior and posterior malleolar folds.^[1] Tympanic membrane conducts sound waves across the middle ear and protects the middle ear cleft from infection.^[2]

Tympanic membrane perforation occurs when there is a break in its continuity, resulting in a hole with direct communication between the external auditory canal and the middle ear cleft. This increases the potential to middle ear cleft infection with a resultant hearing impairment.^[3]

Previous studies have reported a wide range of prevalence for tympanic membrane perforation (9%–47%) among patients injured by explosion.^[4,5] The prevalence of tympanic membrane perforation is on the increase in developing countries due to middle ear infections, resulting from malnutrition, overcrowding, frequent upper respiratory tract infections due to poverty, and ignorance.^[6,7] There is also increase in violence from political, economic, and religious unrest.

Etiologically, tympanic membrane perforations may be secondary to inflammation, trauma, and tumor. Inflammatory causes are due to acute suppurative otitis media and chronic suppurative otitis media. Traumatic tympanic membrane perforation can be due to direct trauma, acoustic trauma, barotrauma, and iatrogenic causes. Perforations secondary to inflammatory causes may heal spontaneously if the infection is adequately treated unless there is associated Eustachian tube dysfunction.^[8] Traumatic perforations tend to heal spontaneously within 3 months.

Tympanic membrane perforation may be classified based on the duration, size, and location of perforation. Tympanic membrane perforation is acute when it is <3 months in duration, while it is chronic perforation when it is >3 months in duration. Classification based on the size of tympanic membrane perforation depends on the extent of perforation, and they are divided into small, medium, large, subtotal, or total perforation.^[9,10] This may also be divided into percentages that is from 1% to 100% or graded from 1 to 4. Based on the locations of the perforation on the tympanic membrane, they may be central, marginal, and attic perforation.^[4,11] In central perforation, the perforation is within the pars tensa or with the annulus intact. However, in marginal perforation, there is destruction of the annulus and the sulcus tympanicus. The attic perforations involve the pars flaccida and usually associated with cholesteatoma.^[12]

There is a paucity of literature on perforation of tympanic membrane in developing countries and Nigeria, in particular. This study aimed at determining the clinicoepidemiological pattern, etiological factors,

clinical presentation, and management of tympanic membrane perforation in a tertiary hospital in Nigeria.

MATERIALS AND METHODS

This was a prospective, hospital-based study of patients with perforated tympanic membrane. The study was conducted in the Ear, Nose, and Throat Department of Ekiti State University Teaching Hospital, Ado Ekiti, Nigeria. The study was carried out over a period of 5 years (September 2012 to August 2017).

Informed consent was obtained from patients/parents/guardian, and consented patients were enrolled in the study.

All patients with a clinical history suggestive of/findings of tympanic membrane perforation were enrolled in the study. Detailed clinical history and examination were obtained from patients using interviewer-assisted questionnaire. The data obtained were on sociodemographic features (such as age, sex, and occupation). Detailed data were also obtained on ear symptoms such as hearing loss, tinnitus, itching, ear pain, vertigo, ear discharge, and duration of symptoms. History on the past illness, ear picking, ototoxic drugs, ear trauma, and ear instrumentation/surgery was also taken.

Detailed ear examination and tympanic membrane perforation assessment were performed using otoscope and otomicroscope. Eardrum perforation grading was made by estimating the relative size of the perforations: grade 1 perforation was defined as a pinpoint or linear tear up to 2 mm, grade 2 was defined as small perforation <25% of the tympanic membrane, grade 3 was defined as medium perforation 25%–50% of the tympanic membrane, and grade 4 was a large perforation >50% of the tympanic membrane.

Pure tone audiometry was performed with the determinations of air and bone conductions at 500, 1000, 2000, and 4000 Hz.

A conservative management approach was adopted for uncomplicated perforation. When there was associated bloody, pus, or watery discharge, nasal decongestant and oral/systemic antibiotics were administered to treat infection. The patients were advised to keep the ear dry. All patients were advised to present if there is recurrent ear discharge. All the patients were then followed up and assessed in the clinic.

Data collected were collated and analyzed using Statistical Package for the Social Sciences (SPSS, Version 16.0. for windows, Chicago II, USA). The data were expressed by table, percentage, bar charts, and pie charts.

Ethical clearance was obtained from the Ethics and Research Committee of the Institution.

RESULTS

A total of 6771 patients were seen in the department during the study period, out of which 529 patients had tympanic membrane perforation. The prevalence of tympanic membrane perforation in this study was 7.8%. All age groups were affected by tympanic membrane perforation. Highest percentage of the participants, 141 (26.7%), were within the age group of 31–40 years. Figure 1 illustrates the age group distribution of patients with tympanic membrane perforation.

There were 368 (69.6%) males and 161 (30.4%) females, with a male-to-female ratio of 2:1. Urban resident patients accounted for 331 (62.6%) while rural resident accounted for 198 (37.4%). Based on educational level of our patients, Primary was the highest representing 173 (32.7%), followed in descending order by secondary in 144 (27.2 %), preschool in 126 (23.8%) and graduate in 86 (16.3%). Regarding patients’ occupation, most common was students/apprentice in 189 (35.7%) followed by artisans in 87 (16.4%) and driver in 78 (14.7%). Table 1 demonstrates the sociodemographic features of patients with tympanic membrane perforation.

The associated symptoms among our patients were otorrhea in 431 (81.5%), otalgia in 385 (72.8%), and tinnitus in 295 (55.7%). Other presenting symptoms were hearing impairment in 278 (52.6%) and aural fullness in 249 (47.1%) [Figure 2].

Table 1: Sociodemographic features of patients with tympanic membrane perforation

Sociodemographic features	n (%)
Sex	
Male	368 (69.6)
Female	161 (30.4)
Residential	
Urban	331 (62.6)
Rural	198 (37.4)
Education level	
Preschool	126 (23.8)
Primary	173 (32.7)
Secondary	144 (27.2)
Postsecondary	86 (16.3)
Patients occupation	
Student/apprentice	189 (35.7)
Applicant	64 (12.1)
Business	6 (1.1)
Driver	78 (14.7)
Industrial worker	51 (9.6)
Farming	54 (10.2)
Artisans	87 (16.4)

In this study, chronic suppurative otitis media was associated with tympanic membrane perforation in 230 (43.5%) patients followed by acute suppurative otitis media in 150 (28.4%). However, trauma and aural mass were also associated with tympanic membrane perforation in 142 (26.8%) and 7 (1.3%) patients, respectively [Figure 3].

Unilateral tympanic membrane perforation was more common than the bilateral perforation; 518 (79.0%) for the former and 111 (21.0%) for the latter, respectively. The left ear tympanic membrane perforation was more common than right ear tympanic membrane perforation and accounted for 232 (43.9%) and 186 (35.2%), respectively. In terms of size, the most predominant grade is grade 1 tympanic membrane perforation in 208 (39.3%) patients. Other grades are grade 2, grade 3, and grade 4 which accounted for 171 (32.3%), 123 (23.3%), and 27 (5.1%), respectively. In this study, majority of the tympanic membrane perforation was central in 202 (38.2%), anterior central in 171 (32.3%), and posterior central in 102 (19.3%). The less common site of tympanic membrane perforation was 39 (7.4%) marginal and 15 (2.8%) attic perforation, which is illustrated in Table 2.

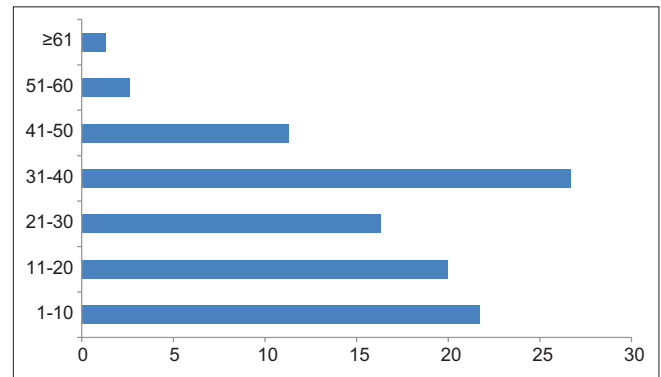


Figure 1: Age group (years) distribution of the patients with tympanic membrane perforation

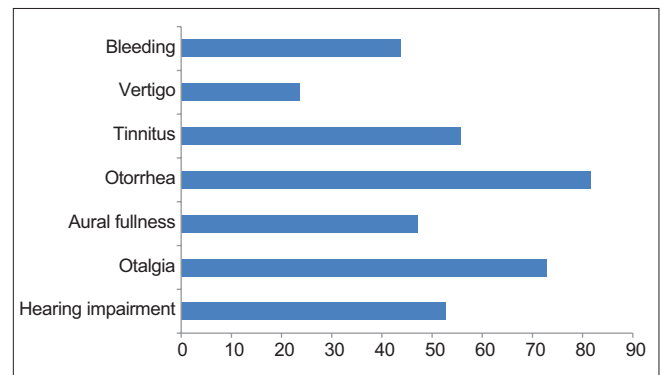


Figure 2: Clinical features of the patients with tympanic membrane perforation

Table 2: Features of tympanic membrane perforation among the patients

Features	n (%)
Lateralization	
Left	232 (43.9)
Right	186 (35.2)
Bilateral	111 (21.0)
Size	
Grade 1	208 (39.3)
Grade 2	171 (32.3)
Grade 3	123 (23.3)
Grade 4	27 (5.1)
Location	
Attic	15 (2.8)
Central	202 (38.2)
Marginal	39 (7.4)
Anterior central	171 (32.3)
Posterior central	102 (19.3)

Table 3: Pattern of hearing impairment

Hearing impairment	n (%)
Type of hearing impairment	
Conductive	326 (61.6)
Sensorineural	66 (12.5)
Mixed	69 (13.1)
Degree of hearing impairment (dB)	
Normal (<26)	68 (12.9)
Mild (26-40)	249 (47.1)
Moderate (41-55)	133 (25.1)
Moderate-severe (56-70)	66 (12.5)
Severe (71-90)	13 (2.5)
Profound (>90)	0 (0)

Table 4: Management of tympanic membrane perforation

Treatment duration	n (%)
Complications	
Hearing loss	278 (52.6)
Tinnitus	137 (25.9)
Infection/reinfection	126 (23.8)
Aural granulation/polyps	22 (4.2)
Treatment offered	
Conservative therapy	425 (80.3)
Minor surgery	104 (19.7)
Referral	36 (6.8)
Treatment outcome	
Healing after 3 months	431 (81.5)
Nonhealing after 3 months	98 (18.5)
Loss to follow-up	29 (5.5)

Major sources of referral were general practitioners and pediatricians which were 190 (35.9%) and 123 (23.3%), respectively. Minor referral was from casualty officer in 84 (15.9%) and self-reporting in 81 (15.3%) [Figure 4].

In this study, conductive hearing impairment is the most common type of hearing impairment and accounted for 326 (61.6%) followed by sensorineural hearing impairment in 134 (25.3%) and mixed hearing impairment in 69 (13.1%). The common degree of hearing impairment was mild and moderate, and they accounted for 249 (47.1%) and 133 (25.1%), respectively. Less common degree of hearing impairment in this study was moderate-severe and severe in 66 (12.5%) and 13 (2.5%), respectively. This is further demonstrated in Table 3.

Most common complication of tympanic membrane perforation was hearing impairment in 278 (52.6%) followed by 137 (25.9%) tinnitus and 126 (23.8%) infection. Majority of treatment offered to the patients was conservative therapy in 425, fat patches in six patients, while surgical intervention in 98 patients. The patients who had tympanic membrane perforation healed at the end of 3 months were 431 (81.5%) while those with nonhealed tympanic membrane perforation after 3 months were 98 (18.5%), which is shown in Table 4.

DISCUSSION

Tympanic membrane perforation is one of the most common otological signs and symptoms encountered in most otorhinolaryngological, head, and neck practice. The prevalence of tympanic membrane perforation in this study was 7.8% and accounted for all patients seen in Ear, Nose, and Throat Department. This high prevalence is likely due to peculiarity of developing country where this study was done with high incidence of malnutrition, overcrowding, frequent upper respiratory tract infections, poverty, and ignorance.^[6,13]

In this study, there was high prevalence of tympanic membrane perforation among the children. This includes preschool age group and primary school pupils. This is most likely due to high incidence of upper airway infection and physical violence in this age group. These findings are in agreement with the findings of previous studies.^[14,15]

There was male preponderance over female in this study. Men are highly adventurous group, more prone to injuries, and exposed to infection in their day-to-day activities. This is similar to the findings in previous studies.^[14,16,17] Other studies showed a contrary trend in their record.^[18,19]

Otorrhea was the most common clinical presentation in this study. This otorrhea is mostly mucopurulent arising from microbial activities from the middle cleft infection. These findings are different from the record in other studies.^[14,17,20,21]

Unilateral tympanic membrane perforation recorded a higher prevalence among the studied patients, and left ear was more commonly affected than the right ear. This is in line with the recorded value from other similar study findings.^[22]

Chronic suppurative otitis media was the most common finding associated with tympanic membrane perforation in this study. A study on pattern of tympanic membrane perforation in another center revealed similar result.^[13] This is followed by acute suppurative otitis media. Patients with acute suppurative otitis media usually present after the 3-month duration of failed self-medication. Contrary to these findings, another study recorded trauma as the major etiological factor for tympanic membrane perforation.^[22,23]

In this study, smaller grade 1 tympanic membrane perforation was more common while the larger grade 4 tympanic membrane perforation was less common. This might have accounted for the spontaneous closure in some of our patients. In another study, their findings were predominated with larger perforations.^[24]

In this study, the most tympanic membrane perforations were in the central, anterior central, and posterior central portions of the tympanic membrane. The central portion is more predisposed to rupture from pressure. This is because the central portion of the pars tensa is the most dependent part of the tympanic membrane with poor blood supply.^[25] The marginal tympanic membrane perforation was the least common in this study.^[25]

In this study, the sources of referral of patients with tympanic membrane perforation to otorhinolaryngologist for expert review and management were mainly from general practitioners and pediatricians followed by casualty officer. This may be because these are the first contact of the patients to seek treatments.

The findings of this study also showed that conductive hearing loss is more common than sensorineural hearing loss and mixed hearing loss in the patients. This is due to loss of ossicular coupling in perforation of the tympanic membrane, which usually causes a loss that ranges from negligible to 50 dB.^[26] Disease process in the middle ear, apart from causing damages to tympanic membrane and ossicular chain, may extend and involve inner ear, thereby causing mixed hearing loss.

In this study, hearing loss increased with increase in size of perforation at each frequency due to hydraulic action arising from the difference in the area of footplate.^[27] When the surface area decreased, there is decrease in amplification and hearing loss will be proportional to the size of perforated tympanic membrane.^[28] Furthermore,

in this study, pure tone audiometric results showed no differences or mild variations in the air–bone gaps at any frequency with relation to location of perforation, i.e., anterior versus posterior perforation. Contrary to widely held clinical view, the posterior perforations result in larger hearing losses than anterior perforations.

All patients with dry ear or with serosanguinous discharge were treated conservatively. The perforated tympanic membrane healed spontaneously in majority. Patients with infected perforated tympanic membrane were managed conservatively using antibiotics, aural toileting, and nasal decongestant to eliminate infection and achieve dry ear. Minor surgeries like Aural polypectomy was done for patients with aural polyps/granulation tissue. Associated complications in this study were aural polyps and infection from rhinosinusitis or from external auditory canal. Associated complications and size of tympanic membrane perforation were determinants of healing rate in this study. Failures of closure of tympanic membrane perforation after 3 months were the major sources of referral to other centers with facilities for tympanoplasty.

CONCLUSION

Tympanic membrane perforation is a common otological condition from mainly ear infections and traumatic causes. At presentation, size and location of perforation vary which may be due to duration of infection or the traumatic causes. The size of perforation and infection determines the duration of closure of the perforation. When conservative therapy failed, prompt referral to other center with facilities for tympanoplasty is advised.

Financial support and sponsorship

Nil.

Conflicts of interest

There are no conflicts of interest.

REFERENCES

1. Voss SE, Rosowski JJ, Merchant SN, Peake WT. Non-ossicular signal transmission in human middle ears: Experimental assessment of the “acoustic route” with perforated tympanic membranes. *J Acoust Soc Am* 2007;122:2135-53.
2. Pickles JO. Physiology of hearing. In: Gleeson M, Browning GG, Burton MJ, Clarke R, Hibbert J, Jones NS, *et al.*, editors. *Scott Brown's Otorhinolaryngology Head and Neck Surgery*. 7th ed., Vol. 3. London: Arnold; 2008. p. 3176-206.
3. Gulya AJ, Glasscock ME. *Glasscock-Shambaugh Surgery of the Ear*. 5th ed. Spain: BC Decker Inc.; 2003. p. 400-20.
4. Ritenour AE, Wickley A, Ritenour JS, Kriete BR, Blackbourne LH, Holcomb JB, *et al.* Tympanic membrane perforation and hearing loss from blast overpressure in Operation Enduring Freedom and Operation Iraqi Freedom Wounded. *J Trauma* 2008;64:S174-8.
5. Almog G, Luria T, Richter E, Pizov R, Bdolah-Abram T, Mintz Y, *et al.* Can external signs of trauma guide management?

- Lessons learned from suicide bombing attacks in Israel. *Arch Surg* 2005;140:390-3.
6. Ologe FE, Nwawolo CC. Prevalence of Chronic Suppurative Otitis Media (CSOM) among school children in a rural community in Nigeria. *Niger Postgrad Med J* 2002;9:63-6.
 7. Ibekwe TS, Ijaduola GT, Nwaorgu OG. Tympanic membrane perforation among adults in West Africa. *Otol Neurotol* 2007;28:348-52.
 8. Dhingra PL. Diseases of the ear. In: Dhingra PL, Dhingra S, editors. *Diseases of Ear, Nose and Throat*. 4th ed. New Delhi: Elsevier; 2007. p. 3-13, 33, 67.
 9. Hsu CY, Chen YS, Hwang JH, Liu TC. A computer program to calculate the size of tympanic membrane perforations. *Clin Otolaryngol Allied Sci* 2004;29:340-2.
 10. Saliba I, Abela A, Arcand P. Tympanic membrane perforation: Size, site and hearing evaluation. *Int J Pediatr Otorhinolaryngol* 2011;75:527-31.
 11. Oluwole M, Mills RP. Tympanic membrane perforations in children. *Int J Pediatr Otorhinolaryngol* 1996;36:117-23.
 12. Gelfand SA. *Essentials of Audiology*. 3rd ed. New York: Thieme Medical Publishers; 2009. p. 171-2.
 13. Olowookere SA, Ibekwe TS, Adeosun AA. Pattern of tympanic membrane perforation in Ibadan: A retrospective study. *Ann Ib Postgrad Med* 2008;6:31-3.
 14. Afolabi OA, Aremu SK, Alabi BS, Segun-Busari S. Traumatic tympanic membrane perforation: An aetiological profile. *BMC Res Notes* 2009;2:232.
 15. Ediale J, Adobamen PR, Ibekwe TS. Aetiological factors and dimension of tympanic membrane perforation in Benin City, Nigeria. *Port Harcourt Med J* 2017;11:55-9.
 16. Orji FT, Agu CC. Determinants of spontaneous healing in traumatic perforations of the tympanic membrane. *Clin Otolaryngol* 2008;33:420-6.
 17. Raj R, Meena SK, Meena DR, Meena M. A study on fate of traumatic tympanic membrane perforation. *Indian J Anat Surg Head Neck Brain* 2016;2:76-8.
 18. Maharjan M, Kafle P, Bista M, Shrestha S, Toran KC. Observation of hearing loss in patients with chronic suppurative otitis media tubotympanic type. *Kathmandu Univ Med J (KUMJ)* 2009;7:397-401.
 19. Ibekwe TS, Adeosun AA, Nwaorgu OG. Quantitative analysis of tympanic membrane perforation: A simple and reliable method. *J Laryngol Otol* 2009;123:e2.
 20. Onyeagwara NC, Okhakhu AL, Braimah OE. A retrospective study of traumatic tympanic membrane perforation at the University of Benin Teaching Hospital, Nigeria. *Ann Biomed Sci* 2014;13:83-92.
 21. da Lilly-Tariah OB, Somefun AO. Traumatic perforation of the tympanic membrane in University of Port Harcourt Teaching Hospital, Port Harcourt, Nigeria. *Niger Postgrad Med J* 2007;14:121-4.
 22. Sarojamma SR, Satish HS. A clinical study of traumatic perforation of tympanic membrane. *J Dent Med Sci* 2014;13:24-8.
 23. Orji FT, Agu CC. Patterns of hearing loss in tympanic membrane perforation resulting from physical blow to the ear: A prospective controlled cohort study. *Clin Otolaryngol* 2009;34:526-32.
 24. Bhusal CL, Guragain RP, Shrivastav RP. Size of tympanic membrane perforation and hearing loss. *JNMA J Nepal Med Assoc* 2006;45:167-72.
 25. Maqbool M. Anatomy of the ear. In: Maqbool M, Maqbool S, editors. *Text Book of Ear, Nose and Throat Diseases*. 11th ed. New Delhi: Jaypee Brothers Medical Publishers; 2007. p. 7-22.
 26. Manolidis S. Closure of tympanic membrane perforations. In: Gulya AJ, Glasscock ME, editors. *Glasscock-Shambaugh Surgery of the Ear*. 5th ed. Spain: BC Decker Inc.; 2003. p. 400-20.
 27. Ahmad SW, Ramani GV. Hearing loss in perforations of the tympanic membrane. *J Laryngol Otol* 1979;93:1091-8.
 28. Chun SH, Lee DW, Shin JK. A clinical study of traumatic perforation of tympanic membrane, Seoul, Korea: Department of Otolaryngology. *Hanil Gen Hosp* 2010;113:679-86.